

UCLA

Proceedings of UCLA Health

Title

Management of a Pregnant Woman with Marfan Syndrome and an Ascending Aorta Pseudoaneurysm

Permalink

<https://escholarship.org/uc/item/4k38r9xx>

Journal

Proceedings of UCLA Health, 21(1)

Authors

Wolfe, Diana S.

Criley, John

Yonekura, Margaret L.

et al.

Publication Date

2017-04-17

CLINICAL VIGNETTE

Management of a Pregnant Woman with Marfan Syndrome and an Ascending Aorta Pseudoaneurysm

Diana S. Wolfe,¹ M.D., MPH; John Michael Criley,² M.D., Margaret L. Yonekura,³ M.D., and Priya Pillutla,² M.D.

¹Department of Obstetrics and Gynecology and Women's Health Albert Einstein College of Medicine, Bronx, NY

²Division of Cardiology, Harbor-UCLA Medical Center, Torrance, CA

³Dignity Health, California Hospital Medical Center, Los Angeles, CA

Introduction

Marfan syndrome is an autosomal dominant connective tissue disorder caused by mutations in the extracellular matrix protein fibrillin-1.¹ The most feared sequelae are aortic aneurysm and aortic dissection. Aortic pseudoaneurysms (contained ruptures) in patients with Marfan syndrome are described in the literature but nearly always as a complication of prior aortic surgery. We describe a patient with a 70 mm dilation of the aortic root with spontaneous ascending aortic pseudoaneurysm who survived pregnancy and delivery after declining cardiothoracic surgery.

Case

A 33-year-old Mexican female was referred to our high-risk obstetric clinic at 8-weeks gestation. Her past medical history was significant for Marfan syndrome, diagnosed at age 5 in Mexico. She had no cardiopulmonary complaints. Her previous pregnancy was in Mexico, delivered by Cesarean at 35 weeks due to premature preterm rupture of membranes. Reportedly, an aortic dissection had been detected by echocardiography and remained stable throughout that pregnancy. Of note, the patient was a Jehovah's Witness, and she informed her physicians that she would not accept blood products under any circumstance even it would save her life.

Transthoracic echocardiogram showed normal left ventricular systolic function with an estimated ejection fraction of 60-65%. The aortic root diameter was 66 mm. There was a localized aortic pseudoaneurysm with a large entry tear above the sinuses of Valsalva but confined to the proximal ascending aorta. Moderate, central aortic regurgitation was also present.

Cardiac computed tomography with contrast (Figure 1) showed that the aortic root was dilated to 70 mm with a focal pseudoaneurysm of the aortic root extending to the proximal ascending aorta at the level of the pulmonary artery bifurcation. An entry tear was visible immediately above the ostium of the right coronary artery. True and false lumens could not be identified, and the morphological characteristics were most consistent with pseudoaneurysm rather than dissection.

The patient was informed that, given the large size of her aortic root with the presence of a pseudoaneurysm, the risk of complications or death would rise as the pregnancy progressed. Urgent resection of the proximal aortic root and valve with root and aortic valve replacement were recommended, but the patient declined surgery due to the risk of fetal demise and her unwillingness to accept blood products as a Jehovah's Witness. The patient was offered genetic testing for the fetus but declined. An anatomy scan and a fetal echocardiogram were performed at 20 and 24 weeks' gestation revealing no fetal anomalies. She had subsequent fetal growth scans every 4 weeks because of risk for intrauterine growth restriction. She reported increasing dyspnea and fatigue as the pregnancy progressed.

An interdisciplinary meeting was held with the cardiology, anesthesia, and obstetric teams to create a pregnancy and delivery plan. It was decided to manage the patient as follows: 1) maintain a blood pressure of 90-100/50 mm Hg; 2) begin metoprolol tartrate to reduce blood pressure, heart rate, and aortic shear stress; and 3) avoid all medications that could potentially increase blood pressure (including terbutaline, vasopressor agents and methergine). All teams were made aware of the increased risk for premature preterm rupture of membranes, cervical incompetence, and preterm labor. With the awareness that greatest risk for pseudoaneurysm rupture would be during the third trimester and while in labor, a plan was made for elective repeat Cesarean section at 34 weeks' gestation following steroid administration. She would be delivered prior to 34 weeks if she were to develop pre-eclampsia, go into spontaneous labor, or develop premature preterm rupture of membranes.

At 33 weeks and 5 days, the patient went into preterm labor. Tocolysis with magnesium sulfate and steroid injection were administered upon admission. She was then taken to the operating room and delivered a male fetus weighing 2675 grams via repeat Cesarean section. This was performed using epidural anesthesia with hemodynamic monitoring via an arterial line. Bilateral tubal ligation was performed per the patient's request. Post-operatively, the patient was transferred

to the cardiac intensive care unit where she was monitored closely. There were no complications, and she was discharged home on post-operative day 4.

At 18 months postpartum, the patient underwent bioprosthetic aortic valve replacement with placement of a 30 mm Hemashield Dacron graft to replace the aortic root. The procedure was performed by a cardiothoracic surgeon specializing in bloodless techniques.

Discussion

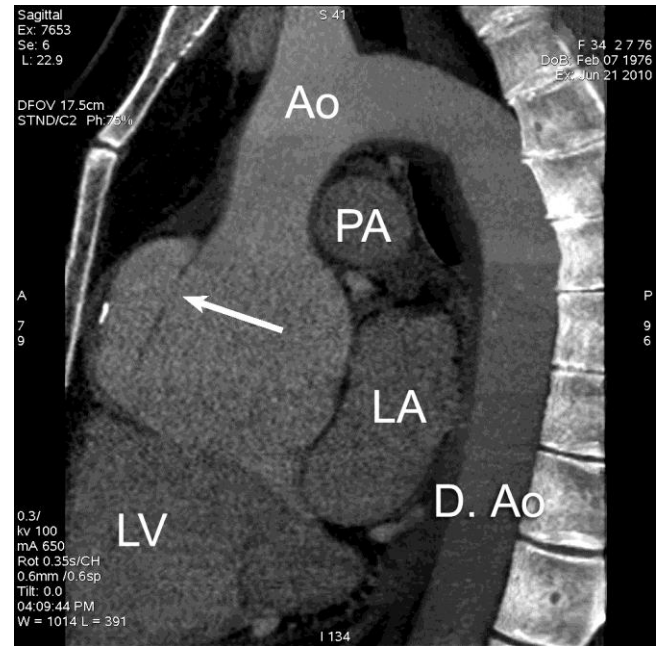
Women with Marfan syndrome have an increased risk of aortic dissection during pregnancy,²⁻³ probably due to a combination of hemodynamic factors including heart rate and stroke volume (leading to increased shear stress) and hormonal factors.⁴ Although aortic dilation is a known cardiovascular sequela of Marfan syndrome and is a risk factor for dissection and/or rupture, aortic dissection may occur in the absence of aortic dilation.⁵

Aortic aneurysms consist of dilation with preservation of all three layers of the aortic wall. In contrast, pseudoaneurysms are a complete tear of one or more aortic layers, subsequently contained by the remaining layers. Although aortic pseudoaneurysms were historically (before the era of antibiotics) seen as a sequelae of endocarditis, they are now more commonly seen as a complication of aortic surgery.⁶ In patients with Marfan syndrome, for example, they may be encountered following the Bentall procedure (aortic valve replacement, aortic root replacement, and ascending aorta replacement with re-implantation of the coronary arteries).⁷⁻⁹ They may be small and clinically silent or they can cause symptoms if they are large and compress adjacent structures. For example, they have been reported to cause chest pain, either from compression of the coronary arteries or from compression of the pulmonary arteries.¹⁰

The present case is the first to report a pseudoaneurysm of the native aorta in the context of Marfan syndrome. Due to the risk of complete rupture, large or symptomatic pseudoaneurysms should be repaired surgically. Our patient's religious beliefs added additional complexity to her management because she did not wish to pursue either surgery or termination. Therefore, we proceeded with assertive blood pressure control with beta-blockade in order to reduce the shear stress on the aorta. Her mode of delivery, cesarean section, was preferred not only because of her history of cesarean delivery but because we wished to avoid the large increases in heart rate and blood pressure, which typically occur during vaginal delivery.

Figures

Figure 1. The arrow demonstrates a complete tear in the aorta, consistent with pseudoaneurysm rather than aneurysm. The aortic root is severely dilated. Abbreviations: Ao – aorta, PA – pulmonary artery, LA – left atrium, D. Ao – descending aorta, LV – left ventricle.



REFERENCES

1. Dietz HC, Cutting GR, Pyeritz RE, Maslen CL, Sakai LY, Corson GM, Puffenberger EG, Hamosh A, Nanthakumar EJ, Curristin SM, et al. Marfan syndrome caused by a recurrent de novo missense mutation in the fibrillin gene. *Nature*. 1991 Jul 25;352(6333):337-9. PubMed PMID: 1852208.
2. Goland S, Elkayam U. Cardiovascular problems in pregnant women with marfan syndrome. *Circulation*. 2009 Feb 3;119(4):619-23. doi:10.1161/CIRCULATIONAHA.104.493569. PubMed PMID: 19188522.
3. Rossiter JP, Repke JT, Morales AJ, Murphy EA, Pyeritz RE. A prospective longitudinal evaluation of pregnancy in the Marfan syndrome. *Am J Obstet Gynecol*. 1995 Nov;173(5):1599-606. PubMed PMID: 7503207.
4. Manalo-Estrella P, Barker AE. Histopathologic findings in human aortic media associated with pregnancy. *Arch Pathol*. 1967 Apr;83(4):336-41. PubMed PMID:4225694.
5. Lipscomb KJ, Smith JC, Clarke B, Donnai P, Harris R. Outcome of pregnancy in women with Marfan's syndrome. *Br J Obstet Gynaecol*. 1997 Feb;104(2):201-6. PubMed PMID: 9070139.
6. Sullivan KL, Steiner RM, Smullens SN, Griska L, Meister SG. Pseudoaneurysm of the ascending aorta following cardiac surgery. *Chest*. 1988 Jan;93(1):138-43. PubMed PMID: 3257182.
7. Kokotsakis JN, Lioulias AG, Foroulis CN, Skouteli EA, Milonakis MK, Bastounis EA, Boulafendis DG. Combined repair of ascending aortic pseudoaneurysm

and abdominal aortic aneurysm: in a patient with Marfan syndrome. *Tex Heart Inst J.* 2003;30(3):233-5. PubMed PMID: 12959210; PubMed Central PMCID: PMC197325.

8. **Navaravong L, Saab F, Cook JR, Peterman M, Flack J.** Ascending aortic pseudoaneurysm, a ticking bomb after cardiac surgery. *Cardiovasc Revasc Med.* 2011 May-Jun;12(3):177-80. doi: 10.1016/j.carrev.2010.02.001. Epub 2010 Oct 20. PubMed PMID: 21640936.
9. **Grapow MT, Matt P, Zerkowski HR, Bernet F.** Pseudoaneurysm in a marfan patient 16 years after Bentall operation. *Asian Cardiovasc Thorac Ann.* 2004 Jun;12(2):182-3. PubMed PMID: 15213091.
10. **Sabri MN, Henry D, Wechsler AS, DiSciascio G, Vetovec GW.** Late complications involving the ascending aorta after cardiac surgery: recognition and management. *Am Heart J.* 1991 Jun;121(6 Pt 1):1779-83. Review. PubMed PMID: 2035391.

Submitted April 17, 2017