

UCLA

UCLA Previously Published Works

Title

A Case of Concurrent Disseminated Coccidioidomycosis and Embryonal Carcinoma When Lice and Fleas Coexist

Permalink

<https://escholarship.org/uc/item/4jw6863f>

Authors

Ke, Michael

Heidari, Arash

Valdez, Michael

et al.

Publication Date

2022

DOI


10.1177/23247096221098339

Copyright Information

This work is made available under the terms of a Creative Commons Attribution-NonCommercial License, available at <https://creativecommons.org/licenses/by-nc/4.0/>

Peer reviewed

A Case of Concurrent Disseminated Coccidioidomycosis and Embryonal Carcinoma When Lice and Fleas Coexist

Journal of Investigative Medicine High Impact Case Reports
Volume 10: 1–5
© 2022 American Federation for Medical Research
DOI: 10.1177/23247096221098339
journals.sagepub.com/home/hic


Michael Ke, MD^{1,2}, Arash Heidari, MD^{1,2} , Michael Valdez, MD³ , Allen Tsiyer, MD³, Rasha Kuran, MD^{1,2}, and Royce Johnson, MD^{1,2}

Abstract

Coccidioidomycosis (CM) is a fungal infection endemic to the southwestern United States with a wide range of clinical presentations depending on the infected organ systems. Most infections are asymptomatic. Coccidioidomycosis causes a primary pulmonary infection and when symptoms occur, they most often resemble community-acquired pneumonia. One percent of cases disseminate, typically via hematogenous or lymphatic spread. It is in these cases that more severe symptoms may present and potentially overlap with those characteristics of other systemic illnesses. This is a case of CM disseminated to lymph nodes in a 24-year-old man with concomitant metastatic embryonal carcinoma. It is difficult to identify the primary etiology for many components of this patient's presentation, including diffuse lymphadenopathy and multiple pulmonary nodules. Furthermore, the relationship between these 2 concurrent disease processes is not entirely clear. Factors that may contribute include the well-known phenomenon of locus minoris resistentiae (LMR) or potentially a shared immune failure between infectious organisms and malignant cells.

Keywords

coccidioidomycosis, embryonal carcinoma, locus minoris resistentiae

Introduction

Coccidioidomycosis (CM), also known as “valley fever,” is a disease caused by the dimorphic fungi, *Coccidioides immitis* and *Coccidioides posadasii*, which are typically found in the soils of the southwestern United States and northwestern Mexico. Approximately 60% of infections are asymptomatic while 40% manifest with symptoms. Coccidioidomycosis is primarily a pulmonary infection with symptoms similar to community-acquired pneumonia, such as fever, cough, chest pain, and dyspnea.¹

One percent of infections lead to disseminated disease which may involve nearly any organ system in the body. The central nervous system (CNS), bones, joints, skin, and soft tissue are most commonly involved.¹ Immunosuppression is one of the most important risk factors for disseminated disease.² Locus minoris resistentiae (LMR), which refers to an area of decreased resistance in any region of the body that leaves it more vulnerable to future infections or malignancy, may also contribute to the pathogenesis of lymphohematogenous dissemination in CM.³

Testicular cancer is the most common cancer in men aged 15 to 44 years of age. The classic presentation involves a

painless testicular mass. Testicular pain is present in less than 10% of cases. One of the most common sites of metastasis includes the retroperitoneal lymph nodes, including the inter-aortocaval, para-aortic, and preaortic nodes. Patients with retroperitoneal lymphadenopathy may present with abdominal or back pain in addition to systemic symptoms.⁴ Metastasis to the lungs are also well documented and usually present as multiple cavitory or necrotic pulmonary nodules measuring greater than 5 mm. Chemotherapy followed by possible surgical removal of any remaining nodules is the standard treatment regimen.⁵

¹Department of Internal Medicine, Division of Infectious Diseases, UCLA at Kern Medical Center, Bakersfield, CA, USA

²Valley Fever Institute, Bakersfield, CA, USA

³Department of Internal Medicine, UCLA at Kern Medical Center, Bakersfield, CA, USA

Received November 15, 2021. Revised March 16, 2022. Accepted April 16, 2022.

Corresponding Author:

Michael Valdez, MD, Department of Internal Medicine, UCLA at Kern Medical Center, 1700 Mount Vernon Ave, Bakersfield, CA 93306, USA. Email: Michael.valdez@kernmedical.com



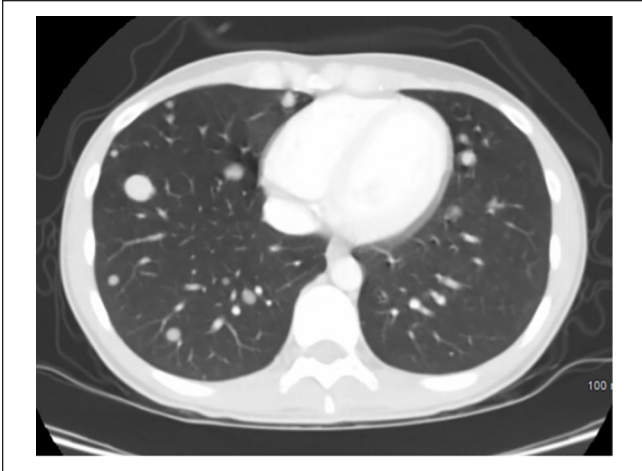

Image 1. Computed tomography (CT) scan of the chest with contrast showing multiple pulmonary nodules.

The unique case of a 24-year-old man with multiple pulmonary nodules and diffuse lymphadenopathy who was later diagnosed with concurrent disseminated CM and metastatic embryonal carcinoma is described herein.

Case Presentation

A 24-year-old Latin man from the central valley of California was in his usual state of health until he spontaneously developed a new rash. He presented to the emergency department (ED) and physical examination was positive for bilateral periorbital edema and erythema with raised, erythematous, hyperpigmented, and non-tender skin lesions located on the bilateral hands, arms, shins, neck, lower abdomen, and forehead. Initial differential diagnosis included CM, dermatomyositis, and psoriasis. Coccidioidomycosis serology obtained at this time showed non-reactive immunodiffusion (ID) IgM, very weakly reactive ID IgG, and complement fixation (CF) titer of <1:2. He was discharged with a plan to follow-up with a primary care physician; however, he was lost to follow-up.

Six weeks later, he returned to the hospital with 7.7 kg unintentional weight loss, progression of the rash, and new-onset bilateral shoulder and proximal thigh pain and weakness. Examination was consistent with heliotrope rash and tenderness to palpation of the shoulders and proximal thighs. Laboratory results were significant for elevated creatine kinase of 1089 U/L, C-reactive protein of 5.8 mg/L, and sedimentation rate of 47 mm/h. Diagnosis of dermatomyositis was made, and he was discharged with prednisone 60 mg daily and referral to the rheumatology clinic.

Two weeks later, the patient returned to the hospital with new-onset fever. Laboratory studies showed absolute eosinophil count elevated at 2.4×10^3 cells/ μ L. Additional work-up with repeat CM serology at this time was notable for an

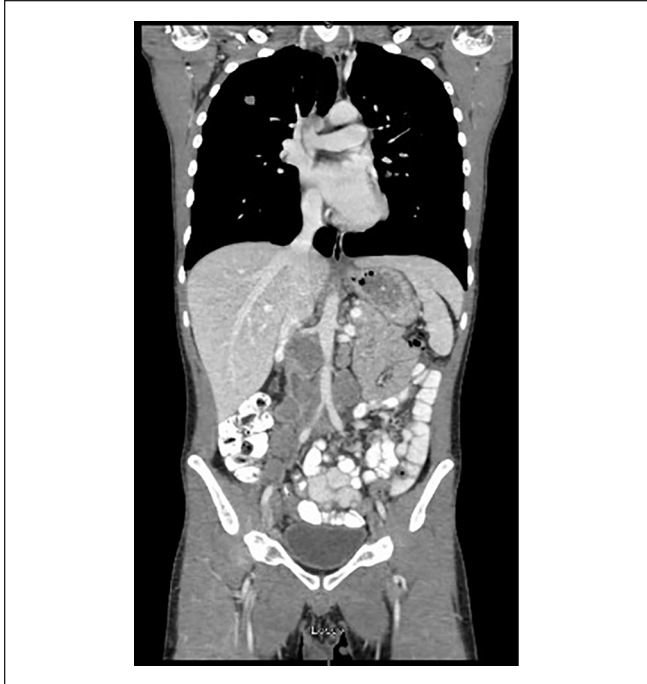


Image 2. Coronal computed tomography (CT) scan of the chest, pelvis, and abdomen with contrast showing multiple pulmonary nodules and pelvic/retroperitoneal lymphadenopathy.

increase in CF titer to 1:16. Imaging studies demonstrated a right iliac crest lytic lesion for which he underwent biopsy that was unfortunately not diagnostic. He was diagnosed with disseminated CM and discharged on fluconazole 800 mg daily, which he self-discontinued after 2 weeks due to dry skin.

Five weeks later, the patient developed a left gluteal soft tissue mass and non-tender sub-mandibular, left clavicular, and right inguinal lymph node enlargement. He also experienced an additional 4.5-kg unintentional weight loss since the previous visit. Computed tomography (CT) scan of the chest, abdomen, and pelvis showed numerous pulmonary nodules, diffuse retroperitoneal and pelvic lymphadenopathy, and destructive lesion in the iliac bone all suspicious for metastatic disease or lymphoma (Images 1-6). Coccidioidomycosis CF titers increased to 1:64 and patient was started on liposomal amphotericin B infusions for disseminated CM.

Patient initially experienced some improvement in clavicular and inguinal lymphadenopathy; however, shortly thereafter, he developed a new retroperitoneal mass and a new right testicular mass. He subsequently underwent right orchiectomy, right inguinal lymph node excision, and a CT-guided biopsy of the retroperitoneal mass. Histopathology from the orchiectomy and retroperitoneal mass biopsy both revealed non-seminomatous germ cell tumor (NSGCT) consistent with embryonal carcinoma (Images 7 and 8) while

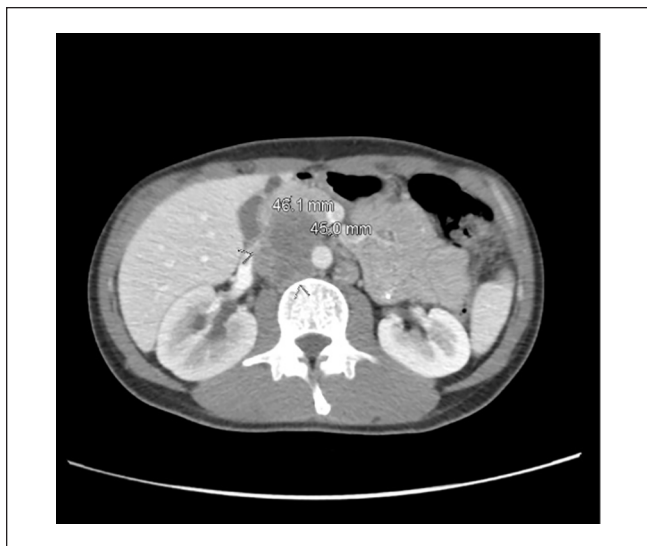

Image 3. Axial computed tomography (CT) scan of the abdomen and pelvis with contrast showing retroperitoneal lymphadenopathy below the right renal hilum resulting in compression of the right renal vein. Right-sided hydronephrosis is also present.

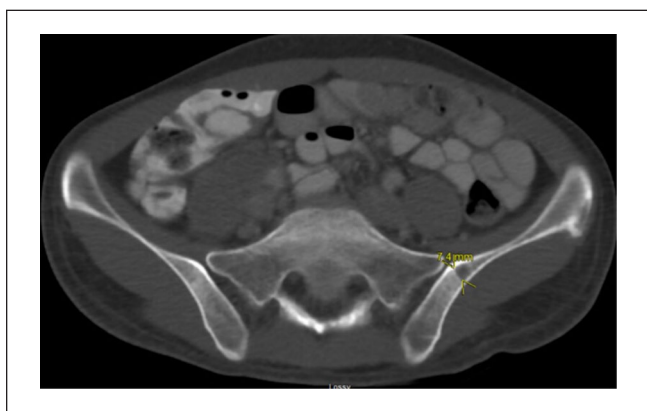

Image 4. Computed tomography (CT) scan of the abdomen and pelvis with contrast showing a focal lesion on the medial aspect of the iliac bone.

histopathology from right inguinal lymph node excision showed granulomatous inflammation with endospore spherules diagnostic for *Coccidioides immitis* (Image 9). He established care with oncology and was promptly started on chemotherapy with etoposide, ifosfamide, and cisplatin.

Patient completed 9 weeks of liposomal amphotericin B and subsequent nuclear medicine bone scan showed no definite suspicious foci of increased uptake. He was placed on fluconazole 600 mg daily (dose based according to renal function) and is on track to complete 4 to 6 cycles of chemotherapy. On subsequent clinic visits, weight, diffuse rash, as well as clavicular and inguinal lymphadenopathy were noted to be improved.

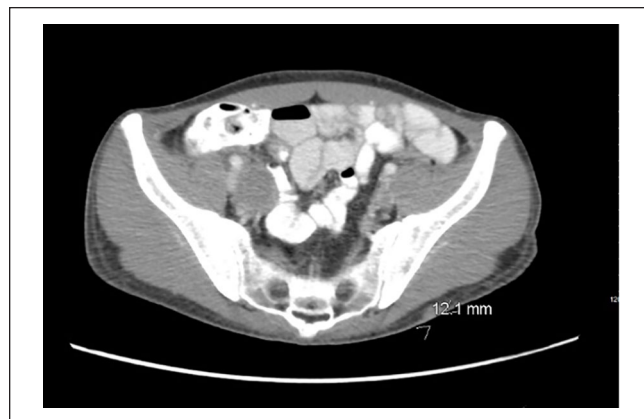


Image 5. Computed tomography (CT) scan of the abdomen and pelvis with contrast showing subcutaneous nodule with fat stranding in the left gluteal region.

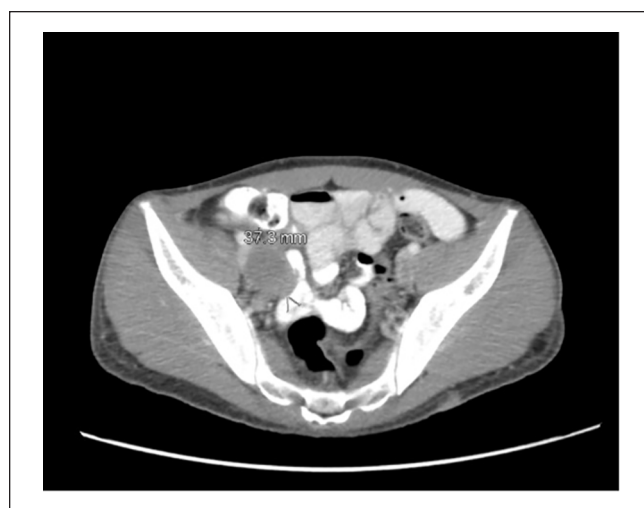

Image 6. Computed tomography (CT) scan of the abdomen and pelvis with contrast showing internal and external iliac chain lymphadenopathy in the right pelvic region.

Discussion

Risk factors for disseminated CM include Filipino or African ancestry and immunocompromised states such as diabetes, HIV/AIDS, pregnancy, and immunosuppressive medications including prednisone, chemotherapy, and tumor necrosis factor (TNF)-alpha inhibitors.^{2,6} One study in 2016 of 30 772 patients taking TNF-alpha inhibitors found that concurrent use of prednisone was associated with an increased risk of fungal infections, including CM.⁷ Administration of corticosteroids in patients with undiagnosed CM and concurrent malignancy has the potential to worsen prognosis, due to an increased risk of reactivation and dissemination.⁸ In the case of our patient, we notice a correlation in time between the administration of prednisone for presumed dermatomyositis in the setting of undiagnosed metastatic embryonal carcinoma and the reactivation of CM.

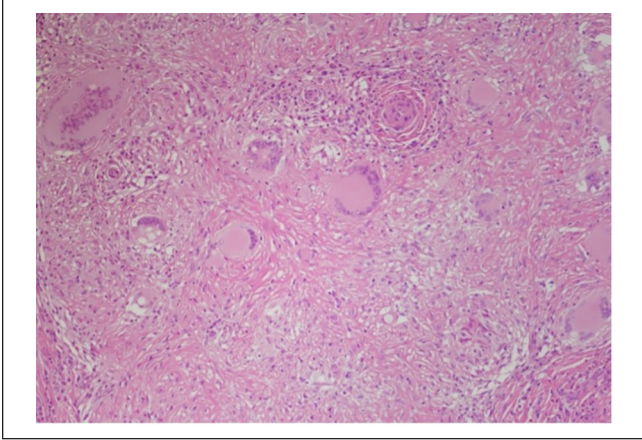


Image 7. Hematoxylin and eosin stain (10× magnification) of the retroperitoneal mass showing nonseminomatous germ cell tumor.

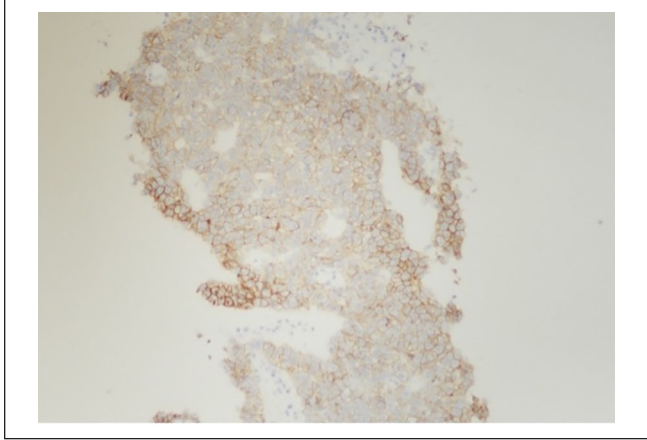


Image 8. CD30 stain (10× magnification) of the retroperitoneal mass showing nonseminomatous germ cell tumor consistent with embryonal carcinoma.

Infectious agents that are neither oncogenic nor oncolytic may contribute to carcinogenesis. These organisms may do so via a shared immune response, such as causing infected cells to display tumor-associated antigen-like proteins which activate the immune cascade or inflammatory response.⁹ Bacteria or fungi may activate T-helper (Th) 17 cells to down-regulate Treg cells and therefore inhibit inflammatory resolution.⁹ The immunopathology associated with CM is believed to include both the innate and adaptive immune systems. Neutrophils, macrophages, and dendritic cells play a role and T-cell responses including Th1 and Th2 ratio and Th17 and regulatory T-cell ratio are important.⁹ Overall, the shared immune response between infectious organisms and malignancy has been relatively unexplored and is an important topic for further research.

Locus minoris resistentiae may occur due to changes in the microenvironment secondary to previous trauma or injury and results in decreased resistance. As a result, infection, inflammatory processes, and malignancy may localize to this area.^{3,10} One case series describes 2 patients with disseminated osseous CM and localization to sites of previous injuries.³ Prostaglandins released from damaged leukocytes at the site of an injury have been shown to stimulate the formation of *Coccidioides immitis* endosporulating spherules. Furthermore, mature spherules may not be susceptible to the neutrophil response.³ This constitutes a complex relationship between the pathogen, modified environment, and immune response which leaves the host more susceptible to infection.³ We hypothesize that our patient may have experienced a change in microenvironment due to undiagnosed metastatic embryonal carcinoma that rendered him more susceptible to the dissemination of CM to lymph nodes when he was started on prednisone.

Comorbidity is defined as the presence of more than one distinct condition in an individual. Although there are

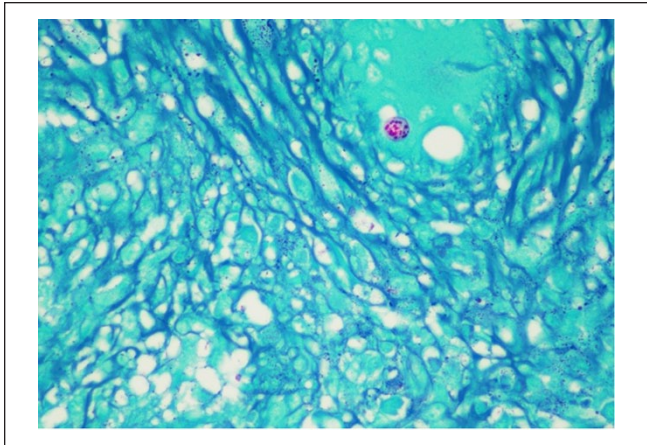


Image 9. Histopathology (10× magnification) of the right inguinal lymph node showing spherule with endospores diagnostic for *Coccidioides*.

several mechanisms that may contribute to comorbidity, including direct causation, associated risk factors, and heterogeneity, it is important to remember that in some cases there may be no etiological association between the 2 distinct disease processes.¹¹ Review of literature revealed that at least 2 cases of CM mimicking bone neoplasms and 1 case mimicking advanced ovarian carcinoma have been documented.^{12,13} Another single patient case report documented CM that presented with diffuse lymphadenopathy in a patient with history of marginal zone lymphoma requiring CT-guided biopsy in order to rule out recurrent malignancy.¹⁴ Our case demonstrates an overlap in symptoms and clinical presentation with unclear original etiology. Specifically, diffuse lymphadenopathy and pulmonary nodules may be characteristic of both disseminated CM and NSGCT. Ultimately, the exact relationship between

disseminated CM and metastatic embryonal carcinoma in our patient remains unclear; however, we suspect that a combination of the LMR phenomenon and a shared immune response between *C immitis* and malignant embryonal carcinoma cells largely contribute to the pathogenesis.

Conclusions

As CM and several types of malignancies may have similar or overlapping clinical presentations, a thorough physical examination and tissue sampling are generally necessary to distinguish. In rare cases, coexistence may occur. “Läuse und Flöhe haben” a German phrase, which translates to “Having lice and fleas,” refers to having 2 reasons for a problem. Understanding the underlying etiology or identifying the relationship between the concomitant conditions is essential to formulate the most appropriate treatment plan. Our patient responded well to treatment regimens for both disseminated CM and embryonal carcinoma. Further research regarding LMR and the shared immune response between infectious organisms and carcinogenesis is necessary.

Declaration of Conflicting Interests

The author(s) declared no potential conflicts of interest with respect to the research, authorship, and/or publication of this article.

Funding

The author(s) received no financial support for the research, authorship, and/or publication of this article.

Ethics Approval

Ethical approval to report this case was obtained from the Kern Medical Institutional Review Board (IRB # 21085).

Informed Consent

Informed consent was obtained from the patient for their anonymized information to be published in this article.

ORCID iDs

Arash Heidari  <https://orcid.org/0000-0003-1091-348X>
Michael Valdez  <https://orcid.org/0000-0003-0340-9023>

References

1. Johnson RH, Sharma R, Kuran R, Fong I, Heidari A. Coccidioidomycosis: a review. *J Investig Med*. 2021;69(2):316-323.
2. Brown J, Benedict K, Park BJ, Thompson GR III. Coccidioidomycosis: epidemiology. *Clin Epidemiol*. 2013;5:185-197.
3. Sherpa N, Shah R, Nordstrom B, Palmares C, Heidari A, Johnson R. Locus minoris resistentiae in coccidioidomycosis: a case series. *J Investig Med High Impact Case Rep*. 2019;7:2324709619858110.
4. Marko J, Wolfman DJ, Aubin AL, Sesterhenn IA. Testicular seminoma and its mimics: from the radiologic pathology archives. *Radiographics*. 2017;37(4):1085-1098.
5. Jamil A, Kasi A. Lung metastasis. In: *Statpearls*. Treasure Island, FL: StatPearls Publishing; 2022.
6. Adam RD, Elliott SP, Taljanovic MS. The spectrum and presentation of disseminated coccidioidomycosis. *Am J Med*. 2009;122(8):770-777.
7. Salt E, Wiggins AT, Rayens MK, et al. Risk factors for targeted fungal and mycobacterial infections in patients taking tumor necrosis factor inhibitors. *Arthritis Rheumatol*. 2016;68(3):597-603.
8. Blair JE, Smilack JD, Caples SM. Coccidioidomycosis in patients with hematologic malignancies. *Arch Intern Med*. 2005;165(1):113-117.
9. Jacqueline C, Tasiemski A, Sorci G, et al. Infections and cancer: the “fifty shades of immunity” hypothesis. *BMC Cancer*. 2017;17(1):257.
10. Farmand D, Valdez MC, Moosavi L, Cobos E. Locus minoris resistentiae: two cases of malignant metastasis and review of literature. *J Investig Med High Impact Case Rep*. 2021;9:2324709621997248.
11. Valderas JM, Starfield B, Sibbald B, Salisbury C, Roland M. Defining comorbidity: implications for understanding health and health services. *Ann Fam Med*. 2009;7(4):357-363.
12. Li YC, Calvert G, Hanrahan CJ, Jones KB, Randall RL. Coccidiomycosis infection of the patella mimicking a neoplasm—two case reports. *BMC Med Imaging*. 2014;14:8.
13. Ellis MW, Dooley DP, Sundborg MJ, Joiner LL, Kost ER. Coccidioidomycosis mimicking ovarian cancer. *Obstet Gynecol*. 2004;104(5, pt 2):1177-1179.
14. Manning MA, Kuo PH, Yeager AM. Disseminated coccidioidomycosis masquerading as recurrent lymphoma. *BMJ Case Rep*. 2018;2018:bcr2018224965.