

UC Irvine

UC Irvine Previously Published Works

Title

Utility of common bile duct measurement in ED point of care ultrasound: A prospective study.

Permalink

<https://escholarship.org/uc/item/4gt978wt>

Journal

The American journal of emergency medicine, 36(6)

ISSN

0735-6757

Authors

Lahham, Shadi
Becker, Brent A
Gari, Abdulatif
et al.

Publication Date

2018-06-01

DOI

10.1016/j.ajem.2017.10.064

Peer reviewed



Contents lists available at ScienceDirect

American Journal of Emergency Medicine

journal homepage: www.elsevier.com/locate/ajemThe
American Journal of
Emergency Medicine

Utility of common bile duct measurement in emergency department point of care ultrasound: A prospective study

Shadi Lahham^{a,*}, Brent A. Becker^b, Abdulatif Gari^a, Steven Bunch^a, Maili Alvarado^a, Craig L. Anderson^a, Eric Viquez^a, Sophia C. Spann^a, John C. Fox^a

^a University of California, Irvine, Department of Emergency Medicine, 333 The City Boulevard West Suite 640, Orange 92868, CA, USA

^b York Hospital, Department of Emergency Medicine, York, PA, USA

ARTICLE INFO

Article history:

Received 10 October 2017

Received in revised form 19 October 2017

Accepted 24 October 2017

Available online xxxx

Keywords:

Common bile duct

Biliary ultrasound

Point of care ultrasound

Biliary disease

Cholelithiasis

ABSTRACT

Background: Measurement of the common bile duct (CBD) is considered a fundamental component of biliary point-of-care ultrasound (POCUS), but can be technically challenging.

Objective: The primary objective of this study was to determine whether CBD diameter contributes to the diagnosis of complicated biliary pathology in emergency department (ED) patients with normal laboratory values and no abnormal biliary POCUS findings aside from cholelithiasis.

Methods: We performed a prospective, observational study of adult ED patients undergoing POCUS of the right upper quadrant (RUQ) and serum laboratory studies for suspected biliary pathology. The primary outcome was complicated biliary pathology occurring in the setting of normal laboratory values and a POCUS demonstrating the absence of gallbladder wall thickening (GWT), pericholecystic fluid (PCF) and sonographic Murphy's sign (SMS). The association between CBD dilation and complicated biliary pathology was assessed using logistic regression to control for other factors, including laboratory findings, cholelithiasis and other sonographic abnormalities.

Results: A total of 158 patients were included in the study. 76 (48.1%) received non-biliary diagnoses and 82 (51.9%) were diagnosed with biliary pathology. Complicated biliary pathology was diagnosed in 39 patients. Sensitivity of CBD dilation for complicated biliary pathology was 23.7% and specificity was 77.9%.

Conclusion: Of patients diagnosed with biliary pathology, none had isolated CBD dilatation. In the absence of abnormal laboratory values and GWT, PCF or SMS on POCUS, obtaining a CBD measurement is unlikely to contribute to the evaluation of this patient population.

© 2017 Elsevier Inc. All rights reserved.

1. Introduction

Biliary disease is common in the United States. Approximately 20 million patients present to the emergency department (ED) annually with complaints related to cholelithiasis [1-4]. Laboratory serum testing is routinely performed, but is generally not sufficient to differentiate between specific biliary diagnoses [5-7]. The use of ultrasound (US) is instrumental in clarifying the diagnosis and guiding treatment [8-10]. In general, uncomplicated symptomatic cholelithiasis can be managed expectantly with symptom control and outpatient referral to surgery. Conversely, complicated biliary pathology, such as acute cholecystitis, choledocholithiasis and ascending cholangitis, warrants more urgent consultation and hospitalization for further diagnostic study or definitive treatment.

Several studies have shown that point of care ultrasound (POCUS) can lead to accurate diagnosis of biliary pathology and expedite patient

care [1,11-13]. POCUS of the right upper quadrant (RUQ) typically assesses for the presence of gallstones, gallbladder wall thickening, pericholecystic fluid (PCF), sonographic Murphy's sign (SMS) and common bile duct (CBD) dilatation [14,15]. Despite being considered a fundamental element of RUQ POCUS, proper identification and accurate measurement of the CBD can prove technically challenging [3,16]. In the face of uncertain CBD identification, the ability of normal laboratory tests and an otherwise normal RUQ US to exclude complicated biliary pathology would be of great clinical benefit. Prior research has suggested that CBD diameter yields limited unique clinical information in patients with cholecystitis and choledocholithiasis with normal laboratory values; however, there are no prospective studies to date that have confirmed these findings [17-21].

We sought to prospectively assess the importance of sonographic CBD measurement in evaluating patients for biliary pathology, particularly in the setting of normal laboratory values and an otherwise unremarkable biliary US. We predict that the incidence of concerning biliary pathology in patients with normal laboratory values and no significant ultrasound finding beyond uncomplicated cholelithiasis is small

* Corresponding author.

E-mail address: slahham@uci.edu (S. Lahham).

and measurement of the CBD in this setting is unlikely to alter diagnosis or change management. The primary objective of this study was to determine if there is any utility to measure a CBD diameter in patients with normal laboratory values and a RUQ POCUS without GWT, PCF and SMS for the diagnosis of complicated biliary pathology in ED patients.

2. Materials and methods

2.1. Study design

We performed a prospective, observational study of adult ED patients receiving serum laboratory studies and undergoing POCUS of the right upper quadrant (RUQ) for evaluation of potential biliary pathology. Final diagnoses were assessed with respect to POCUS findings and laboratory results to determine the relative contribution of CBD measurement.

2.2. Study setting and population

The study was performed at an academic level 1 trauma center with an emergency medicine residency and an emergency ultrasound fellowship program. The ED has an annual census of 50,000 visits with an ethnically and economically diverse patient population. The local institutional review board approved the study prior to screening or enrolling patients.

2.3. Selection of participants

We enrolled a convenience sample of adult patients presenting to the ED between November 2012 and September 2014 with abdominal pain and concern for biliary pathology based on the history and physical examination. Undergraduate emergency medicine research associates screened for potential patients daily between the hours of 8:00 am and 12:00 midnight. Patients were eligible for inclusion if they were at least 18 years old, able to provide written and verbal consent in English or Spanish, and were undergoing both a RUQ POCUS and serum laboratory testing as part of their clinical evaluation. All laboratory tests and imaging studies were performed at the discretion of the ordering physician. Patients were excluded if they were pregnant, incarcerated or did not meet inclusion criteria. The research student obtained informed written consent from eligible patients after discussion of the study with the treating physician.

2.4. Study protocol

Following the screening and consent process, included patients underwent laboratory blood work and a RUQ POCUS performed by the treating emergency physician. A total of 26 resident, fellow and attending physicians actively consented patients and performed the POCUS. Physician sonographers possessed various levels of training and did not receive any study-specific instruction regarding biliary sonography. Data collected included patient age, gender, body mass index (BMI), sonographic findings, laboratory values and final diagnosis. All data were recorded by research associates using a standardized data collection instrument. Images were stored on a secured picture archiving and communication system for review.

The following serum laboratory values were collected and considered abnormal if exceeding the institutional upper limit of normal range: alkaline phosphatase (ALP, >100 μ L), alanine aminotransferase (ALT, >40 μ L), aspartate aminotransferase (AST, >45 μ L), total bilirubin (TB, >1.6 mg/dL) and white blood cell count (WBC, >11,000/mcL) [15]. A given patient was considered to have “abnormal” labs if any one of the above laboratory values exceeded the corresponding upper limit of normal. All enrolled patients received at least the aforementioned tests. The decision to obtain additional laboratory studies, such as lipase, was left

to the discretion of the treating physician, but the results of these tests were not collected as part of the study.

Further management of the patient including CT scan or radiology performed ultrasound was left to the discretion of the treating physician based on their usual clinical approach. This also included specialist consultation, hospitalization or discharge from the ED. The gold standard was based on the final diagnosis which was collected directly from the emergency physician note for patients discharged from the ED and the hospital discharge summary for hospitalized patients. Final diagnosis included ERCP results and surgical pathology. Discharged patients were contacted by telephone approximately two weeks after initial presentation to determine if there was any change in final diagnosis or if they required another ED visit or hospitalization. If the patient was not reached at two weeks, calls continued monthly for up to 1 year. If a patient was unable to be reached via telephone for 1 year, the patient was excluded from the study.

Final diagnoses were classified as non-biliary or biliary. The latter was defined as any biliary tract pathology providing a likely etiology for the patient’s presenting complaint. This group was further classified into two categories: uncomplicated cholelithiasis (biliary colic) and complicated biliary pathology, which included any biliary diagnosis necessitating hospitalization for further diagnostic evaluation or definitive treatment, including, but not limited to, acute cholecystitis, choledocholithiasis, cholangitis and pancreatitis.

2.5. Ultrasound technique

All included patients underwent a POCUS performed by the treating emergency physician prior to review of blood work. The physician performing the ultrasound was blinded to laboratory results. No study-specific ultrasound training was provided, but all emergency medicine residents had completed a basic ultrasound training session at the time of matriculation to the program. This included 1 h of didactics and 3 h of hands on scanning. Each US examination was initiated in the supine position. Additional maneuvers, such as left lateral decubitus positioning, was left to the discretion of the individual physician sonographer. Standard sonographic assessment of the gallbladder included the presence or absence of gallstones, pericholecystic fluid (PCF) and SMS (sonographic Murphy’s sign), as well as measurements of the anterior gallbladder wall and CBD diameter. All POCUS findings were recorded contemporaneously by emergency medicine research associates at the bedside. US images were acquired with a Sonosite Edge (Sonosite FUJIFILM, Bothell WA) using either a 3.5-5 MHz curvilinear or a 1–5 MHz phased array transducer.

An US was deemed “abnormal” if any one of the following were present: anterior gallbladder wall thickness >3 mm (GWT), PCF or SMS. The presence of gallstones and dilated CBD were each considered separate and distinct abnormalities to facilitate statistical analysis. CBD dilation was defined as an internal diameter >6 mm for patients 60 years of age or younger. For patients >60 years of age, an additional 1 mm was added to the upper limit of normal for each subsequent decade of life.

2.6. Outcome measures

The primary outcome was to determine if cases of complicated biliary pathology occurred in the setting of normal laboratory values and a POCUS demonstrating the absence of GWT, PCF and SMS. We predict that a negative POCUS and normal lab values will be associated with a sensitivity >95% for non-complicated biliary pathology.

2.7. Data analysis

Descriptive statistics were performed for patient demographic data. Proportions were calculated with associated 95% confidence intervals (CI) reported for key parameters. The association between CBD dilation

and complicated biliary pathology was assessed using a 2×2 contingency table and sensitivity, specificity, positive/negative likelihood ratios (+LR/−LR) and positive/negative predictive values (PPV/NPV) were derived. Study data were collected and managed using REDCap (Research Electronic Data Capture) tools hosted at our institution [21]. Data was analyzed using SPSS (Version 23, IBM, Armonk, NY) statistical software and Excel (Version 14.7.1, Microsoft, Redmond, WA).

We assumed that no >10% of cases of CBD dilation would occur without laboratory abnormalities or other abnormalities on POCUS. Using $\alpha = 0.05$ and power = 0.80 we anticipated a required sample size of 108 patients. Accounting for anticipated exclusions, we planned a total goal enrollment of 140 patients.

3. Results

3.1. Characteristics of study subjects

A total of 167 patients were enrolled. After excluding 9 cases for missing data, loss to follow up or duplicate enrollment, 158 patients were included in the final analysis. Females comprised 114 (72.2%) of the inclusion cohort. The median age and BMI was 35 years (Interquartile Range (IQR) 28–46.5, range 18–87) and 28 (IQR 25.6–32.8), respectively.

Of the 158 included patients, 76 (48.1%) received non-biliary diagnoses and 82 (51.9%) were diagnosed with biliary pathology. Isolated uncomplicated cholelithiasis was seen in 43 (27.2%) patients and complicated biliary pathology was diagnosed in the remaining 39 (24.7%, 95% CI [18.2–32.2%]). Specific diagnoses comprising this latter group included: 14 (8.9%) cholecystitis, 19 (12.0%, [7.4–18.1%]) choledocholithiasis, 2 (1.3%) extrahepatic ductal dilation, 1 (0.6%) hepatitis, and 3 (1.9%) pancreatitis (Fig. 1).

In the overall cohort, abnormal laboratory values were observed in 100 (63.3%) cases. POCUS demonstrated gallstones in 73 (46.2%) cases and other abnormal US finding in 71 (44.9%) cases. The latter group consisted of 57 (36.0%), 14 (8.9%) and 14 (8.9%) cases of GWT, PCF and SMS, respectively.

A dilated CBD was visualized in 20 (12.7%) cases and the CBD was not definitively identified in 7 (4.4%). Of those patients with CBD dilation, only 2 (10.0%) lacked a concurrent laboratory abnormality, GWT, PCF, SMS or a combination of these findings. One of these patients demonstrated gallstones on POCUS and was diagnosed with uncomplicated cholelithiasis based on radiology performed ultrasound. Neither of these patients was diagnosed with complicated biliary pathology. Only one instance of complicated biliary pathology was diagnosed in the

subset of patients without a visualized CBD, namely a single case of pancreatitis. This patient was found to have an elevated lipase value.

3.2. Primary results

Of the 39 patients diagnosed with complicated biliary pathology, abnormal labs, gallstones, other abnormal POCUS findings and dilated CBD were seen in 31 (79.5%), 18 (46.2%), 29 (74.4%) and 9 (23.7%) cases, respectively. Of the 158 total inclusions, there were 2 (1.3%, [0.2–4.5%]) cases of complicated biliary pathology diagnosed in the absence of laboratory abnormalities, GWT, PCF and SMS. The diagnosis in each of these cases was choledocholithiasis, with one occurring in the absence of gallstones and both occurring in the absence of CBD dilation (Fig. 2).

The association between CBD dilation and complicated biliary pathology in those cases with CBD measurement is represented in Table 1. Sensitivity, specificity, +LR and −LR were 23.7% [11.4–40.2%], 90.27% [83.3–95.0%], 2.43 [1.09–5.42] and 0.85 [0.7–1.0], respectively. PPV and NPV were 45.0% [26.9–64.6%] and 77.9% [74.5–80.9%], respectively.

4. Discussion

Our primary results demonstrate <2% of ED patients diagnosed with complicated biliary pathology failed to simultaneously exhibit abnormal laboratory studies or other concerning findings on POCUS beyond uncomplicated cholelithiasis. Thus, the absence of abnormal laboratory values or other sonographic findings suggests that measurement of the CBD is unlikely to contribute to the evaluation of the patient with suspected biliary pathology. These results are similar to previously published retrospective data suggesting that <1% of patients with cholecystitis and choledocholithiasis present without concurrent laboratory or sonographic abnormalities [17,22,23]. A majority of cases of complicated biliary pathology demonstrated abnormal laboratory values, which is also consistent with prior studies [24–26]. Our data is unique in that it is the first prospective research study to demonstrate these findings.

We found CBD dilation to be a very insensitive (23%) marker for the diagnosis of complicated biliary pathology in the ED population. While the specificity was significantly better (90%), this should be interpreted with the knowledge that a vast majority of CBD dilation coincided with laboratory or other ultrasound abnormalities.

The perceived relative difficulty in obtaining proper CBD images during POCUS was very much an impetus for the study. It is worth noting that the CBD was not visualized in approximately 5% of cases, which supports largely anecdotal assertions that adequate CBD identification and measurement can occasionally prove difficult for POC physician sonographers. A recent study demonstrated that POC sonographers can obtain CBD measurements with similar accuracy to their radiology counterparts; however, this conclusion is tempered by the rigorous 10 h dedicated RUQ POCUS training course and 20 hands-on studies required of participating sonographers [27].

In summary, our results support the concept that CBD diameter is unlikely to affect the final diagnosis of patients with normal laboratory values and a POCUS that does not demonstrate GWT, PCF or SMS.

5. Limitations

There are several limitations to the study. Patients were enrolled as a convenience sample of patients at a single, academic ED. Patients who did not speak English or Spanish were excluded. The experience level of the physician sonographers was variable and POCUS findings, including CBD measurements, were not validated by an expert sonographer or radiologist. While these facts tend to reflect a real-world application of POCUS in the evaluation of potential biliary pathology, the study findings may not be generalizable to other groups of emergency practitioners. Additionally, the average BMI for our patient population was 28. These findings may not be generalizable to patients with higher

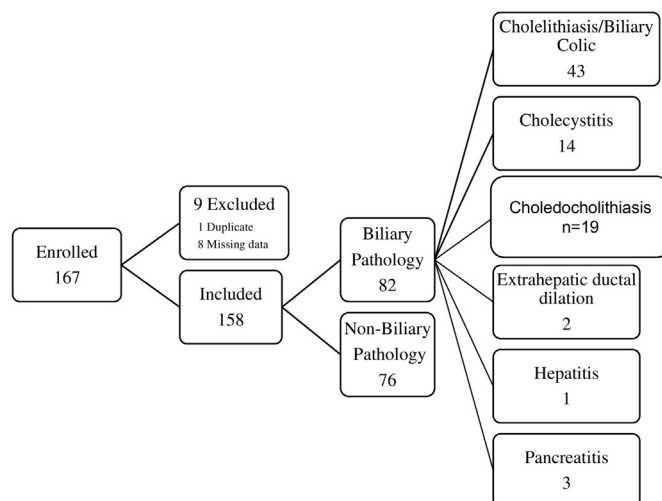


Fig. 1. Flow diagram by diagnosis.

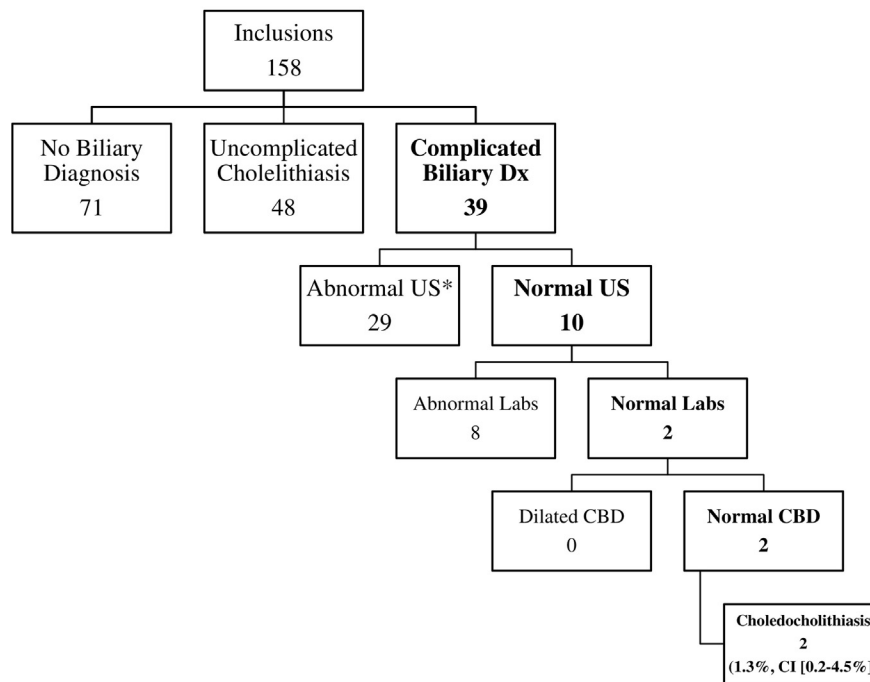


Fig. 2. Flow diagram by diagnosis classification.

Table 1

Association between CBD dilation and complicated biliary pathology. Cases without CBD measurement are excluded.

	Complicated biliary pathology	Uncomplicated cholelithiasis/non-biliary diagnosis	Total
Dilated CBD	9	11	20
Normal CBD	29	102	131
Total	38	113	151

CBD – common bile duct.

BMI. Laboratory testing was partially at the discretion of the treating physicians and lipase was not collected for every patient. While we encountered the more common diagnoses constituting complicated biliary pathology, not all possible relevant diagnoses were seen. For example, there were no cases of cholangitis or malignancy; however, one would expect other laboratory and clinical findings to confirm this diagnosis [28]. For discharged patients, the gold standard was ED diagnosis. There is a possibility that discharged patients may have had complicated biliary pathology without repeat ED visit within 2 weeks.

6. Conclusion

In the absence of abnormal laboratory values or other sonographic findings, measurement of the CBD is unlikely to contribute to the evaluation of the patient with suspected complicated biliary pathology.

Funding

This research did not receive any specific grant from funding agencies in the public, commercial, or not-for-profit sectors.

Funding sources/disclosures

Dr. J Christian Fox receives stock options from Sonosim for consulting. However, no Sonosim products were used in this research project.

Acknowledgments

UC Irvine Health Department of Emergency Medicine, UC Irvine School of Medicine.

References

- [1] Summers SM, Scruggs W, Menchine MD, et al. A prospective evaluation of emergency department bedside ultrasonography for the detection of acute cholecystitis. *Ann Emerg Med* 2010;56(2):114–22.
- [2] Benarroch-Gampel J, Boyd CA, Sheffield KM, et al. Overuse of CT in patients with complicated gallstone disease. *J Am Coll Surg* 2011;213(4):524–30.
- [3] Jafari D, Cheng AB, Dean AJ. Dynamic changes of common bile duct diameter during an episode of biliary colic, documented by ultrasonography. *Ann Emerg Med* 2013; 62(2):176–9.
- [4] Brook OR, Suissa A, Khamaysi I, et al. Difference of CBD width on US vs. ERCP. *Abdom Imaging* 2007;32(5):652–6.
- [5] Singer A, McCracken G, Henry M, et al. Correlation among clinical, laboratory, and hepatobiliary scanning findings in patients with suspected acute cholecystitis. *Ann Emerg Med* 1996;28:167–72.
- [6] Mills LD, Mills T, Foster B. Association of clinical and laboratory variables with ultrasound findings in right upper quadrant abdominal pain. *South Med J* 2005;88: 155–61.
- [7] Spence SC, Teichgraber D, Chandrasekhar C. Emergent right upper quadrant sonography. *J Ultrasound Med* 2009;28:479–96.
- [8] Jang TB. Bedside biliary sonography: advancement and future horizons. *Ann Emerg Med* 2010;56(2):123–5.
- [9] Tsung JW, Raio CC, Ramirez-Schrempp D, et al. Point-of-care ultrasound diagnosis of pediatric cholecystitis in the ED. *Am J Emerg Med* 2010;28(3):338–42.
- [10] Jang TB, Ruggeri W, Dyne P, et al. The learning curve of resident physicians using emergency ultrasonography for cholelithiasis and cholecystitis. *Acad Emerg Med* 2010;17(11):1247–52.
- [11] Blaivas M, Harwood RA, Lambert MJ. Decreasing length of stay with emergency ultrasound examination of the gallbladder. *Acad Emerg Med* 1999;6(10): 1020–3.

- [12] Boys JA, Doorly MG, Zehetner J, et al. Can ultrasound common bile duct diameter predict common bile duct stones in the setting of acute cholecystitis? *Am J Surg* 2013;432–5.
- [13] Kendall JL, Shimp RJ. Performance and interpretation of focused right upper quadrant ultrasound by emergency physicians. *J Emerg Med* 2001;21(1):7–13.
- [14] Kalimi R, Gecelter GR, Caplin D, et al. Diagnosis of acute cholecystitis: sensitivity of sonography, cholescintigraphy, and combined sonography-cholescintigraphy. *J Am Coll Surg* 2001;193(6):609–13.
- [15] Handler SJ. Ultrasound of gallbladder wall thickening and its relation to cholecystitis. *Am J Roentgenol* 1979;132(4):581–5.
- [16] Kendall JL, Shimp RJ. Performance and interpretation of focused right upper quadrant ultrasound by emergency physicians. *J Emerg Med* 2001 Jul;21(1):7–13.
- [17] Becker BA, Chin E, Mervis E, et al. Emergency biliary sonography: utility of common bile duct measurement in the diagnosis of cholecystitis and choledocholithiasis. *J Emerg Med* 2014 Jan;46(1):54–60.
- [18] Cronan JJ. US diagnosis of choledocholithiasis: a reappraisal. *Radiology* 1986;161(1):133–4.
- [19] Contini S, Dalla Valle R, Campanella G. Reliability of ultrasounds in detecting common bile duct stones before biliary surgery. A retrospective analysis. *Panminerva Med* 1997;39:106–10.
- [20] Hunt DR. Common bile duct stones in non-dilated bile ducts? An ultrasound study. *Australas Radiol* 1996;40:221–2.
- [21] Harris Paul A, Taylor Robert, Thielke Robert, Payne Jonathon, Gonzalez Nathaniel, Conde Jose G. Research electronic data capture (REDCap) – a metadata-driven methodology and workflow process for providing translational research informatics support. *J Biomed Inform* 2009 Apr;42(2):377–81.
- [22] Bose SM, Mazumdar A, Prakash VS, et al. Evaluation of the predictors of choledocholithiasis: comparative analysis of clinical, biochemical, radiological, radionuclear, and intraoperative parameters. *Surg Today* 2001;31:117–22.
- [23] American College of Emergency Physicians. Emergency ultrasound guidelines. *Ann Emerg Med* 2009;53:550–70.
- [24] Pereira-Lima JC, Jakobs R, Busnello JV, et al. The role of serum liver enzymes in the diagnosis of choledocholithiasis. *Hepatogastroenterology* 2000;47:1522–5.
- [25] Yang MH, Chen TH, Wang SE, et al. Biochemical predictors for absence of common bile duct stones in patients undergoing laparoscopic cholecystectomy. *Surg Endosc* 2008;22:1620–4.
- [26] Weinstein BJ, Weinstein DP. Biliary tract dilatation in the nonjaundiced patient. *AJR Am J Roentgenol* 1980 May;134(5):899–906.
- [27] Seyedhosseini J, Nasrelari A, Mohammadrezaei N, Karimialavijeh E. Inter-rater agreement between trained emergency medicine residents and radiologists in the examination of gallbladder and common bile duct by ultrasonography. *Emerg Radiol* 2017 Apr;24(2):171–6.
- [28] Wada K, Takada T, Kawarada Y, et al. Diagnostic criteria and severity assessment of acute cholangitis: Tokyo guidelines. *J Hepatobiliary Pancreat Surg* 2007;14:52–8.