

# UC Davis

## Dermatology Online Journal

### Title

Possible new defining presentation of mosaic tetrasomy 9p: multiple and recurrent pilomatrixoma

### Permalink

<https://escholarship.org/uc/item/4qt3p5xx>

### Journal

Dermatology Online Journal, 30(3)

### Authors

Wang, Jonathan W

Behnam, Reta

Porto, Dennis A

### Publication Date

2024

### DOI

10.5070/D330363866

### Copyright Information

Copyright 2024 by the author(s). This work is made available under the terms of a Creative Commons Attribution-NonCommercial-NoDerivatives License, available at

<https://creativecommons.org/licenses/by-nc-nd/4.0/>

Peer reviewed

# Possible new defining presentation of mosaic tetrasomy 9p: multiple and recurrent pilomatrixoma

Jonathan W Wang<sup>1</sup> BS, Reta Behnam<sup>2</sup> BA, Dennis A Porto<sup>3</sup> MD MPH

Affiliations: <sup>1</sup>Keck School of Medicine, University of Southern California, Los Angeles, California, USA, <sup>2</sup>School of Medicine, University of California San Francisco, San Francisco, California, USA, <sup>3</sup>SkinCare.MD, New York, New York, USA

Corresponding Authors: Jonathan Wang, 1975 Zonal Avenue, Los Angeles, CA 90033, Tel: 858-342-7310, Email: [jwang524@usc.edu](mailto:jwang524@usc.edu); Dennis A Porto MD, 224 West 35th Street, Suite 500, #704, New York, New York 10001, Tel: 508-478-2610, Email: [drporto@skincare.md](mailto:drporto@skincare.md)

## Abstract

Tetrasomy 9p is a rare genetic syndrome resulting from two additional copies of the short arm of chromosome 9. Symptoms often present in the form of congenital abnormalities including cognitive disabilities, growth retardation, abnormal earlobes, congenital heart disease, and dysmorphism of the skull and face. Current literature suggests patients with tetrasomy 9p may exhibit any combination of these symptoms or, in rare instances, none at all. Although karyotyping, chromosomal microarray, and galactose-1-phosphate uridylyltransferase activity analyses are the definitive diagnostic methods used, there remains a need for more robust clinical recognition in cases of mild phenotypic expression. Herein, we present a rare case of mosaic tetrasomy 9p in a long-term survival patient with multiple and recurrent pilomatrixomas, rare benign growths more commonly found in individuals under the age of 20. To our knowledge, only two previous reports have noted concurrent tetrasomy 9p with pilomatrixomas. We are the first to identify this phenotype in an adult tetrasomy 9p patient. Dermatopathology evaluation was conducted to verify our diagnoses. Our aim is to present a unique, additional case suggesting multiple pilomatrixomas as a new defining clinical presentation of mosaic tetrasomy 9p and to review the literature underlying the genetic changes associated with this syndrome.

*Keywords: genetic, mosaicism, pilomatrixomas, tetrasomy 9p*

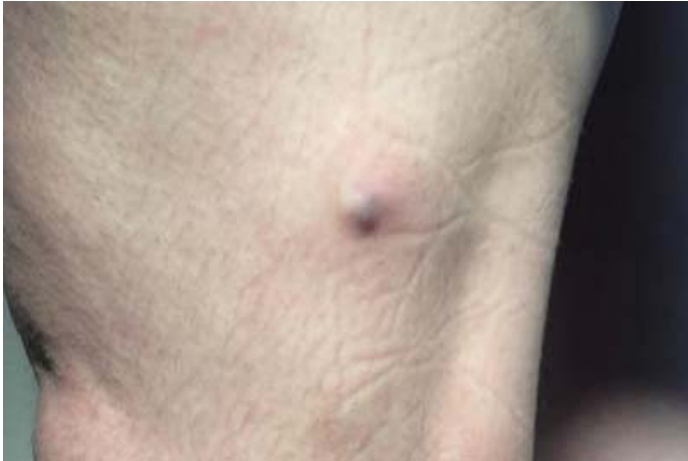## Introduction

Tetrasomy 9p is a rare genetic syndrome that arises from a duplicate copy of the short arm of

chromosome 9 [1]. Affected individuals fall under two different classes, mosaic or non-mosaic, and display a wide range of symptoms that vary in severity [2]. Non-mosaic tetrasomy 9p is often fatal in early infancy, whereas mosaic individuals exhibit long-term survival [2]. Among the commonly reported phenotypes for mosaic tetrasomy 9p, multiple or recurrent pilomatrixomas appear to be an emerging defining characteristic [3]. However, previous literature linking the two has been limited to pediatric patients [3,4]. As pilomatrixomas are more commonly found in these populations, the link between tetrasomy 9p and multiple pilomatrixomas has been tenuous [5]. To our knowledge, we report the first documented adult mosaic tetrasomy 9p patient with multiple pilomatrixomas.

## Case Synopsis

A 34-year-old woman presented to our dermatology clinic for evaluation of a firm, asymptomatic lesion that had developed on her left lower extremity over the past two weeks. Physical examination yielded a 17mm subcutaneous, firm nodule on her left lateral thigh, with a slight bluish discoloration but no notable textural changes of the overlying skin (**Figure 1**). Upon inquiring regarding the patient's past medical history, the patient's mother reported that the patient had been previously diagnosed with mosaic tetrasomy 9p, cerebral dysgenesis, Dandy-Walker malformation/variant, Klippel Feil deformity with congenital fusion of C1-2-3, bilateral hearing loss, and vision loss in the left eye. The patient also reported a history of pilomatrixomas throughout her life, which were removed surgically from the face, scalp, left lower extremity, and left trapezius.



**Figure 1.** Firm nodule with a bluish hue located on the left lateral thigh.

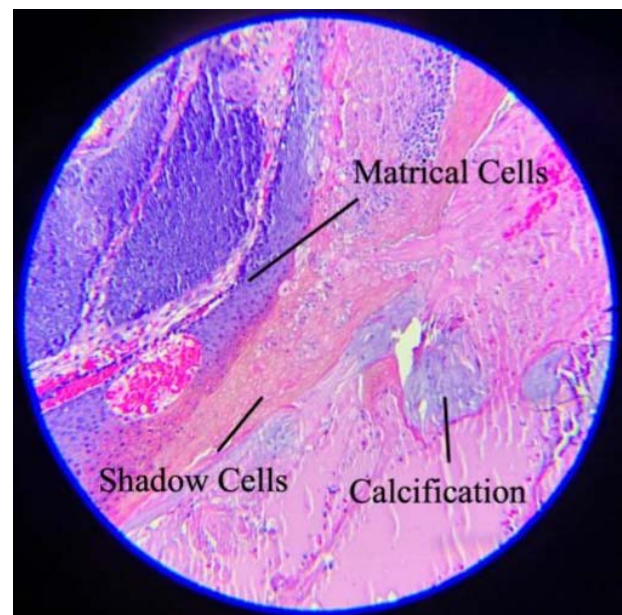
As our clinic had previously diagnosed the patient's last two pilomatrixomas via both shave and punch biopsies and also performed the respective excisions, another biopsy was deemed unnecessary at the time of the visit for pilomatrixoma diagnosis. Instead, an excision was recommended and was subsequently performed the following week. No recurrence was reported post-operation. Dermatopathology analysis revealed a dermal basaloid nodule with cystic architecture. Conspicuous matrical and shadow cells were noted, along with focal areas of calcification (**Figure 2**). Findings from dermatopathology analysis were consistent with pilomatrixomas, as expected.

## Case Discussion

Tetrasomy 9p is a rare autosomal syndrome that was first reported by Ghymers et al. in which affected individuals possess an extra copy of the short arm of chromosome 9p [6]. Two forms of this disease have been documented in the literature: isodicentric chromosome 9p (i[9p]) and pseudodicentric 9p (idic[9p]), [7]. In the former, both duplicates of the 9p arm are linked by a single centromere to form an isochromosome [7]. Alternatively, tetrasomy 9p can include replication of the entire 9p arm as well as heterochromatic and euchromatic portions of the 9q arm [7]. In such cases, the chromosomes are linked by two centromeres and result in idic(9p) classification [7]. It is unclear what triggers this duplication, but several hypotheses point toward

spontaneous errors made early on in embryonic development [4]. Therefore, chances of inheritance are low. To date, over 68 total cases have been reported [8]. We were unable to determine the distribution of i(9p) and idic(9p) within the reported cases in the literature.

Although tetrasomy 9p is marked by duplicate chromosome 9p, these supernumerary copies may not necessarily be present in all tissues. Such a presentation is referred to as tissue-limited mosaicism. Tetrasomy 9p can thus be further categorized based on a spectrum of mosaicism, with approximately 30% of all cases exhibiting some degree [9]. As a result, there are a variety of reported phenotypes in living cases, the most common of which include cognitive impairment, growth retardation, abnormal earlobes, congenital heart disease, and dysmorphia of the skull and face [9]. Very rarely, several cases have been reported in the literature in which affected individuals exhibit no abnormal phenotypes and in fact acquire their diagnoses incidentally [9,10]. For non-mosaic tetrasomy 9p patients on the other hand, the severity of disease complications often prove fatal early on in infancy [2]. However, although it is often true that symptom severity increases with decreasing mosaicism, clinicians must also be aware that



**Figure 2.** Maturation of matrical cells into "shadow cells" devoid of nuclei, consistent with pilomatrixoma. Focal calcification was also observed. H&E, 40x.

exceptions exist, particularly when tissues of greater developmental importance remain unaffected [5].

Owing to the rarity of this condition, the full scope of phenotypic expression is not fully understood. Although delayed cognitive and musculoskeletal development are commonly seen, we posit that pilomatrixomas may be an emerging defining feature of this syndrome.

Pilomatrixomas are rare benign skin tumors of hair follicle matrix cells that are more commonly observed in patients under the age of 20, although they have also been found less frequently in adults [5]. These growths commonly present as painless, slow growing nodules that are most often found on the hands and neck, although they may also present elsewhere on the body [5]. Additionally, pilomatrixomas may be either normal skin colored or possess a bluish hue. Because of the striking similarities between pilomatrixomas and cysts, only approximately 16% of reported pilomatrixoma cases are correctly diagnosed upon clinical examination [11].

Although definitive data is lacking, pilomatrixoma development is believed to be promoted by mutations in the Wnt signaling pathway and more specifically, through mutations in the *CTNNB1* gene encoding beta-catenin [12]. In normal tissues, excess beta-catenin is phosphorylated and marked for ubiquitin-mediated degradation [12,13]. However, this process is often altered in pilomatrixoma formation. Activating mutations in the *CTNNB1* gene eliminate the regulatory phosphorylation site on the N-terminus and result in cytoplasmic accumulation of beta-catenin stores [12]. In turn, elevated beta-catenin may subsequently complex with lymphoid enhancer factor (LEF) to form Wnt-activating transcription factors [14]. Whereas Wnt activation is not observed in all clinical cases, 56% (39/70) of reported pilomatrixoma cases in the current literature bear this mutation [12,14-17].

Previous literature has documented concurrent expression of tetrasomy 9p and multiple

pilomatrixomas. However, the patients in all such reports are children. Owing to the higher occurrence of such growths in pediatric populations, the connection between tetrasomy 9p and multiple pilomatrixomas was inconclusive. We are the first to present an adult patient affected with both tetrasomy 9p and multiple pilomatrixomas. Furthermore, our patient's reported pilomatrixomas were found in highly unusual parts of the body, suggesting they may be secondary to tetrasomy 9p. Genetic testing was not performed to assess genetic variation in the *CTNNB1* gene specifically. However, due to the rarity of these growths in adults and the scarce number of tetrasomy 9p cases more broadly, we hope to highlight the possible connection between the two.

## Conclusion

We presented a unique case of multiple pilomatrixomas in an adult patient diagnosed with mosaic tetrasomy 9p. Dermatopathology examination following tumor excision confirmed the lesion's diagnosis as a pilomatrixoma. A direct causal link between recurrent pilomatrixomas and tetrasomy 9p could not be inferred owing to lack of further genetic and laboratory testing. However, previously documented cases, abnormal tumor location, the patient's age, and the patient's unusual three-decade long history with these otherwise rare growths strengthen this association. Physicians should be aware of the clinical presentations of tetrasomy 9p, especially as it pertains to dermatology. As the literature continues to grow, it appears more likely that pilomatrixomas will become a recognized, defining feature of this genetic condition and may assist in future diagnosis and treatment.

## Potential conflicts of interest

The authors declare no conflicts of interest.

## References

1. Stumm M, Tönnies H, Mandon U, et al. Mosaic tetrasomy 9p in a girl with multiple congenital anomalies: cytogenetic and molecular-cytogenetic studies. *Eur J Pediatr.* 1999;158:571-575. [PMID: 10412817].
2. Dhandha S, Hogge WA, Surti U, McPherson E. Three cases of tetrasomy 9p. *Am J Med Genet.* 2002;113:375-380. [PMID: 12457411].
3. Charalsawadi C, Trongnit S, Jaruthamsophon K, et al. No Evidence of Abnormal Expression of Beta-Catenin and Bcl-2 Proteins in Pilomatricoma as One Clinical Feature of Tetrasomy 9p Syndrome. *Int J Pediatr.* 2021;2021:2612846. [PMID: 34956371].
4. El Khattabi L, Jaillard S, Andrieux J, et al. Clinical and molecular delineation of Tetrasomy 9p syndrome: report of 12 new cases and literature review. *Am J Med Genet A.* 2015;167:1252-1261. [PMID: 25847481].
5. Missak M, Haig A, Gabril M. Pilomatricoma with Atypical Features: A Case Report. *Case Rep Dermatol.* 2021;13:98-102. [PMID: 33708090].
6. Ghymers D, Hermann B, Distèche C, Frederic J. Tétrасоміе partielle du chromosome 9, à l'état de mosaïque, chez un enfant porteur de malformations multiples [Partial tetrasomy of number 9 chromosome, and mosaicism in a child with multiple malformations (author's transl)]. *Humangenetik.* 1973;20:273-282. [PMID: 4772080].
7. Pinto IP, Minasi LB, Steckelberg R, da Silva CC, da Cruz AD. Mosaic Tetrasomy of 9p24.3q21.11 postnatally identified in an infant born with multiple congenital malformations: a case report. *BMC Pediatr.* 2018;18:298. [PMID: 30193577].
8. Kok Kilic G, Pariltay E, Karaca E, et al. Prenatal diagnosis of a case with tetrasomy 9p confirmed by cytogenetics, FISH, microarray analysis and review. *Taiwan J Obstet Gynecol.* 2022;61:122-126. [PMID: 35181020].
9. Shu W, Cheng SSW, Xue S, et al. First Case Report of Maternal Mosaic Tetrasomy 9p Incidentally Detected on Non-Invasive Prenatal Testing. *Genes (Basel).* 2021;12:370. [PMID: 33807602].
10. Wang H, Xie LS, Wang Y, Mei J. Prenatal diagnosis of mosaic tetrasomy 9p in a fetus with isolated persistent left superior vena cava. *Taiwan J Obstet Gynecol.* 2015;54:204-205. [PMID: 25951732].
11. Jones CD, Ho W, Robertson BF, Gunn E, Morley S. Pilomatricoma: A Comprehensive Review of the Literature. *Am J Dermatopathol.* 2018;40:631-641. [PMID: 30119102].
12. Xia J, Urabe K, Moroi Y, et al. beta-Catenin mutation and its nuclear localization are confirmed to be frequent causes of Wnt signaling pathway activation in pilomatricomas. *J Dermatol Sci.* 2006;41:67-75. [PMID: 16378715].
13. Zhang Y, Wang X. Targeting the Wnt/ $\beta$ -catenin signaling pathway in cancer. *J Hematol Oncol.* 2020;13:165. [PMID: 33276800].
14. Chan EF, Gat U, McNiff JM, Fuchs E. A common human skin tumour is caused by activating mutations in b-catenin. *Nat Genet.* 1999;21:410-3. [PMID: 10192393].
15. Durand M, Moles JP. Beta-catenin mutation in a common skin cancer: pilomatricoma. *Bull Cancer.* 1999;86:725-6. [PMID: 10519964].
16. Kajino Y, Yamaguchi A, Hashimoto N, et al. beta-Catenin gene mutation in human hair follicle-related tumors. *Pathol Int.* 2001;51:543-8. [PMID: 11472567].
17. Ha SJ, Kim JS, Seo EJ, et al. Low frequency of b-catenin gene mutations in pilomatricoma. *Acta Derm Venereol.* 2002;82:428-31. [PMID: 12575848].