

UC Irvine

UC Irvine Previously Published Works

Title

Phase I trial of retinol in cancer patients.

Permalink

<https://escholarship.org/uc/item/4gn1347j>

Journal

Journal of clinical oncology : official journal of the American Society of Clinical Oncology, 1(6)

ISSN

0732-183X

Authors

Goodman, G E
Alberts, D S
Earnst, D L
[et al.](#)

Publication Date

1983-06-01

Peer reviewed

Phase I Trial of Retinol in Cancer Patients

By Gary E. Goodman, David S. Alberts, David L. Earnst, and Frank L. Meyskens

Vitamin A (all-*trans*-retinol) and its analogues are undergoing evaluation as antineoplastic and chemoprevention agents. Because its toxicity and activity are poorly defined, we have completed a phase I trial of retinol. Retinol was administered to 13 cancer patients in daily doses ranging from 100,000 units/m² to 350,000 units/m². Neuropsychiatric changes were the earliest dose-limiting symptomatic toxicities, noted in 3 of 5 patients receiving more than 240,000 U/m² for 3–4 months. Two patients receiving more

than 270,000 U/m² developed hepatomegaly after 3 and 4 months. Liver biopsies were consistent with vitamin A toxicity. Three patients receiving 200,000 U/m² developed an increase in serum triglycerides concentration. Mild skin and mucous membrane dryness occurred in most patients receiving more than 150,000 U/m². A mixed response was seen in one patient with melanoma. Because of neuropsychiatric and hepatic toxicity a retinol dose of 200,000 U/m²/day is recommended for future phase II trials.

IN MANY ANIMAL MODELS and man, vitamin A and its naturally occurring and synthetic analogues (the retinoids) prevent the development of preneoplastic lesions and may inhibit the growth of established cancers.^{1–5} Since high doses of either retinol or the retinyl esters can cause severe and occasionally life-threatening toxicity, there has been a major effort to identify less toxic and more potent retinol analogues.⁶ At the present time, however, all-*trans*-retinol, its fatty acid ester, retinyl palmitate, and retinyl acetate remain the major retinoids available for clinical use. Although these compounds have been available for many years as “over-the-counter” dietary supplements, limited data exist concerning their dose-related toxicity and anticancer effect. Animal studies provide most of the information available on retinol toxicity, with human data limited primarily to single case reports and literature reviews.^{7–12} Because of the marked variation in reported doses and schedules, and the anecdotal and retrospective nature of these case reports,

the retinol dose–toxicity relationship in humans is unclear. We report here the toxicity and side effects of daily high-dose oral retinol in 13 cancer patients.

MATERIALS AND METHODS

Between November 1979, and January 1982, eight patients were entered into a phase I trial of retinol. All eight patients had a histologically proven diagnosis of advanced cancer and had failed or declined standard therapies. Retinol was administered orally once daily in doses of 100,000, 150,000, or 200,000 U/m²/day. Five additional patients, who received retinol in a fixed daily dose of 500,000 units as part of a pilot study for the adjuvant treatment of resectable melanoma, were also evaluated in retrospect. Patients were evaluated for side effects, toxicity, and response at 3–4 week intervals. Radionuclide liver–spleen scans were performed prior to treatment and repeated every 2–4 months. Hematologic, coagulation, renal, electrolyte, and hepatic parameters, along with other blood chemistries, were evaluated every 3–4 weeks. Retinol was discontinued if disease progressed or severe toxicity developed. Patients received no other anticancer treatment or vitamin supplementation and remained on their usual diet for the duration of this trial. Informed consent in accordance with institutional and FDA guidelines was obtained from each patient prior to starting retinol.

RESULTS

Toxicity

The clinical characteristics, administered doses, and toxicity of all patients are listed in Table 1. Two patients received retinol, 100,000 U/m², for 2 and 5 months, respectively. Neither patient had clinical or laboratory evidence of toxicity. Both patients developed progressive cancer while on retinol and were taken off the study. Three patients received retinol, 150,000 U/m², for 2, 4, and 6 months respectively. Patient 3, a 67-year-old white female with locally recurrent

From the Sections of Hematology/Oncology, Gastroenterology, and Pharmacology, Department of Internal Medicine and the Cancer Center College of Medicine, University of Arizona, Tucson, Ariz.

Submitted November 23, 1982; accepted March 10, 1983.

Supported by Research Grants CA-17094, T32-GM07533 and CA-27502 from the National Cancer Institute, NIH, DHHS.

Gary E. Goodman, MD, present address: The Swedish Hospital Tumor Institute, Seattle, WA 98104.

Address reprint requests to David S. Alberts, MD, Section of Hematology/Oncology, Department of Internal Medicine, University of Arizona, Tucson AZ 85724.

© 1983 by American Society of Clinical Oncology.

0732-183X/83/0106-0007\$1.00/0

Table 1. Clinical Characteristics and Toxicity of 13 Patients Receiving Oral Retinol

Patient No.	Dose (U/m ²)	Age/ Sex	Duration of Treatment (ml)	Diagnosis	Toxicity
1	100,000	67/M	5	Colon adenocarcinoma, liver metastasis	None
2	100,000	63/F	2	Rectal squamous cell carcinoma, local recurrence	None
3	150,000	67/F	4	Colon adenocarcinoma, local recurrence	Neuropsychiatric symptoms
4	150,000	66/F	2	Melanoma, metastatic	None
5	150,000	56/M	6	Squamous cell carcinoma of oropharynx (adjuvant)	Dry skin
6	200,000	73/M	9	Colon adenocarcinoma, Duke's C (adjuvant)	Dry skin, chelosis, increased triglycerides
7	200,000	71/M	12	Squamous cell carcinoma of nasopharynx (adjuvant)	Dry skin, chelosis, increased triglycerides
8	200,000	76/M	4	Prostatic adenocarcinoma, stage D	Dry skin, chelosis, increased triglycerides
9	240,000	47/M	4	Melanoma, stage I (adjuvant)	Headaches, dry skin, chelosis, neuropsychiatric symptoms
10	250,000	69/M	2	Melanoma, stage I (adjuvant)	Headaches, dry skin, chelosis
11	270,000	33/F	3	Melanoma, stage I (adjuvant)	Headaches, dry skin, chelosis, hepatomegaly, neuropsychiatric symptoms
12	290,000	27/F	3	Melanoma, stage I (adjuvant)	Headache, dry skin, chelosis, neuropsychiatric symptoms
13	350,000	53/F	4	Melanoma, stage I (adjuvant)	Headache, dry skin, chelosis, hepatomegaly

colon cancer, had a rise in fasting serum triglycerides from 240 to 384 mg/dL over a 4-month period. After 4 months of treatment she began to experience emotional lability and depression with frequent crying episodes and hallucinations. A neurologic examination was normal. There was no clinical evidence of increased intracranial pressure (a lumbar puncture was not performed). Retinol was discontinued and the patient's mental status returned to baseline within 4 weeks.

Her fasting serum triglycerides concentration fell to 94 mg/dL over a period of 4 months.

Three patients received retinol, 200,000 U/m², for 4, 9, and 12 months, respectively. All noted mild to moderate dryness of the lips and skin with mild desquamation. No other signs or symptoms of toxicity developed in these three patients. There was no evidence of central nervous system toxicity. All three patients developed a progressive rise in fasting serum tri-

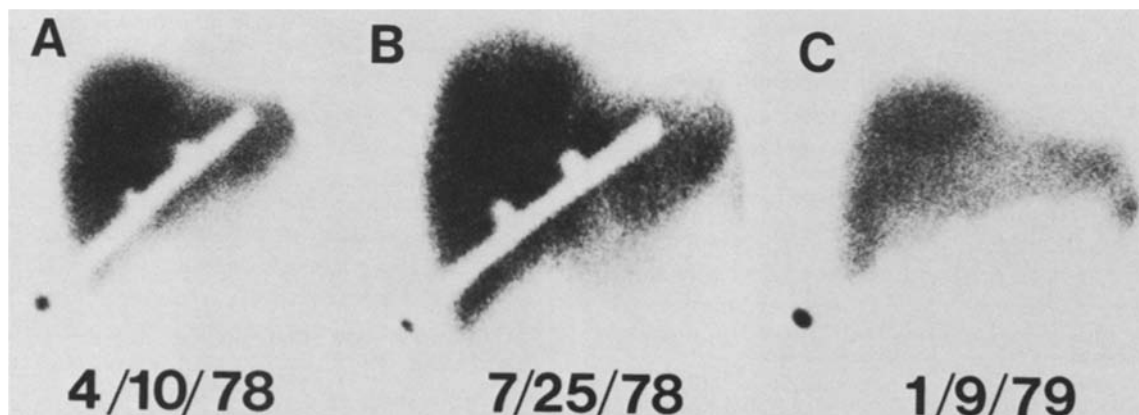


Fig. 1. Serial radionuclide liver scans in patient 13, who received daily oral retinol, 350,000 U/m², showing development of hepatomegaly and increase in uptake of radionuclide. (A) Before retinol. (B) After 3 months of retinol treatment. (C) Six months after stopping retinol.

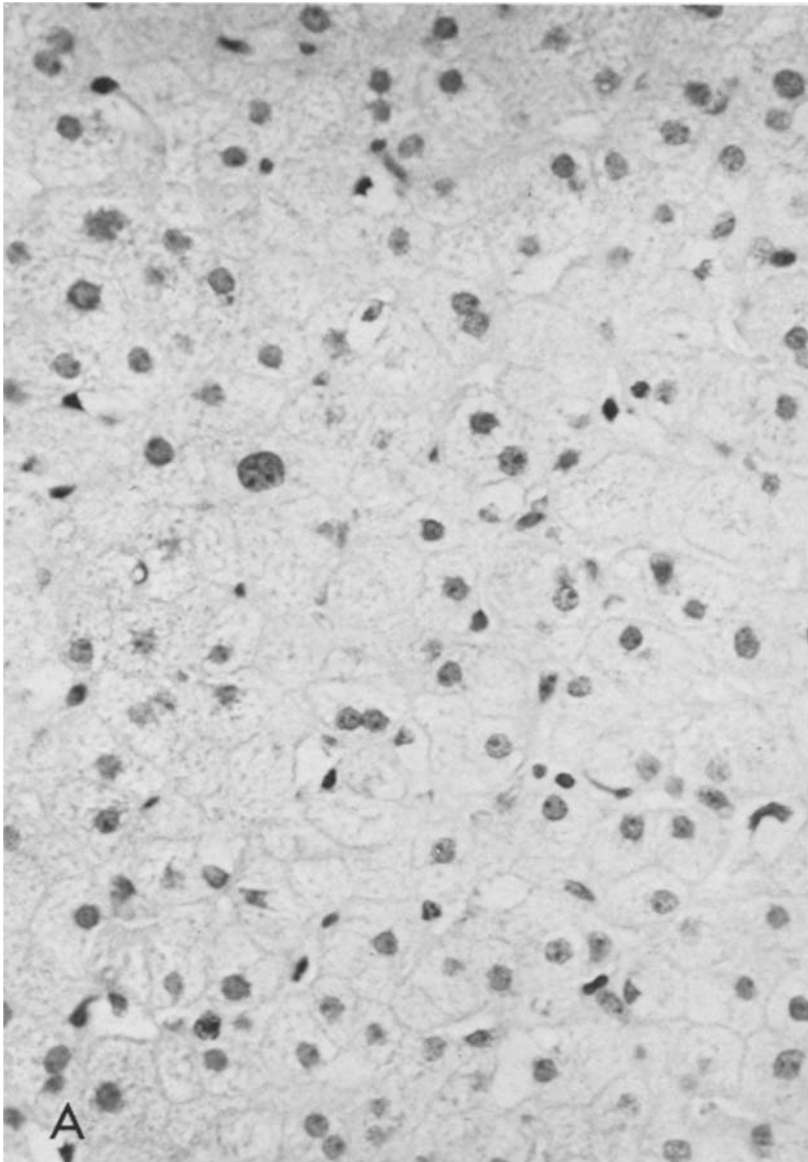


Fig. 2. Histologic sections of liver biopsies of patients 11 and 13, both of whom developed changes in radionuclide liver-spleen scans while receiving daily retinol. (A) Patient 13: swollen hepatocytes with foamy cytoplasm. (B) Patient 11: sinusoidal dilatation, Kupffer cell hyperplasia, and vacuolated cells of Ito.

glycerides (patient 6, 120 to 364 mg/dL; patient 7, 324 to 1430 mg/dL; patient 8, 137 to 270 mg/dL).

Five patients received a fixed daily retinol dose of 500,000 units (range 240,000–350,000 U/m²). All five patients developed occasional but nonpersistent headaches. Three patients developed central nervous system toxicity with neuropsychiatric changes at 3, 4, and 4 months. All three complained of emotional lability with easy irritability, bouts of depression, and anxiety; one patient experienced loss of libido. The neurologic examination was normal in all three patients.

There was no symptomatic or funduscopic evidence to suggest increased intracranial pressure. Symptomatic central nervous system toxicity reversed in all three patients within 4 weeks of retinol discontinuation.

Two patients in the high-dose retinol group who received 270,000 U/m² (patient 11) and 350,000 U/m² (patient 13) had changes in serial radionuclide liver-spleen scans after 3 and 4 months, respectively. Patient 13 developed hepatomegaly with an apparent increase in the uptake of radionuclide in the liver (Fig. 1). Patient 11 developed mild hepatomegaly with promi-

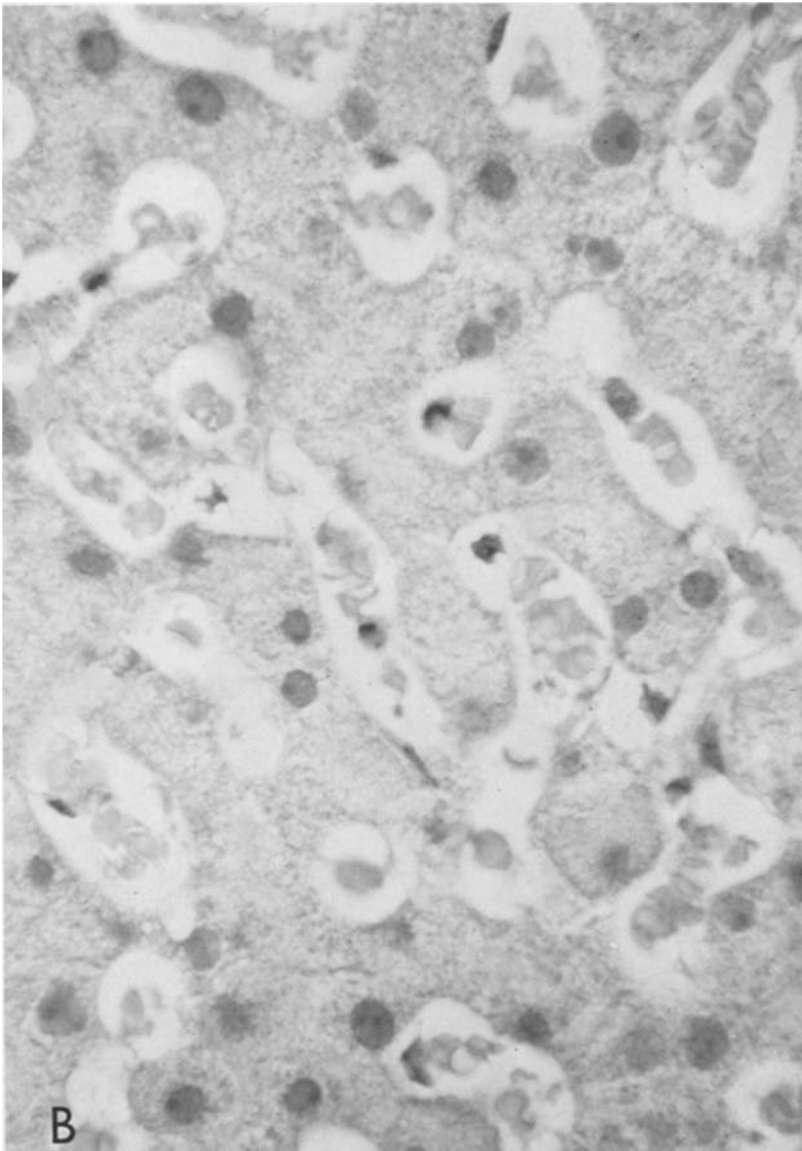


Fig. 2B.

nence of the left lobe. Physical examination was normal in both patients. Liver function tests were also within normal limits and included prothrombin time and partial prothrombin time, serum albumin, glutamic-oxaloacetic transaminase, alkaline phosphatase, lactic acid dehydrogenase, gamma glutamyl transferase, and bilirubin.

Because of the possibility that the hepatomegaly in each of these patients might represent recurrent melanoma, both patients underwent percutaneous liver biopsies. Patient 13 had swollen hepatocytes with foamy cytoplasm, (Fig. 2A) and patient 11 had sinusoidal dilatation, Kupffer

cell hyperplasia, and vacuolated cells of Ito (Fig. 2B). Retinol was discontinued in both patients. Follow-up radionuclide liver-spleen scanning 6 months after retinol was discontinued revealed no persisting liver abnormalities (Fig. 1).

All five patients who received 500,000 units retinol daily noted dry, "chapped" lips and mild to moderate dryness of the skin and mucous membranes. One patient had mild hair loss, one had an increase in the frequency of normal bowel movements, and one experienced arthralgias. All five patients noted intermittent, but not persistent headaches. There was no evidence of hematolog-

ic or renal toxicity. Because these patients were evaluated retrospectively, fasting serum triglycerides concentrations were not available.

Biologic Responses

Three patients appeared to have "biologic responses" to retinol treatment. Patient 4, who had progressive melanoma and multiple subcutaneous and pulmonary metastases, had a mixed response, with a 25%–50% reduction of the subcutaneous masses but no change in the pulmonary metastases. This response lasted 4 weeks with progression in both subcutaneous and pulmonary sites.

Patient 7 had an incidental 30-year history of widespread seborrheic keratoses. Four months after he started taking retinol there was a decrease in both the size and pigmentation of the lesions. The lesions continued to regress and some disappeared completely. When retinol was discontinued the lesions again became pigmented and elevated.

Patient 8; who had widespread painful bony metastases from prostate cancer, had complete resolution of bone pain within 4–6 weeks of starting retinol. Accompanying this subjective response was a decrease in acid phosphatase levels from a pretreatment value of 12.2 to 6.8 IU/L. Increasing bone pain and a rising acid phosphatase level to 13.9 IU/L occurred during the 14th week of retinol treatment.

DISCUSSION

Vitamin A has been available for many years as an over-the-counter dietary supplement. In recent years high doses have been promoted "to improve vision," "to cure cancer," and in general "to maintain good health"; however, there have been no published clinical trials prospectively evaluating toxicity or efficacy. The risks and benefits of these compounds remain anecdotal. In an effort to obtain data regarding some of these issues, we have conducted a prospective phase I trial of oral retinol in cancer patients.

Previous reports of vitamin A toxicity have primarily concerned patients presenting with advanced symptoms.^{7–12} Few patients taking large doses of vitamin A have been regularly followed by a physician, and the majority receive medical attention only when severe toxicity develops. Because of the retrospective nature of these re-

ports, the true incidence and natural history of retinoid toxicity is unknown. In our phase I study, retinol was reasonably well tolerated for up to 4 months at doses as high as 350,000 U/m²/day and signs and symptoms of early vitamin A excess were easily detected.

The most commonly reported signs and symptoms of chronic vitamin A intoxication are dryness, desquamation, and erythema of the skin, alopecia, weakness and easy fatigability, musculoskeletal complaints, anorexia, headache, and hepatomegaly.⁷ In our study mild to moderate skin and mucous membrane dryness were also the most commonly experienced symptoms and were noted by most patients who received a retinol dose of 150,000 U/m² or more. Once it developed, this toxicity did not progress, and no patient discontinued retinol because of skin toxicity.

In contrast to previous reports,^{7–10} central nervous system toxicity proved the earliest dose-limiting toxicity, occurring in 4 of our 13 patients. Four patients receiving 150,000, 240,000, 290,000, and 350,000 U/m² for 3–4 months developed neuropsychiatric symptoms. In all 4 patients the emotional lability and depressive symptoms disappeared within 4 weeks of the discontinuation of retinol. These neuropsychiatric changes are less severe than the central nervous system toxicity generally reported in the literature.^{7,10} It has been postulated that severe retinoid central nervous system toxicity is caused by a rise in intracranial pressure. Although a direct measurement of intracranial pressure was not made, no patient developed papilledema, blurred vision, or nausea and vomiting. It is likely that if our patients had not been closely followed the early neuropsychiatric symptoms may have been overlooked and retinol continued until the development of more serious central nervous system toxicity.

Hepatic dysfunction is another commonly reported finding in late vitamin A intoxication. Reports of advanced toxicity have included portal hypertension, cirrhosis, fibrosis, and hepatic failure.^{7,11,12} None of our 13 patients developed symptomatic, biochemical, or physical findings suggestive of hepatic toxicity. However, two patients receiving the highest doses of retinol, 270,000 and 350,000 U/m² for 3 and 4 months, respectively, developed reversible hepatomegaly

detected only by radionuclide liver-spleen scanning. In these early cases of toxicity, liver biopsy findings were consistent with vitamin A overload but showed no histologic evidence of necrosis, fibrosis, or inflammation. Hence, with close follow-up we were able to document histologic hepatic changes due to retinol accumulation before the development of either symptoms or biochemical abnormalities.

Our findings emphasize that retinoid toxicity encompasses a spectrum of sequential changes. The usual signs and symptoms of vitamin A toxicity reported in the literature probably represent the extreme end of that spectrum. Because high-dose "vitamin therapy" has become increasingly popular with the general public, large numbers of patients may present with symptoms of early vitamin A excess. Physicians must be aware of the signs and symptoms of early vitamin A toxicity, as well as those that occur late.

All three patients who received retinol doses of 200,000 U/m² and one of three who received 150,000 U/m² developed progressive increases in fasting serum triglycerides concentration. Similar findings have been reported previously in animals¹³ and in patients given the synthetic retinoid 13-*cis*-retinoic acid.^{5,14} The mechanism by which retinoid excess causes an elevation in

fasting serum triglyceride concentration is unknown. Excess retinoid may affect the hepatic synthesis, mobilization, or plasma clearance of triglycerides. Further investigation of this relationship appears to be warranted.

Although the objective of this phase I trial was to determine the dose-limiting toxicity of retinol, three patients appeared to have a response to treatment. One patient with disseminated melanoma had a mixed response, while a patient with stage D prostate cancer experienced a subjective response. One patient with seborrheic keratosis had resolution of multiple skin lesions. Care should be taken not to overinterpret these responses. Although two patients had progressive cancer at the start of retinol treatment, the natural history of both untreated melanoma and prostate cancer can frequently be unpredictable.

The retinoids are a diverse family of compounds that have shown a broad spectrum of biologic effects. Based on our findings, the parent retinoid, retinol, has limited and reversible toxicity when administered at a dose of less than 200,000 U/m² for periods of 3–12 months. Because of a suggestion of "anticancer" activity in both clinical and preclinical studies, and because of its potential use as a chemoprevention agent, further clinical trials appear to be justified.

REFERENCES

1. Mayer H, Bollag W, Hanni R, et al: Retinoids, a new class of compounds with prophylactic and therapeutic activities in oncology and dermatology. *Experientia* 34:1105–1119, 1978
2. Sporn MB, Newton DL: Chemoprevention of cancer with retinoids. *Fed Proc* 38:2528–2534, 1979
3. Levine N, Meyskens FL: Topical vitamin A-acid therapy for cutaneous metastatic melanoma. *Lancet* 2:224–225, 1980
4. Trown PW, Buck MJ, Hansen R: Inhibition of growth and regression of a transplantable rat chondrosarcoma by three retinoids. *Cancer Treat Rep* 60:1647–1652, 1976
5. Meyskens FL, Gilmartin E, Alberts DS, et al: Activity of Isoretinoin against squamous cell cancers and pre-neoplastic lesions: *Cancer Treat Rep* 66:1315–1319, 1982
6. Bollog W, Matter A: From vitamin A to retinoids in experimental and clinical oncology: Achievements, failures and outlook. *Ann NY Acad Sci* 351:9–23, 1981
7. Muentner MD, Perry HO, Ludwig J: Chronic vitamin A intoxication in adults, hepatic, neurologic and dermatologic complications. *Am J Med* 50:129–136, 1971
8. Yaffe SJ, Filer LJ: The use and abuse of vitamin A. American Academy of Pediatrics, Joint Committee Statement, Committee on Drugs and Nutrition. *Pediatrics* 48:655–656, 1971
9. Oliver TK Jr: Chronic vitamin A intoxication: Report of a case in an older child and review of the literature. *Am J Dis Child* 95:57–68, 1958
10. Goodman LS, Gilman A (eds): *The Pharmacologic Basis of Therapeutics*. New York, Macmillan, 1980, pp 1583–1608
11. Rubin E, Florman AL, Degnan T, et al: Hepatic injury in chronic hypervitaminosis A. *Am J Dis Child* 119:132–138, 1970
12. Babb RR, Kieraldo JH: Cirrhosis due to hypervitaminosis A. *West J Med* 128:244–246, 1978
13. Setty DH, Misra VK: Retinol feeding and low and high density lipoproteins of plasma of rats. *Int J Vitam Nutr Res* 50:348–351, 1980
14. Marsden JR, Shuster S, Laker MF: Isoretinoin and serum lipids. *Lancet* 1:134, 1983