

UC Davis

Dermatology Online Journal

Title

TNF inhibitor induced alopecia: an unusual form of psoriasiform alopecia that breaks the Renbök mold

Permalink

<https://escholarship.org/uc/item/4gk06758>

Journal

Dermatology Online Journal, 23(3)

Authors

Craddock, Lauren N
Cooley, David M
Endo, Justin O
et al.

Publication Date

2017

DOI

10.5070/D3233034290

Copyright Information

Copyright 2017 by the author(s). This work is made available under the terms of a Creative Commons Attribution-NonCommercial-NoDerivatives License, available at <https://creativecommons.org/licenses/by-nc-nd/4.0/>

Peer reviewed

TNF inhibitor induced alopecia: an unusual form of psoriasiform alopecia that breaks the Renbök mold

Lauren N. Craddock MD¹, D. David M Cooley MD², Justin O. Endo MD³, B. Jack Longley MD³, Freddy Caldera DO⁴

Affiliations: ¹ University of Wisconsin, Departments of Internal Medicine and Dermatology, Madison, Wisconsin, ² St. John Providence, Department of Gastroenterology, Southfield, Michigan, ³ University of Wisconsin, Department of Dermatology, Madison, Wisconsin, ⁴ University of Wisconsin, Department of Medicine, Division of Gastroenterology and Hepatology, Madison, Wisconsin

Corresponding Author: Lauren N. Craddock, MD, University of Wisconsin, Departments of Internal Medicine and Dermatology, 1 South Park Street, 7th Floor, Madison, WI, 53715, USA. Tel. 608-287-2620, Email: LCraddock@uwhealth.org

Abstract

TNF- α -inhibitors are known to induce skin adverse effects including psoriasis and alopecia areata. Here, we describe a unique pattern of hair loss that has psoriatic and alopecia areata-like features. Diagnosis requires clinical-pathologic correlation and is supported by increased catagen/telogen hairs, psoriasiform epidermal hyperplasia, perifollicular lymphocytic infiltrate, and the presence of eosinophils and plasma cells. Although there are no treatment consensus guidelines, management options include stopping therapy, switching to a different TNF- α inhibitor or ustekinumab (in severe cases), or continuing TNF- α inhibitor therapy with addition of topical, intralesional, or systemic immunosuppressants.

The patient's inflammatory bowel disease was well controlled with the combined therapy of azathioprine 125 mg PO daily and adalimumab 40 mg IM every 2 weeks for approximately 2.5 years. Previous Crohn's treatments included azathioprine, methotrexate, and infliximab, all discontinued secondary to lack or loss of efficacy. Three years previous, she had been evaluated by the department of dermatology for biopsy-proven, secondarily impetiginized, seborrheic dermatitis involving the scalp, postauricular neck, axillae, inframammary folds, and upper chest. For this, she was given topical mupirocin and triamcinolone

Keywords: alopecia, psoriasis, psoriasiform, IBD, Crohn's, TNF inhibitor, CXCR3, JAK, Renbök

Presentation

A 21-year-old female with Crohn's disease presented to Dermatology with subacute worsening of chronic, erythematous, scaly plaques on the scalp and ears, with new areas of hair loss developing over 2 months (**Figure 1**). She denied any oral or genital lesions, pustules, vesicles, arthralgias, joint swelling, or worsening Crohn's symptoms. No changes in medications or personal care products had been made prior to onset of the eruption. She intermittently had been applying mupirocin to the lesions without effect.

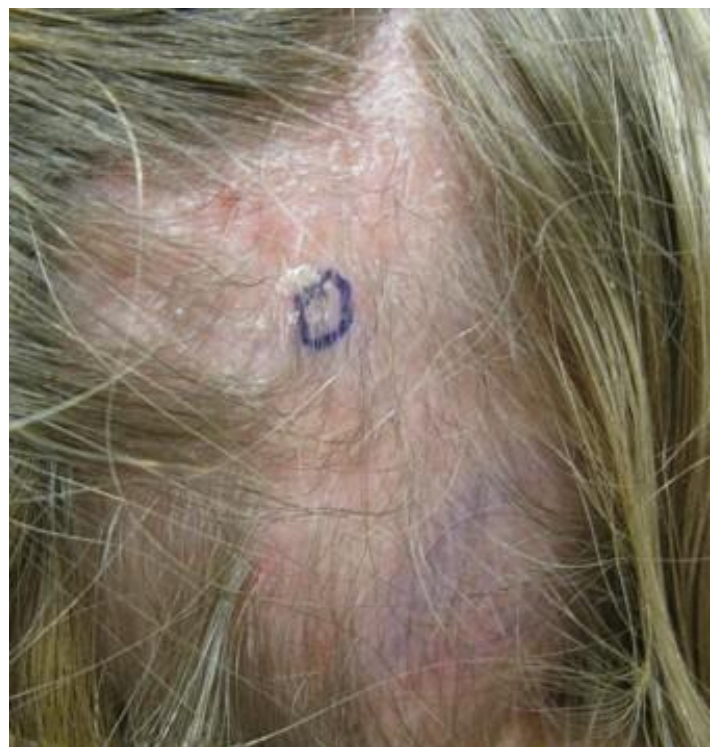

Figure 1. Clinical presentation. Original patch of alopecia on the right temporal scalp with biopsy site marked.

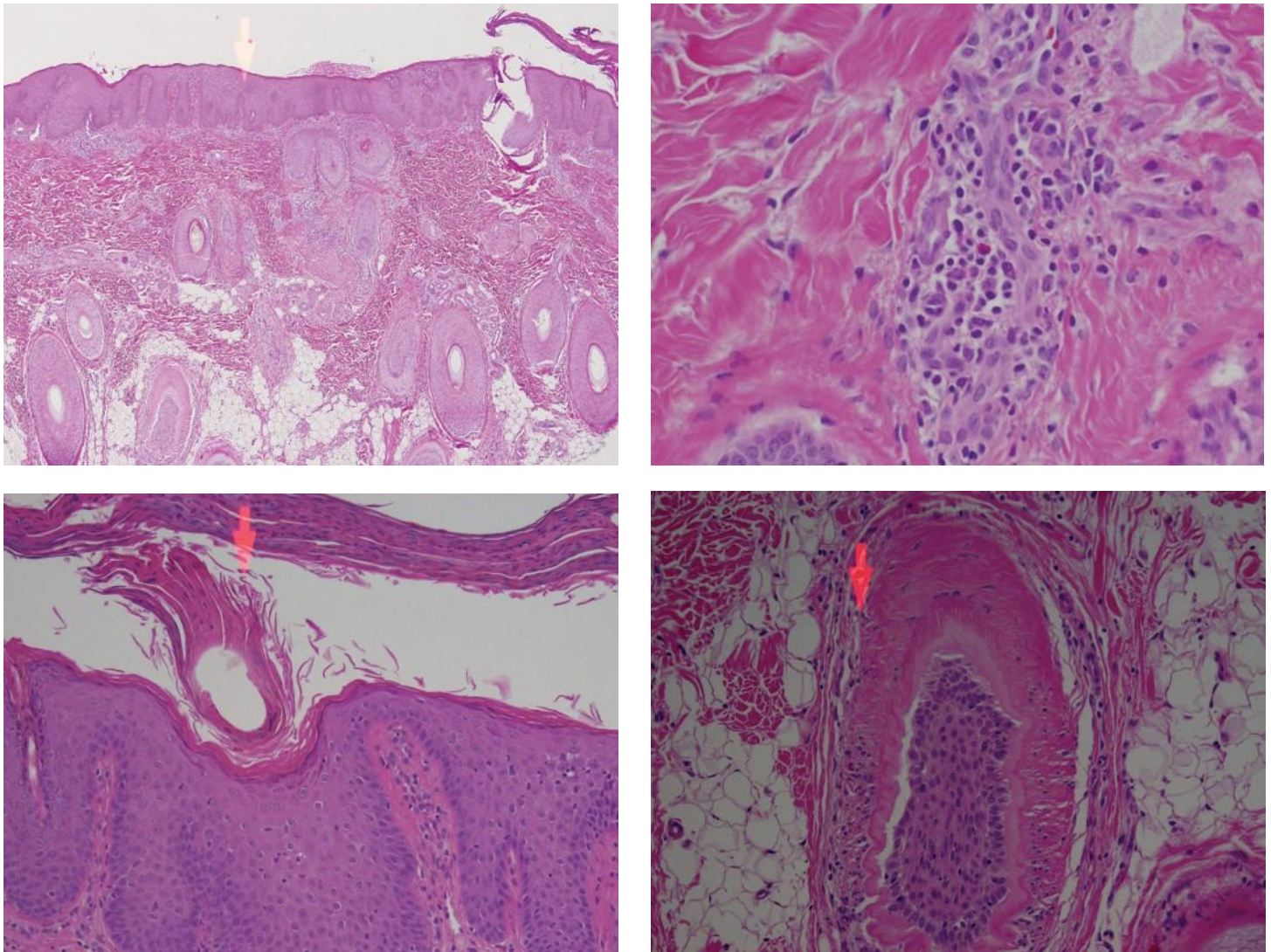


Figure 2. Histopathology. (A), H&E of patient's biopsy from right occipital scalp marked in Fig 1 showing. Low power (4x) revealing both 1) psoriasiform epidermal changes with a thickened epidermis (acanthosis), bulbous rete ridges, and confluent crust (parakeratosis) with neutrophils, and 2) alopecia areata like changes including increased catagen/telogen ratio, minaturized hairs, decreased number of sebaceous glands, and peribulbar lymphocytic infiltrate. (B), Higher power (40x) showing peribulbar lymphocytic infiltrate consisting of many plasma cells and a single eosinophil. (C), Magnification at 10x showing psoriasiform hyperplasia with confluent parakeratosis, neutrophils, and decreased granular layer. (D), Magnification at 20x showing a catagen hair bulb with its characteristic corrugated basement membrane.

acetamide 0.1%, which she used as needed to the areas with good response until recent flaring. She also had a history of iron deficiency already being supplemented at the time of presentation. Past medical and family history were both negative for psoriasis or alopecia.

Skin examination was significant for ill-defined erythema with overlying scale covering the entire scalp and postauricular neck. A shiny plaque with decreased hair follicles concerning for scarring alopecia was found on the right temporal scalp. This alopecia progressed over the next month to also

involve the occipital and left temporal scalp.

Assessment

A punch biopsy of the initial alopecic plaque on the right temporal scalp was performed. Hematoxylin and eosin stained sections showed psoriasiform epidermal hyperplasia with foci of scale crust containing neutrophils. There was a superficial perivascular and peri-infundibular lymphoid infiltrate containing plasma cells and a few eosinophils. The number of hair follicles was within normal range. Notably, there were an increased number of catagen hairs and a decreased number of sebaceous glands.

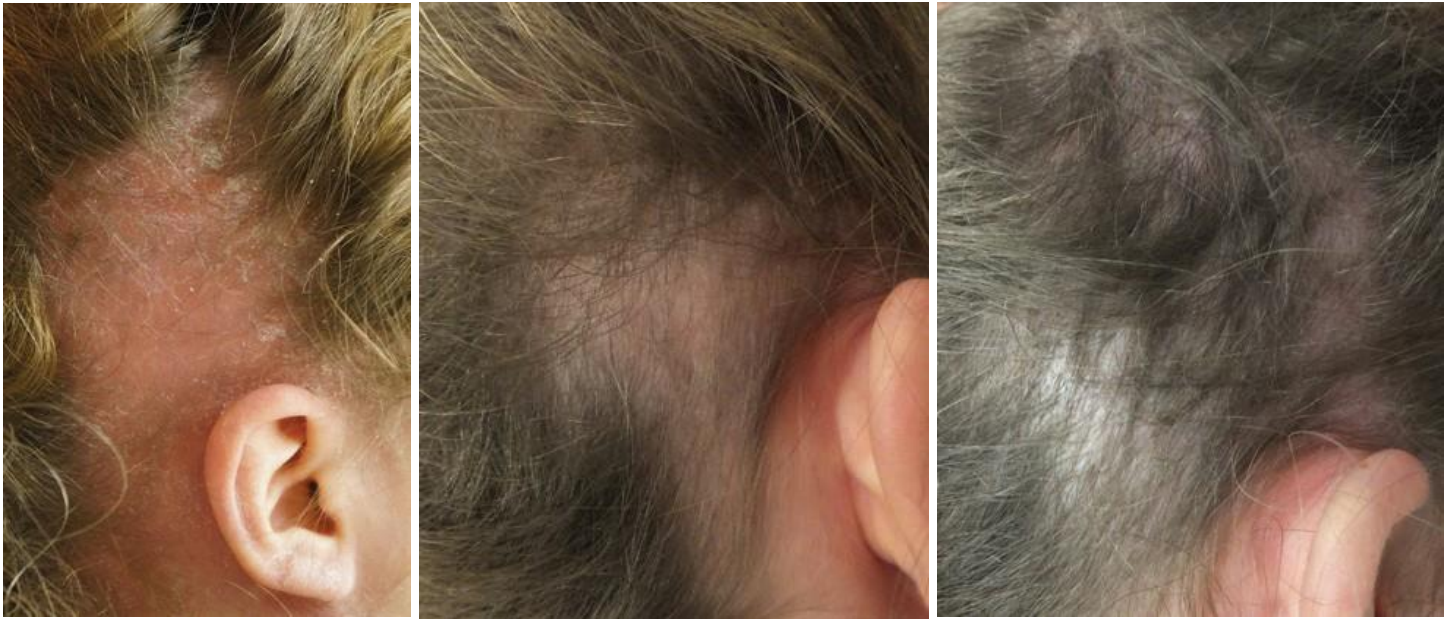

Figure 3. (Left to right). Progressive resolution of alopecia with photos taken at the time of monthly intralesional triamcinolone acetonide injections.

No infectious organisms were noted on periodic acid–Schiff–diastase (PASD) stain.

Lab work up was notable for normal vitamin D, amino alanine aminotransferase (ALT), thyroid-stimulating hormone (TSH), and rapid plasma reagin (RPR). Ferritin was low at 10 (20-300 ng/mL). Total white blood cell count was slightly elevated at 11.1 (3.8-10.5 K/ μ L) and platelets were moderately elevated at 407 (160-370 K/uL).

Diagnosis

Based upon the patient's presentation of psoriasiform, crusted plaques with alopecia on the scalp, the clinical differential included tumor necrosis factor (TNF) inhibitor induced alopecia, psoriatic alopecia, alopecia areata, and alopecia secondary to metabolic, infectious, or nutritional etiologies. Laboratory studies excluded a metabolic abnormality or syphilis. Her low ferritin suggested iron deficiency as a possible contributing factor, but the clinical presentation was not consistent with iron-deficiency telogen effluvium. PASD staining ruled out fungal or other bacterial factors. The remaining differential diagnoses were excluded based upon histopathologic appearance (see discussion below). Of note, although the patient received infliximab prior to adalimumab, review of the previous biopsies from 3 years prior did not show the same characteristic changes of TNF inhibitor induced alopecia.

TNF inhibitor induced alopecia has several key clinicopathological features that distinguish it from other causes of alopecia. Histologically, the epidermis may have psoriasiform changes. Typically, follicular density is preserved or slightly decreased with increased catagen to telogen ratio and follicular miniaturization [1, 2]. Sebaceous glands are dramatically decreased [1, 2]. There is a brisk superficial and deep perifollicular infiltrate consisting of peribulbar lymphocytes, prominent plasma cells, and variable eosinophils [1, 2]. In contrast, primary psoriatic alopecia occurs in the setting of antecedent psoriasis, does not follow TNF inhibitor therapy, and lacks eosinophils and plasma cells [1, 2]. Also in contradistinction, telogen effluvium and alopecia areata do not have striking clinical or histologic psoriasiform features, do not follow TNF inhibitor therapy, and typically lack plasma cells [1, 2].

Up to 5% of patients treated with TNF inhibitors develop psoriasiform skin lesions [3-7]. Clinical presentations include plaque or guttate psoriasis, palmoplantar pustulosis, or, rarely, alopecia [3-7]. It can occur weeks to years after initiating TNF inhibitor therapy for a variety of indications (e.g. inflammatory arthritis, inflammatory bowel disease) [1, 4, 5, 7-10]. Thus, in the case of our patient, it is difficult to prove which of the two (versus both) TNF inhibitors triggered the psoriasiform alopecia.

TNF inhibitor induced alopecia is unusual in that it goes against what is generally accepted as the Renbök, or reverse Köbner, phenomenon—originally used to describe the clinical observation that hair regrowth may be seen in psoriatic plaques of patients with concurrent psoriasis and alopecia areata, this term may be used more broadly to describe how the underlying pathogenic inflammatory pathways of one condition can ‘exclude’ or suppress those of another [11]. TNF inhibitor induced alopecia reminds us that 2 different inflammatory processes may ‘include’ or be driven by the same pathways (and that these processes are much more complicated than what can be extrapolated from clinical observation alone)[12]. A presumed pathogenesis of TNF inhibitor induced alopecia is as follows. TNF inhibition leads to dysregulated plasmacytoid dendritic cell production of interferon- α [4, 6, 7, 13]. Interferon- α leads to increased expression of the chemokine receptor CXCR3 ligands CXCL9, CXCL10, and CXCL11, which in turn recruit CXCR3+ T cells [4, 7, 13, 14]. Both IFN- γ -secreting Th1 cells and IL-17A/IL-22-secreting Th17 cells are CXCR3+ and are seen in increased numbers within psoriatic lesions. Of note, IFN- γ -secreting Th1 cells are also considered the underlying drivers of alopecia areata [7, 15, 16]. Further, expression of CXCL9, CXCL10, and CXCL 11 is significantly increased in patches of alopecia areata [16]. Thus, TNF inhibition increases plasmacytoid dendritic cell production of interferon- α ; which increases expression of the ligands CXCL9, CXCL10, and CXCL11; which increase activation of CXCR3+ IL-17A/IL-22-secreting Th17 cells that drive psoriasiform skin changes and CXCR3+ IFN- γ -secreting Th1 cells that drive both the psoriasiform and alopecic processes. Research to elucidate and therapeutically manipulate the pathogenic pathways of alopecia areata and psoriasis is ongoing.

Management

In cases of TNF inhibitor induced alopecia, treatment of the underlying immunological disease (e.g., Crohn’s disease) usually supercedes the alopecia. However, alopecia can significantly impact quality of life and thus warrants attention. Most published cases describe continuing the TNF inhibitor while treating the alopecia with topical steroids, intralesional steroids, or systemics such as methotrexate or cyclosporine [1, 5, 10]. Switching to a different

TNF inhibitor is rarely successful [1, 4, 5, 7, 9, 10]. Discontinuation of TNF inhibitor may reverse the alopecia, and is especially effective in combination with systemic therapy, but may result in flaring of the underlying inflammatory disease originally targeted with TNF inhibition [1, 5, 10, 17]. A few studies have reported successful use of usetekinumab to both 1) treat severe TNF inhibitor induced psoriasis and/or alopecia not previously responsive to discontinuation of TNF inhibitor therapy (with or without topical treatment), and 2) induce clinical remission of Crohn’s [7, 17]. Another potential treatment option is use of a Janus kinase (JAK) inhibitor. This class of medication is quickly gaining recognition as a possible solution for multiple autoimmune conditions including psoriasis, alopecia areata, and IBD [18-21]. Given the proposed pathogenesis of TNF inhibitor induced alopecia (outlined above), and the fact that JAKs lie downstream of IFN- γ , it follows that JAK inhibitors may be useful for this condition as well. Thankfully for our patient, she was able to continue adalimumab for treatment of Crohn’s, and the alopecic areas on her scalp quickly resolved with intralesional triamcinolone acetonide 5 mg/mL every month for 3 months.

References

1. Doyle LA, Sperling LC, Baksh S, Lackey J, Thomas B, Vleugels RAA, Qureshi AA, Velazquez EF. Psoriatic alopecia/alopecia areata-like reactions secondary to anti-tumor necrosis factor- α therapy: a novel cause of noncicatrical alopecia. *Am J Dermatopathol*. 2011 Apr;33(2):161–166. [PMID: 21317611]
2. Sperling LC, Cowper S, Knopp E. *An Atlas of Hair Pathology with Clinical Correlations*, Second Edition [Internet]. Taylor & Francis; 2012. Available from: <http://books.google.com/books?id=sbMAAAAQBAJ>
3. Cullen G, Kroshinsky D, Cheifetz AS, Korzenik JR. Psoriasis associated with anti-tumour necrosis factor therapy in inflammatory bowel disease: a new series and a review of 120 cases from the literature. *Aliment Pharmacol Ther*. 2011;34(11-12):1318–1327. [PMID: 21957906]
4. El Shabrawi-Caelen L, La Placa M, Vincenzi C, Haidn T, Muellegger R, Tosti A. Adalimumab-induced psoriasis of the scalp with diffuse alopecia: A severe potentially irreversible cutaneous side effect of TNF-alpha blockers. *Inflamm Bowel Dis*. 2010 Feb 1;16(2):182–183. [PMID: 19462433]
5. Ko JM, Gottlieb AB, Kerbleski JF. Induction and exacerbation of psoriasis with TNF-blockade therapy: a review and analysis of 127 cases. *J Dermatol Treat*. 2009;20(2):100–108. [PMID: 18923992]
6. Seneschal J, Milpied B, Vergier B, Lepreux S, Schaefferbeke T, Taieb A. Cytokine imbalance with increased production of interferon-alpha in psoriasiform eruptions associated with antitumor necrosis factor-alpha treatments. *Br J Dermatol*. 2009 Nov;161(5):1081–1088. [PMID: 19681863]
7. Tillack C, Ehmann LM, Friedrich M, Laubender RP, Papay P, Vogelsang H, Stallhofer J, Beigel F, Bedynek A, Wetzke M, Maier H, Koburger M,

- Wagner J, Glas J, Diegelmann J, Koglin S, Dombrowski Y, Schaubert J, Wollenberg A, Brand S. Anti-TNF antibody-induced psoriasiform skin lesions in patients with inflammatory bowel disease are characterised by interferon- γ -expressing Th1 cells and IL-17A/IL-22-expressing Th17 cells and respond to anti-IL-12/IL-23 antibody treatment. *Gut*. 2014 Apr 1;63(4):567–577. [PMID: 23468464]
8. Goldstein J, Levine J. Infliximab-Induced Psoriaform Rash. *Clin Gastroenterol Hepatol Off Clin Pract J Am Gastroenterol Assoc*. 2010 Oct 1;8(10):A24. [PMID: 20435164]
 9. Griffith JL, Ledet JJ, Elewski BE. Resident Rounds. Part III B: tumor necrosis factor- α antagonists and alopecia areata: a class-wide adverse effect. *J Drugs Dermatol JDD*. 2013 Jun;12(6):713–714. [PMID: 2389195]
 10. Kawashima K, Ishihara S, Yamamoto A, Ohno Y, Fukuda K, Onishi K, Kinoshita Y. Development of diffuse alopecia with psoriasis-like eruptions during administration of infliximab for Crohn's disease. *Inflamm Bowel Dis*. 2013 March; 19(3):E33-4. [PMID: 22508420]
 11. Happle R, Van Der Steen P, Perret C. The Renbök phenomenon: An inverse Köebner reaction observed in alopecia areata. *Eur J Dermatol*. 1991; 1(1):39–40.
 12. Mirmirani P. Two Birds that Exclude Each Other: The Renbök Phenomenon. *J Invest Dermatol*. 135(4):1180. [PMID: 25431848]
 13. Palucka AK, Blanck J-P, Bennett L, Pascual V, Banchereau J. Cross-regulation of TNF and IFN- α in autoimmune diseases. *Proc Natl Acad Sci U S A*. 2005 Mar 1;102(9):3372–3377. [PMID: 15728381]
 14. Groom JR, Luster AD. CXCR3 in T cell function. *Exp Cell Res*. 2011 Mar 10;317(5):620–631. [PMID: 21376175]
 15. Chen S-C, de Groot M, Kinsley D, Laverty M, McClanahan T, Arreaza M, Gustafson EL, Teunissen MBM, de Rie MA, Fine JS, Kraan M. Expression of chemokine receptor CXCR3 by lymphocytes and plasmacytoid dendritic cells in human psoriatic lesions. *Arch Dermatol Res*. 2010 Mar;302(2):113–123. [PMID: 19517126]
 16. Fuentes-Duculan J, Gulati N, Bonifacio KM, Kunjraiva N, Zheng X, Suarez-Farinas M, Shemer A, Guttman-Yassky E, Krueger JG. Biomarkers of alopecia areata disease activity and response to corticosteroid treatment. *Exp Dermatol*. 2016 Apr;25(4):282–286. [PMID: 26661294]
 17. Andrisani G, Marzo M, Celleno L, Guidi L, Papa A, Gasbarrini A, Armuzzi A. Development of psoriasis scalp with alopecia during treatment of Crohn's disease with infliximab and rapid response to both diseases to ustekinumab. *Eur Rev Med Pharmacol Sci*. 2013 Oct;17(20):2831–2836. [PMID: 24174369]
 18. Craiglow BG, King BA. Killing two birds with one stone: oral tofacitinib reverses alopecia universalis in a patient with plaque psoriasis. *J Invest Dermatol*. 2014 Dec;134(12):2988–2990. [PMID: 24940651]
 19. Danese S, Grisham M, Hodge J, Telliez J-B. JAK inhibition using tofacitinib for inflammatory bowel disease treatment: a hub for multiple inflammatory cytokines. *Am J Physiol Gastrointest Liver Physiol*. 2016 Feb 1;310(3):G155–162. [PMID: 26608188]
 20. Galluzzo M, D'Adamio S, Servoli S, Bianchi L, Chimenti S, Talamonti M. Tofacitinib for the treatment of psoriasis. *Expert Opin Pharmacother*. 2016 Jul;17(10):1421–1433. [PMID: 27267933]
 21. Xing L, Dai Z, Jabbari A, Cerise JE, Higgins CA, Gong W, de Jong A, Harel S, DeStefano GM, Rothman L, Singh P, Petukhova L, Mackay-Wiggan J, Christiano AM, Clynes R. Alopecia areata is driven by cytotoxic T lymphocytes and is reversed by JAK inhibition. *Nat Med*. 2014 Sep;20(9):1043–1049. [PMID: 25129481]