

UCLA

UCLA Previously Published Works

Title

Phase contrast MRI with flow compensation view sharing

Permalink

<https://escholarship.org/uc/item/4dt2w0g9>

Journal

Magnetic Resonance in Medicine, 73(2)

ISSN

0740-3194

Authors

Wang, D
Shao, J
Rapacchi, S
[et al.](#)

Publication Date

2015-02-01

DOI

10.1002/mrm.25133

Peer reviewed

Phase Contrast MRI with Flow Compensation View Sharing

Da Wang,^{1,2} Jiaxin Shao,¹ Stanislas Rapacchi,¹ Matthew J. Middione,^{1,2}
Daniel B. Ennis,^{1,2,3} and Peng Hu^{1,2*}

Purpose: To develop and evaluate a technique for accelerating phase contrast MRI (PC-MRI) acquisitions without significant compromise in flow quantification accuracy.

Methods: PC-MRI is commonly acquired using interleaved flow-compensated (FC) and flow-encoded (FE) echoes. We hypothesized that FC data, which represent background phase, do not change significantly over time. Therefore, we proposed to undersample the FC data and use an FC view sharing (FCVS) approach to synthesize a composite FC frame for each corresponding FE frame. FCVS was evaluated in a flow phantom and healthy volunteers and compared with a standard FC/FE PC-MRI.

Results: The FCVS sequence resulted in an error of 0.0% for forward flow and 2.0% for reverse flow volume when compared with FC/FE PC-MRI in a flow phantom. Measurements in the common carotid arteries showed that the FCVS method had -1.16 cm/s bias for maximum peak velocity and -0.019 mL bias in total flow, when compared with FC/FE with the same temporal resolution, but double the total acquisition time. These results represent $\leq 1.3\%$ bias error in velocity and volumetric flow quantification.

Conclusion: FCVS can accelerate PC-MRI acquisitions while maintaining flow and velocity measurement accuracy when there is limited temporal variation in the FC data. **Magn Reson Med 73:505–513, 2015. © 2014 Wiley Periodicals, Inc.**

Key words: phase contrast MRI; velocity encoding; view sharing; flow rate; flow quantification; temporal resolution; temporal footprint

INTRODUCTION

Phase contrast MRI (PC-MRI) is a well-established technique for quantification of blood flow velocity and volume. The typical implementation of PC-MRI for cardiovascular applications requires a cardiac phase-resolved acquisition with adequate spatial and temporal

resolution. These requirements often result in relatively long acquisition times, especially for four-dimensional (4D) flow PC-MRI, which appears to be promising for a number of applications (1,2).

Techniques such as non-Cartesian sampling (3,4), parallel imaging (5–7), and compressed sensing (8–10) have been developed to accelerate PC-MRI acquisitions by taking advantage of the faster speed of non-Cartesian trajectories, the coil geometry, or the inherent sparsity of PC-MRI data. In a typical PC-MRI examination, two sets of images are acquired in an interleaved fashion as shown in Fig. 1a. These acquisitions typically include the flow-compensated (FC) and flow-encoded (FE) data, or alternately positive and negative FE data sets (ie, bipolar flow encoding). The flow velocity is encoded in the phase difference between the two images. The FC image, although required for calculating the background signal phase, typically takes the same amount of time as the FE acquisition, which effectively doubles the temporal footprint (ie, the time span of the data used to reconstruct a single temporal frame) (11) of each temporal frame and decreases the temporal resolution (ie, the time between two successive temporal frames) by 50%. To address this problem, the shared velocity encoding (12) technique uses an interleaved bipolar flow encoding strategy such that the temporal resolution is effectively doubled compared with conventional PC-MRI; however, the temporal footprint of each frame remains the same as the conventional PC-MRI. Temporal resolution and temporal footprint are two important indices that govern, for example, the measurement accuracy of peak velocity, which is important for several clinical applications, including the evaluation of carotid artery stenosis (13,14). Low temporal resolution is associated with underestimation of the peak velocity (12) and a long temporal footprint in PC-MRI also results in underestimation of the peak velocity due to temporal averaging and blurring of the FE data.

In certain PC-MRI applications, such as the assessment of volumetric blood flow in the carotid arteries and the brain, where physiological motion is small, each temporal frame of FC data is not expected to change significantly, assuming the background phase does not change significantly over time. In this regard, the conventional FC/FE PC-MRI acquisition strategy is redundant because it acquires the FC data for each individual temporal frame and the FC data does not contain any FE information. In the present study, we propose a technique to accelerate PC-MRI by using sliding window temporal FC view sharing (FCVS), hence improving both the temporal resolution and temporal footprint. Flow phantom and in vivo studies were performed to validate the accuracy of peak velocity and volumetric flow measurements using the proposed FCVS technique.

¹Department of Radiological Sciences, David Geffen School of Medicine, University of California, Los Angeles, Los Angeles, California, USA.

²Biomedical Physics Interdepartmental Graduate Program, University of California, Los Angeles, Los Angeles, California, USA.

³Department of Bioengineering, University of California, Los Angeles, Los Angeles, California, USA.

Grant sponsor: National Heart, Lung, and Blood Institute; Grant number: 1R21 HL113427; Grant sponsor: American Heart Association; Grant number: 10SDG4200076.

*Correspondence to: Peng Hu, Ph.D., Department of Radiological Sciences, 300 UCLA Medical Plaza Suite B119, Los Angeles, CA 90095. E-mail: penghu@mednet.ucla.edu

Received 24 September 2013; revised 10 December 2013; accepted 23 December 2013

DOI 10.1002/mrm.25133

Published online 14 February 2014 in Wiley Online Library (wileyonlinelibrary.com).

© 2014 Wiley Periodicals, Inc.

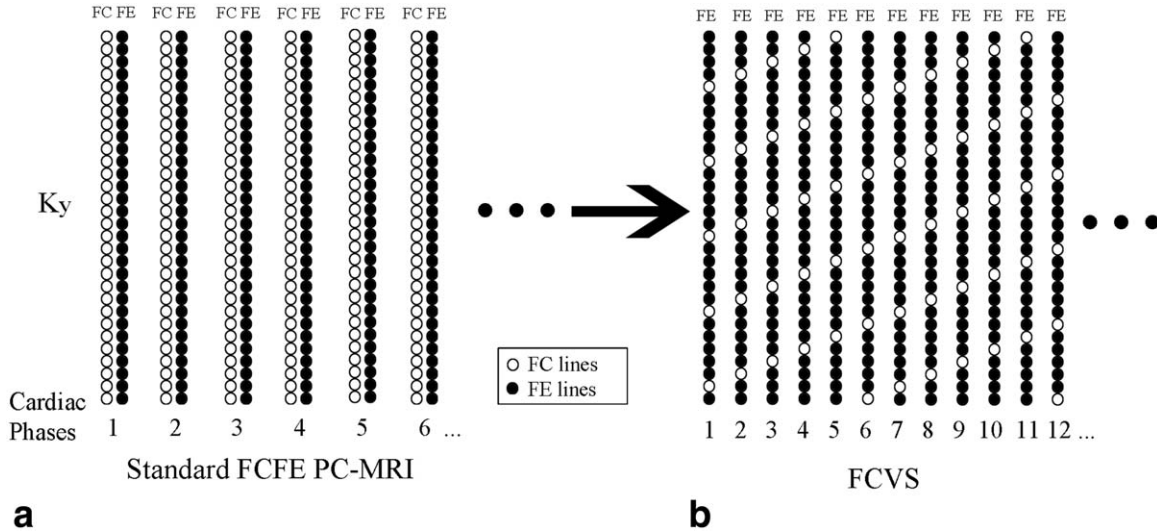


FIG. 1. The data acquisition scheme of (a) the standard FC/FE PC-MRI and (b) the proposed FCVS approach. The FCVS approach approximately doubles the effective temporal resolution by undersampling the FC data by a factor of six.

METHODS

Our institutional review board approved this study. Informed consent was obtained from all participants in this study. All the phantom and in vivo study were performed on a 1.5T scanner with six-channel body (flow phantom study) or head-neck (in vivo studies) coils (Avanto, Siemens, Erlangen, Germany).

MRI Pulse Sequence

For blood vessels such as the common carotid artery (CCA), or peripheral vessels, we hypothesize that the phase of the FC image in a typical PC-MRI scan does not change significantly during the cardiac cycle because it only reflects the background phase, which is not expected to change significantly over time. Therefore, in this study, we propose a PC-MRI technique that uses sliding window FCVS as shown in Fig. 1. In our approach, the FC data is sampled much less frequently than the FE data, as only the FE data contain the FE phase information. In the example shown in Fig. 1b, an FC k-space line is acquired after every five FE lines, hence the FC data are undersampled by a rate $R_{FC}=6$. To compensate for the undersampled FC data, a sliding window view sharing pattern is employed to synthesize a composite FC frame for each corresponding FE frame. For the case of $R_{FC}=6$, FC data from the three cardiac phases before the current frame and two cardiac phases after are included to form the composite FC data for the current frame. Due to the need for FC data acquisition, the FE data are slightly undersampled at $R_{FC}/(R_{FC}-1)=1.2$, and this is overcome by using standard TGRAPPA (15). To calculate the GRAPPA kernel for the FE data, the nearest number of frames equal to R_{FC} were averaged and used as the auto calibration signal. Additionally, a four by three kernel was used for TGRAPPA reconstruction. The traditional phase difference was then calculated between each acquired FE cardiac phase and

its corresponding composite FC frame. In our approach, a longer temporal footprint is used to reconstruct FC images due to view sharing. However, this enables a shorter temporal footprint for the FE phases, which carry the flow information.

Image Analysis

All phase difference images throughout the cardiac cycle were calculated by multiplying the FC image by the complex conjugate of the FE image on a pixel-by-pixel basis, adding the complex results from all of the receiver channels, and taking the phase angle of the sum (16). Region of interest (ROI) contours of the CCA were drawn based on complex difference DICOM images (ie, FC - FE) and propagated to all cardiac phase difference images. The mean flow velocities and peak velocities for each time point were calculated based on the mean and maximum phase difference within the ROI. The maximum mean velocity and the maximum peak velocity were calculated from the mean flow velocity and peak velocity waveforms, respectively, at the time point of the peak during the cardiac cycle. The mean flow rate was calculated by multiplying the mean flow velocity within the ROI by the area of the ROI. The volumetric flow was calculated by integrating the mean flow rate over the cardiac cycle. In the retrospective in vivo study, the error of the proposed FCVS technique in mean flow velocity and peak velocity quantification when compared with the FC/FE reference was calculated as the root mean square error of all the data points over the cardiac cycle. A paired t test was used to compare flow measurements with a two-sided $P < 0.05$ indicating statistical significance.

Computer Simulation

Computer simulations were performed to study the impact of temporal resolution and temporal footprint on

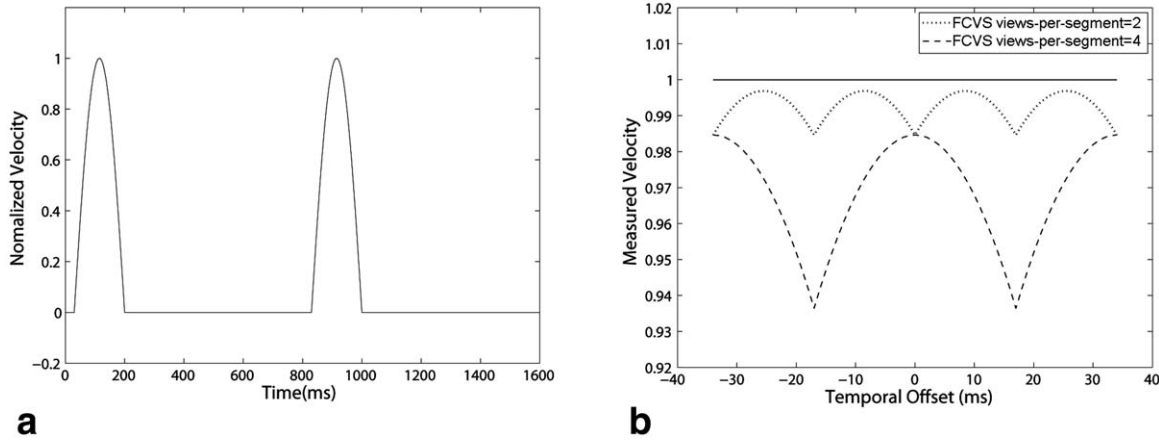


FIG. 2. **a:** Simulated CCA peak velocity waveform with 170-ms half-sinusoidal waveform and 800-ms R-R interval. **b:** Theoretical simulation results show influence of temporal offset, temporal resolution, and temporal footprint of FCVS with views per segment = 2 and 4 on the accuracy of maximum peak velocity measurements.

the accuracy of peak velocity measurements. As shown in Fig. 2a, a 170-ms half-sinusoidal velocity waveform followed by zero velocity was designed to approximate systolic CCA waveform at a heart rate of 75 bpm (800-ms R-R interval). TR was assumed to be 8.5 ms for FC and FE acquisitions. FCVS PC-MRI signal with views-per-segment = 2 and 4 were simulated for maximum peak velocity comparison. For PC-MRI, the maximum peak velocity measurement is also dependent on the temporal offset between the time point of true peak and the time point when PC-MR samples are taken. Therefore, the FCVS signal was simulated for a wide range of temporal offsets to study this effect.

FC Phase Consistency Study

The proposed approach is based on the hypothesis that the signal phase of the FC images does not change significantly over time for relatively stationary tissues because it represents a relatively stable background phase. To test this hypothesis, six healthy volunteers were imaged using a 1.5T scanner and a standard FC/FE PC-MRI sequence, which used the following parameters: through-plane velocity encoding (VENC) = 110 cm/s; flip angle = 30°; readout bandwidth = 260 Hz/pixel; echo time (TE)_{min} = 5.22–6.22 ms; and pulse repetition time (TR)_{min} = 8.5–9.6 ms. Other imaging parameters used were: acquired matrix = 256 × 256; field-of-view (FOV) = 170 × 170 mm² to 200 × 200 mm²; and slice thickness = 5 mm. ROIs within the CCAs were subsequently chosen for each subject to measure the change in the FC phase over the cardiac cycle on a pixel-by-pixel basis. As the complex signal's phase is studied, only data from a single coil channel with the highest signal-to-noise ratio (SNR) in the carotids area were used.

Retrospective In Vivo Study

The same six fully sampled data sets acquired for FC phase consistency study was subsequently used to perform flow velocity and volume measurements. The FC k-space data in these data sets were decimated by the rate

$R_{FC} = 6$ to mimic an undersampled FC acquisition. The view sharing technique was used to generate the composite, but fully sampled FC, cardiac phases as described in Fig. 1b. In our approach, the undersampling rate R_{FC} can potentially affect the reconstruction quality and the resultant quantitative phase (ie, velocity) estimates. Recently, a PC-MRI technique (FE only [FEO]) has been described (17) where the FC data are only acquired for the last cardiac cycle and the same FC data are shared among all the other FE cardiac phases. FEO effectively undersampled the FC data acquisition by a factor equal to the number of cardiac phases. To demonstrate the effect of using different R_{FC} and using the FEO approach, the calculated velocity and total volumetric flow based on $R_{FC} = 6$ and 10 using our FCVS technique and the FEO technique were compared with the ground truth from the fully sampled PC-MRI data.

Flow Phantom Study

The FCVS sequence was implemented and tested prospectively using a flow phantom. The FCVS pulse sequence was compared to the standard FC/FE PC-MRI sequence to demonstrate that it does not introduce significant errors into the volumetric flow and velocity measurements. A pulsatile, but reproducible flow waveform was generated with a computer-controlled flow pump and used to test the agreement of the two sequences with the same temporal resolution. The phantom consisted of rigid pipe with a 25-mm inner diameter and 27-mm outer diameter connected by flexible tubes to a CardioFlow 1000MR computer-controlled displacement pump (Shelley Medical Imaging Technologies, Toronto, Ontario, Canada). The rigid pipe was oriented along the length of the magnet bore and passed through an axial imaging slice at the magnet's isocenter. The flow pump generated a sinusoidal flow waveform with a peak flow rate of 290 mL/s and a period of 924 ms. A simulated retrospective electrocardiography (ECG) signal was used with a 924-ms cardiac cycle length to synchronize data acquisition with the gated PC-MRI sequences. Data were acquired using a standard FC/FE PC-MRI sequence and

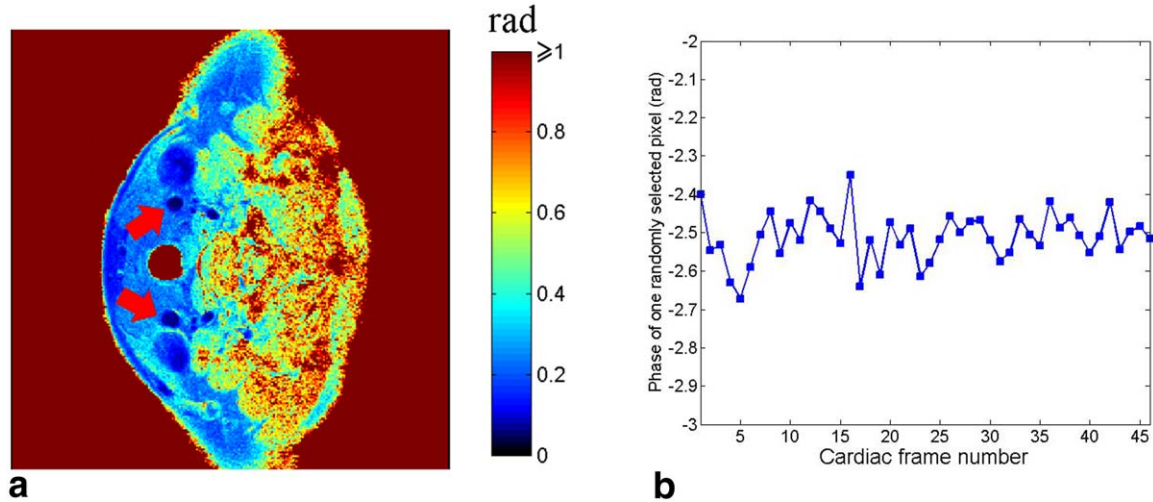


FIG. 3. **a:** A pixel-by-pixel map of the SD of the FC data phase from a single receiver coil with highest SNR. CCAs (red arrows) had very small phase variation through time ($SD = \pm 0.02\pi$). The large phase variation at locations far away from the coil was due to low SNR. **b:** The FC signal phase as a function of the cardiac frames for a randomly selected pixel within the CCA (mean \pm SD = -2.51 ± 0.065).

the FCVS sequence. Both sequences used the following parameters: through-plane VENC = 150 cm/s; flip angle = 30° ; views per segment = 1 (FC/FE) or 2 (FCVS); and readout bandwidth = 501 Hz/pixel. Other parameters used for the flow phantom study were: TE = 4.05 ms; TR = 8.25 ms; acquired matrix = 384×252 ; and FOV = 319×209 mm², which resulted in an in-plane resolution of 0.83×0.83 mm² with 5-mm slice thickness. The temporal resolution for both sequences were 16.5 ms. Due to the acceleration by FCVS, the total acquisition time of the FCVS sequence was 50% of the standard FC/FE.

Prospective In Vivo Study

All scans were acquired during free breathing with retrospective ECG gating. The six volunteers recruited in the retrospective in vivo study were scanned again using the standard FC/FE PC-MRI sequence and the prospective FCVS sequence. Both sequences were implemented using the following parameters: through-plane VENC = 110 cm/s; flip angle = 30° ; readout bandwidth = 260 Hz/pixel; TE_{min} = 5.22–6.22 ms; and TR_{min} = 8.5–9.7 ms. Other imaging parameters included: acquired matrix = 256×256 ; FOV = 170×170 to 200×200 mm²; and slice thickness = 5 mm. Four data sets were acquired for each volunteer: 1) FCVS with 4 views per segment; 2) standard FC/FE with 2 views per segment; 3) FCVS with 2 views per segment; 4) standard FC/FE with 1 view per segment. ROI contours for the left and right CCA were drawn for each volunteer and used to compare the mean flow velocity, peak velocity, and total volumetric flow between FCVS and FC/FE.

As both FCVS and a recently proposed shared velocity encoding (SVE) technique increase the temporal resolution of PC-MRI, six additional healthy volunteers were scanned to compare FCVS and SVE. A modified sequence based on the standard bipolar flow encoding

PC-MRI sequence was developed, where the positively and negatively flow-encoded acquisitions are interleaved to enable the sliding-window SVE reconstruction. For each of the six volunteers, our prospective FCVS sequence and the modified bipolar SVE PC-MRI sequence were performed in a randomized order. Specifically the following five data sets were acquired for each volunteer: 1) SVE with 4 views per segment; 2) FCVS with 4 views per segment; 3) SVE with 2 views per segment; 4) FCVS with 2 views per segment; 5) standard FC/FE with 1 view per segment. The measurements from the standard FC/FE with one view per segment were used as reference.

RESULTS

Computer Simulation

Fig. 2b shows the simulated maximum peak velocity measurements as a function of the temporal offset between the PC-MRI sample points and the true peak. As expected, due to the finite sampling window, the maximum peak velocity is underestimated. Depending on the temporal shift between true peak and FCVS sampling point, the error for maximum peak velocity measurement varied between 0.3% and 1.5% for views per segment = 2, and between 1.5% and 6.3% for views per segment = 4. The relative percentage error was a function of TR, pulse duration, segment, temporal resolution, and temporal footprint, but was independent of actual maximum peak velocity.

FC Phase Consistency Study

A pixel-by-pixel map (Fig. 3a) shows the standard deviation (SD) of the FC signal phase from the receiver channel with the highest SNR acquired on one healthy volunteer. The average SD values within the ROIs for the left and right CCA both were 0.02π . Figure 3b shows the

Table 1

Comparison of Percent Errors Introduced by FC Images View Sharing with Different R_{FC} and Using Last FC Frame for All Phase Difference Calculation (FEO) in Six Volunteers

	Maximum Mean Flow Velocity Error ^b	Maximum Peak Velocity Error ^b	Total Flow Error ^b
$R_{FC}=6$, LCCA	1.2% (0.2%–2.2%)	1.7% (0.7%–2.3%)	0.5% (0.2%–1.0%)
$R_{FC}=6$, RCCA	1.0% (0.1%–1.5%)	1.0% (0.1%–2.0%)	0.3% (0.1%–0.4%)
$R_{FC}=10$, LCCA	2.1% (0.2%–3.4%) ^a	2.4% (0.3%–6.3%)	0.7% (0.3%–1.5%)
$R_{FC}=10$, RCCA	1.3% (0.6%–1.5%) ^a	1.4% (0.2%–2.3%)	0.4% (0.2%–0.6%)
FEO, LCCA	3.3% (0.1%–5.8%) ^a	3.9% (0.1%–6.5%) ^a	4.3% (2.3%–7.9%) ^a
FEO, RCCA	2.0% (0.1%–6.4%) ^a	2.5% (0.9%–4.3%) ^a	3.5% (1.6%–5.7%) ^a

^a $P < 0.05$ when compared with $R_{FC}=6$ at the same location (left common carotid artery [LCCA] or right common carotid artery [RCCA]).

^bMean percentage error (range of percentage error).

FC signal phase over time for one of the pixels within the ROI.

Retrospective In Vivo Study

The maximum mean flow velocity, peak velocity, and total volumetric flow errors introduced by using view sharing with $R_{FC}=6$ and $R_{FC}=10$, and the FEO technique is shown in Table 1. The view sharing technique with $R_{FC}=6$ resulted in significantly reduced errors in the measured maximum mean velocity, peak velocity, and total volumetric flow compared with FEO ($P < 0.05$). The $R_{FC}=6$ acquisition had significantly reduced error in the measured maximum mean velocity compared with the $R_{FC}=10$ acquisition ($P < 0.05$). The average percent error among all six subjects for the velocity calculations from $R_{FC}=6$ were $<2\%$ and $<1\%$ for total volumetric flow volume. Only one in 36 measurements from the $R_{FC}=10$ data had a percent error larger than 5%. For FEO, nine out of 36 measurements were $>5\%$. Based on these results, $R_{FC}=6$ was used for the prospective in vivo study.

An example of the measured mean and peak velocity waveforms over the cardiac cycle for one healthy volunteer is shown in Fig. 4. The velocity measurements based on view sharing ($R_{FC}=6$) correlates well with the reference, with root mean square error of 0.77 cm/s for mean flow velocity and 1.49 cm/s for peak velocity when com-

pared with the fully sampled FC/FE reference data. The FEO technique had a root mean square root error of 1.80 cm/s for mean flow velocity and 3.69 cm/s for peak velocity.

Flow Phantom Study

Mean flow velocities within an ROI measured by the prospective FCVS sequence were compared with measurements acquired with standard FC/FE PC-MRI using the same temporal resolution, but twice the total acquisition time. The mean flow velocities over time were highly correlated (Fig. 5a). The total forward volumetric flow volume was 40.8 mL using FCVS and 40.8 mL using standard FC/FE PC-MRI. The total reverse volumetric flows were -29.6 mL for FCVS and -29.0 mL for standard FC/FE PC-MRI method. The forward and reverse percent error using the FC/FE as the reference was 0.0% and 2.0%, respectively. Fig. 5b shows the peak velocity waveforms for the two sequences.

Prospective In Vivo Study

Figure 6 shows an example of mean flow velocity and peak velocity waveform measurements obtained on a healthy volunteer with 1) FC/FE PC-MRI with 2 views per segment and 34-ms temporal resolution, 2) FCVS with 2 views per segment and 17-ms temporal resolution, and 3) FC/FE PC-MRI with 1 view per segment

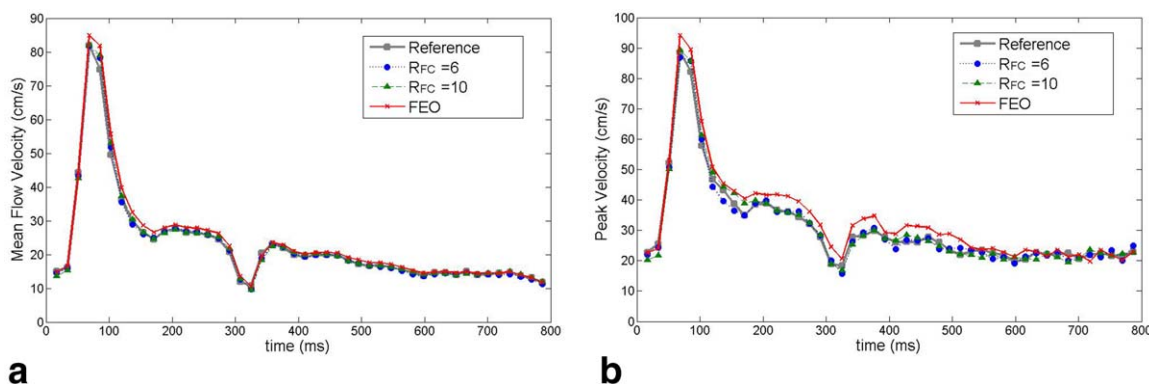


FIG. 4. Comparison of (a) the mean flow velocity waveform and (b) the peak velocity waveform for left CCA measured by standard FC/FE PC-MRI (gray curve), view sharing ($R_{FC}=6$, blue curve; $R_{FC}=10$, green curve), and FEO PC-MRI (red curve). The view sharing technique provided accurate measurements of mean flow velocity and peak velocity. As the FC undersampling factor R_{FC} increased from 6 to 10 and then approaches FEO, the measurement accuracy decreased. In this example, FEO overestimated the mean flow velocity and peak velocity.

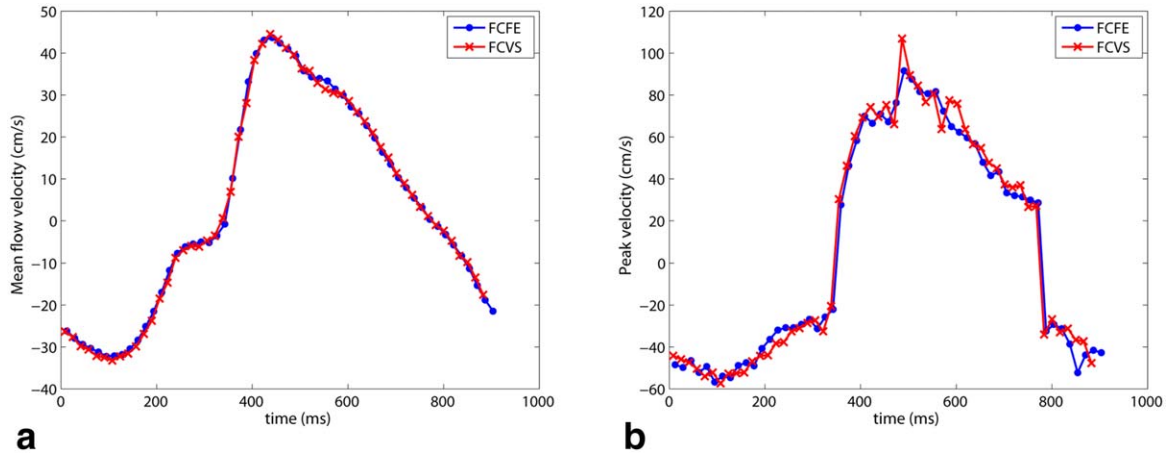


FIG. 5. Mean flow velocity waveform (a) and peak velocity waveform (b) for the flow phantom study. FCVS (red curve) and standard FC/FE PC-MRI (blue curve) are shown. The FCVS technique provides accurate flow velocity measurements, albeit only using half of the acquisition time as standard FC/FE PC-MRI.

with 17-ms temporal resolution. The 34-ms temporal resolution FC/FE scan failed to capture the maximum peak velocity at around 75 ms into the cardiac cycle. The 17-ms FCVS scan provided similar peak velocity values compared with the 17-ms FC/FE scan albeit at half of the total acquisition time. The maximum mean flow velocities and maximum peak velocity for the left and right CCA from the six volunteers are shown in Fig. 7, where the FCVS technique is compared with FC/FE PC-MRI with the same temporal resolution (~ 17 ms), but twice the acquisition time. A Bland-Altman plot demonstrates that the bias was 0.03 cm/s, and the 95% confidence interval was $[-5.10, 5.17]$ cm/s for the maximum mean flow velocity. The bias was -1.16 cm/s and the 95% confidence interval was $[-6.13, 3.81]$ cm/s for the maximum peak flow velocity. The total volumetric flow values measured in the left and right CCA in the six volunteers using FCVS with two different temporal resolutions of 17 ms and 34 ms (views per segment = 2 and 4,

respectively) and standard FC/FE PC-MRI (temporal resolution = 17 ms, views per segment = 1) are shown in Fig. 8. For views per segment = 4, the bias was 0.045 mL and the 95% confidence interval was $[-0.66, 0.75]$ mL. For views per segment = 2, the bias was -0.019 mL and the 95% confidence interval was $[-0.20, 0.24]$ mL.

Examples of peak velocity waveform comparisons obtained on a healthy volunteer with: 1) FCVS (4 views per segment), SVE (4 views per segment), and FC/FE (1 view per segment) and 2) FCVS (2 views per segment), SVE (2 views per segment), and FC/FE (1 view per segment) are shown in Fig. 9. The maximum peak velocity of FC/FE with 1 view per segment was 95.0 cm/s, which was used as the reference. Maximum peak velocities measured by FCVS (90.5 cm/s and 4.7% error for 4 views per segment, and 96.0 cm/s and 1.1% error for 2 views per segment) were more accurate than SVE (80.2 cm/s and 15.6% error with 4 views per segment, 87.4 cm/s and 8.0% error with 2 views per segment). Based on

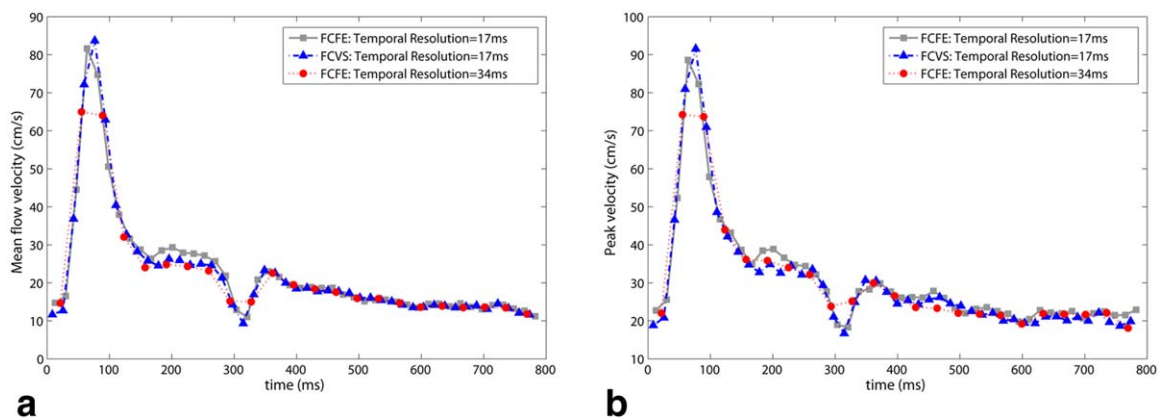


FIG. 6. Mean flow velocity waveforms (a) and peak velocity waveforms (b) from the standard FC/FE PC-MRI (gray curve) with a temporal resolution of 17 ms and an acquisition time of 214 s, FCVS (blue curve) with a temporal resolution of 17 ms and an acquisition time of 106 s, and standard FC/FE PC-MRI (red curve) with a temporal resolution of 34 ms and an acquisition time of 107 s. The FCVS results are highly correlated with the measurements from standard FC/FE PC-MRI at the same temporal resolution, but FCVS only requires 50% of the acquisition time. The standard FC/FE PC-MRI fails to capture the peak velocity at ~ 75 ms or the transient dip at 320 ms when its temporal resolution is halved to match the total acquisition time of FCVS.

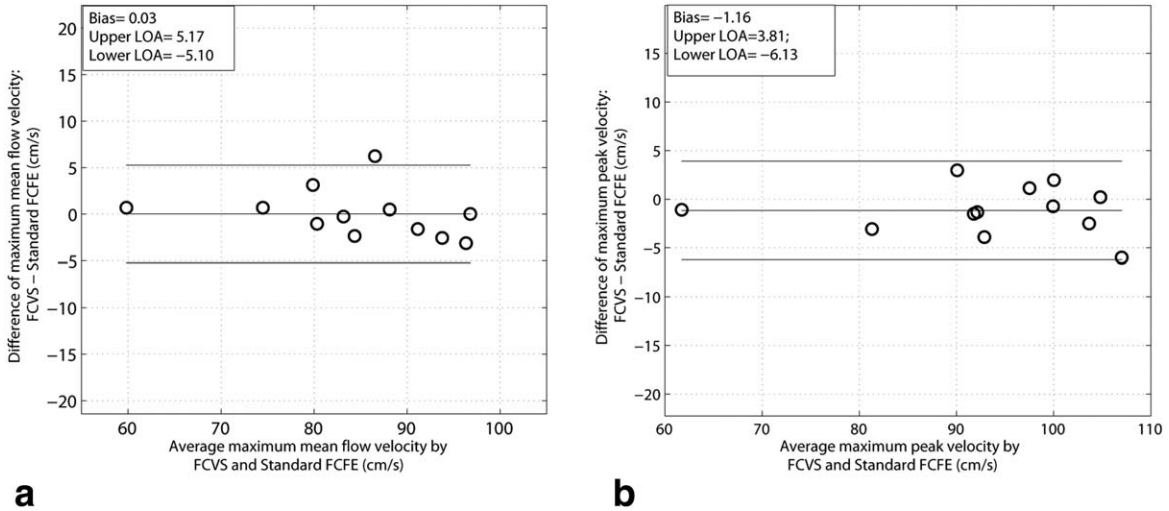


FIG. 7. **a:** Bland-Altman plot of the maximum mean flow velocities between standard FC/FE PC-MRI and FCVS. **b:** Bland-Altman plot of maximum peak velocities between standard FC/FE PC-MRI and FCVS. The standard FC/FE PC-MRI had the same temporal resolution as FCVS, but double the acquisition time. The interval between the upper and lower limits of agreement (LOA) is also known as the 95% confidence interval.

data from the six subjects scanned, the average (range) percentage errors were 2.24% (0.03%–5.62%) for FCVS (2 views per segment), 6.08% (1.04%–11.71%) for SVE (2 views per segment), 3.74% (0.11%–9.03%) for FCVS (4 views per segment), and 9.84% (3.83%–25.72%) for SVE (4 views per segment).

DISCUSSION

In this study, we propose the FCVS technique for accelerating PC-MRI by undersampling the FC k-space and performing a view-shared sliding window reconstruction of the FC data. This was feasible because the FC data only represent a background phase that does not contain dynamic FE information and hence are not expected to vary significantly over time, as demonstrated in Fig. 3. Our strategy results in a two-fold acceleration compared with standard FC/FE PC-MRI while maintaining accu-

racy of in vivo blood flow velocity and volume measurements. Therefore, the proposed technique appears to be promising for flow quantification of blood vessels where there is no significantly physiological motion, such as carotids arteries and intracranial and peripheral blood vessels.

Similar techniques for performing view sharing of the FC data have been previously applied to PC-MRI of the thorax (18), whereas we focus on the CCAs and potentially extend to intracranial or peripheral blood vessels. Many of the blood vessels in the thorax are subject to significant physiological motion and variations in vessel diameter due to the pulsatility of the blood flow. As a result, the FC phase for thoracic vessels likely has greater temporal variation compared with the carotid arteries. Therefore, further studies are needed to study the applicability of FCVS in the thorax and abdomen. Compared with the previous study (18), our study provides a more

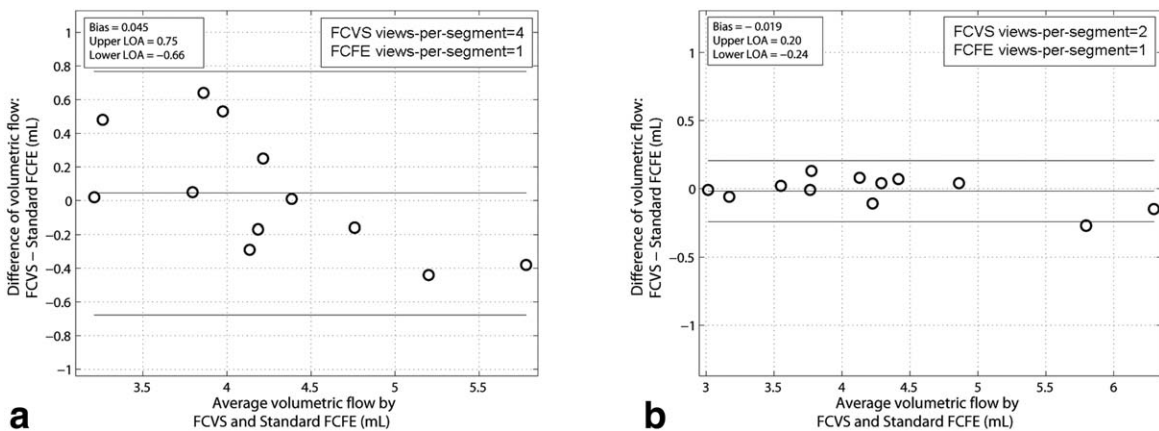


FIG. 8. Bland-Altman plot of total volumetric flow measurements between standard FC/FE PC-MRI (1 view per segment) and FCVS with two different temporal resolutions: in the left and right CCA in six volunteers for a total of 12 flow measurements. **a:** 4 views per segment FCVS and 1 view per segment FC/FE. **b:** 2 views per segment FCVS and 1 view per segment FC/FE. In panel b, the standard FC/FE PC-MRI had the same temporal resolution as FCVS, but double the acquisition time.

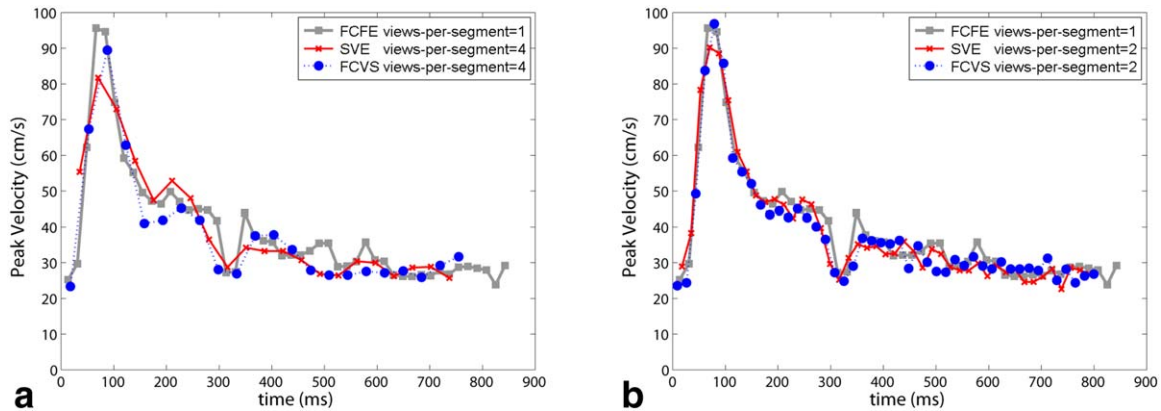


FIG. 9. Example peak velocity waveforms from the left CCA of one volunteer. **a**: Standard FC/FE PC-MRI (gray curve) with 1 view per segment, FCVS (blue curve) with 4 views per segment, and SVE (red curve) with 4 views per segment. **b**: Standard FC/FE PC-MRI (gray curve) with 1 view per segment, FCVS (blue curve) with 2 views per segment, and SVE (red curve) with 2 views per segment. The SVE tends to underestimate the maximum peak velocity due to its longer temporal footprint.

detailed validation using both retrospective and prospective PC-MRI data, which can potentially bring the FCVS techniques presented in our study and the aforementioned study (18) closer to clinical utility.

The FCVS technique accelerates the PC-MRI acquisition by taking advantage of an inherent property of the background phase in PC-MRI. In this study, we demonstrate its use in PC-MRI with FE only in one direction. The same technique could potentially be applied to 4D PC-MRI where three FE directions are sampled. It is noted that the potential acceleration achievable for 4D PC-MRI is approximately 4/3-fold instead of two-fold for 2D PC-MRI. Nevertheless, considering the often prohibitively long acquisition time of 4D PC-MRI, the 4/3-fold acceleration would likely achieve significant and useful savings in time. FCVS can be combined with other fast MRI techniques such as parallel imaging, compressed sensing, or non-Cartesian readout to enable even faster PC-MRI sequence beyond what is achievable using other acceleration techniques alone. The extra acceleration could improve applications such as real-time single-directional flow encoding MRI.

The background phase of the FC data is not expected to change over time, but in practice, there might be slight variations for several reasons. Besides the aforementioned potential FC phase variation due to physiology motion in certain body regions, the flow-related phase is not perfectly compensated for in the FC data due to small residual first- or second-order gradient moments, which might cause phase variations in the presence of pulsatile flow. Nevertheless, in our study, the phase variations in the FC data were all minimal, similar to Fig. 3.

The recently reported SVE approach effectively doubles the temporal resolution of PC-MRI by using a bipolar FE strategy and a sliding window reconstruction technique. Although SVE, FEO, and FCVS can all be used to improve the temporal resolution, there are important differences between them. Although SVE doubles the effective temporal resolution of conventional PC-MRI, its temporal footprint is twice as long as the temporal resolution, because both the positive FE and

negative FE data carry FE information. Therefore, although the temporal frame rate is doubled in SVE, the estimated velocity in each temporal frame is the mean velocity averaged over two temporal frames, which results in underestimation of maximum peak velocity, as shown in Fig. 9. FEO only acquires the FC data for the last cardiac cycle, and the same FC data is shared among all the other FE cardiac phases. FEO effectively improves the temporal resolution and temporal footprint by a factor of 2. However, as shown in Fig. 3b, even though FC data are relative consistent over time, they still have slight temporal variations. Any errors in the last FC frame will be propagated to all other FE temporal frames, which may result in errors on both peak velocity and volumetric flow estimations. Furthermore, although there is not significant bulk motion at the carotid arteries, it is possible that the carotid vessel diameter can expand or shrink slightly during the cardiac cycle. This can at least partially compensate for using our sliding window FC approach but is expected to cause greater error using the FEO approach, which may explain why our FCVS approach has better flow estimation accuracy than FEO as shown in Fig. 4a. In FCVS, the temporal footprint of the FC frames is much longer than the FE frames due to the sliding window view sharing; however, only the FE echoes carry FE information. Therefore, the temporal footprint of FCVS is defined by the temporal footprint of the FE data, which is the same as the temporal resolution. Therefore, our FCVS approach improves both the temporal resolution and temporal footprint, which is of clinical importance for accurate velocity and flow quantification. However, because FCVS relies on ECG gating, its application in patients with arrhythmia can be limited, although the same limitation is also true for the conventional PC-MRI as well as the SVE and FEO approaches. Furthermore, when more views are sampled per k-space segment in FCVS, the temporal footprint of the FC data will inevitably become longer, which increases errors for both maximum peak velocity and volumetric flow measurements. In our study, the flow measurement bias errors associated with views per

segment = 4, which is commonly used in PC-MRI, were still relatively small.

REFERENCES

1. Markl M, Frydrychowicz A, Kozerke S, Hope M, Wieben O. 4D flow MRI. *J Magn Reson Imaging* 2012;36:1015–1036.
2. Harloff A, Albrecht F, Spreer J, et al. 3D blood flow characteristics in the carotid artery bifurcation assessed by flow-sensitive 4D MRI at 3T. *Magn Reson Med* 2009;61:65–74.
3. Gu T, Korosec FR, Block WF, Fain SB, Turk Q, Lum D, Zhou Y, Grist TM, Houghton V, Mistretta CA. PC VIPR: a high-speed 3D phase-contrast method for flow quantification and high-resolution angiography. *Am J Neuroradiol* 2005;26:743–749.
4. Negahdar M, Kadbi M, Tavakoli V, Heidenreich J, Amini AA. Comparison of Cartesian, UTE radial, and spiral phase-contrast MRI in measurement of blood flow in extracranial carotid arteries: normal subjects. *SPIE Proc* 2013. Vol. 8672; 86720A.
5. Griswold MA, Jakob PM, Heidemann RM, Nittka M, Jellus V, Wang J, Kiefer B, Haase A. Generalized autocalibrating partially parallel acquisitions (GRAPPA). *Magn Reson Med* 2002;47:1202–1210.
6. Pruessmann KP, Weiger M, Scheidegger MB, Boesiger P. SENSE: sensitivity encoding for fast MRI. *Magn Reson Med* 1999;42:952–962.
7. Kim D, Dyvorne HA, Otazo R, Feng L, Sodickson DK, Lee VS. Accelerated phase-contrast cine MRI using k-t SPARSE-SENSE. *Magn Reson Med* 2012;67:1054–1064.
8. Lustig M, Donoho D, Pauly JM. Sparse MRI: the application of compressed sensing for rapid MR imaging. *Magn Reson Med* 2007;58:1182–1195.
9. Tao Y, Rilling G, Davies M, Marshall I. Carotid blood flow measurement accelerated by compressed sensing: validation in healthy volunteers. *Magn Reson Imaging* 2013;31:1485–1491.
10. Kwak Y, Nam S, Akçakaya M, Basha TA, Goddu B, Manning WJ, Tarokh V, Nezafat R. Accelerated aortic flow assessment with compressed sensing with and without use of the sparsity of the complex difference image. *Magn Reson Med* 2013;70:851–858.
11. Haider CR, Hu HH, Campeau NG, Huston J, Riederer SJ. 3D high temporal and spatial resolution contrast-enhanced MR angiography of the whole brain. *Magn Reson Med* 2008;60:749–760.
12. Lin H-Y, Bender JA, Ding Y, Chung Y-C, Hinton AM, Pennell ML, Whitehead KK, Raman SV, Simonetti OP. Shared velocity encoding: a method to improve the temporal resolution of phase-contrast velocity measurements. *Magn Reson Med* 2012;68:703–710.
13. Srichai MB, Lim RP, Wong S, Lee VS. Cardiovascular applications of phase-contrast MRI. *Am J Roentgenol* 2009;192:662–675.
14. Vanninen RL, Manninen HI, Partanen PL, Vainio PA, Soimakallio S. Carotid artery stenosis: clinical efficacy of MR phase-contrast flow quantification as an adjunct to MR angiography. *Radiology* 1995;194:459–467.
15. Breuer FA, Kellman P, Griswold MA, Jakob PM. Dynamic autocalibrated parallel imaging using temporal GRAPPA (TGRAPPA). *Magn Reson Med* 2005;53:981–985.
16. Lu K, Liu TT, Bydder M. Optimal phase difference reconstruction: comparison of two methods. *Magn Reson Imaging* 2008;26:142–145.
17. Offerman E, Glielmi C, Markl M, Koktzoglou I, Edelman RR. Flow-Encode Only Phase Contrast Magnetic Resonance Imaging. In Proceedings of the 21st Annual Meeting of ISMRM, Salt Lake City, Utah, USA, 2013. Abstract 4434.
18. Lin H-Y, Ding Y, Chung Y, Raman S.V., Simonetti O.P. Efficient Velocity Mapping by Accelerated Acquisition of Phase Reference Data. In Proceedings of the 15th Annual Meeting of ISMRM, Berlin, Germany, 2007. p. 249.