

UC Davis

UC Davis Previously Published Works

Title

Kinematic performance of a novel temporomandibular joint replacement prosthesis under bite-force conditions in dogs and cats.

Permalink

<https://escholarship.org/uc/item/4cs4f5ss>

Authors

Arzi, Boaz

Weed, Morgan

Garcia, Tanya C

et al.

Publication Date

2024-04-01

DOI

10.2460/ajvr.24.01.0009

Copyright Information

This work is made available under the terms of a Creative Commons Attribution-NonCommercial License, available at <https://creativecommons.org/licenses/by-nc/4.0/>

Peer reviewed

Kinematic performance of a novel temporomandibular joint replacement prosthesis under bite-force conditions in dogs and cats

Boaz Arzi, DVM, DAVDC, DEVDC, FF-AVDC-OMFS^{1,2*}; Morgan Weed, BS¹; Tanya C. Garcia, MS^{1,2}; Stephanie L. Goldschmidt, DVM, DAVDC, DEVDC¹; Denis J. Marcellin-Little, DEDV, DACVS, DECVS, DACVSMR^{1,2}

¹Department of Surgical and Radiological Sciences, School of Veterinary Medicine, University of California-Davis, Davis, CA

²The J.D. Wheat Veterinary Orthopedic Research Laboratory, School of Veterinary Medicine, University of California-Davis, Davis, CA

*Corresponding author: Dr. Arzi (barzi@ucdavis.edu)

OBJECTIVE

To evaluate the kinematics and stability of the temporomandibular joint (TMJ) of cats and dogs with and without a TMJ replacement (TMJR) prosthesis under simulated bite forces and mouth opening.

ANIMALS

Sixteen cadaver skulls from domestic cats (n = 8) and medium- to large-breed dogs (n = 8).

METHODS

Intact TMJs were tested. Following condylectomy and coronoidectomy, the skulls were fitted with a TMJR prosthesis unilaterally and retested. Prosthesis was similarly implanted in the contralateral TMJ in 4 cats and 4 dogs before retesting. Left and right bite motions were evaluated before bite contact to peak bite force (200 N in dogs, 63 N in cats). Mouth opening motion was recorded. Mandibular displacement under load was evaluated in 3 orthogonal planes. Maximal displacement was compared between TMJR groups and native TMJ. Prosthesis-bone motion of the temporal and mandibular components was evaluated during simulated bites and mouth opening.

RESULTS

TMJR resulted in joint motion not demonstrably different from the native TMJ, with the ability to fully open and close the mouth and with minimal laterotrusion. The TMJR prosthesis demonstrated similar stability after unilateral and bilateral replacement during bite force and with an open mouth. Mean implant-bone motion during bite simulations for the temporal and mandibular TMJR components was $\leq 60 \mu\text{m}$ in cats and $\leq 30 \mu\text{m}$ in dogs.

CLINICAL RELEVANCE

A novel TMJR can be implanted and allows normal jaw motion. Joint stability is maintained after TMJR implantation in the TMJ of dogs and cats TMJ that is devoid of muscular support.

Keywords: temporomandibular joint, prosthesis, implant, kinematics, biomechanics

The temporomandibular joint (TMJ) may be affected by several disorders, including geometric abnormalities, end-stage degenerative joint disease, ankylosis, and neoplasia.¹⁻⁵ These disorders result in pain and dysfunction, leading to morbidity in eating, drinking, swallowing, and self-defense and potential mortality.^{1-4,6-8}

In humans, TMJ replacement (TMJR) is recommended when conservative management has failed or salvage procedures, such as gap arthroplasty,

are required.^{1,2,9-11} Modern TMJR was introduced in 1986.^{9,10} The design features and clinical applications of TMJR for humans have been reviewed elsewhere¹²⁻¹⁴ Briefly, the TMJR prostheses that are used most widely are cementless implants with low-constraint metal on polyethylene-bearing surfaces from manufacturers such as TMJ Concepts, Stryker, and Biomet/Lorenz Microfixation TMJ replacement system.⁹ In these implants, “low constraint” means that the convex metal head is not held in the concave polyethylene liner. Rather, the metal head can slide rostrocaudally and allows movements of the mandibular component of the prosthetic TMJ and the mandible relative to the skull in the sagittal, frontal, and transverse planes. These systems have high

Received January 6, 2024

Accepted March 25, 2024

doi.org/10.2460/ajvr.24.01.0009

© 2024 THE AUTHORS. Published by the American Veterinary Medical Association as an Open Access article under Creative Commons CCBY-NC license.

success rates and lead to the largest mouth-opening angles and highest quality of life relative to other TMJR prostheses.^{5,9,11}

In dogs and cats, ankylosis is an occasional condition affecting the TMJ.^{15,16} Ankylosis is a severely debilitating condition; patients exhibit a loss of ability to open the mouth that progresses rapidly.^{15,17,18} Ankylosis of the TMJ prevents adequate water intake, food prehension, thermoregulation, grooming, and vocalization.^{15,18} Ankylosis may also lead to skeletal and dental malocclusion, periodontitis, and oral mucosal ulcers. Gap arthroplasty has been demonstrated as a salvage procedure where ankylotic tissues are excised to allow for opening of the mouth.¹⁶ Gap arthroplasty results in opening of the mouth to allow eating, drinking, grooming, and survival. However, mandibular drift, malocclusion, and a recurrence of ankylosis may occur.^{10,16}

A TMJR prosthesis was developed to address the clinical ramifications of a TMJ loss in cats and dogs (US patent no. 63/414,297, filed October 7, 2023). The prosthesis has a mandibular and a temporal component made of titanium alloy (Ti6Al4V), and the temporal component has a polyethylene liner. The aims of this study were to evaluate the initial stability of the TMJR and its range of motion under simulated jaw opening and bite forces in cats and dogs. We hypothesized that the mandibular and temporal bone-implant interfaces will be stable under bite loads simulating mastication (ie, exhibit bone-implant displacements < 100 μ m) and that the TMJR will be stable (ie, exhibit motion in each plane within 3 mm of motion in the unoperated TMJ) have a stability not demonstrably different from a normal TMJ during simulated jaw opening and bite loads. To test these hypotheses, we conducted an ex vivo study on cadaver heads of adult domestic cats and dogs.

Methods

TMJR prosthesis

Temporal and mandibular components of a TMJR prosthesis for large-breed dogs and cats were designed to fit on 5 large-breed dog skulls and 5 cat skulls, respectively. The TMJR prosthesis had a temporal/zygomatic component that included a computer numerical control (CNC-machined fixation plate, a press-fit liner, and a mandibular component that included a CNC-machined fixation plate with a prosthetic neck and head extending caudally and proximally) (**Figure 1**). The temporal/zygomatic and mandibular components were made of titanium alloy (Ti6Al4V), and the liner was made of crosslinked ultra-high-molecular-weight polyethylene. The prosthetic head diameter was 4.3 mm for the cat TMJR and 7.5 mm for the dog TMJR. The head was slightly constrained by the liner for the cat and dog TMJR so that it could be reduced and separated using gentle manual pressure and traction, respectively.

Sample and preparation

The study used a sample of convenience. Eight clinically healthy cadaver heads from adult cats and




Figure 1—These exploded renderings of temporomandibular joint (TMJ) replacement (TMJR) prostheses for cats (A) or dogs (B) show the mandibular components, liner, and temporal components, with a box for the polyethylene liner. For the cat, the mandibular component has a 33-mm-long plate with 4 threaded holes for 2.0-mm locking screws and a 4.5-mm-diameter prosthetic head. The temporal component has a plate with 3 holes for 2.0-mm cortical (nonlocking) screws. For the dog, the mandibular component has a 55-mm-long plate with 5 threaded holes for 2.4-mm locking screws and a 7.3-mm-diameter prosthetic head. The temporal component has a plate with 4 holes for 2.4-mm cortical screws.

8 clinically healthy cadaver heads from adult medium- to large-breed dogs weighing 25 to 35 kg that were euthanized for reasons unrelated to this study were used. For all skulls, the muscles of mastication (temporalis, masseter, medial/lateral pterygoid, and digastricus) were bilaterally excised. The lateral ligaments surrounding the TMJ and the joint capsules were left intact. A small metal plate was placed at the insertion site of the masseter, pterygoid, and digastricus muscles and was secured with screws on the caudoventral aspect of both mandibles (**Figure 2**). The plate fixation was reinforced using nonsurgical dental cast polymethyl methacrylate (PMMA) (Coe Tray

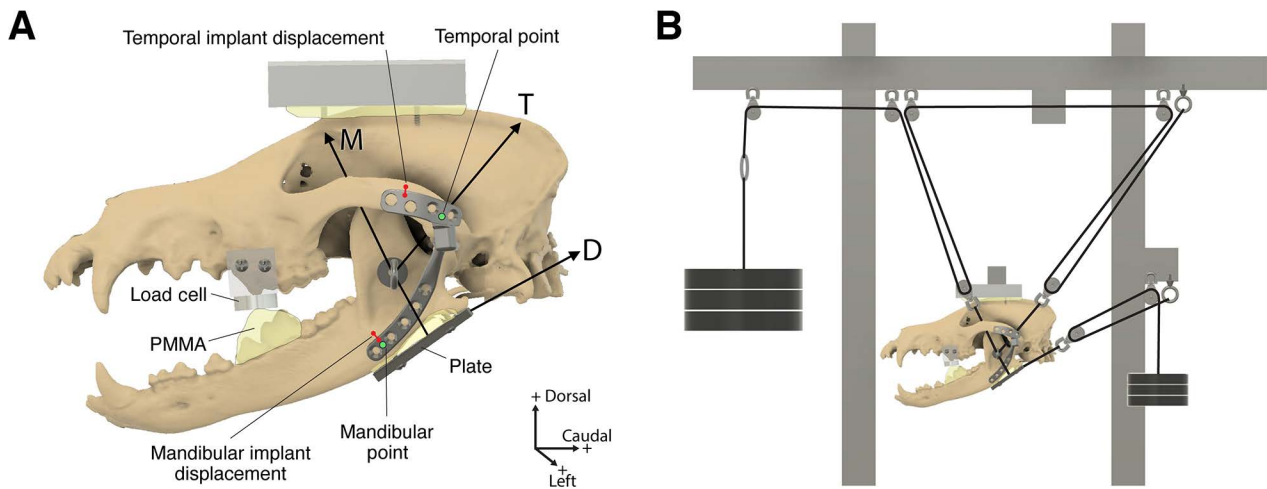


Figure 2—Illustration of a dog skull with TMJR prosthesis replacing the left TMJ (A). A load cell has been fixed to the maxillary premolar teeth. Polymethyl methacrylate has been added to a mandibular premolar and molar teeth and has been shaped so that it contacts the load cell when the mouth closes. A bone plate has been fixed to the caudoventral aspect of the mandible. Three vectors show the direction of action of masticatory muscles: the masseter (M) and digastricus muscles (D) originate on the mandibular fixation plate, and the temporalis muscle (T) originates on a hook on the mandibular ramus. The locations used to measure mandibular motion relative to the zygomatic arch (temporal and mandibular points, green circles) and to measure displacement of the prosthetic components relative to the adjacent bone (short red lines with dots) are shown. The reference frame shows directional definitions. The instrumented skull has been placed in a load frame conceptually showing how pulleys allow hanging weights to produce the simulated contraction forces of the temporalis and masseter muscles for mouth closing and the digastricus for mouth opening on the left and right sides equally and simultaneously (B). PMMA = Polymethyl methacrylate.

Plastic; GC America). The plate was aligned with the ramus, rostrally, and the angular process, caudally. A small eye bolt was secured to the ramus of both mandibles at the insertion site of the temporalis muscle and fixed using PMMA as previously described.¹⁹ A 3D-printed load cell holder was secured to the left and right maxillary premolar and molar teeth using 2 pins and PMMA. The load cell was placed in the holder. PMMA was placed on the fourth premolar and first molar teeth of the mandible on both sides so that PMMA contacted the load cells when the jaw was closed. Dorsally, the parietal bone was secured to the load frame using screws and PMMA.

Preliminary study of implant motion

A pilot study was performed to determine the range of motion of TMJR components in the cat and the dog before and after implantation. Computed tomography images of 5 cat and 5 dog skulls unrelated to the final study were imported into computer modeling software (Fusion 360, Autodesk). The respective model of the implants was also imported. The temporal and mandibular components were oriented to fit best on the bones when the mandible was in occlusion (**Figure 3**). The caudal and medial tilts of the temporal component relative to each skull's sagittal and frontal planes were measured. To fit the temporal component to the skull, the mean caudal tilt from the skull transverse plane was 12° for cats and 10° for dogs, and the mean medial tilt from the skull sagittal plane was 6° for cats and 8° for dogs. The mean medial angulation of the mandibular plate from the temporal component was 5° for cats and 4° for dogs.

The temporal and mandibular components were set at the mean medial and caudal tilt angles listed above. That neutral implant position was defined as the origin of rostrocaudal and mediolateral motion (0° in each of these 2 planes). From that neutral position, the plate was rotated in 5° increments in the motion of jaw closing (negative motion) and opening (positive motion) about the mandibular component's prosthetic head, keeping the mandibular plate in the sagittal plane of the head, through the furthest mechanical extents (limits where the plate contacted the liner rostrocaudally without regard to skull anatomy or occlusion). At each 5° increment, the plate was rotated within the frontal plane, and the mechanical extents where the plate collided with the liner were determined. The open-close (rostrocaudal) range of motion for the cat and dog implants were 46° and 36°, respectively (Figure 3). Mediolateral range of motion varied based on the mouth-opening angle between 16° and 48° for the cat and between 17° and 36° for the dog. The data show that the mechanical extents of the TMJR prosthesis are well beyond the anatomical limits of mandibular motion. Therefore, the TMJR prosthesis is unlikely to restrict mandibular motion, even in the presence of adjustments to the implant position done to fit the prosthetic components to the temporal and mandibular bones.

TMJR prosthesis implantation

Following mechanical testing of the intact TMJ (described below), a left condylectomy and coronoidectomy were performed using a piezo surgical unit (Piezotome Cube; Acteon) with a bone-cutting

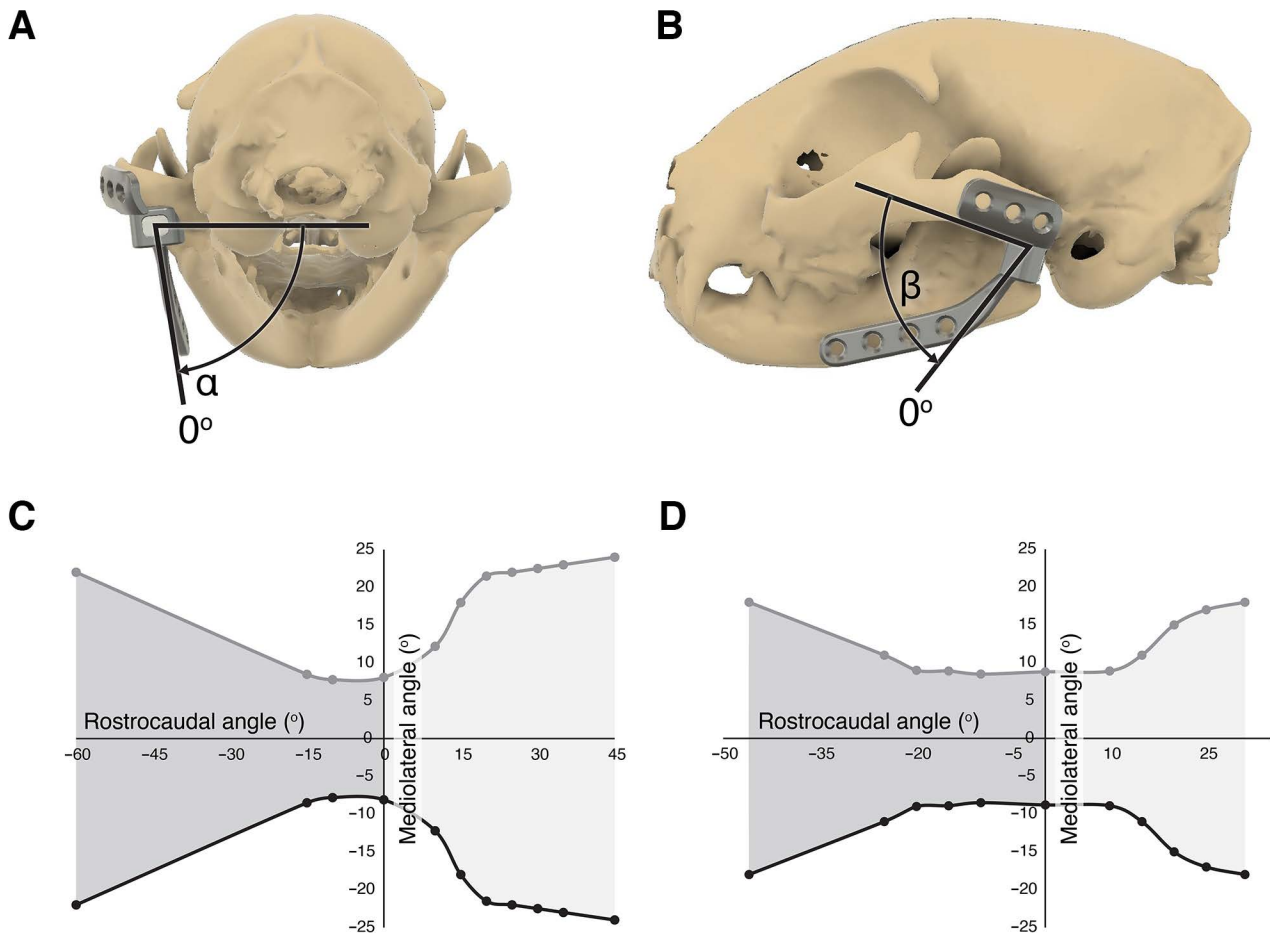


Figure 3—Determination of impingement-free implant motion included the placement of the temporal and mandibular components of a cat (A and B) and dog (not shown) skull in silico. The temporal component was tilted caudally, and the mandibular component was tilted medially to optimize implant fit on 5 cats and 5 dogs before the evaluation of impingement-free motion. Plots demonstrating the impingement-free rostrocaudal (within the sagittal plane, β) and mediolateral (within the frontal plane, α) motion of the TMJR implant relative to the temporal prosthetic component are shown for 1 cat (C) and dog skull (D). Maximal medial (black line) and lateral (gray line) impingement-free motions are shown. Positive rostrocaudal motion (shaded in light grey) represents mouth opening. Negative rostrocaudal motion (shaded in dark grey) is theoretical since the jaw closes at a rostrocaudal angle of approximately 0° .

tip (BS1S or BS1L; Acteon) as performed clinically for TMJ surgeries at our facility.¹⁶ The condylar and coronoid processes were removed in 1 piece. The TMJ disk was removed. The piezo surgical unit was used to remove the retroarticular process to flatten the mandibular fossa of the squamous temporal bone, allowing the placement of the temporal plate of the TMJR. The TMJR components were secured to the temporal bone and mandible while the jaw was manually kept in occlusion, similar to the placement of maxillomandibular fixation.

Temporal plate fixation to the caudolateral aspect of the zygomatic arch and the mandibular fossa was achieved using 3 6-mm-long 2.0-mm titanium cortical screws (VST201.006; DePuy Orthopaedics; 1.5-mm pilot hole, 0.75-mm thread pitch) for the cat and 3 8-mm-long 2.4-mm titanium cortical screws (VST212.008; DePuy Orthopaedics; 1.8-mm pilot hole, 0.60-mm thread pitch) for the dog. Mandibular plate fixation was achieved using 3 8-mm-long 2.0-mm titanium locking screws (VST202.008;

DePuy Orthopaedics) for the cat and 3 16-mm-long 2.4-mm locking titanium screws (VST212.016; DePuy Orthopaedics) for the dog. In cats, the caudal hole of the mandibular plate was left empty. In dogs, the caudal hole of the temporal plate and the caudal 2 holes of the mandibular plate were left empty. The liner was inserted into the temporal plate. The mandibular head was manually fitted into the liner. In cases with suboptimal innate occlusion, occlusal adjustment was achieved by bending the mandibular plate.

Mechanical testing

A load frame similar to a frame used in a previous experiment²⁰ was custom-built from extruded aluminum framing (Bosch Rexroth). The parietal bone was rigidly attached to the frame, and the mandible hung freely (Figure 2). A 2-kN load cell (SLV-500; Transducer Techniques) with a 19-mm (0.75") diameter and a 6-mm (0.25") thickness was placed in the load cell holder on the maxillary teeth. A bite was

produced on cadaveric skulls by simulating muscle activation on skulls without and with TMJR prostheses to determine if the implant had an effect. Three treatments were successively applied: intact TMJ, left unilateral TMJR (UniTMJR), and bilateral TMJR (BiTMJR). Intact TMJ and UniTMJR were tested on 8 cats and 8 dogs; BiTMJR was tested on the first 4 cats and 4 dogs based on the results of a power analysis that indicated that a sample size of 3 was sufficient to detect a 4-fold increase in mean displacement.

Mechanical complications, such as fissure, fracture, or luxation, during implantation were recorded. During preliminary mechanical testing, 6 rostral liner dislodgements relative to the temporal component (rostral liner translation) were observed after UniTMJR in 2 cats and 1 dog and after bilateral TMJR in 2 cats (1 unilateral liner dislodgement and 1 bilateral). Liner dislodgement appeared associated with a slightly undersized liner (4 instances) or excessive temporal component inclination (2 instances). To address these dislodgements, the 4 undersized liners were exchanged, and 2 temporal components were placed slightly more cranially on the zygomatic arch. By doing so, the inclination of the temporal components decreased, and their center of rotation translated cranially. Subjectively, the change in inclination was $< 10^\circ$. These changes were sufficient to eliminate liner dislodgement.

Displacement of the mandible was measured on the left side for intact TMJ, after unilateral left TMJR, and after BiTMJR (for a subset of patients). Motion simulations included a bite with the object (load cell) on the left side, a bite with the object on the right side, and mandible opening.

Traction was applied to both mandibles using 80-lb-test braided nylon lines to simulate the pulls of action of the masticatory muscles. In cats, to simulate the action of the masseter muscles, lines were attached bilaterally to the ventral metal plate, traveled 50° dorsorostrally, and were connected to a pulley. To simulate the temporalis muscles, nylon lines were attached to the eye bolt in the ramus of the mandible, traveled 135° caudomedially medial to the zygomatic arch, and connected to a pulley.²¹ At the caudal aspect of the ventral metal plate, a third nylon line was attached and pulled 22° caudodorsally to simulate the pull of the digastric muscle during mouth opening. In dogs, the setup was similar to cats but with traction angles of 65° for the masseter muscle, 130° for the temporalis muscle, and 26° for the digastric muscle.²¹⁻²³ The nylon lines were also routed through a pulley system on each side of the mandible through the bone-attached pulleys, directed to positioning pulleys on the frame (Figure 2). The lines on both sides were connected to each other rostrally with a freely moveable ring on the line to ensure equal pull on each side of the mandible. Prior to loading, an electronic hoist (EMW-500B; Coffing Hoist) supported a stack of weights. To start data collection, the hoist slowly lowered the weights at a speed of 0.081 m/s onto the pulley line that was attached to the skull.

The amount of hanging weight that generated the force equivalent to a bite force on the load cell was determined in a separate trial for a cat and a dog. In dogs, the maximum bite force has been reported to be 600 N.^{21,24} In humans, chewing produces a bite force equivalent to one-seventh of the maximal bite force, and denture wearers produce one-third of the bite force produced by natural teeth.^{25,26} To simulate daily living forces such as mastication, licking, and yawning in cats and dogs, a bite force of one-third of maximal bite force was selected, which is still likely greater than actual force during normal chewing, while large enough to make sure the implants withstood large forces. In dogs, the force used was 200 N for one side of the mandible.²⁷ The weights required to create a 200-N bite force using the pulley setup was 35 kg, which resulted in a bite force of 150 to 250 N, depending on skull anatomy. In cats, the target bite force was 63 N for one side, representing one-third of a maximal bite force of 190 N.²⁸ The hanging weights used to achieve 63 N were 15.5 kg, which resulted in a bite force of 60 to 70 N for one side of the mandible among cat skulls. For mouth opening, the force of the digastric muscle is 60% of that of the masseter muscle, the masseter muscle accounting for about 35% of the total bite force.²⁹ From this calculation, a force of 15 N (2.5 kg on the pulleys) was used to produce mouth opening in cats, and a force of 45 N (5.2 kg on the pulleys) was used to produce mouth opening in dogs.

Motion measurements

Motion was captured using a 3-camera digital image correlation (DIC) system (Dantec Dynamics). Three cameras affixed to a tripod were positioned to view the left lateral skull. The cameras were calibrated in 3 dimensions using a manufacturer's video calibration object. Skulls were spray-painted white, allowed to dry, and lightly speckled with black dots using spray paint. Data were synchronously initiated and captured at the same rate as the load cell (50 Hz). The DIC software used image correlation to determine the motion of the black speckle pattern in a grid of square facets, which are 17 X 17 pixels in size, covering the mandible and zygomatic region. The resolution of motion was 0.01 mm. Diamond-shaped regions of interest measuring 0.51 mm² were placed at 2 locations to capture regions of motion: at the implant on the zygomatic arch (or equivalent location on the intact skull) and at the mandibular plate between the rostral-most screw hole and the next hole (or equivalent location on intact skull; Figure 2). The linear gauge DIC software function was used to measure temporal and mandibular implant-bone displacement by calculating point-to-point displacement during loading tests (**Supplementary Figure S1**). The points of interest were drawn at the dorsal edge of the implants, adjacent to the Zygomatic Point and Mandibular Point and on the adjacent bone. The position of each region of interest was determined for the loading/movement cycle and exported in 3 dimensions in the reference frame. Mechanical complications during testing were recorded.

Data reduction

For left and right biting conditions, bite motion started just prior to teeth contacting the load cell. The maximum bite displacement was measured at the time of peak force on the load cell. Displacement was maximal bite position minus starting position. To determine the effect of biting motion on the mandible, the zygomatic arch was used as a reference frame, so the Zygomatic Point was subtracted from the Mandibular Point to exclude skull motion in the load frame. Displacement from start bite to end bite was measured in the 3 anatomical directions. To measure implant-bone motion, change in line-gauge length was collected relative to line length at the start of bite motion.

For mouth-opening motion, the start-gape angle was first determined for each skull. The largest start-gape angle of all skulls was determined and used as the start-gape angle for each skull by starting data collection when the start-gape angle occurred. The maximum mandible-open position for each skull was found as the caudal-most position while fully loaded in the pulley system. The Zygomatic Point displacement was subtracted from the Mandibular Point to account for possible head motion, and the change in displacement was measured relative to the start-gape angle. The change in displacement in 3 dimensions of the Mandibular Point while held loaded at maximum opening was determined as the time when the load was fully on the pulleys, with a hold of 0.5 seconds. The displacement in 3 dimensions during the hold was determined.

Statistical analysis

Maximum displacements during bite motion and mouth opening were compared between the native TMJ, UniTMJR, and BiTMJR using an ANOVA with repeated measures. Data were assessed for normality with Shapiro-Wilks at $P < .05$. Values that were not normally distributed were transformed to ranks before the ANOVA. Post hoc pairwise comparisons were done with Tukey honestly significant difference

(HSD) test and were considered significantly different with $P < .05$.

Results

Twenty-four TMJR procedures were performed in cadaveric cat and dog heads. No mechanical complication occurred during implantation or testing. A range of motion was achieved larger than in vivo jaw-opening motion, indicating that TMJR would not restrict mouth opening.³⁰⁻³² Similar to other maxillofacial applications, the principles of internal fixation set by the *Arbeitsgemeinschaft für Osteosynthesefragen* were used to secure the TMJR implants.^{33,34}

Motions of the mandible relative to the temporal bone were numerically very similar between intact TMJ, UniTMJR, and BiTMJR. In cats, motion of the mandible relative to the temporal bone ranged from 0.036 mm to 0.885 mm in intact TMJ, 0.011 mm to 1.187 mm after UniTMJR, and 0.008 mm to 6.505 mm after BiTMJR (**Table 1**). Rostrocaudal motion during left bite was less after BiTMJR than in intact TMJ ($P = .034$) and mediolateral motion during right bite was less after UniTMJR than in intact TMJ ($P = .002$). In dogs, motion of the mandible relative to the temporal bone ranged from 0.397 mm to 1.747 mm in intact TMJ, 0.414 mm to 3.079 mm after UniTMJR, and 0.003 mm to 14.282 mm after BiTMJR (**Table 2**). Mediolateral motion during right bite was also less after UniTMJR than in intact TMJ ($P = .017$). Other motions did not differ statistically between intact TMJ, UniTMJR, and BiTMJR in cats and dogs.

In cats, mean prosthesis-bone motion during bite simulations ranged from 20 to 41 μm after UniTMJR and 36 to 60 μm after BiTMJR (**Table 3**). These motions did not differ statistically. Mean implant-bone motion during mouth opening was 53 μm after UniTMJR and 141 μm after BiTMJR. In dogs, mean implant-bone motion during bite simulations ranged from 3 to 30 μm after UniTMJR and BiTMJR. These motions did not differ statistically.

Table 1—Mean (\pm SD) temporomandibular joint (TMJ) displacement during bite simulations and mouth opening in 8 cat skulls.

Test	Direction	Intact TMJ (mm) ^a	Left UniTMJR (mm) ^a	BiTMJR ^{a,b} (mm)
Left bite	Rostrocaudal	-0.359 ^c \pm 0.511	-0.091 ^{c,d} \pm 0.886	-0.036 ^d \pm 0.837
	Dorsoventral	0.063 \pm 0.181	0.339 \pm 0.458	0.284 \pm 0.369
	Mediolateral	0.263 \pm 0.957	0.044 \pm 0.542	0.885 \pm 0.523
Right bite	Rostrocaudal	-0.478 \pm 0.672	-0.323 \pm 1.103	0.018 \pm 0.931
	Dorsoventral	0.256 ^c \pm 0.310	0.801 ^d \pm 0.361	0.231 ^c \pm 0.438
	Mediolateral	1.187 ^c \pm 1.061	0.011 ^d \pm 0.495	0.750 ^{c,d} \pm 0.609
Mouth opening	Rostrocaudal	6.505 \pm 4.560	5.133 \pm 3.549	6.338 \pm 3.686
	Dorsoventral	-1.833 \pm 1.663	-2.822 \pm 1.964	-2.596 \pm 1.329
	Mediolateral	0.073 \pm 0.817	0.019 \pm 0.495	0.554 \pm 1.117
	Held open rostrocaudal	0.233 \pm 0.151	0.323 \pm 0.160	0.223 \pm 0.112
	Held open dorsoventral	-0.025 ^c \pm 0.038	-0.123 ^d \pm 0.045	-0.068 ^{c,d} \pm 0.030
	Held open mediolateral	0.008 \pm 0.218	-0.029 \pm 0.088	0.057 \pm 0.055

Within a row, means with different superscript letters (^c and ^d) differ significantly ($P < .05$).

BiTMJR = Bilateral TMJ replacement. UniTMJR = Unilateral TMJ replacement.

^aPositive values represent caudal, dorsal, and left lateral displacement of the mandible relative to the temporal bone. ^bN = 4 cat skulls.

Table 2—Mean (\pm SD) TMJ displacement during bite simulations and mouth opening in 8 dog skulls.

Test	Direction	Intact TMJ ^a (mm)	Left UniTMJR ^a (mm)	BiTMJR ^{a,b} (mm)
Left bite	Rostrocaudal	1.059 \pm 1.592	1.594 \pm 1.131	1.747 \pm 1.329
	Dorsoventral	-0.422 \pm 0.897	-0.425 \pm 1.100	-1.071 \pm 0.826
	Mediolateral	0.677 \pm 1.730	-0.628 \pm 1.022	0.397 \pm 1.740
Right bite	Rostrocaudal	1.277 \pm 1.812	1.587 \pm 1.260	2.418 \pm 0.175
	Dorsoventral	-0.440 \pm 0.453	-0.414 \pm 0.850	-1.217 \pm 1.070
	Mediolateral	3.079 ^c \pm 1.862	0.417 ^d \pm 1.042	0.783 ^{c,d} \pm 2.309
Mouth opening	Rostrocaudal	12.410 \pm 7.743	10.834 \pm 6.950	14.872 \pm 3.173
	Dorsoventral	-3.375 \pm 1.960	-2.901 \pm 1.800	-3.465 \pm 2.346
	Mediolateral	-0.224 \pm 1.678	0.024 \pm 0.806	-0.606 \pm 1.476
	Held open rostrocaudal	0.772 \pm 0.783	0.377 \pm 0.202	0.477 \pm 0.115
	Held open dorsoventral	-0.142 \pm 0.136	-0.066 \pm 0.079	-0.020 \pm 0.054
	Held open mediolateral	0.011 \pm 0.117	0.003 \pm 0.034	-0.105 \pm 0.212

Within a row, means with different superscript letters (^c and ^d) differ significantly ($P < .05$).

BiTMJR = Bilateral TMJ replacement. UniTMJR = Unilateral TMJ replacement.

^aPositive values represent caudal, dorsal, and left lateral displacement of the mandible relative to the temporal bone. ^bN = 4 cat skulls.

Table 3—Mean (\pm SD) displacement of temporal^a and mandibular prosthetic component relative to the bone during bite simulations and mouth opening in cats ($n = 8$) and dogs ($n = 8$) skulls.

Group	Test	Left uniTMJR (mm)	BiTMJR ^b (mm)
Cat mandible	Left bite	-0.041 \pm 0.093	0.060 \pm 0.228
	Right bite	-0.020 \pm 0.050	0.036 \pm 0.082
	Mouth opening	0.053 \pm 0.057	0.141 \pm 0.247
Dog mandible	Left bite	-0.003 \pm 0.113	0.030 \pm 0.077
	Right bite	0.030 \pm 0.073	0.027 \pm 0.104
	Mouth opening	0.025 \pm 0.042	0.037 \pm 0.044
Dog zygomatic arch	Left bite	0.025 \pm 0.066	-0.014 \pm 0.043
	Right bite	0.025 \pm 0.071	-0.003 \pm 0.008
	Mouth opening	0.006 \pm 0.022	0.003 \pm 0.017

^aIn cats, displacement of the temporal prosthetic component could not be measured because the implant covered the zygomatic arch. ^bN = 4 cat skulls and 4 dog skulls.

Mean implant-bone motion during mouth opening ranged from 6 to 25 μ m after UniTMJR and 3 to 37 μ m after BiTMJR.

Discussion

This project was the first kinematic evaluation of a novel TMJR prosthesis intended for the management of several severe TMJ disorders in cats and dogs. The study included the implantation of 24 TMJR prostheses in cats and dogs. Subjectively, UniTMJR and BiTMJR implantation after condylectomy and coronoidectomy in cadavers was safe, rapid, and effective. In both the modeling simulations and the cadaver experiments, UniTMJR and BiTMJR resulted in the full ability to open and close the mouth with minimal laterotrusion. Mandibular motion in all planes after UniTMJR and BiTMJR did not differ from TMJ motion by > 3 mm. Therefore, the hypothesis that TMJR maintains motion in the TMJ was accepted. Joint motion after UniTMJR and BiTMJR was not demonstrably different from the stability of intact TMJ in most instances and was more stable than intact TMJ in a few instances. The increased stability of UniTMJR and BiTMJR relative to the native TMJ likely resulted from the increased constraint of the prosthetic head in the liner relative to the low constraint of the condylar process in the mandibular fossa. The motion

of the native TMJ in cats and dogs is mostly hinged, without rostrocaudal translation in the native cat TMJ and with minimal rostrocaudal translation in approximately half of dogs.^{6,35} Also, minimal laterotrusion is observed in the native TMJ of cats and dogs.²⁰ This means that the constraint of the TMJR implant should not interfere with normal TMJ function. The motion and stability of UniTMJR and BiTMJR did not differ, which suggests that BiTMJR may be a viable option to manage patients with severe bilateral TMJ disease. This is particularly relevant to cats, in which approximately half of cases with TMJ ankylosis are bilaterally affected.^{16,17} In human TMJR, translational motion, particularly during maximal mouth opening, is increased after TMJR, and lateral mandibular translation toward the operated side occurs during maximal mouth opening.^{3,36} Human TMJR implants and human native TMJ, however, have less constraint than the TMJR implant tested in the current study and less constraint than the native TMJ in cats and dogs.

During preliminary testing, liner dislodgement was observed during bite simulations and appeared to be caused by suboptimal liner constraint or by temporal component malpositioning. Liner dislodgement was successfully addressed by liner replacement or implant repositioning. No luxation occurred during testing. In human TMJR, luxation occurs primarily during the first postoperative week.³⁷ Human

TMJR implants have minimal constraint. Their stability is mostly influenced by muscular activity.³⁷ However, the removal of the condylar and coronoid processes disrupts the masseter, temporal, and pterygoid muscles.^{16,37} Since, in the current study, the coronoid and condylar processes were excised and muscles of mastication were removed, TMJ stability relied exclusively on the stability of the TMJR implant. The absence of luxation during bite and mouth opening simulations suggests that the implant would likely be stable in the early postoperative period.

In this study, the TMJR prosthesis was fitted and secured using 3 screws in the temporal component and 3 screws in the mandibular component. In a finite element study of human TMJR, the use of 3 staggered screws for fixation of the temporal and mandibular TMJR components provided optimal stability and only exhibited a minor increase in implant stability and a minor decrease in prosthetic component stress when additional screws were added.³⁸ The implant design allows for the placement of 1 additional screw in the zygomatic plate in the dog and 1 (cat) or 2 (dog) additional screws in the mandibular plate. These additional screws would likely be placed in clinical patients but were not deemed necessary to achieve stability in the current study. Locking screws were selected to affix the mandibular component to maximize the stiffness of fixation.³⁹ Nonlocking screws were selected to affix the temporal component to maintain the ability to angle the screws relative to the bone. The stability of the study implants was confirmed by the absence of failure of fixation during testing and by the small implant-bone motion under bite conditions ($\leq 60 \mu\text{m}$). The hypothesis that implants were stable under bite conditions was accepted. The bite conditions simulated in the study corresponded to a third of maximal bite forces. Little is known about chewing forces relative to maximal bite forces in cats and dogs. In humans, chewing produces a bite force of one-seventh of the maximal bite force;^{25,40} the forces used during the experiments potentially exceeded the postoperative *in vivo* forces. We would, therefore, anticipate that the TMJR components tested in the current study would be stable after surgery when implanted in cats and dogs with clinical problems.

The TMJR components were CNC machined in Ti6Al4V titanium alloy, with a metal-on-polyethylene articulation. This combination is the current standard for low-friction TMJ total joint arthroplasty.⁴¹ Titanium and cobalt-chromium alloys are the only metals approved by the FDA for the fabrication of TMJR in humans. Relative to cobalt-chromium, Ti6Al4V offers the advantages to be less stiff and more conveniently machined.⁴² Titanium alloy also has an excellent biocompatibility profile.⁴³

The screws used for fixation of the temporal and mandibular components had the same size. Cortical (nonlocking) screws were used for fixation of the temporal component because the alignment of the temporal component plate to the caudal portion of the zygomatic arch was less predictable and possibly required angling of the screw orientation. Screw

orientation has been shown to influence the stability of the temporal TMJR component more than the number of screws, primarily through optimization of bone surface strains.³⁸ Fixed-angle locking screws were used for fixation of the mandibular component because screws could be implanted perpendicular to the plate to maximize the strength of fixation. The 2.4-mm screws used for TMJR in dogs appeared appropriate to achieve component stability in the large-breed skulls used in the study. Screws were 1 size smaller in cats (2.0 mm) than dogs (2.4 mm). The choice of a screw size was guided by the intent to balance several factors: increasing screw strength to minimize the risk of screw breakage, increasing screw stiffness to minimize implant-bone motion, increasing thread depth to increase the strength of the screw-bone interface, avoiding an excessively large pilot hole to maintain the strength of the zygomatic arch and mandible, and keeping their thread pitch low to protect the strength of the screw-bone interface. The 2.0-mm locking screws used in cats and 2.4-mm locking screws used in dogs appear to balance these factors. The implant size used in the current study matches the sizes of implants used in biomechanical studies in cats^{39,44} and the size of implants used to treat maxillofacial and mandibular fracture in clinical patients.⁴⁵ A larger screw size may be required for giant-breed dogs. In humans, the fixation of TMJR components most often relies on 4 2.0-mm screws (range, 4 to 7 screws) for the glenoid fossa component (mandibular fossa in animals) and 8 2.7-mm screws (range, 5 to 12 screws) for the mandibular component.^{14,46} Micromotion under load of the temporal and mandibular components was small ($\leq 60 \mu\text{m}$ during bite simulations) and was comparable with the micromotion of acetabular or glenoid components used in human total joint replacement.^{47,48}

By bending the mandibular plate during surgery, the TMJR procedure also enabled the adjustment of occlusion to correct malocclusion. The ability to alter occlusion is beneficial considering that problems such as mandibular malunion and ankylosis alter occlusion. In human patients, TMJR has been shown to improve occlusion.^{49,50} TMJR has also been used to manage severe malocclusion.⁵¹

This study has several limitations. Tests of TMJR stability were conducted in cadavers, without muscular support. It is unclear how muscle function would influence the stability of TMJR implants. However, because muscles crossing the TMJ have a stabilizing influence on the joint, it is likely that the prosthesis would be as stable *in vivo* as it was during the experiments reported here, particularly several weeks after surgery, once muscle function returns to normal.⁵² Preventive occlusal guidance with orthodontic buttons and elastic chain may minimize the risk of luxation in the postoperative period in clinical patients.³⁷ The bite forces tested in the current study were lower than the maximal bite forces reported in cats and dogs.¹⁹ While this does require testing in the future, we do not expect a maximal bite force to be used following surgery as reported in people

following TMJR placement.⁵² Several polyethylene liners dislodged during preliminary mechanical tests. Liner constraint within the temporal TMJR component should be high and should be more consistent. This may be achieved during the fabrication of future TMJR components by slightly increasing the size of the liner and by having tighter fabrication tolerances on the liner and the temporal TMJR component. Also, several liners could be provided with the implant to allow liner exchanges during implantation. Finally, the design of the temporal component could be modified slightly to improve the snap fit of the liner while allowing forced dislodgement of the liner when needed. Only one TMJR implant size was available for the cats and the dogs, potentially having a negative impact on implant fit on bones with varying geometry. While this may be less of a concern for cat skulls than dog skulls, an evaluation of variation in skull geometry using statistical shape modeling or other methods is warranted before starting a clinical trial or before potential commercialization.⁵³ Additional implant sizes will be needed to adapt to a wider range of skull sizes and geometry. Developing a temporal TMJR component with higher inclination of the zygomatic arch plate may be beneficial for use in patients with high zygomatic arch inclination. Finite element analysis (FEA) models of the TMJR components or of a skull fitted with TMJR components were not developed. Implant design could be optimized using an FEA model of TMJR components. Similarly, implant fixation could be optimized using an FEA model of a skull fitted with TMJR components.^{3,54} The current study did not evaluate the long-term performance or failure strength of the implant, particularly regarding fatigue life (liner wear). Implant wear during cyclic loading and device strength is the focus of ongoing experiments. Human TMJR implants have shown excellent longevity.^{9,50}

Humans with severe TMJ disease have been managed with TMJR since 1987.^{49,55-57} Long-term studies have shown good TMJR function (increased mouth opening, improved chewing ability) and stability combined with decreased pain.^{49,55-57} We anticipate that cats and dogs can similarly benefit from TMJR. The study presented here is the first step toward TMJR in dogs and cats. Under *ex vivo* conditions, TMJR is feasible in dogs and cats and provides satisfactory function and mechanical stability. Current efforts are ongoing to evaluate implant wear properties and kinematics under cyclic loading before the initiation of clinical trials.

Acknowledgments

The TMJR prosthesis was invented by 3 of the authors (Boaz Arzi, Tanya Garcia, and Denis Marcellin-Little), US patent no. 63/414,297, filed October 7, 2023. The authors thank Dr. Chrisoula Toupadakis Skouritakis for the illustrations.

Disclosures

None reported. No AI-assisted technologies were used in the generation of this manuscript.

Funding

The study was supported by the Center for Companion Animal Health and the Maggie LS Faculty Research Companion Animal Fund, School of Veterinary Medicine, University of California-Davis.

References

1. Linsen SS, Schon A, Mercuri LG, Teschke M. Unilateral, alloplastic temporomandibular joint reconstruction, biomechanically what happens to the contralateral temporomandibular joint?-A prospective cohort study. *J Oral Maxillofac Surg.* 2021;79(10):2016-2029. doi:10.1016/j.joms.2021.01.025
2. Mercuri LG. Temporomandibular joint disorder management in oral and maxillofacial surgery. *J Oral Maxillofac Surg.* 2017;75(5):927-930. doi:10.1016/j.joms.2016.10.033
3. Pinheiro M, Willaert R, Khan A, Krairi A, Paepegem WV. Biomechanical evaluation of the human mandible after temporomandibular joint replacement under different biting conditions. *Sci Rep.* 2021;11(1):14034.
4. Zhang L, Qin H, Abdelrehem A, He D. Biomechanical evaluation of A standard temporomandibular joint prosthesis and screw arrangement optimization: a finite element analysis. *J Craniofac Surg.* 2023;34(6):1888-1894. doi:10.1097/SCS.00000000000009471
5. Wang J, Hua J, Ding R, et al. Comparative study of normal condyle and temporomandibular joint prosthesis movement during mouth opening by dynamic magnetic resonance imaging and computed tomography. *Quant Imaging Med Surg.* 2023;13(7):4147-4159. doi:10.21037/qims-22-1239
6. Arzi B, Lantz GC. Fractures and luxations involving the temporomandibular joint. In: Verstraete FJM, Lommer MJ, Arzi B, eds. *Oral and Maxillofacial Surgery in Dogs and Cats.* 2nd ed. Elsevier, 2020;368-376.
7. Tamimi DF, Tamimi D, Hatcher DC. *Specialty Imaging: Temporomandibular Joint.* Elsevier; 2016.
8. Tanaka E, Detamore MS, Mercuri LG. Degenerative disorders of the temporomandibular joint: etiology, diagnosis, and treatment. *J Dent Res.* 2008;87(4):296-307. doi:10.1177/154405910808700406
9. Leandro LF, Ono HY, Loureiro CC, Marinho K, Guevara HAG. A ten-year experience and follow-up of three hundred patients fitted with the Biomet/Lorenz Microfixation TMJ replacement system. *Int J Oral Maxillofac Surg.* 2013;42(8):1007-1013. doi:10.1016/j.ijom.2013.04.018
10. Mercuri LG, Neto MQ, Pourzal R. Alloplastic temporomandibular joint replacement: present status and future perspectives of the elements of embodiment. *Int J Oral Maxillofac Surg.* 2022;51(12):1573-1578. doi:10.1016/j.ijom.2022.05.015
11. Mercuri LG, Wolford LM, Sanders B, White RD, Giobbie-Hurder A. Long-term follow-up of the CAD/CAM patient fitted total temporomandibular joint reconstruction system. *J Oral Maxillofac Surg.* 2002;60(12):1440-1448. doi:10.1053/joms.2002.36103
12. Balel Y, Tumer MK. A bibliometric analysis of international publication trends in total temporomandibular joint replacement research (1986-2020). *J Oral Maxillofac Surg.* 2021;79(7):1458.e1-1458.e12.
13. Elledge R, Mercuri LG, Attard A, Green J, Speculand B. Review of emerging temporomandibular joint total joint replacement systems. *Br J Oral Maxillofac Surg.* 2019;57(8):722-728. doi:10.1016/j.bjoms.2019.08.009
14. Yadav P, Roychoudhury A, Kumar RD, Bhutia O, Bhutia T, Aggarwal B. Total alloplastic temporomandibular joint replacement. *J Maxillofac Oral Surg.* 2021;20(4):515-526. doi:10.1007/s12663-021-01628-8

15. Strom PC, Arzi B, Cissell DD, Verstraete FJM. Ankylosis and pseudoankylosis of the temporomandibular joint in 10 dogs (1993-2015). *Vet Comp Orthop Traumatol*. 2016;29(5):409-415. doi:10.3415/VCOT-15-11-0189
16. Aghashani A, Verstraete FJM, Arzi B. Temporomandibular joint gap arthroplasty in cats. *Front Vet Sci*. 2020;7:482. doi:10.3389/fvets.2020.00482
17. Zavodovskaya R, Vapniarsky N, Garcia T, Verstraete FJM, Hatcher DC, Arzi B. Intra- and extra-articular features of temporomandibular joint ankylosis in the cat (*Felis catus*). *J Comp Pathol*. 2020;175:39-48. doi:10.1016/j.jcpa.2019.12.006
18. Villamizar-Martinez LA, Ferro DG, Carvalho VG, Ferreira J, Reiter AM. Caudal and middle segmental mandibulectomies for the treatment of unilateral temporomandibular joint ankylosis in cats. *JFMS Open Rep*. 2022;8(1):20551169221086438. doi:10.1177/20551169221086438
19. Kim SE, Arzi B, Garcia TC, Verstraete FJM. Bite forces and their measurement in dogs and cats. *Front Vet Sci*. 2018;5:76. doi:10.3389/fvets.2018.00076
20. Arzi B, Verstraete FJM, Garcia TC, Lee M, Kim SE, Stover SM. Kinematic analysis of mandibular motion before and after mandibulectomy and mandibular reconstruction in dogs. *Am J Vet Res*. 2019;80(7):637-645. doi:10.2460/ajvr.80.7.637
21. Brassard C, Merlin M, Guintard C, et al. Bite force and its relationship to jaw shape in domestic dogs. *J Exp Biol*. 2020;223(Pt 16):jeb224352.
22. Hartstone-Rose A, Perry JM, Morrow CJ. Bite force estimation and the fiber architecture of felid masticatory muscles. *Anat Rec (Hoboken)*. 2012;295(8):1336-1351. doi:10.1002/ar.22518
23. Penrose F, Cox P, Kemp G, Jeffery N. Functional morphology of the jaw adductor muscles in the Canidae. *Anat Rec (Hoboken)*. 2020;303(11):2878-2903. doi:10.1002/ar.24391
24. Ellis JL, Thomason JJ, Kebreab E, France J. Calibration of estimated biting forces in domestic canids: comparison of post-mortem and in vivo measurements. *J Anat*. 2008;212(6):769-780. doi:10.1111/j.1469-7580.2008.00911.x
25. Shala K, Tmava-Dragusha A, Dula L, et al. Evaluation of maximum bite force in patients with complete dentures. *Open Access Maced J Med Sci*. 2018;6(3):559-563. doi:10.3889/oamjms.2018.141
26. Apostolov NCI, Drajev T. Measurement of the maximum bite force in the natural dentition with a gnathodynamometer. *J Med Dent Pract*. 2014;1(2):70-75. doi:10.18044/MedInform.201412.70
27. Ellis JL, Thomason J, Kebreab E, Zubair K, France J. Cranial dimensions and forces of biting in the domestic dog. *J Anat*. 2009;214(3):362-373. doi:10.1111/j.1469-7580.2008.01042.x
28. Fleming PA, Crawford HM, Auckland CH, Calver MC. Body size and bite force of stray and feral cats-Are bigger or older cats taking the largest or more difficult-to-handle prey? *Animals (Basel)* 2020;10(4):707. doi:10.3390/ani10040707
29. Merg FR. *The Influence of Force Application to the Teeth upon Tension Development of the Masseter and Digastric Muscles of the Cat*. Loyola University Chicago; 1967.
30. Gracis M, Zini E. Vertical mandibular range of motion in anesthetized dogs and cats. *Front Vet Sci*. 2016;3:51. doi:10.3389/fvets.2016.00051
31. Renner EK, Thatcher G, Hetzel S, Snyder CJ. Temporomandibular joint gape angles in normal and painful domestic felines. *J Vet Dent*. 2024;41(2):129-136. doi:10.1177/08987564231157591
32. Thomson A, Hetzel S, Snyder CJ. Gape angle in asymptomatic dogs with normal occlusion. *J Vet Dent*. 2021;38(1):24-29. doi:10.1177/08987564211012487
33. Arzi B, Verstraete FJ. Internal fixation of severe maxillofacial fractures in dogs. *Vet Surg*. 2015;44(4):437-442. doi:10.1111/j.1532-950X.2014.12161.x
34. Arzi B. AO Surgery Reference: Dog midface and mandible [Online Surgery Reference]. 2015. Accessed April 2, 2024. <https://surgeryreference.aofoundation.org/vet/dog>
35. Lin AW, Vapniarsky N, Cissell DD, et al. The temporomandibular joint of the domestic dog (*Canis lupus familiaris*) in health and disease. *J Comp Pathol*. 2018;161:55-67. doi:10.1016/j.jcpa.2018.05.001
36. Leiggenger CS, Erni S, Gallo LM. Novel approach to the study of jaw kinematics in an alloplastic TMJ reconstruction. *Int J Oral Maxillofac Surg*. 2012;41(9):1041-1045. doi:10.1016/j.ijom.2012.06.014
37. Mustafa el M, Sidebottom A. Risk factors for intraoperative dislocation of the total temporomandibular joint replacement and its management. *Br J Oral Maxillofac Surg*. 2014;52(2):190-192. doi:10.1016/j.bjoms.2013.09.018
38. Hsu JT, Huang HL, Tsai MT, Fuh LJ, Tu MG. Effect of screw fixation on temporomandibular joint condylar prosthesis. *J Oral Maxillofac Surg*. 2011;69(5):1320-1328. doi:10.1016/j.joms.2010.05.074
39. Greiner CL, Verstraete FJM, Stover SM, Garcia TC, Leale D, Arzi B. Biomechanical evaluation of two plating configurations for fixation of a simple transverse caudal mandibular fracture model in cats. *Am J Vet Res*. 2017;78(6):702-711. doi:10.2460/ajvr.78.6.702
40. Tabrizi R, Langner NJ, Zamiri B, Aliabadi E, Daneste H, Naghizade S. Comparison of nonsurgical treatment options in pediatric condylar fractures: rigid intermaxillary fixation versus using guiding elastic therapy. *J Craniofac Surg*. 2013;24(3):e203-e206. doi:10.1097/SCS.0b013e318293d605
41. Neto MQ, Radice S, Hall DJ, Matthew MT, Mercuri LG, Pourzal R. Alloys used in different temporomandibular joint reconstruction replacement prostheses exhibit variable microstructures and electrochemical properties. *J Oral Maxillofac Surg*. 2022;80:798-813. doi:10.1016/j.joms.2021.12.016
42. Davis R, Singh A, Jackson MJ, et al. A comprehensive review on metallic implant biomaterials and their subtractive manufacturing. *Int J Adv Manuf Technol*. 2022;120(3-4):1473-1530. doi:10.1007/s00170-022-08770-8
43. Lemons JE. Biomaterials and orthopaedic considerations for endoprostheses. *Oral Maxillofacial Surg Clin N Am*. 2000;12(1):43-56. doi:10.1016/S1042-3699(20)30230-2
44. Kot CCS, Verstraete FJM, Garcia TC, Stover SM, Arzi B. Biomechanical evaluation of locking versus nonlocking 2.0-mm malleable L-miniplate fixation of simulated caudal mandibular fractures in cats. *Am J Vet Res*. 2022;83(8):ajvr.22.03.0043. doi:10.2460/ajvr.22.03.0043
45. Evenhuis JV, Verstraete FJM, Arzi B. Management of failed stainless steel implants in the oromaxillofacial region of dogs. *Front Vet Sci*. 2022;9:992730. doi:10.3389/fvets.2022.992730
46. Yoda T, Ogi N, Yoshitake H, et al. Clinical guidelines for total temporomandibular joint replacement. *Jpn Dent Sci Rev*. 2020;56(1):77-83. doi:10.1016/j.jdsr.2020.03.001
47. Goossens Q, Pastrav LC, Mulier M, Desmet W, Sloten JV, Denis K. Two different methods to measure the stability of acetabular implants: a comparison using artificial acetabular models. *Sensors (Basel)* 2020;20(1):254. doi:10.3390/s20010254
48. Formaini NT, Everding NG, Levy JC, Santoni BG, Nayak AN, Wilson C. Glenoid baseplate fixation using hybrid configurations of locked and unlocked peripheral screws. *J Orthop Traumatol*. 2017;18(3):221-228. doi:10.1007/s10195-016-0438-3
49. Wolford LM, Mercuri LG, Schneiderman ED, Movahed R, Allen W. Twenty-year follow-up study on a patient-fitted temporomandibular joint prosthesis: the Techmedica/TMJ Concepts device. *J Oral Maxillofac Surg*. 2015;73(5):952-960. doi:10.1016/j.joms.2014.10.032

50. Gerbino G, Zavatiero E, Bosco G, Berrone S, Ramieri G. Temporomandibular joint reconstruction with stock and custom-made devices: indications and results of a 14-year experience. *J Craniomaxillofac Surg.* 2017;45(10):1710-1715. doi:10.1016/j.jcms.2017.07.011
51. Webster K, McIntyre G, Laverick S, McLoughlin P, Tothill C. Treatment of a class 2 skeletal malocclusion with degenerative arthritis of the condyles using custom-made temporomandibular joint replacements and genioplasty. *J Orthod.* 2017;44(1):55-58. doi:10.1080/14653125.2016.1275441
52. Speksnijder CM, Mutsaers NEA, Walji S. Functioning of the masticatory system in patients with an alloplastic total temporomandibular joint prostheses compared with healthy individuals: a pilot study. *Life (Basel).* 2022;12(12):2073. doi:10.3390/life12122073
53. Schoenebeck JJ, Ostrander EA. The genetics of canine skull shape variation. *Genetics.* 2013;193(2):317-325. doi:10.1534/genetics.112.145284
54. Ingawale SM, Goswami T. Design and finite element analysis of patient-specific total temporomandibular joint implants. *Materials (Basel).* 2022;15(12):4342. doi:10.3390/ma15124342
55. Idle MR, Lowe D, Rogers SN, Sidebottom AJ, Speculand B, Worrall SF. UK temporomandibular joint replacement database: report on baseline data. *Br J Oral Maxillofac Surg* 2014;52(3):203-207. doi:10.1016/j.bjoms.2013.12.004
56. Rikhotso RE, Sekhoto MG. Alloplastic total temporomandibular joint reconstruction: a 10-Year experience of the University of the Witwatersrand, Johannesburg. *J Craniofac Surg.* 2021;32(5):1658-1663. doi:10.1097/SCS.00000000000007227
57. Speculand B. Current status of replacement of the temporomandibular joint in the United Kingdom. *Br J Oral Maxillofac Surg.* 2009;47(1):37-41. doi:10.1016/j.bjoms.2008.05.012

Supplementary Materials

Supplementary materials are posted online at the journal website: avmajournals.avma.org