

UCSF

UC San Francisco Previously Published Works

Title

Intact speech perception after resection of dominant hemisphere primary auditory cortex for the treatment of medically refractory epilepsy: illustrative case.

Permalink

<https://escholarship.org/uc/item/4c90t0kr>

Journal

Journal of neurosurgery. Case lessons, 4(22)

ISSN

2694-1902

Authors

Hullett, Patrick W
Kandahari, Nazineen
Shih, Tina T
[et al.](#)

Publication Date

2022-11-01

DOI

10.3171/case22417

Peer reviewed

Intact speech perception after resection of dominant hemisphere primary auditory cortex for the treatment of medically refractory epilepsy: illustrative case

*Patrick W. Hullett, MD, PhD,² Nazineen Kandahari, MS,^{1,2} Tina T. Shih, MD,² Jonathan K. Kleen, MD, PhD,² Robert C. Knowlton, MD, MSPH,² Vikram R. Rao, MD, PhD,² and Edward F. Chang, MD¹

¹Department of Neurosurgery, University of California San Francisco, San Francisco, California; and ²Department of Neurology, Weill Institute for Neurosciences, University of California San Francisco, San Francisco, California

BACKGROUND In classic speech network models, the primary auditory cortex is the source of auditory input to Wernicke's area in the posterior superior temporal gyrus (pSTG). Because resection of the primary auditory cortex in the dominant hemisphere removes inputs to the pSTG, there is a risk of speech impairment. However, recent research has shown the existence of other, nonprimary auditory cortex inputs to the pSTG, potentially reducing the risk of primary auditory cortex resection in the dominant hemisphere.

OBSERVATIONS Here, the authors present a clinical case of a woman with severe medically refractory epilepsy with a lesional epileptic focus in the left (dominant) Heschl's gyrus. Analysis of neural responses to speech stimuli was consistent with primary auditory cortex localization to Heschl's gyrus. Although the primary auditory cortex was within the proposed resection margins, she underwent lesionectomy with total resection of Heschl's gyrus. Postoperatively, she had no speech deficits and her seizures were fully controlled.

LESSONS While resection of the dominant hemisphere Heschl's gyrus/primary auditory cortex warrants caution, this case illustrates the ability to resect the primary auditory cortex without speech impairment and supports recent models of multiple parallel inputs to the pSTG.

<https://thejns.org/doi/abs/10.3171/CASE22417>

KEYWORDS Heschl's gyrus; transverse temporal gyrus; epilepsy surgery; primary auditory cortex; resection; superior temporal gyrus

Wernicke's area, located in the posterior segment of the superior temporal gyrus (pSTG), is a core brain region necessary for speech perception. Because the term pSTG is more anatomically specific, this notation will be used. Lesions to the pSTG within the dominant hemisphere cause a Wernicke's aphasia with a complete lack of speech comprehension (word deafness) and fluent errors in speech production (phonemic paraphasias and neologistic jargon).^{1,2} Recently, many neural mechanisms that underlie speech comprehension in the pSTG have been discovered, including speaker normalization, categorical perception, pitch and prosody representation, acoustic-phonetic encoding, modulotopic processing, and high-level linguistic representation.³⁻⁷ Because the pSTG is necessary

for speech perception, this region is considered eloquent cortex and is avoided during surgical resection.

Current speech network models postulate that the dominant inputs to the pSTG arise from the primary auditory cortex along Heschl's gyrus (Fig. 1A).⁸ The primary auditory cortex is the main cortical area that receives auditory input from subcortical structures. In classical models, the primary auditory cortex encodes sound in Heschl's gyrus before it reaches the pSTG. Because of this hierarchical architecture, neurosurgeons avoid resecting the primary auditory cortex in the dominant hemisphere due to the perceived risk of speech deficits from removing primary inputs to the pSTG.⁸ However, this perceived risk may be overestimated. In support of this,

ABBREVIATIONS EEG = electroencephalography; MRI = magnetic resonance imaging; *MYBL1* = myeloblastosis viral oncogene homolog-like 1; pSTG = posterior segment of the superior temporal gyrus; SOZ = seizure-onset zone; STRF = spectrotemporal receptive field; TIRDA = temporal intermittent rhythmic delta activity; TOX = thymocyte selection-associated high mobility group box protein.

INCLUDE WHEN CITING Published November 28, 2022; DOI: 10.3171/CASE22417.

SUBMITTED September 26, 2022. **ACCEPTED** October 27, 2022.

* P.W.H. and N.K. contributed equally to this work.

© 2022 The authors, CC BY-NC-ND 4.0 (<http://creativecommons.org/licenses/by-nc-nd/4.0/>).

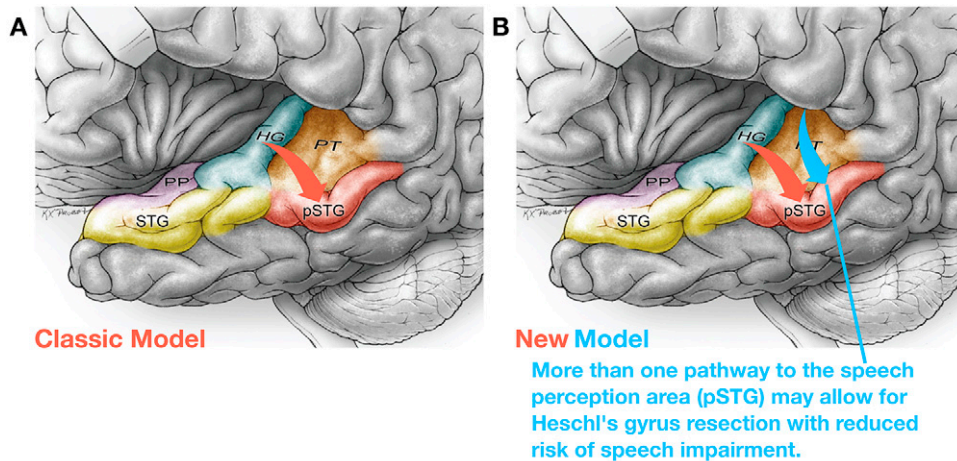


FIG. 1. New speech network model shows parallel inputs to Wernicke's area (pSTG). **A:** Classic models postulate the dominant inputs to pSTG are from Heschl's gyrus (red arrow). **B:** New speech network models show posterior superior temporal gyrus receives parallel input from other sources, potentially lowering the risk of aphasia from resection of the primary auditory cortex (blue arrow). HG = Heschl's gyrus; PP = planum polare; PT = planum temporale; STG = superior temporal gyrus.

recent work has shown other parallel input sources to the pSTG⁹ (Fig. 1B), thus potentially lowering the risk of primary auditory cortex resection due to inputs from nonprimary auditory cortex areas.

Here, we report a case of a patient with severe medically refractory epilepsy with a seizure focus located on Heschl's gyrus within the dominant hemisphere. Analysis of speech-driven neural responses in this area was consistent with primary auditory cortex localization to Heschl's gyrus. Given new data showing parallel inputs to the pSTG⁹ and reassuring stimulation-based language mapping, the estimated benefit outweighed the risk in this patient and she underwent complete resection of Heschl's gyrus in the dominant hemisphere without secondary speech impairment. We present the clinical reasoning, workup, and outcome here.

Illustrative Case

Presentation and Workup

A 30-year-old, right-handed, Dari-speaking woman presented for evaluation of medically refractory focal epilepsy. The history was obtained in partnership with a certified medical interpreter and a medical student who immigrated from Afghanistan, spoke Dari natively, and was certified to interpret. The patient had onset of seizures at 13 years old, and, despite numerous antiseizure medication trials, her seizure frequency increased slowly over time to 3 focal seizures per day and weekly convulsions. She had no epilepsy risk factors and could not work given her seizure burden. She was married and the mother of 3 children. Over the years, in the course of normal daily activities, she sustained several seizure-related injuries, including lower extremity fractures, tongue lacerations, and burn injuries.

Her seizure semiology consisted of a sudden loss of hearing with receptive and expressive aphasia, retained awareness (on most seizures), and bimanual automatisms. Once per week, her seizures secondarily generalized. In-between seizures, she had a continuous mild-to-moderate receptive aphasia in which she relied on lip-reading and slow-talking to communicate. This aphasia would acutely worsen in the postictal period, for 1–2 hours, with complete word deafness

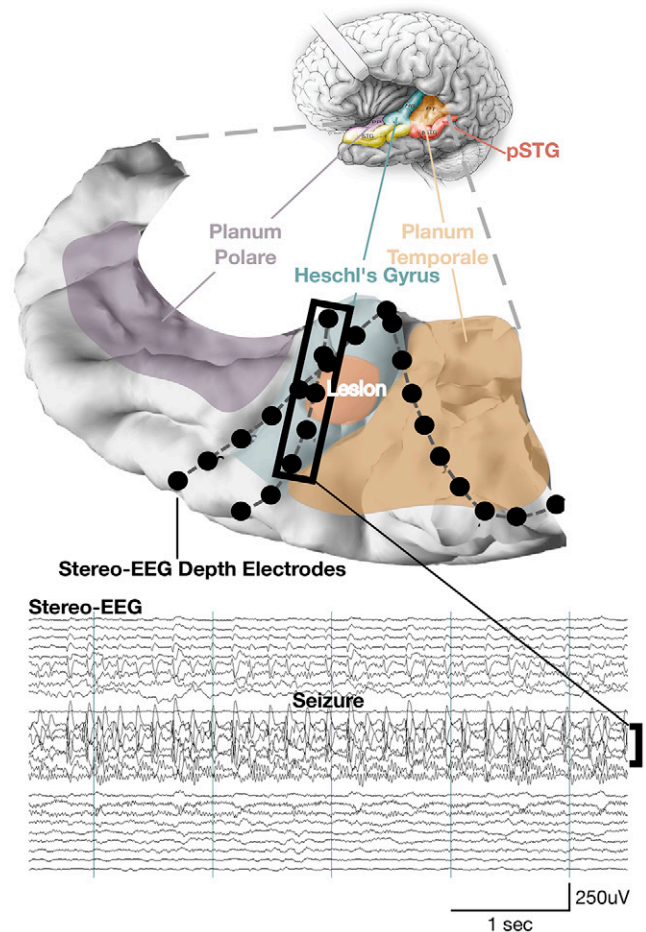


FIG. 2. Superior temporal plane reconstruction of the suspected seizure focus with stereo-EEG depth electrodes. A segment of a single seizure is shown with ictal activity confined to the left Heschl's gyrus. Lateral temporal and frontoparietal grids are not shown but were implanted for comprehensive language mapping and seizure localization.

but a preserved ability to hear environmental sounds, such as running water and cars.

After establishing epilepsy care at our center, the patient was admitted for scalp video-electroencephalography (EEG) monitoring. Video-EEG showed rare left temporal intermittent rhythmic delta activity¹⁰ (TIRDA) and 1 typical seizure with no clear electrographic correlate. Given the presence of left-sided TIRDA and seizures consisting of aphasia with no ictal correlate on EEG, a left intrasylvian focus was the leading hypothesis for seizure localization. Brain magnetic resonance imaging (MRI) showed a nonenhancing T2-hyperintense lesion in the left Heschl's gyrus (low-grade glioma versus focal cortical dysplasia), consistent with this localization hypothesis. Magnetoencephalography showed no epileptiform activity. Neuropsychological evaluation was notable for intact verbal and visual memory but poor verbal fluency, consistent with a speech network focus that spares mesial temporal structures.

The patient underwent phase 2 intracranial electrode implantation to delineate the seizure-onset zone (SOZ) and its spatial relationship within the speech network. Electrode coverage included stereotactic-EEG leads along the superior temporal plane around the lesion and a 256-channel subdural grid on the lateral perisylvian cortex (Fig. 2). The grid was placed to determine the extent of seizure involvement of lateral cortex speech areas. Interictal recordings showed abundant spike-wave discharges arising from Heschl's gyrus with propagation to the superior temporal gyrus. Multiple typical seizures were captured, and recordings revealed a single SOZ within the left Heschl's gyrus around the MRI-defined lesion. While most seizures propagated to the lateral superior temporal gyrus, all ictal onsets were within Heschl's gyrus.

Although the SOZ was located on Heschl's gyrus, the primary auditory cortex does not always localize to this area. The primary

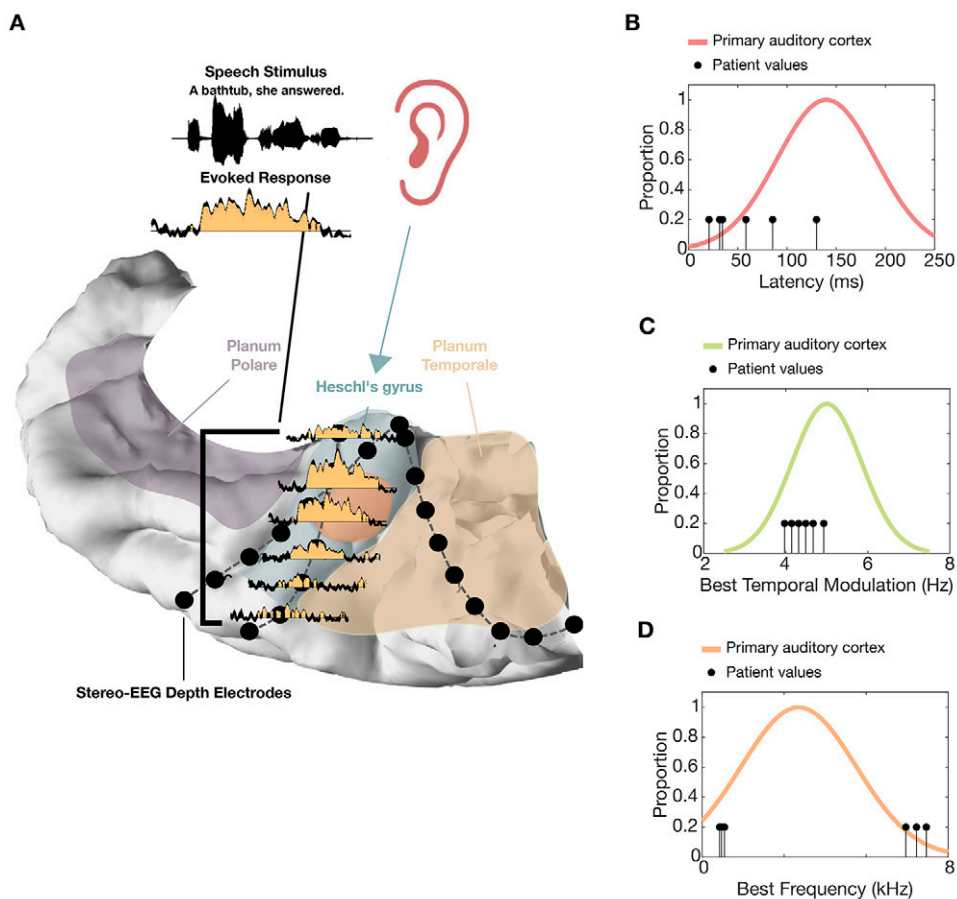


FIG. 3. Several analyses are consistent with the primary auditory cortex being localized to Heschl's gyrus in this patient. **A:** Stereo-EEG recordings taken while the patient listened to prerecorded sentences show neural responses localized to Heschl's gyrus (the yellow shaded portion represents a significant neural response to a single sentence repeated 10 times; $p < 0.05$ at each 10-msec bin; 2-sided Wilcoxon rank-sum test; neural responses based on high gamma activity in the neural recordings²⁵). The time-locked responses for the sentence's duration are consistent with the primary auditory cortex. **B:** Speech processing along Heschl's gyrus matches known processing for the primary auditory cortex. The response latency value for each electrode within Heschl's gyrus is within the range of response latencies observed in primary auditory cortex^{15,16} (latencies computed from the peak of the spectrotemporal receptive field calculated for each electrode). **C:** The best temporal modulation value for each electrode is within the range of best temporal modulation tuning observed in the human primary auditory cortex (best temporal modulation values derived from the modulation transfer function of the spectrotemporal receptive field at each site^{14,15}). **D:** The best frequency for each electrode (i.e., the frequency that evokes the largest response) is within the range of best frequencies observed for the human primary auditory cortex¹⁵ (best frequency obtained from each speech-derived STRF¹⁴).

auditory cortex can have alternative localizations due to normal variation in functional anatomy or, more commonly, from remapping of functional areas to other cortical regions in the setting of underlying epilepsy or tumors.^{11–13} To determine if the primary auditory cortex was within Heschl's gyrus, post hoc analysis was performed. Consistent with primary auditory cortex physiology, a single sentence of speech elicited high-amplitude neural responses along Heschl's gyrus that are time-locked to the stimulus and occur for the entire duration of the sentence (Fig. 3A). To further determine if these speech-evoked responses were consistent with the primary auditory cortex, each electrode's spectrotemporal receptive field (STRF) was computed to estimate the auditory processing at each site.¹⁴ From this, auditory processing parameters were derived and compared with known parameters for the primary auditory cortex.^{15,16} The best frequency, response onset latency, and best temporal modulation estimates from the patient-derived STRFs matched the distributions of these parameters seen in the primary auditory cortex (Fig. 3B). Thus, neurophysiology was consistent with primary auditory cortex localization to Heschl's gyrus despite the presence of the SOZ and a lesion in this area.

Language mapping was performed to assess the risk of primary auditory cortex resection (Fig. 4). Bedside cortical stimulation mapping during repetition and comprehension tasks revealed no sites exhibiting clear speech perception or production deficits on medial or core Heschl's gyrus. Some sites caused impaired repetition due to perception deficits on the most lateral aspect of Heschl's gyrus but were felt unlikely to cause persistent functional deficits if removed due to mild or unreliable perceptual effects

with stimulation. Additional lateral temporal cortex mapping using the 256-channel grid confirmed the presence of Wernicke's area on the left pSTG.

Operation and Postoperative Course

Given new speech models suggesting multiple parallel inputs to Wernicke's area and the reassuring stimulation mapping, the patient underwent lesionectomy with resection of Heschl's gyrus/primary auditory cortex (Fig. 5). The patient was counseled on the risk of speech perception or production deficits. Overall, the multidisciplinary epilepsy team and the patient felt the potential benefits of seizure reduction outweighed the risks of language deficits, and she underwent lesionectomy. Intraoperatively, the tumor was approached through microdissection of the sylvian fissure. Ultrasound was used to visualize the depth of the lesion and surrounding vasculature. The stereo-EEG electrodes were left in place during resection and served as key landmarks for defining the margins of the tumor and SOZ. The tumor was firm and gliotic and was resected until normal tissue margins were obtained. After resection, intraoperative electrocorticography showed no residual interictal spiking within the superior temporal plane or on the lateral superior temporal gyrus.

The patient demonstrated no speech deficits in the immediate postoperative period, including no transient deficits upon awakening from anesthesia. In fact, her mild-to-moderate receptive aphasia resolved, and she had no further need for slow-talking or lip-reading. The patient spontaneously endorsed, "My hearing is clear now. It's much better, like it's born again." On detailed neurological examination before discharge, she could follow 3-step complex commands at normal speech production speeds while the examiner wore a mask to prevent lip-reading. Her naming was intact to high- and low-frequency objects, her repetition was intact, and she had normal articulation without any perceptible dysarthria. Her only deficit on examination was a 50% reduction in volume in the right ear to near-threshold sounds, but normal-volume sounds were equal bilaterally.

Pathology showed a moderately cellular glial neoplasm composed of a heterogeneous population of tumor cells in a fibrillar background. In addition, tumor sequencing was notable for a large inversion on chromosome 8 that brings together the genes myeloblastosis viral oncogene homolog-like 1 (*MYBL1*) and thymocyte selection-associated high mobility group box protein (*TOX*). Collectively, the histopathologic and molecular features support an integrated diffuse astrocytoma, *MYBL1*-altered, World Health Organization grade 1, a newly recognized entity that is considered a benign pediatric-type diffuse glioma even when presenting in adult patients. She is now undergoing routine monitoring for tumor recurrence and has been seizure-free since the procedure (9 months).

Discussion

Observations

Because the primary auditory cortex is typically located along Heschl's gyrus, resection of Heschl's gyrus in the dominant hemisphere is avoided to minimize the risk of speech impairment. However, recent work has shown that the primary auditory cortex in the dominant hemisphere may not be necessary for intact speech perception—potentially due to parallel inputs to the pSTG.⁹ This is an illustrative patient case that shows an example of dominant hemisphere Heschl's gyrus resection without speech impairment.

This illustrative case adds to the sparse literature on dominant Heschl's gyrus resection in 2 important respects.^{17,18} First, the

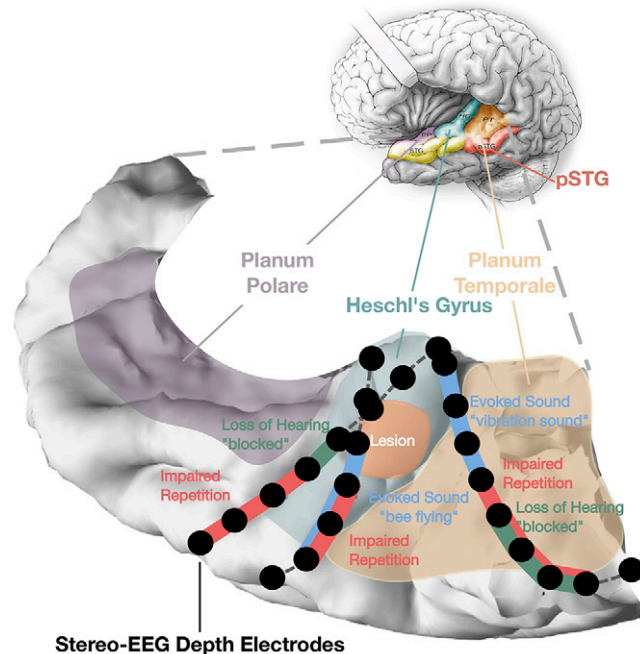


FIG. 4. Functional stimulation mapping shows sites within Heschl's gyrus are not necessary for speech perception or production. The patient was able to perform a 4-syllable word-repetition task with continuous electrical stimulation along the medial and core Heschl's gyrus during the perception and production phase of the task. All electrode pairs within the superior temporal plane were stimulated, with positive effects noted by color.

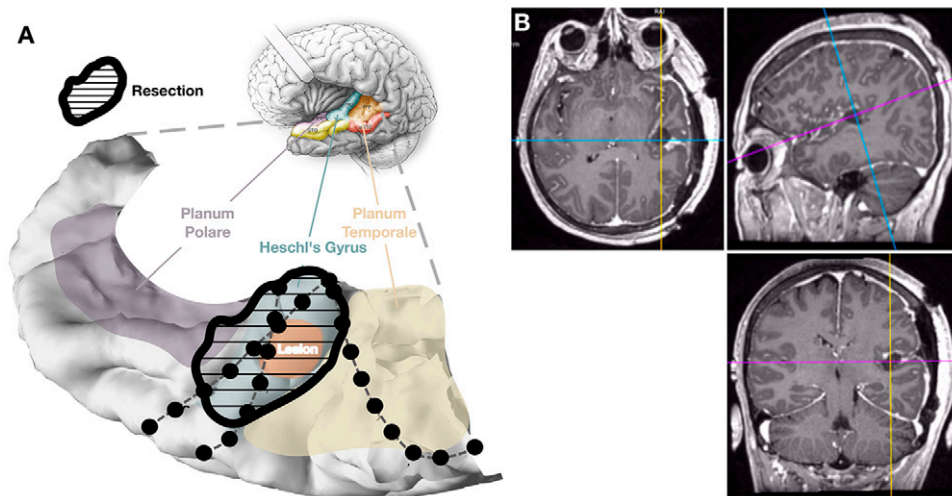


FIG. 5. Postoperative MR image and temporal plane reconstruction showing the resection margins with full removal of the lesion and Heschl's gyrus. **A:** Reconstruction of the superior temporal plane with the true resection margins. **B:** Postoperative T1-weighted axial, sagittal, and coronal MR images showing the resection cavity. MR = magnetic resonance.

primary auditory cortex does not always localize to Heschl's gyrus, particularly in patients with epilepsy where the underlying pathology can lead to the remapping of this functional area to alternative locations. This is the first case report to show data consistent with primary auditory cortex localization to Heschl's gyrus and subsequent resection, thus adding data to support the ability to resect the dominant hemisphere primary auditory cortex without speech impairment. Second, in prior case reports,^{17,18} only partial dominant hemisphere Heschl's gyrus resections were performed or, in 2 cases, the extent of resection was not specified. In this report, the entirety of Heschl's gyrus was resected. Although this is a single case, it demonstrates complete resection of Heschl's gyrus with no resulting speech deficits.

One positive but unexpected outcome of the case was the resolution of the patient's continuous mild-to-moderate receptive aphasia. We postulate 2 mechanisms for this. First, it is known that interictal epileptiform discharges can lead to transient functional deficits.^{19,20} In this patient, abundant interictal epileptiform discharges in the primary auditory cortex propagated to the lateral temporal cortex, including the pSTG. Postresection electrocorticography was performed and showed cessation of all interictal spiking. The immediate resolution of her aphasia postoperatively was consistent with interictal epileptiform discharges contributing to her aphasia. Second, the significant worsening of her aphasia to near-complete word deafness after seizures is consistent with a postictal functional deficit in speech cortex—akin to the mechanism of postictal Todd's paralysis.^{21,22} With complete control of her multiple daily seizures, this mechanism of speech impairment is also no longer contributing.

Lessons

Overall, this case highlights a prominent issue in epilepsy surgery. A core tenet of medicine is to do no harm. As such, even small degrees of uncertainty about the procedure risk are highly influential in deciding against surgical intervention. Because of this,

there are areas within the speech network where resections are underperformed due to risk uncertainty or overestimated perceived risk. As more knowledge is gained through basic and clinical research, more accurate risk assessments will be possible, and potentially more resective procedures will be performed. In support of this, Broca's area resection is now a more common procedure in our center due to research showing that the speech-production functions typically associated with Broca's area do not localize to this region.^{23,24} While resection of Broca's area does not come without risk, these new data lower the risk estimate, thus allowing for resections in more cases where the benefit outweighs that risk. The case presented here is an illustrative case of dominant primary auditory cortex resection due to a more informed risk assessment from new knowledge of the speech network.⁹ Ongoing research on the structural and functional architecture of the speech network will continue to allow for more-accurate risk assessments and increase the frequency of resections in or near the speech network.

Acknowledgments

We thank the EEG technologists at the University of California, San Francisco, for their help in acquiring electrophysiological data.

References

1. Kertesz A. *Aphasia and Associated Disorders: Taxonomy, Localization and Recovery*. Grune & Stratton; 1979.
2. Spreen O, Risser AH. *Assessment of Aphasia*. Oxford University Press; 2003.
3. Chang EF, Rieger JW, Johnson K, Berger MS, Barbaro NM, Knight RT. Categorical speech representation in human superior temporal gyrus. *Nat Neurosci*. 2010;13(11):1428–1432.
4. Fox NP, Leonard M, Sjerps MJ, Chang EF. Transformation of a temporal speech cue to a spatial neural code in human auditory cortex. *eLife*. 2020;9:e53051.

5. Sjerps MJ, Fox NP, Johnson K, Chang EF. Speaker-normalized sound representations in the human auditory cortex. *Nat Commun*. 2019;10(1):2465.
6. Tang C, Hamilton LS, Chang EF. Intonational speech prosody encoding in the human auditory cortex. *Science*. 2017;357(6353):797–801.
7. Li Y, Tang C, Lu J, Wu J, Chang EF. Human cortical encoding of pitch in tonal and non-tonal languages. *Nat Commun*. 2021;12(1):1161.
8. Jasmin K, Lima CF, Scott SK. Understanding rostral-caudal auditory cortex contributions to auditory perception. *Nat Rev Neurosci*. 2019;20(7):425–434.
9. Hamilton LS, Oganian Y, Hall J, Chang EF. Parallel and distributed encoding of speech across human auditory cortex. *Cell*. 2021;184(18):4626–4639.e13.
10. Reiher J, Beaudry M, Leduc CP. Temporal intermittent rhythmic delta activity (TIRDA) in the diagnosis of complex partial epilepsy: sensitivity, specificity and predictive value. *Can J Neurol Sci*. 1989;16(4):398–401.
11. Hamberger MJ, Cole J. Language organization and reorganization in epilepsy. *Neuropsychol Rev*. 2011;21(3):240–251.
12. Fisicaro RA, Jost E, Shaw K, Brennan NP, Peck KK, Holodny AI. Cortical plasticity in the setting of brain tumors. *Top Magn Reson Imaging*. 2016;25(1):25–30.
13. Hartwigsen G, Saur D. Neuroimaging of stroke recovery from aphasia—insights into plasticity of the human language network. *Neuroimage*. 2019;190:14–31.
14. Hullett PW, Hamilton LS, Mesgarani N, Schreiner CE, Chang EF. Human superior temporal gyrus organization of spectrotemporal modulation tuning derived from speech stimuli. *J Neurosci*. 2016;36(6):2014–2026.
15. Khalighinejad B, Patel P, Herrero JL, Bickel S, Mehta AD, Mesgarani N. Functional characterization of human Heschl's gyrus in response to natural speech. *Neuroimage*. 2021;235:118003.
16. Nourski KV, Steinschneider M, McMurray B, et al. Functional organization of human auditory cortex: investigation of response latencies through direct recordings. *Neuroimage*. 2014;101:598–609.
17. Silbergeld DL. Tumors of Heschl's gyrus: report of two cases. *Neurosurgery*. 1997;40(2):389–392.
18. Zatorre RJ, Penhune VB. Spatial localization after excision of human auditory cortex. *J Neurosci*. 2001;21(16):6321–6328.
19. Kleen JK, Scott RC, Holmes GL, et al. Hippocampal interictal epileptiform activity disrupts cognition in humans. *Neurology*. 2013;81(1):18–24.
20. Kleen JK, Scott RC, Holmes GL, Lenck-Santini PP. Hippocampal interictal spikes disrupt cognition in rats. *Ann Neurol*. 2010;67(2):250–257.
21. Adam C, Adam C, Rouleau I, Saint-Hilaire JM. Postictal aphasia and paresis: a clinical and intracerebral EEG study. *Can J Neurol Sci*. 2000;27(1):49–54.
22. Koerner M, Laxer KD. Ictal speech, postictal language dysfunction, and seizure lateralization. *Neurology*. 1988;38(4):634–636.
23. Gajardo-Vidal A, Lorca-Puls DL, Team P, et al. Damage to Broca's area does not contribute to long-term speech production outcome after stroke. *Brain*. 2021;144(3):817–832.
24. Andrews JP, Cahn N, Speidel BA, et al. Dissociation of Broca's area from Broca's aphasia in patients undergoing neurosurgical resections. *J Neurosurg*. Published online August 5, 2022. doi: 10.3171/2022.6.JNS2297.
25. Ray S, Maunsell JHR. Different origins of gamma rhythm and high-gamma activity in macaque visual cortex. *PLoS Biol*. 2011;9(4):e1000610.

Disclosures

The authors report no conflict of interest concerning the materials or methods used in this study or the findings specified in this paper.

Author Contributions

Conception and design: Chang, Hullett, Kandahari, Shih, Rao. Acquisition of data: Chang, Hullett, Kandahari, Kleen, Knowlton, Rao. Analysis and interpretation of data: Chang, Hullett, Kandahari, Kleen, Knowlton. Drafting of the article: Hullett, Kandahari. Critically revising the article: Chang, Hullett, Kandahari, Kleen, Knowlton, Rao. Reviewed submitted version of manuscript: Hullett, Kandahari, Shih, Knowlton, Rao. Approved the final version of the manuscript on behalf of all authors: Chang. Statistical analysis: Hullett. Administrative/technical/material support: Hullett, Kandahari, Shih. Study supervision: Chang, Hullett, Rao. Medical and cultural interpreter: Kandahari.

Correspondence

Edward F. Chang: University of California, San Francisco, CA. edward.chang@ucsf.edu.