

UC Davis

Dermatology Online Journal

Title

Crusted scabies in an elderly woman

Permalink

<https://escholarship.org/uc/item/4c36775g>

Journal

Dermatology Online Journal, 26(10)

Authors

Cartron, Alexander M
Boettler, Michelle
Chung, Catherine
et al.

Publication Date

2020

DOI

10.5070/D32610050466

Copyright Information

Copyright 2020 by the author(s). This work is made available under the terms of a Creative Commons Attribution-NonCommercial-NoDerivatives License, available at <https://creativecommons.org/licenses/by-nc-nd/4.0/>

Peer reviewed

Crusted scabies in an elderly woman

Alexander M Cartron¹ BS, Michelle Boettler² BS, Catherine Chung² MD, John C Trinidad² MD MPH

Affiliations: ¹Department of Dermatology, University of Maryland School of Medicine, Baltimore Maryland, USA, ²Division of Dermatology, Department of Internal Medicine, The Ohio State University Wexner Medical Center, Columbus, Ohio, USA

Corresponding Author: John CL Trinidad MD MPH, The Ohio State University College of Medicine Division of Dermatology, 540 Officenter Place, Suite 240, Columbus, OH 43230, Tel: 510-331-9966, Fax: 614-293-1716, Email: john.trinidad@osumc.edu

Abstract

Crusted scabies is a highly contagious variant of classic scabies. Affected individuals are often elderly or immunocompromised and disease is associated with significant morbidity and mortality. Herein, we report an elderly woman residing in an assisted living facility who presented with diffuse sand-on-skin scale on her trunk, proximal extremities, scalp, hands, and feet. She was diagnosed with crusted scabies, isolated from other patients, and subsequently treated with permethrin 5% lotion and ivermectin. She died two weeks after initial presentation owing to sepsis.

Keywords: crusted scabies, elderly, sepsis

Introduction

Crusted scabies is a highly contagious form of scabies which is common in immunocompromised individuals and elderly patients [1]. In comparison to classic scabies, crusted scabies often progresses to sepsis and is associated with significant patient mortality [2]. A case of crusted scabies is presented in an elderly woman.

Case Synopsis

An elderly woman residing in an assisted living facility presented to the emergency department with erythroderma, hypotension, hypothermia. The rash began on the feet and spread diffusely over her entire body for two months encompassing up to 90% of her body surface area. Two courses of prednisone were initiated at 6 weeks, and two weeks

prior to her emergency department presentation with improvement in the rash but with subsequent flare. The patient was sent from an outpatient clinic with concerns for erythrodermic psoriasis.

On physical exam, diffuse, homogeneous, blanchable erythema with gritty, sandy scale was observed on the trunk and proximal extremities. Discrete erythematous plaques with scale were also noted on the scalp with thicker, more confluent scale present on the dorsal hands and feet (**Figure 1**). Scale had a distinct sand-on-skin type morphology. There was no facial or mucosal involvement and no ectropion.

Punch biopsy was performed and the stratum corneum revealed multiple mites and irregular structures consistent with scybala as well as an associated inflammatory infiltrate (**Figure 2**). Clinicopathological correlation was consistent with crusted scabies. She was also determined to have concomitant bacteremia with a urinary tract infection.

Contact precautions were initiated, an institutional infection control consultation was obtained, and the

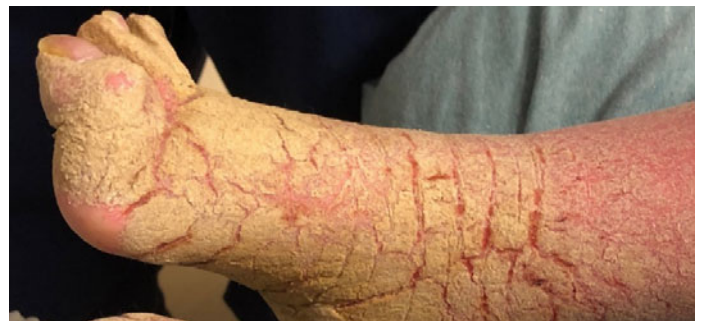

Figure 1. Clinical photo of the right dorsal foot showing thicker, more confluent scale.

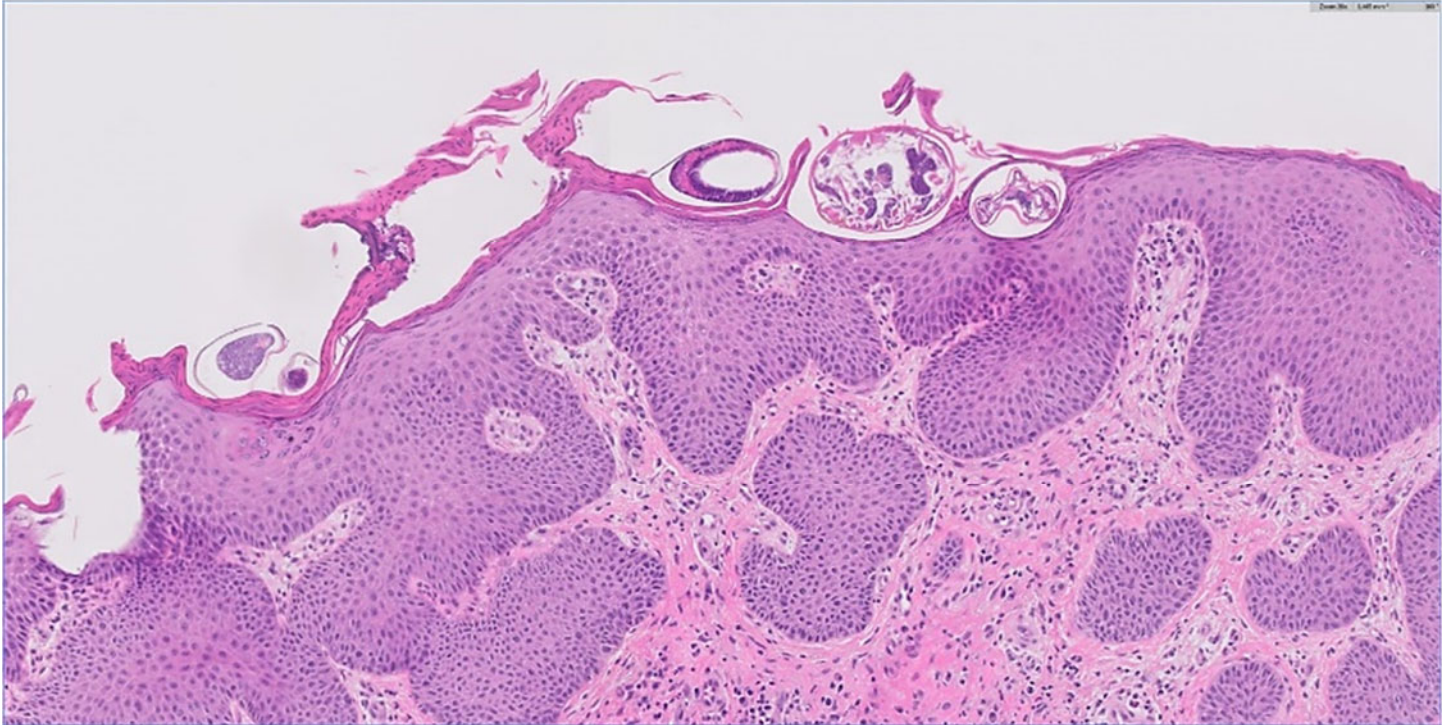


Figure 2. Histopathology of scabies showing multiple mites and irregular structures consistent with scybala in the stratum corneum. H&E, 200 \times .

regional department of public health was alerted. Permethrin 5% lotion was applied to the entire body daily for 7 days then twice weekly. Ivermectin 200mcg/kg was also given on days 1, 2, 8, 9, and 15 after diagnosis.

The patient's erythema resolved after one week with a fine macular rash remaining over her whole body with residual crusting on the feet, posterior neck, and scalp. However, subsequent scrapings for mites remained positive. The patient's chest radiograph demonstrated lung infiltrates and she had increased coughing and wheezing. There was significant concern for chronic aspiration during her hospitalization. She had an episode of tachycardia (140), hypoxia (85% on 2L NC), tachypnea (30), and decreased mental status, which prompted activation of the hospital emergency response team. Ultimately, her family decided to focus on the patient's comfort including an unrestricted diet, cessation of antibiotic therapy, initiation of a do not resuscitate order, and patient autonomy over medication compliance. The patient died two weeks after initial presentation.

Case Discussion

Crusted scabies is a highly contagious and form of scabies owing to hyper-infection of the organism *Sarcoptes scabiei*. Crusted scabies is characterized by unopposed proliferation of mites in the skin, hyperkeratotic scaling, crusted lesions, and variable pruritus [1,2]. Uncontrolled proliferation of mites typically occurs in patients with decreased cutaneous sensation, defective T-cell response, or reduced ability to mechanically debride the mites [2]. Major risk factors for crusted scabies include patients with nutritional deficiencies, patients with modified host response, such as older adults and cognitively impaired individuals, and patients with altered immune response [3]. In comparison to classic scabies in which patients may have 10 to 15 mites on the body, patients with crusted scabies have thousands to millions of mites [3,4]. Individuals with crusted scabies often contribute to mite transmission and major scabies outbreaks [4-6].

More than half of patients with crusted scabies may have identifiable immunosuppressive risk factors [2,5]. In comparison to classic scabies, crusted scabies often has an insidious onset and an eruption

consisting of localized horny plaques and characteristic erythema. As a result, scabies shares clinical features with, and may mimic, psoriasis, atopic dermatitis, contact dermatitis, and pityriasis rubra pilaris [2]. Diagnosis of crusted scabies is confirmed by examination of scrapings for mites and histopathological correlation on biopsy.

Treatment should include topical scabidical agents, systemic ivermectin, and potentially topical keratolytics. Permethin 5% cream is a first-line treatment, which should be applied daily for 7 days, and then twice weekly until symptoms have resolved. A single 200µg/kg dose of ivermectin should be given concomitantly on days 1, 2, 8, and 15, and potentially on days 22 and 29 for severe cases [4]. For patients who are unable to tolerate permethrin cream, sulfur, benzoyl benzoate, crotamiton, and malathion may be used as second-line topical agents [4]. Elderly patients may have difficulty applying topical therapy owing to limited mobility and therefore require assistance with treatment application. Effective treatment often involves prolonged hospitalization and may be challenging if patients have a large mite burden or compromised immunity. Sepsis is a common complication of crusted scabies and requires aggressive treatment with broad-spectrum antibiotics [5].

Recognition of crusted scabies in an institutional setting warrants immediate notification of institutional infection-control personnel. The Center for Disease Control and Prevention (CDC) recommends that local and state health departments develop guidelines for preventing, detecting, and responding to a single case or multiple cases of crusted scabies [7]. For surveillance, staff should maintain a high index of suspicion that scabies may be the underlying cause of an undiagnosed skin rash. At nursing homes, a staff member should be trained and experienced in obtaining and examining skin scrapings to identify scabies mites [7]. Institutions should maintain records with protected health information such as patient name, age, sex, room number, and roommates as well as the names of all staff who provided hands-on care to the patient before

implementation of infection control measures. Symptoms may take up to two months to appear in exposed patients and staff, despite the high transmission risk [8]. Environmental disinfection is important, and bedding used by the exposed person should be collected and transported in a secure manner to prevent transmission via fomites. Communication is extremely important to ensure a proactive employee health service approach to mitigate risk for other patients and staff.

In Ohio, where our academic medical center is located, The Ohio Department of Health has specific guidelines for typical scabies with additional measures for crusted scabies [9]. Until the patient is successfully treated and skin scrapings are negative for live mites, the patient should be placed on strict precautions. The patient should be isolated in a private room or a room with another person with crusted scabies. Designated staff should care for the affected patient, visitor contact should be restricted, and upholstered furniture covered with cloth fabric should be removed. Contact precautions are essential to decrease skin-to-skin contact and disposable gowns, gloves, and shoe covers should be used at all times. The patient's room should be vacuumed daily, and upon discharge, the vacuum cleaner should be designated to the patient's room. All individuals who may have been exposed to the affected patient should be identified and treated in a single 24- to 48-hour period to prevent re-exposure. In Ohio, scabies is not an individually reportable disease but outbreaks are, which is defined as two or more cases [9]. Crusted scabies is a major public health concern and careful adherence to local guidelines can mitigate outbreak-related morbidity and mortality.

Conclusion

Elderly patients are at increased risk for crusted scabies in comparison to the larger adult population. Once crusted scabies is identified, infection control personnel should be notified, the affected patient should be isolated, and the patient and exposed contacts should be treated immediately. Crusted scabies carries a significant risk for complications

including sepsis. Prompt recognition and treatment is essential to limit patient morbidity and mortality.

Potential conflicts of interest

The authors declare no conflicts of interest.

References

1. Douri T, Shawaf AZ. Treatment of crusted scabies with albendazole: A case report. *Dermatol Online J*. 2009;15:17. [PMID: 19951635].
2. Kutlu NS, Turan E, Erdemir A, Gürel MS, Bozkurt E. Eleven years of itching: A case report of crusted scabies. *Cutis*. 2014;94:6-9. [PMID: 25184648].
3. Guldbakke KK, Khachemoune A. Crusted scabies: a clinical review. *J Drugs Dermatol*. 2006;5:221-7. [PMID: 16573253].
4. Raffi J, Suresh R, Butler DC. Review of Scabies in the Elderly. *Dermatol Ther*. 2019;9:623-30. [PMID: 31512176].
5. Roberts LJ, Huffam SE, Walton SF, Currie BJ. Crusted scabies: clinical and immunological findings in seventy-eight patients and a review of the literature. *J Infect*. 2005;50:375-381. [PMID: 15907543].
6. Cassell JA, et al. Scabies outbreaks in ten care homes for elderly people: a prospective study of clinical features, epidemiology, and treatment outcomes. *Lancet Infect Dis*. 2018;18:894-902. [PMID: 30068499].
7. Crusted Scabies Cases (Single or Multiple) | Centers for Disease Control and Prevention. https://www.cdc.gov/parasites/scabies/health_professionals/cru sted.html. Accessed on March 29, 2020.
8. FitzGerald D, Grainger RJ, Reid A. Interventions for preventing the spread of infestation in close con- tacts of people with scabies. *Cochrane Database Syst Rev*. 2014; 2. [PMID: 24566946].
9. Scabies Prevention and Control Guidelines | Ohio Department of Health. https://odh.ohio.gov/wps/portal/gov/odh/know-our- programs/outbreak-response-bioterrorism-investigation- team/media/scabies_manual. Accessed on March 29, 2020.