

# UC San Diego

## UC San Diego Previously Published Works

### Title

Field tourniquets in an austere military environment: A prospective case series

### Permalink

<https://escholarship.org/uc/item/4bt5x4sz>

### Journal

Injury, 53(10)

### ISSN

0020-1383

### Authors

Covey, DC  
Gentchos, Christopher E

### Publication Date

2022-10-01

### DOI

10.1016/j.injury.2022.07.044

Peer reviewed



## Field tourniquets in an austere military environment: A prospective case series

D.C. Covey<sup>a,c,\*</sup>, Christopher E. Gentchos<sup>b,c</sup>

<sup>a</sup> Department of Orthopaedic Surgery, University of California, San Diego, 200 West Arbor Drive, San Diego, CA 92103, USA

<sup>b</sup> Concord Orthopaedics PA, 264 Pleasant Street, Concord, NH 03301, USA

<sup>c</sup> Level 2 United States Marine Corps Surgical Company, Al Anbar Province, Iraq



### ARTICLE INFO

#### Article history:

Accepted 25 July 2022

#### Keywords:

Tourniquet  
Trauma  
Vascular injury  
Extremity

### ABSTRACT

**Objective:** Field tourniquets are often used for battlefield extremity injuries. Their effectiveness has been documented by a large combat theater trauma center. However, their use and effectiveness by an austere forward surgical team has not been reported. Aims of this study were to determine: Whether field tourniquets: (1) Were placed for appropriate indications; (2) significantly reduced hemorrhage as measured by transfusion requirements; (3) influenced vital signs and injury severity scores; and (4) did they cause limb amputation, changed amputation level, or other complications.

**Methods:** Twenty-five patients with 30 involved extremities presenting to a forward surgical team in Iraq met the inclusion criteria. We prospectively collected data regarding the presence, indications for, and effectiveness of field tourniquets based on the need for blood transfusion. We recorded any complications associated with their use.

**Results:** Tourniquets significantly reduced hemorrhage from penetrating injuries as measured by transfusion requirements. Those having major vascular injuries with effective tourniquets, a total of 12 units of blood were transfused (1.7 units/vascular injury; 2 units/patient). However, 19 units were transfused in patients (3.3 units/vascular injury; 3.8 units/patient) who had an ineffective or no tourniquet ( $p = 0.0006$ ). Transfusion requirements were related the presence of an effective tourniquet regardless of concomitant injuries. The group with effective tourniquets and compressed hemorrhage presented with higher mean systolic ( $p = 0.003$ ) and diastolic ( $p = 0.023$ ) blood pressures than the group with no tourniquets or ineffective ones. Complications included one peroneal nerve palsy and no amputations resulted from tourniquet application.

**Conclusion:** Field tourniquets applied for penetrating injuries with severe bleeding can significantly reduce transfusion requirements and help maintain adequate blood pressure. Tourniquets were not the proximate cause of amputation and did not determine the choice of immediate amputation level.

Published by Elsevier Ltd.

This is an open access article under the CC BY license (<http://creativecommons.org/licenses/by/4.0/>)

### Introduction

Uncontrolled extremity hemorrhage is a major cause of potentially preventable death in combat casualties [1], and field tourniquets are frequently used in the initial treatment of patients with life-threatening musculoskeletal injuries. They were used in the Iraq War and are used in combat operations in Afghanistan [2–5]. Most orthopedic surgeons are familiar with tourniquet use for surgery in civilian operating rooms [6–13]. In this controlled

setting, tourniquet times ranging from one to three hours can usually be safely tolerated [14,15]. Even though operating room tourniquets are wide, well-padded, carefully positioned and have controlled pressures [16], complications such as nerve palsy [10] or muscle necrosis [17] may still occur.

Field tourniquet use for hemorrhage control in civilian extremity trauma has been questioned by some authors [18,19]. Potential concerns included severe ischemia with reperfusion injury, limb loss, and causing a more proximal amputation level than might otherwise be needed. These concerns also extended to tourniquet use on the battlefield. Conversely, a study by Lackstein et al. [20] on the tourniquet experience of the Israeli Defense Force in treating combat casualties found that 78% of 110 of tourniquets were effective and acute complications occurred in only 5 of 91

\* Corresponding author at: Department of Orthopaedic Surgery, University of California, 200 West Arbor Drive, San Diego, CA 92103.

E-mail addresses: [dcovey@health.ucsd.edu](mailto:dcovey@health.ucsd.edu) (D.C. Covey), [Christopher.Gentchos@concordortho.com](mailto:Christopher.Gentchos@concordortho.com) (C.E. Gentchos).

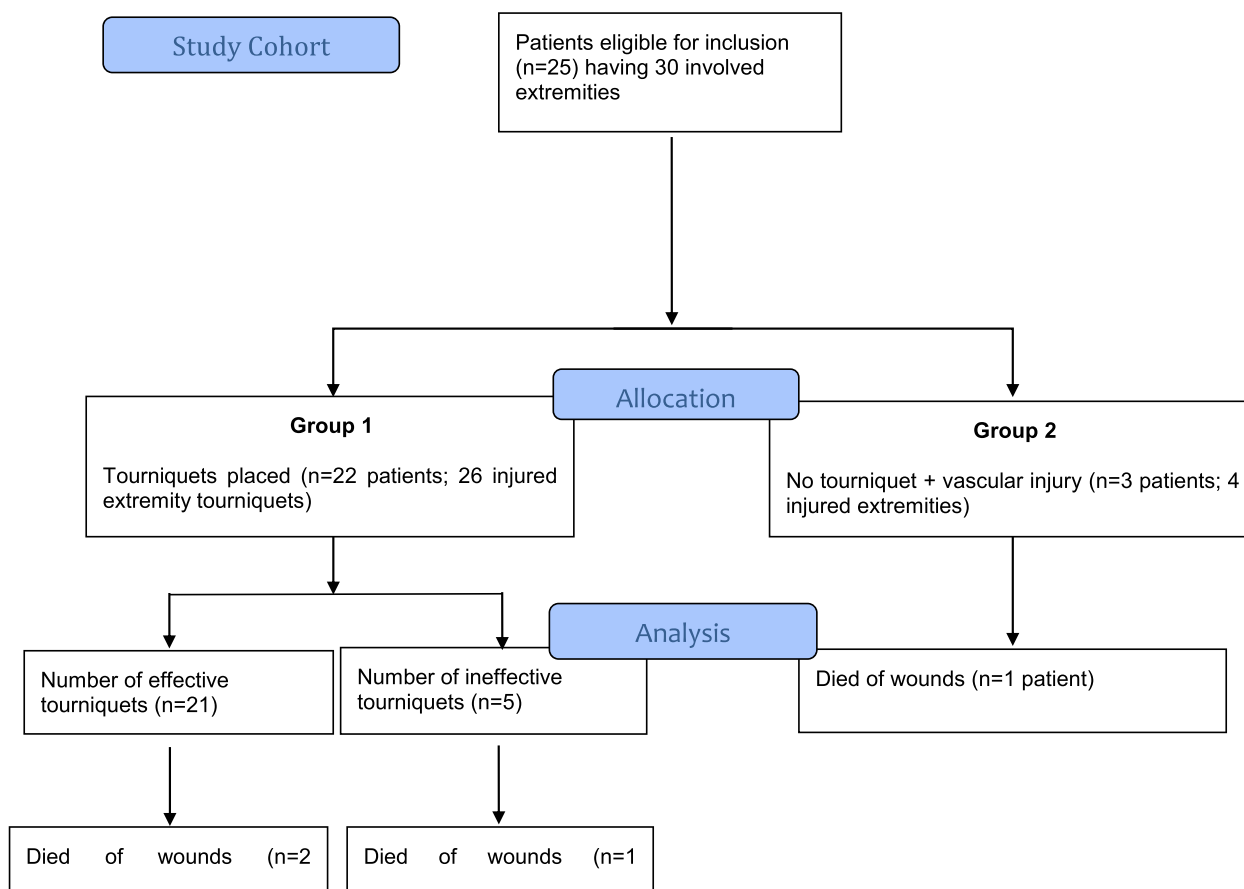


Fig. 1. Patient flow diagram.

patients. Nevertheless, questions persisted regarding proper indications, application, timing, and complications of tourniquet use for combat casualty care [3].

In a comprehensive review of battlefield-related injuries, Owens et al. [21] reported that of 82% of 1566 military personnel who sustained combat injuries had extremity trauma. In a study of vascular injuries, Fox et al. [22] reported known or suspected vascular injuries in 7% of 1524 combat casualties of which 88% involved the extremities. In the initial care of today's combat casualties, tourniquets are often applied on the battlefield for extremity trauma with presumptive vascular injury. Military first responders (corpsmen and medics) are taught that tourniquets can be lifesaving [2], and they usually decide on its use at the point of injury.

Aims of this study were to determine: Whether field tourniquet placement (1) was made for appropriate indications, (2) significantly reduced hemorrhage from penetrating injuries as measured by transfusion requirements, (3) if vital signs and injury severity scores were influenced by an effective tourniquet; and (4) did a tourniquet result in limb amputation, affect the immediate amputation level, or cause other complications.

#### Patients and methods

This study was approved by the Institutional Review Board of Naval Medical Center, San Diego. Tourniquet data was prospectively collected by a U.S. Marine Corps far forward surgical team in Al Anbar Province, Iraq, that received casualties from the point of injury. This surgical team was part of a Level 2 treatment facility within a 5-level echelon system where a higher number denotes increased sophistication of patient care [23].

This case series included 25 consecutive patients (30 involved extremities) who sustained extremity trauma during a defined four-month period. There were 24 males and one female, and the mean age was 29 years (range, 6 to 66 years). The decision to use a field tourniquet (Combat Application Tourniquet; CAT Resources, Rock Hill, SC) was made by a corpsman or medic in the field at the time of injury using the following guidelines: (1) If under fire, tourniquets should be placed proximal to the site of hemorrhage, over the casualty's uniform, and tightened as necessary to stop the bleeding; (2) once the patient is not under fire, the wound should be reevaluated, the tourniquet applied directly to the skin 2 to 3 inches above the bleeding site, and tightened sufficiently to stop the distal pulse; (3) tourniquets should be rechecked frequently to ensure that the hemorrhage is still controlled; (4) tourniquets should be left in place without attempts to transition to other methods of hemorrhage control if evacuation is expected to take 2 h or less; (5) tourniquets should be used for all traumatic amputations; and (6) application time should always be documented [24].

Each consecutive casualty who presented with a tourniquet in place composed Group 1, and those with presumptive extremity vascular injury based on clinical signs without a tourniquet composed Group 2 (Fig. 1). Patients were further classified as those who presented with an effective tourniquet (resulting in compressed hemorrhage), and those who presented either with an ineffective tourniquet or had major arterial hemorrhage without a tourniquet (uncompressed hemorrhage).

Patients having any arterial or major venous injury were considered to have a vascular injury. However, a major vascular injury was defined in this study as a proximal venous injury, a large arterial injury requiring repair or ligation (such as in cases traumatic am-

putations of mangled extremities) above the knee or elbow [22]. Casualties with *major vascular injuries* were further divided into subgroups: those having a *major vascular injury* with an effective tourniquet (compressed major vascular injuries); and those with a *major vascular injury* without a tourniquet or an ineffective one (uncompressed major vascular injuries).

#### Data collection

Patient demographics, injury mechanism, and clinical and surgical data were recorded for each patient (Table 1). Reports of obvious arterial bleeding, massive bleeding, or uncontrolled bleeding were frequently recounted by the corpsman or patient at the time the field tourniquet was applied.

Physical examination in the casualty receiving area determined the effectiveness of a tourniquet. It was considered effective if there was absence of palpable pulses or lack of active bleeding from a mangled or traumatically amputated limb [19]. Secondary indicators of included a relatively cooler limb and decreased capillary refill. Tourniquet application time was typically well documented, but in several instances was estimated based on time of injury. Field tourniquets were typically removed in the operating room before wound exploration to better control any profuse hemorrhage that may occur. Surgical findings, operative procedures, transfusion requirements and whether a tourniquet influenced the surgical amputation level were recorded. Specifically, the relationship between an *in situ* tourniquet and the decision to amputate a mangled extremity or revise an existing traumatic amputation to a level proximal to the tourniquet was made by clinical assessment of limb viability.

The Abbreviated Injury Scale (AIS) [25] was assigned to all injuries. New Injury Severity Scores (NISS) [26] and Revised Trauma Scores (RTS) [27] were calculated for all patients. These scoring systems were based on the modifications to the AIS in the case of the NISS; and on the patient's Glasgow Coma Scale, systolic blood pressure and respiratory rate for the RTS. Surgical interventions, a complete list of injuries, as well as follow up data were obtained via the Joint Theater Trauma Registry (JTTR), a prospective database that captures information on patients treated in combat theater U.S. Military treatment facilities. Non-U.S. service members were tracked until discharged to an Iraqi civilian hospital or other facility.

#### Statistical analysis

Descriptive statistics were used for demographic data. Power calculations showed that a minimum of 18 patients would be needed to differentiate mean systolic and diastolic blood pressure differences of 20 mm Hg with a power of 0.80 and a significance level of 0.05. Other data was analyzed using rank-sum, chi squared, and Fisher's Exact tests with STAT/SAS software (SAS Institute Inc., Cary, NC). Statistical significance for these calculations was set at  $p < 0.05$ .

## Results

#### Injury mechanisms

Penetrating trauma was the cause of injury in most cases (Table 2). The majority of penetrating trauma was caused by explosive ordnance (56%), followed by gunshot wounds (36%). Vascular injuries were most seen followed by open fractures (Table 3). Two patients had traumatic amputations at presentation.

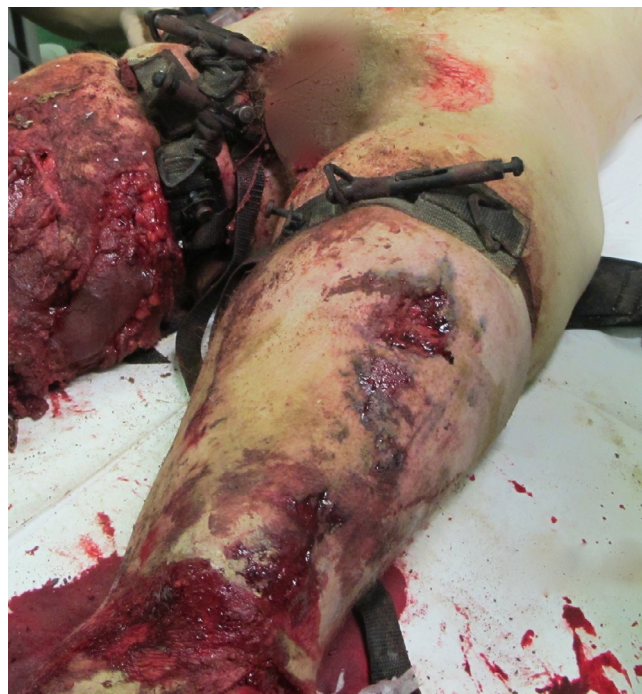

Fig. 2. 22-year-old Marine with bilateral tourniquets in place for severe lower extremity trauma due to detonation of an improvised explosive device.

#### Patients and tourniquets

Twenty-two patients presented with tourniquets on 26 extremities. Eleven of these patients (13 extremities) had *major vascular injuries*, and 8 patients had non-major vascular injuries. Eight of 11 patients with *major vascular injuries* presented with an effective tourniquet, and the other 3 presented without a tourniquet or an ineffective one (Table 4). Five of the above 26 extremities (19%) had tourniquets that were ineffective because palpable pulses were present distal to the tourniquet; but they did not have uncontrolled hemorrhage. There were no identifiable vascular injuries in 8 limbs where tourniquets were utilized. In those patients who presented without a tourniquet (Group 2), 3 patients (4 extremities) had vascular injuries. All patients who presented with traumatic amputations or mangled extremities had a tourniquet upon arrival (Fig. 2).

#### Blood products

Thirty-one packed or whole blood units were transfused in 11 patients with major vascular injuries of the extremities. Immediate transfusion requirements for initial resuscitation were different ( $p = 0.0006$ ) depending upon the presence and effectiveness of a field tourniquet, regardless of concomitant injuries. Twelve units were transfused in 6 patients (1.7 units/vascular injury or 2 units/patient) whose tourniquets were effective. Nineteen units were transfused into 5 patients with six major vascular injuries (3.3 units/vascular injury 3.8 units/patient) who had no tourniquet or an ineffective one.

#### Vital signs

The group with effective tourniquets presented with significantly higher mean systolic ( $p = 0.003$ ) and diastolic ( $p = 0.023$ ) blood pressures than the group with no tourniquets or ineffective ones (Table 5). Furthermore, the group with effective tourniquets had a significantly greater mean score on the Glasgow Coma Scale

**Table 1**  
Patient characteristics, injury, tourniquet and treatment data.

Patient	Age	Tourniquet Time (min)	Tourniquet Effective	Vital Signs	Exam	Mechanism	Surgical Findings	Vascular Injury	Associated Injuries	Procedure(s)	Transfusion	NISS
1	25	60	Yes	BP 129/60 HR 84 GCS 15 RR 16	No R. DP or PT a. pulses until tourniquet release	Dismounted IED	3B R. tib/fib fxs, no vascular injury (AIS = 3)	None	Blast bil. LEs (AIS = 2); face; arms (AIS = 2); jaw fx (AIS = 1); 3A L. ulna fx (AIS = 2)	I&D, ex-fix R. tib/fib, I&D, splint L. ulna fx, I&D soft tissue wounds	None	13
2	22	70	Yes	BP 92/50 HR 121 GCS 15 RR 30	No R. radial or ulnar a. pulses, global paresthesias	GSW	R. medial arm wound, laceration brachial a. (AIS = 3)	Brachial a.	GSW L RF (AIS = 1)	Brachial a. shunt; SVG & fasciotomy (storm precluded medevac)	1 U O+	10
3	29	150	Yes	BP 132/73 HR 94 GCS 15 RR 24	No R. radial, ulnar a. pulses; hand cold, pale	7-ton truck MVC	R. near AEA, lacerated brachial a. (AIS = 3)	Brachial a.	Closed R. femur fx (AIS = 3); lig. injury L. knee (AIS = 2)	AEA completion, ex-fix R. femur	None	18
4	18	85	Yes	BP 127/60 HR 76 GCS 15 RR 20	No L. DP & PT a. pulses until tourniquet release	Dismounted IED	Moderate size L thigh wounds w/o fx (AIS = 2)	None	None	I&D wounds	None	4
5	28	60	Yes	BP 137/76 HR 113 GCS 15 RR 18	No DP, PT a. pulses until tourniquet release; nerve deficit resolved	Dismounted IED	R. leg soft tissue wounds (AIS = 2)	None	None	I&D wounds, delayed partial closure	None	4
6	36	58	No	BP 114/73 HR 102 GCS 15 RR 16	R. DP & PT a. pulses on arrival	Dismounted IED	Soft tissue wound thigh, (AIS = 2)	None	None	I&D wounds,	None	4
7	27	70	Yes	BP 130/70 HR 91 GCS 15 RR 20	R. leg pale, cool; no pulses, R. arm cool, no pulses	Dismounted IED	Mangled R. leg, 3 arteries transected, 3C tib/fib fxs (AIS = 3)	Subclavian a., ant. tibial, post. tibial a; peroneal a.	Shoulder girdle fxs (AIS = 3); colon injury (AIS = 4) hemothorax (AIS = 3)	R. BKA; R. shoulder disarticulation	3U O+; 2U Whole Blood	25
8	24	70	Yes, both	B/P 150/97 HR 85 GCS 15 RR 16	R. foot traumatic amputation, no arterial bleeding; R. hand burns, no pulses, cool	Dismounted IED	Mangled R. leg, 3 arteries transected (AIS = 3) Return of hand pulses, bone loss MC 3–5, soft tissue injury (AIS = 3)	R. leg ant., post. tib. a, peroneal a; R. UE tourniquet w/o vascular injury	Facial laceration, hip laceration (AIS = 1)	Guillotine R BKA, debride hand wounds	None	18
9*	20	154	Yes, all	BP 54/45 HR 129 GCS 11 (eyes = 1, motor = 5) RR 20	L. arm cool & pale w/o pulses, open humerus fx; L. knee traumatic amputation; mangled R. leg	Dismounted IED	Tourniquet in place & no arterial bleeding during resuscitation from L. arm (AIS = 3) or bil. legs (AIS = 3,4)	L. brachial artery; R SFA; mangled RLE with vascular injuries	Open head trauma	Presenting temp 31° C, intra-thoracic active rewarming followed by open cardiac massage	none	24
10	23	125	Yes	BP 95/43 HR 120 GCS 14 (Verbal = 4) RR 20	Absent pulses; R. foot cool, pale	GSW	R. 3C tib/fib, peroneal a. lac.; tense compartments, pulses present with tourniquet release AIS = 3)	Peroneal a.	GSW abd & liver lac. (AIS = 3) GSW hemothorax (AIS = 3); GSWs gluteal region & R. thigh (AIS = 2)	Ex-lap; L. chest tube; I&D; ex-fix & fasciotomy w/ ligation of peroneal a.	5U O+, 4U Whole Blood	18
11	24	70	Yes	BP 73/56 HR 104 GCS 15 RR 24	L foot absent pulses, cool, pale	GSW & RPG blast	No fx; soft tissue wounds thigh (AIS = 2)	None	1) Bil. hemo-pneumothorax (AIS = 4) 2) small bowel perforation (AIS = 4)	Bilateral chest tubes; ex-lap & small bowel resection; I&D soft tissue wounds	3U autotransfusion	32
12	24	86	Yes	BP 132/68 HR 68 GCS 15 RR 21	Traumatic amputation R. hand at mid carpus	Grenade (picked up and threw to save others)	Traumatic amputation of R. mid carpus (AIS = 3)	Radial, ulnar a.	Small frag wounds bil. thighs (AIS = 1) and chin (AIS = 1)	I&D open amputation, ligation of radial, ulnar a.	None	10
13	56	79	Yes	BP 130/80 HR 61 GCS 15 RR 24	R. hand cool; pulses present	GSW	Radius fx, lg. soft tissue defect, intact radial, ulnar a; tense forearm swelling (AIS = 3)	None	GSW chest/hemothorax (AIS = 3)	R. chest tube I&D/fasciotomy R. forearm GSW	None	18

(continued on next page)

Table 1 (continued)

Patient	Age	Tourniquet Time (min)	Tourniquet Effective	Vital Signs	Exam	Mechanism	Surgical Findings	Vascular Injury	Associated Injuries	Procedure(s)	Transfusion	NISS
14	50	118	Yes	BP 129/83 HR 92 GCS 15 RR 22	L. arm cool, pale, absent distal pulses	GSW	BBFA fx, radial a. segmental loss, intact, dominant ulnar a. (AIS = 3)	Radial a.	GSW L thigh (No fx, ABI = 1.1) (AIS = 2)	I&D forearm w/ ex-fix, ligation radial a.	None	13
15	66	170	Yes	BP 150/65 HR 83 GCS 15 RR 24	Absent pulses, DP, PT and Popliteal, R. foot cool	GSW	Proximal saphenous v. lac, fxs superior & inferior pubic rami (AIS = 3)	Saphenous v.	GSW L. shoulder, no fracture, intact pulses (AIS = 2)	I&D wounds, ligation saphenous v.	None	13
16*	36	75	No (both)	BP 55/palp HR 134 GCS 8 RR 30	Traumatic bilateral AKAs	Mounted IED blunt/blast	Tourniquets loose, no blood flow bil. SFA during resuscitation (AIS = 4 R., 4 L.)	R. SFA; L. SFA	Possible blast injury to lungs & heart	B/L SFA ligation during resuscitation effort	7U O+	32
17	34	45	No	BP 139/88 HR 115 GCS 15 RR 16	Pressure dressing L. arm, palp rad pulse, hand pink/warm	Glass laceration during room clearance	Lacs. dorsal branch ulnar a., dorsal sensory branch ulnar n., FDS/FDP SF, MF; FCU (AIS = 2)	L. ulnar a. (branch)	none	I&D; nerve repair; artery ligated; flexor tendon repairs	None	4
18	24	60	No	BP 112/54 HR 63 GCS 15 RR 16	R. foot pink and warm, palpable pulses	Dismounted GSW	R. thigh ant. 2 × 2 cm wound, 7 × 3 cm post. wound, no fx (AIS = 2)	None	GSW R. forearm with distal radius fracture (AIS=3)	I&D forearm, splint; I&D thigh wounds	None	13
19	40	90	No	BP 120/80 GCS 15 RR 16	Foot pink and warm, palpable DP pulse	GSW escalation of force	SFA 6 cm intimal injury just proximal to Hunter's canal; no fractures (AIS = 3)	L. SFA	None	1° repair SFA	2U O+	9
20*	20	N/A	N/A	BP 80/40 HR 160 GCS 11 (3 = eye 4 = Verbal 4 = motor) RR 30	Palpable pulses bil. legs, open fractures	IED blast & vehicle rollover (blunt/blast)	Comminuted bil. open tib/fib fxs (AIS = 3 R & 3 L), tense swelling; L. peroneal a. lac	L. peroneal a.	Pelvis fracture (AIS = 4); L. hip dislocation (AIS = 3); bil calc. fxs (AIS = 2); L knee lig. injury (AIS = 2)	Spanning ex-fix of bil. legs & fasciotomies	7U O+ 1U whole blood	25
21	23	N/A	N/A	BP 111/66 HR 83 GCS 15 RR 18	Absent L. DP, PT, popliteal a. pulses	GSW	Intimal flap tear SFA; lac. saphenous v. (AIS = 3)	SFA, saphenous v.	None	I&D wounds, ligation saphenous v.; SFA bypass with reverse SVG	2U O+	9
22*	21	190	Yes	BP 100/28 HR 131 GCS 8 RR 10	Absent L. foot pulses; pale, cool	IED & MVC (Blunt/Blast)	3C L. tib/fib fxs with ant tibial a. injury (AIS = 3)	Anterior tibial a.	Splenic rupture (AIS = 4); bil. globe injury (AIS = 3); 3A femur fx (AIS = 3)	Ex-lap with splenectomy; L knee-spanning ex fix; I&D wound	6U O+	25
23	6	N/A	N/A	BP 99/37 HR 131 GCS 13 (4 = verbal 5 = pain) RR 10	Absent radial/ulnar a. pulses	Mortar attack	Proximal R brachial artery (AIS = 3)	Brachial a.	Small bowel wounds (AIS = 4), 3A L tibia, open L knee (AIS = 3), multiple soft tissue wounds R thigh/leg (AIS = 2)	resection; shunt to R brachial a.; I&D splint R leg 4) I&D, L knee joint	3U O+	25
24	28	125	Yes	BP 145/91 GCS 15 RR = 20	No DP, PT a. pulses, R. leg cool and blue	Dismounted IED	SFA lacerations (no fracture) (AIS = 3)	SFA & ant. tibial a.	Colon & small bowel injuries (AIS = 4); soft tissue wounds R arm (AIS = 2) & R leg (AIS = 2)	R hemi-colectomy, small bowel resection, R SFA shunt, R leg fasciotomy	4U O+ PRBC 4U whole blood	25
25	29	62	Yes	BP 147/81 HR 86 GCS 15 RR 18	Absent L. PT & DP a. pulses	GSW	Popliteal a. & v. transection; lateral tibial plateau fx (AIS = 3)	Popliteal a. & v.	None	Shunt SFA to popliteal a.; ligation popliteal v., L leg fasciotomy	3U O+	9

Abbreviations: AEA – Above elbow amputation; AIS – Abbreviated Injury Score; BBFA – Both-bone forearm; BKA – Below knee amputation; Calc – calcaneus; DP – Dorsalis pedis; Ex-fix – External fixation; Ex-lap – Exploratory laparotomy; FCU – Flexor carpi ulnaris; FDP Flexor digitorum profundus, FDS – Flexor digitorum superficialis; Fx – fracture; GCS – Glasgow Coma Scale; GSW – Gunshot wound; 3C – Gustillo grade 3C open fracture; I&D – Irrigation and debridement; IED – Improvised explosive device; MF – Middle finger; MVC – Motor vehicle collision; PT – Posterior tibial; RPG – Rocket propelled grenade; RF – Ring finger; SF – Small finger, SFA – Superficial femoral artery; SVG – Saphenous vein graft; Tib/fib – Tibia and fibula; N/A – Presentation without tourniquet.

**Table 2**  
Mechanisms of injury resulting in tourniquet use.

Mechanism	No. of Patients (%)
Improvised explosive device	11 (44)
Gunshot wound	9 (36)
Gunshot wound + rocket propelled grenade	1 (4)
Grenade	1 (4)
Mortar	1 (4)
Broken glass	1 (4)
Motor vehicle crash	1 (4)

**Table 3**  
Type and number of injuries.

Injury	No.
Vascular	13
Open fracture	10
Soft tissue	6
Traumatic amputations	6
Above knee (2)	
Below knee (2)	
Above elbow (1)	
Shoulder disarticulation (1)	
Neurologic	1

(Table 5). There were no significant differences in heart rate, respiratory rate, AIS and NISS between groups.

*Tourniquet complications*

The use of a tourniquet did not affect choice of immediate amputation level for those presenting with a mangled or traumatically amputated extremity based upon clinical criteria. Signs of limb viability were assessed in the operating room and included tissue color and consistency, bleeding ability and muscle contractility. There was one case (patient 5) of motor and sensory common peroneal nerve palsy after having had a thigh tourniquet applied for a proximal leg wound without a vascular injury that resolved after tourniquet release.

*Mortality*

Of the 4 patients (9, 16, 20, 22) who died of wounds (DOW), 4 effective tourniquets were placed for two major vascular injuries, while 2 ineffective tourniquets were placed for 2 other major vascular injuries. Patient 20 had no tourniquets in place when he presented with a pelvic fracture, which was immediately addressed [28] as well as other severe injuries resulting from an IED blast and vehicle rollover. He was treated with damage control resuscitation and external fixation but died of his wounds soon thereafter. The number of DOW patients was small, and thus no correlation was found between presence and effectiveness of a tourniquet and

survivability in these patients. Mean Glasgow Coma Scale at presentation for patients who died of wounds was 9.5 compared to 14.9 for survivors.

**Discussion**

In this investigation, we found that field tourniquets applied for penetrating injuries with severe bleeding can significantly reduce transfusion requirements and help maintain adequate blood pressure. The effective tourniquet group also had a significantly greater mean score on the Glasgow Coma Scale. Our observation that tourniquet use did not result in immediate limb amputation and did not affect the immediate amputation level was a clinical one made at our forward surgical team prior to onward medical evacuation of the patient. However, it is possible that tourniquet pressure may cause injury through local compression and temporary interruption of perfusion leading tissue damage that may not be appreciated during the immediate surgery. This might lead to soft tissue necrosis necessitating a different final amputation level.

A study by Kragh et al. [29] of casualties with tourniquets treated at a Level 3 trauma center found no association between tourniquet time and morbidity, no amputations that resulted solely from tourniquet use, but 4 patients (2%) had transient nerve palsies at the tourniquet level. The most likely factor that ultimately contributed to limb viability was the mechanism and energy of the injury, and not the application of a field tourniquet. Dunn et al. [5] retrospectively studied tourniquet use in US Army cavalry scouts wounded-in-action over an eight-year period during the Iraq and Afghanistan Wars. In a cohort of 313 patients having adequate documentation, 23 of 24 service members survived who had tourniquets in place upon arrival at a forward surgical team. Most of these soldiers were injured by an explosive device.

A field tourniquet is not appropriate for all extremity trauma [30]. There are areas of the extremities that are readily accessible and lend themselves to techniques of rapid bandage application even under combat conditions [31]. Another consideration is use of Combat Gauze [32] which is composed of a kaolin-impregnated rayon and polyester hemostatic dressing that may preclude the need for tourniquet application. In cases of below elbow or below knee vascular injuries a tourniquet can be utilized if needed, but a pressure dressing for an isolated below knee or below elbow injury may provide adequate hemostasis as these anatomic regions have smaller diameter vessels with lower occlusion pressures than proximal limb vessels [33].

Another consideration to assist in hemostasis in battlefield trauma is use of tranexamic acid, an antifibrinolytic drug that has been safely used to decrease blood loss after major surgery. Schiavone et al. [34] found that tranexamic acid given at the time of surgical incision significantly reduced blood loss in nailing of pertrochanteric femur fractures. Similarly, Porter et al [35] found that use of tranexamic acid in high-risk patients undergoing arthroplasty for hip fractures was not associated with an increased

**Table 4**  
Tourniquet use in patients with successful vs. unsuccessful compression of hemorrhage.

Variable	Category	Patients with Compressed Hemorrhage		Patients with Uncompressed Hemorrhage		Total #	P (FET)
		No.	%	No.	%		
Tourniquet Used	Yes	11	69%	5	31%	16	0.058
	No	0	0%	3	100%		
Vascular Injury	Yes	8	73%	3	27%	11	0.516
	No	3	60%	2	40%		
Tourniquet Effective	Yes	11	92%	1	8%	12	0.003*
	No	0	0%	4	100%		

\*Significant at P < 0.05; FET: Fisher's Exact Test.

**Table 5**  
Major vascular injury patients with successful vs. unsuccessful compression of hemorrhage.

Variable	Successful (C) or Unsuccessful (U) Bleeding Compression	No. of Patients	Mean $\pm$ SD	<i>P</i> <sup>1</sup>
Tourniquet Time (minutes)	C	11	88.6 $\pm$ 35.5	0.363
	U	5	70.6 $\pm$ 12.7	
SBP mm Hg	C	11	131.5 $\pm$ 15.0	0.003*
	U	8	102.6 $\pm$ 24.3	
DBP mm Hg	C	11	75.4 $\pm$ 13.0	0.023*
	U	8	53.7 $\pm$ 23.5	
HR	C	11	91.4 $\pm$ 19.2	0.297
	U	7	109.1 $\pm$ 33.8	
RR	C	11	21.2 $\pm$ 4.2	0.295
	U	8	19.5 $\pm$ 7.1	
GCS	C	11	15.0 $\pm$ 0	0.032*
	U	8	13.4 $\pm$ 2.6	
AIS	C	11	2.7 $\pm$ 0.5	0.075
	U	8	3.2 $\pm$ 0.7	
NISS	C	11	11.5 $\pm$ 5.9	0.209
	U	8	17.8 $\pm$ 10.2	

<sup>1</sup>From rank-sum test. \*Significant at 0.05 level. SBP: Systolic Blood Pressure. DBP: Diastolic Blood Pressure. HR: Heart Rate. RR: Respiratory Rate. GCS: Glasgow Coma Scale. AIS: Abbreviated Injury Scores. NISS: New Injury Severity Scores.

risk of mortality, deep venous thrombosis, pulmonary embolism, myocardial infarction, or stroke. Although not available for use in our series, given its efficacy in safely reducing postoperative blood loss, it should be considered for use by surgical teams during future deployments. There are several limitations of our study. First, although our study was adequately powered for the parameters of systolic and diastolic blood pressure, but it did not have the large patient numbers required to further refine statistical analysis. Second, because the vascular injuries were diagnosed by direct inspection of wounds, minor vascular injuries may have been underestimated. When penetrating trauma was not near a major vascular structure, and palpable pulses were present, the assumption was made that there was likely no major arterial injury. In some instances, this could be an inaccurate assumption because vascular injuries can be occult and present with delayed clinical symptoms [22]. Third, tissue viability was determined by clinical assessment by the surgeon, which is to a degree subjective, and might lead to under diagnosis of potentially adverse tourniquet effects.

The successful use of tourniquets in the Iraq and Afghanistan Wars has stimulated interest in using these devices in the management of civilian patients with severe extremity trauma [19]. Although most external bleeding can be controlled with direct pressure, there are cases where this is insufficient to stop arterial bleeding and may lead to exsanguination. Schroll et al. [36] performed a multi-center, retrospective study of 197 adult trauma patients admitted to Level I trauma centers with prehospital extremity tourniquets. They found that tourniquets were applied safely and effectively in their cohort, no limb loss was directly attributable their use, and that their results compared favorably to a similar military study [37]. Furthermore, in a retrospective study of 190 civilian patients who sustained extremity arterial injuries requiring amputation or revascularization, Passos et al. [38] showed that early tourniquet placement increased patient survival compared to no tourniquet. Our study lends support to these findings as tourniquets were placed in the field by junior personnel with training analogous to civilian first responders.

The austere location of our study could be likened to some rural or remote civilian environments where sophisticated trauma care such as revascularization is not readily available [39]. In such settings, tourniquet control of compressible extremity bleeding can be lifesaving. Although no large studies that address this issue, case reports have shown that use of tourniquets can lifesaving in cases of uncontrolled hemorrhage from a farm machinery injury in ru-

ral Queensland, Australia [39], from a gunshot wound in a remote region of Quebec, Canada [40], or from a rollover motor vehicle crash in Pennsylvania, USA [41]. The first two of these cases had prolonged evacuation times to reach surgical care.

In practice, field tourniquets are appropriate in the prehospital setting for control of significant extremity hemorrhage if direct pressure is ineffective or impractical [42]. The field tourniquet may be applied over clothing and is then tightened until the bleeding has stopped. In most cases, it should be left on until care is assumed by the surgical team. In cases where the tourniquet is in place for a prolonged period, its use should be reassessed frequently. Malo et al. [40] recommended that unless the patient is hemodynamically unstable, the environment is unstable, or insufficient assistance is available, direct pressure or a pressure dressing can be applied to the hemorrhage site, and the tourniquet pressure released while leaving it in place. If significant bleeding recurs, the tourniquet can be retightened. Before removal, one should be cognizant of the possibility of sudden cardiovascular collapse due to reperfusion and release of toxic cytokines into the systemic circulation.

## Conclusion

Field tourniquets have a distinct role in combat casualty care [43] and a role in civilian prehospital treatment as well [44]. When applied for upper or lower extremity penetrating injuries with severe bleeding, they can significantly reduce hemorrhage. The results of the current study show that immediate transfusion requirements for resuscitation were less if the patient had an effective a field tourniquet in place regardless of concomitant injuries. Also, those with effective tourniquets had higher mean systolic and diastolic blood pressures and higher GCS scores than those with no or ineffective tourniquets. Furthermore, this study found that field tourniquet use did not result in limb amputation or affect the immediate amputation level in otherwise mangled extremities.

## Declaration of Competing Interest

None.



## References

- [1] Bellamy RF. The causes of death in conventional land warfare: implications for combat casualty care research. *Mil Med* 1984;149:55–62.
- [2] Kragh JF, Baer DG, Walters TJ. Extended (16-Hour) Tourniquet application after combat wounds: a case report and review of the current literature. *J Orthop Trauma* 2007;21:274–8.
- [3] Walters TJ, Mabry RL. Issues related to the use of tourniquets on the battlefield. *Mil Med* 2005;170:770–5.
- [4] Dunn JC, Kusnezov N, Schoenfeld AJ, Orr JD, Cook PJ, Belmont PJ. Vascular injuries in combat-specific soldiers during operation Iraqi freedom and operation enduring freedom. *Ann Vasc Surg* 2016;35:30–7.
- [5] Dunn JC, Fares A, Kusnezov N, Chandler P, Cordova C, Orr J, Belmont P, Pallis M. US service member tourniquet use on the battlefield: Iraq and Afghanistan 2003–2011. *Trauma* 2016;18(3):216–20.
- [6] Bruner JM. Safety factors in the use of the pneumatic tourniquet for hemostasis in surgery of the hand. *J Bone Joint Surg Am* 1951;33:221–4.
- [7] Flatt AE. Tourniquet time in hand surgery. *Arch Surg* 1972;104:190–2.
- [8] Graham B, Breault MJ, McEwen JA, et al. Occlusion of arterial flow in the extremities at subsystolic pressures through the use of wide tourniquet cuffs. *Clin Orthop* 1993;286:257–61.
- [9] Moore MR, Garfin SR, Hargens AR. Wide tourniquets eliminate blood flow at low Inflation pressures. *J Hand Surg Am* 1987;12:1006–11.
- [10] Odinson A, Finsen V. The position of the tourniquet on the upper limb. *J Bone Joint Surg Br* 2002;84:202–4.
- [11] Shaw JA, Murray DG. The relationship between tourniquet pressure and underlying soft-tissue pressure in the thigh. *J Bone Joint Surg Am* 1982;64:1148–52.
- [12] Swanson AB, Livengood LC, Sattel AB. Local hypothermia to prolong safe tourniquet time. *Clin Orthop* 1991;264:200–8.
- [13] Wakai A, Winter DC, Street JT, Redmond PH. Pneumatic tourniquets in extremity surgery. *J Am Acad Orthop Surg* 2001;9:345–51.
- [14] Klenerman L. Tourniquet time-how long? *Hand* 1980;12:231–4.
- [15] Kam PC, Kavanagh R, Yoong FF, et al. The arterial tourniquet: pathophysiological consequences and anaesthetic implications. *Anaesthesia* 2001;56:534–45.
- [16] Crenshaw AG, Hargens AR, Gershuni DH, Rydevik B. Wide tourniquet cuffs more effective at lower Inflation pressures. *Acta Orthop Scand* 1988;59:447–51.
- [17] Williams JE, Tucker DB, Read JM. Rhabdomyolysis-myoglobinuria: consequences of prolonged tourniquet. *J Foot Surg* 1983;22:52–6.
- [18] Husum H, Gilbert M, Wisborg T, Pillgram-Larsen J. Prehospital tourniquets: there should be no controversy. *J Trauma* 2004;56:214–15.
- [19] Lee C, Porter KM, Hodgetts TJ. Tourniquet use in the civilian prehospital setting. *Emerg Med J* 2007;24:584–7.
- [20] Lakstein D, Blumfenfeld A, Sokolov T, Lin G, Bssorai R, Lynn M, Ben-Abraham R. Tourniquets for hemorrhage control on the battlefield: a 4-year accumulated experience. *J Trauma* 2003;54:S221–5.
- [21] Owens BD, Kragh JF, Macaitis J, Svoboda SJ, Wenke JC. Characterization of extremity wounds in operation Iraqi freedom and operation enduring freedom. *J Orthop Trauma* 2007;21:254–7.
- [22] Fox CJ, Gillespie DL, O'Donne 11 SD, Rasmussen TE, Goff JM, Johnson CA, Gagon RE, Sarac TP, Rich NM. Contemporary management of wartime vascular trauma. *J Vasc Surg* 2005;41:638–44.
- [23] Bagg MR, Covey DC, Powell ET. Levels of medical care in the global war on terrorism. *J Am Acad Orthop Surg* 2006;14:S7–9.
- [24] Butler FK. Tactical combat casualty care: update 2009. *J Trauma* 2010;69(1):S10–13 July.
- [25] Greenspan L, McLellan B, Greig H. Abbreviated injury scale and injury severity score: a scoring chart. *J Trauma* 1985;25:60–4.
- [26] Osier T, Baker S, Long W. A modification of the injury severity score that both improves accuracy and simplifies scoring. *J Trauma* 1997;43:922–6.
- [27] Champion H, Sacco W, Copes W, Gann D, Gennarelli T, Flanagan M. A revision of the trauma score. *J Trauma* 1989;29:623–9.
- [28] Meccariello L, Razzano C, De Dominicis C, Herrera-Molpeceres JA, Liuzza F, Erasmo R, Rocca G, Bisaccia M, Pagliarulo E, Cirfeda P, Gómez Garrido D, Rollo G. A new prognostic pelvic injury outcome score. *Med Glas* 2021;18(1):299–308 (Zenica)Feb 1.
- [29] Kragh JF, Walters TJ, Baer DG, Fox CJ, Wade CE, Salinas J, Holcomb JB. Practical use of emergency tourniquets to stop bleeding in major limb trauma. *J Trauma* 2008;64 S38 –50.
- [30] Smith AH, Laird C, Porter K, Bloch M. Haemostatic dressings in prehospital care. *Emerg Med J* 2013;30:784–9.
- [31] Zietlow JM, Zietlow SP, Morris DS, Berns KS, Jenkins DH. Prehospital use of hemostatic bandages and tourniquets: translation from military experience to implementation in civilian trauma care. *J Spec Oper Med* 2015;15:48–53.
- [32] Gegel BT, Austin PN, Johnson AD. An evidence-based review of the use of a combat gauze (QuikClot) for hemorrhage control. *AANA J* 2013;81(6):453–8 Dec 1.
- [33] Covey DC. Blast and fragment injuries of the musculoskeletal system. *J Bone Joint Surg Am* 2002;84:1221–34.
- [34] Schiavone A, Bisaccia M, Inkov I, Rinonapoli G, Manni M, Rollo G, Meccariello L, Vicente CI, Ceccarini P, Ruggiero C, Caraffa A. Tranexamic acid in pertrochanteric femoral fracture: is it a safe drug or not? *Folia Med* 2018;60(1):67–78 (Plovdiv).
- [35] Porter SB, Spaulding AC, Duncan CM, Wilke BK, Pagnano MW, Abdel MP. Tranexamic acid was not associated with increased complications in high-risk patients with hip fracture undergoing arthroplasty. *J Bone Joint Surg Am* 2021;103(20):1880–9.
- [36] Schroll R, Smith A, McSwain NE, Myers J, Rocchi K, Inaba K, Siboni S, Ver-cruyse GA, Ibrahim-Zada I, Sperry JL, Martin-Gill C, Cannon JW, Holland SR, Schreiber MA, Lape D, Eastman AL, Stebbins CS, Ferrada P, Han J, Meade P, Duchesne J. A multi-institutional analysis of prehospital tourniquet use. *J Trauma* 2015;79(1):10–14.
- [37] Kragh JF, Walters TJ, Baer DG, Fox CJ, Wade CE, Salinas J, Holcomb JB. Survival with emergency tourniquet use to stop bleeding in major limb trauma. *Ann Surg* 2009;249(1):1–7.
- [38] Passos E, Dingley B, Smith A, Engels PT, Ball CG, Faidi S, Nathens A, Tien HCanadian trauma trials collaborative. Tourniquet use for peripheral vascular injuries in the civilian setting. *Injury* 2014;45(3):573–7.
- [39] Fludger S, Bell A. Tourniquet application in a rural Queensland HEMS environment. *Air Med J* 2009;28(6):291–3.
- [40] Malo C, Bernardin B, Nemeth J, Khwaja K. Prolonged prehospital tourniquet placement associated with severe complications: a case report. *Can J Emerg Med* 2015;17(4):443–6 Jul.
- [41] Sims C, Polk T. Rollover car crash almost costs driver his life, limb. *J Emerg Med Serv* 2012;37(9):30–1.
- [42] Bulger EM, Snyder D, Schoelles K, Gotschall C, Dawson D, Lang E, et al. An evidence-based prehospital guideline for external hemorrhage control: American college of surgeons committee on trauma. *Prehosp Emerg Care* 2014;18(2):163–73 Apr 3.
- [43] Howard JT, Kotwal RS, Stern CA, Janak JC, Mazuchowski EL, Butler FK, et al. Use of combat casualty care data to assess the US military trauma system during the Afghanistan and Iraq conflicts, 2001–2017. *JAMA Surg* 2019;154(7):600–8.
- [44] Goodwin T, Moore KN, Pasley JD, Troncoso R, Levy MJ, Goolsby C. From the battlefield to main street: tourniquet acceptance, use, and translation from the military to civilian settings. *J Trauma* 2019;87(1S):S35–9.