

UC Irvine

Clinical Practice and Cases in Emergency Medicine

Title

CPC-EM Full Issue Text

Permalink

<https://escholarship.org/uc/item/4982883s>

Journal

Clinical Practice and Cases in Emergency Medicine, 8(3)

Author

Valenzi, Nicole

Publication Date

2024-08-09

DOI

10.5811/cpcem.33592

Copyright Information

This work is made available under the terms of a Creative Commons Attribution License, available at <https://creativecommons.org/licenses/by/4.0/>

CPC Emergency Medicine

Volume 8, Number 3, August 2024

Open Access at www.cpcem.org

ISSN: 2474-252X

Clinical Practice and Cases in Emergency Medicine

In Collaboration with the *Western Journal of Emergency Medicine*

Clinicopathological Cases from the University of Maryland

- 182 A 77-Year-Old Male with a Rapid Change in Mental Status**
Andrew Piner, Spencer S. Lovegrove, Laura J. Bontempo, T. Andrew Windsor

Case Reports

- 189 Pneumothorax Identified by a Remote Physician Using Paramedic-obtained Tele-ultrasound: Case Report**
Shriman Balasubramanian, Michael DeFilippo, Michael Stone, Gabriela Galli, Matthew McCarty, Brock Daniels
- 194 Renal Artery Aneurysm Rupture as a Dangerous Mimic of Ovarian Cyst Rupture: A Case Report**
Lauren Kaplan, Kaushal H. Shah, Christie Lech, Mary-Kate Gorlick
- 197 *Capnocytophaga ochracea* Septicemia After a Dog Bite: The Case of a Usual Suspect Transmitting an Unusual Organism**
Clifford Chang, Vakula Atthota, Madison Lord, Michael P. Bonk, Muhammad Durrani
- 202 High-altitude Cerebral Edema and High-altitude Pulmonary Edema Diagnosed in the Desert: A Case Report**
Bryn Walsh, Suneil Agrawal
- 206 Acute Confusional Migraines: A Case Report**
Devin M. Howell, Garrett Lamouree
- 211 Spontaneous Osteomyelitis and Intraosseous Abscess: A Case Report**
Meghan Chamberlain, Simon A. Sarkisian
- 215 A Case Report of Wunderlich Syndrome Causing Massive Hemorrhage During Hemodialysis**
Karalee Bluhm, Ravali Kundeti, Nicole Maguire

Contents continued on page iii



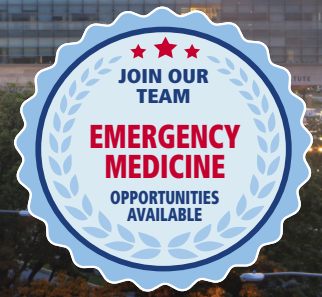UC Irvine Health



A Peer-Reviewed, International Professional Journal



**ACOEPE stands with all emergency
physicians and providers on the
front line. We thank you for your
tireless work and effort.**



Penn State Health Emergency Medicine

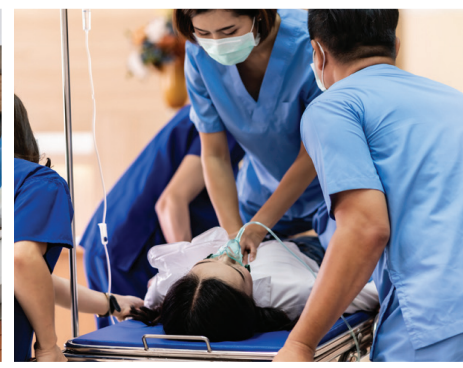About Us:

Penn State Health is a multi-hospital health system serving patients and communities across central Pennsylvania. We are the only medical facility in Pennsylvania to be accredited as a Level I pediatric trauma center and Level I adult trauma center. The system includes Penn State Health Milton S. Hershey Medical Center, Penn State Health Children’s Hospital, and Penn State Cancer Institute based in Hershey, Pa.; Penn State Health Hampden Medical Center in Enola, Pa.; Penn State Health Holy Spirit Medical Center in Camp Hill, Pa.; Penn State Health St. Joseph Medical Center in Reading, Pa.; Penn State Health Lancaster Pediatric Center in Lancaster, Pa.; Penn State Health Lancaster Medical Center (opening fall 2022); and more than 3,000 physicians and direct care providers at more than 126 outpatient practices in 94 locations. Additionally, the system jointly operates various health care providers, including Penn State Health Rehabilitation Hospital, Hershey Outpatient Surgery Center, Hershey Endoscopy Center, Horizon Home Healthcare and the Pennsylvania Psychiatric Institute.

We foster a collaborative environment rich with diversity, share a passion for patient care, and have a space for those who share our spark of innovative research interests. Our health system is expanding and we have opportunities in both academic hospital as well community hospital settings.

Benefit highlights include:

- Competitive salary with sign-on bonus
- Comprehensive benefits and retirement package
- Relocation assistance & CME allowance
- Attractive neighborhoods in scenic central Pa.



PennState Health

FOR MORE INFORMATION PLEASE CONTACT:

Heather Peffley, PHR CPRP - Penn State Health Lead Physician Recruiter

hpeffley@pennstatehealth.psu.edu

Penn State Health is fundamentally committed to the diversity of our faculty and staff. We believe diversity is unapologetically expressing itself through every person’s perspectives and lived experiences. We are an equal opportunity and affirmative action employer. All qualified applicants will receive consideration for employment without regard to age, color, disability, gender identity or expression, marital status, national or ethnic origin, political affiliation, race, religion, sex (including pregnancy), sexual orientation, veteran status, and family medical or genetic information.

Clinical Practice and Cases in Emergency Medicine

Indexed in PubMed and full text in PubMed Central

Rick A. McPheeters, DO, Editor-in-Chief
Kern Medical/UCLA- Bakersfield, California

R. Gentry Wilkerson, MD, Deputy Editor
University of Maryland School of Medicine

Mark I. Langdorf, MD, MHPE, Senior Associate Editor
University of California, Irvine School of Medicine- Irvine, California

Shahram Lotfipour, MD, MPH, Senior Associate Editor
University of California, Irvine School of Medicine- Irvine, California

Shadi Lahham, MD, MS, Associate Editor
Kaiser Permanente- Orange County, California

John Ashurst, DO, Decision Editor/ ACOEP Guest Editor
Kingman Regional Health Network, Arizona

Anna McFarlin, MD, Decision Editor
Louisiana State University Health Science Center- New Orleans, Louisiana

Lev Libet, MD, Decision Editor
Kern Medical/UCLA- Bakersfield, California

Christopher Sampson, MD, Decision Editor
University of Missouri- Columbia, Missouri

Joel Moll, MD, Decision Editor
Virginia Commonwealth University School of Medicine- Richmond, Virginia

Steven Walsh, MD, Decision Editor
Einstein Medical Center Philadelphia-Philadelphia, Pennsylvania

Melanie Heniff, MD, JD, Decision Editor
University of Indiana School of Medicine- Indianapolis, Indiana

Austin Smith, MD, Decision Editor
Vanderbilt University Medical Center-Nashville, Tennessee

Rachel A. Lindor, MD, JD, Decision Editor
Mayo Clinic College of Medicine and Science

Jacqueline K. Le, MD, Decision Editor
Desert Regional Medical Center

Christopher San Miguel, MD, Decision Editor
Ohio State University Wexner Medical Center

Editorial Board

Amin A. Kazzi, MD, MAAEM
The American University of Beirut, Beirut, Lebanon

Barry E. Brenner, MD, MPH
Case Western Reserve University

Brent King, MD, MMM
University of Texas, Houston

Daniel J. Dire, MD
University of Texas Health Sciences Center San Antonio

Edward Michelson, MD
Texas Tech University

Edward Panacek, MD, MPH
University of South Alabama

Erik D. Barton, MD, MBA
Icahn School of Medicine, Mount Sinai, New York

Francesco Dellacorte, MD
Azienda Ospedaliera Universitaria "Maggiore della Carità," Novara, Italy

Gayle Galletta, MD
Sorlandet Sykehus HF, Akershus Universitetssykehus, Lorenskog, Norway

Hjalti Björnsson, MD
Icelandic Society of Emergency Medicine

Leslie Zun, MD, MBA
Chicago Medical School

Linda S. Murphy, MLIS
University of California, Irvine School of Medicine Librarian

Niels K. Rathlev, MD
Tufts University School of Medicine

Pablo Aguilera Fuenzalida, MD
Pontificia Universidad Católica de Chile, Región Metropolitana, Chile

Peter A. Bell, DO, MBA
Baptist Health Science University

Peter Sokolove, MD
University of California, San Francisco

Robert Suter, DO, MHA
UT Southwestern Medical Center

Robert W. Derlet, MD
University of California, Davis

Scott Rudkin, MD, MBA
University of California, Irvine

Scott Zeller, MD
University of California, Riverside

Steven Gabaeff, MD
Clinical Forensic Medicine

Steven H. Lim, MD
Changi General Hospital, Simei, Singapore

Vijay Gautam, MBBS
University of London, London, England

Wirachin Hoonpongsimanont, MD, MSBATS
Siriraj Hospital, Mahidol University, Bangkok, Thailand

Advisory Board

Amal Khalil, MBA
UC Irvine Health School of Medicine

Elena Lopez-Gusman, JD
California ACEP American College of Emergency Physicians

DeAnna McNett, CAE
American College of Osteopathic Emergency Physicians

John B. Christensen, MD
California Chapter Division of AAEM

Randy Young, MD
California ACEP American College of Emergency Physicians

Mark I. Langdorf, MD, MHPE
UC Irvine Health School of Medicine

Jorge Fernandez, MD
California ACEP American College of Emergency Physicians University of California, San Diego

Peter A. Bell, DO, MBA
American College of Osteopathic Emergency Physicians Baptist Health Science University

Robert Suter, DO, MHA
American College of Osteopathic Emergency Physicians UT Southwestern Medical Center

Shahram Lotfipour, MD, MPH
UC Irvine Health School of Medicine

Brian Potts, MD, MBA
California Chapter Division of AAEM Alta Bates Summit-Berkeley Campus

Editorial Staff

Isabelle Nepomuceno, BS
Executive Editorial Director

Visha Bajaria, BS
CPC-EM Editorial Director

Emily Kane, MA
CPC-EM Editorial Director

Stephanie Burmeister, MLIS
CPC-EM Staff Liaison

Cassandra Saucedo, MS
Executive Publishing Director

Nicole Valenzi, BA
CPC-EM Publishing Director

June Casey, BA
Copy Editor

Official Journal of the California Chapter of the American College of Emergency Physicians, the American College of Osteopathic Emergency Physicians, and the California Chapter of the American Academy of Emergency Medicine



Available in MEDLINE, PubMed, PubMed Central, Google Scholar, eScholarship, DOAJ, and OASPA.

Editorial and Publishing Office: *WestJEM/Department of Emergency Medicine, UC Irvine Health, 3800 W. Chapman Ave. Suite 3200, Orange, CA 92868, USA*

Office: 1-714-456-6389; Email: Editor@westjem.org

Clinical Practice and Cases in Emergency Medicine

Indexed in PubMed and full text in PubMed Central

This open access publication would not be possible without the generous and continual financial support of our society sponsors, department and chapter subscribers.

Professional Society Sponsors

AMERICAN COLLEGE OF OSTEOPATHIC EMERGENCY PHYSICIANS
CALIFORNIA ACEP

CALIFORNIA CHAPTER DIVISION OF
AMERICAN ACADEMY OF EMERGENCY MEDICINE

Academic Department of Emergency Medicine Subscribers

Albany Medical College Albany, NY	INTEGRIS Health Oklahoma City, OK	Robert Wood Johnson University Hospital New Brunswick, NJ	University of Florida, Jacksonville Jacksonville, FL
American University of Beirut Beirut, Lebanon	Kaweah Delta Health Care District Visalia, CA	Rush University Medical Center Chicago, IL	University of Illinois at Chicago Chicago, IL
Arrowhead Regional Medical Center Colton, CA	Kennedy University Hospitals Turnersville, NJ	Southern Illinois University Carbondale, IL	University of Illinois College of Medicine Peoria, IL
Augusta University Augusta GA	Kern Medical Bakersfield, CA	St. Luke's University Health Network Bethlehem, PA	University of Iowa Iowa City, IA
Baystate Medical Center Springfield, MA	Lakeland HealthCare St. Joseph, MI	Stanford/Kaiser Emergency Medicine Residency Program Stanford, CA	University of Louisville Louisville, KY
Beaumont Hospital Royal Oak, MI	Lehigh Valley Hospital and Health Network Allentown, PA	Staten Island University Hospital Staten Island, NY	University of Maryland Baltimore, MD
Beth Israel Deaconess Medical Center Boston, MA	Loma Linda University Medical Center Loma Linda, CA	SUNY Upstate Medical University Syracuse, NY	University of Michigan Ann Arbor, MI
Boston Medical Center Boston, MA	Louisiana State University Health Sciences Center New Orleans, LA	Temple University Philadelphia, PA	University of Missouri, Columbia Columbia, MO
Brigham and Women's Hospital Boston, MA	Madigan Army Medical Center Tacoma, WA	Texas Tech University Health Sciences Center El Paso, TX	University of Nebraska Medical Center Omaha, NE
Brown University Providence, RI	Maimonides Medical Center Brooklyn, NY	University of Alabama, Birmingham Birmingham, AL	University of South Alabama Mobile, AL
Carl R. Darnall Army Medical Center Fort Hood, TX	Maricopa Medical Center Phoenix, AZ	University of Arkansas for Medical Sciences Little Rock, AR	University of Southern California/Keck School of Medicine Los Angeles, CA
Conemaugh Memorial Medical Center Johnstown, PA	Massachusetts General Hospital Boston, MA	University of California, Davis Medical Center Sacramento, CA	University of Tennessee, Memphis Memphis, TN
Desert Regional Medical Center Palm Springs, CA	Mayo Clinic College of Medicine Rochester, MN	University of California Irvine Orange, CA	University of Texas, Houston Houston, TX
Doctors Hospital/Ohio Health Columbus, OH	Mt. Sinai Medical Center Miami Beach, FL	University of California, Los Angeles Los Angeles, CA	University of Texas Health San Antonio, TX
Eastern Virginia Medical School Norfolk, VA	North Shore University Hospital Manhasset, NY	University of California, San Diego La Jolla, CA	University of Warwick Library Coventry, United Kingdom
Einstein Healthcare Network Philadelphia, PA	Northwestern Medical Group Chicago, IL	University of California, San Francisco San Francisco, CA	University of Washington Seattle, WA
Emory University Atlanta, GA	Ohio State University Medical Center Columbus, OH	UCSF Fresno Center Fresno, CA	University of Wisconsin Hospitals and Clinics Madison, WI
Genesys Regional Medical Center Grand Blanc, Michigan	Ohio Valley Medical Center Wheeling, WV	University of Chicago, Chicago, IL	Wake Forest University Winston-Salem, NC
Hartford Hospital Hartford, CT	Oregon Health and Science University Portland, OR	University of Colorado, Denver Denver, CO	Wright State University Dayton, OH
Hennepin County Medical Center Minneapolis, MN	Penn State Milton S. Hershey Medical Center Hershey, PA	University of Florida Gainesville, FL	
Henry Ford Hospital Detroit, MI	Presence Resurrection Medical Center Chicago, IL		

State Chapter Subscribers

ARIZONA CHAPTER DIVISION OF THE
AMERICAN ACADEMY OF EMERGENCY MEDICINE
CALIFORNIA CHAPTER DIVISION OF THE
AMERICAN ACADEMY OF EMERGENCY MEDICINE
FLORIDA CHAPTER DIVISION OF THE
AMERICAN ACADEMY OF EMERGENCY MEDICINE

GREAT LAKES CHAPTER DIVISION OF THE
AMERICAN ACADEMY OF EMERGENCY MEDICINE
TENNESSEE CHAPTER DIVISION OF THE
AMERICAN ACADEMY OF EMERGENCY MEDICINE

UNIFORMED SERVICES CHAPTER DIVISION OF THE
AMERICAN ACADEMY OF EMERGENCY MEDICINE
VIRGINIA CHAPTER DIVISION OF THE
AMERICAN ACADEMY OF EMERGENCY MEDICINE

International Society Partners

EMERGENCY MEDICINE ASSOCIATION OF TURKEY
LEBANESE ACADEMY OF EMERGENCY MEDICINE
MEDITERRANEAN ACADEMY OF EMERGENCY MEDICINE

NORWEGIAN SOCIETY FOR EMERGENCY MEDICINE
SOCIEDAD ARGENTINA DE EMERGENCIAS

SOCIEDAD CHILENO MEDICINA URGENCIA
THAI ASSOCIATION FOR EMERGENCY MEDICINE

To become a *WestJEM* departmental sponsor, waive article processing fee, receive print and copies for all faculty and electronic for faculty/residents, and free CME and faculty/fellow position advertisement space, please go to <http://westjem.com/subscribe> or contact:

Stephanie Burmeister
WestJEM Staff Liaison
Phone: 1-800-884-2236
Email: sales@westjem.org

JOURNAL FOCUS

Clinical Practice and Cases in Emergency Medicine (CPC-EM) is a MEDLINE-indexed internationally recognized journal affiliated with the *Western Journal of Emergency Medicine* (WestJEM). It offers the latest in patient care case reports, images in the field of emergency medicine and state of the art clinicopathological and medicolegal cases. CPC-EM is fully open-access, peer reviewed, well indexed and available anywhere with an internet connection. CPC-EM encourages submissions from junior authors, established faculty, and residents of established and developing emergency medicine programs throughout the world.

Table of Contents

- 219 **A Case Report of Crotalidae Immune F(ab')₂-associated Coagulopathy Recurrence in a Preschool-age Child**
Jean C. Y. Lo, E. Lea Walters, Brian Wolk
- 222 **A Case Report of Delayed Opioid Toxidrome After Administration of Naloxone**
Maiya Cowan, Prasanna Kumar, Jenny McManus, Sean Bilodeau, Andrew Beck
- 226 **Testicular Traction Technique with Intact Cremasteric Reflex, a Novel Approach for Manual Detorsion: Case Report**
Garrett Trang, Taz Brinkerhoff
- 231 **A Case Report of Hematogenous Osteomyelitis of the Manubrium Caused by Seeding from a Colovesicular Fistula**
Celina Wong, Tammy Phan, Emmelyn Samones, Sharmin Kalam
- 235 **Ultrasound-guided Supraclavicular Brachial Plexus Block for Therapeutic Management of Postoperative Compressive Brachial Plexus Neuropathy: A Case Report**
Daniela Usuga, Sofia Portuondo, David Farcy, Michael Shalaby
- 239 **Neurogenic Pulmonary Edema Associated with Hyponatremia, Primary Polydipsia, and Cannabis Use: A Case Report**
Christian Treat, Nicholas Ulloa, Alyssa Kettler, David Lawrence
- 243 **Spontaneous Intracranial Hypotension Associated with Marfan Syndrome: A Case Report**
Faiza Tariq, Wesley Eilbert
- 246 **Atrial Fibrillation Occurring After Smoking Marijuana: A Case Report and Review of the Literature**
Mary Unanyan, Christopher Colbert, Wesley Eilbert
- 250 **ST-Elevation Myocardial Infarction Due to Coronary Vasospasm Associated with Eosinophilic Granulomatosis with Polyangiitis: A Case Report**
Christopher Allen, Christopher Poyorena, Lauren B. Querin
- 254 **Point-of-Care Ultrasound Findings in Occlusive Iliac Vein Thrombus During Pregnancy: A Case Report**
Donald Pettet III, John Forrester, Mathew Nelson, Tanya Bajaj
- 259 **Rectus Sheath Blocks for Umbilical Hernia Reductions in the Emergency Department: A Case Series**
Katherine Vlasica, Amanda Hall
- 264 **Angioedema Secondary to Tenecteplase Use in a Patient with Acute Ischemic Stroke: A Case Report**
Babette Newman, Matthew Poremba, R. Gentry Wilkerson
- 268 **Tension Pyopneumothorax in an Immunocompetent Adolescent: A Case Report**
Elizabeth May-Smith, Marc Olshan, Mark Supino

Policies for peer review, author instructions, conflicts of interest and human and animal subjects protections can be found online at www.westjem.com.

JOURNAL FOCUS

Clinical Practice and Cases in Emergency Medicine (CPC-EM) is a MEDLINE-indexed internationally recognized journal affiliated with the *Western Journal of Emergency Medicine* (WestJEM). It offers the latest in patient care case reports, images in the field of emergency medicine and state of the art clinicopathological and medicolegal cases. CPC-EM is fully open-access, peer reviewed, well indexed and available anywhere with an internet connection. CPC-EM encourages submissions from junior authors, established faculty, and residents of established and developing emergency medicine programs throughout the world.

Table of Contents *continued*

- 273 **Community-Acquired *Candida albicans* Empyema Leading to Tension Physiology: A Case Report**
Jason Cinti, Paula Gomez, Suneil Agrawal
- 277 **“K Cramps,” Recurrent Abdominal Pain in a Patient with Chronic Ketamine Use: A Case Report**
Tucker Avra, Jesus Torres, Kumar Felipe Vasudevan, Elizabeth A. Samuels
- 282 **Pupil Unleashed: Unraveling the Enigma of an Unusual Traumatic Head Injury: A Case Report**
Akash Daswaney, Shuchi Abhishek, Sanjan Asanaru Kunju, Priya Pattath Sankaran, Ahlam Abdul Rahman
- 287 **Spontaneous Hemothorax from Pulmonary Intralobar Sequestration: A Case Report**
Clayton Korson, Jasmine Yu, John M. Pester
- 291 **Median Nerve Measurement and Steroid Injection for Carpal Tunnel Syndrome: A Case Report**
Gregory Oliva, Joseph McShannic, Yonghoon Lee, Michael Shalaby

Images in Emergency Medicine

- 295 **Bezold Abscess in a Case of Eosinophilic Otitis Media**
Satoshi Tsuruta, Takashi Fujiwara
- 298 **Point-of-care Ultrasound Diagnosed Intraocular Breast Metastasis**
Hamzah M. Yusuf, Timothy Batchelor, Nicholas Ashenburg
- 300 **Spinal Arachnoid Web**
Maiya Smith, Morgan Ketterling, Alexander Gallaer, Rowan Kelner, Christine Raps, Allison M. Beaulieu
- 302 **A Woman with Right Shoulder Pain**
Kitan Akinosho, William Weber
- 305 **Point-of-Care Ultrasound for Earlier Detection of Pediatric Pneumonia**
John H. Priester, Prasanna Kumar, Jesse Naumann, Katherine Dolbec, Peter Weimersheimer, Christian D. Pulcini
- 308 **Painful Enlarging Cervical Mass in Young Male**
Jacob Lawing, Jeremy Towns, Matthew A. Heimann
- 311 **Atraumatic Infected Septal Hematoma in a Pediatric Patient**
Osher Shefer, Jacqueline Le, Eshaan Daas, Eugene Hu
- 314 **Brugada Syndrome and Sudden Cardiac Death: An Electrocardiographic History**
Mark L. Moubarek, Gordon X. Wong, James S. Ford

Policies for peer review, author instructions, conflicts of interest and human and animal subjects protections can be found online at www.westjem.com.

CPC*EM* Clinical
Practice
& Cases

CALL FOR CPC-EM SECTION EDITORS!

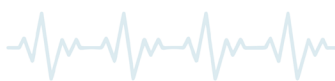- Medical-Legal Case Reports
- Case Reports/Images in
Emergency Medicine

**Send your CV and letter of interest to
editor@cpcem.org**

**Clinical Practice and Cases in
Emergency Medicine (CPC*EM*) is
now indexed on Scopus – Elsevier's
Abstract and Citation Database!**



CPC*EM* Clinical
Practice
& Cases



PubMed[®]

Also indexed in PubMed and PubMed Central

Call for Section Editors

- Behavioral Emergencies
- Cardiac Care
- Geriatrics
- Musculoskeletal
- Trauma
- Toxicology
- Legal Medicine

WestJEM Integrating Emergency Care
with Population Health
westjem.org

Send CV and letter of interest to
Editor@WestJEM.org

CALL FOR REVIEWERS!

WestJEM Integrating Emergency Care
with Population Health
westjem.org

CPCEM Clinical
Practice
& Cases

Send CV and letter of interest to
editor@cpcem.org

A 77-Year-Old Male with a Rapid Change in Mental Status

Andrew Piner, MD*
Spencer S. Lovegrove, MD†
Laura J. Bontempo, MD, MEd†
T. Andrew Windsor, MD†

*University of Maryland Medical Center, Baltimore, Maryland
†University of Maryland School of Medicine, Department of Emergency Medicine,
Baltimore, Maryland

Section Editor: Joel Moll, MD

Submission history: Submitted January 17, 2024; Revision received March 25, 2024; Accepted April 4, 2024

Electronically published June 14, 2024

Full text available through open access at http://escholarship.org/uc/uciem_cpccm

DOI: [10.5811/cpcem.7213](https://doi.org/10.5811/cpcem.7213)

A 77-year-old male who presented to the emergency department with generalized weakness and worsening chronic dysphagia was diagnosed with pneumonia. Shortly after receiving vascular access for his treatment, he had a rapid change in his mental status and neurological examination. [Clin Pract Cases Emerg Med. 2024;8(3)182–188.]

Keywords: *air embolism; stroke; CPC.*

CASE PRESENTATION (DR. PINER)

A 77-year-old male presented to the emergency department (ED) for generalized weakness as well as worsening chronic dysphagia. He was accompanied by his wife, who assisted in providing the history. His past medical history included diabetes, hypothyroidism, a thyroid goiter, right internal jugular (IJ) thrombus for which he was taking anticoagulation, and cirrhosis. His surgical history was significant for remote bilateral percutaneous nephrostomy tube placement, years prior. Three weeks preceding this hospital visit, he had been admitted and discharged from the same hospital after receiving a thoracentesis with drainage of a simple transudative pleural effusion. This incompletely relieved his hypoxia, and he was discharged on three liters per minute (L/min) of oxygen via nasal cannula.

Since returning home, the patient thought his breathing had slightly improved, but he had difficulty completing his daily activities. He had a poor appetite and when he did eat, he experienced dysphagia from his goiter, which he felt was getting worse. He reported general malaise and chills. He did not feel short of breath on exertion, as he had during his last hospitalization, and he was not experiencing any chest discomfort. He denied any nausea, vomiting, constipation, diarrhea, dysuria, or urinary changes. He was able to ambulate but had difficulty doing so due to his weakness.

The patient was recovering from alcohol use disorder and denied having any alcoholic drinks in multiple years. He had a remote, five pack-year tobacco history but did not smoke any longer. He denied any use of illicit drugs. His wife

oversaw his medications, which had not changed since his hospital discharge. He took metoprolol, spironolactone, levothyroxine, and apixaban. He had no known drug allergies.

The patient's vital signs revealed an oral temperature of 100.4° Fahrenheit (38° Celsius), heart rate of 90 beats per minute, a blood pressure of 90/40 millimeters of mercury (mm Hg), a respiratory rate of 15 breaths per minute, and his oxygen saturation was 94% on 3 L/min via nasal cannula. He weighed 64 kilograms (142 pounds) and was 170 centimeters tall (5 feet 7 inches) with a body mass index of 22.1.

On physical examination, the patient was alert and oriented to person, place, time, and events. He was able to speak in full sentences without dyspnea. He did not appear in acute distress. He had evidence of a large goiter and denied tenderness or the sensation of it expanding or changing. His breath sounds were diminished at the right lower base with scattered rhonchi and an occasional cough. His heart sounds were regular without murmurs, rubs, or gallops. His abdomen was large, protuberant, and had a soft fluid wave that could be appreciated. It was not increased in size per his wife. There was no guarding or tenderness. He had trace pedal edema without lateralizing swelling. He moved all extremities without localizing weakness. Although he reported weakness, his strength was 5/5 symmetrically in his upper and lower extremities. His cranial nerves (CN) II–XII were intact. His Glasgow Coma Scale (GCS) score was 15/15 – Eye 4, Verbal 5, Motor 6. His pupils were equal, round, and reactive to light. He was not ambulated in the

Table. Initial laboratory results of a 77-year-old man with a rapid change in mental status.

Test name	Patient value	Reference range
Complete blood count		
Hemoglobin	10.4	11.9–15.7 g/dL
Hematocrit	32.3	35.0–45.0%
White blood count	18.2	4.5–11 K/mcL
Platelet	187	153–367 K/mcL
Neutrophils	72.5	42.6–74.5%
Lymphocytes	10.3	20.8–50.5%
Monocytes	16.2	2.0–10.3%
Eosinophils	0.2	0.9–2.9%
Complete metabolic panel		
Sodium	132	136–145 mmol/L
Potassium	4.0	3.5–5.1 mmol/L
Chloride	102	98–107 mmol/L
Bicarbonate	24	21–30 mmol/L
Glucose	147	70–99 mg/dL
Blood urea nitrogen	21	7–17 mg/dL
Creatinine	0.74	0.52–1.04 mg/dL
Calcium	7.8	8.6–10.2 mg/dL
Magnesium	1.5	1.6–2.6 mg/dL
Phosphorus	2.9	2.5–4.5 mg/dL
Total protein	5.2	6.3–8.2 g/dL
Total bilirubin	1	0.3–1.2 mg/dL
Aspartate aminotransferase	46	14–36 units/L
Alanine aminotransferase	21	0–34 units/L
Alkaline phosphatase	82	38–126 units/L
Coagulation		
Protime	15.9	12.1–15.0 seconds
International normalized ratio	1.3	0.8–1.1
Partial thromboplastin time	45	25–38 seconds
Fibrinogen	280	200–400 mg/dL
Thyroid		
Thyroid stimulating hormone	0.01	0.4–4 mIU/L
Free Thyroxine	6.6	0.8–1.8 ng/dL
Additional tests		
Lactate	1.7	0.5–2.2 mmol/L
Ammonia	9	9–30 mcmol/L
Troponin I	0.02	<0.06 ng/mL

dL, deciliter; g, grams; K, thousands; mcL, microliter; mcmol, micromole; mg, milligram; mIU, milli-international units; mmol, millimole; ng, nanogram; L, liter.

Population Health Research Capsule

What do we already know about this clinical entity?

Air embolism is a rare but potentially life-threatening complication of various procedures, including central line placement.

What makes this presentation of disease reportable?

This patient experienced a cerebral air embolism but did not have a patent foramen ovale, and the air embolism remained within the venous system.

What is the major learning point?

Although rare, clinicians should consider air embolism for a patient who has an unexpected decline in their condition shortly after an intravascular procedure.

How might this improve emergency medicine practice?

This case discusses treatment of this serious condition, including bedside treatment and hyperbaric oxygen therapy.

room but had been seen earlier moving from a hospital wheelchair to the stretcher with assistance. There was no skin rash or joint swelling.

Initial laboratory results are shown in [Table](#). An electrocardiogram (ECG) was performed and showed a sinus rhythm without ectopy or ST-segment changes and was unchanged from his previous hospitalization. Chest radiography (CXR) was obtained, shown in [Image 1](#). The radiologist's interpretation was "[p]atchy opacity in the right lower lobe suggestive of pneumonia in the correct clinical setting. Goiter redemonstrated when compared to previous. Normal cardiac findings." A point-of-care ultrasound (POCUS) of the heart showed no pericardial effusion, no suggestion of right ventricle strain, no volume overload, and a normal left ventricle.

Before treatment for pneumonia could be started, the nurse alerted the physician to the loss of vascular access. There were no reliable peripheral veins seen via ultrasound; so, central access was obtained in the left IJ vein via ultrasound guidance while the patient was in a semi-reclined position. The wire was confirmed in the vein and removed. The physician instilled a bolus of agitated normal saline, confirming the central access was in the venous system by

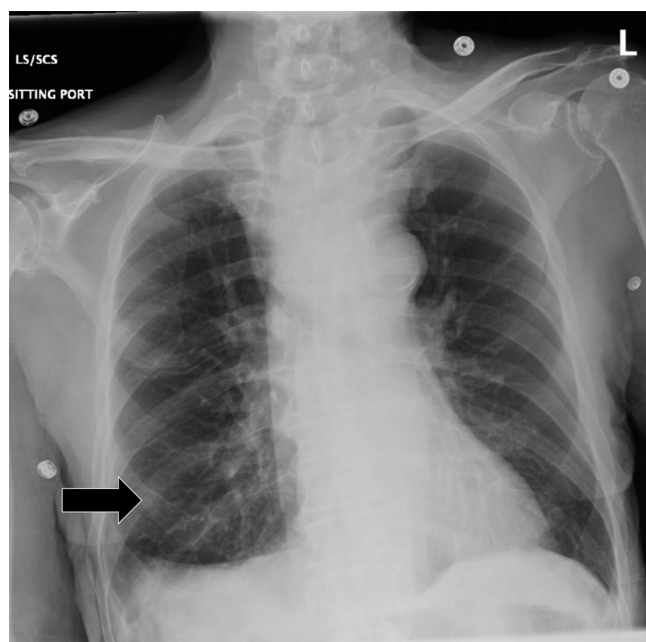


Image 1. Initial chest radiograph showing an opacity in the right midlung (black arrow) in a 77-year-old man before he experienced a rapid change in mental status.

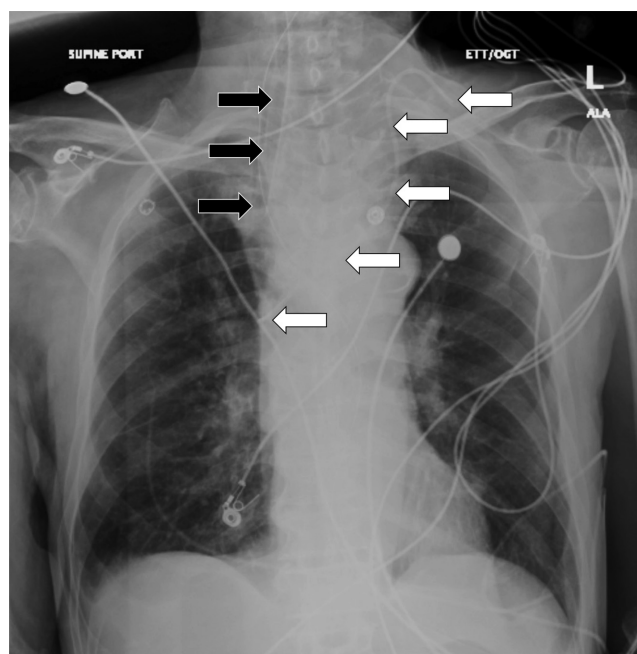


Image 2. Repeat chest radiograph of a 77-year-old man after a rapid change in mental status showing the placement of an endotracheal tube (black arrows) and left internal jugular central line (white arrows).

visualizing turbulent flow in the right atrium with POCUS. The line was sutured and dressed.

Fifteen minutes later, the physician was called to the room as the patient's oxygen requirement increased and he was less responsive. Repeat physical examination revealed new tachycardia with a mean arterial pressure of 59 mm Hg. The patient's respiratory rate was 20, and his oxygen saturation remained 94% on 15 L/min via a non-rebreather mask. Repeat POCUS showed unchanged cardiac function and no evidence of pneumothorax. The patient was unable to follow commands, his eyes opened only to pain, and he muttered incomprehensible words. He was noted to withdraw to pain on the right arm and leg, the left arm was flaccid, and the left leg was flexed. His new GCS was 8/15 – Eye 2, Verbal 2, Motor 4. His left eye was midline, but his right eye was noted to deviate laterally and inferiorly.

The patient was intubated, and a confirmatory CXR demonstrated interval changes of a new left IJ central line catheter and an endotracheal tube that both appeared adequately positioned as seen in [Image 2](#).

A test was performed, and a diagnosis was made.

CASE DISCUSSION (DR. LOVEGROVE)

This is a case of an elderly gentleman who acutely decompensated in the ED after initially presenting due to worsening weakness and dysphagia. When there is a patient who acutely decompensates in the ED, as this patient did, it is important to consider whether this was the result of the

patient's natural disease course, something that happened in the ED (iatrogenic), or even a little bit of both.

The patient's initial complaint is worsening dysphagia as well as weakness. He has an extensive medical history that includes diabetes, hypothyroidism, goiter, right IJ thrombus, and anticoagulant use. His physical exam is notable for multiple abnormalities including fever, hypotension, abnormal breath sounds in his right lung, and ascites. It is also important to point out that his neurologic exam is normal, including full strength in all extremities.

Looking over the labs and imaging, I do not believe they provide a significant amount of new information but could be used to remove some differentials. The patient's chemistry had some slight abnormalities but nothing unexpected given his comorbidities. His coagulation studies were consistent with someone with cirrhosis. There were some abnormalities in his thyroid function panel, but I do not think they explain his acute change. We also do not know the timing of his levothyroxine dose, and his thyroid stimulating hormone indicates that he has likely been taking it. The etiology of hematuria is unclear, but his urine is otherwise without any sign of infection. His complete blood count does show leukocytosis as well as mild anemia. Lastly, his CXR is subtle, but an opacity in the right midlung, as interpreted by radiology, would be consistent with his abnormal breath sounds.

Based off the history, physical exam, and diagnostic studies, the patient's initial presentation was concerning for

sepsis, potentially from pneumonia associated with aspiration or due to spontaneous bacterial peritonitis (SBP). However, I do not believe these issues alone would necessarily progress to cause such an abrupt change in mental status and neurologic function. Was his dysphagia being caused simply by mass effect of his goiter, or was it something else? Could there be another underlying etiology that was exacerbated by the patient's septic state?

Once he decompensated, his exam changed, and the differential expanded. He now had a GCS of 8 with gaze deviation of his right eye "down and out" to the right, but his left pupil is midline. He also had a flaccid left arm and his left leg remained flexed. His right arm and leg withdrew to pain. I considered the following differentials, grouped by category, based off his initial presentation and chief complaint as well as the events of his ED visit, as it is unclear whether they are related.

Autoimmune: For a potential autoimmune cause, I did consider potentially undiagnosed myasthenia gravis (MG). He had a known history of goiter and thyroid disease, which does have an association with developing MG. Patients with MG can present with asymmetric muscle weakness that commonly involves the extraocular muscles. Asymmetric presentations can mimic a stroke. Perhaps his worsening dysphagia and weakness were being caused by MG, and he rapidly deteriorated in the ED due to his sepsis. He may have had unrecognized respiratory muscle compromise and may have become hypercapnic, causing his altered mental status. This is unlikely since he had no evidence of any weakness on his initial exam, but it could not readily be ruled out by the results I was given, so I kept it on the differential.

Infectious: As we discussed earlier, it is possible that he has pneumonia or SBP; however, I do not think they would cause these focal neurologic abnormalities. His blood pressure is on the lower end, potentially due to sepsis, but I do not believe he would have suffered a watershed infarct causing these specific abnormalities. Similarly, I considered meningitis or encephalitis due to his fever and altered mental status, but again I do not think they explain his rapid deterioration and focal deficits. He also did not complain of any neck pain or headache prior to his decompensation.

Cardiac: Arrhythmia is always a potential cause of acute decompensation. I would have loved to have seen a repeat ECG or rhythm strip at the time of decompensation, but there was no mention of him being particularly tachycardic or bradycardic with his repeat vitals, so I feel this is unlikely. I considered the possibility of acute heart failure or cardiac tamponade causing hypotension and subsequent poor cerebral perfusion and altered mental status, but the point-of-care echocardiogram remained essentially normal.

Pulmonary: I considered pneumothorax as a complication of central line placement as a cause of the acute respiratory decompensation; however, this was not

seen on CXR after placement, and it should not cause focal neurologic deficits.

Endocrine/metabolic: Hypoglycemia and hyponatremia can both cause acute altered mental status; however, the patient's labs showed no evidence of hyponatremia or hypoglycemia, and the treatments he received in the ED should not have caused them. Uremia and hyperammonemia were ruled out in his chemistry panel. I considered thyroid storm due to his fever and elevated free T4; however, this patient's T4 is presumably coming from his levothyroxine. Without acute changes to his regimen or suspected overdose of his medications, I felt this was unlikely.

Toxicological: There is no history of abnormal exposures. He was started on antibiotics, as well as norepinephrine. Some antibiotics, such as cefepime, can produce neurologic abnormalities such as seizures, but it would be unlikely to occur this rapidly after initial administration. He also presumably received lidocaine as part of his central line placement. Lidocaine toxicity can cause altered mental status and seizure. Often, when administered as part of central line placement, about 5–10 milliliters (mL) of 1% lidocaine is used, and precautions are taken to avoid vascular injection. This dosage should not be high enough to cause acute lidocaine toxicity.

Hematologic: I did consider thrombotic thrombocytopenic purpura (TTP) as a potential cause. Infection can prompt the development of TTP and could potentially explain the patient's neurologic deficits hematuria and proteinuria. However, I eliminated this from the differential as he had only mild anemia and no significant thrombocytopenia or evidence of renal failure.

Neurologic: The patient's acute abnormalities that developed in the ED were primarily neurologic, which means this is the organ system I considered the most heavily. The new physical exam is interesting because classically in a hemispheric stroke there is conjugate gaze deviation, with both eyes looking toward the lesion. In seizure, the conjugate gaze deviation is classically away from the lesion. The disconjugate gaze, as well as the left arm weakness involving the opposite side as the gaze deviation, led me away from a large hemispheric ischemic or hemorrhagic stroke. While considering diagnoses that could cause unilateral gaze deviation, I again considered muscular weakness being caused by a disorder at the neuromuscular junction, such as MG; however, I also considered ischemic or compressive lesions to CN III. Cavernous sinus thrombosis has been known to cause isolated cranial nerve palsies, including CN III, IV, V, and VI. This patient did have a history of thrombosis with a previous IJ thrombus, but he was currently taking an anticoagulant and had not been complaining of headache.

The patient's symptoms were fairly consistent with a stroke in the midbrain and Weber syndrome, which is described as having an ipsilateral CN III palsy with

contralateral hemiplegia. However, those patients generally have a relatively normal mental status, whereas our patient had a GCS of 8. It could be possible that he had multiple areas of infarct or disease that are making it difficult to pinpoint the exact location of his lesion or lesions.

After considering these differentials and the results that were available, I ultimately narrowed the differential down to three final diagnoses. An undiagnosed neuromuscular junction disorder, such as MG, would potentially explain his multiple deficits and incorporate his original chief complaint. My last two differentials are similar in that they are both iatrogenic and related to his central line placement involving different types of emboli. He decompensated shortly after the placement of the line; so, a potential iatrogenic cause needed heavy consideration.

He had a known history of prior right IJ thrombus; so, perhaps a central line was placed through a new, undiagnosed left-sided IJ thrombus and caused a shower of embolic thrombi. However, for this to have caused a stroke instead of a pulmonary embolism, he would have also needed to have a patent foramen ovale to allow shunting to the arterial circulation. If the clinician used ultrasound during the placement of the central line and the patient has been taking his anticoagulation, hopefully placement through a thrombus would have been avoided. This right-to-left cardiac shunting could also have been detected during the bolus of agitated saline visualized for line confirmation on point-of-care echocardiogram, and there was no mention of this.

For my final differential, I considered air embolism. A shower of air emboli to the midbrain, as well as multiple other areas of the brain, could explain his focal neurologic deficits as well as his suppressed mental status. This is a rare but possible complication of central line placement, and retrograde venous flow of air is possible due to buoyancy if the patient is upright. It was noted that the patient was semi-reclined during placement, rather than in the preferable Trendelenburg position, which can be protective against air embolus. Like a thrombus, air emboli could also be transmitted to the arterial circulation if this patient had an undiagnosed patent foramen ovale.

Ultimately, I did not choose undiagnosed MG since his initial strength testing was completely normal. With the patient already taking anticoagulation, a new thrombus is less likely; so, I opted to choose air embolism as my final diagnosis as it makes the most sense with the timing after central line placement and the multiple different neurologic deficits. My test of choice from the ED would be computed tomography (CT) of the head.

CASE OUTCOME (DR. PINER)

The patient underwent an emergent CT of the head (Image 3) due to the change in mental status. The radiology impression of the CT revealed “extensive venous gas, which

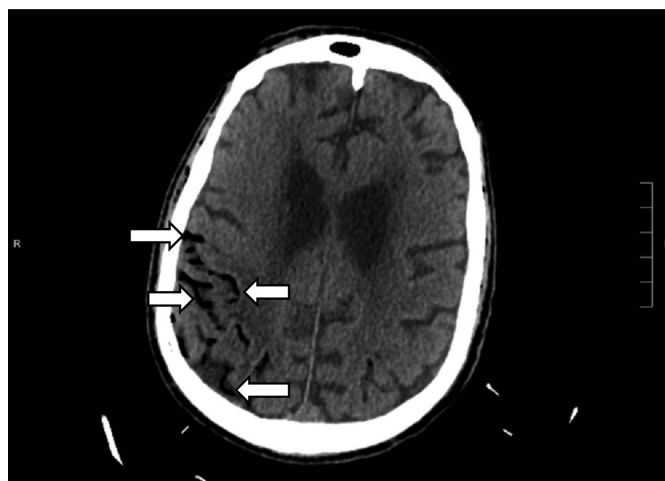

Image 3. Computed tomography of the brain of a 77-year-old man after a rapid change in mental status showing extensive venous gas (white arrows) in the right parieto-occipital region.

may indicate gas embolus with possible evolving infarction in the right parietal region. No hemorrhage or shift. Further evaluation with magnetic resonance imaging [MRI] may be useful. Large goiter.” Immediately the team assessed the patient’s central venous catheter and found an uncapped line. After the air was withdrawn from the line, the line was capped. The patient was transferred to the intensive care unit at our hospital for further management and a hyperbaric medicine consultation. He underwent a hyperbaric oxygen therapy treatment with resolution of the gas on the repeat CT head. A follow-up MRI revealed multifocal infarcts in multiple vascular territories.

In the following days, the patient’s mental status unfortunately never improved. Palliative care discussions with the patient’s family indicated that he would not want to have any further artificial prolongation of life without any meaningful neurologic functioning, and the team transitioned his care to comfort measures only. He was transferred to hospice care and died surrounded by his family.

RESIDENT DISCUSSION (DR. PINER)

Air embolism represents a rare phenomenon when air enters either arterial or venous circulation with subsequent obstruction of the vasculature, preventing distal blood flow. The condition requires that there be a direct connection between the vasculature and the gas source. This can be due to vascular trauma prompting gas entry or direct entry from placement of an intravascular catheter. Many of the cases of air embolism involve a preventable iatrogenic process, prompting the Centers for Medicare and Medicaid Services at one point to classify it as a “never event” along with other preventable conditions such as falls, retained surgical objects, and incompatible blood transfusion.¹

The rate of air embolism following a central line manipulation (insertion, drug delivery, or removal) is estimated to be between 0.3–2%.² Considering how commonplace central access insertion is, this could involve a significant level of morbidity and mortality. However, not all cases of air embolism are as dramatic or symptomatic as in this case. Most air emboli will be asymptomatic and unrecognized, as their volume and rate of accumulation may be miniscule. The lethal dose depends on location of the obstruction, volume, and rate of administration, but lethal doses range between 3–5 milliliters (mL) per kilogram or about 200–300 mL in adults.³

Other etiologies of air embolisms involve blast injuries, barotrauma, and direct vascular trauma. Surgery has been associated with air embolism, particularly neurosurgery, where the incidence of air embolism has been reported to be higher when the patient was undergoing an open craniotomy in a seated or semi-seated position.⁴

The key for air embolism is prevention. This is particularly important to remember when obtaining vascular access, manipulating existing catheters, or other high-risk surgical procedures. High-risk vascular access involves large-bore catheters, emergent placement, access site above the level of the heart, and pressure-infused fluids (eg, arterial line or rapid infusion machine). Care can be taken to properly position patients when placing catheters and placing the vascular access point at or above the level of the heart. Lines should be immediately capped or clamped to prevent direct air entry. Although debated, asking your patient to exhale during removal may prevent negative intrathoracic pressure, which enhances venous return and can pull air in if there is an entry portal. Additionally, pressure should be held after the catheter is removed in all cases.⁵

Prompt recognition is crucial for treatment. Diagnosis should be made rapidly by first having a high index of suspicion and then followed by treatment. The location in the arterial or venous system, amount of gas, and the organ affected will dictate the management, as well as the signs and symptoms guiding the workup.

If the air embolism occurs in the pulmonary system, it could be expected to behave like a thrombotic pulmonary embolism. However, if there is a connection between the venous/arterial side, as in the context of a patent foramen ovale, then venous gas could traverse and cause symptoms of arterial ischemia. Our patient had cerebral venous gas, likely as a result of retrograde flow with the patient in an upright position.

A POCUS can be performed to look for a gas bubble in the right ventricle as well as alternative explanations for the change in a patient's hemodynamics (for example, pneumothorax or pericardial tamponade). Transesophageal echocardiogram (TEE) is more sensitive for detection; however, there is limited access to this method, and it may be more applicable in the operating room. Some high-risk

procedures use a TEE intraoperatively to proactively monitor for such events. Diagnostic measures should be ordered based on the site of the suspected embolism. These may commonly include a troponin, ECG, lactate, or renal function. Imaging will help confirm the diagnosis; CT angiography is the most likely diagnostic modality, although air can sometimes be seen on plain films.

If an air embolism is suspected, the site of air entry should be covered if open, pressure held, and any offending actions (line insertion, insufflation, pressure infusion) should be stopped. The next step involves positioning the patient to trap gas in the venous system and prevent it from causing complete cardiovascular collapse in the form of an air trap. The patient should be placed in the left lateral decubitus position in the Trendelenburg position (head down). This is called the Durant maneuver. This allows for blood to still pass into the pulmonary artery while displacing and hopefully trapping the air bubble away from the right ventricular outflow tract. It also prevents right-to-left traversing of the gas bubble.⁵

Treatment involves supportive care of the organ affected. Supplemental oxygen should be applied via a non-rebreather mask. If an air embolism is suspected and there is a central catheter in the superior vena cava, then one can attempt to aspirate blood from the distal tip in hopes of suctioning the air embolism.

If these measures fail to alleviate the cardiovascular collapse, then venous-arterial extracorporeal membrane oxygenation could provide rescue therapy as a bridge to definitive care. Interestingly though, this procedure itself has a high risk of causing an air embolism if there is any air in the catheters when they are hooked to the circuit. The gold standard involves hyperbaric oxygenation therapy with earlier treatment preferred; however, cases have been successfully treated after 24 hours of symptoms, as the availability of dive resources may vary widely among institutions and involve prolonged and careful transport.⁶

FINAL DIAGNOSIS

Cerebral air embolism secondary to central line complication.

KEY TEACHING POINTS

- Rapid changes in a patient's clinical stability may be related to progression of the known presenting disease or a new process entirely.
- Central venous catheter placement is not a benign procedure, and given its frequent use, care should be taken to avoid complications.
- Cerebral air embolism is caused by air entry directly into the vascular space, which may present as a change in a patient's neurological examination.

- Prevention is key for air embolisms; however, if one occurs then oxygen, Durant maneuver, and hyperbaric therapy are the cornerstones of therapy.

The authors attest that their institution requires neither Institutional Review Board approval, nor patient consent for publication of this case report. Documentation on file.

Address for Correspondence: T. Andrew Windsor, MD, University of Maryland School of Medicine, Department of Emergency Medicine, 110 S Paca St., 6th Floor, Suite 200, Baltimore, MD 21201. Email: awindsor@som.umaryland.edu

Conflicts of Interest: By the CPC-EM article submission agreement, all authors are required to disclose all affiliations, funding sources and financial or management relationships that could be perceived as potential sources of bias. The authors disclosed none.

Copyright: © 2024 Piner et al. This is an open access article distributed in accordance with the terms of the Creative Commons

Attribution (CC BY 4.0) License. See: <http://creativecommons.org/licenses/by/4.0/>

REFERENCES

1. Mattie AS and Webster BL. Centers for Medicare and Medicaid Services' "never events": an analysis and recommendations to hospitals. *Health Care Manag (Frederick)*. 2008;27(4):338–49.
2. Arcinas LA, Liu S, Schacter GI, et al. Cerebral air embolism following central venous catheter removal. *Am J Med*. 2017;130(12):e549–50.
3. Toung TJ, Rossberg MI, Hutchins GM. Volume of air in a lethal venous air embolism. *Anesthesiology*. 2001;94(2):360–1.
4. Giraldo M, Lopera LM, Arango M. Venous air embolism in neurosurgery. *Rev Col Anest*. 2015;43(Supp 1):40–4.
5. McCarthy C, Behraves S, Naidu S, et al. Air embolism: practical tips for prevention and treatment. *J Clin Med*. 2016;5(11):93.
6. Murphy R and Donnellan J. A high-pressure solution for a high-pressure situation: management of cerebral air embolism with hyperbaric oxygen therapy. *Cureus*. 2019;11(9):e5559.

Pneumothorax Identified by a Remote Physician Using Paramedic-obtained Tele-ultrasound: Case Report

Shriman Balasubramanian, DO, MSc*
Michael DeFilippo, DO*
Michael Stone, MD*
Gabriela Galli, MD*
Matthew McCarty, MD†
Brock Daniels, MD, MAS, MPH†

*New York Presbyterian Hospital Cornell and Columbia, Department of Emergency Medicine, New York

†Weill Cornell Medicine, Department of Emergency Medicine, New York

Section Editor: Christopher Sampson, MD

Submission history: Submitted April 23, 2023; Revision received September 20, 2023; Accepted October 6, 2023

Electronically published June 3, 2024

Full text available through open access at http://escholarship.org/uc/uciem_cpchem

DOI: [10.5811/cpcem.1296](https://doi.org/10.5811/cpcem.1296)

Introduction: The use of telemedicine and ultrasound is emerging and novel in the field of community paramedicine. However, there is a paucity of data supporting its use and even less evidence that shows a morbidity and mortality benefit. This case highlights a unique way to diagnose a common medical emergency, which can lead to a good outcome.

Case Report: We describe the use of lung point-of-care ultrasound by a trained community paramedic that led to the identification of a pneumothorax in an 86-year-old male at a scheduled home visit. The images were interpreted over telehealth in real-time by an emergency physician, and the patient was transported to the emergency department where the diagnosis was confirmed by chest radiography. He underwent chest tube placement and was discharged five days later after returning to his baseline.

Conclusion: Despite minimal data to support or refute the use of paramedic tele-ultrasound, this case highlights a unique opportunity to expand the use of telemedicine and ultrasound in community paramedicine to improve patient outcomes. [Clin Pract Cases Emerg Med. 2024;8(3)189–193.]

Keywords: telehealth; case report; community paramedicine; pneumothorax; point-of-care ultrasound.

INTRODUCTION

With the emergence of telemedicine and ultrasound use combined with community paramedicine, health systems are finding novel ways to diagnose and treat both common and unusual diseases. However, evidence is still sparse regarding the use of telehealth and ultrasound by paramedics. This case report highlights a novel use of ultrasound by a community tele-paramedic program (CTP) to diagnose a pneumothorax in the prehospital setting and refer the patient to emergency care, leading to a good outcome.

A pneumothorax occurs when air accumulates between the parietal and visceral pleura inside the chest wall, causing the lung parenchyma to collapse.¹ It can be either traumatic or atraumatic and is further classified as simple, tension, or open. Atraumatic pneumothorax is either primary, occurring

without an inciting event, or secondary as in the setting of pulmonary disease.^{1,2} Traumatic pneumothorax is seen in 20% of blunt chest trauma, and up to 40% of penetrating trauma.² Patients can be asymptomatic or present with shortness of breath, chest pain, tachycardia, decreased breath sounds, jugular venous distention, hypotension, cyanosis, and cardiac arrest.¹

While computed tomography (CT) remains the gold standard of diagnosis (despite some debate), the diagnosis can also be made with ultrasound or with chest radiography.³ Ultrasound has a 94% sensitivity and up to a 100% specificity depending on the operator.² Ultrasound findings include a loss of lung sliding in B-mode and the presence of a “barcode sign” on M-mode, signifying the loss of pleural movement.² Chest radiography and CT findings include space between

the pleura and chest wall.³ The differential diagnosis often includes cardiac tamponade, aortic dissection, rib fracture, acute coronary syndrome, pulmonary embolism, and pneumonia.¹ Management depends on the severity of pneumothorax and can include the following: needle decompression, finger thoracostomy, pigtail thoracostomy, and large-bore tube thoracostomy.

The uniqueness of this case revolves around the method of diagnosis. The case patient was enrolled in a CTP program, which is part of a large, urban academic emergency department. Patients are jointly evaluated by community paramedics (CP) on scene as well as by an emergency physician (EP) over video conference. These paramedics underwent a one-hour long training session in lung point-of-care-ultrasound (POCUS) using the Butterfly iQ (Butterfly Network, Burlington, MA) connected to a mobile device. Images were obtained by the CP crew using the “lung” preset of the device, with the probe marker pointing superiorly, and interpreted in real-time by the EP over the telehealth platform. While some studies have reported the feasibility of teaching emergency medical services (EMS) professionals how to obtain and read POCUS images, there is a paucity of data regarding the regular use of POCUS in the prehospital setting and even fewer involving live image interpretation by an EP.⁷

CASE REPORT

This case highlights an 86-year-old male who was being followed closely by the CTP program of an urban, academic hospital-based EMS system. His medical history included Parkinson disease, stroke, peripheral neuropathy, atrial fibrillation status-post multiple ablations, direct-current cardioversion, and implantation of a Watchman device, sick sinus syndrome status-post automatic implantable cardioverter defibrillator placement, congestive heart failure, chronic obstructive pulmonary disease (COPD), and frequent falls requiring multiple hospitalizations. He presented at a routine home visit complaining of left rib pain and shortness of breath after a fall two days prior. Of note, a month before this visit he had been hospitalized for a fall and declined the recommended subacute rehabilitation placement. The only home care services he received at the time were weekly CTP visits.

During his initial evaluation by paramedics he denied other complaints. Initial vitals were pulse 65 beats per minute, blood pressure 122/77 millimeters of mercury, pulse oximetry 100% on room air, temperature 36.6° Celsius, and respirations 19 breaths per minute. His physical exam was significant for lethargy, although he was easily arousable to voice; left-sided chest wall tenderness to palpation; bruising; crepitus; decreased left breath sounds; and bilateral lower extremity pitting edema. Paramedics obtained bilateral anterior views of the lung (Image 1a), and images were interpreted in real-time by the physician via a video

Population Health Research Capsule

What do we already know about this clinical entity?

Computed tomography is generally considered the gold standard for diagnosis of a pneumothorax.

What makes this presentation of disease reportable?

Using real-time video, an emergency physician diagnosed a pneumothorax by interpreting ultrasound images obtained by the paramedic on scene.

What is the major learning point?

The clinician's telehealth consult with the paramedic on scene demonstrates a novel solution to diagnosing conditions where time to diagnosis affects outcomes.

How might this improve emergency medicine practice?

Emergency physicians will be able to diagnose and treat patients earlier, potentially leading to improved patient outcomes.

telehealth platform. The EP noted the absence of lung sliding in the left inferior lung field (Image 1b).

The patient was placed on 100% oxygen via non-rebreather mask and transported to a local emergency department (ED). Upon arrival at the ED he denied new complaints, and his vitals and physical exam were not significantly changed. His electrocardiogram (ECG) showed an atrial sensed paced rhythm consistent with prior ECGs. He had a chest radiograph (CXR) showing left fifth and sixth rib fractures with a moderate circumferential pneumothorax (Images 2 and 3).

He additionally had non-contrast CTs of the head and cervical spine showing interval resolution of prior subdural and subarachnoid hemorrhages without any acute findings. Serum complete blood count, chemistry panel, cardiac biomarkers, and coagulation profile were unremarkable. He was continued on 100% oxygen via a non-rebreather mask. Tube thoracostomy placement in the ED was deferred due to the patient's clinical stability, presence of bilateral pleural effusions, and absence of a safe window to place a chest tube on ultrasound. The patient was admitted to the surgical service. On hospital day one, a repeat CXR showed an unchanged pneumothorax. He underwent an interventional radiology CT-guided pigtail thoracostomy placement.

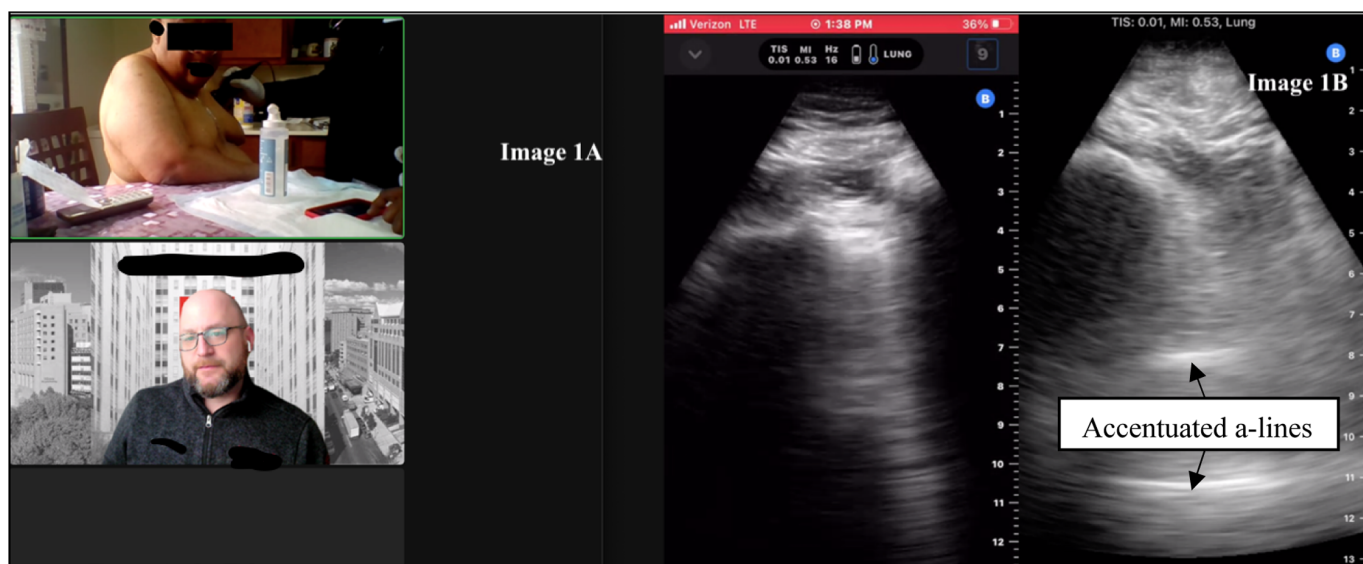


Image 1. (A) Example of a community tele-paramedic visit with video conference and screen sharing using mobile ultrasound. The patient is seen at the top, and the emergency physician is seen on the bottom screen. (B) The case patient's b-mode lung point-of-care ultrasound, showing accentuated a-lines, loss of b-lines, and in real-time video without lung sliding (not pictured here).

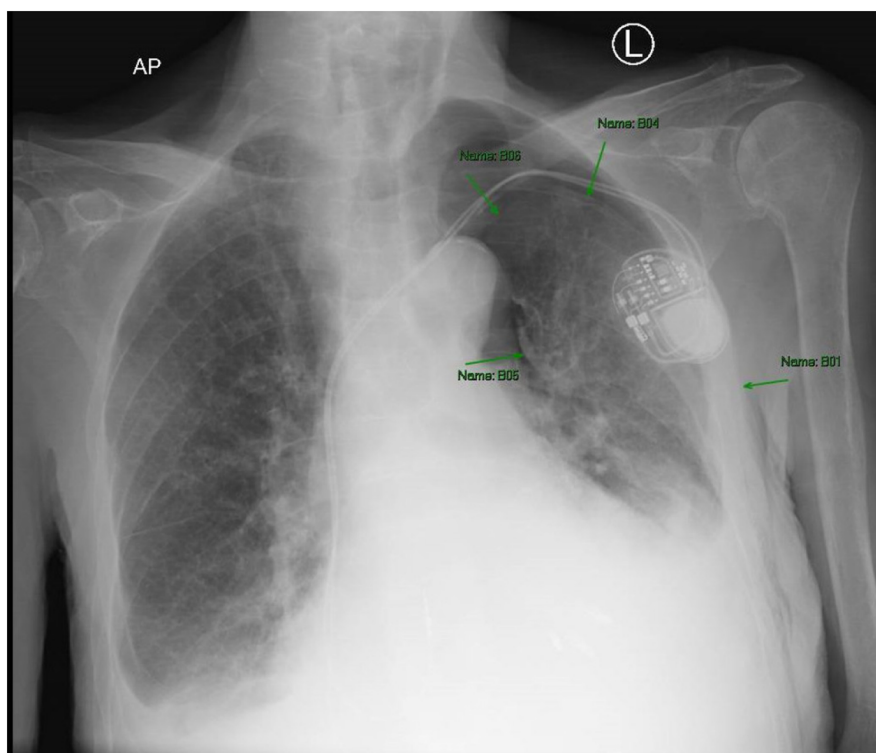


Image 2. Chest radiograph with arrows pointing to left-sided moderate circumferential pneumothorax. There is a loss of symmetry, a visible lung border, and loss of lung marking superior to the lung border.

On hospital day three, the chest tube was clamped and subsequently removed. He was recommended for subacute rehabilitation; however, both the patient and family declined. He was discharged home on hospital day five with

continued weekly follow up with the CTP program, visiting nurses, and home physical therapy.

The patient was seen with family by his primary care physician three days after hospital discharge. Home safety

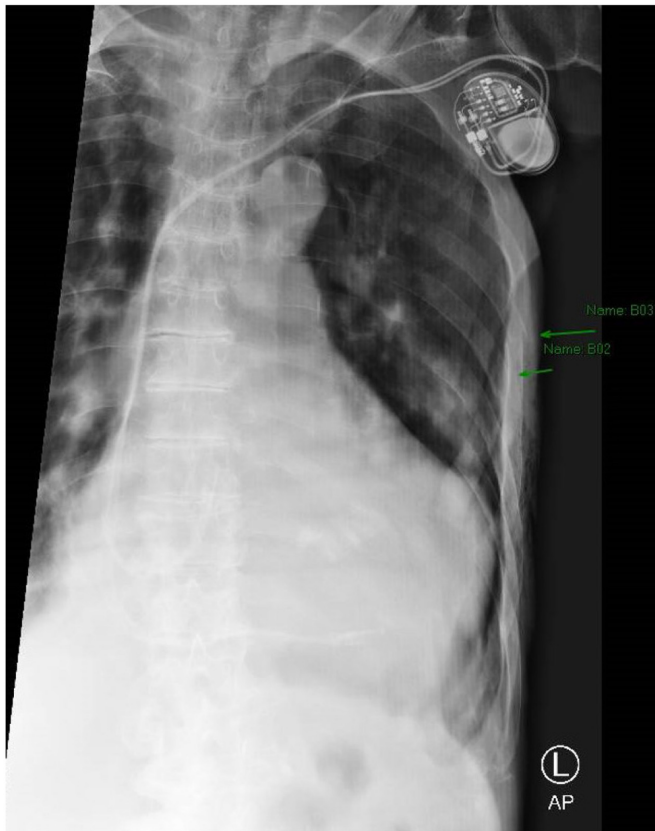


Image 3. Magnified view of the chest radiograph demonstrating fractures of ribs five and six (arrows).

concerns were addressed, fall prevention teaching was given, and the patient chose a “do not resuscitate/do not intubate” status. He continues to be followed by the CTP program on a weekly basis, and unfortunately has had a subsequent admission for congestive heart failure exacerbation and two ED visits for falls.

DISCUSSION

Although pneumothorax is not a rare condition and EPs are quite familiar with the diagnosis and treatment, clinicians must be aware of the increasing presence of virtual care and mobile integrated healthcare (MIH). The novelty surrounding this case lies in how the diagnosis was made. The paramedics are part of an EMS division under the department of emergency medicine at a large, urban, academic medical center. They are specially trained as CPs providing scheduled home visits to patients primarily with heart failure. Their role has expanded to include post-ED or post-hospital discharge follow-ups for conditions such as COPD and falls.

While there are national EMS standards on CP training, there are few to no standards regarding the training of EMS professionals in the use of POCUS.⁵ A scoping review regarding educational standards revealed less than 20 review articles, with a consensus showing little-to-no

standardization and no consideration for level of training. However, some studies have shown that after a training program paramedics can accurately acquire and interpret lung POCUS for pneumothorax or tension pneumothorax with similar accuracy to EPs.^{6,7} It should be noted that most of these studies had assessments of simulated patients or patients with a known pneumothorax rather undifferentiated prehospital patients. The results of small pilot studies have suggested that prehospital POCUS performed by paramedics and interpreted via telehealth platform using cellular data has “good” to “very good” quality and that remote lung POCUS is feasible, although further research on reliability and clinical outcomes is needed.^{8,9}

There is a paucity of quality data showing that immediate interpretation of lung POCUS leads to more rapid diagnosis, intervention, and better patient outcomes despite the potential of lung POCUS to positively impact immediate care. In this case we describe a unique method of diagnosis and rapid treatment leading to a positive patient outcome, which may have otherwise been missed leading to clinical decline, significant morbidity or even death if left untreated. This case highlights an opportunity for both EPs and EMS professionals to expand their scope of practice within the prehospital setting. The use of real-time interpretation by an EP over telemedicine (as compared to paramedic-only interpretation or asynchronous store and forward) affords the opportunity to guide image acquisition for less-experienced ultrasonographers and in cases of difficult patient windows, while providing additional clinical context to the EP reading the images. Overall, this has the potential to effectively triage patients to appropriate dispositions starting from very early on in their care.¹⁰

One limitation is the small body of literature evaluating whether early lung POCUS read by an EP improves clinical outcomes. This case report highlights the need for further implementation studies to better understand the risks and benefits of POCUS in the remote management of patient populations living with chronic illness such as heart failure and COPD where rapid evaluation and differentiation of the many causes of dyspnea at the patient’s side can be valuable for determining the most appropriate treatment and level of care.

With the case report we also sought to increase EP awareness of the possibility of prehospital use of POCUS. A needs assessment at our institution suggests that while EPs involved in the remote management of medically complex patients through MIH programs believe remote lung ultrasound is valuable, most were not aware it was available, safe, or effective. However, the data referred to above suggests that with the right training, paramedics are able to obtain ultrasound images. As emergency medicine expands to involve mobile integrated healthcare and virtual care, we believe EPs can expect to see that patient assessments by paramedics include POCUS images to interpret.

CONCLUSION

This case of community tele-paramedicine use of lung POCUS read by an EP as a pneumothorax shows both the diagnostic diversity of pneumothorax and the feasibility of EMS professionals using POCUS to advance patient care. It is important to recognize a pneumothorax and treat it early to prevent progression to tension physiology. By partnering with EMS, we may be able to identify this diagnosis and initiate emergent treatment early on. Emergency physicians should be aware of the growing prevalence of prehospital ultrasound and its utility in the diagnosis of common lung pathology.

ACKNOWLEDGMENTS

We would like to acknowledge Elisa Aponte MD, Sophia Lin, MD, and Rahul Sharma, MD, from the Department of Emergency Medicine at New York Presbyterian Weill Cornell Medicine for their hard work in the Community Tele-paramedicine Program. With their efforts, the department is able to provide valuable services to high-risk patients and valuable research to better help the community.

The authors attest that their institution requires neither Institutional Review Board approval, nor patient consent for publication of this case report. Documentation on file.

Address for Correspondence: Shriman Balasubramanian, DO, MSc, New York Presbyterian Hospital, Department of Emergency Medicine, 525 E. 68th Street, New York, NY 10065. Email: shb9291@nyp.org

Conflicts of Interest: By the *CPC-EM* article submission agreement, all authors are required to disclose all affiliations, funding sources and financial or management relationships that could be perceived as potential sources of bias. The authors disclosed none.

Copyright: © 2024 Balasubramanian et al. This is an open access article distributed in accordance with the terms of the Creative Commons Attribution (CC BY 4.0) License. See: <http://creativecommons.org/licenses/by/4.0/>

REFERENCES

- McKnight CL and Burns B. Pneumothorax. In *StatPearls [Internet]*. Treasure Island, Florida: StatPearls Publishing; 2023.
- Husain LF, Hagopian L, Wayman D, et al. Sonographic diagnosis of pneumothorax. *J Emerg Trauma Shock*. 2012;5(1):76–81.
- Wong A, Galiabovitch E, Bhagwat K. Management of primary spontaneous pneumothorax: a review. *ANZ J Surg*. 2019;89(4):303–8.
- Daniels B, Greenwald P, Hsu H, et al. 284 Using community tele-paramedicine to reduce unnecessary emergency department visits and 30-day readmissions among high-risk patients with heart failure. *Ann Emerg Med*. 2019;74(4):S112–3.
- Meadley B, Olaussen A, Delorenzo A, et al. Educational standards for training paramedics in ultrasound: a scoping review. *BMC Emerg Med*. 2017;17:18.
- Brooke M, Walton J, Scutt D, et al. Acquisition and interpretation of focused diagnostic ultrasound images by ultrasound-naïve advanced paramedics: trialing a PHUS education programme. *Emerg Med J*. 2012;29:322–6.
- Khalil P, Merelman A, Riccio J, et al. Randomized controlled trial of point-of-care ultrasound education for the recognition of tension pneumothorax by paramedics in prehospital simulation. *Prehosp Disaster Med*. 2021;36(1):74–8.
- Berlet M, Vogel T, Gharba M, et al. Emergency telemedicine mobile ultrasounds using a 5G-enabled application: development and usability study. *JMIR Form Res*. 2022;6(5):e36824.
- Pietersen PI, Mikkelsen S, Lassen AT, et al. Quality of focused thoracic ultrasound performed by emergency medical technicians and paramedics in a prehospital setting: a feasibility study. *Scand J Trauma Resusc Emerg Med*. 2021;29:40.
- Langabeer JR 2nd, Gonzalez M, Alqusairi D, et al. Telehealth-enabled emergency medical services program reduces ambulance transport to urban emergency departments. *West J Emerg Med*. 2016;17(6):713–20.

Renal Artery Aneurysm Rupture as a Dangerous Mimic of Ovarian Cyst Rupture: A Case Report

Lauren Kaplan, MD*
 Kaushal H. Shah, MD[†]
 Christie Lech, MD, MHPE[†]
 Mary-Kate Gorlick, MD*

*New York-Presbyterian Hospital, New York, New York
[†]New York-Presbyterian Hospital; Weill Cornell Medical Center, Department of
 Emergency Medicine, New York, New York

Section Editor: Lev Libet, MD

Submission history: Submitted August 2, 2023; Revision received October 8, 2023; Accepted November 2, 2023

Electronically published May 14, 2024

Full text available through open access at http://escholarship.org/uc/uciem_cpccem

DOI: 10.5811/cpcem.1585

Introduction: Renal artery aneurysm rupture is a rare but morbid diagnosis, often requiring emergency surgery and nephrectomy. Clinical presentation can mimic more common pathology in non-pregnant women such as ruptured ovarian cyst.

Case Report: We present a case of a woman with a prior history of ovarian cyst presenting with a ruptured renal artery aneurysm. Prompt computed tomography (CT) imaging revealed a left renal artery aneurysm rupture with hemoperitoneum and renal infarct. She underwent emergency laparotomy and nephrectomy and was ultimately discharged in good condition.

Conclusion: While ovarian cyst rupture is the most common cause of spontaneous hemoperitoneum in non-pregnant women of childbearing age, renal artery aneurysm rupture should be considered and prompt CT imaging obtained, particularly in cases of hemodynamic instability, to ensure prompt treatment. [Clin Pract Cases Emerg Med. 2024;8(3)194–196.]

Keywords: *case report; aneurysm; renal; rupture.*

INTRODUCTION

Renal artery aneurysm (RAA) is a rare diagnosis, estimated to occur in 0.09% of the general population.⁵ Rupture is a rare but morbid complication, often requiring emergent surgery and nephrectomy. In contrast, ovarian cyst rupture is the most common cause of spontaneous hemoperitoneum in non-pregnant women of reproductive age and is usually managed conservatively in the absence of hemodynamic compromise or associated torsion.^{1,2} We report a case of spontaneous ruptured RAA as a dangerous mimic of ovarian cyst rupture.

CASE REPORT

A 52-year-old woman with a past medical history of ovarian cysts was brought in by emergency medical services (EMS) to our emergency department (ED) for acute onset of atraumatic left lower quadrant pain. Her symptoms started abruptly while at work, which she stated felt like symptoms

one year prior when she was found to have ovarian cysts and likely an ovarian cyst rupture. She endorsed lightheadedness, but she denied any shortness of breath, chest pain, cough, fevers, chills, or changes in urination.

Per EMS report, she acutely became pale and somnolent, associated with bradycardia to the 40s. In the ED she was hypotensive to 84/48 millimeters of mercury, with heart rate 84 beats per minute, oxygen saturation 100% on room air, and she was afebrile. Physical examination revealed pallor, somnolence, cool extremities, and a peritoneal abdomen. Focused assessment with sonography in trauma examination was positive for free fluid in the left upper quadrant. Pregnancy test was negative. Initial labs were notable for lactate 4.59 millimoles per liter (mmol/L) (reference range 0.50–1.60 mmol/L). Initial hemoglobin was 10 grams per deciliter (g/dL) (12.6–17.0 g/dL); hematocrit 30.5% (37.2–47.9%); platelets 317,000 per milliliter (mL) (156,000–325,000/mL); and white blood cell count

15,000/mL (3,120–8,440/mL). Coagulation factors were normal. Chemistry panel was notable for sodium 130 mmol/L (137–145 mmol/L); potassium 3.3 mmol/L (3.5–5.1 mmol/L); bicarbonate 21 mmol/L (19–27 mmol/L); blood urea nitrogen 18 milligrams (mg)/dL (7–26 mg/dL); and creatinine 1.0 mg/dL (0.70–1.30 mg/dL). Emergency physicians activated a massive transfusion protocol and paged the obstetrics and gynecology service due to concern for hemorrhagic ruptured ovarian cyst vs ovarian torsion.

Emergent computed tomography of the abdomen and pelvis revealed a large left retroperitoneal and peritoneal hematoma secondary to left RAA rupture, as well as concern for developing splenic infarcts in the left lower renal pole (**Image**). The patient was taken emergently to the operating room (OR) for exploratory laparotomy within two hours of ED arrival. She underwent suprarenal cross-clamping with repair of the left renal artery and ligation of renal vessels. She returned to the OR two days later for left nephrectomy and abdominal closure. She was extubated and transferred to the floor. She was discharged home two days later in good condition.

DISCUSSION

Although the incidence of RAA is rare, ranging from 0.01–0.09% of the population, this case report illustrates the importance of timely diagnosis.^{3,4} Contemporary rupture rates are estimated at approximately 3%.⁵ They are most commonly found in women >60 years with risk factors including hypertension, fibrodysplasia, and connective tissue disorders causing arterial medial wall degeneration. Patients notably lack traditional cardiovascular risk factors such as cigarette use and diabetes.^{6,7} Aneurysms are usually asymptomatic and found incidentally on screening imaging, although patients can present with symptoms such as hypertension, flank pain, hematuria, and abdominal pain.⁵

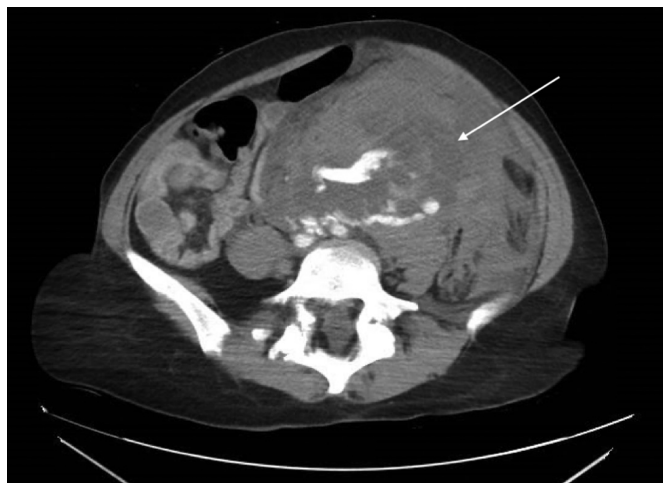

Image. Cross-sectional image of abdominal computed tomography showing hematoma with extravasation of contrast (arrow) as a result of ruptured left renal artery aneurysm.

Population Health Research Capsule

What do we already know about this clinical entity?

Renal artery aneurysm (RAA) rupture is a rare but morbid diagnosis that can lead to emergency surgery and nephrectomy.

What makes this presentation of disease reportable?

We report a case of spontaneous ruptured RAA presenting as a dangerous mimic of ovarian cyst rupture, a more common pathology in non-pregnant women.

What is the major learning point?

Emergency physicians should maintain an index of suspicion for emergent vascular pathology in non-pregnant women of childbearing age with spontaneous hemoperitoneum.

How might this improve emergency medicine practice?

Maintaining an index of suspicion for rare disease processes such as RAA rupture will ensure prompt recognition and treatment in the ED.

As the presentation of a ruptured RAA can be identical to the more common ruptured ovarian cyst, consideration of rare serious surgical pathology should be maintained for patients with acute abdominal pain and free fluid on exam. Bradycardia in the setting of hemoperitoneum is a well described phenomenon particularly in ruptured ectopic pregnancy and can indicate hemorrhagic shock, both of which were considerations in the case reported here.^{8,9} Other emergent complications of RAA include thrombosis, embolism, and obstructive uropathy.

For non-ruptured RAA, surgical or endovascular intervention is recommended for aneurysms with a diameter exceeding two centimeters, patients with uncontrolled symptoms (ie. pain or refractory hypertension), or in women of childbearing age (as there are higher rates of rupture and mortality in pregnancy and puerperium than in the general population).^{3,6} These guidelines remain somewhat controversial given the increased incidence of aneurysms uncovered by widespread use of imaging combined with a knowledge gap of the natural progression of disease.^{2,4} Endovascular intervention through stenting or angioembolization is a safe and effective alternative to open repair, with studies suggesting a trend toward shorter

hospital stays and fewer complications.¹⁰ In cases of hemodynamic compromise, exploratory laparotomy and nephrectomy are often indicated.^{2,3,4}

CONCLUSION

This is a case of spontaneous rupture of a left renal artery aneurysm as a dangerous mimic of ovarian cyst rupture. While ovarian cyst rupture remains the most common cause of spontaneous hemoperitoneum in non-pregnant women of childbearing age, RAA should be considered with confirmation via computed tomography, particularly in cases of hemodynamic instability to ensure prompt treatment of a disease with potentially high morbidity and mortality.

The authors attest that their institution requires neither Institutional Review Board approval, nor patient consent for publication of this case report. Documentation on file.

Address for Correspondence: Lauren Kaplan, MD, New York-Presbyterian Hospital, 525 East 68th Street, New York, NY 10065. Email: Lek9048@nyp.org

Conflicts of Interest: By the CPC-EM article submission agreement, all authors are required to disclose all affiliations, funding sources and financial or management relationships that could be perceived as potential sources of bias. The authors disclosed none.

Copyright: © 2024 Kaplan et al. This is an open access article distributed in accordance with the terms of the Creative Commons Attribution (CC BY 4.0) License. See: <http://creativecommons.org/licenses/by/4.0/>

REFERENCES

1. Lee YR. CT imaging findings of ruptured ovarian endometriotic cysts: emphasis on the differential diagnosis with ruptured ovarian functional cysts. *Korean J Radiol.* 2011;12(1):59.
2. Lim WH, Woods N, Lamaro VP. Trends and outcomes of ruptured ovarian cysts. *Postgrad Med J.* 2021;98(1161):e9.
3. Gonzalez J, Esteban M, Andres G, et al. Renal artery aneurysms. *Curr Urol Rep.* 2014;15(1):376.
4. Villianou NG, Sikara M, Zisis C. Rupture of a left renal artery aneurysm: a rare abdominal emergency. *Am J Emerg Med.* 2016;34(2):e347.e3–4.
5. Klausner JQ, Lawrence PF, Harlander-Locke MP, et al. The contemporary management of renal artery aneurysms. *J Vasc Surg.* 2015;61(4):978–84.
6. Augustin G, Kulis T, Kello N, et al. Ruptured renal artery aneurysm in pregnancy and puerperium: literature review of 53 cases. *Arch Gynecol Obstet.* 2019;299(4):923–31.
7. Coleman DM and Stanley JC. Renal artery aneurysms. *J Vasc Surg.* 2015;62(3):779–85.
8. Snyder H. Lack of a tachycardic response to hypotension with ruptured ectopic pregnancy. *Am J Emerg Med.* 1990;8(1):23–6.
9. Somers MP, Spears M, Maynard AS, et al. Ruptured heterotopic pregnancy presenting with relative bradycardia in a woman not receiving reproductive assistance. *Ann Emerg Med.* 2004;43(3):382–5.
10. Orion KC and Abularrage CJ. Renal artery aneurysms: movement toward endovascular repair. *Semin Vasc Surg.* 2013;26(4):226–32.

Capnocytophaga ochracea Septicemia After a Dog Bite: The Case of a Usual Suspect Transmitting an Unusual Organism

Clifford Chang, MD*
 Vakula Atthota, MD^{†‡}
 Madison Lord, DO[‡]
 Michael P. Bonk, MD[§]
 Muhammad Durrani, DO*

*Inspira Health Network, Department of Emergency Medicine, Vineland, New Jersey
[†]Inspira Health Network, Department of Infectious Diseases, Vineland, New Jersey
[‡]Inspira Health Network, Department of Internal Medicine, Vineland, New Jersey
[§]Rowan University, Cooper Medical School, Division of Critical Care Medicine, Camden, New Jersey

Section Editor: Austin Smith, MD

Submission history: Submitted November 26, 2023; Revision received January 17, 2024; Accepted January 23, 2024

Electronically published July 11, 2024

Full text available through open access at http://escholarship.org/uc/uciem_cpccem

DOI: 10.5811/cpcem.5826

Introduction: *Capnocytophaga ochracea* is found in the human oral microbiome and is a rare cause of antibiotic-resistant, opportunistic septicemia in immunocompromised hosts. The zoonotic transmission of *C ochracea* from canines to humans has not yet been reported in the literature. Cohabitation with people is associated with oral colonization in dogs and may be a reservoir for *Capnocytophaga* infections, which have a decreased susceptibility to first-line antibiotics commonly used to treat animal exposures.

Case Report: This is the case of a 70-year-old male with a remote history of lymphoma status post splenectomy, in remission, who presented with stigmata of *Capnocytophaga* septicemia after a dog bite, which included purpura fulminans on physical examination. Initial broad-spectrum coverage with cefepime failed to slow the progression into multiorgan failure. A *Capnocytophaga* strain with extended resistance was suspected. Antibiotics were transitioned to meropenem, and the patient eventually made a good recovery. Blood cultures isolated *C ochracea*.

Conclusion: *Capnocytophaga* infections should be suspected in patients with severe sepsis and purpura fulminans after a canine exposure. Canine pets may be a reservoir for *Capnocytophaga* species with increased antibiotic resistances, such as *C ochracea*, which trace their origins to the human oral microbiome. A thorough medical history is essential to identify risk factors such as asplenia and active immune compromise that are associated with infections from antibiotic-resistant strains and worse outcomes. For *Capnocytophaga* infections that fail initial therapies, cephalosporins should be avoided because of high resistance rates, and the use of carbapenems may be favored over combination beta-lactam/beta-lactamase inhibitors in select clinical scenarios. [Clin Pract Cases Emerg Med. 2024;8(3)197–201.]

Keywords: *capnocytophaga*; antibiotic resistance; dog bite; purpura fulminans; immunocompromise; extended-spectrum β -lactamases; ESBL.

INTRODUCTION

Capnocytophaga is a genus of encapsulated, Gram-negative rods that resides in the commensal mammalian flora as facultative anaerobes. Native to the canine oral microbiome, *C canimorsus* is well known to cause infections in humans through canine exposures such as bites, licks, and

scratches. Other species of *Capnocytophaga* such as *C ochracea*, *C sputigena*, and *C gingivalis* are native to the human oral microbiome and often found in association with gingivitis.¹ Bacteremia from these human oral *Capnocytophaga* (HOC) species disproportionately affects severely immunocompromised patients and is associated

with poor outcomes. A retrospective study published in 2021 by Chesdachai et al found that the six-month mortality of patients with HOC bacteremia was higher than those with *C canimorsus* bacteremia, 36.4% vs 6.2%, respectively.²

Potentiated by a compromised immune system, the pathogenesis of HOC bacteremia likely involves self-seeding from the oral cavity into the systemic circulation. While the majority of *C canimorsus* infections are associated with known animal exposures (up to 77%), the zoonotic transmission of HOC species such as *C ochracea* has not yet been reported in the literature.² Interestingly, *C ochracea* along with other human oral microbes are found in the mouths of dogs that cohabit with people.^{3,4} Such pets may be a reservoir of potentially pathogenic bacteria that do not yet have a track record for causing zoonotic infections.

The poor outcomes associated with *C ochracea* and other HOC infections are multifactorial and include the degree of host immune suppression, the presence of underlying diseases such as hematologic malignancy, and increased antibiotic resistance. Unlike *C canimorsus*, which is almost universally susceptible to narrow-spectrum antibiotics (eg, penicillin), *C ochracea* and other HOC species are often resistant to commonly used broad-spectrum antibiotics for polymicrobial animal exposures. Up to 70% of HOC isolates produce beta-lactamases, which confer resistance to first-generation cephalosporins (100% resistant), amoxicillin (86%), and third-generation cephalosporins (63%).⁵⁻⁷

Although *Capnocytophaga* species are typically sensitive to combination beta-lactam/beta-lactamase inhibitors in vitro, treating critically ill, bacteremic patients with antibiotics such as amoxicillin-clavulanate or piperacillin-tazobactam may result in poor outcomes. A noninferiority trial published in 2019 randomized 378 patients with Gram-negative bacteremia demonstrating extended spectrum beta-lactamase activity (ESBL), defined as resistance to ceftriaxone, to either treatment with piperacillin-tazobactam or meropenem. Despite having confirmed in vitro susceptibility to both antibiotics, patients treated with piperacillin-tazobactam (12.3%) had increased 30-day mortality when compared to meropenem (3.7%).⁸

Herein we describe the first reported case to our knowledge of human oral-associated *Capnocytophaga* bacteremia transmitted from an animal. The patient described in this case developed severe *C ochracea* septicemia with purpura fulminans after a dog bite and eventually had a good outcome after treatment with meropenem.

CASE REPORT

A 70-year-old male with a history of Stage III diffuse large B-cell lymphoma status post chemotherapy and splenectomy 20 years prior, currently in remission, presented to a large community emergency department with generalized weakness and altered mental status three days after he

Population Health Research Capsule

What do we already know about this clinical entity?

Human oral bacteria are often resistant to conventional antibiotics. Cohabitation is associated with the oral colonization of these bacteria in dogs.

What makes this presentation of disease reportable?

*This is the first reported case of a human oral *Capnocytophaga* species causing sepsis after zoonotic transmission via a dog bite.*

What is the major learning point?

Pet bites may transmit antibiotic-resistant bacteria that originate from the human oral microbiome. The use of carbapenems should be considered when initial therapies fail.

How might this improve emergency medicine practice?

Clinicians should recognize the changing nature of infectious diseases and understand the role of extended spectrum antimicrobials.

sustained a bite to his left thumb from a pet dog. The dog was fully vaccinated and had not been demonstrating abnormal behaviors leading up to the incident. On arrival the patient appeared acutely ill. Vitals signs were notable for a heart rate of 108 beats per minute, blood pressure of 78/43 millimeters of mercury, tachypnea at a rate of 38 breaths per minute, and a temperature of 36.3° Celsius. Examination of the ulnar aspect of the left thumb revealed two faint, punctate bite marks that later became dusky and locally necrotic (Image 1). Dark purple, non-blanching macules were seen in all extremities consistent with purpura fulminans and highly suggestive of *Capnocytophaga* septicemia (Image 2).

The initial lactic acid was 15.0 millimoles per liter (mmol/L) (reference range: 0.5–1.5 mmol/L), and the white blood cell count reached a peak of 90.0×10^9 cells/L ($4.5 - 11.0 \times 10^9$ cells/L). Given the severity of the patient's illness, vancomycin and cefepime were initiated empirically. Despite broad spectrum antibiotics and the resuscitation of septic shock with crystalloid fluids, glucocorticoid therapy, and escalating vasoactive medications, the patient deteriorated into multiorgan failure. Within the first day of admission the patient was intubated, placed on mechanical ventilation, initiated on renal replacement therapy, developed coagulopathy, and required intravenous inotropic support.

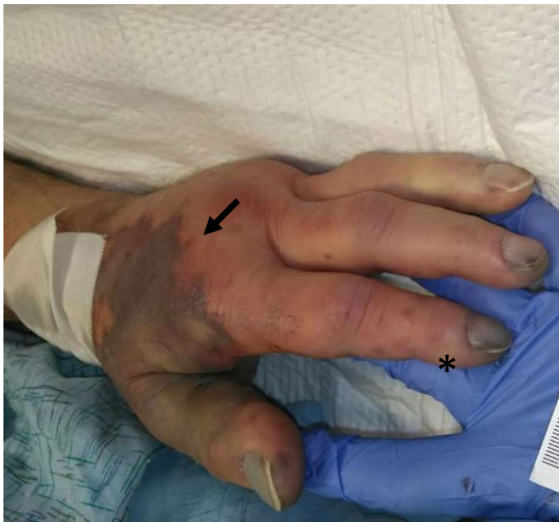

Image 1. Left hand with purpura and local necrosis (arrows) as well as petechiae (asterisk).

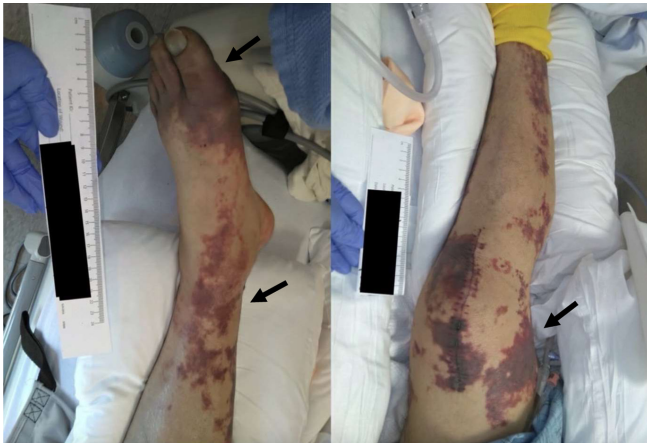

Image 2. Purpura fulminans (arrows) of the left and right lower extremities, respectively.

Echocardiogram demonstrated severe global hypokinesis of the left ventricle with a newly depressed ejection fraction of 20–25% consistent with acute septic cardiomyopathy.

Encapsulated *Capnocytophaga* infection remained highest on the differential given the patient's history of asplenia, recent canine exposure, and purpura fulminans on physical examination. However, the lack of response to cefepime raised concerns for the presence of a resistant *Capnocytophaga* species, potentially with extended spectrum activity. The patient's treatment regimen was transitioned to meropenem one gram every eight hours on which he began to demonstrate clinical improvement.

Capnocytophaga are fastidious, slow-growing bacteria, and our suspicion for this organism was communicated to the microbiology laboratory to increase culture yields.

Additional growth media were used, and the specimens were

observed for a longer duration. Gram-negative bacilli were found in the aerobic bottles after five days, and *C ochracea* finally speciated after 11 days. The speciation was confirmed by both biochemical methods, using RapID ANA II (Thermo Fisher Scientific Inc, Waltham, MA) and mass spectrometry matrix-assisted laser desorption/ionization (Bruker Corporation, Billerica, MA). Susceptibilities studies were unfortunately not performed given difficulty of culturing the organism.

After a gradual recovery, the patient was transferred out of the intensive care unit nine days after admission and discharged back home on day 18 with visiting rehabilitation services as well as the remainder of a four-week total course of meropenem. At discharge, he was ambulatory and had a recovered left ventricular ejection fraction of 50–55%. Other sequelae included multiple toe amputations for vasopressor and coagulopathy-associated gangrene as well as post-debridement contractures of the left hand. Despite his critical illness and prolonged hospitalization, the patient made a remarkable recovery. His goal was to eventually return to work full time.

DISCUSSION

Although more commonly thought of as a commensal organism in the oral microbiota, HOC species such as *C ochracea* are a rare cause of severe, opportunistic bacteremia in patients with risk factors for active immune suppression. A case series published in 2001 reported that of 28 cancer patients with neutropenic fevers related to HOC bacteremia, 25 (89%) had an active hematologic malignancy and half had moderate to severe mucositis.⁹ Identified in one third of cases, *C ochracea* was the most commonly isolated species. A more recent review published in 2021 found that all 22 patients with HOC bacteremia had at least one risk factor for active immunocompromise, most commonly immunosuppressive medications (72%), hematopoietic stem cell transplantation (54%), and hematologic malignancy (40%).²

The patient described in this case underwent chemotherapy and splenectomy for a lymphoma 20 years prior and had been in remission since. Without signs of an active malignancy, his primary risk factor for *Capnocytophaga* sepsis was likely asplenia. In terms of infectious source, the patient exhibited no signs of mucositis and was bitten only three days prior to presentation, which is within the one to seven day incubation period of *Capnocytophaga* infections.¹⁰

The speciation of *C ochracea* instead of *C canimorsus* from the dog bite was unanticipated. In a retrospective review of *Capnocytophaga* bacteremia, animal exposure was confirmed in 68.8% of *C canimorsus* infections while no patients with infections from other *Capnocytophaga* species had reported exposures.² *Capnocytophaga ochracea* is not thought to be native to the canine oral microbiome; however,

several HOC species have been identified in the oral microbiomes of pets.³ Cohabitation and close contact may facilitate the transmission of microorganisms from humans to pet animals. Similar to how the human oral and gut microbiome is often transmitted from mothers to their children, there may be transmission of human oral microbes to pet dogs and cats.^{4,11,12} The potential of pets as reservoirs for HOC species, timing of symptoms following inoculation, and absence of strong risk factors for spontaneous opportunistic bacteremia make the case for zoonosis as the source of our patient's *C ochracea* sepsis.

The antimicrobial susceptibility of *C ochracea* and other HOC infections differs from that of *C canimorsus*.

Capnocytophaga canimorsus strains rarely produce beta-lactamases and are largely susceptible to common antibiotics used in the management of polymicrobial animal exposures (ie, amoxicillin-clavulanate, clindamycin, third-generation cephalosporins). Up to 70% of HOC isolates produce beta-lactamases, and more than 60% of those are resistant to third-generation cephalosporins.⁷ Additionally, there are reports of multidrug resistant strains of *C ochracea*, *C sputigena*, and *C gingivalis* that are resistant to fourth-generation cephalosporins (eg, cefepime).^{13,14} These findings are concerning for extended-spectrum β -lactamases (ESBL) activity among HOC species.

Combination antibiotics (ie, amoxicillin-clavulanate or piperacillin-tazobactam) may appear to be reasonable alternatives based on in vitro susceptibilities; however, the treatment of ESBL Gram-negative bacteremia with piperacillin-tazobactam rather than meropenem is associated with decreased survival.⁸ Increased bacterial density within infected tissue can alter local pharmacokinetics through the well-described "inoculum effect" where sensitivity to piperacillin-tazobactam can decrease from 95% at in vitro bacterial concentrations to 58% at in vivo concentrations.¹⁵ This effect is limited in carbapenems and appears to be mediated by the downregulation of target proteins, synergistic enzymatic degradation, and biofilm production.

A limitation of our case is the lack of susceptibility data; however, the prevalence of later-generation cephalosporin resistance among *C ochracea* strains and the patient's lack of clinical improvement with cefepime raised our suspicion for the presence of extended spectrum resistances. In our case, treatment with meropenem ultimately led to a good outcome.

CONCLUSION

Capnocytophaga bacteremia should be suspected in patients with severe sepsis and purpura fulminans after a canine exposure. Resistant infections should be considered in patients who do not respond to initial therapies. Patients with asplenia and active immunocompromise are at highest risk. In such cases, cephalosporins should be avoided because of

high resistance rates, and the use of carbapenems may be favored over combination beta-lactam/beta-lactamase inhibitors in select clinical scenarios. Canine pets may be a reservoir for *Capnocytophaga* species with increased resistances, such as *C ochracea*, which trace their origins to the human oral microbiome.

The authors attest that their institution requires neither Institutional Review Board approval, nor patient consent for publication of this case report. Documentation on file.

Address for Correspondence: Muhammad Durrani, DO, Inspira Vineland Medical Center, Department of Emergency Medicine, 1505 West Sherman Ave., Vineland, NJ 08360.

Email: DurraniM1@ihn.org

Conflicts of Interest: By the *CPC-EM* article submission agreement, all authors are required to disclose all affiliations, funding sources and financial or management relationships that could be perceived as potential sources of bias. The authors disclosed none.

Copyright: © 2024 Chang et al. This is an open access article distributed in accordance with the terms of the Creative Commons Attribution (CC BY 4.0) License. See: <http://creativecommons.org/licenses/by/4.0/>

REFERENCES

1. Idate U, Bhat K, Kotrashetti V, et al. Molecular identification of *Capnocytophaga* species from the oral cavity of patients with chronic periodontitis and healthy individuals. *J Oral Maxillofac Pathol.* 2020;24(2):397.
2. Chesdachai S, Tai DBG, Yetmar ZA, et al. The characteristics of *Capnocytophaga* infection: 10 years of experience. *Open Forum Infect Dis.* 2021;8(7):ofab175.
3. Yamasaki Y, Nomura R, Nakano K, et al. Distribution of periodontopathic bacterial species in dogs and their owners. *Arch Oral Biol.* 2012;57(9):1183–8.
4. Kato Y, Shirai M, Murakami M, et al. Molecular detection of human periodontal pathogens in oral swab specimens from dogs in Japan. *J Vet Dent.* 2011;28(2):84–9.
5. Jolivet-Gougeon A, Tamanai-Shacoori Z, Desbordes L, et al. Genetic analysis of an ambler class A extended-spectrum beta-lactamase from *Capnocytophaga ochracea*. *J Clin Microbiol.* 2004;42(2):888–90.
6. Ehrmann E, Handal T, Tamanai-Shacoori Z, et al. High prevalence of β -lactam and macrolide resistance genes in human oral *Capnocytophaga* species. *J Antimicrob Chemother.* 2014;69(2):381–4.
7. Jolivet-Gougeon A, Tamanai-Shacoori Z, Desbordes L, et al. Prevalence of oropharyngeal beta-lactamase-producing *Capnocytophaga* spp. in pediatric oncology patients over a ten-year period. *BMC Infect Dis.* 2005;5:32.
8. Harris PNA, Tambyah PA, Lye DC, et al. Effect of piperacillin-tazobactam vs meropenem on 30-day mortality for patients with

- E coli or Klebsiella pneumoniae bloodstream infection and ceftriaxone resistance: a randomized clinical trial. *JAMA*. 2018;320(10):984–94.
9. Martino R, Rámila E, Capdevila JA, et al. Bacteremia caused by *Capnocytophaga* species in patients with neutropenia and cancer: results of a multicenter study. *Clin Infect Dis*. 2001;33(4):E20–2.
 10. Oehler RL, Velez AP, Mizrahi M, et al. Bite-related and septic syndromes caused by cats and dogs. *Lancet Infect Dis*. 2009;9(7):439–47.
 11. Tamura K, Nakano K, Hayashibara T, et al. Distribution of 10 periodontal bacteria in saliva samples from Japanese children and their mothers. *Arch Oral Biol*. 2006;51(5):371–7.
 12. Arashima Y, Kumasaka K, Okuyama K, et al. Clinicobacteriological study of *Pasteurella multocida* as a zoonosis condition of dog and cat carriers of *Pasteurella*, and the Influence for human carriers rate by kiss with the pets. *Kansenshogaku Zasshi*. 1992;66(2):221–4.
 13. Wang HK, Chen YC, Teng LJ, et al. Brain abscess associated with multidrug-resistant *Capnocytophaga ochracea* infection. *J Clin Microbiol*. 2007;45(2):645–7.
 14. Migiyama Y, Anai M, Kashiwabara K, et al. Lung abscess following bronchoscopy due to multidrug-resistant *Capnocytophaga sputigena* adjacent to lung cancer with high PD-L1 expression. *J Infect Chemother*. 2018;24(10):852–5.
 15. Thomson KS and Moland ES. Cefepime, piperacillin-tazobactam, and the inoculum effect in tests with extended-spectrum beta-lactamase-producing Enterobacteriaceae. *Antimicrob Agents Chemother*. 2001;45(12):3548–54.

High-altitude Cerebral Edema and High-altitude Pulmonary Edema Diagnosed in the Desert: A Case Report

Bryn Walsh, DO
Suneil Agrawal, MD

Desert Regional Medical Center, Palm Springs, California

Section Editor: Joel Moll, MD

Submission history: Submitted October 20, 2023; Revision received January 10, 2023; Accepted January 25, 2024

Electronically published May 28, 2024

Full text available through open access at http://escholarship.org/uc/uciem_cpccem

DOI: [10.5811/cpcem.3851](https://doi.org/10.5811/cpcem.3851)

Introduction: Acute mountain sickness, high-altitude pulmonary edema (HAPE), and high-altitude cerebral edema (HACE) are a spectrum of high-altitude conditions, with HACE being the most life-threatening. Most cases develop at altitudes of greater than 4,000 meters (~13,000 feet) above sea level and after one to five days.

Case Report: A previously healthy 46-year-old female presented to the emergency department with ataxia, altered mental status, and vomiting that developed after rapidly ascending to ~2,400 meters (~7,800 feet) above sea level. She was treated for HACE and HAPE with resolution of her symptoms within 24 hours.

Conclusion: High-altitude pulmonary edema and HACE can develop rapidly and at moderate altitudes. Expedient recognition and treatment is imperative to avoid life-threatening complications. [Clin Pract Cases Emerg Med. 2024;8(3)202–205.]

Keywords: *acute mountain sickness; high altitude pulmonary edema; high altitude cerebral edema; case report; computed tomography.*

INTRODUCTION

High-altitude conditions involve a spectrum of diseases including acute mountain sickness (AMS), high-altitude pulmonary edema (HAPE), and high-altitude cerebral edema (HACE).^{1–3} Acute mountain sickness manifests with non-specific symptoms, most commonly headache, nausea, and fatigue. It usually develops 2–12 hours after initial arrival at high elevation.¹ High-altitude pulmonary edema can present with exertional dyspnea, chest tightness, cough, and decreased exercise capacity.⁴ High-altitude cerebral edema generally presents with varying levels of confusion, ataxia, altered mental status, and vomiting, with ataxia present in up to 60% of reported cases.^{1,4,5} Early HACE may manifest as social withdrawal and drowsiness.⁴ High-altitude cerebral edema represents the least common form of high-altitude illness; however, it is the most important to diagnose and treat as the condition can rapidly progress to coma secondary to brain herniation and death in as few as 12 hours.^{1,6}

The reported prevalence of HACE between 4,200–5,000 meters (m) (~13,800 to ~16,400 feet [ft]) above sea level is 0.5–1%.^{3,4} When HACE does present, it is thought to occur within 1–5 days of an ascent greater than 2,500–3,000 m (8,200–9,800 ft) above sea level, and it is rarely seen at altitudes lower than 2,500 m (8,200 ft) above sea level or within the first 24 hours of arrival.⁴ The most important factors in the development of symptoms are the rate of ascent and period of acclimatization.¹ This case highlights a patient who developed symptoms of HACE and HAPE within hours of rapidly ascending to ~2,400 m (~7,800 ft) above sea level, which only few cases have previously demonstrated.

CASE REPORT

A 46-year-old female with no past medical history and taking no medications presented to the emergency department (ED) via emergency medical services (EMS) for acute altered mental status that developed while hiking on Mount San Jacinto in Southern California. The patient had

traveled from the coastal region of Southern California (~20 m [~60 ft] above sea level) to Palm Springs, CA, (~150 m [~490 ft] above sea level) with a wilderness group. After ascending via the Palm Springs Aerial Tramway over a 10–12 minute period and arriving at the base camp station (~2,400 m [~7,800 ft] above sea level), the patient began complaining of worsening malaise, nausea, chest tightness, and headache. Her symptoms worsened while hiking a short distance to a campsite (~2,800 m [~9,200 ft]). Shortly after arriving, the patient began vomiting, which prompted the team leader to descend on the tram with the patient and call EMS. During descent, the patient became more confused and ataxic, requiring assistance with ambulation. On EMS arrival at the base of the tram, the patient was markedly altered and agitated.

In the ED, vitals were blood pressure 132/86 millimeters of mercury, heart rate 84 beats per minute, respirations 21 breaths per minute, and oxygen saturation 100% on 2 liters nasal cannula. On physical exam, the patient was noted to be tachypneic, mumbling incomprehensible sounds, only opening eyes to voice, and withdrawing to pain. She was not answering questions or following commands. She was intermittently combative and fighting to get out of bed. Her Glasgow Coma Score was 10 (eyes-3, voice-2, motor-5). There was no evidence of trauma.

Workup in the ED included electrocardiogram, complete blood count, metabolic panel, urinalysis, drug screen, ethanol level, acetaminophen level, salicylate level, coagulation studies, quantitative human chorionic gonadotropin, chest radiograph (CXR), and computed tomography (CT) of the head. The only lab abnormalities were in the metabolic panel, with a sodium of 128 milliequivalents per liter (mEq/L) (reference range: 135–145 mEq/L), potassium of 3.1 mEq/L (3.5–5.0 mEq/L), carbon dioxide of 18 millimoles (mmol)/L (20–32 mmol/L), and elevated anion gap at 22 mEq/L (7–13 mEq/L). Ethanol, acetaminophen, salicylate, and urine drug screen were negative. The CXR ([Image](#)) showed diffuse pulmonary vascular congestion. She remained quite agitated in the ED, requiring 3 milligrams (mg) of lorazepam intravenously (IV). The head CT interpretation was limited due to patient motion because of agitation, although no acute intracranial abnormality was seen.

Without another obvious cause of her hypoxia and altered mental status, HACE/HAPE treatment was started in the ED. She was given 250 mg acetazolamide IV and 8 mg dexamethasone IV. The patient was admitted to the hospital for observation, with neurology and nephrology specialist consultation for altered mental status and minor electrolyte abnormalities. Her symptoms completely resolved the following day, and her lab values normalized. Her mild hyponatremia of 128 mmol/L was not thought to be the main driving factor behind her symptoms. At the time of discharge she had no memory of descent, EMS transport, or her time in

CPC-EM Capsule

What do we already know about this clinical entity?

Most cases of high altitude cerebral edema (HACE) and high altitude pulmonary edema (HAPE) occur at greater than >4000 m (~13000 ft) above sea level.

What makes this presentation of disease reportable?

This case highlights a patient who developed symptoms of HACE and HAPE within hours of rapidly ascending to ~2400 m (~7800 ft) above sea level.

What is the major learning point?

HAPE and HACE can occur more rapidly and at lower elevations than previously thought.

How might this improve emergency medicine practice?

Given the high mortality rate in delayed diagnosis of HAPE and HACE, it is imperative to keep a high index of suspicion when susceptible individuals present.

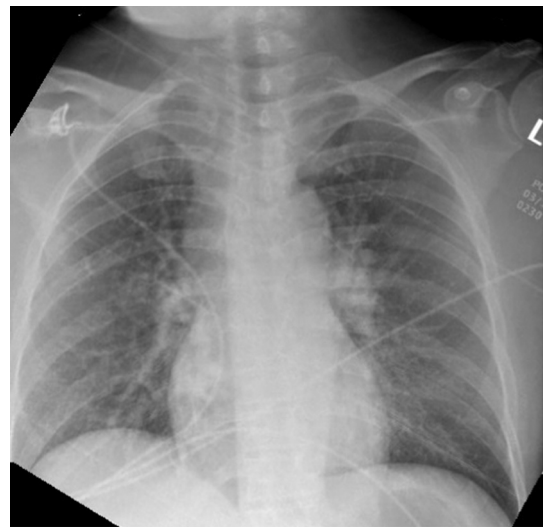

Image. One view anterior-posterior chest radiograph obtained due to patient's complaint of chest tightness during ascent to high altitude and tachypnea on presentation. Pulmonary vascular congestion is seen throughout. There is no evidence of pneumothorax, cardiomegaly, or consolidation.

the ED. Once awake, she denied any previous drug or alcohol use.

DISCUSSION

In the progression of high-altitude disease, AMS generally develops first.⁵ Symptoms are usually seen after 2–12 hours and reach maximum intensity at 18–24 hours at altitudes greater than 2,500 m (~8,200 ft) above sea level.^{1,4,7} High-altitude cerebral edema and HAPE are rare, and usually occur at higher altitudes (>4,000 m [>13,000 ft]) after a longer period of time (1–5 days).⁴ Progression of AMS to HACE is thought to result from disruption of the blood brain barrier, intracellular edema and, possibly, venous outflow obstruction.^{2,5} Hypoxia leads to cerebral vasodilation and increased capillary pressure, eventually leading to fluid shifts into cells and cerebral edema.^{2,5} Hypoxia and cerebral vasodilation is thought to cause the initial headaches and lethargy seen in AMS, and alert patients can rapidly deteriorate to coma (within 12 hours), although this is rare and usually occurs at extreme altitudes.^{2,5,8} In HAPE, pulmonary artery pressures increase from hypoxic pulmonary vasoconstriction, causing capillary hypertension and fluid shifts.^{4,5} Of patients with HAPE, 15% will also have HACE, and HACE has been reported at altitudes as low as 2,500 m (~8,200 ft) above sea level in patients who have concomitant HAPE.^{1,7,9}

Risk factors for increased susceptibility for high-altitude illnesses include female gender, younger age, and a history of migraines.³ In the case described above, the patient presented with classic symptoms of both HACE (ataxia, altered mental status, vomiting) and HAPE (chest tightness, hypoxia, tachypnea). It is possible that our patient's gender potentially contributed to her rapid progression. At 46 years of age, she was on the cusp of the defined age risk of AMS, which may have also played a part. The patient had no reported history of migraines. History of AMS has also been cited as a risk factor for recurrent episodes; however, she had no reported history of AMS.³

Our patient's initial head CT, although limited secondary to motion artifact, did not reveal any obvious edema. When findings are present, CT of the head can show diffuse low density in the entire cerebrum, white matter signal attenuation with flat gyri and effaced sulci, and small ventricles.^{5,8,10} Magnetic resonance imaging (MRI) findings can include edema in the genu and splenium of the corpus callosum and the subcortical white matter.^{1,5} Microbleeds have also been seen in the cerebral white matter tracts of HACE survivors, which were not seen in patients with AMS or HAPE only.^{1,7,11} Cerebral white matter cytotoxic edema on brain MRI is more consistently seen after 22 hours of symptom onset.¹ Hackett in 1998 detailed nine patients with HACE, all of whom recovered with treatment. Four patients who were defined as "moderately ill" had normal MRIs.¹¹ In a recent study conducted by Long et al, the brain CT and

MRI from 30 patients diagnosed with HACE were reviewed from January 2012–August 2022. Findings revealed a 100% sensitivity and 100% specificity of MRI diagnosis, and a 23.3% sensitivity and 100% specificity of CT diagnosis.¹² Unfortunately, brain MRI was not done on our patient during hospitalization. Given the broad potential findings on CT head with its poor sensitivity, if clinical suspicion is high enough treatment should not be delayed due to negative CT head imaging.

High-altitude pulmonary edema can manifest as patchy lung infiltrates on CXR, which are usually unevenly distributed.^{4,5,13} As in HACE, CXR findings resolve as clinical features improve.¹³ While our patient's CXR showed pulmonary edema consistent with HAPE, the distribution was more even than what is classically seen. Lower respiratory tract infections before travel are a risk factor that may account for HAPE at low altitudes.⁴ Viruses could alter the permeability of the alveolar-capillary barrier and lower the pressure required for formation of edema.⁴ To our knowledge, the patient had no known viral symptoms before ascent. The case also occurred before the 2019 coronavirus pandemic.

Once there is suspicion for a high-altitude condition of any degree, the most important treatment is descent. This is especially true in individuals with HACE due to the cerebral edema and risk of brain herniation.^{2,12} Wilderness Medical Society Guidelines recommend that rather than treating patients based on altitude only, treatment should be based on symptoms.⁹ Symptoms usually resolve after descent of 300–1,000 m (~980–3,200 ft) above sea level.⁹ Interestingly, our patient's condition worsened with descent. Once descended or if descent is not an option, low-flow oxygen can be applied with an oxygen saturation goal of greater than 90% for patients with suspected HAPE. The use of dexamethasone in the treatment of AMS and HACE is widely accepted, with a recommended dose of 8 mg (intramuscularly, IV, or orally), followed by 4 mg every six hours until symptoms resolve.^{2,5,9} Dexamethasone may help with HAPE, although this is unclear.⁹ There is limited data on the use of acetazolamide as a treatment for AMS or HACE. However, current literature recommends consideration of its use in AMS.¹² For HAPE, acetazolamide may cause hypotension, especially if there is concomitant dehydration, which can worsen dyspnea.⁹ Loop diuretics should be avoided in HACE due to associated dehydration.^{5,9}

CONCLUSION

Acute mountain sickness, HAPE, and HACE are a spectrum of conditions under the umbrella of high-altitude illnesses. While rarely seen, and generally only at very high elevations (>4,000 m [>13,000 ft] above sea level), HAPE and HACE can occur more rapidly and at lower elevations than previously thought. Given the high mortality rate in delayed diagnosis of HAPE and HACE, it is imperative that physicians keep a high index of suspicion when potentially

susceptible individuals present. Once high-altitude sickness is diagnosed, prompt treatment is crucial to avoid life-threatening complications.

The authors attest that their institution requires neither Institutional Review Board approval, nor patient consent for publication of this case report. Documentation on file.

Address for Correspondence: Suneil Agrawal, MD, Desert Regional Medical Center, 1150 N. Indian Canyon Dr., Palm Springs, CA 92262. Email: Suneil.Agrawal@vituity.com

Conflicts of Interest: By the CPC-EM article submission agreement, all authors are required to disclose all affiliations, funding sources and financial or management relationships that could be perceived as potential sources of bias. The authors disclosed none.

Copyright: © 2024 Walsh et al. This is an open access article distributed in accordance with the terms of the Creative Commons Attribution (CC BY 4.0) License. See: <http://creativecommons.org/licenses/by/4.0/>

REFERENCES

1. Turner R, Gatterer H, Falla M, et al. High-altitude cerebral edema: its own entity or end-stage acute mountain sickness? *J Appl Physiol.* 2021;131(1):313–25.
2. Basnyat B and Murdoch DR. High-altitude illness. *Lancet.* 2003;361(9373):1967–74.
3. Bärtsch P and Swenson ER. Acute high-altitude illnesses. *N Engl J Med.* 2013;368(24):2294–302.
4. Luks AM, Swenson ER, Bärtsch P. Acute high-altitude sickness. *Eur Respir Rev.* 2017;26(143):160096.
5. Davis C and Hackett PH. Advances in the prevention and treatment of high altitude illness. *Emerg Med Clin North Am.* 2017;35(2):241–60.
6. Jensen J and Vincent AL. High Altitude Cerebral Edema. In: *StatPearls.* Treasure Island (FL): StatPearls Publishing; 2023. Available at: <https://www.ncbi.nlm.nih.gov/books/NBK430916/>. Accessed August 1, 2023.
7. Hackett PH, Yarnell PR, Weiland D, et al. Acute and evolving MRI of high-altitude cerebral edema: microbleeds, edema, and pathophysiology. *AJNR Am J Neuroradiol.* 2019;40(3):464–9.
8. Hackett PH and Roach RC. High altitude cerebral edema. *High Alt Med Biol.* 2004;5(2):136–46.
9. Luks AM, Auerbach PS, Freer L, et al. Wilderness Medical Society Clinical Practice Guidelines for the Prevention and Treatment of Acute Altitude Illness: 2019 update. *Wilderness Environ Med.* 2019;30(4):S3–18.
10. Kobayashi T, Koyama S, Kubo K, et al. Clinical features of patients with high-altitude pulmonary edema in Japan. *Chest.* 1987;92(5):814–21.
11. Hackett PH, Yarnell PR, Hill RN, et al. High-altitude cerebral edema evaluated with magnetic resonance imaging. *JAMA.* 1998;280(22):1920.
12. Long C and Bao H. Study of high-altitude cerebral edema using multimodal imaging. *Front Neurol.* 2023;13:1041280.
13. Koyama S, Kobayashi T, Kubo K, et al. The increased sympathoadrenal activity in patients with high altitude pulmonary edema is centrally mediated. *Jpn J Med.* 1988;27(1):10–6.

Acute Confusional Migraines: A Case Report

Devin M. Howell, DO*
Garrett Lamouree†

*Northwell Health, Department of Emergency Medicine, Huntington, New York
†Binghamton University, Binghamton, New York

Section Editor: Rachel Lindor, MD, JD

Submission history: Submitted November 4, 2023; Revision received January 17, 2024; Accepted January 26, 2024

Electronically published May 14, 2024

Full text available through open access at http://escholarship.org/uc/uciem_cpccem

DOI: 10.5811/cpcem.4918

Introduction: Acute confusional migraine (ACM) is a rare variant of migraine that is benign and self-resolving but difficult to diagnose. Without known causative pathophysiology and a lack of recognition in the International Classification of Headache Disorders (ICHD-3), ACM offers a puzzling clinical presentation. There currently is no standardized treatment for ACM, but with a growing anecdotal dataset there is the opportunity to formally recognize and establish protocols to improve patient care and outcomes.

Case Report: A 14-year-old female presented to the emergency department (ED) with acute onset of confusion, vision changes, right-sided weakness, and dysarthria one hour prior to arrival. A stroke workup at the initial ED offered no pertinent findings. The patient was transferred to a pediatric specialty ED where all symptoms, aside from numbness and a mild headache, resolved during transfer. After administration of a migraine cocktail at the pediatric specialty ED, all remaining symptoms completely resolved. The patient was discharged home from the ED the same evening with outpatient follow-up.

Conclusion: This case presents the difficulty of diagnosing and treating ACM prior to its self-resolution. It highlights the need for formal recognition of the condition by the ICHD-3. In doing so, greater recognition will promote more research, awareness, and establishment of a standardized treatment for ACM. [Clin Pract Cases Emerg Med. 2024;8(3)206–210.]

Keywords: *pediatric; migraine; confusion; stroke; case report.*

INTRODUCTION

Acute confusional migraine (ACM) afflicts all ages, with a predominance in children, and involves a suite of symptoms, including confusion, aphasia, and hemiplegia.¹ With no known causative pathophysiology and a lack of recognition in the International Classification of Headache Disorders (ICHD-3) as a migraine variant, knowledge of this disorder is limited among clinicians, making ACM an exclusionary diagnosis.¹ The clinical presentation of ACM offers a broad range of differential diagnoses, making it difficult to diagnose patients in the absence of an individual or family history of migraines.² Together, these aspects have likely led to underdiagnosis of ACM and a lack of standardized treatment.^{1,2}

We present the case of a 14-year-old female who presented to the emergency department (ED) with an acute onset of confusion, vision changes, right-sided weakness, and

dysarthria, which began one hour prior to arrival. Her symptoms were preceded by an incident of minor head trauma that occurred the day prior. Both the rarity of ACM and the discussion regarding ACM-associated head trauma make this case a unique account of the disorder.

CASE REPORT

A 14-year-old female presented to the ED with acute altered mental status. Per the mother, an hour prior to ED arrival, the patient had an acute onset of confusion with vision changes, followed by dysarthria and right-sided upper extremity weakness and numbness. It was discovered that the patient had suffered a minor head trauma from a backward fall the day prior without loss of consciousness or vomiting. She was not evaluated for her head trauma prior to the current visit. The patient had a history of intermittent headaches (not formally diagnosed) and a family history of

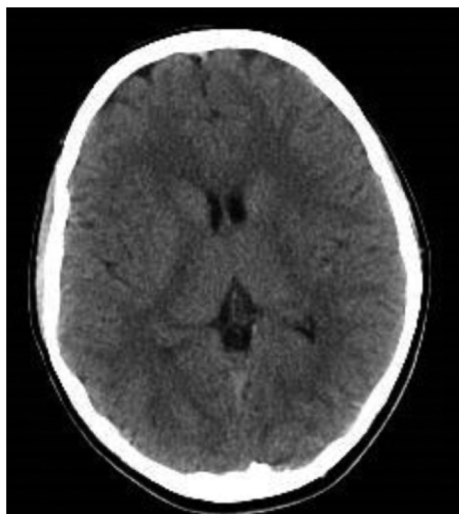


Image 1. Normal non-contrast computed tomography of the brain.

one episode of transient global amnesia in her mother. There was no other reported medical history or any prior psychiatric history. Upon presentation to the ED, the patient was not oriented to self and could not follow commands. Physical examination (PE) was completed with the patient responding “I don’t know” to most questions and commands aside from her name, a mild right pronator drift, and inability to follow additional commands, thereby limiting her examination. All other PE findings were unremarkable, including any signs of external trauma.

A National Institute of Health Stroke Scale (NIHSS) was calculated to be 6, and a code stroke was called. Deficits included level of consciousness, in that she only answered one question correctly (1) and performed neither task for level of consciousness commands correctly (2). Her motor function was hindered with right arm drift, with the limb holding 90 (or 45) degrees, but drifting down before the full 10 seconds, but not hitting the bed or support (1). Her final deficit was severe aphasia (2), with all communication through fragmented expression, which required a great need for inference, questioning, and guessing by the listener. The range of information that could be exchanged was limited; listener carried the burden of communication. Examiner could not identify materials provided from patient response.

Both a computed tomography (CT) ([Image 1](#)) and CT angiogram (CTA) ([Image 2](#)) of the brain were completed. No pertinent findings were yielded from the CTA; however, the non-contrast CT was read by neuroradiology as having a possible punctate focus of hemorrhage, which prompted further emergent imaging. This punctate focus was not appreciated by our team. A stat magnetic resonance imaging (MRI) of the brain was performed without significant findings ([Image 3](#)). Laboratory evaluation, including a complete blood count, comprehensive metabolic panel,

Population Health Research Capsule

What do we already know about this clinical entity?

Acute confusional migraine (ACM) can be treated with traditional migraine medications but may present with worrying symptoms, including significant neurological deficits.

What makes this presentation of disease reportable?

Acute confusional migraine is an under-reported stroke mimic that may present to the emergency department and should, therefore, be considered.

What is the major learning point?

Clinicians should be aware of ACM, particularly in children, to have a broader differential for those presenting with stroke-like symptoms.

How might this improve emergency medicine practice?

Through increased awareness of ACM, emergency physicians may be able to avoid unnecessary radiation and lab testing.

pregnancy test, urine toxicology, and serum drug screen, were completed with no remarkable findings.

During the initial ED visit, the patient’s clinical status remained unchanged aside from an episode where she

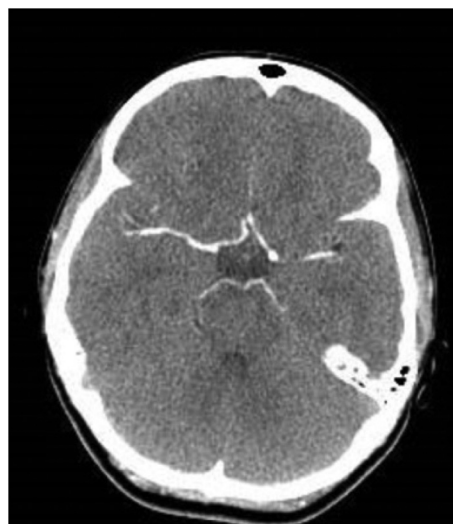

Image 2. Normal computed tomography angiography at the level of the circle of Willis.

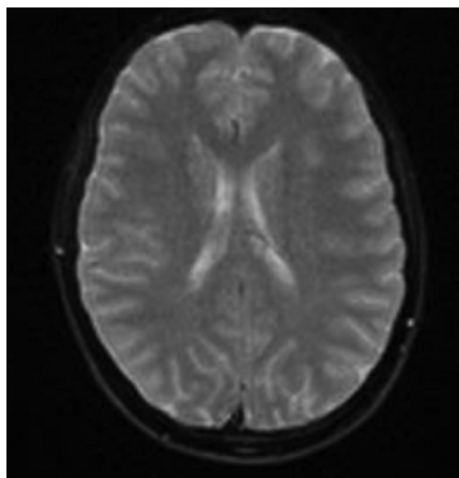


Image 3. Normal magnetic resonance imaging of the brain.

became somnolent, desaturating to 75% with good waveform and improving to 99% upon arousal. She appeared to be complaining of a headache and had one episode of vomiting; therefore, 1000 milligrams (mg) of acetaminophen and 4 mg of ondansetron were administered intravenously.

Thrombolytics, such as tissue plasminogen activator or tenecteplase, were not administered throughout patient care, as neither have been studied in pediatric patients.³

Interfacility transport to a specialty pediatric hospital for pediatric neurology consultation and medical admission was arranged at that time.

During transport, all symptoms resolved aside from a headache and mild numbness of the right arm. Upon arrival at the pediatric ED, the patient was able to speak in complete sentences, and her NIHSS improved to 0. The patient was given a migraine cocktail of 25 mg ketorolac, 1000 milliliters normal saline, and 7 mg prochlorperazine intravenously. Following administration, the patient stated improvement in headache, thus concluding her symptoms, which in total lasted approximately 6.5 hours. Following a formal pediatric neurology consult, the working diagnosis was ACM. The patient was considered stable and was subsequently discharged that evening with an anticipated outpatient pediatric neurology appointment in one to two weeks.

DISCUSSION

The diagnostic and treatment route chosen for this patient highlights the difficulty of clinical presentation to differentiate from other serious diagnoses, including cerebral infarction, intracranial hemorrhage, nonconvulsive status epilepticus, and encephalitis, among others.¹ Ischemic pediatric strokes have an incidence rate of 1.2–13/100,000, making them exceedingly rare.⁴ However, with a 10% mortality rate and the critical consequence of neurological impairment in development, pediatric strokes are a serious medical emergency.⁴

Aside from astute history-taking, one of the few promising diagnostic tests to diagnose ACM is an electroencephalogram (EEG). In previous studies, EEG has shown slowing in 49 of 50 patients during the onset of symptoms through the retrospective study of patients with confusional migraines; therefore, we recommend the use of EEG in these patients, if capable.¹ Beyond an EEG, no other diagnostic modality offers an indication for ACM until the benign resolution of symptoms, a characteristic of ACM known since the cases first recorded by Gascon and Barlow.⁵ Therefore, without any significant patient or family history beyond her mother's transient global amnesia episode, or the capability of performing a spot EEG, a CT without contrast, CTA, and MRI were completed to rule out serious disease.

Prior to the onset of the patient's ACM, the patient noted a fall backward in which she hit her head without loss of consciousness or vomiting. Although the pathophysiology has not been confirmed, literature review has shown that the onset of ACM is preceded by mild head trauma in 37% of patients.¹ Some proposed mechanisms for ACM via mild head trauma include isolated cerebral edema and cortical spreading depression (CSD), inducing a temporary state of brainstem dysfunction.^{6,7} In these instances of mild, trauma-induced ACM, the typical time from traumatic injury to onset of ACM is seconds to approximately four hours, putting our patient's fall well outside the typical timeframe of onset.¹

While considering the CSD mechanism, in a retrospective study of 143 migraine patients 72.2% of those suffering migraines with aura reported deficits in higher brain function.⁷ With research demonstrating an association of migraine auras with CSD, it is plausible that the higher function deficits seen in cases of ACM are caused by CSD, thereby allowing ACM to be seen as a complex form of aura.⁸ However, with formal recognition and a standardized treatment for ACM lacking within the ICHD-3, the discussion now is whether ACM should have its own distinction.

Through retroactive studies it has been shown that of 2,509 diagnosed patients within a neuropaediatric ward, 2.7% of the migraine diagnoses qualified as ACM.⁹ Without the specific classification criteria to diagnose these patients, diagnostic uncertainty can prevail, leading to misdiagnosis and underdiagnosis, especially amongst adults with a new diagnosis of migraine.¹⁰ Similarly, with the use of techniques such as CT, pediatric patients are put at a higher risk of malignancy following exposure to ionizing radiation.¹¹ The use of CT highlights how diagnostic tools can potentially be hazardous, in addition to delaying diagnosis and treatment. Should a patient have a pertinent history for ACM, excessive diagnostics should be avoided, a viewpoint that has been held since ACM's identification in the 1970s and well into the 21st century.^{12,13}

Should ACM earn classification within the ICHD-3, further formal research would likely occur to seek out a standardized treatment for episodes. To date, due to its rarity, knowledge of ACM is primarily limited to case reports, meaning standardized treatment has yet to be determined. Although, considering ACM as a migraine variant, case studies have shown success with traditional migraine treatment with sodium valproic acid.¹⁴ In this case, most symptoms self-resolved; however, the administration of a migraine cocktail including ketorolac, normal saline, and prochlorperazine did show improvement in the patient's residual symptoms, supporting that traditional migraine treatments are effective for ACM.

It should be noted that although there is not enough research on ACM in particular, migraines are often associated with a variety of comorbidities, ranging from psychiatric disorders to epilepsy, as well as different means of cardiovascular compromise. For this reason, it is important to recognize as it may limit patient care options, and with future research could offer greater insight into the mechanism by which ACM arises.¹⁵

With the aforementioned in mind, it is important to consider the clinical approach for ACM. With a pediatric patient presenting with altered mental status, one must begin to rule out the broad spectrum of differential diagnoses. A complete set of vital signs, including rectal temperature (as appropriate) and blood glucose should be obtained. Thorough history-taking should be performed from the patient and/or any bystanders, to include relevant medical, surgical, psychiatric, and familial history. Care must be taken to also obtain potential ingestions, including those that are accidental, such as medications, drugs (edibles), environmental (carbon monoxide, chemical, cleaning products), etc. A thorough physical exam should elicit any signs of trauma, a complete neurologic exam, evaluation of the cardiac and respiratory systems, and a skin examination. The approach to laboratory testing should include the following, if relevant: complete blood cell count; complete metabolic panel; urinalysis; urine and serum toxicology studies; thyroid function tests; and cerebrospinal fluid testing. If concern exists for intracranial pathology, neuroimaging should not be delayed and a spot EEG can be performed, if available.

To pursue a route of treatment for a patient with suspected ACM, traditional migraine medications have shown promise. Treatment options may include the following: sodium valproic acid, prochlorperazine with or without diphenhydramine, metoclopramide, dihydroergotamine, triptans, ketorolac, steroids, or normal saline. Patients with ACM will classically see full resolution of symptoms without any lasting consequences after receiving treatment. Even with complete resolution, patients may be admitted for formal EEG monitoring or discharged with close outpatient neurology follow-up.

CONCLUSION

Acute confusional migraines are a rare variant of migraine that primarily afflicts children. Lack of awareness of the disease, however, poses risks for delayed diagnosis, delayed treatment, and excessive diagnostic tests in pediatric patients. This case contributes to the growing collection of ACM episodes that continues to validate the argument for recognition of ACM by the ICHD-3. Clinically, ACM poses a challenge to diagnose; therefore, without a pertinent patient or family history, further diagnostics should be carried out to rule out serious disease. With cases of ACM, although the episodic symptoms are severe, physicians should find solace in knowing they are benign and self-resolving, and that traditional migraine treatments show promise in reducing or resolving symptoms.

The authors attest that their institution requires neither Institutional Review Board approval, nor patient consent for publication of this case report. Documentation on file.

Address for Correspondence: Devin M. Howell, DO, Northwell Health, 270 Park Avenue, Huntington, NY 11743. Email: Dhowell6@northwell.edu

Conflicts of Interest: By the *CPC-EM* article submission agreement, all authors are required to disclose all affiliations, funding sources and financial or management relationships that could be perceived as potential sources of bias. The authors disclosed none.

Copyright: © 2024 Howell et al. This is an open access article distributed in accordance with the terms of the Creative Commons Attribution (CC BY 4.0) License. See: <http://creativecommons.org/licenses/by/4.0/>

REFERENCES

1. Schipper S, Riederer F, Sándor PS, et al. Acute confusional migraine: our knowledge to date. *Expert Rev Neurother.* 2012;12(3):307–14.
2. Ehyai A and Fenichel GM. The natural history of acute confusional migraine. *Arch Neurol.* 1978;35(6):368–9.
3. Center for Drug Evaluation and Research. About drugs@fda. U.S. Food and Drug Administration. Available at: <https://www.fda.gov/drugs/drug-approvals-and-databases/about-drugsfda>. Accessed November 19, 2023.
4. Tsze DS and Valente JH. Pediatric stroke: a review. *Emerg Med Int.* 2011;2011:734506.
5. Gascon G and Barlow C. Juvenile migraine, presenting as an acute confusional state. *Pediatrics.* 1970;45(4):628–35.
6. Shaabat A. Confusional migraine in childhood. *Pediatr Neurol.* 1996;15(1):23–5.
7. Vincent M and Hadjikhani N. Migraine aura and related phenomena: beyond scotomata and scintillations. *Cephalalgia.* 2007;27(12):1368–77.

8. Hadjikhani N, Sanchez del Rio M, Wu O, et al. Mechanisms of migraine aura revealed by functional MRI in human visual cortex. *Proc Natl Acad Sci U S A*. 2001;98(8):4687–92.
9. Pacheva I and Ivanov I. Acute confusional migraine: Is it a distinct form of migraine? *Int J Clin Prac*. 2013;67(3):250–6.
10. Fisher CM. Late-life migraine accompaniments as a cause of unexplained transient ischemic attacks. *Can J Neurol Sci*. 1980;7(1):9–17.
11. Meulepas JM, Ronckers CM, Smets AM, et al. Radiation exposure from pediatric CT scans and subsequent cancer risk in the Netherlands. *J Natl Cancer Inst*. 2018;111(3):256–63.
12. Emery ES. Acute confusional state in children with migraine. *Pediatrics*. 1977;60(1):110–4.
13. Farooqi A, Padilla J, Monteith T. Acute confusional migraine: distinct clinical entity or spectrum of migraine biology? *Brain Sci*. 2018;8(2):29.
14. Fujita M, Fujiwara J, Maki T, et al. The efficacy of sodium valproate and a MRA finding in confusional migraine. *Brain Dev*. 2007;29(3):178–81.
15. Scher AI, Bigal ME, Lipton RB. Comorbidity of migraine. *Curr Opin Neurol*. 2005;18(3):305–10.

Spontaneous Osteomyelitis and Intraosseous Abscess: A Case Report

Meghan Chamberlain, MD
Simon A. Sarkisian, DO

Cooper University Hospital, Department of Emergency Medicine, Camden, New Jersey

Section Editor: Manish Amin, DO

Submission history: Submitted November 17, 2023; Revision received January 26, 2024; Accepted January 29, 2024

Electronically published June 3, 2024

Full text available through open access at http://escholarship.org/uc/uciem_cpccem

DOI: [10.5811/cpcem.6568](https://doi.org/10.5811/cpcem.6568)

Introduction: Acute hematogenous osteomyelitis may have significant morbidity and mortality if undiagnosed. Because it is uncommon in developed countries and has variable presentations, the patient may undergo several healthcare visits prior to diagnosis.

Case Report: We report the case of a 9-year-old male who presented with hip and knee pain with associated fevers and was found to have osteomyelitis and intraosseous abscess in the diaphysis of the right femur. He had multiple emergency department and outpatient visits before the ultimate diagnosis was made. He was treated with irrigation and debridement in addition to intravenous antibiotics.

Conclusion: Pediatric acute hematogenous osteomyelitis can have subtle presentations, and this case illustrates some of the difficulties in making the diagnosis. This condition should be considered in the workup of a child with undifferentiated fever, pain, or decrease in mobility. [Clin Pract Cases Emerg Med. 2024;8(3)211–214.]

Keywords: *osteomyelitis; intraosseous abscess; pediatric; case report.*

INTRODUCTION

Acute hematogenous osteomyelitis is caused by bacteria proliferating within the bone. It occurs from hematogenous spread, where episodes of bacteremia combine with turbulent flow at the metaphyseal arteriolar-venous sinusoid transition to allow local invasion. These episodes occur more commonly during childhood, as the immature bone is less capable of containing infection. Most cases involve children younger than five years of age.¹ Local trauma contributes to risk of hematogenous infection, presumed to be secondary to microvascular bleeding and stasis. After age one, male children are much more likely to sustain minor trauma than female children, which may explain why osteomyelitis disproportionately affects males.² Other causes include direct inoculation from a procedure or trauma such as intraosseous access or spread from surrounding tissues.

In older patients, the bones are thicker and the periosteum is denser; so osteomyelitis is more likely to cause formation of an intraosseous abscess. Infections are predominantly caused by *Staphylococcus aureus*, with about one third

being methicillin resistant.³ Patients with sickle hemoglobinopathies are at specific risk for infection from salmonella.⁴ Patients can have a variety of presentations including fevers, irritability, decreased extremity function, point tenderness, swelling, and warmth. Because *S aureus* has variable growth and the inoculum may be small, the clinical course may be indolent and patients may present without fever or with only low-grade fever. Risk factors include sickle cell disease or any immunocompromised state, sepsis, minor trauma, and indwelling vascular catheters.⁵

CASE REPORT

A nine-year-old male with history of Hashimoto thyroiditis and Raynaud disease presented to the emergency department (ED) for intermittent right hip and knee pain, daily fevers, and difficulty with ambulation for 16 days. He had no prior history of injury to the leg or of intraosseous access. He had initially presented to a different ED on day 10 of illness where he had a normal hip radiograph and labs. The patient was evaluated for

autoimmune and tick-borne illnesses. He was then referred to an infectious disease specialist whom he saw on day 16. The patient was ultimately sent to our ED for further evaluation and imaging.

Vital signs were notable for a temperature of 37.9° Celsius orally and heart rate of 155 beats per minute. On physical exam, the patient had no tenderness to palpation of the right lower extremity, normal range of motion of all joints, and was able to ambulate and jump without pain. No swelling of the hip or overlying skin changes were noted. The patient's laboratory testing was notable for C-reactive protein (CRP) elevated at 16.82 milligrams per deciliter (mg/dL) (reference range 0.3–1.0 mg/dL), erythrocyte sedimentation rate (ESR) above assay limits at greater than 100 millimeters per hour (mm/hr) (10–15 mm/hr in males, 0–20 mm/hr in females), but no leukocytosis. Radiographs of his right hip, right knee, and right femur were unremarkable (Image 1).

The patient was admitted for further evaluation and found to have continued intermittent fevers and right lower extremity pain. On Day 17, he had magnetic resonance imaging (MRI) of the right lower extremity with and without contrast, which revealed right femoral osteomyelitis with underlying intraosseous abscess (Image 2). He was taken to the operating room for a right femur reaming and irrigation with debridement. Blood and tissue cultures grew methicillin susceptible *S aureus*, and workup was notable for an echocardiogram without evidence of vegetation and abdominal ultrasound without evidence of an intra-abdominal source of infection. He received intravenous

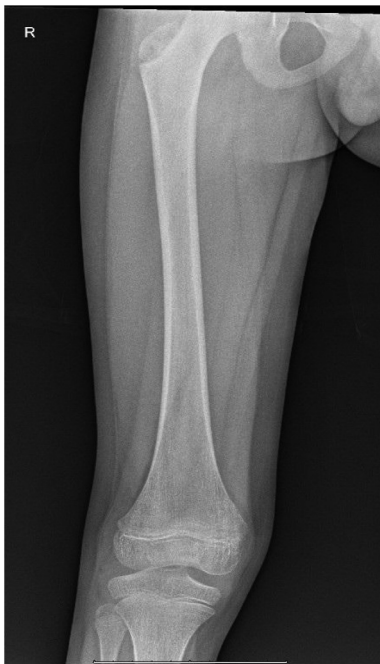

Image 1. Radiograph of the right femur upon emergency department presentation with no acute abnormalities.

Population Health Research Capsule

What do we already know about this clinical entity?

Acute hematogenous osteomyelitis is well characterized in the literature with regard to the physiology, epidemiology, presentation, and management.

What makes this presentation of disease reportable?

Aside from the reported history, this pediatric patient had a clinically benign presentation of this uncommon disease process.

What is the major learning point?

Consider diagnosis of acute hematogenous osteomyelitis in patients with localized pain and recurrent fever, even if the physical exam is underwhelming.

How might this improve emergency medicine practice?

Clinicians should consider this diagnosis more frequently and consider more intensive evaluation.

cefazolin for 30 days and was then transitioned to two weeks of oral antibiotics, starting with doxycycline, which was then changed to oral levofloxacin due to side effects. His inflammatory markers were trended throughout therapy until they normalized. Patient had resolution of his symptoms and was able to ambulate without abnormality.

DISCUSSION

Acute hematogenous osteomyelitis is uncommon, with an estimated incidence of eight per 100,000 children per year.³ Diagnosis can be subtle, and patients often present with pain that is not well localized and without signs of local infection. Patients typically present within one week of onset, but diagnosis can require multiple visits, as occurred with our case.⁶

A systemic review of the literature by Darnell et al found that presenting symptoms were most commonly pain (81.1%), localized signs or symptoms of infection, such as warmth, point tenderness, or swelling (70%), fever (61.7%), reduced range of motion (50.3%), and reduced weight-bearing (49.3%). The most common laboratory abnormalities were elevated inflammatory markers (ESR 91%, CRP 80.5%), with or without leukocytosis (35.9%). They also found that initial imaging was limited with

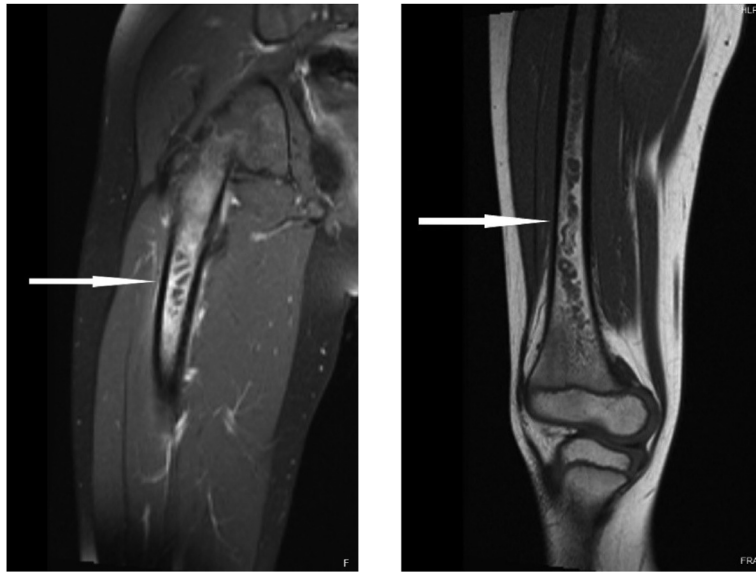


Image 2. Magnetic resonance imaging of the right femur with contrast demonstrating lesions in the proximal (left) and mid (right) femoral diaphysis (arrows).

sensitivity of radiograph 16–20%, computed tomography (CT) 67%, ultrasound 55%, while other imaging modalities had significantly better sensitivity with bone scan 53–100% and MRI 80–100%. The decision to perform MRI with contrast in children is controversial as there is no evidence that contrast improves sensitivity or specificity of detection.⁷ Because MRI requires deep sedation or general anesthesia in young children, children with concerning clinical or lab findings are usually hospitalized for close monitoring and/or treatment pending MRI imaging.

In a systematic review examining intraosseous abscess (termed Brodie abscess) by Van der Naald et al, 407 patients were examined. Of these, the median time to diagnosis from initial complaint was 12 weeks with primary presenting complaints of pain (98%) and swelling (53%). Patients typically had full resolution of symptoms; however, two of the included patients (0.5%) had lasting sequelae from bony destruction: limb shortening, and vertebral body collapse complicated by neurologic deficits.³

This case demonstrates the difficulties in evaluating for this condition. While the patient's history was concerning for possible infection, upon presentation to the ED he did not have any localizing exam findings to suggest underlying infection and had no identifiable risk factors for development of this condition. This case was uniquely difficult as well given that the abscesses were localized to the diaphysis of the bone, whereas lesions are typically located in the metaphysis or epiphysis. Further complicating the diagnosis was the patient's history of autoimmune conditions, namely Hashimoto thyroiditis and Raynaud syndrome, which suggested a possible autoimmune etiology of his symptoms. There is no established relationship between the development

of osteomyelitis and these conditions. The differential for this presentation is extensive and includes tick-borne illnesses, autoimmune conditions, musculoskeletal injuries, and infection.

CONCLUSION

Acute hematogenous osteomyelitis can have serious consequences if undiagnosed, including sepsis and bony destruction. Not all patients will have identifiable risk factors and presentations may be subtle. Many patients will lack focal tenderness or swelling on exam, and the diagnosis should be considered in patients who have recurrent fevers or complain of localized pain.

The authors attest that their institution requires neither Institutional Review Board approval, nor patient consent for publication of this case report. Documentation on file.

Address for Correspondence: Meghan Chamberlain, MD, Cooper University Hospital, Department of Emergency Medicine, 401 Haddon Avenue, Camden, New Jersey 08103. Email: Chamberlain-meghan@cooperhealth.edu

Conflicts of Interest: By the *CPC-EM* article submission agreement, all authors are required to disclose all affiliations, funding sources and financial or management relationships that could be perceived as potential sources of bias. The authors disclosed none.

Copyright: © 2024 Chamberlain et al. This is an open access article distributed in accordance with the terms of the Creative Commons Attribution (CC BY 4.0) License. See: <http://creativecommons.org/licenses/by/4.0/>

REFERENCES

1. Sonnen GM and Henry NK. Pediatric bone and joint infections: diagnosis and antimicrobial management. *Pediatr Clin*. 1996;43(4):933–47.
2. Rivara FP, Bergman AB, LoGerfo JP, et al. Epidemiology of childhood injuries: II. Sex differences in injury rates. *Am J Dis Child*. 1982;136(6):502–6.
3. Van der Naald N, Smeeing DP, Houwert RM, et al. Brodie's abscess: a systematic review of reported cases. *J Bone Joint Infect*. 2019;4(1):33–9.
4. Burnett MW, Bass JW, Cook BA. Etiology of osteomyelitis complicating sickle cell disease. *Pediatr*. 1998;101(2):296–7.
5. Riise ØR, Kirkhus E, Handeland KS, et al. Childhood osteomyelitis-incidence and differentiation from other acute onset musculoskeletal features in a population-based study. *BMC Pediatr*. 2008;8:45.
6. Woods CR, Bradley JS, Chatterjee A, et al. Clinical practice guideline by the Pediatric Infectious Diseases Society and the Infectious Diseases Society of America: 2021 guideline on diagnosis and management of acute hematogenous osteomyelitis in pediatrics. *J Pediatr Infect Dis Soc*. 2021;10(8):801–44.
7. Dartnell J, Ramachandran M, Katchburian M. Haematogenous acute and subacute paediatric osteomyelitis: a systematic review of the literature. *J Bone Joint Surg Br*. 2012;94(5):584–95.

A Case Report of Wunderlich Syndrome Causing Massive Hemorrhage During Hemodialysis

Karalee Bluhm, MD
Ravali Kundeti, DO
Nicole Maguire, DO

Rutgers-RWJBH- Community Medical Center, Department of Emergency Medicine,
Toms River, New Jersey

Section Editor: R. Gentry Wilkerson, MD

Submission history: Submitted November 26, 2023; Revision received January 25, 2024; Accepted January 31, 2024

Electronically published May 14, 2024

Full text available through open access at http://escholarship.org/uc/uciem_cpccem

DOI: 10.5811/cpcem.1891

Introduction: Wunderlich syndrome (WS) refers to subcapsular, perirenal, or pararenal hemorrhage due to non-traumatic and iatrogenic conditions. Neoplasms, vascular disease, renal etiology, and anticoagulant use are underlying risk factors.

Case Report: We describe a case of WS in a 79-year-old male who was undergoing hemodialysis, which resulted in hemorrhagic shock requiring multiple transfusions and embolization by interventional radiology.

Conclusion: Most commonly, patients present with flank pain; a computed tomography with contrast of the abdomen is essential for diagnosis. Surgical intervention is considered in hemodynamically unstable patients. Conservative therapy and intravenous resuscitations with blood products are considered a priority in hemodynamically stable patients. [Clin Pract Cases Emerg Med. 2024;8(3)215–218.]

Keywords: *Wunderlich syndrome; hemorrhagic shock; renal emergency; case report; dialysis.*

INTRODUCTION

Wunderlich syndrome (WS) is a rare but life-threatening condition defined as acute-onset, spontaneous, non-traumatic renal hemorrhage into the subcapsular, perirenal, or pararenal spaces. Fewer than 300 documented cases have been reported between 1974–2016. It is characterized by the Lenk triad: acute flank pain, flank mass, and hypovolemic shock.¹ However, the clinical manifestations can be varied and nonspecific. Presence of all three components of the triad is uncommon, occurring in only 20% of cases. Abdominal and flank pain are the most frequent symptoms, occurring in 67% of patients, followed by hematuria (40%) and hemorrhagic shock (26.5%).²

Approximately 60–65% of cases are related to renal neoplasms, with angiomyolipoma leading benign neoplasm causes and renal cell carcinoma the main cause of malignant neoplasms. The overall prevalence of WS as a complication of renal cell carcinoma occurs in only 0.3–1.4% of cases, whereas it is estimated to occur in 13–100% of cases of renal angiomyolipoma.³ Other causes include tuberous sclerosis,

vascular lesions (eg, polyarteritis nodosa), arteriovenous malformations, renal artery aneurysms, ruptured renal cysts, renal calculi, and coagulopathy.⁴ Wunderlich syndrome is often associated with hypertension (33–50%) and atherosclerosis (80–87%).³ Wunderlich syndrome has a slight male preponderance with an average age of 46.8 years, with most cases occurring between 30–60 years.²

Traditionally, the management has ranged from symptomatic care and observation to partial or complete nephrectomy. Currently, the treatment of choice includes stabilization and transcatheter arterial embolization (TAE), but this depends on the severity of presentation or underlying cause of WS. Surgical treatment or curative nephrotomy is preferred in patients with diagnosed renal malignancy, in cases of hemodynamic instability, and/or failed TAE.^{4,5}

We present the case of a 79-year-old male who presented with a spontaneous left renal subcapsular hematoma and an active perinephric hemorrhage that occurred during hemodialysis, leading to hemorrhagic shock requiring multiple blood transfusions and arterial embolization.

CASE REPORT

A 79-year-old male presented to the emergency department with 30 minutes of acute and worsening abdominal pain that occurred suddenly during the first hour of his scheduled hemodialysis. He described the pain as sharp, cramping, stabbing, constant, and diffuse but worse in the left upper quadrant and flank and associated with acute abdominal distention. He denied any recent trauma, chest pain, shortness of breath, paresthesias, nausea, vomiting, or urinary complaints.

His past medical history included end-stage renal disease (on hemodialysis), type 2 diabetes mellitus, chronic obstructive pulmonary disease, hypertension, hyperlipidemia, and hypothyroidism. On chart review it was noted that there was a history of left renal cyst, last measuring 6.8 centimeters (cm) × 5.5 cm × 5.3 cm four years prior to presentation found incidentally on computed tomography (CT). Follow-up renal ultrasound was ordered but never obtained. The patient's chronic kidney disease was related to his diabetes and poorly controlled hypertension that required treatment with four antihypertensive medications. His surgical history included two unspecified hernia repairs, bilateral knee replacements, loop recorder placement, and small bowel resection due to small bowel obstruction 15 years previously. His social history included daily alcohol use, and he was a non-smoker who lived with family and was retired.

Initial vital signs revealed slight hypotension with blood pressure of 98/42 millimeters of mercury; otherwise, vitals were within normal limits. The patient had been awake and alert, in obvious distress due to pain, and having difficulty sitting still. Abdominal exam was notable for being obese with rigidity, distention, diffuse tenderness, guarding, and without appreciable bowel sounds, rebound tenderness, or ecchymosis. The remainder of his exam was unremarkable.

A point-of-care ultrasound (POCUS) revealed a grossly positive focused assessment with sonography for trauma (FAST) in Morrison's pouch and splenorenal recess, with limited subxiphoid and suprapubic views. He was treated with fentanyl intravenously and bolused with normal saline. The CT angiogram of the abdomen and pelvis was notable for an 18-cm left renal subcapsular hematoma and hemorrhage in the left perinephric space with active contrast blush coming from the left renal segmental and interlobar branches (Images 1 and 2). There were also multiple sclerotic lesions of the thoracic and lumbar spine indicating possible metastasis. Pertinent lab values included white blood cell count of $14.6 \times 10^3/\mu\text{L}$ (reference range $4.3\text{--}12.0 \times 10^3/\mu\text{L}$), with 83% neutrophils (5–13%), hemoglobin 7.8 grams per deciliter (g/dL) (13.4–17.4 g/dL), hematocrit 24.1% (40–54%), platelets $271 \times 10^3/\mu\text{L}$ ($150\text{--}440 \times 10^3/\mu\text{L}$), international normalized ratio 1.09 (0.83–1.11), partial thromboplastin time 29.3 seconds (21.5–31.9 seconds), prothrombin time 12.7 seconds

Population Health Research Capsule

What do we already know about this clinical entity?

In patients with risk factors, Wunderlich syndrome (WS) may present as the Lenk triad: acute flank pain, flank mass, and hypovolemic shock due to renal hemorrhage.

What makes this presentation of disease reportable?

Fewer than 300 reported cases of WS have been reported between 1974–2016. It has never been reported in patients actively undergoing hemodialysis.

What is the major learning point?

Presentation varies from vague to life-threatening. Prompt computed tomography will aid in diagnosis; treatment ranges from supportive to surgical management.

How might this improve emergency medicine practice?

This rare presentation of WS highlights the importance of a wide differential in those presenting with the Lenk triad.

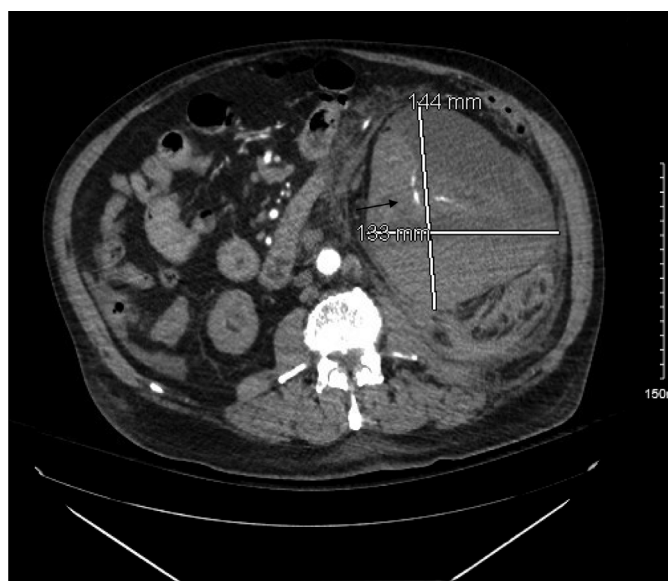

Image 1. Axial view of computed tomography angiogram of the abdomen showing large left renal hematoma with contrast blush (arrow) suggestive of active bleeding. mm, millimeter.

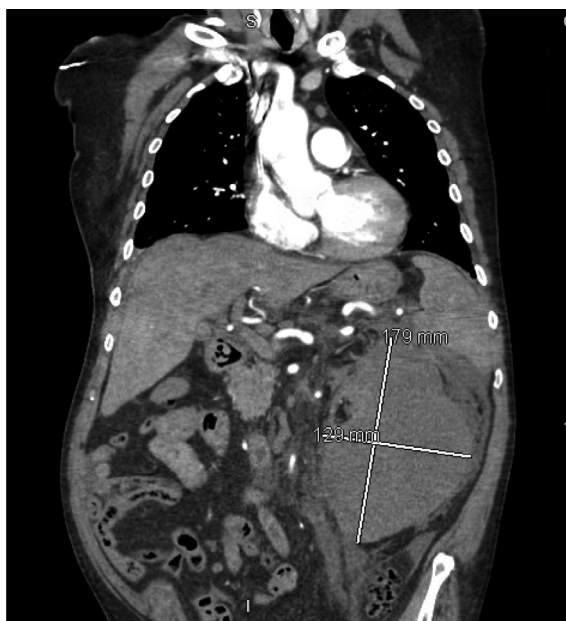

Image 2. Coronal view of computed tomography angiogram of the abdomen and pelvis showing large left renal subcapsular hematoma and hemorrhage.
mm, millimeter.

(10–13 seconds), point-of-care lactic acid 2.4 millimoles per liter (mmol/L) (0.0–2.0 mmol/L), glucose 204 milligrams per deciliter (mg/dL) (60–110 mg/dL), blood urea nitrogen 47 mg/dL (8–25 mg/dL), and creatinine 7.13 mg/dL (0.5–1.12 mg/dL).

While awaiting interventional radiology for renal embolization, the patient clinically deteriorated requiring emergent central line placement and two units of uncross-matched blood administered by pressure infuser and warmer for hypotension and active bleeding. During embolization, multiple branches of the left kidney including upper pole, mid-pole and lower pole subsegmental arteries, as well as interlobular and arcuate arteries at all three junctures, were selected and embolized with good angiographic result and no evidence of extravasation at the termination of the procedure. The patient was then admitted to the surgical intensive care unit for monitoring. He maintained stable blood pressures and was discharged home after four nights in the hospital.

After discharge, he was sent for hematology and oncology referral and positron emission tomography due to incidental findings on his CT during the current admission. However, the patient returned three days after discharge with hypoglycemia, severe anemia, and active upper gastrointestinal bleed. He underwent an esophagogastroduodenoscopy and exploratory laparotomy but ultimately died due to complications of the gastrointestinal bleed within three days of his subsequent admission. There was no further oncological workup performed.

DISCUSSION

Wunderlich syndrome is a rare condition, but its occurrence in a dialyzed patient is extremely rare with only a handful of other reports in the literature.^{5,6} Wunderlich syndrome occurring during hemodialysis has never previously been reported. Our case is an uncommon example of WS as it occurred in a patient with end-stage renal disease during dialysis without a known history of malignancy that resulted in significant hemodynamic instability requiring emergent transfusion, embolization, and intensive care admission. Computed tomography with contrast or CT angiogram are the diagnostic tests of choice,⁷ but POCUS is useful in identifying intra-abdominal fluid, which may be hemorrhage.

Although the images in this report do not demonstrate fluid around the liver, POCUS exam swiftly revealed a more diffuse, intra-abdominal hemorrhage as demonstrated by the positive FAST exam, indicating that the blood had escaped the retroperitoneal perinephric Gerota fascia into the peritoneal cavity. Unfortunately, we were not able to save the ultrasound images. The use of ultrasound, while not novel, did substantially reduce the time taken from commencing care to definitive treatment. Treatment is based on the patient's condition, but stabilization and transcatheter arterial embolization are standard of care for WS causing hemorrhagic shock.^{8,9}

Our patient had several risk factors that may have contributed to the development of WS. He had a history of hypertension, renal cysts, diabetic nephropathy, and atherosclerosis. Additionally, he had a daily aspirin regimen, which might have exacerbated his outcome. A previous case of bleeding into a simple renal cyst causing hemorrhagic shock without other risk factors known to WS has been reported.⁸ Hemorrhage in our patient was located in the kidney, which had the background of renal cysts, suggesting non-malignant kidney masses as a nidus for hemorrhage that is consistent with literature review.

Furthermore, it is possible that he had an undiagnosed metastatic cancer as evidenced by lesions noted incidentally on CT. Further workup was unobtainable due to clinical deterioration. The relative risk of renal cell carcinoma in hemodialysis patients was found to be 13.3 to 29-fold higher than in normal subjects, and hemodialysis patients have a risk of 2.3–3.3% of developing renal cell carcinoma.⁶ An autopsy was not performed; therefore, biopsy of the lesion was not obtained.

The patient was on daily aspirin but otherwise was not receiving anticoagulation. His subsequent admission also revealed massive bleeding; so, it is possible there was some underlying hematological component that was causing or contributing to his bleeding diathesis. Daily alcohol use also may be a risk factor for WS or the severity of presentation. However, urologists have documented that uremic patients have a bleeding tendency associated with platelet

dysfunction¹⁰ because platelets in uremic patients have a reduced aggregating response to adenosine diphosphate, epinephrine, and collagen.¹¹ Hemodialysis patients, therefore, are more likely to have more severe bleeding, and treatment should include consideration of one or a combination of the following: cryoprecipitate, desmopressin, and conjugated estrogens.¹²

Due to our patient's sudden presentation during hemodialysis, we considered whether hemodialysis may have been a risk factor causing enough shifts in pressure to lead to spontaneous atraumatic renal hemorrhage. Very few cases of WS occur in hemodialysis patients; therefore, this subset of patients with WS risk factors has a higher likelihood of developing WS, particularly if they present with elements of the Lenk triad.

CONCLUSION

Wunderlich syndrome is a rare but important differential to consider in atraumatic flank and abdominal pain. Mild presentations can easily be misdiagnosed as back pain, urolithiasis, or renal infections; so, keeping this process in one's differential, especially in patients with risk factors, is important in obtaining the diagnosis. Point-of-care ultrasound, CT, and CT angiogram are paramount in identifying intraperitoneal free fluid and active hemorrhage. Although several cases of WS have been effectively managed conservatively, patients such as ours can suffer from hemorrhagic shock resulting from the syndrome.

Patient consent has been obtained and filed for the publication of this case report.

Address for Correspondence: Karalee Bluhm, MD, Rutgers-RWJBH-Community Medical Center, Department of Emergency Medicine, 99 Route 37 West, Toms River, NJ 08755.
Email: Karalee.Bluhm@rwjbh.org

Conflicts of Interest: By the CPC-EM article submission agreement, all authors are required to disclose all affiliations, funding sources and financial or management relationships that could be perceived as potential sources of bias. The authors disclosed none.

Copyright: © 2024 Bluhm et al. This is an open access article distributed in accordance with the terms of the Creative Commons Attribution (CC BY 4.0) License. See: <http://creativecommons.org/licenses/by/4.0/>

REFERENCES

1. Parmar N, Langdon J, Kaliannan K, et al. Wunderlich syndrome: wonder what it is. *Curr Probl Diagn Radiol.* 2022;51(2):270–81.
2. Grubb SM, Stuart JI, Harper HM. Sudden onset flank pain: spontaneous renal rupture. *Am J Emer Med.* 2017;35(11),1787.e1–e3.
3. Wang BH, Pureza V, Wang H. A tale of Wunderlich syndrome. *J of Surg Case Rep.* 2012;2012(11):rjs015.
4. Kim JW, Kim JY, Ahn ST, et al. Spontaneous perirenal hemorrhage (Wunderlich syndrome): an analysis of 28 cases. *Am J Emer Med.* 2019;37(1):45–7.
5. Tzu-Cheng W, Kuo-Hua L, Pin-Fang C, et al. Bilateral spontaneous massive renal hemorrhage in a peritoneal dialysis patient: a case report. *Medicine (Baltimore).* 2021;100(44):e27549.
6. Kawahara T, Kawahara K, Ito H, et al. Spontaneous renal hemorrhage in hemodialysis patients. *Case Rep Nephrol Urol.* 2011;1(1):1–6.
7. Zagoria RJ, Dyer RB, Assimos DG, et al. Spontaneous perinephric hemorrhage: Imaging and management. *J of Urol.* 1991;145(3):468–71.
8. Blakeley CJ and Thiagalingham N. Spontaneous retroperitoneal haemorrhage from a renal cyst: an unusual cause of haemorrhagic shock. *Emerg Med J.* 2003;20(4):388.
9. Albi G, Del Campo L, Tagarro D. Wunderlich's syndrome: causes, diagnosis and radiological management. *Clin Radiol.* 2002;57(9):840–5.
10. Di Minno G, Martinez J, McKean ML, et al. Platelet dysfunction in uremia. Multifaceted defect partially corrected by dialysis. *Am J Med.* 1985;79(5):552–9.
11. Evans EP, Branch RA, Bloom AL. A clinical and experimental study of platelet function in chronic renal failure. *J Clin Pathol.* 1972;25(9):745–53.
12. Hedges SJ, Dehoney SB, Hooper JS, et al. Evidence-based treatment recommendations for uremic bleeding. *Nat Clin Pract Nephrol.* 2007;3(3):138–53.

A Case Report of Crotalidae Immune F(ab')₂-associated Coagulopathy Recurrence in a Preschool-age Child

Jean C.Y. Lo, MD

E. Lea Walters, MD

Brian Wolk, MD

Loma Linda University Medical Center, Department of Emergency Medicine,

Loma Linda, California

Section Editor: Rachel Lindor, MD, JD

Submission history: Submitted November 26, 2023; Revision received February 14, 2024; Accepted March 7, 2024

Electronically published May 14, 2024

Full text available through open access at http://escholarship.org/uc/uciem_cpchem

DOI: 10.5811/cpcem.6583

Introduction: Pit viper envenomation may cause coagulopathy. The coagulopathy has been treated with crotalidae polyvalent immune fragment antigen-binding (Fab) ovine antivenom for the last few decades in the United States and usually corrects the acute coagulopathy within hours. Days after receiving Fab, coagulopathy may recur in approximately half of the patients. Another divalent antivenom, crotalidae immune F(ab')₂ (equine)-F(ab')₂-was approved by the US Food and Drug Administration for the treatment of pit viper envenomation. F(ab')₂ is composed of two linked antigen-binding fragments of immunoglobulin G. Several studies have demonstrated that F(ab')₂ is less likely to be associated with recurrence. There is no reported case of F(ab')₂-associated late coagulopathy in very young patients. We report the first case of recurrence associated with F(ab')₂ use in a preschool-age child.

Case Report: A preschool-age male developed leg swelling and hypofibrinogenemia after rattlesnake envenomation. F(ab')₂ was administered to stabilize the leg edema and to correct the hypofibrinogenemia. The patient improved clinically and was discharged on hospital day five. Seven days after the rattlesnake envenomation, he returned to the emergency department as instructed. Laboratory data revealed recurrent hypofibrinogenemia.

Conclusion: There are two antivenoms available in the US to treat crotalid envenomation, Fab and F(ab')₂. F(ab')₂ is less likely to be associated with recurrent coagulopathy in comparison to Fab. We report the first case of recurrence associated with F(ab')₂ in a preschool-age child. It is important that the emergency physician be aware of potential F(ab')₂-associated recurrent coagulopathy. Adult and pediatric patients may need to follow up to be evaluated for hypofibrinogenemia and/or thrombocytopenia after receiving F(ab')₂. [Clin Pract Cases Emerg Med. 2024;8(3)219–221.]

Keywords: *pediatric; case report; recurrence; F(ab')₂.*

INTRODUCTION

Pit viper (*Crotalinae*) envenomation in North America may cause coagulopathy, which manifests as hypofibrinogenemia and thrombocytopenia.¹ The coagulopathy has been treated with crotalidae polyvalent immune Fab (ovine) (Fab) for the last few decades in the United States.² While Fab corrects the initial coagulopathy within hours, days after initial Fab administration, coagulopathy may recur.^{1,3,4,5} Recurrent coagulopathy may be due to rapid clearance of Fab, which has an effective half

life of less than 12 hours.¹ Approximately half of the patients who received Fab develop recurrent hypofibrinogenemia or thrombocytopenia.¹ The concern with recurrence phenomenon is increased risk of bleeding.^{1,3,4}

Another antivenom, crotalidae immune F(ab')₂ (equine)-F(ab')₂-was approved by the US Food and Drug Administration (FDA) in 2015 for the treatment of North American pit viper envenomation.⁶ F(ab')₂ is composed of two linked fragment antigen-binding regions with a longer half-life than Fab.⁷ Several studies have demonstrated that

F(ab')₂ is less likely to be associated with recurrence.^{7,8,9} Previous reported cases of F(ab')₂-associated recurrence were noted in adults and children >10 years old. We report the first case of recurrent coagulopathy associated with F(ab')₂ in a preschool-age child.

CASE REPORT

A preschool-age male presented to an outside emergency department (ED) after rattlesnake envenomation to his leg. F(ab')₂ 10 vials were given at the outside hospital prior to transfer to a pediatric ED. Vital signs revealed temperature 98.1° Fahrenheit, blood pressure 105/64 millimeters of mercury, heart rate 108 beats per minute, respiratory rate 18 breaths per minute, and oxygen saturation 97%. Physical exam demonstrated left leg edema with ecchymosis. The initial fibrinogen was 178 milligrams per deciliter (mg/dL) (reference range 200–393 mg/dL). The patient developed worsening leg swelling. He received F(ab')₂ 10 vials in the ED and was admitted to the pediatric intensive care unit (PICU). An additional 28 vials of F(ab')₂ were given in the PICU (48 vials in total). His leg edema and ecchymosis stabilized. No other source of bleeding was noted. His fibrinogen and platelet level remained within normal range during the admission. The patient was discharged on day five.

He returned to the ED seven days after envenomation. The ED evaluation revealed fibrinogen of 147mg/dL. Subsequent ED visit three days later revealed fibrinogen improved to 162 mg/dL. The Table includes his fibrinogen trend after rattlesnake envenomation. His leg edema and ecchymosis improved. No thrombocytopenia was noted during admission or follow-up.

DISCUSSION

Approximately 5,000 snake envenomations are reported to poison control centers each year in the US.¹⁰ The majority of these snake envenomations are secondary to rattlesnake envenomation.¹¹ *Crotalinae* envenomation is predominately associated with local tissue effect and hematologic effects. Hematologic effects are treated with antivenom. Over the last few decades, Fab has been the primary treatment for *Crotalinae* envenomation in the US.² The platelet level and fibrinogen level typically improve within hours of antivenom administration. In approximately half of the patients the platelet and/or fibrinogen levels drop again a few days after initial Fab administration.¹ Patients are instructed to follow up with a primary care physician or return to the ED to recheck their platelet and fibrinogen levels a few days after initial Fab administration.

Population Health Research Capsule

What do we already know about this clinical entity?

Recurrent coagulopathy occurs commonly in patients who receive Fab. Recurrence is less common in patients who received crotalidae immune F(ab')₂ (equine)–F(ab')₂.

What makes this presentation of disease reportable?

Until now there has been no reported case of recurrence in very young patients who received F(ab')₂. Our patient developed hypofibrinogenemia one week after initial treatment.

What is the major learning point?

Recurrence of hypofibrinogenemia may occur in patients of all ages who receive F(ab')₂ after rattlesnake envenomation.

How might this improve emergency medicine practice?

Emergency physicians who administer F(ab')₂ to patients after rattlesnake envenomation should recommend close follow-up in a week.

Patients who develop recurrence require close follow-up with frequent measurement of platelet and fibrinogen levels. Severe thrombocytopenia or hypofibrinogenemia have been associated with increased risk of bleeding.^{4,5,6} Another antivenom F(ab')₂ was approved by the FDA in 2015.⁶ F(ab')₂ is larger in size in comparison to the Fab fragment and is thought to have a slower renal clearance and longer half-life. The benefit of F(ab')₂ over Fab is that F(ab')₂ is less likely to result in recurrence due to longer half-life.

Now there are two competing antivenoms. F(ab')₂ appears to have a lower risk of recurrent coagulopathy in multiple studies. A randomized-controlled trial by Bush et al that compared Fab and F(ab')₂ revealed that F(ab')₂ is less likely to be associated with recurrence phenomenon. While 29.7% of patients in the Fab group developed recurrence, 10.3% patients in the F(ab')₂ group developed recurrence.

Table. Fibrinogen trend between day one and day 10 after rattlesnake envenomation.

Day after rattlesnake envenomation	1	2	3	4	7	10
Fibrinogen level milligrams per deciliter (reference range 200–393)	176	396	283	297	147	162

The platelet counts and fibrinogen levels were lower in the Fab group than those in the F(ab')₂ group. All six patients who developed recurrence after receiving F(ab')₂ lived in inland Southern California. One possibility is that rattlesnake envenomation in inland Southern California is more likely to be associated with late coagulopathy. Furthermore, the study by Bush included 29.3% of patients in the F(ab')₂ group who were younger than 10 years old. None of the children <10 years developed recurrence.⁷

A study by Mascarenas et al also reported no late coagulopathy associated with F(ab')₂. Mascarenas compared 37 patients, 11 in the F(ab')₂ group and 26 in the Fab group. The rate of coagulopathy was 0% in the F(ab')₂ group and 29% in the Fab group.⁸ A study by Boyer et al demonstrated that more patients who received Fab developed thrombocytopenia and hypofibrinogenemia in comparison to patients who received F(ab')₂. Of the six patients who received F(ab')₂, one patient developed thrombocytopenia and zero patients had a low fibrinogen level (<150 mg/dL).⁹ These studies demonstrated that recurrence is less likely in patients who received F(ab')₂. However, there is still a non-zero risk for recurrent coagulopathy, as illustrated by this case. To date, there has been no reported case of recurrence associated with F(ab')₂ use in children <10. We report the first case of F(ab')₂-associated recurrence in a preschool-age child without known pre-existing hematopathologic condition.

Limitations of our report include risk of extrapolation from a single case as well as the fact that the fibrinogen concentration did not reach a level that would suggest a high risk of bleeding.¹² A larger dataset would be required to establish whether laboratory surveillance is mandatory after discharge for children receiving F(ab')₂ antivenom.

CONCLUSION

The antivenom crotalidae immune F(ab')₂ (equine) is less likely than Fab to result in recurrence or severe bleeding associated with late coagulopathy. The benefit of F(ab')₂ is lower bleeding risk and potentially less frequent follow-up for laboratory testing. While F(ab')₂-associated late coagulopathy is infrequent, it does occur. Adult and pediatric patients may still require follow-up for detection of recurrent thrombocytopenia and coagulopathy after receiving F(ab')₂.

The authors attest that their institution requires neither Institutional Review Board approval, nor patient consent for publication of this case report. Documentation on file.

Address for Correspondence: Jean C.Y. Lo, MD, Loma Linda University Medical Center, Department of Emergency Medicine, 11234 Anderson St., Loma Linda, CA 92354. Email: clo@llu.edu

Conflicts of Interest: By the CPC-EM article submission agreement, all authors are required to disclose all affiliations, funding sources and financial or management relationships that could be perceived as potential sources of bias. The authors disclosed none.

Copyright: © 2024 Lo et al. This is an open access article distributed in accordance with the terms of the Creative Commons Attribution (CC BY 4.0) License. See: <http://creativecommons.org/licenses/by/4.0/>

REFERENCES

1. Boyer LV, Seifert SA, Clark RF, et al. Recurrent and persistent coagulopathy following pit viper envenomation. *Arch Intern Med.* 1999;159(7):706–10.
2. Goto C and Feng S. Crotalidae polyvalent immune fab for the treatment of pediatric crotaline envenomation. *Ped Emerg Care.* 2009;25(4):273–9.
3. Bogdan GM, Dart RC, Falbo SC, et al. Recurrent coagulopathy after antivenom treatment of crotalid snakebite. *South Med J.* 2000;93(6):562–6.
4. Bailey AM, Justice S, Davis GA, et al. Delayed hematologic toxicity following rattlesnake envenomation unresponsive to crotalidae polyvalent antivenom. *Am J Emerg Med.* 2017;35(7):1038.
5. Kitchens C and Eskin T. Fatality in a case of envenomation by *Crotalus adamanteus* initially successfully treated with polyvalent ovine antivenom followed by recurrence of defibrinogenation syndrome. *J Med Toxicol.* 2008;4(3):180–3.
6. Wilson BZ, Larsen J, Smelski G, et al. Use of Crotalidae equine immune F(ab')₂ antivenom for treatment of an *Agkistrodon* envenomation. *Clin Toxicol (Phila).* 2021;59(11):1023–6.
7. Bush SP, Ruha AM, Seifert SA, et al. Comparison of F(ab')₂ versus Fab antivenom for pit viper envenomation: a prospective, blinded, multicenter, randomized clinical trial. *Clin Toxicol (Phila).* 2015;53(1):37–45.
8. Mascarenas DN, Fullerton L, Smolinske S, et al. Comparison of F(ab')₂ and Fab antivenoms in rattlesnake envenomation: first year's post-marketing experience with F(ab')₂ in New Mexico. *Toxicol.* 2020;186:42–45.
9. Boyer LV, Chase PB, Degan JA, et al. Subacute coagulopathy in a randomized, comparative trial of Fab and F(ab')₂ antivenoms. *Toxicol.* 2013;74:101–8.
10. Green S, Folt J, Wyatt K, et al. Epidemiology of fatal snakebites in the United States 1989–2018. *Am J Emerg Med.* 2021;45:309–16.
11. Ruha AM, Kleinschmidt KC, Greene S, et al. The epidemiology, clinical course, and management of snakebites in the North American snakebite registry. *J Med Toxicol.* 2017;13(4):309–20.
12. Faraoni D, Willems A, Savan V, et al. Plasma fibrinogen concentration is correlated with postoperative blood loss in children undergoing cardiac surgery. a retrospective review. *Eur J Anaesthesiol.* 2014;31(6):317–26.

A Case Report of Delayed Opioid Toxidrome After Administration of Naloxone

Maiya Cowan, MD*†

Prasanna Kumar, MD*†

Jenny McManus, MD, MPH*†

Sean Bilodeau, DO*†

Andrew Beck, MD, MS†

*Brown University, Providence, Rhode Island

†Lifespan/Rhode Island Hospital, Department of Emergency Medicine, Providence, Rhode Island

Section Editor: Steven Walsh, MD

Submission history: Submitted December 13, 2023; Revision received February 20, 2024; Accepted March 8, 2024

Electronically published May 29, 2024

Full text available through open access at http://escholarship.org/uc/uciem_cpccem

DOI: [10.5811/cpcem.6622](https://doi.org/10.5811/cpcem.6622)

Introduction: Opioid use is an epidemic that plagues the United States. Patients frequently present to the emergency department (ED) after opioid toxicity, which can lead to respiratory failure, apnea, and death. Although there is an effective antidote, naloxone, the current guidelines surrounding post-naloxone administration monitoring are loosely defined.

Case Report: We present a case in which an individual was administered naloxone after an intentional opioid overdose and was monitored for four hours, as is standard in our institution. He remained in the ED for additional workup following this observation period and subsequently experienced signs of severe respiratory depression, requiring bag-valve-mask ventilation, naloxone, and admission. Had he been discharged, as is typical after a four-hour observation period, the consequences could have been fatal. We present multiple theories as to why his opioid toxidrome may have presented in a delayed manner, including ingestion of fentanyl analogues and variability in metabolism of both opioids and naloxone. We also explore alternative overdose antidote products approved by the US Food and Drug Administration, which may impact post overdose care.

Conclusion: This case suggests that the correct amount of time to monitor patients after naloxone administration may be longer than originally thought. Our aim in this article was to further the discussion regarding the most appropriate observation period in cases of opioid toxicity. [Clin Pract Cases Emerg Med. 2024;8(3)222–225.]

Keywords: *naloxone; opioid; overdose; fentanyl; case report.*

INTRODUCTION

The opioid epidemic remains a serious public health crisis in the United States (US). Opioid overdoses account for a large proportion of emergency department (ED) visits nationwide and are the number one cause of death in individuals between 25–64 years of age.^{1,2} In 2021, 80,411 deaths involving opioid overdose were reported in the US, an increase from 68,630 the year prior.³ Naloxone is a competitive mu opioid receptor antagonist used to reverse the central and peripheral effects of opioid toxicity.²

Currently, there is no consensus regarding the duration of observation after naloxone administration. Various studies have cited between 1–4 hours as sufficient to prevent adverse events such as recurrence of respiratory depression, providing the patient has normal vital signs and mentation.^{4,5} However, some authors recommend even longer observation periods.⁶ This report highlights a case of delayed opioid toxidrome after naloxone administration despite an observation period of four hours, shedding light on potential pitfalls with current practice.

CASE REPORT

A 30-year-old male with past medical history of polysubstance use disorder and asthma presented to the ED following an intentional intranasal opioid overdose with illicitly purchased fentanyl. He was found unresponsive, and an ambulance was called. En route, he received a total of six milligrams (mg) of intranasal (IN) naloxone and 0.4 mg intravenous (IV) naloxone to reverse the apneic state. This was his first time using fentanyl, and he denied any known co-ingestion. He did not take any daily medications or have any allergies.

Initial vital signs were as follows: heart rate 116 beats per minute; blood pressure 184/118 millimeters of mercury; temperature 97° Fahrenheit, and oxygen saturation of 94–100% on two liters of oxygen. On exam, the patient was mildly somnolent but arousable, nodding off during the interview with a Glasgow Coma Scale (GCS) of 15. His pupils were pinpoint. Thought content included active suicidal ideation (SI) with a plan. He demonstrated no signs of trauma. Urine drug screen, an immunoassay, was positive only for fentanyl, cannabinoids, and cocaine. This was later confirmed with an extended drug panel, which was also negative for the following: methadone, benzodiazepines, buprenorphine, amphetamines, oxycodone, opiates, and phencyclidine. Acetaminophen, ethanol, toxic alcohol, and salicylate levels were not detected. No other lab abnormalities were present.

The patient was given one liter of normal saline and placed on telemetry with constant observation. After four hours, the patient was medically stable as he was awake, alert, and cooperative with a GCS of 15. At this point, he demonstrated no signs of respiratory depression, pupillary abnormality, or mental status change. He remained in the ED for psychiatric evaluation in the setting of active SI. During this time, he was under constant in-person observation and handcuffed to his stretcher (arrested on scene). Approximately 5.5 hours after initial naloxone administration, the patient became apneic and unresponsive. He was ventilated via bag-valve-mask and given two mg of IN naloxone with prompt clinical response. He was started on an IV naloxone infusion at 0.4 mg/hour and admitted to the intensive care unit.

He was on the infusion for approximately two hours when it was discontinued. Approximately three hours after cessation of the infusion, he had another episode of apnea. An IV naloxone infusion was reinitiated with a 0.2 mg IV bolus, again with appropriate clinical response. He was successfully weaned off IV naloxone later that night. He was discharged to a correctional facility with psychiatric follow-up two days later.

DISCUSSION

Deaths from opioid overdose have more than tripled over the last decade.³ As ED visits for opioid-related overdoses continue to rise, it is paramount to have standardized

Population Health Research Capsule

What do we already know about this clinical entity?

The opioid epidemic is a significant cause of morbidity and mortality in the United States. Naloxone is a readily available antidote that is clinically effective.

What makes this presentation of disease reportable?

The patient suffered from opioid toxicity well after the established observation period for naloxone use at our institution ended.

What is the major learning point?

There may not be a universal observation period for opioid toxicity in the emergency department, as individuals may metabolize naloxone and opioids differently.

How might this improve emergency medicine practice?

This case may encourage clinicians to consider a longer observation period or maintain a higher threshold for discharging a patient after an opioid overdose.

treatment protocols in place. Intranasal naloxone has gained momentum in the prehospital and community settings, even becoming available over the counter in 2023. Despite its widespread use, there continues to be disagreement over the most appropriate observation period to prevent adverse events.

The elimination half-life of IV naloxone ranges from 20–90 minutes, whereas that of many opioids can be substantially longer.⁵ For example, pharmaceutical fentanyl has a half-life of approximately 3.6 hours; and although human studies are lacking, some animal studies suggest that carfentanil can have a half-life of up to 7.7 hours.^{7,8,9} As a result, various time periods have been suggested as the most appropriate for observation after treatment with naloxone to prevent recurrence of toxicity. There are studies that cite one hour as safe and others that recommend observation periods of up to four hours.^{4,5,10} The patient was observed for four hours in keeping with institutional policy and subsequently recrudesced, which could have proven fatal.

There are many hypotheses as to why this patient presented atypically after opioid intoxication: variability in naloxone metabolism, ingestion of fentanyl analogues, and variability in opioid metabolism. The elimination of

naloxone follows first order kinetics.¹¹ Consequently, after four to five half-lives, 93.75–97% of the drug is eliminated, allowing for negligible remaining effect. Based on the well documented half-life range of 20–90 minutes, the rate of elimination among two people on either end of the spectrum can be approximately 4.5 times faster or slower.⁵ This is a substantial difference. Based on this range, if our patient were a fast metabolizer of naloxone, he likely would have required repeat doses within the observation period. However, if he were a slow metabolizer, he may have had enough naloxone to pass a four-hour observation period but would experience rebound toxicity once it wore off. There is scarce data reviewing this specific topic.

One recent study suggests a prolonged observation period between 6–12 hours in chronic opioid users or those who have ingested methadone, buprenorphine, or other long-acting opioids. Additionally, once 5 mg or more of IV naloxone is administered, admission is recommended.⁶ The rationale is that this increased dose may reflect the potency and half-life of the opioid ingested. Our case may be another data point to support the notion that there may be a role for dose-dependent observation periods after naloxone administration. This may be hard to quantify as dosing is based on clinical response and may overestimate the minimum amount of naloxone required for adequate reversal. In addition, this would require a method of standardization when current observation periods already vary greatly from facility to facility.^{5,10}

Another explanation is that the patient unintentionally ingested a long-acting opioid, such as a fentanyl analogue. Fentanyl analogues and novel synthetic opioids have infiltrated the unregulated illicit drug market.⁷ Data regarding pharmacokinetic and pharmacodynamic properties of fentanyl analogues/novel synthetic opioids is scarce, and much of the data come from animal studies. One example, carfentanil, has permeated throughout the illicit drug market and may be associated with increasing overdoses in the US.⁷ One small cohort study of human subjects that analyzed postoperative pain found that fentanyl is 50–100 times more potent than morphine, while carfentanil is 10,000 times more potent than morphine.⁷ This is significant because potency, affinity for mu opioid receptors, and ease of dissociation can influence how much naloxone is needed to reverse opioid toxicity.⁸ Most relevant to this case, the half-lives of these compounds vary greatly and would have significant implications for the duration of monitoring.

The half-life of pharmaceutical fentanyl is 219 minutes (~3.6 hours), and animal data suggests that the half-life of carfentanil is 7.7 hours.^{7,9,12} Given that the half-life of naloxone is 20–90 minutes, these compounds can be present for much longer than the reversal agent, resulting in recurrence of toxicity and need for longer monitoring times. To illustrate, one case series highlights 18 patients who experienced exaggerated opioid toxicity after testing positive

for fentanyl on a limited drug screen. Seventeen of these patients required naloxone boluses, with four requiring prolonged infusions (26–39 hours). Furthermore, one patient experienced recurrent toxicity eight hours after naloxone discontinuation,¹⁰ similar to the patient presented in this case report. This sheds light on the need for more data regarding fentanyl and its analogues and potentially increasing the time for observation after fentanyl ingestions specifically.

Consideration was also given to the possibility that he had self-administered fentanyl in the ED. However, this was unlikely as he always had a staff member present due to SI and was in handcuffs. Another explanation for delayed opioid toxidrome could be variable metabolization of the drug. Fentanyl is primarily metabolized by cytochrome P450 3A4 (CYP450 3A4) in the liver and, to a lesser extent, duodenal microsomes and renally.¹³ Fentanyl is eliminated through conversion to inactive, nontoxic metabolites.⁷ As with any enzyme, metabolic function may be subject to variability among individuals with respect to expression and drug interactions. For example, patients with hepatic impairment will likely have decreased clearance of these medications. Additionally, drugs that compete with fentanyl can result in unforeseen interactions. To illustrate, benzodiazepines are also metabolized by CYP450 3A4, and co-ingestion could result in delayed conversion of fentanyl into inactive metabolites.¹³ As a result, if metabolism of the opioid was slower than that of naloxone then this patient could have experienced rebound toxicity once naloxone effects had diminished or waned. However, this patient specifically did not have any laboratory evidence of hepatic impairment or benzodiazepine co-ingestion.

While naloxone is the standard of care for opioid overdose reversal, other emerging products in the pharmaceutical sector may address breakthrough presentations similar to this case. For instance, in 2023 the US Food and Drug Administration approved nalmefene as an intranasal alternative to naloxone. While nalmefene and naloxone are both opioid antagonists, the benefit of nalmefene is that its half-life is considerably longer than naloxone at 11.4 hours.¹⁴ More studies are needed to compare its efficacy and side-effect profile to naloxone. However, it may serve as a potential alternative for opioid overdoses.

CONCLUSION

This discussion highlights a case of delayed opioid toxidrome more than four hours after naloxone administration. The mechanism of these findings is unclear but may involve ingestion of fentanyl analogues or inter-individual variability in metabolization of opioids or naloxone. While data is limited on this phenomenon, this case highlights the need for more controlled studies on appropriate duration for monitoring after naloxone administration.

The authors attest that their institution requires neither Institutional Review Board approval, nor patient consent for publication of this case report. Documentation on file.

Address for Correspondence: Maiya Cowan MD, Rhode Island Hospital, Department of Emergency Medicine, 55 Claverick Street, Providence, RI 02903-4144. Email: Maiya_cowan@brown.edu

Conflicts of Interest: By the *CPC-EM* article submission agreement, all authors are required to disclose all affiliations, funding sources and financial or management relationships that could be perceived as potential sources of bias. The authors disclosed none.

Copyright: © 2024 Cowan et al. This is an open access article distributed in accordance with the terms of the Creative Commons Attribution (CC BY 4.0) License. See: <http://creativecommons.org/licenses/by/4.0/>

REFERENCES

- Skolnick P. Treatment of overdose in the synthetic opioid era. *Pharmacol Ther.* 2022;233:108019.
- Boyer EW. Management of opioid analgesic overdose. *New Engl J Med.* 2012;367(2):146–55.
- National Institute on Drug Abuse. Drug Overdose Death Rates. 2023. Available at: <https://nida.nih.gov/research-topics/trends-statistics/overdose-death-rates#:~:text=Opioid%2Dinvolved%20overdose%20deaths%20rose,with%2080%2C411%20reported%20overdose%20deaths>. Accessed December 10, 2023.
- Clemency BM, Eggleston W, Shaw EW, et al. Hospital observation upon reversal (HOUR) with naloxone: a prospective clinical prediction rule validation study. *Acad Emerg Med.* 2019;26(1):7–15.
- Heaton JD, Bhandari B, Faryar KA, et al. Retrospective review of need for delayed naloxone or oxygen in emergency department patients receiving naloxone for heroin reversal. *J Emerg Med.* 2019;56(6):642–51.
- Jordan MR, Patel P, Morrisonponce D Naloxone. In: *StatPearls*. Treasure Island (FL): StatPearls Publishing; Available at: <https://www.ncbi.nlm.nih.gov/books/NBK441910/#:~:text=The%20half%2Dlife%20of%20naloxone,until%20obtaining%20a%20full%20recovery>. Accessed December 10, 2023.
- Armenian P, Vo KT, Barr-Walker J, et al. Fentanyl, fentanyl analogs and novel synthetic opioids: a comprehensive review. *Neuropharmacol.* 2018;134(Pt A):121–32.
- Lynn RR and Galinkin JL. Naloxone dosage for opioid reversal: current evidence and clinical implications. *Ther Adv Drug Saf.* 2018;9(1):63–88.
- Cole A, Mutlow A, Ramiro I, et al. Pharmacokinetics and pharmacodynamics of carfentanil and naltrexone in female common eland (*Taurotragus oryx*). *J Zoo Wildl Med.* 2006;37(3):318–26.
- Willman MW, Liss DB, Schwarz ES, et al. Do heroin overdose patients require observation after receiving naloxone? *Clin Toxicol.* 2017;55(2):81–7.
- Dowling J, Isbister G, Kirkpatrick C, et al. Population pharmacokinetics of intravenous, intramuscular, and intranasal naloxone in human volunteers. *Ther Drug Monit.* 2008;30(4):490–6.
- Wolff K, Rostami-Hodjegan A, Shires S, et al. The pharmacokinetics of methadone in healthy subjects and opiate users. *Br J Clin Pharmacol.* 1997;44(4):325–34.
- Labroo RB, Paine MF, Thummel KE, et al. Fentanyl metabolism by human hepatic intestinal cytochrome P450 3A4: implications for interindividual variability in disposition, efficacy, and drug interactions. *Drug Metab and Disp.* 1997;25(9):1072–80.
- US Food and Drug Administration. Highlights of Prescribing Information. Available at: https://www.accessdata.fda.gov/drugsatfda_docs/label/2023/217470Orig1s000.pdf. Accessed December 10, 2023.

Testicular Traction Technique with Intact Cremasteric Reflex, a Novel Approach for Manual Detorsion: Case Report

Garrett Trang, BS
Taz Brinkerhoff, MD

The University of Arizona, College of Medicine-Phoenix, Phoenix, Arizona

Section Editor: Christopher Sampson, MD

Submission history: Submitted August 1, 2023; Revision received February 19, 2024; Accepted March 8, 2024

Electronically published May 29, 2024

Full text available through open access at http://escholarship.org/uc/uciem_cpem

DOI: 10.5811/cpcem.1568

Introduction: Recognizing testicular torsion is extremely important in patients presenting to the emergency department (ED) with acute scrotal pain. Traditional manual detorsion techniques are frequently employed by emergency physicians but are not always successful. Delays in detorsion increase the risk of testicular infarction and infertility, and the need for orchiectomy. Novel techniques such as the testicular traction technique have been described as a potential solution for difficult-to-detorse testicles.

Case Report: Our case report describes a 20-year-old male with no significant past medical history who presented to a rural ED with acute, atraumatic testicular pain secondary to testicular torsion with an intact cremasteric reflex. After confirming the diagnosis using Doppler ultrasound, manual detorsion using the traditional “open book” technique was attempted and unsuccessful. The patient was subsequently successfully detorsed using the novel testicular traction technique.

Conclusion: The testicular traction technique is a safe, rapid, and effective primary or adjunctive technique in manual testicular detorsion. Given the time-sensitive nature of testicular torsions, adjunctive techniques play a crucial role in managing challenging detorsions, particularly in resource-limited rural settings with limited access to urologic services. Although it is commonly thought that the cremasteric reflex is absent in testicular torsions, it may be present in rare circumstances, and its presence should not be an absolute in ruling out torsion. [Clin Pract Cases Emerg Med. 2024;8(3)226–230.]

Keywords: case report; testicular torsion; manual detorsion; technique; cremasteric reflex.

INTRODUCTION

Scrotal complaints comprise at least 0.5% of all emergency department (ED) visits.¹ Among the differential diagnoses, testicular torsion is one of the most serious and is considered a surgical emergency. The annual incidence of testicular torsion is estimated to be 3.8 per 100,000 for males <18 years of age, and rates of orchiectomy were found to be as high as 42% in these boys.^{2,3} Given that the complications of testicular torsion include testicular infarction and infertility, quickly diagnosing and treating it is imperative.^{3,4}

In the ED, manual detorsion is a safe, rapid, noninvasive treatment that should be attempted to reverse ischemia and provide rapid pain relief.⁴ Since up to 95% of testicular torsions are due to internal rotation, the detorsion technique

often requires external rotation of the testicle as if one was “opening a book.”⁵ For a suspected torsion of the left testicle, the physician should place his or her right thumb and index finger on the testicle and rotate 180 degrees from medial to lateral (or clockwise).⁴ The procedure may be repeated several times since torsion can involve rotations of 180–720 degrees.⁴ The success rate of manual detorsion in the literature varies; it can be as high as 76–95% when performed by urologists, but other studies found the success rate more variable.^{6–8} Given the variable success rate of the “open book” technique, it is important to have an adjunctive technique if it fails or urologic intervention is not immediately available.

The testicular traction technique was first described in 2022 by Mellick et al⁹; it involves grasping the testicle with

one or both hands and pulling inferiorly to stretch the spermatic cord to its maximum length. From there, manual detorsion of the testicle is performed by externally rotating the testicle using the “open book” technique until the spermatic cord feels normal. We describe a successful detorsion using the testicular traction technique after conventional methods failed.

CASE REPORT

A 20-year-old White male with no known medical conditions presented to a rural ED with complaints of atraumatic and continuous pain to the left testicle and inguinal region that worsened with movement. The pain developed after a day of work involving frequent heavy lifting. During his shower at home approximately five hours prior to presentation, he noticed the left testicular pain was more pronounced with associated bulging and tenderness in the left scrotal region. He denied any associated symptoms such as nausea and vomiting. He had no history of torsion, undescended testicles, testicular malignancy, or surgery to the testicle or abdominal region.

On physical exam, the patient appeared pale, nervous, and apprehensive of movement. Vital signs were within normal limits. Genitourinary examination revealed a high-riding and hard testicle that was diffusely tender to palpation. There were no masses in the inguinal region, and no testicular erythema, swelling, visible masses, or penile discharge. A hard, knot-like mass was palpated on the superior pole of the left testicle along the spermatic cord, suspicious for a torsed spermatic cord. Unexpectedly, the cremasteric reflex was present. The sonographer who performed the ultrasound approximately six hours after symptom onset noted minimal blood flow to the left testicle (Image 1). The on-call radiologist quickly confirmed the diagnosis of testicular

Population Health Research Capsule

What do we already know about this clinical entity?

The testicular traction technique was first described in 2022 as an adjunctive manual detorsion technique for testicular torsions.

What makes this presentation of disease reportable?

A patient with a testicular torsion and an intact cremasteric reflex was detorsed using the testicular traction technique.

What is the major learning point?

This is a safe, noninvasive treatment that provides rapid pain relief. Absence of the cremasteric reflex may not always be a reliable sign of testicular torsion.

How might this improve emergency medicine practice?

The testicular traction technique is an effective primary or adjunctive technique for difficult-to-detorse testicles.

torsion. The radiology report also noted a tangled, heterogenous mass superior to the testicle that was consistent with the torsed spermatic cord palpable on physical exam (Image 1). There was no notable enlargement or changes in echotexture that were concerning for an infarction or necrosis.

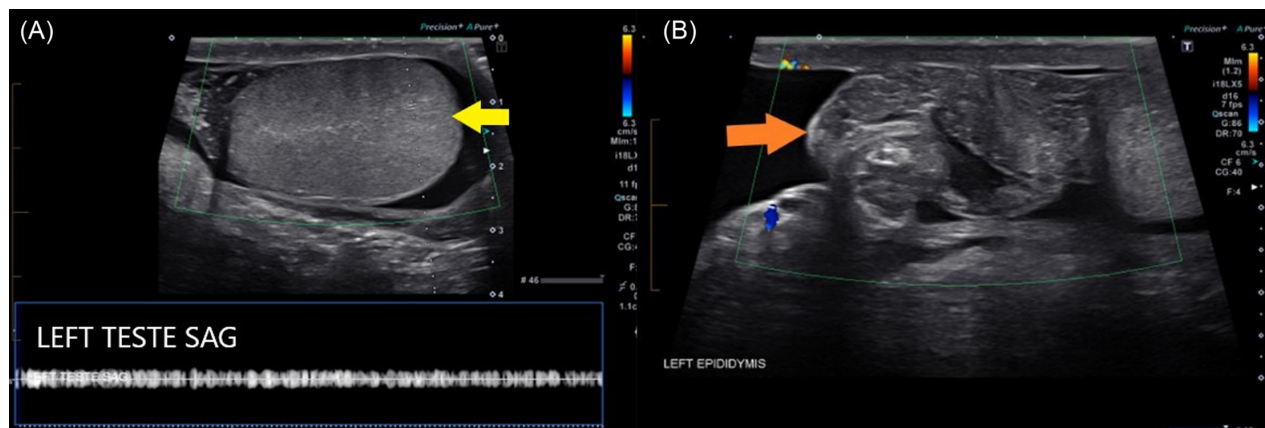


Image 1. Arterial and venous flow in the left testicle and epididymis under Doppler ultrasound. Note the lack of flow in both the left testicle (yellow arrow) (A) and left epididymis (orange arrow) (B). There was a heterogenous mass (orange arrow) superior to the left testis without blood flow, consistent with tangled vasculature (B). A discussion with the radiologist determined that the spectral waveform was artifact and not venous flow (A).

TRANS, transverse view; SAG, sagittal view.

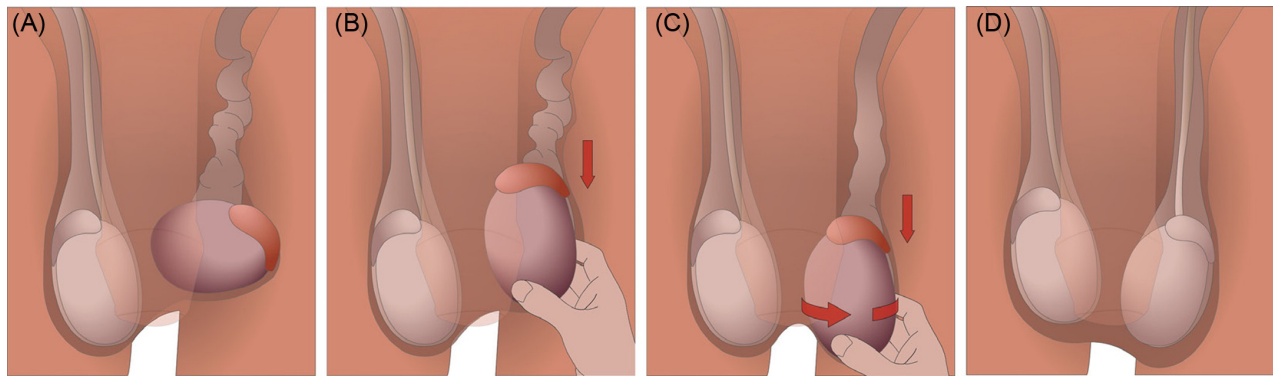


Figure. The testicular traction technique. (A) The torsed left testicle is identified. Typical symptoms include a high-riding, hard, inflamed, and tender testicle as depicted here. A twisted spermatic cord may also be palpated superior to the testicle. (B) Traction is applied to the affected testicle until the spermatic cord is maximally lengthened. In our case, the side-lying angle of the torsed testicle was corrected to a more natural, vertical angle. (C) With the spermatic cord lengthened, the testicle is rotated externally while maintaining traction. Most testicular torsions are medially twisted; therefore, clockwise rotation should be attempted for the left testicle and counterclockwise rotation for the right testicle. The physician should visualize and palpate for any flipping or spinning of the testicle throughout the maneuver. (D) Successful detorsion is often represented by immediate resolution of pain. Repeat Doppler ultrasound should be performed to confirm restoration of blood flow to the affected testicle.

The patient was prepped for manual detorsion in a standing position approximately six hours after the onset of symptoms. We attempted the “open book” technique several times in both directions without successful detorsion. Subsequently, the testicular traction technique (Figure) was performed by first grasping and applying inferior traction to the left testicle, while correcting the side-lying angle to a more natural vertical angle of the testicle.

The tension reduced the palpable lump of anticipated spermatic cord at the superior pole. While maintaining traction and lengthening the spermatic cord, the left testicle was manually rotated clockwise by ~90°. At this point, the testicle spontaneously detorsed by at least 1–2 turns. It was challenging to determine the precise number of rotations, as the testicle rapidly rotated within the scrotum. However, the physician could feel the testicular anatomy during this

movement. Resolution was apparent by both visible and physical exams immediately following the procedure. The patient reported instant relief of pain. A repeat Doppler ultrasound was performed, which confirmed the detorsion and restoration of normal blood flow with no evidence of infarct or necrosis (Image 2). Based on resolution of symptoms and blood flow, the on-call urologist determined that the patient could follow up in an outpatient setting urgently for elective orchiopexy procedure. Follow-up information was not available.

DISCUSSION

This case reports describes a 20-year-old man with a testicular torsion and intact cremasteric reflex that was successfully detorsed with the testicular traction technique. The spermatic cord is highly mobile and stretches and

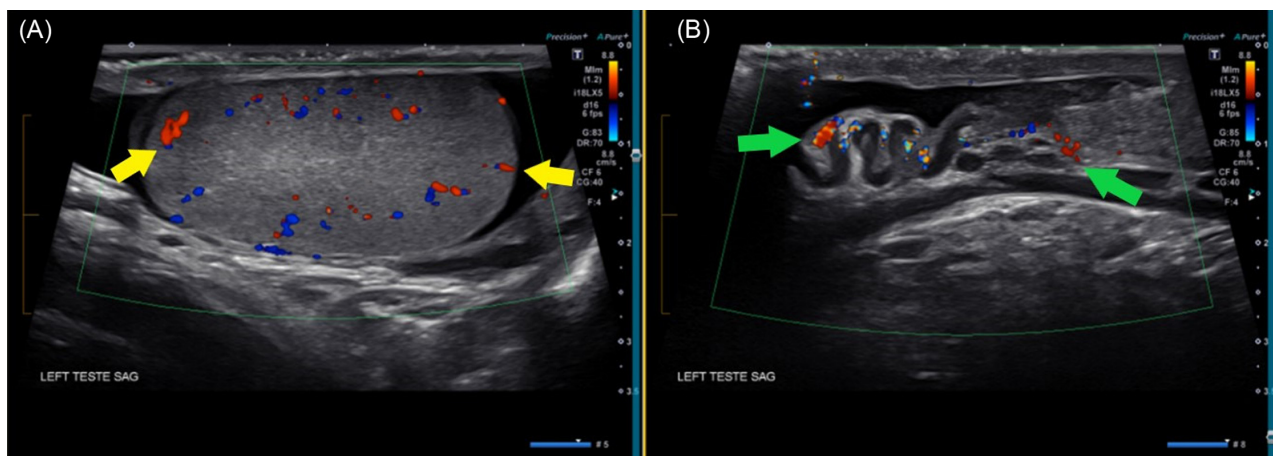


Image 2. Repeat Doppler ultrasound of the left testicle after manual detorsion. (A) Sagittal view of the left testicle showing restored arterial and venous flow (yellow arrows). (B) Sagittal view of the spermatic cord and epididymis with resolution of the heterogenous mass and restoration of blood flow (green arrows), consistent with successful detorsion.

retracts under normal physiologic responses. As a result, the traction maneuver in the testicular traction technique should be physiologically and anatomically tolerated.⁹ This technique is particularly useful when torsion has been prolonged and the spermatic cord becomes edematous, increased in volume, and partially trapped making extraction from the inguinal canal necessary.⁹ The proposed mechanism of the technique is analogous to stretching a tangled phone cord to allow for partial unraveling prior to applying a rotational force. Scheier and Levy in 2023 described a similar phenomenon where each traction attempt returned transient and pulsatile blood flow to the testicle despite the manual detorsion failing.¹⁰

Our case was consistent with what was described in the first case series reporting use of this technique.⁹ The traction technique in our case was employed as an adjunct maneuver, which removed the resistance felt during the initial detorsion attempt using standard methods. While the stretching of the spermatic cord did not directly lead to unraveling of the torsion, spontaneous unraveling did occur after gentle external rotation of the testicle. We hypothesize that the additional downward force of gravity in the standing position may have contributed to the spontaneous detorsion. However, the technique could be performed in a supine position as described in the previous case series.

The most important determinants of an early salvage rate of testes are the time from symptom onset to detorsion and the degree of spermatic cord twisting.¹¹ The sensitive time frame of testicular salvage in testicular torsion cases further emphasizes the importance of timely diagnoses and manual detorsion. In rural hospitals like ours, subspecialty services such as urology are not immediately available, and transfer to tertiary care centers may prolong testicular ischemia if not successfully detorsed in the ED. The cremasteric reflex is often thought to be absent in 100% of patients with testicular torsion. Unexpectedly, the cremaster reflex was present in our case, which is similar to what was reported in other case reports.¹² The cremasteric reflex may be a useful sign, but its reliability in diagnosing or excluding testicular torsion has been challenged in recent years.¹³

Regardless, a scrotal ultrasound should be immediately performed on any patient who presents with acute atraumatic scrotal pain, and manual detorsion should be attempted in a timely fashion. The rates of orchiectomy following testicular torsion vary in the literature; nonetheless, they are significantly higher in patients who were not successfully manually detorsed.¹⁴ Manual detorsion in the ED can buy precious time that is vital for successful surgical salvage and may sometimes even convert an emergent urologic surgery into an urgent but elective one.⁶

The time window for survival and successful salvage of a torsed testicle had been commonly thought to be 6–8 hours or less.¹⁵ Delays past this time window may lead to orchiectomy, which is associated with reduced fertility and

medico-legal litigation. Some physicians even forgo manual detorsion beyond this point. In a systematic review by Mellick et al that included 2,116 patients with testicular torsion, they found that testicular survival was significantly beyond the original 6–8 hour time frame: 90.4% survival when detorsed within the first 12 hours, 54% from 13–24 hours, and 18.1% when after 24 hours. Successful detorsion may still be achieved past the commonly accepted window, but the decision to attempt manual detorsion should be made on a case-by-case basis.

CONCLUSION

The absence of the cremasteric reflex may not always be a telltale sign in identifying patients with an acute scrotum, and ultrasound should be performed whenever testicular torsion is suspected. It is commonly thought that testicles are unsalvageable past the 6–8 hour time window; however, there is literature that supports longer survivability. Physicians should not forgo manual detorsion solely based on the duration of torsion. The testicular traction technique is a rapid, easy-to-perform, and safe maneuver that can be used as a primary or adjunctive treatment for detorsion in any setting. Despite limited patient cases, the novel testicular technique shows promise as a solution for difficult-to-reduce testicles.

The authors attest that their institution requires neither Institutional Review Board approval, nor patient consent for publication of this case report. Documentation on file.

Address for Correspondence: Garrett Trang, BS, The University of Arizona, College of Medicine-Phoenix, 475 N 5th St., HSEB Building C532, Phoenix, AZ 85004. Email: gtrang@arizona.edu

Conflicts of Interest: By the CPC-EM article submission agreement, all authors are required to disclose all affiliations, funding sources and financial or management relationships that could be perceived as potential sources of bias. The authors disclosed none.

Copyright: © 2024 Trang et al. This is an open access article distributed in accordance with the terms of the Creative Commons Attribution (CC BY 4.0) License. See: <http://creativecommons.org/licenses/by/4.0/>

REFERENCES

- Schick MA and Sternard BT. Testicular torsion. In *StatPearls [Internet]*. Treasure Island, Florida: StatPearls Publishing, 2023. Available at: <https://www.ncbi.nlm.nih.gov/books/NBK448199/>. Accessed May 22, 2024.
- Zhao LC, Lautz TB, Meeks JJ, et al. Pediatric testicular torsion epidemiology using a national database: incidence, risk of orchiectomy and possible measures toward improving the quality of care. *J Urol*. 2011;186(5):2009–13.
- Sharp VJ, Kieran K, Arlen AM. Testicular torsion: diagnosis, evaluation, and management. *Am Fam Physician*. 2013;88(12):835–40.

4. Laher A, Ragavan S, Mehta P, et al. Testicular torsion in the emergency room: a review of detection and management strategies. *Open Access Emerg Med.* 2020;12:237–46.
5. Aggarwal D, Parmar K, Sharma AP, et al. Long-term impact of testicular torsion and its salvage on semen parameters and gonadal function. *Indian J Urol.* 2022;38(2):135–9.
6. Dias Filho AC, Oliveira Rodrigues R, Riccetto CLZ, et al. Improving organ salvage in testicular torsion: comparative study of patients undergoing vs not undergoing preoperative manual detorsion. *J Urol.* 2017;197(3):811–7.
7. Hawtrey CE. Assessment of acute scrotal symptoms and findings. A clinician's dilemma. *Urol Clin North Am.* 1998;25(4):715–23.
8. Demirbas A, Demir DO, Ersoy E, et al. Should manual detorsion be a routine part of treatment in testicular torsion? *BMC Urol.* 2017;17(1):84.
9. Mellick LB and Watters BC. The torsed testicle traction technique and 2 case reports. *Pediatr Emerg Care.* 2023;39(5):364–7.
10. Scheier E and Levy ES. Testicular traction technique in an adolescent with torsion. *Pediatr Emerg Care.* 2023;39(11):75–6.
11. Visser AJ and Heyns CF. Testicular function after torsion of the spermatic cord. *BJU Int.* 2003;92(3):200–3.
12. Murphy FL, Fletcher L, Pease P. Early scrotal exploration in all cases is the investigation and intervention of choice in the acute paediatric scrotum. *Pediatr Surg Int.* 2006;22(5):413–6.
13. Paul EM, Alwayay C, Palmer L. How useful is the cremasteric reflex in diagnosing testicular torsion? *J Am Coll Surg.* 2004;199(3):101.
14. Vuruşkan E, Erçil H, Karkin K, et al. The effect of manual detorsion on testicular salvage rates in adult testicular torsion patients: single center experience. *Duzce Med J.* 2022;24(2):101–4.
15. Mellick LB, Sinex JE, Gibson RW, et al. A systematic review of testicle survival time after a torsion event. *Pediatr Emerg Care.* 2019;35(12):821–5.

A Case Report of Hematogenous Osteomyelitis of the Manubrium Caused by Seeding from a Colovesicular Fistula

Celina Wong, MD
Tammy Phan, BS
Emmelyn Samones, BS
Sharmin Kalam, MD

Loma Linda University Medical Center, Department of Emergency Medicine,
Loma Linda, California

Section Editor: Jacqueline Le, MD

Submission history: Submitted November 28, 2023; Revision received February 23, 2024; Accepted March 11, 2024

Electronically published June 3, 2024

Full text available through open access at http://escholarship.org/uc/uciem_cpchem

DOI: [10.5811/cpcem.6591](https://doi.org/10.5811/cpcem.6591)

Introduction: Osteomyelitis can occur at various osseous locations and commonly presents in the emergency department (ED). The incidence of osteomyelitis is 21.8 cases per 100,000 persons annually.¹ Hematogenous osteomyelitis typically occurs in the vertebrae; however, it may seldomly occur in the manubrium. Hematogenous osteomyelitis can be seen in patients with complicated thoracic surgery, radiation, fracture, diabetes, immunosuppression, steroid therapy, and malnutrition.² Because signs and symptoms of osteomyelitis may be nonspecific, clinicians must have high suspicion based on history and physical. Workup should include identifying the source, imaging, and surgical cultures.

Case Report: A 60-year-old male with hypertension and diabetes presented with atraumatic right shoulder and chest pain. The patient presented twice to the ED for clavicle pain five days prior. Computed tomography (CT) of the chest detected osseous infection of the manubrium and upper sternum, right clavicle, and mediastinal phlegmon. A CT of the abdomen and pelvis revealed osteomyelitis and discitis of the 12th thoracic and first lumbar vertebral body with gas at the psoas muscle, as well as sigmoid diverticulitis with colovesicular fistula. The patient was started on broad spectrum antibiotics and 1,500 milliliters of lactated Ringer's in the ED. After evaluation by cardiothoracic surgery, the patient was taken to the operating room for neck exploration, incision/drainage, manubriectomy, and right sternoclavicular joint resection. Surgical, blood, urine, and respiratory cultures grew *Klebsiella pneumoniae*. After a 34-day hospital course, the patient was discharged on two weeks of oral levofloxacin and follow-up appointments with cardiothoracic surgery and infectious disease. The patient had good prognosis and recovery.

Conclusion: Hematogenous osteomyelitis to the manubrium is rare and may present with only chest pain. It is important to consider other sources that seed in the manubrium and imaging to evaluate multisite infection. Treatment should include intravenous antibiotics and/or surgical intervention for debridement with washout or manubriectomy. [Clin Pract Cases Emerg Med. 2024;8(3)231–234.]

Keywords: *hematogenous osteomyelitis; sternal osteomyelitis; discitis; colovesicular fistula; Klebsiella pneumoniae; case report.*

INTRODUCTION

Osteomyelitis is defined as infection and inflammation of bone with multiple types that require different interventions and management. Osteomyelitis develops by three mechanisms: bacteremia leading to hematogenous spread to

the bone; contiguous spread from adjacent soft tissue to the bone; or direct inoculation into the bone.³ The rarest type of osteomyelitis is that of hematogenous spread.⁴ The most common location of osteomyelitis is the vertebrae. Additionally, osteomyelitis of the manubrium (outside of

thoracic surgery- related complications) is even more uncommon with very few case reports published; it can either lead to or be a result of hematogenous seeding.⁵ Typically, these patients will have multiple risk factors such as diabetes or immunodeficiency that predispose them to infection. Treatments vary from intravenous (IV) antibiotics alone to the addition of surgery. This case of manubrium osteomyelitis is unique in that it was the result of hematogenous spread; a manubriectomy was necessary in addition to long-term IV and oral antibiotics.

CASE REPORT

A 60-year-old male with a past medical history significant for hypertension and diabetes mellitus presented to the emergency department (ED) with right-sided shoulder and chest pain. The patient initially presented five days prior with complaints of a three-day history of right clavicle pain. There was no reported direct trauma, but the patient noticed the pain started after he was catching boxes at work. A chest radiograph and dedicated right clavicle radiograph was ordered at the time, and both imaging resulted as normal. The patient was then discharged and diagnosed with a musculoskeletal strain. Five days later, the patient presented to the same ED, now with associated chest pain, fevers, and shortness of breath. Between the two presentations, the patient was seen at another facility, where computed tomography (CT) revealed osteomyelitis of the sternoclavicular joint and manubrium. According to the patient, the CT also mentioned colonic fistula and because that facility did not have a cardiothoracic specialist available, transfer arrangements were attempted but were unsuccessful. Therefore, the patient decided to leave against medical advice and present to the ED directly. The patient denied any IV drug use, tobacco use, or history of autoimmune disorders.

Initial vital signs were the following: temperature 99.3° Fahrenheit, pulse 120 beats per minute, blood pressure 120/70 millimeters of mercury, respiratory rate 24 breaths per minute, and oxygen saturation 97% on room air. On physical exam, the patient was ill-appearing. There was right clavicle and right-sided chest wall tenderness but no appreciation for crepitus or mass. His cardiopulmonary exam revealed tachycardia. There were no heart murmurs, and lung sounds were clear bilaterally. Laboratory values revealed a white blood count of 7.41×10^9 per liter (reference range 4.8–11.4 $\times 10^9$ per liter), a blood sugar level of 352 milligrams per deciliter (mg/dL) (70–140 mg/dL), and an elevated lactate level of 3.5 millimoles per liter (mMol/L) (0.5–2.0 mMol/L). Additionally, there was an elevated sedimentation rate of 84 millimeters per hour (mm/hr) (0–20 mm/hr), an elevated C-reactive protein level of 22.3 mg/dL (0.0–0.8 mg/dL), and an elevated procalcitonin level of 12.90 micrograms per liter ($\mu\text{g/L}$) (0.0–0.15 $\mu\text{g/L}$). A CT of the chest revealed an osseous infection of the manubrium, upper sternum, and right

Population Health Research Capsule

What do we already know about this clinical entity?

Hematogenous osteomyelitis is a rare form of osteomyelitis that occurs when bacteria spreads to the bone through the bloodstream.

What makes this presentation of disease reportable?

We report a rare location of the hematogenous spread to the manubrium with an even more uncommon treatment course.

What is the major learning point?

This case teaches the importance of an extensive workup to identify the primary source of hematogenous osteomyelitis when found in rare locations.

How might this improve emergency medicine practice?

Emergency physicians should be aware of hematogenous osteomyelitis and how extensive workup will aid in evaluating this disease process.

clavicle with an associated mediastinal phlegmon and soft tissue gas extending to the neck and right pectoralis major muscle (**Image 1**). A CT of the abdomen and pelvis revealed osteomyelitis and discitis of the 12th thoracic and first lumbar vertebral body with associated gas in the psoas muscle body at that level (**Image 2**). Additionally, sigmoid diverticulitis with colovesicular fistula was noted on the CT abdomen and pelvis (**Image 3**), mentioned by the patient as a notable finding at the outside hospital.

Differential diagnosis for this patient included septic shock secondary to *Klebsiella pneumoniae* bacteremia, with hematogenous spread to the manubrium and first lumbar vertebral body. The source was suspected to be from the sigmoid diverticulitis with a colovesicular fistula. Alternative differential diagnoses could include necrotizing fasciitis given the presence of gas in the nearby psoas and pectoral muscle, pulmonary embolism, or endocarditis based on fever and chest pain.

The patient was started on broad spectrum antibiotics (piperacillin-tazobactam, vancomycin, and clindamycin) and given a 1,500 milliliter (mL) lactated Ringer's bolus while in the ED for presumed sepsis. The patient then became hypotensive and was started on a norepinephrine drip with additional crystalloid fluids given. Cardiothoracic surgery

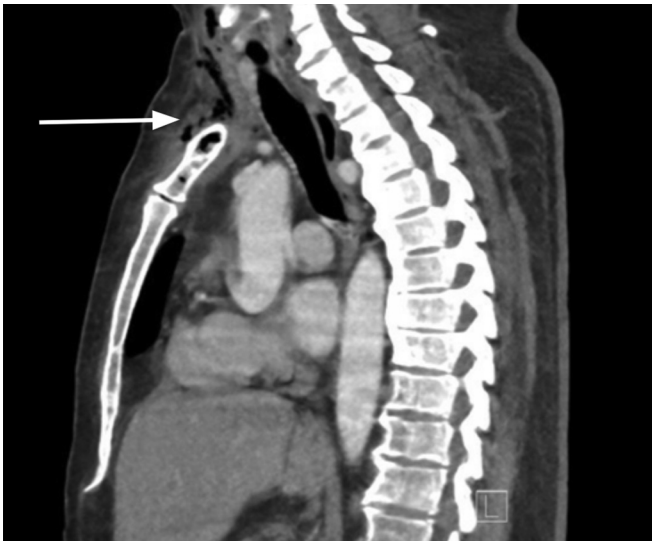


Image 1. A sagittal view of computed tomography of the chest, revealing osseous infection of manubrium with surrounding gas (arrow) extending into the neck.

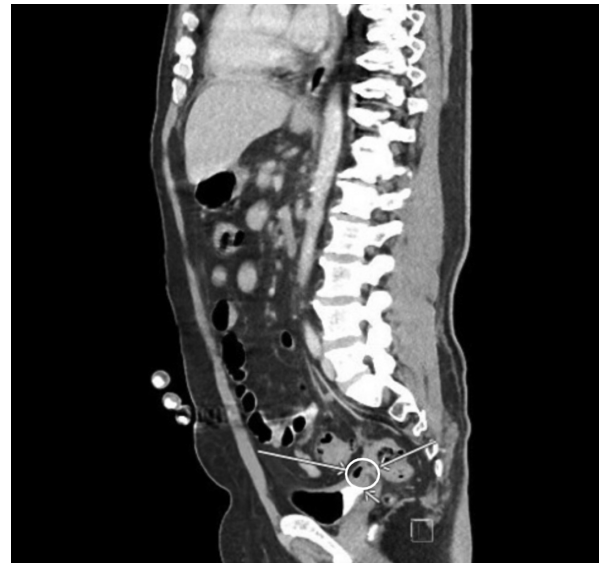


Image 3. A sagittal view of computed tomography of the abdomen and pelvis demonstrating sigmoid diverticulitis with a colovesicular fistula (circle, arrows).

was consulted for chest findings. Neurosurgery was consulted for the spine findings, and colorectal surgery was consulted to address the fistula. After being evaluated by cardiothoracic surgery, the patient was immediately taken to the operating room (OR) from the ED for a manubriectomy and for source

control. In the OR, the surgeons performed a neck exploration, an incision and drainage, a manubriectomy, and a resection of the right sternoclavicular joint. The patient was then admitted to the surgical intensive care unit after being intubated, and he continued to require vasopressors. Surgical, blood, urine and respiratory cultures grew *K pneumoniae*, which was presumed to be the source of infection. On day six, the patient was found to have additional septic emboli on CT head. A lumbar puncture was performed on day eight; however, cerebrospinal fluid cultures grew no bacteria. The patient was eventually extubated, weaned off vasopressors, and managed on the medical/surgical floor on day 11.

During his hospital stay on the surgical floor, the patient completed a six-week course of intravenous (IV) antibiotics and was switched to oral antibiotics. On hospital day 30, the patient underwent additional surgery for a right sternocleidomastoid muscle flap, debridement of the sternoclavicular joint, and closure of the neck wound. After a 34-day hospital course, the patient was discharged on oral levofloxacin for an additional two weeks with follow-up with cardiothoracic surgery and infectious disease specialists.

DISCUSSION

Few case reports have been published regarding primary sternal osteomyelitis, with the thought that most stem from hematogenous spread.^{4,5} This again is supported by our patient's presentation, where there were multiple sites of infection including vertebral osteomyelitis, extensive neck and psoas muscle abscesses, and septic emboli infarcts.

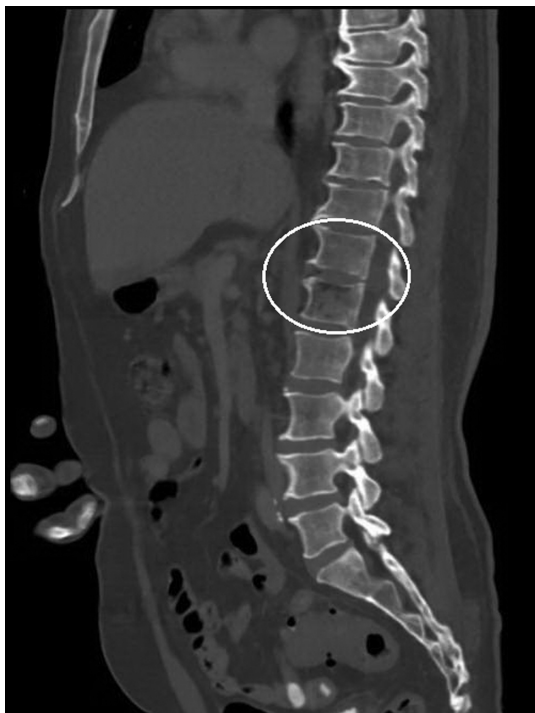

Image 2. A sagittal bone view of computed tomography of the abdomen and pelvis revealing gas within the twelfth thoracic and first lumbar vertebral body (circle) suspicious for osteomyelitis.

In hematogenous osteomyelitis, bacteria in the blood flowing through the vasculature in the bone can adhere to it. Bacteria may cause inflammatory changes, breaking down the bony cortex and periosteum, which can cause further invasion of the bacteria and necrosis of the bone.⁶ Typically, risk factors for hematogenous osteomyelitis include endocarditis, IV drug use, sickle cell disease, hemodialysis, orthopedic hardware, and intravascular devices.⁷ However, this patient did not present with any known risk factors. The patient's history of diabetes mellitus may have been a risk factor for contiguous spread from diabetic ulcers into the adjacent bone. Additionally, the patient presented with only chest pain with no chest mass as seen in other case reports of sternum osteomyelitis.^{5,8,9,10}

Furthermore, when taking a closer look at the pathogen isolated in this case, *K pneumoniae* was found both in the vertebrae and the manubrium surgical cultures.

K pneumoniae is a typical anaerobic organism of the gastrointestinal (GI) tract. One study showed it to cause severe bacterial infections where there was a correlation with increased morbidity seen in patients with GI fistulas.¹¹ Similarly, with this case it is assumed that the fistula may have caused hematogenous spread of the infection, thus causing the multiple sites of osteomyelitis. Treatment for hematogenous osteomyelitis is normally IV antibiotics alone.⁴ However, for this case a manubriectomy was performed for source control due to the patient's septic shock. Typically, surgical treatment for sternum osteomyelitis has included surgical debridement, surgical washout, and even hyperbaric oxygen therapy.^{5,12} In addition to surgery, this patient did receive a prolonged course of IV and oral antibiotics.

CONCLUSION

Hematogenous osteomyelitis to the manubrium is rare and may present with only chest pain. Workup includes obtaining inflammatory markers, as well as CT imaging of the chest. Additionally, it is important to consider other sources that may have seeded the manubrium, such as in this patient with colovesicular fistula, and to obtain additional imaging/workup to evaluate for multiple sites of infection. Once the diagnosis is made, treatment at minimum should include IV antibiotics but may require surgical intervention such as debridement with washout or even a manubriectomy.

The authors attest that their institution requires neither Institutional Review Board approval, nor patient consent for publication of this case report. Documentation on file.

Address for Correspondence: Sharmin Kalam, MD, Loma Linda University Medical Center, Department of Emergency Medicine, 11234 Anderson St., Room A890A, Loma Linda, California 92354. Email: Skalam@llu.edu

Conflicts of Interest: By the CPC-EM article submission agreement, all authors are required to disclose all affiliations, funding sources and financial or management relationships that could be perceived as potential sources of bias. The authors disclosed none.

Copyright: © 2024 Wong et al. This is an open access article distributed in accordance with the terms of the Creative Commons Attribution (CC BY 4.0) License. See: <http://creativecommons.org/licenses/by/4.0/>

REFERENCES

1. Kremers HM, Nwojo ME, Ransom JE, et al. Trends in the epidemiology of osteomyelitis: a population-based study, 1969 to 2009. *J Bone Joint Surg Am.* 2015;97(10):837–45.
2. Gill GS and Pulcini M. Maxillary osteomyelitis in a patient with pansinusitis and recently diagnosed focal segmental glomerulosclerosis. *Cureus.* 2019;11(8):e5347.
3. Kolinsky DC and Liang SY. Musculoskeletal infections in the emergency department. *Emerg Med Clin North Am.* 2018;36(4):751–66.
4. Lew DP and Waldvogel FA. Osteomyelitis. *Lancet.* 2004;364(9431):369–79.
5. Platt MA and Ziegler K. Primary sternal osteomyelitis with bacteremia and distal seeding. *J Emerg Med.* 2012;43(2):e93–5.
6. Schmitt SK. Osteomyelitis. *Infect Dis Clin North Am.* 2017;31(2):325–38.
7. Renz N, Haupenthal J, Schuetz MA, et al. Hematogenous vertebral osteomyelitis associated with intravascular device-associated infections - a retrospective cohort study. *Diagn Microbiol Infect Dis.* 2017;88(1):75–81.
8. Carnevale A, Righi R, Maniscalco P, et al. Primary septic arthritis of the manubriosternal joint in an immunocompetent young patient: a case report. *Radiol Case Rep.* 2017;12(4):682–5.
9. DiNardo AR, Schmidt D, Mitchell A, et al. First description of oral *Cryptococcus neoformans* causing osteomyelitis of the mandible, manubrium and third rib with associated soft tissue abscesses in an immunocompetent host. *Clin Microbiol Case Rep.* 2015;1(3):017.
10. Rodríguez Lorenzo P, Fernández Martínez B, Pérez Alba M, et al. Primary sternal osteomyelitis. *Arch Argent Pediatr.* 2023;121(5):e202201449.
11. Li J, Ren J, Wang W, et al. Risk factors and clinical outcomes of hypervirulent *Klebsiella pneumoniae* induced bloodstream infections. *Eur J Clin Microbiol Infect Dis.* 2018;37(4):679–89.
12. de Nadai TR, Daniel RF, de Nadai MN, et al. Hyperbaric oxygen therapy for primary sternal osteomyelitis: a case report. *J Med Case Rep.* 2013;7:167.

Ultrasound-guided Supraclavicular Brachial Plexus Block for Therapeutic Management of Postoperative Compressive Brachial Plexus Neuropathy: A Case Report

Daniela Usuga, MS*
Sofia Portuondo, MD†
David Farcy, MD‡
Michael Shalaby, MD‡

*Florida International University, Herbert Wertheim College of Medicine, Miami, Florida
†Mount Sinai Medical Center Miami Beach, Department of Emergency Medicine, Miami Beach, Florida
‡Florida International University, Herbert Wertheim College of Medicine, Department of Emergency Medicine and Critical Care, Miami, Florida

Section Editor: Shadi Lahham, MD

Submission history: Submitted November 30, 2023; Revision received February 27, 2024; Accepted March 11, 2024

Electronically published June 14, 2024

Full text available through open access at http://escholarship.org/uc/uciem_cpem

DOI: [10.5811/cpcem.6600](https://doi.org/10.5811/cpcem.6600)

Introduction: Compressive neuropathy of the brachial plexus is a common issue following laparoscopic and robotic surgeries.

Case Report: A 71-year-old male, post-lumbar spinal surgery, presented with excruciating right upper extremity pain and paresthesias. A supraclavicular brachial plexus (SBP) block with bupivacaine provided significant pain relief, lasting 36 hours. Subsequent physical therapy led to gradual pain and weakness improvement in compressive neuropathy.

Discussion: The SBP block, facilitated by ultrasound guidance, is a safe procedure with few serious complications. It proves beneficial for managing postoperative compressive neuropathy, allowing patients to break pain cycles and participate in rehabilitation.

Conclusion: The SBP block is an effective addition to the management of postoperative compressive neuropathy, given its ease, safety, and potency. Although regional anesthesia provides only temporary relief, patients can experience a break in debilitating pain cycles associated with compressive neuropathy. [Clin Pract Cases Emerg Med. 2024;8(3)235–238.]

Keywords: *Supraclavicular Brachial Block; ultrasound; compressive neuropathy; brachial plexus.*

INTRODUCTION

The brachial plexus arises from the spinal nerve roots of fifth cervical to first thoracic and supplies sensory and motor innervation to the upper limb and shoulder girdle. Compressive neuropathy, also known as entrapment neuropathy, occurs from the compression of a nerve and can result in temporary or permanent weakness and pain, which can be debilitating.¹ The brachial plexus is located in the posterior triangle in the neck and passes proximally between the scalene muscle and distally between the first rib and clavicle.² With increased utilization of laparoscopic and robotic surgery, there has been an increased incidence of

brachial plexus neuropathy,³ especially given the prolonged time that the patient spends in the Trendelenberg position.²⁻⁴

Previously published case reports and case series have reported brachial plexus neuropathy following prolonged spinal surgery.⁵⁻⁷ Spinal surgeries in which the patient is in the prone position with their arms abducted at an angle greater than 90° have been demonstrated to have significantly increased incidence of postoperative brachial plexus injury.⁶ Such cases have also been replicated in animal studies, in which interrupted blood flow to or prolonged stretching of the brachial plexus results in intraneural capillary rupture and hematoma formation.⁴

Parsonage-Turner syndrome, also known as idiopathic brachial plexopathy or neuralgic amyotrophy, is a rare condition characterized by a diverse range of symptoms.⁸ It typically manifests with sudden onset shoulder pain on one side, followed by progressive neurological issues such as motor weakness, dysesthesias, and numbness. While the exact cause of the syndrome is not well understood, it has been observed in various clinical scenarios, including postoperative compressive, postinfectious, post-traumatic, and post-vaccination settings.⁸

CASE REPORT

Our patient was a 71-year-old man who had a fourth lumbar to fifth lumbar posterior lumbar interbody fusion with third lumbar to fifth lumbar posterolateral decompression and fusion one month before presentation. He presented to our emergency department (ED) with a chief complaint of painful paresthesias of the entire right upper extremity. After remaining on his right lateral decubitus for an extended period intraoperatively, the patient subsequently developed painful paresthesias in the right shoulder and right arm. He had seen a neurologist in the clinic, who prescribed gabapentin 300 milligrams (mg) three times daily and methocarbamol 750 mg three times daily for compressive neuropathy. However, the patient had achieved minimal analgesia with this regimen, and he rated his pain as a 10/10 upon presentation to the ED. The patient's physical exam showed intact strength and reflexes in upper extremities bilaterally. However, he had decreased sensation to sharp touch over the entire upper extremity compared to the left.

The patient consented to a supraclavicular brachial plexus (SBP) block, which was performed with 15 milliliters (mL) bupivacaine 0.5% with epinephrine. He tolerated the procedure well and was pain-free when discharged. At follow-up via phone call one week later he stated that he'd had 36 hours of pain relief from the brachial plexus block. Since the procedure, the patient has been in physical therapy and his pain from his compressive neuropathy has been slowly improving.

DISCUSSION

An ultrasound (US)-guided SBP block involves instilling anesthetic within the nerve sheath to anesthetize the upper, middle, and lower trunks of the brachial plexus. The SBP can typically be visualized by placing a short linear US probe within the supraclavicular fossa, the space immediately posterior to the middle to medial clavicle (*Image*). In this view, the subclavian artery is viewed medial to the SBP, the first rib caudal, and the pleura deep to the first rib (*Figure*).

With an in-plane needle technique, the physician uses a shallow needle approach from lateral to medial to guide the needle toward the SBP. Once the needle is clearly visualized within the SBP sheath, the physician slowly injects aliquots of 5 mL of anesthetic at a time, making sure to aspirate prior to

Population Health Research Capsule

What do we already know about this clinical entity?

Brachial plexus compression is a common post-operative complication, exacerbated by prolonged procedures such as robotic surgeries in the Trendelenberg position.

What makes this presentation of disease reportable?

We report successful treatment of post-operative brachial plexus neuropathy with ultrasound-guided supraclavicular brachial plexus (SBP) block.

What is the major learning point?

Ultrasound-guided SBP block offers significant pain relief for post-operative compressive neuropathy, breaking pain cycles until outpatient management is feasible.

How might this improve emergency medicine practice?

Ultrasound-guided SBP block is a safe, effective option to break pain cycles, enabling therapy and enhancing post-operative compressive neuropathy management.

any injection. Furthermore, injecting at the “corner pocket” (*Figure*) closest to the subclavian artery helps to guarantee complete anesthesia of the inferior trunk of the brachial plexus.⁹ The SBP is very superficial, typically 1–2 centimeters deep in the skin; thus, a 22-gauge, non-spinal needle can usually be used for this procedure. The Miller weight-based local anesthetic dosing should be used to calculate the ideal anesthetic dosage based on ideal body weight.¹⁰ However, 15–20 mL of local anesthetic is usually adequate for anesthesia of the upper limb. The first rib serves as a backstop, should the physician accidentally overshoot the SBP, to avoid causing a pneumothorax.¹⁰ Besides pneumothorax, other complications of the SBP include axonal damage, hemidiaphragmatic paralysis, and subclavian artery puncture.¹⁰

The use of US to perform a SBP block, as opposed to the landmark-based technique, significantly reduces the likelihood of pneumothorax and neuronal injury, as reported in previous studies.^{11,12} Additionally, should the performing physician maintain proper needle control throughout the procedure, the pleura and subclavian artery remain comfortably outside the needle's trajectory to the SBP.⁹ By anesthetizing all trunks of the brachial plexus, the

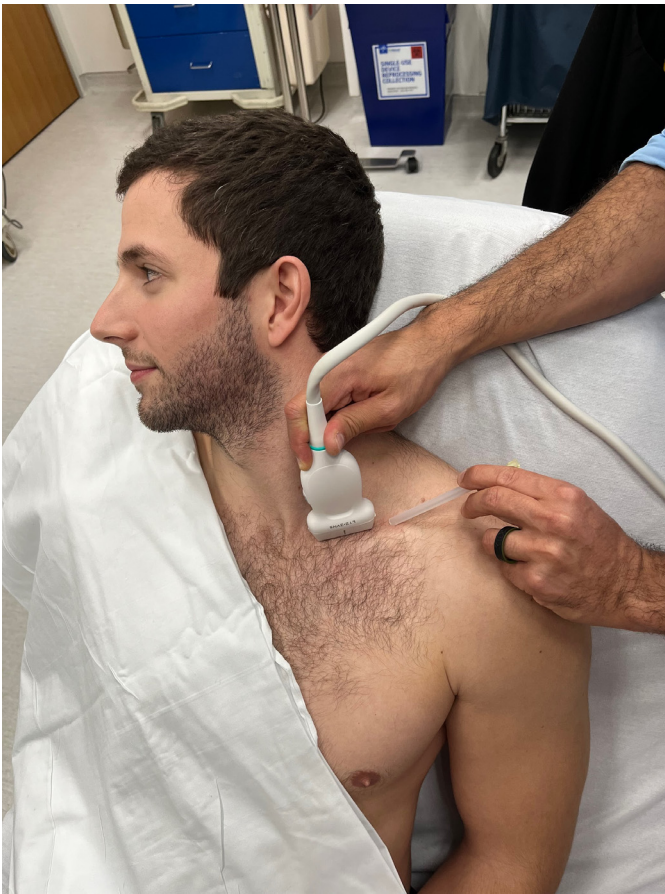

Image. Ultrasound probe placement in the supraclavicular fossa to identify and anesthetize the supraclavicular brachial plexus. The needle is shown before introduction from a lateral to medial approach (shown here on a model patient).

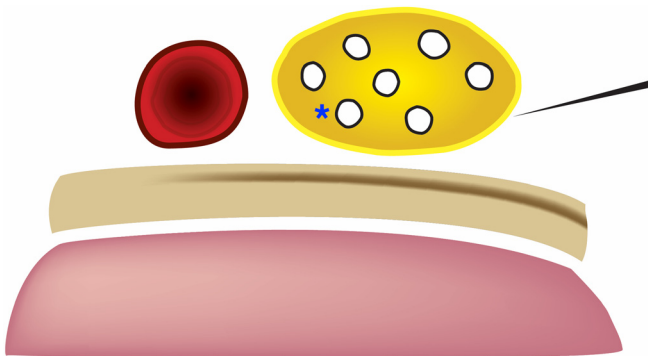


Figure. Graphic demonstrating the supraclavicular brachial plexus (yellow), subclavian artery medial (red), first rib deep (beige), and pleura (pink). The needle shaft makes a shallow angle towards the brachial plexus. The blue asterisk represents the “corner pocket.”

SBP block provides reliable anesthesia of most of the upper extremity, including the shoulder, but sparing the upper medial arm (which is innervated by the second thoracic spinal nerve).^{13,14,15}

The brachial plexus has increased vulnerability to injury due to its superficial location in the neck and to patient positioning during certain prolonged surgical procedures. While our patient had not yet received a formal diagnosis of Parsonage-Turner Syndrome by his neurologist, his symptoms were consistent with the disease. Although chronic pain resulting from compressive neuropathy often fluctuates in intensity, our patient experienced excruciating pain, which caused him to present to the ED that day. While regional anesthesia does not provide a permanent solution, it can afford a substantial amount of relief in the short term and break pain cycles.

Subsequently, our patient was able to resume his physical therapy without revisiting the ED due to pain. For patients grappling with similar debilitating pain caused by compressive neuropathy, regional anesthesia can be a safe and effective option. Furthermore, per the American Society of Regional Anesthesia, post-surgical compressive neuropathy is not a contraindication to treatment with regional anesthesia.¹⁶ The SBP block is feasible for emergency physicians to perform at the bedside, and the use of US significantly reduces complications.^{6,16-19}

CONCLUSION

Considering the ease, safety, and potency of the SBP block, emergency physicians should include the SBP block in the multimodal approach to the management of postoperative compressive neuropathy. While pain from compressive neuropathy is chronic, it also waxes and wanes and at times can become debilitating. Thus, regional anesthesia in general can provide significant relief for patients experiencing similar pain.

Video. Performance of an ultrasound-guided supraclavicular brachial plexus block.
SA, subclavian artery; BP, brachial plexus; NS, needle shaft.

Patient consent has been obtained and filed for the publication of this case report.

Address for Correspondence: Daniela Usuga, MS, Florida International University, Herbert Wertheim College of Medicine, 11200 SW 8th St., AHC2, Miami, FL 33199. Email: 15danielausuga@gmail.com

Conflicts of Interest: By the CPC-EM article submission agreement, all authors are required to disclose all affiliations, funding sources and financial or management relationships that could be perceived as potential sources of bias. The authors disclosed none.

Copyright: © 2024 Usuga et al. This is an open access article distributed in accordance with the terms of the Creative Commons Attribution (CC BY 4.0) License. See: <http://creativecommons.org/licenses/by/4.0/>

REFERENCES

1. Thatte MR and Mansukhani KA. Compressive neuropathy in the upper limb. *Indian J Plast Surg.* 2011;44(2):283–97.
2. Kwann JH and Rappaport I. Postoperative brachial plexus palsy. a study on the mechanism. *Arch Surg.* 1970;101(5):612–5.
3. Thomas J. Post-operative brachial plexus neuropraxia: a less recognised complication of combined plastic and laparoscopic surgeries. *Indian J Plast Surg.* 2014;47(3):460–4.
4. Chin P and Poole G. Bilateral brachial plexus injury during laparoscopic sigmoid colectomy. *ANZ J Surg.* 2003;73(1–2):86–8.
5. Schwartz DM, Sestokas AK, Hilibrand AS, et al. Neurophysiological identification of position-induced neurologic injury during anterior cervical spine surgery. *J Clin Monit Comput.* 2006;20(6):437–44.
6. Than KD, Mummaneni PV, Smith ZA, et al. Brachial plexopathy after cervical spine surgery. *Global Spine J.* 2017;7(1 Suppl):17S–20S.
7. Uribe JS, Kolla J, Omar H, et al. Brachial plexus injury following spinal surgery. *J Neurosurg Spine.* 2010;13(4):552–8.
8. Feinberg JH and Radecki J. Parsonage-turner syndrome. *HSS J.* 2010;6(2):199–205.
9. Soares LG, Brull R, Lai J, et al. Eight ball, corner pocket: the optimal needle position for ultrasound-guided supraclavicular block. *Reg Anesth Pain Med.* 2007;32(1):94–5.
10. Shalaby M, Smith M, Tran L, et al. Utility of supraclavicular brachial plexus block for anterior shoulder dislocation: could it be useful? *West J Emerg Med.* 2023;24(4):793–7.
11. Bendtsen TF, Lopez AM, Vandepitte C. Ultrasound-guided supraclavicular brachial plexus nerve block. 2018. Available at: <https://www.nysora.com/topics/regional-anesthesia-for-specific-surgical-procedures/upper-extremity-regional-anesthesia-for-specific-surgical-procedures/anesthesia-and-analgesia-for-elbow-and-forearm-procedures/ultrasound-guided-supraclavicular-brachial-plexus-block/>. Accessed October 1, 2023.
12. Kapral S, Krafft P, Eibenberger K, et al. Ultrasound-guided supraclavicular approach for regional anesthesia of the brachial plexus. *Anesth Analg.* 1994;78(3):507–13.
13. Shalaby M and Sahni R. Supraclavicular brachial plexus block: the unsung hero of emergency department regional anesthesia. *Clin Exp Emerg Med.* 2023;10(3):342–4.
14. Brown DL, Cahill DR, Bridenbaugh LD. Supraclavicular nerve block: anatomic analysis of a method to prevent pneumothorax. *Anesth Analg.* 1993;76(3):530–4.
15. D'Souza RS and Johnson RL. Supraclavicular Block. In: *StatPearls*. Treasure Island (FL): StatPearls Publishing; 2023.
16. Perlas A, Lobo G, Lo N, et al. Ultrasound-guided supraclavicular block: outcome of 510 consecutive cases. *Reg Anesth Pain Med.* 2009;34(2):171–6.
17. Togioka BM and Wu CL. Supraclavicular block. 2019. Available at: <https://www.asra.com/news-publications/asra-updates/blog-landing/legacy-b-blog-posts/2019/08/07/supraclavicular-block>. Accessed September 20, 2023.
18. Williams SR, Chouinard P, Arcand G, et al. Ultrasound guidance speeds execution and improves the quality of supraclavicular block. *Anesth Analg.* 2003;97(5):1518–23.
19. Franco CD, Gloss FJ, Voronov G, et al. Supraclavicular block in the obese population: an analysis of 2020 blocks. *Anesth Analg.* 2006;102(4):1252–4.

Neurogenic Pulmonary Edema Associated with Hyponatremia, Primary Polydipsia, and Cannabis Use: A Case Report

Christian Treat, MD, MSPH
Nicholas Ulloa, MD
Alyssa Kettler, MD
David Lawrence, DO

Stony Brook University, Department of Emergency Medicine, Stony Brook, New York

Section Editor: Joel Moll, MD

Submission history: Submitted November 15, 2023; Revision received February 27, 2024; Accepted March 12, 2024

Electronically published June 3, 2024

Full text available through open access at http://escholarship.org/uc/uciem_cpce

DOI: [10.5811/cpcem.6562](https://doi.org/10.5811/cpcem.6562)

Introduction: Neurogenic pulmonary edema is a rare and potentially life-threatening condition that can present as severe pulmonary edema after significant neurologic insults. This is the first documented instance that shows a plausible causal link between cannabis consumption, psychogenic polydipsia, and the subsequent development of neurogenic pulmonary edema associated with status epilepticus secondary to acute hyponatremia.

Case Report: We report a case of a 34-year-old female who presented to the emergency department altered and postictal after a witnessed new-onset seizure. She developed significant respiratory distress that required intubation. Her sodium was 121 millimoles per liter (mmol/L), from 137 mmol/L 36 hours prior on routine outpatient labs. Further history revealed excessive water ingestion after eating a cannabis edible prior to the seizure.

Conclusion: This case highlights the importance of recognizing neurogenic pulmonary edema in connection with psychogenic polydipsia, severe hyponatremia, and status epilepticus subsequent to cannabis consumption. [Clin Pract Cases Emerg Med. 2024;8(3)239–242.]

Keywords: *neurogenic pulmonary edema; hyponatremia; primary polydipsia; cannabis intoxication; case report.*

INTRODUCTION

Neurogenic pulmonary edema (NPE) is a rare and potentially life-threatening condition that can occur as a complication of neurologic insults such as seizures, traumatic brain injury, and intracranial hemorrhage.¹ It is believed to result from a sudden increase in sympathetic tone leading to increased pulmonary capillary hydrostatic pressure and increased pulmonary vascular permeability.^{2,3} Neurogenic pulmonary edema is often associated with significant morbidity and mortality, and early recognition and management are crucial for favorable outcomes. In this case report, we illustrate a plausible causal link between cannabis consumption, psychogenic polydipsia, and the subsequent development of NPE associated with status epilepticus secondary to acute hyponatremia.

CASE REPORT

A 34-year-old female with a medical history of well-controlled HIV, depression, and anxiety presented to the emergency department (ED) with new-onset seizures. According to her partner, she had consumed an edible cannabis cookie earlier in the day and then drank approximately eight 16.9-ounce bottles of water over the course of one hour in response to her severe thirst. Emergency medical services were called because she had a witnessed, generalized tonic-clonic seizure that lasted approximately five minutes. Prehospital vital signs were notable for peripheral oxygen saturation (SpO₂) of 69% on room air and a fingerstick glucose of 254 milligrams per deciliter (mg/dL) (normal range 70–99 mg/dL).

On arrival to the ED, the patient's heart rate was 104 beats per minute, blood pressure 117/71 millimeters of mercury (mm Hg), respiratory rate of 39 breaths per minute, and SpO₂ 69% on room air. A non-rebreather mask was placed with improvement of SpO₂ to 90%. She was combative and altered, unable to follow commands to not remove the non-rebreather mask, and demanding water from ED staff. Due to excessive agitation, 50 mg of intravenous (IV) ketamine was given to the patient to allow us to obtain an emergent computed tomography (CT) head without contrast, CT angiogram head and neck, and CT chest without contrast. Following CT imaging, she had another seizure and her SpO₂ in the low 80% range despite non-rebreather mask. In the setting of her refractory hypoxia, altered mental status, and seizures, the decision was made to intubate. We used a delayed sequence intubation to preoxygenate the patient by first administering 100 mg of IV ketamine. This improved SpO₂ to 96%. Then we proceeded with paralysis with 100 mg of rocuronium and intubated successfully without episodes of hypoxia. Post-intubation, we administered propofol at a rate of 20 micrograms (mcg)/kg/minute.

Laboratory evaluation of the patient revealed marked hyponatremia of 121 millimoles per liter (mmol/L), compared to her baseline level of 137 mmol/L obtained 36 hours prior during a routine outpatient visit (normal range 135–146 mmol/L). Two ampules (100 mL) of 8.4% sodium bicarbonate were administered to the patient for acute symptomatic hyponatremia. Acetaminophen, salicylate, and ethanol levels were all negative. A urine toxicology screen was positive for cannabis, and an expanded urine toxicology panel was sent to an external laboratory. Emergent CT imaging showed normal findings on non-contrast head and angiography of the head and neck, and a CT perfusion study demonstrated no signs of acute infarction. The non-contrast CT chest revealed multifocal airspace and diffuse bilateral ground-glass opacities, with no evidence of effusion or pneumothorax.

Arterial blood gas analysis revealed the following results after intubation: pH 7.20 (normal range 7.35–7.45), partial pressure of carbon dioxide (PaCO₂) 59 mm Hg (35 to 45 mm Hg), partial pressure of oxygen (PaO₂) 83 mm Hg (normal range 80–100 mm Hg), and bicarbonate 23 mmol/L (22–26 mmol/L). The patient's ventilation status necessitated high levels of positive end-expiratory pressure (PEEP) and fraction of inspired oxygen (FiO₂), 16 centimeters H₂O and 100%, respectively. She was admitted to the intensive care unit for acute hyponatremia and hypoxemic respiratory failure. After receiving two ampules of sodium bicarbonate in the ED, her sodium levels increased from an initial level of 121 mmol/L to 123 mmol/L after four hours. Subsequently, she was administered two doses of 100 mL of 3% saline, resulting in a repeat sodium level of 131 mmol/L after 13 hours from initial sodium level. Finally, her sodium reached 135 mmol/L after 29 hours from initial level.

Population Health Research Capsule

What do we already know about this clinical entity?

Neurogenic pulmonary edema (NPE) is a rare, life-threatening complication arising from neurological insults such as seizures and intracranial hemorrhage.

What makes this presentation of disease reportable?

This report highlights a novel case of psychogenic polydipsia from cannabis use leading to NPE with status epilepticus due to hyponatremia.

What is the major learning point?

Cannabis use may lead to psychogenic polydipsia, symptomatic hyponatremia, and potentially induce neurologic sequelae including seizures and NPE.

How might this improve emergency medicine practice?

Patterns of increasing cannabis use in the United States show the need to consider lesser known complications in patients with cannabis-related ED visits.

Her expanded drug toxicology panel that was sent to an outside laboratory reported that her urine was positive for >500 mcg/mL 11-nor-9-carboxy-tetrahydrocannabinol (the psychoactive compound found in cannabis) and negative for 3,4-methylenedioxyamphetamine (MDMA), amphetamines, barbiturates, benzodiazepine, cocaine, methadone, opiates, phencyclidine, and propoxyphene.

The patient's ventilatory requirements were weaned to FiO₂ 40%, PEEP 10 cm H₂O, with pH 7.35, PaCO₂ 37 mm Hg, and PaO₂ 155 mm Hg, and she was extubated to four liters nasal cannula 14 hours after intubation and transferred to the general medical floors on hospital day three.

An echocardiogram performed showed normal cardiac parameters with an ejection fraction of 71% and normal valvular structures. An electrocardiogram showed sinus rhythm, short PR interval, narrow QRS, and normal QTc. Telemetry was without evidence of any ventricular arrhythmias. Follow-up chest radiographs (CXR) showed resolving pulmonary edema.

Intravenous ceftriaxone and azithromycin were continued for her hospital course. The patient was afebrile, had no leukocytosis, and reported no respiratory issues

post-extubation. The infectious workup also included a sputum culture with normal flora, negative urinary legionella and pneumococcal antigens, negative blood cultures, and negative urine cultures. Additionally, a CD4 level drawn two days prior to admission was 752 cells per microliter, HIV viral load was undetectable, and a respiratory pathogen panel, including testing for respiratory syncytial virus, influenza virus, and SARS-CoV-2, was negative. The patient underwent 24-hour video electroencephalogram monitoring, which revealed no seizure activity and she returned to normal neurological status by hospital day one after sodium correction.

On social work evaluation, she was adherent to her mental healthcare treatment regimen, regularly attended therapy, and used escitalopram for depression and anxiety. She had no documented psychiatric hospitalizations, suicidal or homicidal ideation, or hallucinations in the prior year. She was discharged to home on hospital day six. She reported no acute concerns at her subsequent primary care and nephrology follow-up visits, seven and 22 days later, respectively.

DISCUSSION

This case shows the development of NPE from severe acute hyponatremia caused by psychogenic polydipsia related to cannabis use. To our knowledge, this specific acute complication of cannabis has not been extensively reported. Preliminary data has shown the association between chronic cannabis use and hyponatremia. In rat models, chronic marijuana administration reduced serum sodium in rats over a 12-week period, likely via inhibitor effects on sodium channels.⁴ Another study used spectrophotometry to estimate serum sodium levels in a sample of regular marijuana smokers and non-marijuana smoking controls and found significantly decreased mean sodium levels of 119 ± 26 mmol/L compared to mean sodium levels of 140 ± 6 mmol/L.⁵ Taken together, this evidence indicates marijuana can disrupt sodium balance, which emergency physicians should recognize as an important possible complication of cannabis use.

Any acute central nervous system event that abruptly triggers a sympathetic discharge can potentially trigger NPE. Multiple references link status epilepticus to noncardiogenic pulmonary edema, emphasizing the relevance of considering NPE in the context of seizure-related complications. For instance, one report described a stronger association between seizures lasting greater than 200 seconds and the development of pulmonary edema on CXR.⁶

Proposed criteria for the diagnosis of NPE include the following: bilateral opacities, PaO₂/FiO₂ ratio <200; no evidence of left arterial hypertension, presence of neurologic injury, and absence of other causes of acute respiratory distress syndrome.⁷ Our patient, who presented with first-time seizures, had bilateral opacities and met criteria for severe acute

respiratory distress syndrome (ARDS) with a PaO₂/FiO₂ of 83. The echocardiogram findings, including normal left ventricular size, wall thickness, global systolic function, absence of hypertrophy, and no signs of impaired diastolic function or left atrial enlargement, collectively suggested no evidence of left arterial hypertension in the patient.

Intriguingly, Ayus-Arieff syndrome is a condition characterized by hyponatremia-induced cerebral edema leading to the development of pulmonary edema and has been documented in case reports, particularly in contexts involving MDMA use and in marathon runners.^{8,9} No reports currently link it to cannabis consumption. The syndrome became a significant consideration for our patient, who experienced new-onset seizures in the context of acute hyponatremia, attributable to polydipsia secondary to cannabis intoxication. Subsequently, she required intubation due to acute hypoxemic respiratory failure associated with ARDS. Notably, a thorough workup revealed normal cardiological and infectious parameters with a rapid return to clinical baseline following correction of sodium.

Effective management of hyponatremia requires a tailored approach based on underlying causes and severity. Hyponatremia stems from diverse causes, including severe renal failure, excessive water intake, hypovolemic factors such as gastrointestinal losses or diuretics, euvolemic conditions such as adrenal insufficiency and syndrome of inappropriate antidiuretic hormone (SIADH), and edematous states such as heart failure or cirrhosis. Patients with acute hyponatremia exhibit serum sodium levels below 135 mmol/L within 48 hours, while chronic hyponatremia develops over more than 48 hours or is assumed in the absence of a known baseline. The management of hyponatremia is critically influenced by its chronicity and severity. Immediate concerns in symptomatic hyponatremia involve seizures, cerebral edema, and brain herniation. In chronic cases, the risk lies in the potential for rapid correction. Although osmotic demyelination is rare if the initial sodium level exceeds 120 mmol/L, it becomes a concern with a high rate of sodium rise, typically surpassing 8 mmol/L in a 24-hour period.¹⁰

The patient's acute hyponatremia appeared to be linked to psychogenic polydipsia given the historical context, likely due to excessive water intake in the setting of cannabis intoxication. Given her history of depression and anxiety, an alternative diagnosis could be SIADH, which is known to be associated with antidepressants.¹¹ This syndrome tends to have a more insidious onset, making this diagnosis less likely as her sodium was within normal range the day prior to hospitalization.

In terms of management, patients who develop severe symptoms such as seizures or coma, should be treated promptly and aggressively with hypertonic 3% saline. Of note, multiple studies confirm that 3% saline is safe to administer through a peripheral line.¹²⁻¹⁴ Therefore,

attempting central access is unnecessary and should not delay treatment. Depending on the ED, 3% saline may require the pharmacy to prepare, which will further delay treatment. In those circumstances, ampules of sodium bicarbonate are a resourceful alternative for the treatment of severe hyponatremia. For example, one ampule of sodium bicarbonate has the same osmolarity of 5.8% saline, essentially twice the osmolarity of 3% saline.¹⁵ Therefore, 50 mL of sodium bicarbonate, or one ampule, is roughly equivalent to 100 mL of 3% saline. For our patient, we administered 100 mL, or two ampules, of sodium bicarbonate because it was the most rapid method to treat her severe hyponatremia. This increased her sodium to 123 mmol/L, which was within our goal.

CONCLUSION

This case underscores the rare occurrence of neurogenic pulmonary edema linked to psychogenic polydipsia, severe hyponatremia, and status epilepticus following cannabis consumption. The significance of this potential association with cannabis is heightened against the backdrop of the escalating consumption, decriminalization, and legalization trends observed in the United States. This not only underscores the clinical complexity of the case but also emphasizes the urgent need for thorough investigation and awareness as cannabis usage patterns evolve.

The authors attest that their institution requires neither Institutional Review Board approval, nor patient consent for publication of this case report. Documentation on file.

Address for Correspondence: Christian Treat, MD, MSPH, Renaissance School of Medicine at Stony Brook University, Department of Emergency Medicine, 101 Nicolls Road, Stony Brook, NY 11794. Email: Christian.Treat@stonybrookmedicine.edu

Conflicts of Interest: By the CPC-EM article submission agreement, all authors are required to disclose all affiliations, funding sources and financial or management relationships that could be perceived as potential sources of bias. The authors disclosed none.

Copyright: © 2024 Treat et al. This is an open access article distributed in accordance with the terms of the Creative Commons Attribution (CC BY 4.0) License. See: <http://creativecommons.org/licenses/by/4.0/>

REFERENCES

- Rogers FB, Shackford SR, Trevisani GT, et al. Neurogenic pulmonary edema in fatal and nonfatal head injuries. *J Trauma*. 1995;39(5):860–6.
- Hall S RR, Wang L, Milne B, et al. Intrathecal lidocaine prevents cardiovascular collapse and neurogenic pulmonary edema in a rat model of acute intracranial hypertension. *Anesth Analg*. 2002;94(4):948–53.
- Šedý J, Kuneš J, Zicha J. Pathogenetic mechanisms of neurogenic pulmonary edema. *J Neurotrauma*. 2015;32(15):1135–45.
- Taiwo OA, Dosumu OA, Ugbaja RN, et al. Oral administration of marijuana produces alterations in serotonin 5-hydroxytryptamine receptor 3A gene (*HTR3A*) and electrolyte imbalances in brain of male Wistar rats. *Mol Biol Res Commun*. 2021;10(1):5–11.
- Osadolor HB and Emokpae AM. Effects of marijuana on sodium and potassium (Na⁺& K⁺) ions homeostasis among smokers in Benin City - a metropolitan city in Nigeria. *Int J Pharm Bio Sci*. 2010;3(1):1–3.
- Kennedy JD, Hardin KA, Parikh P, et al. Pulmonary edema following generalized tonic clonic seizures is directly associated with seizure duration. *Seizure*. 2015;27:19–24.
- Davison DL, Terek M, Chawla LS. Neurogenic pulmonary edema. *Crit Care*. 2012;16(2):212.
- Ayus JC, Varon J, Arieff AI. Hyponatremia, cerebral edema, and noncardiogenic pulmonary edema in marathon runners. *Ann Intern Med*. 2000;132(9):711–4.
- Thakkar A, Parekh K, El Hachem K, et al. A case of MDMA-associated cerebral and pulmonary edema requiring ECMO. *Case Rep Crit Care*. 2017;2017:6417012.
- Rondon-Berrios H. Therapeutic relowering of plasma sodium after overly rapid correction of hyponatremia: what is the evidence? *Clin J Am Soc Nephrol*. 2020;15(2):282–4.
- Pinkhasov A, Xiong G, Bourgeois JA, et al. Management of SIADH-related hyponatremia due to psychotropic medications: an expert consensus from the Association of Medicine and Psychiatry. *J Psychosom Res*. 2021;151:110654.
- Moussavi K. Safety of peripheral line administration of 3% hypertonic saline and mannitol in the emergency department. *J Emerg Med*. 2019;56(4):431–6.
- Meng L, Nguyen CM, Patel S, et al. Association between continuous peripheral IV infusion of 3% sodium chloride injection and phlebitis in adults. *Am J Health Syst Pharm*. 2018;75(5):284–91.
- Dillon RC, Merchan C, Altshuler D, et al. Incidence of adverse events during peripheral administration of sodium chloride 3%. *J Intensive Care Med*. 2018;33(1):48–53.
- Farkas J. Emergent treatment of hyponatremia or elevated ICP with bicarb ampules. 2015. Available at: <https://emcrit.org/pulmcrit/emergent-treatment-of-hyponatremia-or-elevated-icp-with-bicarb-ampules/>. Accessed June 7, 2023.

Spontaneous Intracranial Hypotension Associated with Marfan Syndrome: A Case Report

Faiza Tariq, MBBS
Wesley Eilbert, MD

University of Illinois, College of Medicine, Department of Emergency Medicine, Chicago, Illinois

Section Editor: Jacqueline Le, MD

Submission history: Submitted January 23, 2024; Revision received March 6, 2024; Accepted March 12, 2024

Electronically published May 29, 2024

Full text available through open access at http://escholarship.org/uc/uciem_cpem

DOI: [10.5811/cpcem.7223](https://doi.org/10.5811/cpcem.7223)

Introduction: Spontaneous intracranial hypotension (SIH) is an uncommon and frequently misdiagnosed condition characterized by a lower-than-normal volume of cerebrospinal fluid (CSF) caused by leakage of CSF through the dural membrane. The primary manifestation of SIH is an orthostatic headache, which is frequently accompanied by nausea and vomiting. Patients with connective tissue disorders are at increased risk for spontaneous CSF leaks due to the structural weakness of their dural membranes.

Case Report: An 18-year-old woman with no reported past medical history presented to the emergency department with 10 days of a bifrontal headache that was orthostatic in nature with associated nausea and vomiting. She was noted to have several marfanoid features on physical examination. Spontaneous intracranial hypotension was ultimately diagnosed and treated successfully with an epidural blood patch. Subsequent genetic testing revealed a diagnosis of Marfan syndrome.

Conclusion: Spontaneous intracranial hypotension is an uncommon cause of headache. Individuals with connective tissue disorders such as Marfan syndrome are at increased risk for SIH. Knowledge of the relationship between these two conditions allows for a more rapid diagnosis of SIH. [Clin Pract Cases Emerg Med. 2024;8(3)243–245.]

Keywords: *spontaneous intracranial hypotension; Marfan syndrome; meningeal diverticulum; spinal cerebrospinal fluid leak; case report.*

INTRODUCTION

First described in 1938, spontaneous intracranial hypotension (SIH) is a condition characterized by a lower-than-normal volume of cerebrospinal fluid (CSF) caused by leakage of CSF through the dural membrane.^{1,2} Patients with connective tissue disorders are at increased risk for spontaneous CSF leaks due to the structural weakness of their dural membranes.³ The primary manifestation of SIH is an orthostatic headache that may be accompanied by nausea, tinnitus, and photophobia.⁴ We report the case of a young woman with previously undiagnosed Marfan syndrome who presented with SIH.

CASE REPORT

An 18-year-old woman presented to the emergency department (ED) complaining of a bifrontal headache present for 10 days. The headache was of insidious onset and was significantly worse in the upright position, better when supine. She reported nausea with the headache and one episode of vomiting two days earlier. On physical examination, she had several marfanoid features including a tall, slender build with disproportionately long arms, legs, and fingers. She was afebrile and had a normal neurologic examination.

Computed tomography of her brain showed no significant abnormalities and magnetic resonance imaging (MRI) of the brain with venogram was ordered because of concern for possible dural venous sinus thrombosis. The MRI showed dural thickening and increased dural enhancement suggestive of intracranial hypotension. The patient was admitted to the hospital, and MRI of the cervical, thoracic, and lumbar spine performed the next day showed no extradural fluid collections to suggest a CSF leak. She had modest improvement of her headache after an epidural blood patch and was discharged on hospital day three.

The patient returned to the ED five days later complaining of a return of the headache. A second MRI of the spine was performed that showed a meningeal diverticulum arising from the left first and second thoracic level with an adjacent pleural effusion concerning for a possible ruptured nerve root sleeve diverticulum (*Image*). She received a second epidural blood patch with complete, longstanding relief of the headache. Subsequent outpatient genetic testing revealed a pathogenic variant of the FBN1 gene consistent with a diagnosis of Marfan syndrome.

DISCUSSION

Spontaneous intracranial hypotension is distinguished from other causes of CSF leaks of known cause such as spinal surgery, craniospinal trauma, and, most commonly, lumbar puncture or spinal anesthesia. Spontaneous intracranial hypotension is an uncommon cause of headache in the ED, with an estimated annual incidence of 5/100,000 individuals—half the incidence of subarachnoid hemorrhage.⁵ Women are diagnosed with SIH more

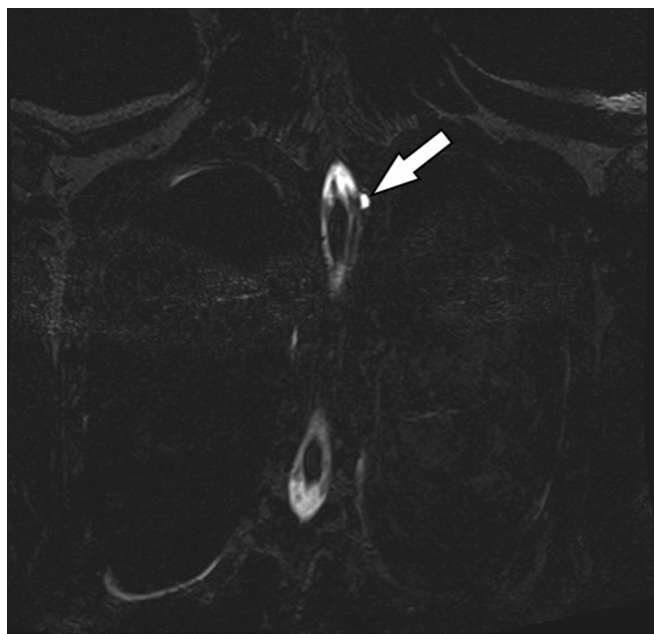


Image. Magnetic resonance imaging (coronal view) showing a meningeal diverticulum at the first and second thoracic level (arrow).

Population Health Research Capsule

What do we already know about this clinical entity?

Spontaneous intracranial hypotension (SIH) is caused by leakage of cerebrospinal fluid through the dural membrane, which can be weakened by connective tissue disorders.

What makes this presentation of disease reportable?

A woman who presented with an orthostatic headache was ultimately diagnosed with SIH. Genetic testing later revealed a diagnosis of Marfan syndrome.

What is the major learning point?

Individuals with connective tissue disorders such as Marfan syndrome are at increased risk for spontaneous cerebrospinal fluid leaks resulting in SIH.

How might this improve emergency medicine practice?

Knowledge of the predilection of patients with connective tissue disorders for SIH may assist clinicians in the diagnosis of similar cases.

frequently than men, with a female-male ratio of approximately 2:1.⁶ Spontaneous intracranial hypotension is often initially misdiagnosed, with 94% of patients receiving an incorrect initial diagnosis in one study.⁷ The headache caused by SIH is believed to be the result of downward displacement of the brain due to loss of CSF buoyancy, resulting in traction on pain-sensitive fibers in the dura mater.^{3,6} The orthostatic headache caused by SIH is typically described as diffuse, occipital, or frontal.⁴ Other associated symptoms are often present (*Table 1*).⁴

Table 1. Symptoms associated with the headache of spontaneous intracranial hypotension.

Symptom	Estimated proportions
Nausea/vomiting	54%
Neck pain/stiffness	43%
Hearing disturbances	28%
Dizziness	27%
Tinnitus	20%
Vertigo	17%
Photophobia	11%

Table 2. Diagnostic criteria for spontaneous intracranial hypotension.

1. Any headache attributed to low CSF pressure or CSF leakage that meets criterion 3 below.
2. Either or both of the following:
 - a. Low CSF pressure (<60 mm H₂O CSF)
 - b. Evidence of CSF leakage on imaging
3. Headache that developed in temporal relation to the low CSF pressure or CSF leakage, or that leads to its discovery.
4. Absence of a procedure or trauma known to be able to cause CSF leakage.
5. Headache not better accounted for by another diagnosis.

CSF, cerebrospinal fluid; mm H₂O, millimeters of water.

The location of the CSF leak with SIH is often not determined since spinal CSF leaks generally do not cause local symptoms.⁶ Extradural spinal CSF collections are found in approximately half of all patients with SIH.² The majority of identified spinal CSF leaks occur at the thoracic or cervicothoracic spine level.⁸ Spinal CSF leaks occur via three main mechanisms: meningeal diverticula; ventral dural tears; and CSF-venous fistulas, with diverticula being most common.⁹ Patients with genetic connective tissue disorders such as Marfan syndrome, Ehlers-Danlos syndrome Type II, and autosomal dominant polycystic kidney disease are at higher risk for spontaneous CSF leaks due to the structural weakness of their dural membranes.^{3,10} One prospective study found that up to two-thirds of patients with spontaneous spinal CSF leaks had some evidence of a connective tissue disorder.¹⁰

Diagnostic criteria for SIH have been proposed (Table 2).^{2,11} Brain MRI with contrast is the most sensitive imaging study for diagnosing SIH.^{4,9} Smooth, generalized dural enhancement is the feature most commonly seen, present in 73% of patients with SIH.^{2,4} Many cases of SIH resolve spontaneously with no specific treatment required.¹² Initial conservative treatments of bed rest, oral hydration, and caffeine are effective in approximately 25% of patients.⁴ Epidural blood patching is the most commonly performed intervention for spinal CSF leaks, with estimates of efficacy ranging from 36–90%.⁹

CONCLUSION

Spontaneous intracranial hypotension is an uncommon cause of headache and is frequently misdiagnosed. Individuals with Marfan syndrome and other connective tissue disorders are at increased risk for SIH due to the structural weakness of their dural membranes predisposing to spontaneous CSF leaks. Knowledge of the relationship between these associated conditions allows for more rapid diagnosis of SIH.

The authors attest that their institution requires neither Institutional Review Board approval, nor patient consent for publication of this case report. Documentation on file.

Address for Correspondence: Wesley Eilbert, MD, University of Illinois, College of Medicine, Department of Emergency Medicine, 1819 W. Polk St., Room 469, Chicago, IL 60612.

Email: weilbert@uic.edu

Conflicts of Interest: By the CPC-EM article submission agreement, all authors are required to disclose all affiliations, funding sources and financial or management relationships that could be perceived as potential sources of bias. The authors disclosed none.

Copyright: © 2024 Tariq et al. This is an open access article distributed in accordance with the terms of the Creative Commons Attribution (CC BY 4.0) License. See: <http://creativecommons.org/licenses/by/4.0/>

REFERENCES

1. Schaltenbrand G, Neure anschauungen zur pathophysiologie der liquorzirkulation (Recent views on the pathophysiology of CSF circulation). *Zentralbl Neurochir.* 1938;3:290–300.
2. Schievink WI. Spontaneous intracranial hypotension. *N Engl J Med.* 2021;385(23):2173–8.
3. Dobrocky T, Nicholson P, Hani L, et al. Spontaneous intracranial hypotension: searching for the CSF leak. *Lancet Neurol.* 2022;21(4):369–80.
4. D'Antona L, Jaime Merchan MA, Vassiliou A, et al. Clinical presentation, investigation findings, and treatment outcomes of spontaneous intracranial hypotension syndrome: a systematic review and meta-analysis. *JAMA Neurol.* 2021;78(3):329–37.
5. Schievink WI, Maya MM, Moser F, et al. Frequency of spontaneous intracranial hypotension in the emergency department. *J Headache Pain.* 2007;8(6):325–8.
6. Schievink WI. Spontaneous spinal cerebrospinal fluid leaks and intracranial hypotension. *JAMA.* 2006;295(19):2286–96.
7. Schievink WI. Misdiagnosis of spontaneous intracranial hypotension. *Arch Neurol.* 2003;60(12):1713–8.
8. Mokri B, Maher CO, Sencakova D. Spontaneous CSF leaks: underlying disorder of connective tissue. *Neurology.* 2002;58(5):814–6.
9. Kranz PG, Gray L, Malinzak MD, et al. Spontaneous intracranial hypotension: pathogenesis, diagnosis and treatment. *Neuroimaging Clin N Am.* 2019;29(4):581–94.
10. Schievink WI, Gordon OK, Tourje J. Connective tissue disorders with spontaneous spinal cerebrospinal fluid leaks and intracranial hypotension: a prospective study. *Neurosurgery.* 2004;54(1):65–70.
11. Headache Classification Committee of the International Headache Society (IHS). The International Classification of Headache Disorders, 3rd ed. *Cephalgia.* 2018;38(1):1–211.
12. Davenport RJ, Chataway SJ, Warlow CP. Spontaneous intracranial hypotension from a CSF leak in a patient with Marfan's syndrome. *J Neurol Neurosurg Psychiatry.* 1995;59(5):516–9.

Atrial Fibrillation Occurring After Smoking Marijuana: A Case Report and Review of the Literature

Mary Unanyan, DO
Christopher Colbert, DO
Wesley Eilbert, MD

University of Illinois at Chicago, College of Medicine, Department of Emergency Medicine,
Chicago, Illinois

Section Editor: Steven Walsh, MD

Submission history: Submitted January 23, 2024; Revision received March 2, 2024; Accepted March 2, 2024

Electronically published July 11, 2024

Full text available through open access at http://escholarship.org/uc/uciem_cpccem

DOI: [10.5811/cpcem.7227](https://doi.org/10.5811/cpcem.7227)

Introduction: Atrial fibrillation (AF) is the most common cardiac arrhythmia, occurring primarily in individuals with known risk factors such as advanced age, heart failure, and coronary artery disease. Cannabis use produces several cardiovascular changes resulting in proarrhythmic effects on the heart.

Case Report: A 38-year-old woman with no significant past medical history presented to the emergency department (ED) complaining of palpitations with associated shortness of breath occurring after smoking marijuana. She was found to be in AF. Evaluation in the ED and during hospitalization found no cardiac or metabolic conditions that predisposed to AF. The AF resolved within three hours of onset without intervention.

Conclusion: Cannabis use should be considered as a possible etiology of new-onset AF, especially in relatively young patients with no other predisposing risk factors. [Clin Pract Cases Emerg Med. 2024;8(3)246–249.]

Keywords: atrial fibrillation; marijuana-induced atrial fibrillation; marijuana-induced arrhythmia; cannabis-induced arrhythmia; case report.

INTRODUCTION

Atrial fibrillation (AF) is the most common cardiac arrhythmia, occurring in 1–3% of the general population and in up to 17% of individuals >80 years in age.¹ The majority of AF cases occur in patients with known risk factors such as advanced age, heart failure, and coronary artery disease.¹ We report a case of paroxysmal AF in a 38-year-old woman with no associated risk factors after smoking marijuana.

CASE REPORT

A 38-year-old woman with a history of obesity presented to the emergency department (ED) complaining of palpitations with associated shortness of breath, dizziness, and chest discomfort. The symptoms had begun abruptly approximately one hour earlier while she was a patient in a nearby dental clinic. She admitted to recreational marijuana use and reported she had smoked marijuana just prior to her dental appointment to alleviate her related anxiety.

On physical examination, she had a pulse of 93 beats per minute with an irregular rhythm, and her blood pressure was 123/90 millimeters of mercury. Her lungs were clear to auscultation. An electrocardiogram revealed an irregular rhythm with a narrow QRS complex and an absence of P waves, consistent with AF (Image). No ischemic changes were present.

Laboratory testing in the ED was remarkable for a minimally elevated serum high-sensitivity troponin I level of 15 nanograms per liter (ng/L) (reference range: 0–15 ng/L) and a serum thyroid stimulating hormone level in the normal range. Approximately 90 minutes after ED arrival, the patient spontaneously converted to a normal sinus rhythm. She was admitted to the hospital for evaluation of new-onset AF.

The patient remained in a sinus rhythm while in the hospital. Serial serum high-sensitivity troponin I levels were not indicative of myocardial damage. Her serum magnesium

level was found to be just below the normal range at 1.7 milligrams per deciliter (mg/dL) (1.8–2.4 mg/dL). Her urine toxicological screening was positive only for cannabinoids. Her transthoracic echo revealed no structural abnormalities of the heart and normal left ventricular function. The patient was discharged home on hospital day two on no new medications as her AF was felt to be paroxysmal in nature.

DISCUSSION

Cannabis is the most widely used illicit drug in the United States (US).² The percentage of US adults that use marijuana has more than doubled since 2001, and cannabis in various forms for recreational or medicinal use is now legal in 46 states.^{3,4} The potency of cannabis has also increased significantly in the past 20 years in the US.⁵ As of 2021, approximately 75% of US adults believed cannabis use was as safe or safer than tobacco use.⁶

Paroxysmal AF following marijuana use was first reported in 2000.⁷ Since then, several similar cases have been described, often in young people with structurally normal hearts and no other risk factors for AF.⁸ It is possible that AF after marijuana use is under-reported because patients are reluctant to seek medical care while under the influence of the drug due to legal concerns. Also, palpitations suggestive of AF experienced by users may be interpreted as simply an expected cardiovascular effect of cannabis use. Atrial fibrillation following use of synthetic cannabinoids has also been described.⁹

CPC-EM Capsule

What do we already know about this clinical entity?

Atrial fibrillation (AF) occurs primarily in individuals with known risk factors.

Marijuana use has several proarrhythmic effects on the heart.

What is the major impact of the image(s)?

A patient with no risk factors for AF presented to the ED with paroxysmal AF after smoking marijuana. No other cause of her AF was identified after hospital admission.

How might this improve emergency medicine practice?

Use of cannabis should be considered as a possible etiology of new-onset AF, especially in patients with no other predisposing factors.

Various cardiac arrhythmias have been reported with marijuana use, with AF and ventricular fibrillation the most common (Table).^{10–12} The mechanisms by which marijuana induces cardiac arrhythmias is unknown, although several

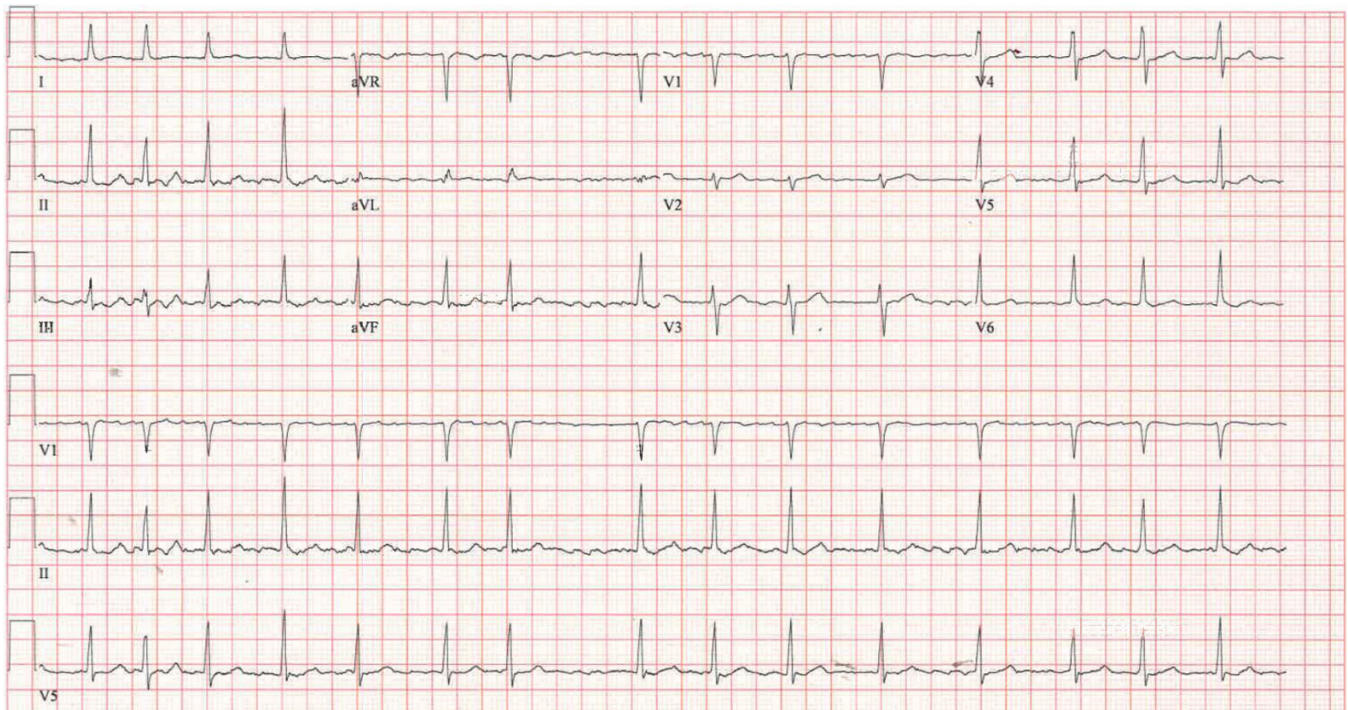
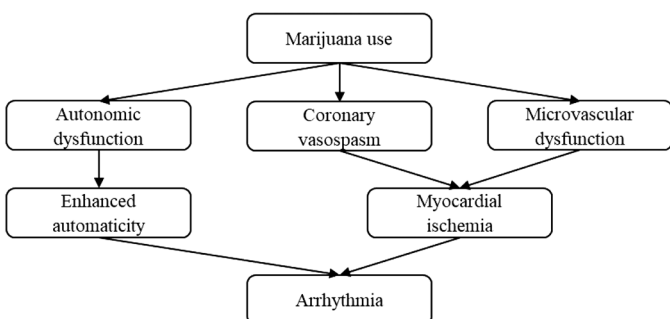


Image. The patient's electrocardiogram showing atrial fibrillation.

Table. Cardiac arrhythmias reported with marijuana use.

Supraventricular arrhythmias	Ventricular arrhythmias
Atrial fibrillation	Ventricular tachycardia
Atrial flutter	Ventricular fibrillation
Ectopic atrial tachycardia	Asystole
Supraventricular tachycardia	
Junctional rhythm	
Sinus bradycardia	
Sinus arrest	
First degree AV block	
Second degree AV block	
Third degree AV block	

AV, atrioventricular.

**Figure.** Proposed mechanisms of marijuana-induced cardiac arrhythmias.

mechanisms have been proposed (Figure).^{8–10} Autonomic dysfunction begins within minutes after smoking marijuana, causing a biphasic and dose-dependent effect. Sympathetic stimulation is predominant at lower doses, leading to tachycardia and enhanced cardiac automaticity. At higher doses, parasympathetic activation leads to bradycardia and hypotension.^{8,13} Cannabis may also induce coronary vasospasm and have a detrimental effect on the coronary microcirculation, leading to myocardial ischemia.^{8,10} All of these cardiovascular changes result in proarrhythmic effects on the heart.

The incidence of AF related to marijuana use is difficult to estimate, although the prevalence of cannabis use disorder among patients admitted for AF is increasing, with the greatest increase in percentage prevalence among younger patients.¹⁴ Atrial fibrillation related to marijuana use at this point seems to be a transient and relatively benign phenomena, leading some authors to compare it to “holiday heart” occurring with ethanol use.¹⁵ Screening for cannabis use by history or laboratory testing should be considered in patients with new-onset AF, especially in those otherwise young and healthy.

CONCLUSION

Atrial fibrillation associated with marijuana use has been increasingly described in the past 20 years. The exact mechanism by which marijuana induces AF is unknown. This phenomenon is typically transient and relatively benign in patients that are otherwise young and healthy. Cannabis use should be considered as a possible etiology of new onset AF, especially in young patients with no other predisposing risk factors.

The authors attest that their institution requires neither Institutional Review Board approval, nor patient consent for publication of this case report. Documentation on file.

Address for Correspondence: Mary Unanyan, DO, University of Illinois at Chicago, College of Medicine, Department of Emergency Medicine, Room 469 CME 1819 W Polk St., Chicago IL, 60612. Email: munanyan2@uic.edu

Conflicts of Interest: By the CPC-EM article submission agreement, all authors are required to disclose all affiliations, funding sources and financial or management relationships that could be perceived as potential sources of bias. The authors disclosed none.

Copyright: © 2024 Unanyan et al. This is an open access article distributed in accordance with the terms of the Creative Commons Attribution (CC BY 4.0) License. See: <http://creativecommons.org/licenses/by/4.0/>

REFERENCES

- Freedman B, Hindricks G, Banerjee A, et al. World Federation Roadmap on Atrial Fibrillation - a 2020 update. *Glob Heart*. 2021;16(1):41.
- Centers for Disease Control and Prevention. Marijuana and Public Health. 2021. Available at: <https://www.cdc.gov/marijuana/data-statistics.htm>. Accessed December 28, 2023.
- Hasin DS, Saha TD, Kerridge BT, et al. Prevalence of marijuana use disorders in the United States between 2001–2002 and 2012–2013. *JAMA Psychiatry*. 2015;72(12):1235–42.
- DISA Global Solutions. Marijuana legality by state. 2023. Available at: <https://www.disa.com/marijuana-legality-by-state>. Accessed December 29, 2023.
- Chen M, Lu YL, Chen XF, et al. Association of cannabis use disorder with cardiovascular diseases: a two-sample Mendelian randomization study. *Front Cardiovasc Med*. 2022;9:966707.
- Chambers J, Kehani S, Ling PM, et al. Perceptions of daily cannabis vs tobacco smoking and secondhand smoke exposure, 2017–2021. *JAMA Netw Open*. 2023;6(8):e2328691.
- Kosior DA, Filipiak KJ, Solarz P, et al. Paroxysmal atrial fibrillation in a young healthy female patient following marijuana intoxication—a case report a possible association. *Med Sci Monit*. 2000;6(2):386–9.
- Korantzopoulos P, Liu T, Papaioannides D, et al. Atrial fibrillation and marijuana smoking. *Int J Clin Pract*. 2008;62(2):308–13.

9. Efe TH, Felekoglu MA, Cimen T, et al. Atrial fibrillation following synthetic cannabinoid use. *Turk Kardiol Dern Ars.* 2017;45(4):362–4.
10. Kariyanna PT, Wengrofsky P, Jayarangaiah A, et al. Marijuana and cardiac arrhythmias: a scoping review. *Int J Clin Res Trials.* 2009;4:132.
11. Desai R, Patel U, Deshmukh A, et al. Burden of arrhythmia in recreational marijuana users. *Int J Cardiol.* 2018;264:91–2.
12. Richards JR, Blohm E, Toles KA, et al. The association of cannabis use and cardiac dysrhythmias: a systematic review. *Clin Toxicol (Phila).* 2020;58(9):861–9.
13. Yahud E, Paul G, Rahkovich M, et al. Cannabis induced cardiac arrhythmias: a case series. *Eur Heart J Case Rep.* 2020;4(6):1–9.
14. Chouairi F, Miller PE, Guha A, et al. Cannabis use disorder among atrial fibrillation admissions, 2008–2018. *Pacing Clin Electrophysiol.* 2021;44(11):1934–8.
15. Charbonney E, Sztajzel JM, Polleti PA, et al. Paroxysmal atrial fibrillation after recreational marijuana smoking: another “holiday heart”? *Swiss Med Wkly.* 2005;135(27–28):412–4.

ST-Elevation Myocardial Infarction Due to Coronary Vasospasm Associated with Eosinophilic Granulomatosis with Polyangiitis: A Case Report

Christopher Allen, BS*
Christopher Poyorena, BS*
Lauren B. Querin, MD, MEd, MSc*†

*Mayo Clinic Alix School of Medicine, Scottsdale, Arizona
†Mayo Clinic Hospital Phoenix, Department of Emergency Medicine, Phoenix, Arizona

Section Editor: R. Gentry Wilkerson, MD

Submission history: Submitted February 7, 2024; Revision received March 12, 2024; Accepted April 1, 2024

Electronically published June 14, 2024

Full text available through open access at http://escholarship.org/uc/uciem_cpchem

DOI: 10.5811/cpcem.19412

Introduction: ST-elevation myocardial infarction (STEMI) can be caused by underlying coronary artery vasospasm (CAV) with or without associated atherosclerotic disease. Coronary artery vasospasm is a rare but potentially devastating manifestation of eosinophilic granulomatosis with polyangiitis (EGPA).

Case Report: We describe a 54-year-old male with a known history of EGPA and coronary artery disease presenting to the emergency department with chest pain and an inferior STEMI on electrocardiogram. He was ultimately taken for coronary angiography and found to have a discrete vasospastic lesion in the right coronary artery that was treated with intra-coronary nitroglycerin and calcium channel blockers. He was continued on immunosuppressant agents (prednisone and mepolizumab) for management of EGPA and followed up with outpatient cardiology and rheumatology for vasospastic angina.

Conclusion: This case highlights a rare cause of STEMI, discusses the nuances in treatment of STEMI due to CAV, and provides background on pathophysiology and treatment of EGPA. [Clin Pract Cases Emerg Med. 2024;8(3)250–253.]

Keywords: case report; STEMI; coronary artery vasospasm; eosinophilic granulomatosis with polyangiitis.

INTRODUCTION

The most common cause of ST-elevation myocardial infarction (STEMI) is acute plaque rupture associated with atherosclerotic disease. However, about 5–25% of cases are caused by a non-atherosclerotic event, such as coronary artery vasospasm (CAV).¹ Differentiating STEMI due to atherosclerosis vs CAV is challenging and often requires coronary angiography for definitive diagnosis.¹ Although rare, CAV has been associated with vasculitis seen in rheumatologic and systemic inflammatory conditions.^{2,3} Eosinophilic granulomatosis with polyangiitis (EGPA) (formerly Churg-Strauss syndrome) is a rare, small- and medium-vessel vasculitis.⁴ Coronary artery vasospasm is a potentially devastating complication of EGPA. We report a

unique case of an inferior STEMI secondary to CAV associated with underlying EGPA.

CASE REPORT

A 54-year-old male presented to the emergency department (ED) with acute-onset, severe left-sided chest pain and diaphoresis. He had taken 81 milligrams aspirin and sublingual nitroglycerin prior to presentation, which did not alleviate his symptoms. Past medical history was notable for hypertension, hyperlipidemia, coronary artery disease (CAD), and EGPA. He had four prior right coronary artery (RCA) stents, with the most recent at an outside hospital one month prior. He also reported several months of anginal chest pain thought to be secondary to coronary vasospasm.

Initial vital signs included blood pressure 148/99 millimeters of mercury (mm Hg), heart rate 69 beats per minute (bpm), respiratory rate 26 breaths per minute, temperature 36.7° Celsius, and pulse oximetry 98% on room air. On exam he was diaphoretic and uncomfortable appearing with mild tachypnea, but his cardiopulmonary exam was otherwise normal. Initial electrocardiogram (ECG) (*Image 1*) showed a normal sinus rhythm with ST-segment changes concerning for inferior STEMI. The patient was treated with aspirin, morphine, and sublingual nitroglycerin, and a code STEMI was activated. Interval ECG obtained 15 minutes later demonstrated no significant change.

The patient was taken for coronary angiography, which revealed a high-grade stenosis of the distal RCA due to a discrete 99% vasospastic lesion (*Figure*). Intracoronary nitroglycerin was administered, ultimately resulting in resolution of the stenosis. His previous stents were patent without restenosis, and there was no significant atherosclerotic disease. Following catheterization, the patient was started on a nitroglycerin drip and diltiazem. A post-catheterization ECG (*Image 2*) showed evidence of recent inferior infarct. He was discharged two days later on dual antiplatelet therapy, diltiazem, isosorbide mononitrate, L-arginine, prednisone, and mepolizumab therapy.

DISCUSSION

Anginal chest pain secondary to CAV occurs when one or more coronary arteries constrict, leading to occlusion of the affected vessel(s). This can evolve into acute myocardial

Population Health Research Capsule

What do we already know about this clinic entity?

ST-elevation myocardial infarction (STEMI) is caused by acute plaque rupture with atherosclerotic disease. A small subset is caused by non-atherosclerotic events, including coronary artery vasospasm.

What makes this presentation of disease reportable?

This is a rare underlying cause of a relatively common and “can’t miss” diagnosis of STEMI in the ED.

What is the major learning point?

Coronary artery vasospasm (CAV) is associated with underlying vasculitis and can cause STEMI. Management should include vasodilators.

How might this improve emergency medicine practice?

Rare causes of STEMI, including CAV and its risk factors (eg, vasculitis), should be kept on differentials so that early intervention can be implemented.

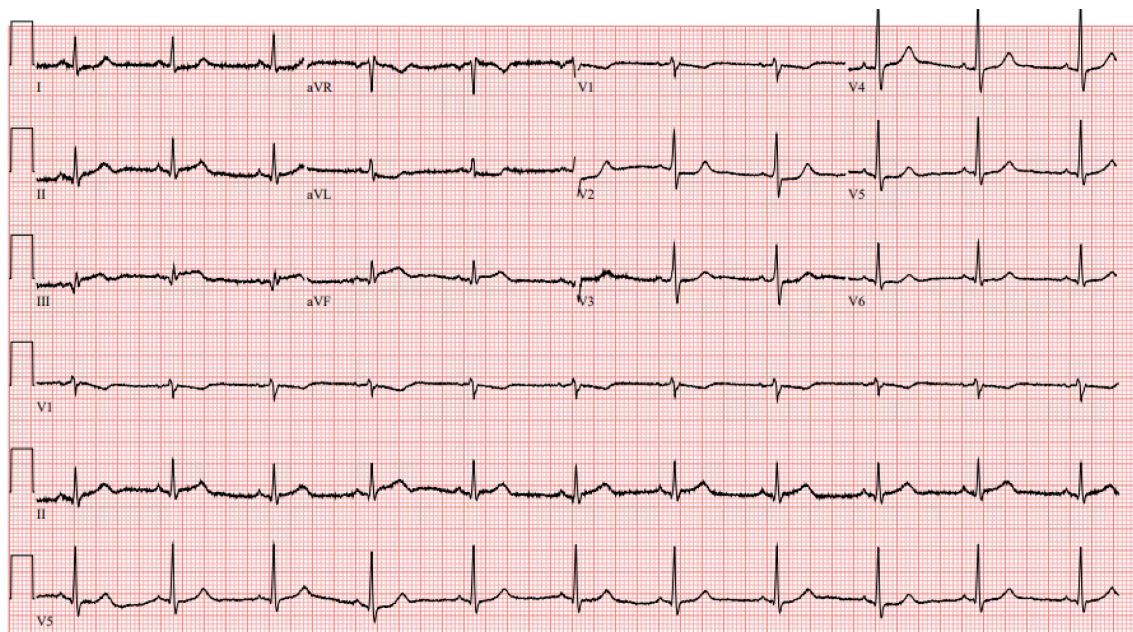


Image 1. Initial electrocardiogram demonstrating a normal sinus rhythm with ST elevations in leads II, III, and aVF as well as reciprocal mild ST depressions in leads I and aVL raising concern for inferior ST-elevation myocardial infarction.

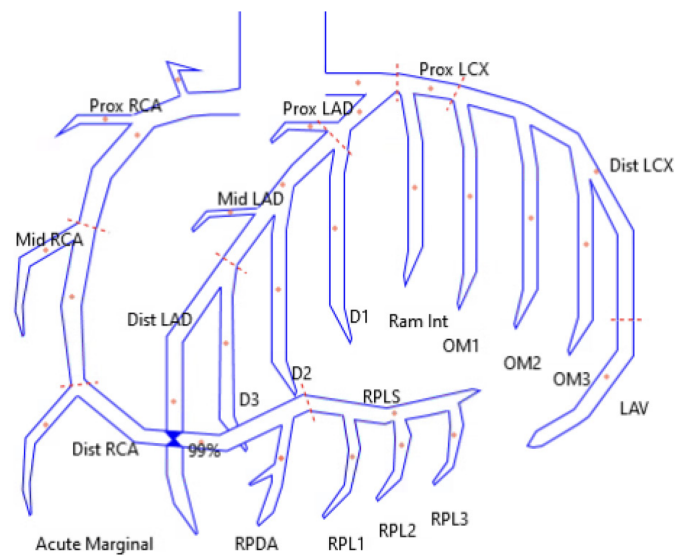


Figure. Reconstructed drawing of coronary artery anatomy demonstrating the location of the distal right coronary artery 99% stenosis.
RCA, right coronary artery.

infarction (MI), as seen in this case.^{1,5} Risk factors for CAV include female gender, Japanese or Korean lineage, emotional stress, tobacco use, sympathomimetic drugs, and systemic inflammatory conditions (vasculitis).^{6,7}

Eosinophilic granulomatosis with polyangiitis is a rare vasculitis thought to be caused by anti-neutrophil cytoplasmic antibody-induced endothelial damage and multisystem eosinophilic infiltration.^{8,9} Typical presenting features include adult-onset asthma, rhinosinusitis, and constitutional

symptoms. However, involvement of end organs may be seen, leading to renal dysfunction, gastrointestinal symptoms, skin, and/or cardiac manifestations.^{4,10} Cardiac involvement in EGPA typically manifests as cardiomyopathy, myopericarditis, and/or dysrhythmia.¹¹ Coronary artery vasospasm and MI are rarely reported. Although pathogenesis is not fully understood, it is postulated that eosinophilic inflammation induces hypercontraction of coronary smooth muscle through activation of mast cells and release of vasoactive substances.^{12,13}

The presentation and initial treatment of acute vasospastic angina is the same irrespective of the underlying cause of the vasospasm. During the acute presentation of CAV, symptoms are nearly identical to atherosclerotic etiologies of acute coronary syndromes, including chest pain, diaphoresis, and dyspnea. Subtle differences exist, including that CAV often presents at rest, especially during rapid eye movement (REM) sleep and in the early morning.^{5,14} Electrocardiogram findings are variable and can range from normal to ST-elevations meeting STEMI criteria.¹

Differentiating between atherosclerotic plaque rupture and CAV as etiology of STEMI can be challenging. However, definitive treatment differs and, therefore, physicians should be attentive in considering CAV, particularly in patients with underlying risk factors.¹ Coronary artery vasospasm may be suggested if on repeat ECG there is resolution or improvement of ST changes following administration of fast-acting nitrate. However, definitive diagnosis requires coronary angiography, especially if the diagnosis is unclear, or if symptoms persist.⁵ Emergency physicians should initiate rapid involvement of

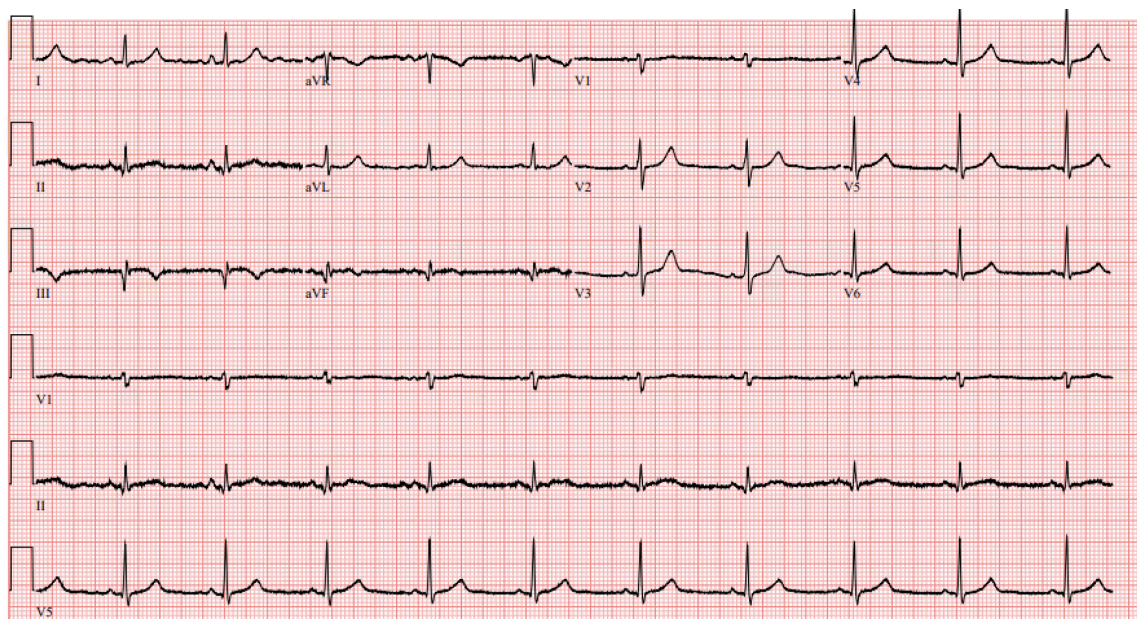


Image 2. Electrocardiogram on day of discharge (post-catheterization) demonstrating a normal sinus rhythm with evidence of inferior infarct with Q waves in leads II, III, aVF and new T-wave inversions in leads III and aVF. There is resolution of previously seen ST elevations and depressions.

interventional cardiology colleagues, while simultaneously starting vasodilatory treatment in patients with STEMI and suspected CAV.

Mainstay therapy of CAV is centered around vasodilation of the coronary vasculature. Non-dihydropyridine calcium channel blockers (CCB) and nitrates are the pharmacotherapies of choice.^{1,14} Additionally, lifestyle changes, treatment of underlying conditions, and optimization of cardiovascular risk, are indicated.

Primary treatment of EGPA is corticosteroids, along with other immunosuppressive agents.¹⁵ Treatment of vasospastic angina in EGPA is less established and dependent on acuity of presentation. Case reports in cardiology literature highlight treatment with systemic and intracoronary nitroglycerin and calcium channel blockers, as utilized in this case.^{2,3}

This patient had known EGPA with a recent history of anginal chest pain that raised suspicion for vasospastic angina. However, he also had risk factors for, and previously diagnosed, CAD with a recent stent placement, which raised concern for plaque rupture or stent thrombosis. Therefore, the patient underwent coronary angiography, which allowed for definitive diagnosis and treatment. Upon discharge, the patient was continued on nitroglycerin, CCB, and dual-antiplatelet therapy. Additionally, treatment with prednisone and mepolizumab (interleukin-5 inhibitor) were continued to address the underlying EGPA in hopes of preventing recurrent vasospastic angina.

CONCLUSION

Coronary artery vasospasm is a rare but potentially devastating manifestation of EGPA. Acute STEMI can be caused by CAV, which is primarily treated medically with nitrates and calcium channel blockers, as opposed to coronary stent placement frequently used to treat STEMI due to underlying atherosclerotic disease. Emergency physicians should maintain suspicion for CAV in patients with underlying risk factors, including in those with EGPA, in the appropriate clinical context. Initiation and referral for treatment of EGPA is also key for prevention of recurrent vasospastic angina.

The authors attest that their institution requires neither Institutional Review Board approval, nor patient consent for publication of this case report. Documentation on file.

Address for Correspondence: Lauren B. Querin, MD, MEd, MSc, Mayo Clinic Hospital Phoenix, Department of Emergency Medicine, 5777 E. Mayo Blvd., Phoenix, AZ 85054. Email: querin.lauren@mayo.edu

Conflicts of Interest: By the CPC-EM article submission agreement, all authors are required to disclose all affiliations, funding sources and financial or management relationships that could be perceived as potential sources of bias. The authors disclosed none.

Copyright: © 2024 Allen et al. This is an open access article distributed in accordance with the terms of the Creative Commons Attribution (CC BY 4.0) License. See: <http://creativecommons.org/licenses/by/4.0/>

REFERENCES

1. Beijk MA, Vlastra WV, Delewi R, et al. Myocardial infarction with non-obstructive coronary arteries: a focus on vasospastic angina. *Neth Heart J*. 2019;27(5):237–45.
2. Bitar AY, Thompson CD, Tan CW, et al. Coronary artery vasospasm and cardiogenic shock as the initial presentation for eosinophilic granulomatosis with polyangiitis. *J Cardiol Cases*. 2015;13(4):105–8.
3. Watanabe K, Yamochi W, Oshitani T, et al. Low-dose corticosteroid therapy improves refractory coronary vasospasm accompanied by eosinophilic granulomatosis with polyangiitis. *J Cardiol Cases*. 2020;23(2):69–72.
4. Chakraborty RK and Aeddula NR. Eosinophilic Granulomatosis With Polyangiitis (Churg-Strauss Syndrome). In: *StatPearls*. Treasure Island (FL): StatPearls Publishing; 2023.
5. Swarup S, Patibandla S, Grossman SA. Coronary Artery Vasospasm. In: *StatPearls*. Treasure Island (FL): StatPearls Publishing; 2023.
6. Fernandez D, Rosenthal JE, Cohen LS, et al. Alcohol-induced Prinzmetal variant angina. *Am J Cardiol*. 1973;32(2):238–9.
7. Ranzani OT, Zampieri FG, Forte DN, et al. C-reactive protein/albumin ratio predicts 90-day mortality of septic patients. *PLoS One*. 2013;8(3):e59321.
8. Lie JT. Illustrated histopathologic classification criteria for selected vasculitis syndromes. American College of Rheumatology Subcommittee on Classification of Vasculitis. *Arthritis Rheum*. 1990;33(8):1074–87.
9. Mohammad AJ. An update on the epidemiology of ANCA-associated vasculitis. *Rheumatology (Oxford)*. 2020;59(Suppl 3):iii42–50.
10. Guillevin L, Cohen P, Gayraud M, et al. Churg-Strauss syndrome. Clinical study and long-term follow-up of 96 patients. *Medicine (Baltimore)*. 1999;78(1):26–37.
11. Dennert RM, van Paassen P, Schalla S, et al. Cardiac involvement in Churg-Strauss syndrome. *Arthritis Rheum*. 2010;62(2):627–34.
12. Chapman FA, Dhaun N, Dweck M, et al. Coronary vasospasm in eosinophilic granulomatosis with polyangiitis. *Rheumatology (Oxford)*. 2020;59(12):e144–6.
13. Petrakopoulou P, Franz WM, Boekstegers P, et al. Vasospastic angina pectoris associated with Churg-Strauss syndrome. *Nat Clin Pract Cardiovasc Med*. 2005;2(9):484–90.
14. Han SH, Lee KY, Her SH, et al. Impact of multi-vessel vasospastic angina on cardiovascular outcome. *Atherosclerosis*. 2019;281:107–13.
15. Chung SA, Langford CA, Maz M, et al. 2021 American College of Rheumatology/Vasculitis Foundation guideline for the management of antineutrophil cytoplasmic antibody-associated vasculitis. *Arthritis Rheumatol*. 2021;73(8):1366–83.

Point-of-Care Ultrasound Findings in Occlusive Iliac Vein Thrombus During Pregnancy: A Case Report

Donald Pettet III, DO
John Forrester, DO
Mathew Nelson, DO
Tanya Bajaj, MD

North Shore University Hospital, Department of Emergency Medicine, Manhasset, New York

Section Editor: Shadi Lahham, MD

Submission history: Submitted January 5, 2024; Revision received March 11, 2023; Accepted March 13, 2024

Electronically published June 14, 2024

Full text available through open access at http://escholarship.org/uc/uciem_cpchem

DOI: [10.5811/cpcem.6658](https://doi.org/10.5811/cpcem.6658)

Introduction: Diagnosing deep venous thromboses and venous thromboemboli (DVT/VTE) in pregnant patients presents a unique challenge for emergency physicians. The risk of DVT/VTE increases during pregnancy, and the potential consequences of misdiagnoses are severe. Point-of-care ultrasonography (POCUS) is frequently a first-line diagnostic imaging modality. However, recent studies have shown a high incidence of thromboses proximal to the common femoral vein during pregnancy, and these would not be visualized using compressive ultrasonography, which traditionally can only visualize thromboses distal to the femoral vein.

Case Report: A 38-year-old female, 25-weeks primiparous, presented to the emergency department with a three-day history of left lower extremity swelling. Point-of-care three-point compression testing was used to evaluate for a DVT; however, no thrombus was visualized. Given high clinical suspicion, color and spectral Doppler testing were performed and demonstrated turbulent flow and reduced respiratory variation in the common femoral vein. This prompted further additional testing for a proximal DVT using magnetic resonance venography, which revealed an occlusive left external iliac thrombus. The patient was subsequently started on daily subcutaneous enoxaparin and discharged home with close follow-up.

Conclusion: Emergency physicians play a critical role in evaluations for the presence of DVT/VTE, particularly in pregnant patients. We endorse the use of POCUS with three-point compression testing, as well as color and spectral Doppler imaging, to help identify proximal DVTs in this patient population. This case report can aid physicians in the diagnosis of this pathological condition that if left untreated can have severe consequences. [Clin Pract Cases Emerg Med. 2024;8(3)254–258.]

Keywords: *deep vein thrombosis; DVT; pregnancy; point-of-care ultrasound; case report.*

INTRODUCTION

Diagnosing deep venous thromboses (DVT) and venous thromboemboli (VTE) in pregnant patients presents a unique challenge for emergency physicians. Pregnancy increases the risk of DVT/VTE. The potential consequences of misdiagnoses are severe and include DVT/VTE recurrence, post-thrombotic syndrome, pulmonary embolism, and even death.¹ Venous ultrasonography is a first-line diagnostic imaging modality in the emergency department (ED) for

patients with a moderate to high pretest probability for DVT/VTE.² However, recent studies have shown a higher incidence of thromboses proximal to the common femoral vein during pregnancy.³ For this reason, in cases where clinical suspicion remains high despite negative three-point compression testing, adjunctive ultrasound imaging modalities and more comprehensive imaging may be required.

In this report, we present a case of a previously healthy pregnant woman in her second trimester with a DVT within

the left external iliac vein, which was not initially detected with point-of-care ultrasonography (POCUS) and three-point compression testing. With limitations regarding the use of ultrasonography to detect thromboses proximal to the common femoral vein, this case underscores the importance of considering this entity in pregnant patients with suspected DVT/VTE.⁴

CASE REPORT

A 38-year-old female presented to the ED with a three-day history of progressively worsening swelling in her left lower extremity. At the time of presentation, she was 25 weeks pregnant and had no significant medical, surgical, or family history. Physical examination revealed circumferential swelling in her left lower extremity extending from the knee to the distal forefoot. Additionally, she exhibited left calf tenderness upon palpation.

To evaluate for the presence of a DVT in her left lower extremity, we used POCUS with three-point compression testing. The femoral and popliteal regions demonstrated normal manual compressibility, and no thrombus was visualized. Despite these findings, the patient's exam and clinical history raised suspicion for thrombosis. As a result, color and spectral Doppler testing were performed, which revealed turbulent flow and reduced respiratory variation in the common femoral vein. These findings prompted additional testing for a proximal DVT using magnetic resonance venography (MRV), which ultimately revealed an occlusive DVT in the left external iliac vein. The patient was subsequently evaluated by hematology, started on daily subcutaneous enoxaparin sodium injections, and discharged home with close follow-up.

DISCUSSION

A DVT is considered "proximal" when it is identified within the popliteal, femoral, or iliac veins of the lower extremity on radiographic imaging. The initial presentation for patients with proximal DVTs can vary significantly, but common symptoms include swelling, discoloration, and cramping sensations within the calf and thigh of the effected limb. In the ED, the initial diagnostic approach involves an assessment of pretest probability with consideration for the patient's history, genetic and acquired risk factors, and signs and symptoms. One risk factor of particular importance to the emergency physician is the association of DVT/VTE with pregnancy.

Observational studies and meta-analyses have established pregnancy as a risk factor for DVT/VTE, with as many as 1.0–1.8% of pregnant patients developing this condition.⁴ This thromboembolic risk increases throughout pregnancy to nine-fold during the third trimester, and peaks two to six weeks postpartum when the risk is 80 times higher than in non-pregnant patients.⁵ It is important to note that unlike in men and non-pregnant women, pregnant patients are more

CPC-EM Capsule

What do we already know about this clinical entity?

Pregnant patients are at increased risk for deep vein thromboses (DVT) proximal to the femoral vein.

What makes this presentation of disease reportable?

While three-point compression testing is frequently applied in the emergency department, this case highlights false-negative results due to a proximal DVT.

What is the major learning point?

Three-point compression testing may lead to false-negative results in pregnant patients due to increased rates of thromboses proximal to the femoral vein.

How might this improve emergency medicine practice?

Consideration for proximal DVT in pregnant patients may help avoid adverse outcomes related to false-negative, three-point compression testing.

likely to develop proximal rather than distal thromboses. Previous studies investigating the anatomic distribution of DVTs in pregnant patients found thromboses to more commonly be left-sided (84%) and restricted to the iliofemoral (64%) and iliac (12%) veins.⁶ Given that 9.3% of pregnancy-related deaths are due to pulmonary emboli, the importance of identifying such thromboses in this patient population cannot be overstated.⁷

In pregnant patients, the formation of DVT/VTE is heavily influenced by physiologic hypercoagulability and intra-abdominal anatomical changes. Pregnancy is characterized by a hypercoagulable state caused by an increase in clotting factors, a decrease in natural anticoagulants, and alterations in fibrinolytic activity.⁸ These changes are thought to be protective against hemorrhage during delivery, but they also predispose patients to thromboses. The approximation of the gravid uterus with the vertebral bodies due to increased lordosis also predisposes pregnant patients to thromboses through venous compression.⁹ The influence of these anatomical changes is highlighted in cases of aortocaval compression when pregnant patients are lying supine.

Other anatomical influences may also play a role. For example, May-Thurner syndrome is a condition in which compression of the left common iliac vein by the overlying right common iliac artery may lead to inflammation, sclerosis, venous stasis, and thromboses. May-Thurner syndrome has been identified in over 30% of all-comers previously diagnosed with left lower extremity DVT and is often overlooked.¹⁰ Other risk factors for DVT/VTE in pregnancy include immobility, advanced maternal age, obesity, smoking, multiple gestations, and a personal or family history of thromboembolic disease. It is important for emergency physicians to be aware of these risk factors and maintain a high level of suspicion for DVT/VTE in pregnant patients presenting with lower extremity swelling or pain.

The initial imaging test of choice when evaluating a pregnant patient for a DVT is venous ultrasonography. Traditionally, the initial diagnostic imaging modality of choice has been the complete duplex ultrasound. However, with the emergence of POCUS, three-point compression testing has been employed in the ED to evaluate patients for DVTs, with advocates highlighting improved times to study completion, decreased costs, and the avoidance of unnecessary transfers and treatments.^{11–13} This method involves evaluations of the common femoral vein one to two centimeters above the bifurcation with the saphenous vein, the common femoral vein at the bifurcation with the saphenous vein, the femoral vein at the bifurcation with the deep femoral vein, and the popliteal vein.

Loss of compressibility is considered the most reliable indicator of a DVT, and color Doppler imaging may be used to differentiate between complete and incomplete occlusions. Multiple studies have validated this approach and

demonstrated false negative results in as little as 1.4%.^{14,15} A recent systematic review and meta-analysis by Hercz et al additionally found a pooled sensitivity of 90% and specificity of 95% using emergency physician-performed ultrasound evaluations for DVTs.¹⁶ Unfortunately, studies evaluating the use of three-point compression testing during pregnancy are not available. Importantly, the American College of Obstetrics and Gynecology guidelines recommend close follow-up with repeat imaging at three and seven days if ultrasound evaluations are negative and an ilio caval thrombosis is not suspected.⁷ This case highlights the diagnostic challenge that emergency physicians may encounter, as three-point compression testing can yield negative results even in the presence of an occlusive ilio caval thrombus.

Given the possibility of false-negative results with three-point compression testing in pregnant patients, POCUS evaluations should incorporate color and spectral Doppler studies of the common femoral veins. Color Doppler enables clinicians to visualize turbulent flow patterns, also known as “rouleaux,” while spectral Doppler can identify changes in respiratory phasicity, suggesting a venous occlusion proximal to the area of insonation.¹⁷ Under normal conditions, spectral Doppler testing should demonstrate phasic variations in waveform throughout the cardiac cycle due to respiration. An abnormal spectral Doppler waveform that is flat and continuous indicates decreased respiratory variation and should raise concern for a venous obstruction proximally.¹⁸ Importantly, to obtain accurate results physicians should ensure that the angle of incidence is below 60 degrees and compare results to the contralateral extremity.

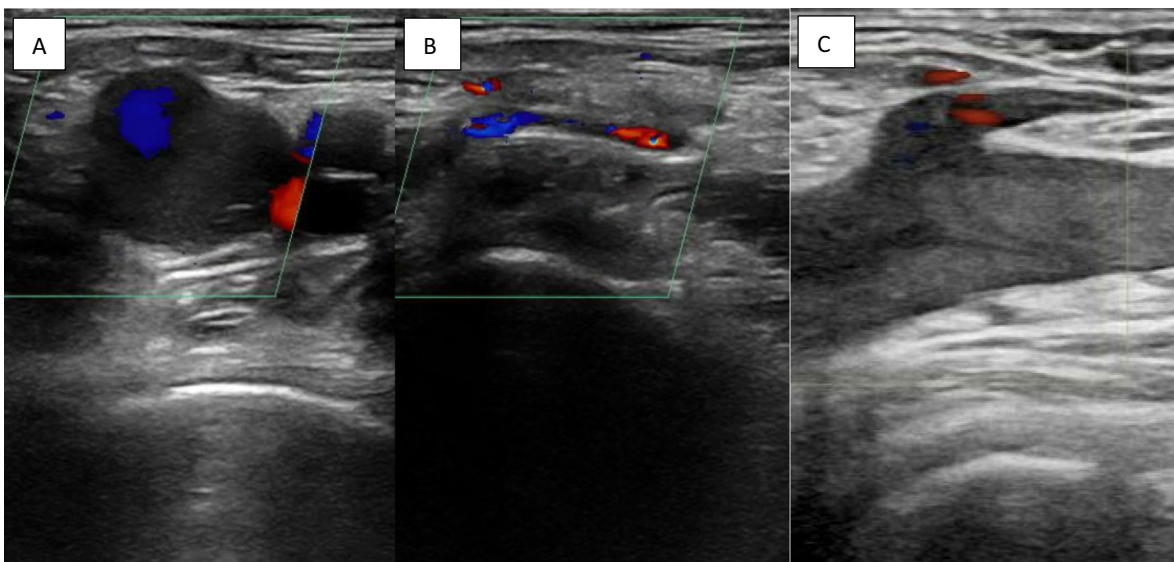


Image 1. Point-of-care ultrasound images of the left common femoral vein in transverse view without (A) and with (B) compression, and in long view (C). Notably, images A and C demonstrate sluggish venous flow with a lack of directionality in the common femoral vein using color Doppler.

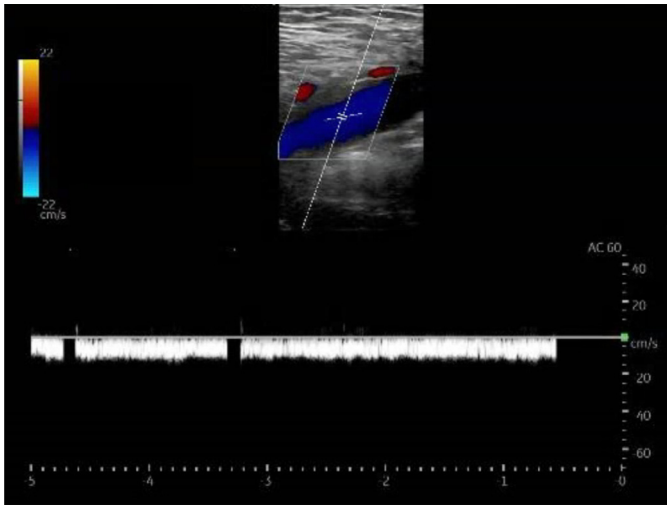


Image 2. Point-of-care ultrasound image of the left common femoral vein in longitudinal view demonstrating lack of normal respiratory phasicity with spectral Doppler.

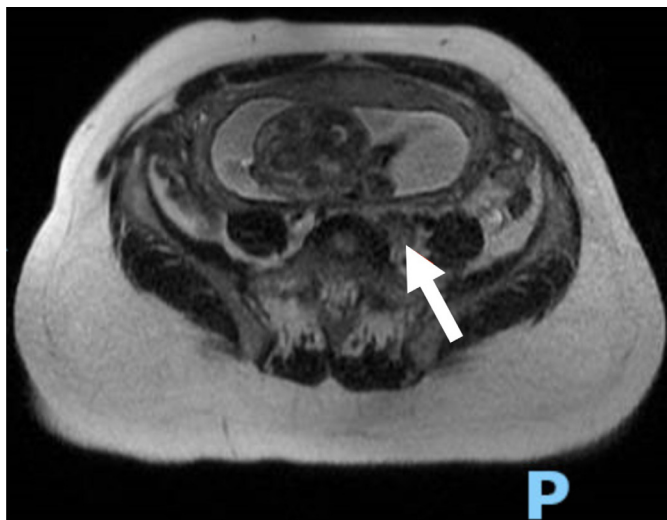

Image 3. Magnetic resonance venogram image of the left external iliac vein demonstrating a deep vein thrombosis (white arrow).

Despite negative results with three-point compression testing, circumferential leg swelling in this patient's case prompted color and spectral Doppler assessments for a proximal, ilio caval thrombus. These studies ultimately demonstrated turbulent flow patterns and decreased respiratory phasicity (Images 1 and 2). If there is evidence of a proximal venous obstruction on ultrasound imaging, computed tomography and MRV have been established as the imaging modalities of choice due to limitations of duplex ultrasonography above the inguinal plane.^{19,20} In this patient's case, magnetic resonance imaging was obtained and identified a DVT within the left external iliac vein (Image 3). Overall, this case highlights the importance of investigations

for thromboses proximal to the common femoral vein in pregnant patients when suspicion is high, even when three-point compression testing is negative.

CONCLUSION

Emergency physicians play a critical role in the evaluation of high-risk patients for the presence of DVT/VTE, particularly in pregnant patients who may have familial, genetic, or anatomic factors that increase their risk for thromboses. Clinicians evaluating pregnant patients should maintain a high degree of clinical suspicion and have a low threshold to obtain comprehensive ultrasound studies and magnetic resonance venography when necessary. The information provided in this case underscores the importance of considering DVTs proximal to the common femoral vein in pregnant patients and may aid clinicians in the diagnosis of this pathological condition, which if left untreated can result in serious consequences, including DVT/VTE recurrence, post-thrombotic syndrome, pulmonary embolism, and even death.

The authors attest that their institution requires neither Institutional Review Board approval, nor patient consent for publication of this case report. Documentation on file.

Address for Correspondence: John Forrester, DO, North Shore University Hospital, Department of Emergency Medicine, 300 Community Drive, Manhasset, NY 11030. Email: jforrest@northwell.edu

Conflicts of Interest: By the CPC-EM article submission agreement, all authors are required to disclose all affiliations, funding sources and financial or management relationships that could be perceived as potential sources of bias. The authors disclosed none.

Copyright: © 2024 Pettet et al. This is an open access article distributed in accordance with the terms of the Creative Commons Attribution (CC BY 4.0) License. See: <http://creativecommons.org/licenses/by/4.0/>

REFERENCES

1. Leizorovicz A. Long-term consequences of deep vein thrombosis. *Haemost.* 1998;28(Suppl. 3):1–7.
2. Bates SM, Jaeschke R, Stevens SM, et al. *Diagnosis of DVT: Antithrombotic Therapy and Prevention of Thrombosis, 9th ed:* American College of Chest Physicians Evidence-Based Clinical Practice Guidelines. *CHEST.* 2012;141(2):e351S–418S.
3. Chan WS, Spencer FA, Lee AYY, et al. Safety of withholding anticoagulation in pregnant women with suspected deep vein thrombosis following negative serial compression ultrasound and iliac vein imaging. *Can Med Assoc J.* 2013;185(4):E194–200.
4. Jain AK, Soutl MC, Resnick SA, et al. Detecting iliac vein thrombosis with current protocols of lower extremity venous duplex ultrasound. *J Vasc Surg Venous Lymphat Disord.* 2018;6(6):724–29.

5. James AH, Jamison MG, Brancazio LR, et al. Venous thromboembolism during pregnancy and the postpartum period: Incidence, risk factors, and mortality. *Am J Obstet Gynecol.* 2006;194(5):1311–15.
6. Chan WS, Spencer FA, Ginsberg JS. Anatomic distribution of deep vein thrombosis in pregnancy. *Can Med Assoc J.* 2010;182(7):657–60.
7. American College of Obstetricians and Gynecologists' Committee on Practice Bulletins—Obstetrics. ACOG practice bulletin no. 196: thromboembolism in pregnancy [published correction appears in *Obstet Gynecol.* 2018 Oct;132(4):1068]. *Obstet Gynecol.* 2018;132(1):e1–17.
8. Jacobsen AF, Skjeldestad FE, Sandset PM. Incidence and risk patterns of venous thromboembolism in pregnancy and puerperium—a register-based case-control study. *Am J Obstet Gynecol.* 2008;198(2):233.e1–233.7.
9. Schrufer-Poland TL, Florio K, Grodzinsky A, et al. Management of May-Thurner syndrome in pregnant patients. *J Cardiovasc Dev Dis.* 2022;9(12):410.
10. Dix C, Clements W, Gibbs H, et al. Venous anomalies and thromboembolism. *Thromb J.* 2023;21(1):45.
11. Pedraza García J, Valle Alonso J, Ceballos García P, et al. Comparison of the accuracy of emergency department-performed point-of-care-ultrasound (POCUS) in the diagnosis of lower-extremity deep vein thrombosis. *J Emerg Med.* 2018;54(5):656–64.
12. Varrías D, Palaiodimos L, Balasubramanian P, et al. The use of point-of-care ultrasound (POCUS) in the diagnosis of deep vein thrombosis. *J Clin Med.* 2021;10(17):3903.
13. Blaivas M, Lambert MJ, Harwood RA, et al. Lower-extremity doppler for deep venous thrombosis: can emergency physicians be accurate and fast? *Acad Emerg Med.* 2000;7(2):120–6.
14. Frazee BW, Snoey ER, Levitt A. Emergency department compression ultrasound to diagnose proximal deep vein thrombosis. *J Emerg Med.* 2001;20(2):107–12.
15. Lee JH, Lee SH, Yun SJ. Comparison of 2-point and 3-point point-of-care ultrasound techniques for deep vein thrombosis at the emergency department: a meta-analysis. *Medicine.* 2019;98:e15791.
16. Hercz D, Mechanic OJ, Varella M, et al. Ultrasound Performed by Emergency Physicians for Deep Vein Thrombosis: A Systematic Review. *West J Emerg Med.* 2024;25(2):282–90.
17. Blanco P and Volpicelli G. Common pitfalls in point-of-care ultrasound: a practical guide for emergency and critical care physicians. *Crit Ultrasound J.* 2016;8(1):15.
18. Needleman L, Cronan JJ, Lilly MP, et al. Ultrasound for lower extremity deep venous thrombosis. *Circulation.* 2018;137(14):1505–15.
19. Liu D, Peterson E, Dooner J, et al. Diagnosis and management of iliofemoral deep vein thrombosis: clinical practice guideline. *Can Med Assoc J.* 2015;187(17):1288–96.
20. Dronkers CE, Srámek A, Huisman MV, et al. Accurate diagnosis of iliac vein thrombosis in pregnancy with magnetic resonance direct thrombus imaging (MRDTI). *BMJ Case Rep.* 2016;2016:bcr2016218091.

Rectus Sheath Blocks for Umbilical Hernia Reductions in the Emergency Department: A Case Series

Katherine Vlasica, DO St. Joseph's Health, Paterson, New Jersey
 Amanda Hall, DO

Section Editor: Austin Smith, MD

Submission history: Submitted January 26, 2024; Revision received March 20, 2024; Accepted April 4, 2024

Electronically published July 31, 2024

Full text available through open access at http://escholarship.org/uc/uciem_cpchem

DOI: 10.5811/cpcem.7233

Introduction: Rectus sheath blocks have been used for decades in the operating room for analgesia following umbilical surgical procedures. We present the first reported case series of a rectus sheath block used in the emergency department (ED) for the reduction of an umbilical hernia.

Case Series: Four patients presented to the ED for painful, non-reducible umbilical hernias. An ultrasound-guided bilateral rectus sheath block was used in all four patients with complete pain relief and an easy hernia reduction.

Conclusion: Rectus sheath blocks are an excellent addition to a multimodal analgesic regimen in periumbilical pain and painful procedures. This block is easy to perform and implement for pain control in umbilical hernias in an ED setting. [Clin Pract Cases Emerg Med. 2024;8(3)259–263.]

Keywords: *rectus sheath block; umbilical hernia.*

INTRODUCTION

Umbilical hernias are a common entity presenting to the emergency department (ED) and frequently present a pain management challenge for the emergency physician. Umbilical hernias account for 6–14% of all adult abdominal wall hernias and are more common in women and individuals with increased intraabdominal pressure as in pregnancy, obesity, or ascites.¹ Patients with increased abdominal pressure typically have underlying pathology, making any surgical intervention a high risk for complications. Of note, 20% of all cirrhotic patients will develop an umbilical hernia, which makes a surgical intervention or procedural sedation deemed high risk for complications.¹ This case series examines how we can use a bilateral rectus sheath block (BRSB) for safe and efficient ED umbilical hernia reduction.

The BRSB was first described in the literature in 1899. Throughout its lifespan the BRSB was primarily used in the operating room (OR) as a targeted analgesic intervention reducing postoperative nausea, vomiting, constipation, and opioid consumption.^{2,3,4} A BRSB provides midline analgesia to the rectus muscle and overlying skin from the xiphoid

process to the symphysis pubis. The rectus abdominis muscle is a medial oval-shaped muscle that lies inside its rectus sheath formed by the split aponeurosis of the external oblique, transversus abdominus, and internal oblique, bordered by the linea alba medially and the linea semilunaris laterally. The ninth through eleventh intercostal nerves, epigastric artery and veins are in the space between the rectus abdominis muscle and its posterior rectus sheath. Deep to the rectus sheath is the transversalis fascia and abdominal cavity containing peritoneum and abdominal viscera. In the rectus sheath block 0.1 milliliters (mL) per kilogram (kg) to a maximum of 10 mL per side is deposited bilaterally, resulting in a total volume of 20 mL of local anesthetic. The local anesthetic is deposited between the posterior rectus sheath and rectus abdominus muscle to allow for a successful block (Image 1). The block typically works unilaterally from approximately the seventh through eleventh thoracic level.⁴

CASE SERIES

All four patients underwent the same technique for a BRSB. Consent was obtained prior to the procedure, and the

patient was placed on a cardiac monitor. With the skin disinfected, a transducer was placed in a transverse axis above the umbilicus slightly lateral to the midline. Color Doppler was used to identify and avoid the epigastric arteries. A blunt-tipped hyperechoic block needle was inserted in plane through the subcutaneous tissue, anterior rectus sheath, and rectus muscle until resistance was felt as the blunt-tipped needle contacted the posterior rectus sheath (**Image 1**). Initially, 1–2 mL of saline were used to confirm placement after a heme-negative aspiration. We then instilled 10 mL of 0.5% ropivacaine under the posterior aspect of the rectus muscle, effectively lifting it from the posterior rectus sheath (**Video**). The process was repeated on the contralateral side. Each patient received a total of 20 mL of 0.5% ropivacaine, totaling 100 milligrams (mg) of ropivacaine. Maximum dose of ropivacaine is 3 mg/kg. All the patients were well within the safety margin of maximum dosing.

The video is a SonoClip (SonoClipShare.com) demonstrating the relevant anatomy and rectus sheath block performance. An echogenic block needle enters the rectus sheath from a lateral to medial direction. The target area of injection is between the underside of the rectus abdominus and posterior rectus sheath. An anechoic local anesthetic is seen lifting the rectus abdominus muscle from the posterior rectus sheath.

Case One

A 60-year-old male with a past medical history of chronic umbilical hernia and alcohol use disorder presented to the ED following a fall resulting in a non-reducible umbilical hernia and left ankle pain. The patient was given 400 mg of ibuprofen orally and 15 mg of ketorolac intravenously (IV) for his ankle pain caused by a distal fibular fracture. His ankle pain was controlled, but he still had pain with bedside

reduction attempts. After the BRSB the umbilical hernia was easily reduced. The patient was discharged home for medical optimization and an elective umbilical hernia repair at the patient's convenience.

Population Health Research Capsule

What do we already know about this clinical entity?

Bilateral rectus sheath blocks have been used for decades in the operating room for periumbilical surgical anesthesia.

What makes this presentation of disease reportable?

This is the first reported case series of a bilateral rectus sheath block used in the ED for bedside reduction of an incarcerated umbilical hernia.

What is the major learning point?

The bilateral rectus sheath block can be safely performed in the ED and should be added to the procedural armamentarium of emergency physicians.

How might this improve emergency medicine practice?

Bilateral rectus sheath block performed in the ED in lieu of procedural sedation provides targeted analgesia in a patient with an incarcerated umbilical hernia.

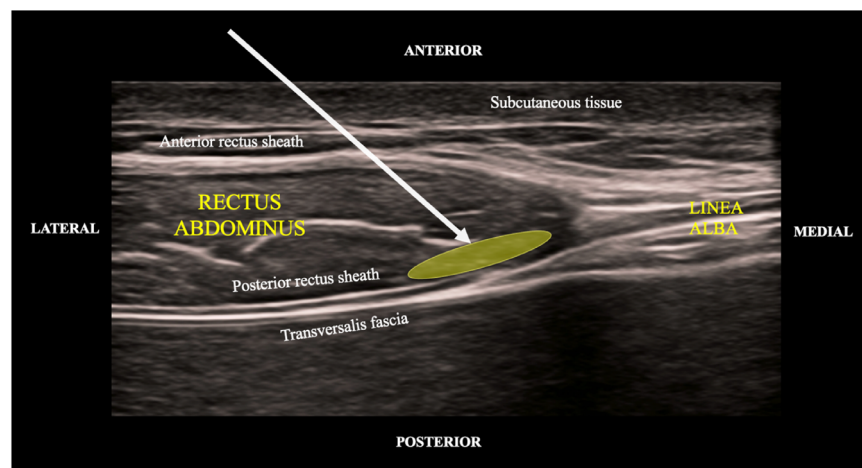


Image 1. Point-of-care ultrasound demonstrating anatomical landmarks in the rectus sheath block. Yellow oval denotes the target area of injection. Arrow represents relative angle of trajectory for the needle.

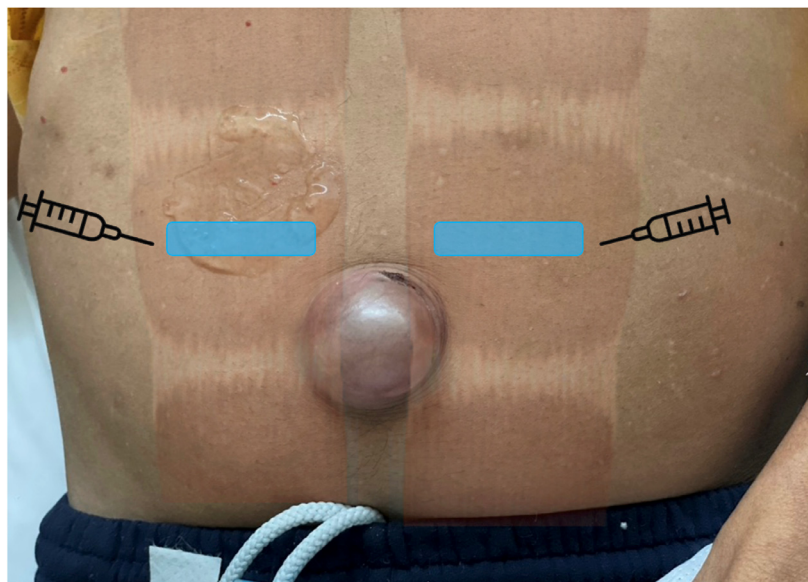


Image 2. Patient with an incarcerated umbilical hernia prior to the bilateral rectus sheath block performed for pain control. Blue boxes indicate footprints of linear probe for a bilateral rectus sheath block. The needle is inserted in the lateral to medial direction, in plane with the linear transducer probe.

Case Two

A 60-year-old male with past medical history of opioid abuse, ascites secondary to alcoholic cirrhosis, inguinal hernia, and umbilical hernia presented to the ED with complaints of gradually worsening severe abdominal pain with a worsening umbilical bulge (*Image 2*). The patient was initially given fentanyl 100 micrograms IV and haloperidol 5 mg IV for pain and nausea. There was an obvious umbilical hernia identified with skin changes and abdominal tenderness. Computed tomography (CT) of the abdomen and pelvis showed an umbilical hernia containing a small-bowel loop resulting in a small-bowel obstruction. Incarceration was unable to be excluded on CT. Surgery was consulted, and the patient was scheduled to undergo an emergent operative repair. Due to continued severe pain a BRSSB was performed. Shortly after the block the patient reported significant improvement of pain and was transferred to the preoperative area. Three hours later the patient was re-evaluated in the preoperative area by the surgical team; the patient's hernia had spontaneously reduced, and he was pain free and resting comfortably. Given the patient's numerous comorbidities, the decision was made to postpone the surgery for medical optimization. The patient was monitored in the hospital for a few days, normal bowel patterns returned, pain did not resume, and he was discharged home four days after initial presentation. After the BRSSB the patient did not require any additional analgesia.

Case Three

A 49-year-old female with a past medical history of obesity, hypercholesterolemia, non-insulin-dependent

diabetes, and hypertension presented to the ED for abdominal pain at the site of a previous umbilical hernia repair. The patient stated she had been admitted multiple times for pain control and discharged with instructions to schedule an elective operative repair as outpatient. Physical exam showed an obese female with mild tenderness to palpation of the umbilicus. The patient took acetaminophen 975 mg at home prior to arrival and received ketorolac 15 mg IV in the ED with improvement of pain but had persistent tenderness to palpation of hernia. A BRSSB was performed in the ED. The patient's hernia spontaneously reduced, and she had complete resolution of her pain. She was discharged for outpatient follow-up with her general surgeon.

Case Four

The last case was a 42-year-old male with no past medical history who presented to the ED for eight months of intermittent umbilical pain, that had worsened over the prior three days. He had not sought medical care prior to arrival in the ED. On exam he had a tender umbilical, non-reducible hernia, approximately 4 centimeters (cm) in size. Computerized tomography revealed a $3 \times 3.7 \times 3.4$ cm, fat-containing umbilical hernia with a narrow neck measuring 15 millimeters. Initial bedside reduction was unsuccessful after administration of ketorolac 15 mg IV, placement in Trendelenburg position, and application of ice to the umbilicus. Surgical consult was called, and after discussion with the surgical team the patient underwent a BRSSB. Approximately 20 minutes after the block the hernia was reduced at bedside without difficulty, and the patient was discharged home with outpatient surgical follow-up.

DISCUSSION

The BRSB has been used in the OR for decades to provide sensory analgesia to the anterior abdominal wall. In the past the rectus sheath block was performed without visualization, using a loss-of-resistance approach as the blunt-tipped block needle passed through fascial and muscle planes of the rectus sheath to anesthetize the anterior divisions of the seventh thoracic to first lumbar spinal nerves. This procedure was typically not performed in the ED due to fear of epigastric vessel puncture or bowel perforation due to inaccurate needle placement. However, the rise of ultrasound use in ED procedures over the last decade has led to the adaptation of many ultrasound-guided regional anesthesia (UGRA) techniques from their OR provenance. The ability to visualize the distribution of analgesic medications around and near nerves has increased accuracy of these blocks and limited accidental injection into vasculature or damage to surrounding anatomy. To the best of our knowledge, these four cases represent the first reported use of BRSB for the management of an umbilical hernia in the ED.

Given the rising rates of substance use disorders in the US, the spotlight has been placed on opioid usage and prescribing. Physicians are constantly evaluating novel methods of targeted analgesia for painful ED conditions as a part of a multimodal pain regimen. As demonstrated in this case series, we believe BRSB is a valuable tool for control of umbilical hernia pain in the ED. All four patients had complete resolution of their pain with minimal use of opioids, allowing for an either spontaneous or manual reduction of umbilical hernias with significantly less procedural discomfort to the patient.

The rectus sheath block can be performed quickly and safely at the bedside, providing rapid pain relief without parenteral opioids or the large mobilization of resources required for procedural sedation. All the procedures were performed by an emergency medicine resident and an UGRA-credentialed emergency attending physician, proving the safety, ease of performance and generalizability of this case series.

Ultrasound-guided regional anesthesia has proven to have numerous advantages over parenteral analgesic therapies for patients presenting with painful injuries to the ED: decreased incidence of central sensitization leading to chronic pain⁵; decreased adverse effects such as hypoxia, nausea and vomiting^{6,7}; reduced opioid requirements^{8,9}; and decreased length of stay.^{10,11} In multiple, published anesthesia literature cases it has been demonstrated that BRSBs were performed as the primary anesthetic in high-risk patients in cases of both inguinal and umbilical hernia repair with success.⁴ In this ED case series, a BRSB provided an expeditious and safe resolution of the patient's pain with no complications, minimal opioid utilization, and no need for a full procedural sedation. While there are risks to both

procedural sedation and UGRA, the risks of procedural sedation and parenteral opioid medications are more complex and potentially severe in the patient population typically prone to umbilical hernias. All patients avoided emergent operative repair subsequent to successful reduction of their umbilical hernias, enabling them to be discharged with outpatient scheduling for medical optimization.

CONCLUSION

Ultrasound-guided regional anesthesia allows physicians to treat numerous acutely painful conditions and painful procedures in a timely, expeditious, and safe manner. The above cases describe the use of UGRA for the reduction of umbilical hernias without the need for procedural sedation or emergent surgical intervention. In all four cases the pain was controlled with minimal ED use of opioids, and the hernia was reduced without procedural sedation. Without this intervention the patients may have required emergent operative repair rather than an elective outpatient repair.

As emergency physicians expand their knowledge base and skillset, UGRA including the rectus sheath block is a technique we can use with hernia reduction, abdominal wall abscess, and any other painful periumbilical conditions. These four cases demonstrated the utility of a bilateral rectus sheath block in averting the need for procedural sedation and emergent operative repairs from the ED, also resulting in decreased resource utilization, opioid consumption, and length of stay. Overall, the BRSB is a great addition to the armamentarium of the emergency physician as an expeditious pain control option for periumbilical conditions.

The authors attest that their institution requires neither Institutional Review Board approval, nor patient consent for publication of this case report. Documentation on file.

Address for Correspondence: Katherine Vlasica, DO, St. Joseph's Health, 703 Main St., Paterson NJ 07043. Email: Vlasicak@sjhmc.org

Conflicts of Interest: By the *CPC-EM* article submission agreement, all authors are required to disclose all affiliations, funding sources and financial or management relationships that could be perceived as potential sources of bias. The authors disclosed none.

Copyright: © 2024 Vlasica et al. This is an open access article distributed in accordance with the terms of the Creative Commons Attribution (CC BY 4.0) License. See: <http://creativecommons.org/licenses/by/4.0/>

REFERENCES

1. Coste AH, Bamarni S, Leslie SW. Umbilical hernia. [Updated 2024 Feb 27]. In: *StatPearls* [Internet]. Treasure Island (FL): StatPearls

- Publishing. 2024. Available at: <https://www.ncbi.nlm.nih.gov/books/NBK459312/>. Accessed March 20, 2024.
2. Manassero A, Bossolasco M, Meineri M, et al. Spread patterns and effectiveness for surgery after ultrasound-guided rectus sheath block in adult day-case patients scheduled for umbilical hernia repair. *J Anaesthesiol Clin Pharmacol*. 2015;31(3):349–53.
 3. Phua DS, Phoo JW, Koay CK. The ultrasound-guided rectus sheath block as an anaesthetic in adult paraumbilical hernia repair. *Anaesth Intensive Care*. 2009;37(3):499–500.
 4. Karaarslan E, Topal A, Avcı O, et al. Research on the efficacy of the rectus sheath block method. *Agri*. 2018;30(4):183–8.
 5. Quek KH and Phua DS. Bilateral rectus sheath blocks as the single anaesthetic technique for an open infraumbilical hernia repair. *Singapore Med J*. 2014;55(3):e39–41.
 6. Levin M. Nerve blocks in the treatment of headache. *Neurotherapeutics*. 2010;7(2):197–203.
 7. Wathen JE, Gao D, Merritt G, et al. A randomized controlled trial comparing a fascia iliaca compartment nerve block to a traditional systemic analgesic for femur fractures in a pediatric emergency department. *Ann Emerg Med*. 2007;50(2):162–71.
 8. Tezel O, Kadirim U, Bilgic S, et al. A comparison of suprascapular nerve block and procedural sedation analgesia in shoulder dislocation reduction. *Am J Emerg Med*. 2014;32(6):549–52.
 9. Beaudoin FL, Haran JP, Liebmann O. A comparison of ultrasound-guided three-in-one femoral nerve block versus parenteral opioids alone for analgesia in emergency department patients with hip fractures: a randomized controlled trial. *Acad Emerg Med*. 2013;20(6):584–91.
 10. Neubrand TL, Roswell K, Deakyne S, et al. Fascia iliaca compartment nerve block versus systemic pain control for acute femur fractures in the pediatric emergency department. *Pediatr Emerg Care*. 2014;30(7):469–73.
 11. Blaivas M, Adhikari S, Lander L. A prospective comparison of procedural sedation and ultrasound-guided interscalene nerve block for shoulder reduction in the emergency department. *Acad Emerg Med*. 2011;18(9):922–7.
 12. Stone MB, Wang R, Price DD. Ultrasound-guided supraclavicular brachial plexus nerve block vs procedural sedation for the treatment of upper extremity emergencies. *Am J Emerg Med*. 2008;26(6):706–10.

Angioedema Secondary to Tenecteplase Use in a Patient with Acute Ischemic Stroke: A Case Report

Babette Newman, DO*
 Matthew Poremba, PharmD†
 R. Gentry Wilkerson, MD*

*University of Maryland Medical Center, Department of Emergency Medicine,
 Baltimore, Maryland

†University of Maryland Medical Center, Department of Pharmacy,
 Baltimore, Maryland

Section Editor: Steven Walsh, MD

Submission history: Submitted January 9, 2024; Revision received April 9, 2024; Accepted April 16, 2024

Electronically published July 11, 2024

Full text available through open access at http://escholarship.org/uc/uciem_cpchem

DOI: 10.5811/cpcem.7190

Introduction: Angioedema, a swelling of the subcutaneous or submucosal layers of the skin or gastrointestinal tract, is a potential complication to thrombolytic therapy in the treatment of acute ischemic strokes. In these cases, angioedema develops due to increased levels of bradykinin as a result of the activation of the fibrinolytic pathway and contact activation system. Angioedema can involve the tongue, larynx, and vocal cords, leading to occlusion of the airway and death due to asphyxiation. It is vital for the emergency physician to know that this complication can occur to ensure appropriate monitoring for development of angioedema.

Case Report: We report the case of a 65-year-old Black man who presented with signs of an acute ischemic stroke and was treated with tenecteplase. The patient's stroke symptoms mostly resolved within 90 minutes; however, he developed swelling of his right upper lip consistent with angioedema. The patient was treated with steroids and antihistamines. He was closely monitored and did not require airway intervention. The angioedema was almost fully resolved by the following day.

Conclusion: Angioedema is a known complication of thrombolytic therapy for acute ischemic stroke. Risk factors for alteplase-associated angioedema include use of angiotensin-converting enzyme inhibitors, female gender, diabetes, and infarcts of the insula and frontal cortex. As hospital systems switch from alteplase to tenecteplase for the treatment of acute ischemic strokes for reasons of cost and ease of administration, it is important to recognize that angioedema is also a potential complication of tenecteplase. [Clin Pract Cases Emerg Med. 2024;8(3)264–267.]

Keywords: *angioedema; tenecteplase; stroke; airway.*

INTRODUCTION

Angioedema describes the development of swelling of the subcutaneous or submucosal layers of the cutaneous and gastrointestinal tracts. Numerous mechanisms can result in the development of angioedema, and these are usually classified based on the underlying substance causing the swelling. Histaminergic angioedema is due to the release of histamine and is seen in cases of allergy and anaphylaxis as well as other immunologic processes. Bradykinin-mediated angioedema includes hereditary angioedema (HAE), which is usually caused by deficient quantity or function of

C1-esterase inhibitor (C1-INH), acquired angioedema where the levels of C1-INH are low due to increased consumption, and medication-associated increases in bradykinin including angiotensin-converting enzyme (ACE) inhibitors.¹ In ACE inhibitor-induced angioedema, the ACE enzyme, which also acts as the primary enzyme to break down bradykinin, is inhibited leading to increased levels of bradykinin.²

Numerous case reports have described the development of angioedema following administration of alteplase for the treatment of acute ischemic stroke. In many of these cases the swelling is contralateral to the infarcted hemisphere.³ When

plasminogen is activated to plasmin, the plasmin activates Factor XII to Factor XIIa, which in turn converts prekallikrein to kallikrein, the enzyme responsible for the cleavage of bradykinin from high molecular weight kininogen.¹ Herein we describe a case of angioedema that developed after administration of tenecteplase (TNK). Individual reports of angioedema secondary to tenecteplase have rarely been described,⁴ and to date none have been in a patient not taking an ACE inhibitor.

CASE REPORT

A 65-year-old man presented to the emergency department (ED) via emergency medical services as a stroke alert for acute onset right-sided facial droop, dysarthria, and aphasia. The patient was reportedly found outside by a neighbor who noticed that he was having trouble speaking. On arrival, the patient's neighbor and family members could not be reached for additional information, but his last known well time was estimated to be approximately one hour prior to arrival in the ED. The patient denied any preceding head trauma as well as associated headache, dizziness, vision changes, chest pain, shortness of breath, nausea, or vomiting. His past medical history included hypertension, well-controlled HIV, and previous successful treatment for hepatitis C. He had no history of prior strokes and was not taking anticoagulants. He had documented allergies to lisinopril and shellfish. The patient's initial vital signs were notable for hypertension to 156/84 millimeters of mercury (mm Hg), but otherwise were within normal limits with heart rate 96 beats per minute, respiratory rate 18 respirations per minute, pulse oximetry 96% on room air, and temperature 98.4° Fahrenheit.

On physical exam, the patient was alert and interactive. His speech was moderately dysarthric and aphasic but intelligible with effort. He had facial paralysis on the right. He was able to answer one question correctly and follow two commands correctly. There was no gaze deviation, visual field loss, extremity drift, sensory loss, limb ataxia, or extinction. His initial National Institutes of Health Stroke Scale score was five. The brain attack team was called, and the patient was quickly taken for computed tomography (CT) of the head as well as CT angiography of the head and neck with perfusion. Imaging revealed no intracranial hemorrhage or large vessel occlusion. Since the patient presented within 4.5 hours of symptom onset and there were no obvious contraindications, the decision was made to administer TNK with emergency consent.

The patient received an intravenous (IV) 0.25 milligrams per kilogram (mg/kg) bolus of TNK, 16 mg total. Shortly after TNK administration, his blood pressure increased to 188 mm Hg, so he was started on a clevidipine infusion at 1 mg/hour. Approximately 90 minutes after TNK administration, the patient's neurologic deficits had improved, but he was found to have developed profound swelling of his right upper lip, consistent with angioedema

Population Health Research Capsule

What do we already know about this clinical entity?

Bradykinin-mediated angioedema occurs due to C1-esterase inhibitor deficiency, angiotensin-converting enzyme (ACE) inhibitors, and thrombolytics.

What makes this presentation of disease reportable?

There are few reports of angioedema due to tenecteplase. This is the first description involving a patient not on an ACE inhibitor.

What is the major learning point?

Clinicians should be aware of angioedema as a potential complication of tenecteplase use. It occurs in about 1.1% of patients receiving tenecteplase.

How might this improve emergency medicine practice?

This report underscores the need for close patient monitoring after giving tenecteplase, as the patient's airway may become compromised due to angioedema.

(Image). There was no associated tongue swelling, drooling, or stridor. He had no increased work of breathing and continued to saturate well at 95% on room air. The patient was treated with IV methylprednisolone 125 mg, famotidine 20 mg, and diphenhydramine 50 mg, and close monitoring was continued in the ED. He was ultimately admitted to the neurologic intensive care unit where the angioedema was noted to be almost fully resolved by the following day. Magnetic resonance imaging was performed the following day demonstrating a distal left middle cerebral artery infarct.

DISCUSSION

Alteplase is the current standard of care treatment for acute ischemic stroke and is the only US Food and Drug Administration-approved agent for this indication. Tenecteplase is considered an alternative to alteplase in the 2019 American Heart Association/American Stroke Association guidelines.⁵ It is a genetically modified alteplase variant with increased fibrin specificity and a longer half-life. These modifications allow TNK to be given intravenously as a single, rapid bolus dose, whereas alteplase requires a bolus dose followed by a one-hour infusion.⁶ Recently, multiple trials comparing TNK with alteplase for treatment of stroke

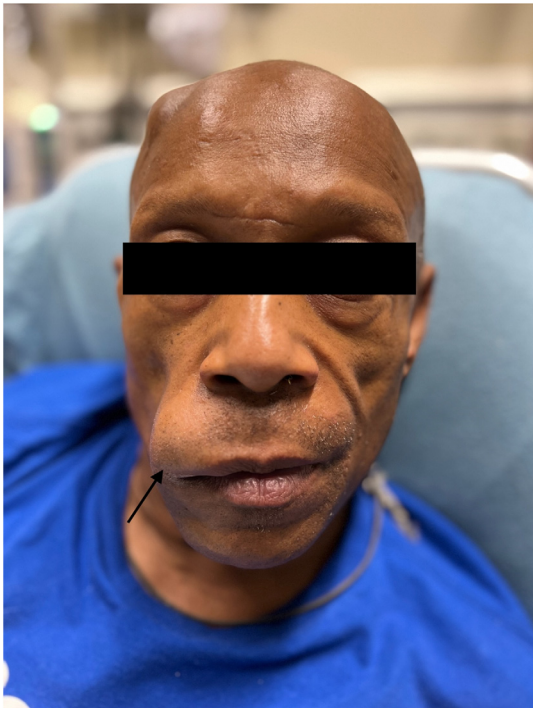

Image. Angioedema of the right upper lip in a patient following administration of tenecteplase (arrow).

have shown TNK to be not inferior in both efficacy and safety.^{7,8} Data from these trials, in combination with the ease of administration and improved cost effectiveness, has prompted many health systems to switch from alteplase to TNK for stroke treatment.^{2,9}

Published studies comparing TNK and alteplase for treatment of stroke most commonly report symptomatic intracranial hemorrhage or any intracranial hemorrhage as their primary safety endpoints, while rates of angioedema are reported inconsistently. The largest published trial comparing alteplase to TNK reported that 9/800 patients (1.1%) receiving TNK and 9/763 patients (1.2%) receiving alteplase experienced angioedema.³ In a single-center retrospective analysis of patients treated with alteplase, the rate of angioedema was reported to be 7.9%.¹⁰ Rose et al performed a systematic review and meta-analysis of complications of TNK and alteplase for stroke and found cumulative angioedema rates of 0.56% in patients with TNK compared to 0.63% in patients receiving alteplase.¹¹

Overall rates of angioedema appear to be similar between alteplase and TNK, but specific characteristics of patients who experience angioedema are seldom reported. A 2022 meta-analysis from Mas Serrano et al found prior treatment with ACE inhibitors, diabetes, dyslipidemia, female gender, and hypertension to be associated with development of angioedema after alteplase administration.¹² Strokes involving the frontal cortex and insula have also been described as having increased risk of angioedema.³ Potential risk factors for experiencing angioedema after TNK administration are not

well described in current literature, although they are expected to be similar to those seen with alteplase given both agents share their mechanism of action. The only published case reports of angioedema after TNK administration occurred in a patients who were currently using an ACE inhibitor, which is a known risk factor for development of angioedema.^{4,13} Our patient was not currently taking an ACE inhibitor at the time he received TNK, although he had documented history of an allergic reaction to the ACE inhibitor lisinopril.

There have been no studies to determine the best treatment of angioedema following TNK administration. The primary goal is to ensure airway patency. Despite histamine not being the substrate causing angioedema following TNK administration, some have suggested that it should be treated similarly to allergic reactions by administering antihistamines, steroids, and in some cases epinephrine. The use of medications that are approved for HAE have not been studied and are currently not recommended for this indication. The lysine analog, tranexamic acid (TXA), could have a potential benefit as it binds to plasmin, preventing the activation of Factor XII leading to decreased production of bradykinin. Tranexamic acid is an antifibrinolytic in that it prevents plasmin degradation of fibrin-to-fibrin degradation products. Use of TXA may lead to worse outcomes in patients with acute ischemic strokes.

CONCLUSION

This case report provides details regarding the development of angioedema in a patient being treated with tenecteplase for an acute ischemic stroke. While it is known that angioedema is a potential complication of TNK administration, the details of individual cases are rarely reported. It is important for the emergency physician to be aware of this potential complication of TNK so that patients do not experience further morbidity and mortality.

The authors attest that their institution requires neither Institutional Review Board approval, nor patient consent for publication of this case report. Documentation on file.

Address for Correspondence: R. Gentry Wilkerson, MD, University of Maryland Medical Center, Department of Emergency Medicine, 110 S Paca St., 6th Floor, Suite 200, Baltimore, MD 21201. Email: gwilkerson@som.umaryland.edu

Conflicts of Interest: By the CPC-EM article submission agreement, all authors are required to disclose all affiliations, funding sources and financial or management relationships that could be perceived as potential sources of bias. The authors disclosed none.

Copyright: © 2024 Newman et al. This is an open access article distributed in accordance with the terms of the Creative Commons Attribution (CC BY 4.0) License. See: <http://creativecommons.org/licenses/by/4.0/>

REFERENCES

1. Wilkerson RG and Moellman JJ. Hereditary angioedema. *Emerg Med Clin N Am.* 2021;40(1):99–118.
2. Wilkerson RG and Winters ME. Angiotensin-converting enzyme inhibitor-induced angioedema. *Emerg Med Clin N Am.* 2021;40(1):79–98.
3. Hill MD, Lye T, Moss H, et al. Hemi-orolingual angioedema and ACE inhibition after alteplase treatment of stroke. *Neurology.* 2003;60(9):1525–7.
4. Shi G, Lv J, Wu W, et al. Ipsilateral orolingual angioedema following rhTNK-tPA administration for acute ischemic stroke. *Am J Emerg Med.* 2024;77:231.e1–3.
5. Powers WJ, Rabinstein AA, Ackerson T, et al. Guidelines for the early management of patients with acute ischemic stroke: 2019 update to the 2018 guidelines for the early management of acute ischemic stroke: a guideline for healthcare professionals from the American Heart Association/American Stroke Association. *Stroke.* 2019;50(12):e344–418.
6. Noh L, Pham F, Haddad L, et al. A practice game changer: impact of tenecteplase for acute ischemic stroke in a multicenter quality improvement project. *Am J Health Syst Pharm.* 2022;79(9):e149–53.
7. Menon BK, Buck BH, Singh N, et al. Intravenous tenecteplase compared with alteplase for acute ischaemic stroke in Canada (AcT): a pragmatic, multicentre, open-label, registry-linked, randomised, controlled, non-inferiority trial. *Lancet.* 2022;400(10347):161–9.
8. Burgos AM and Saver JL. Evidence that tenecteplase is noninferior to alteplase for acute ischemic stroke: meta-analysis of 5 randomized trials. *Stroke.* 2019;50(8):2156–62.
9. Dittmar E, Wolfel T, Menendez L, et al. Conversion from intravenous alteplase to tenecteplase for treatment of acute ischemic stroke across a large community hospital health system. *Ann Pharmacother.* 2023;57(10):1147–53.
10. Hurford R, Rezvani S, Kreimeier M, et al. Incidence, predictors and clinical characteristics of orolingual angio-oedema complicating thrombolysis with tissue plasminogen activator for ischaemic stroke. *J Neurol Neurosurg Psychiatry.* 2015;86(5):520–3.
11. Rose D, Cavalier A, Kam W, et al. Complications of intravenous tenecteplase versus alteplase for the treatment of acute ischemic stroke: A systematic review and meta-analysis. *Stroke.* 2023;54(5):1192–204.
12. Mas-Serrano M, García-Pastor A, Iglesias-Mohedano AM, et al. Related factors with orolingual angioedema after intravenous alteplase in acute ischemic stroke: results from a single-center cohort and meta-analysis. *Neurol Sci.* 2022;43(1):441–52.
13. Lapostolle A, Weisenburger-Lile D, Yger M, et al. Bradykinin-mediated angioedema following tenecteplase administration in an acute ischemic stroke. *Stroke.* 2022 Oct;53(10):e446–7.

Tension Pyopneumothorax in an Immunocompetent Adolescent: A Case Report

Elizabeth May-Smith, MD
Marc Olshan, MD
Mark Supino, MD

Jackson Memorial Hospital, Department of Emergency Medicine, Miami, Florida

Section Editor: Anna McFarlin, MD

Submission history: Submitted November 28, 2024; Revision received April 12, 2024; Accepted April 16, 2024

Electronically published July 18, 2024

Full text available through open access at http://escholarship.org/uc/uciem_cpccem

DOI: [10.5811/cpcem.6590](https://doi.org/10.5811/cpcem.6590)

Introduction: Tension pyopneumothorax is a rare, life-threatening condition that occurs as a complication of intrathoracic infection or bronchopleural fistula. In the few cases reported in the literature, the patients typically have multiple comorbidities, underlying lung disease, and/or an immunocompromised state.

Case Report: This case describes tension pyopneumothorax in a previously healthy adolescent male with no existing risk factors for this disease. After emergent stabilization and admission, surgical exploration of the chest revealed no fistulas or pleural defects. Extensive workup did not show any underlying risk factors for development of this condition.

Conclusion: This case of pyopneumothorax with progression to tension physiology is exceedingly rare. Uniquely, the patient had no underlying medical or anatomical predisposition to developing this condition. The case also emphasizes pediatric patients' capacity to compensate in the setting of critical illness. [Clin Pract Cases Emerg Med. 2024;8(3)268–272.]

Keywords: *tension pyopneumothorax; thoracostomy; empyema; case report; pediatrics.*

INTRODUCTION

Tension pneumothorax is a standard emergency department (ED) diagnosis, typically seen in the setting of trauma, and requires immediate clinical recognition and intervention. Tension physiology can less commonly occur with other pathology inside the chest, such as infection. Tension pyopneumothorax is a rare, life-threatening condition that can develop in the setting of intrathoracic infection. There are few cases described in the literature. The diagnosis tends to occur in patients with multiple comorbidities and underlying lung pathology.^{1,2} We describe a case of tension pyopneumothorax in a previously healthy adolescent with slow development over several weeks. Management includes prompt thoracostomy, respiratory support, antibiotics and, often, surgical management for adequate source control.^{3,4}

CASE REPORT

The patient was a 12-year-old Hispanic male who presented to the ED accompanied by his father for shortness of breath. On arrival, the patient was diaphoretic, profoundly tachypneic, and appeared frightened in triage. The father reported that the patient had complained of severe chest pain and difficulty breathing for several days. The patient was promptly moved to the resuscitation room, where initial vital signs were as follows: temperature 37.1° Celsius, heart rate 150 beats per minute, respiratory rate 60 breaths per minute, oxygen saturation 91% on room air, and blood pressure 120/90 millimeters of mercury. He weighed 69 kilograms with a body mass index of 28.

Upon auscultation, absent breath sounds were noted over the left chest. There was initial concern for spontaneous pneumothorax. As the patient was being connected to the monitor and a stat portable chest radiograph (CXR) was

ordered, a point-of-care ultrasound demonstrated absent lung sliding over the left chest. No fluid was noted at that time on ultrasound. On further physical exam, the patient was alert with appropriate mentation but appeared to be in significant distress. In the wheelchair before transferring to the stretcher he was in a tripod position and profoundly tachypneic. He was tachycardic with intact peripheral pulse, capillary refill of 2–3 seconds, and no jugular venous distension was noted. The patient's father elaborated that the patient had complained of shortness of breath and malaise for more than one week leading up to his presentation but denied any cough or fevers. He reported that the patient had no past medical history, no known allergies, and no prior surgeries. The patient was up to date on all vaccinations since immigrating to the United States five years prior from Central America.

A rapid portable CXR demonstrated a left-sided apical pneumothorax with effusion at the base and evidence of tension physiology (**Image 1A**). Needle decompression was deferred as the patient was normotensive without signs of imminent circulatory collapse, and the team quickly set up for tube thoracostomy. The team was worried that intubation would exacerbate underlying tension physiology and circulatory status; so the patient was maintained on non-rebreather oxygenation and sedated with ketamine for the procedure. A pigtail catheter placement was attempted with lateral approach; however, a syringe of bloody, purulent malodorous fluid was aspirated; thus, the team switched to a traditional large-bore thoracostomy with a 28 French tube. Upon accessing the chest, a large volume of foul-smelling purulent fluid was extruded. A post-procedure radiograph showed the chest tube in proper position and improved position of mediastinal structures, with some persistent left pneumothorax and effusion (**Image 1B**). The patient's heart rate improved to 130 beats per minute, respiratory rate decreased to 30 breaths per minute, oxygen saturation of 100% on 15 liters oxygen non-rebreather, and his blood pressure remained the same.

CPC-EM Capsule

What do we already know about this clinical entity?

Tension pyopneumothorax is a rare clinical presentation in the emergency department that requires swift recognition and intervention.

What makes this presentation of disease reportable?

This is the first described case in an immunocompetent pediatric patient due to the organism Streptococcus Constellatus.

What is the major learning point?

Clinicians with suspicion for this presentation should consider large-bore tube thoracostomy and transfer to a facility with pediatric surgical capability.

How might this improve emergency medicine practice?

Timely intervention is key to preventing morbidity and mortality. Point-of-care ultrasound and prompt thoracostomy will aid in diagnosis and management.

Blood work was significant for a white blood cell count of 26,000 per microliter (μL) (normal range 4,500–13,000/ μL), lactate of 3.1 millimoles per liter (mmol/L) (0.7–2.1 mmol/L), albumin of 2.8 grams per deciliter (g/dL) (3.9–5.0 g/dL), mild transaminitis, normal renal function, and normal pH on venous blood gas. On further chart review, we found that the patient had been seen in the ED two weeks prior for back

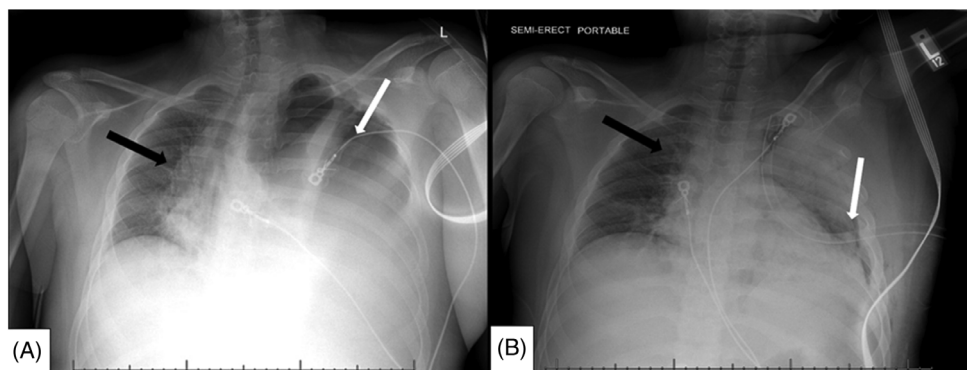


Image 1. Emergency department chest radiograph (CXR): A) first semi-upright, one view radiograph of the chest demonstrating left-sided hydropneumothorax (white arrow) with shifting of the mediastinal structures toward the right (arrow); B) one view CXR post-procedure demonstrating interval chest tube placement on the left side with expansion of left lung (arrow), improved hydropneumothorax, and resolved tension physiology (black arrow).

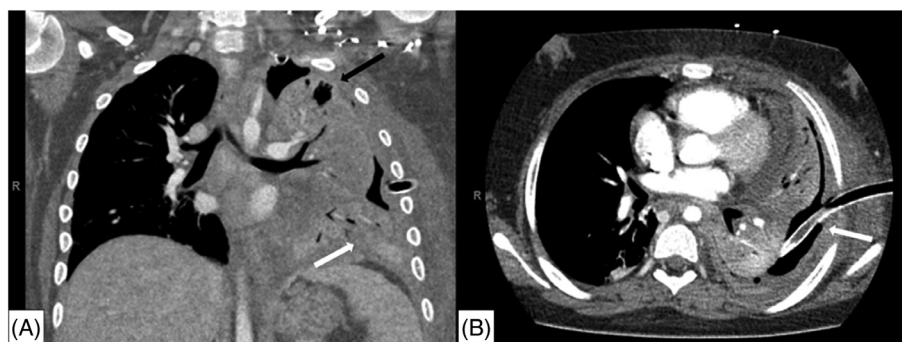


Image 2. Computed tomography imaging of the chest during early hospital course: A) coronal view and B) axial view demonstrating residual moderate left hydropneumothorax with diffuse opacification of left lung representing extensive pneumonia (white arrow), and peripheral air lucencies on the left suggestive of loculations (black arrow). Chest tube noted to be in good position with fluid and debris obstructing the lumen of tube (white arrow).

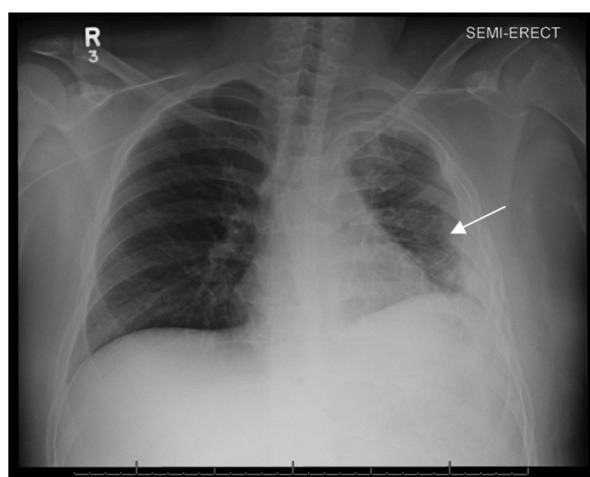


Image 3. Chest radiograph one view that shows re-expansion of the lung with improved opacification and some residual diffuse interstitial prominence of the left lung (arrow). Interval removal of chest tube.

pain and had a normal CXR at that time. Broad spectrum antibiotics were administered in the ED, the patient was placed on high-flow nasal cannula, and he was admitted to the pediatric intensive care unit (PICU). By the time he transferred out of the ED, greater than 1.5 liters of purulent output from the chest tube had emptied into the closed chest drainage system. Once the patient was stabilized in the PICU, computed tomography of the chest was obtained the following day that showed a moderate left hydropneumothorax, diffuse opacification of the left lung in the setting of extensive pneumonia, and peripheral air lucencies on the left, likely representing loculations (Image 2).

The patient remained in the PICU for three weeks. He continued parenteral antibiotics and required multiple doses of intrapleural alteplase to clear debris from the chest tube. On hospital day five, he underwent a video-assisted

thoroscopic (VATS) procedure for washout of the chest and replacement of the original chest tube. Operative report from the VATS procedure described fibrinous debris on the surface of the lung upon entry into the chest cavity, as well as dense adhesions between the lung and pleural surface of the chest wall. Gross examination and recruitment maneuvers did not reveal any other focal abnormalities of the lung itself, and no bronchopleural fistulas were observed.

Culture of the chest tube output grew *Streptococcus constellatus* for which antibiotics were narrowed to ampicillin-sulbactam. The patient required intermittent bilevel positive airway pressure for the first two weeks of admission but was eventually weaned from all supplemental oxygen. Further workup for tuberculosis, underlying immunodeficiency, and malignancy were negative. Ultimately the final CXR demonstrated improved aeration of the left lung (Image 3). The patient was discharged home after a total of one month in the hospital. He attended one follow-up appointment one month after hospital discharge and reported no residual respiratory symptoms at that time. Unfortunately, he was lost to follow-up after that appointment.

DISCUSSION

Tension pyopneumothorax is a rare, life-threatening condition in which air and pus compress the lung and other intrathoracic structures, and it occurs as a complication of pneumonia, trauma, aspiration, lung abscess, or preexisting bronchopulmonary or pleural fistula.³ In the absence of a pleural defect, it is also theorized that a pyopneumothorax can arise from an abscess, empyema, or pyogenic infection with a gas-forming organism inside the chest.⁵ The tension physiology in this case was characterized by severe respiratory distress and signs of shock including tachycardia and mild hypoxia with visible shifting of mediastinal structures on radiograph. Although the patient was normotensive on initial assessment, he became hypertensive throughout hospitalization and required antihypertensive

medications upon discharge. This suggests that his presenting blood pressure was likely below his baseline and a sign of early circulatory compromise.

There are few case reports describing this condition, and only a handful of cases are described in the pediatric population. Most documented cases of tension pyopneumothorax have a rapidly progressive clinical course and occurred in patients with underlying disease or immunocompromise, such as malignancy, Parkinson disease, cerebral palsy, substance use, recurrent pneumonias, and/or aspiration events. There is one similar case that describes development of symptoms and progression to tension physiology over several weeks in a pediatric patient.³ Our patient's case is quite unique in that the patient had a gradual development of a pyogenic pneumonia that led to tension physiology without any identifiable underlying disease or immunocompromise.

Anaerobic bacteria are implicated in 30% of pyothorax, although a combined flora can be seen in cases of pyothorax with aspiration etiology.^{6,7} *S constellatus* was the culprit organism in our patient's pyopneumothorax. *S constellatus* is part of the *S anginosus* group; these anaerobes are native to different systems in the body including the upper respiratory tract, oral cavity, gastrointestinal tract, and reproductive tract.² Since these Gram-positive bacteria are native to the respiratory tract, it can be difficult to distinguish them from contaminant or causative organism on culture; rarely, these bacteria can lead to aggressive pyogenic infections.⁸ *S constellatus* has been associated with abscess formation and empyema. Due to its anaerobic metabolism, *S constellatus* produces gas, which could lead to development of tension in pyogenic intrathoracic infections.⁵

Patients with severe infections typically have risk factors such as extensive smoking history, malignancy, chronic lung disease, periodontal disease, and infectious diseases such as HIV and hepatitis.² One case report describes a 57-year-old male patient with history of hepatitis C, tobacco use, and chronic obstructive pulmonary disease who was found to have an aggressive *S constellatus* cavitary lesion as a sequela of a recent subsegmental pulmonary emboli.⁹ Despite early initiation of broad-spectrum antibiotic coverage, the lesion rapidly expanded, necessitating extensive surgical management including partial pleurectomy and localized resection in addition to antibiotics. Our case is the first to describe *S constellatus* as the causative organism in pyopneumothorax with tension physiology.

The mainstay of treatment for tension pyopneumothorax is pleural drainage and parenteral antibiotics, although for some patients with underlying fistula or other structural abnormalities of the lung, resection or lobectomy may be required.^{4,10} Needle decompression is indicated in tension physiology due to impending circulatory collapse; however, this step was not performed in our patient due to normotension and rapid capability to perform tube

thoracostomy. Initial pleural drainage in these cases can be done with small- or large-bore tube thoracostomy. Small-bore or pigtail catheters are generally better suited for pneumothoraces and transudative effusions due to their small diameter and potential for occlusion.¹¹ In this case, small-bore thoracostomy was attempted but aborted due to aspiration of blood and purulence into the syringe. Even when the patient had successful initial drainage with a large-bore thoracostomy, he eventually required multiple days of intrapleural alteplase due to tube occlusion and definitive VATS procedure to achieve source control. Similar cases presenting to smaller community hospitals would require transfer to a larger center where pediatric thoracic surgery consult and management is available.

CONCLUSION

Our patient presented with a progressive *S constellatus* pneumonia and empyema that led to formation of a tension pyopneumothorax, a rare, life-threatening condition. This case is unique in that the patient did not have any risk factors for development of the tension pyothorax or severe pyogenic infection from *S constellatus*, and he exhibited a subacute course leading to ED presentation. Additionally, our case highlights the resilience of pediatric patients and their ability to compensate during active disease processes. Our patient presented critically ill from a severe pneumonia that had been developing for at least one week. Despite the tension physiology he developed from the underlying pneumonia, his mental status and blood pressure were intact. The patient did well after initial management with tube thoracostomy and further parenteral antibiotics, supplemental oxygen, and a VATS procedure. The patient might have benefited from earlier surgery, which would have resulted in more rapid source control of such an aggressive infection, but he was ultimately liberated from all respiratory support and completed several weeks of parenteral antibiotics to make a full recovery.

The authors attest that their institution requires neither Institutional Review Board approval, nor patient consent for publication of this case report. Documentation on file.

Address for Correspondence: Elizabeth May-Smith, MD, Jackson Memorial Hospital, Department of Emergency Medicine, 1611 NW 12th Ave., Miami, FL, 33136. Email: elizabeth.smith@jhsmiami.org

Conflicts of Interest: By the CPC-EM article submission agreement, all authors are required to disclose all affiliations, funding sources and financial or management relationships that could be perceived as potential sources of bias. The authors disclosed none.

Copyright: © 2024 May-Smith et al. This is an open access article distributed in accordance with the terms of the Creative Commons Attribution (CC BY 4.0) License. See: <http://creativecommons.org/licenses/by/4.0/>

REFERENCES

1. Kanai O, Fujita K, Okamura M, et al. Afebrile tension pyopneumothorax due to anaerobic bacteria: fistula or gas production? *Respir Med Case Rep.* 2021;32:101372.
2. Noguchi S, Yatera K, Kawanami T, et al. The clinical features of respiratory infections caused by the *Streptococcus anginosus* group. *BMC Pulm Med.* 2015;15:133.
3. Whiteman PJ, Wilson MT, Barcay D, et al. Tension pyopneumothorax in a child: a case report. *J Emerg Med.* 2003;24(4):429–31.
4. Mitsui S and Tauchi S. Tension pyopneumothorax. *BMJ Case Rep.* 2021;14(3):e242197.
5. Hsieh C-F, Lin H-J, Foo N-P, et al. Tension pyopneumothorax. *Resuscitation.* 2007;73(1):6–7.
6. Tsang KY, Leung WS, Chan VL, et al. Complicated parapneumonic effusion and empyema thoracis: microbiology and predictors of adverse outcomes. *Hong Kong Med J.* 2007;13(3):178–86.
7. Jerng J-S, Hsueh P-R, Teng L-J, et al. Empyema thoracis and lung abscess caused by viridans streptococci. *Am J Respir Crit Care Med.* 1997;156(5):1508–14.
8. Porta G, Rodriguez-Carballeira M, Gomez L, et al. Thoracic infection caused by *Streptococcus milleri*. *Eur Respir J.* 1998;12(2):357–62.
9. Vulisha AK, Sam R, Nur H, et al. Aggressive presentation of *Streptococcus constellatus*. *Cureus.* 2021;13(4):e14534.
10. Reid JM, Barclay RS, Stevenson JG, et al. The management of spontaneous pyopneumothorax and empyema in young children. *Dis Chest.* 1966;49(2):175–8.
11. Anderson D, Chen S, Godoy L, et al. Comprehensive review of chest tube management. *JAMA Surg.* 2022;157(3):269–74.

Community-Acquired *Candida albicans* Empyema Leading to Tension Physiology: A Case Report

Jason Cinti, DO
Paula Gomez, DO
Suneil Agrawal, MD

Desert Regional Medical Center, Department of Emergency Medicine, Palm Springs, California

Section Editor: Christopher San Miguel, MD

Submission history: Submitted February 10, 2024; Revision received April 19, 2024; Accepted April 19, 2024

Electronically published August 1, 2024

Full text available through open access at http://escholarship.org/uc/uciem_cpccem

DOI: [10.5811/cpcem.19426](https://doi.org/10.5811/cpcem.19426)

Introduction: A tension empyema, in which purulent material accumulates in the chest cavity and leads to cardiopulmonary dysfunction, is a rare complication of empyemas. Moreover, fungal empyemas that grow *Candida albicans* and cause tension physiology have not yet been previously described.

Case Report: In this report, we present an immunocompetent 30-year-old male who presented to the emergency department with worsening shortness of breath and was found to have a left-sided fungal empyema causing tension physiology. Left chest thoracostomy yielded approximately 4 liters of purulent fluid. Pleural cultures eventually grew *C albicans*, and after antifungal therapy, surgical decortication of the lung, and a prolonged intensive care unit stay, the patient was discharged home in stable condition.

Conclusion: While mortality from *C albicans* empyemas that cause respiratory compromise is exceedingly high, our case highlights that aggressive management with rapid chest thoracostomy and antifungal therapy can lead to a favorable outcome. [Clin Pract Cases Emerg Med. 2024;8(3)273–276.]

Keywords: case report; empyema thoracis; tension empyema; *Candida albicans*; severe hyponatremia.

INTRODUCTION

Tension empyema describes a large accumulation of purulent material in the chest cavity, which then entraps the lung and compresses mediastinal structures. This causes cardiopulmonary dysfunction by preventing adequate ventilation and can lead to severely reduced cardiac output via increased intrathoracic pressures and decreased venous return, resulting in life-threatening cardiac arrest.¹

Empyemas are often polymicrobial, composed of both aerobic and anaerobic bacteria, and are most commonly caused by pneumonia and parapneumonic effusion.^{2,3} Those that grow fungi are particularly rare. *Candida albicans* empyema has previously been described as a potential complication of community-acquired pneumonia.⁴ However, most candidal empyemas have been diagnosed in patients with preceding abdominal and intrathoracic surgeries or patients with esophageal rupture.⁵ To our knowledge, there have been no cases in the literature that describe candida empyema that demonstrate tension

physiology. In this case we present an immunocompetent patient with no reported past medical history who presented to the emergency department (ED) with a chief complaint of shortness of breath. He was found to have a tension empyema that grew *C albicans*.

CASE REPORT

A 30-year-old male with no reported past medical history presented to the ED by ambulance with the chief complaint of shortness of breath. He reported progressively worsening dyspnea and a productive cough for the prior 6–8 weeks. He was given an albuterol breathing treatment by emergency medical services (EMS) with no relief of his symptoms, and he was placed on a non-rebreather mask at 15 liters per minute (L/min) by EMS due to an initial oxygen saturation of 80%. The patient denied recent fevers, chills, chest pain, nausea, vomiting, abdominal pain, urinary complaints, leg swelling, recent sick contacts, or recent travel. He denied a history of intravenous drug use; however, he did endorse

daily tobacco smoking and heavy alcohol use, particularly beer. His mother provided additional history, stating that the patient had been drinking over 10 beers per day for the prior several weeks with minimal food intake.

Initial vitals in the ED were notable for tachycardia at 115 beats per minute, tachypnea at 30 breaths per minute, and hypoxia at 82% on a 15 L/min non-rebreather mask. He was afebrile, and his blood pressure was 135/85 millimeters of mercury (mm Hg). Physical exam revealed a toxic-appearing, uncomfortable male in moderate respiratory distress. He was diaphoretic. He had decreased breath sounds over the left lower lobe and clear breath sounds on the right. His chest wall was asymmetrical, with the left chest appearing larger and more protruding than the right chest. Laboratory blood work taken on arrival revealed a leukocytosis of 20×10^3 white blood cells per microliter ($10^9/L$) (reference range $4.2\text{--}10.8 \times 10^9/L$), severe hyponatremia at 104 milliequivalents (mEq)/L ($137\text{--}145$ mEq/L), a lactic acidosis at 3.22 millimoles (mmol)/L ($0.8\text{--}2.0$ mmol/L), and a negative blood alcohol level. The rest of the basic metabolic panel revealed a potassium of 5.3 mEq/L ($3.4\text{--}5.0$ mEq/L), chloride of 69 mEq/L ($98\text{--}107$ mEq/L), bicarbonate of 21 mEq/L ($21\text{--}30$ mEq/L), glucose 138 mg/dL ($70\text{--}110$ mg/dL), calcium of 7.0 milligrams per deciliter (mg/dL) ($7.8\text{--}9.8$ mg/dL), blood urea nitrogen of 8.0 mg/dL ($9.0\text{--}20$ mg/dL), creatinine of 0.3 mg/dL ($0.7\text{--}1.3$ mg/dL), and an albumin of 2.7 grams (g)/dL ($3.5\text{--}5.0$ g/dL). The urine drug screen was positive only for tetrahydrocannabinol.

The patient was started on broad spectrum antibiotics with vancomycin and cefepime in the ED. Due to delays in radiographs, the patient had a computed tomography (CT) of the chest with intravenous contrast to further investigate the cause of his difficulty breathing. The CT was immediately reviewed by the emergency physician, and the patient was found to have a large collection of fluid and gas in the left chest, with a deviated trachea and extensive rightward deviation of the heart (**Image 1**). While not true tension physiology given the patient's indolent onset of symptoms (6–8 weeks) and initial hemodynamic stability, as tension

Population Health Research Capsule

What do we already know about this clinical entity?

Tension empyemas are large accumulations of purulent material in the chest cavity that entrap the lung, leading to cardiopulmonary dysfunction.

What makes this presentation of disease reportable?

Fungal empyemas that grow Candida albicans and cause tension physiology have not been previously described.

What is the major learning point?

Tension physiology and cardiovascular collapse are rare but possible complications of empyemas; thus, it is critical that physicians quickly identify and treat it.

How might this improve emergency medicine practice?

Aggressive management with chest thoracostomy and antifungal therapy can lead to a favorable outcome despite the high mortality associated with this disease process.

physiology typically describes a more acute condition involving hemodynamic collapse, such findings on CT were certainly concerning for impending tension physiology.

Based on the findings on CT and his increasing work of breathing, he was intubated emergently. His oxygen saturation prior to intubation was 84% on a 15 L/min non-rebreather mask. He became hypotensive post-intubation after sedation and was started on norepinephrine infusion. Given the large amount of fluid and air seen on CT, it was

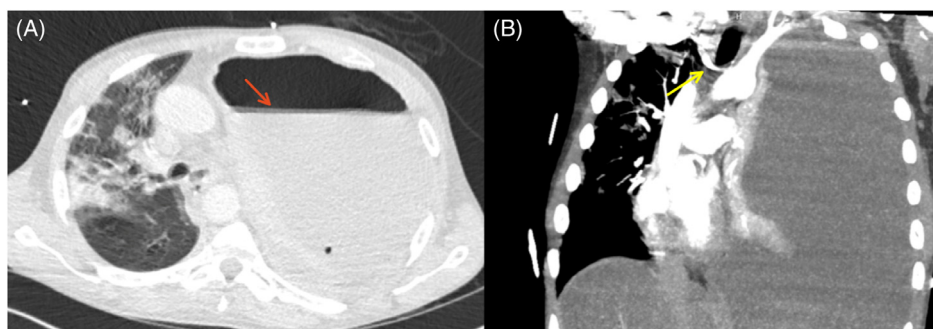


Image 1. A. Axial view of initial computed tomography chest showing large left hydro-pneumothorax with complete left lung collapse (red arrow). B. Coronal view of significant rightward shift of the trachea and mediastinum (yellow arrow).

initially thought that the patient may have had a diaphragmatic hernia with extrusion of the stomach into the left thorax. For this reason, general surgery was consulted. A subsequent CT of the abdomen and pelvis showed no diaphragmatic rupture or abdominal involvement. The surgery resident performed a left-sided thoracostomy, with immediate output of four liters of thick, purulent, and highly malodorous material. Hemodynamics improved after chest tube insertion, with improvement in his blood pressure from 88/55 mm Hg to 113/64 mm Hg. The patient was admitted to the intensivist care unit (ICU) on mechanical ventilation and remained on 15 micrograms/min of norepinephrine.

During his inpatient stay, pleural fluid anaerobic cultures grew *Prevotella oris*, suggesting oral microbes and aspiration pneumonia with parapneumonic effusion and empyema. Pleural fluid and sputum cultures as well as blood cultures also grew *C albicans*. On repeat CT chest one day later, the patient had a persistent empyema. To evacuate the empyema, cardiothoracic surgery was consulted and performed a left thoracoscopy with total decortication, lysis of adhesions, and total parietal pleurectomy. Postoperative CT chest showed persistent but reduced empyema and improved mediastinal shift (Image 2).

The patient was successfully extubated six days after the cardiothoracic procedure, the chest tubes were removed, and he was downgraded from the ICU to the telemetry unit 15 days after admission. His hyponatremia resolved on day nine after admission with careful fluid restriction and maintenance fluids. Owing to rapid initial overcorrection, desmopressin and dextrose 5% in water were used to prevent central pontine myelinolysis.

Repeat CT chest prior to discharge showed residual airspace densities in the lungs with improved aeration compared to the prior study, persistent atelectasis at the left

lower lobe with interval re-expansion of the left upper lobe, and diffuse pleural thickening in the left hemithorax with loculated left hydropneumothorax, significantly smaller compared to the prior study. He was discharged home with a walker 24 days after admission with follow-up with cardiothoracic surgery in two weeks.

DISCUSSION

In this report we describe a case of *C albicans* empyema causing impending tension physiology in a 30-year-old male with a history of alcoholism, with over 4 liters of purulent, malodorous output after initial tube thoracostomy. There are only a few case reports in the literature that describe tension empyemas, and none that we are aware of that describe tension physiology from a fungal empyema. Ooko et al discuss a tension empyema causing cardiac arrest in a young, immunocompromised patient with HIV and tuberculosis, with ~2900 milliliters (mL) of pus output after thoracostomy.⁶ Ahern et al describe a 28-year-old female with HIV with post-intubation cardiac arrest and output of ~1500–2000 mL of purulent exudate.⁷ Bramley et al discuss a 42-year-old male with diabetes mellitus type 1 and trisomy 21 who presented in pulseless electrical activity and a hypo-inflated left hemithorax with absent breath sounds, with ~900 mL of malodorous pus output.⁸ None of these cases were of fungal etiology. Until our case, the largest fungal empyema described in the literature was by Srinivasnakshatri et al in 2014, with ~2500 mL of fluid that grew *C krusei* and *C tropicalis* drained over 48 hours.⁹ The immediate drainage of 4 liters of pus growing *C albicans* in our case is thus unprecedented.

The case is also unusual in that empyemas that grow *C albicans* are often a result of esophageal perforation, fistula formation, or preceding abdominal and intrathoracic surgeries.⁴ In the first retrospective analysis of 67 patients with fungal empyema in Taiwan by Ko et al, the most common underlying cause (30%) was abdominal disease, especially prior abdominal surgery or gastrointestinal perforation.⁵ Our patient did not have a preceding surgery or gastrointestinal perforation. It is likely that he had an aspiration event owing to his excessive alcohol use that ultimately led to pneumonia with subsequent parapneumonic effusion, which is further reflected by the fact that the pleural fluid also grew *Prevotella*, predominantly an oral microbe. This is a common mechanism: in one retrospective study of 63 patients with *Candida* empyema thoracis, 55.6% of these were from contiguous infection.¹⁰

In another retrospective analysis of 81 patients, *Candida* empyema was from an intrathoracic source in 51% of patients.⁴ The second most common underlying cause of fungal empyema in the analysis by Ko et al was bronchopulmonary infections at 22%.⁵ However, given that our patient was found to have candidemia, it is also possible that an existing trigger in the pleural space, such as a

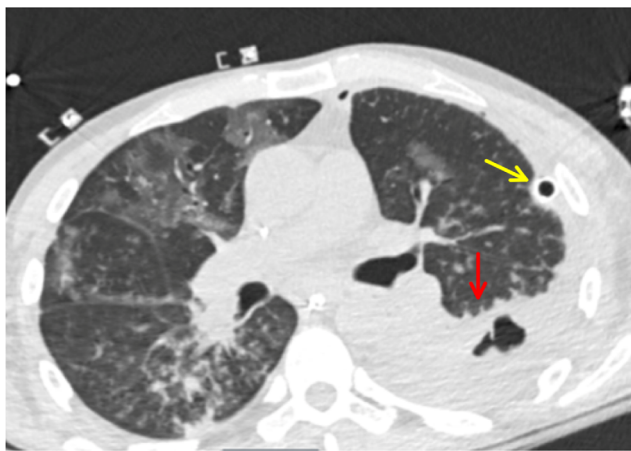


Image 2. Repeat axial computed tomography chest with contrast on day six of intensive care unit admission showing persistent large empyema reduced in size (red arrow) with resolution of mediastinal shift. Chest tube still in place (yellow arrow), and bilateral ground-glass opacities present.

hemothorax, chylothorax, or hydrothorax, became infected due a systemic infection via hematogenous spread. This is less commonly reported in the literature, with 2% of patients having concurrent candidemia in Senger et al and 27% having concurrent fungemia in Ko et al.^{4,5}

Furthermore, mortality from *C albicans* empyemas is extremely high and is more likely to occur in older patients and those in an immunocompromised state. In the retrospective analysis previously discussed by Ko et al, mortality in patients with fungal empyema was 73%.⁵ Lin et al's retrospective study of patients with *Candida* empyema thoracis found mortality to be 61.9%.¹⁰ *C albicans* empyema was most common. Patients who presented with respiratory failure, as our patient did, were associated with higher mortality. In conjunction, these two studies show that fungal empyema of any kind is associated with very high mortality.

An immunocompromised state appears to play a role in *Candida* empyemas as well. We saw this association previously in patients with tension empyemas without fungal etiologies who were immunocompromised secondary to HIV, tuberculosis, and type 1 diabetes mellitus.^{6,8} Two other case reports describe patients with *C albicans* empyemas who were immunocompromised secondary to carcinoma, specifically, esophageal carcinoma, and one of which did not involve gastrointestinal perforation.^{11,12} Fortunately, our young patient with no significant medical history other than alcohol use survived the tension empyema and was eventually discharged from the hospital. In our case, however, it is likely that the patient developed an immunocompromised state not from HIV but from chronic alcoholism and malnutrition.

CONCLUSION

Tension physiology and cardiovascular collapse are rare complications of empyema thoracis. This case report is unique in that this was a community-acquired *C albicans* infection, not associated with gastrointestinal perforation, HIV, or recent surgery, and demonstrated impending tension physiology on physical exam and imaging. Due to the high risk of mortality associated with pulmonary fungal infections, it is critical that physicians quickly identify tension physiology and keep a broad differential when choosing appropriate antibiotic treatment.

The authors attest that their institution requires neither Institutional Review Board approval, nor patient consent for publication of this case report. Documentation on file.

Address for Correspondence: Suneil Agrawal, MD, Desert Regional Medical Center, Department of Emergency Medicine, 1150 N Indian Canyon Dr., Palm Springs, CA 92262.
Email: suneil.agrawal@vituity.com

Conflicts of Interest: By the CPC-EM article submission agreement, all authors are required to disclose all affiliations, funding sources and financial or management relationships that could be perceived as potential sources of bias. The authors disclosed none.

Copyright: © 2024 Cinti et al. This is an open access article distributed in accordance with the terms of the Creative Commons Attribution (CC BY 4.0) License. See: <http://creativecommons.org/licenses/by/4.0/>

REFERENCES

- Whiteman PJ, Wilson MT, Barcay D, et al. Tension pyopneumothorax in a child: a case report. *J Emerg Med.* 2023;24(4):429–31.
- McCauley L and Dean N. Pneumonia and empyema: causal, casual or unknown. *J Thorac Dis.* 2015;7(6):992–8.
- Ishiguru T, Takayanagi N, Ikeya T, et al. Isolation of *Candida* species is an important clue for suspecting gastrointestinal tract perforation as a cause of empyema. *Intern Med.* 2010;49(18):1957–64.
- Senger SS, Thompson GR, Samanta P, et al. *Candida* empyema thoracis at two academic medical centers: new insights into treatment and outcome. *Open Forum Infect Dis.* 2021;8(4):ofaa656.
- Ko SC, Chen KY, Hsueh PR, et al. Fungal empyema thoracis. *Chest.* 2000;117(6):1672–8.
- Ooko PB, Ongondi M, White RE. Tension empyema thoracis. *Ann Afr Surg.* 2015;12(2):109–10.
- Ahern TL and Miller GA. Tension pyothorax causing cardiac arrest. *West J Emerg Med.* 2009;10(1):61.
- Bramley D, Dowd H, Muwanga C. Tension empyema as a reversible cause of cardiac arrest. *Emerg Med J.* 2005;22(12):919–20.
- Srinivasnakshatri VK, Subramani P, Venkateshwaraprasad KN, et al. A fatal case of fungal empyema due to *Candida krusei* and *Candida tropicalis*: a rare occurrence with an atypical presentation. *J Clin Diagn Res.* 2014;8(11):DD01–2.
- Lin K-H, Liu Y-M, Lin P-C, et al. Report of a 63-case series of *Candida* empyema thoracis: 9-year experience of two medical centers in central Taiwan. *J Microbiol Immuno Infect.* 2014;47(1):36–41.
- Hull JH, Kendall A, Lofts F. Fungal empyema thoracis complicating treatment of esophageal carcinoma. *Postgrad Med J.* 2004;80(941):154.
- Baradkar VP, Mathur M, Kulkarni SD, et al. Thoracic empyema due to *Candida albicans*. *Indian J Pathol Microbiol.* 2008;(512):286–8.

“K Cramps,” Recurrent Abdominal Pain in a Patient with Chronic Ketamine Use: A Case Report

Tucker Avra, DVM*

Jesus Torres, MD, MPH, MSc[†]

Kumar Felipe Vasudevan, MD[‡]

Elizabeth A. Samuels, MD, MPH, MHS[†]

*UCLA David Geffen School of Medicine, Los Angeles, California

[†]UCLA David Geffen School of Medicine, Department of Emergency Medicine, Los Angeles, California

[‡]UCLA David Geffen School of Medicine, Department of Internal Medicine, Los Angeles, California

Section Editor: Steven Walsh, MD

Submission history: Submitted February 16, 2024; Revision received April 19, 2024; Accepted April 22, 2024

Electronically published August 1, 2024

Full text available through open access at http://escholarship.org/uc/uciem_cpchem

DOI: 10.5811/cpcem.19431

Introduction: Medical and nonmedical ketamine use is increasing in the United States. This will likely lead to an increase in emergency department (ED) visits in individuals experiencing associated side effects. Physicians will need to be able to effectively recognize and manage ketamine-related complications.

Case Report: A 31-year-old male with a three-year history of inhalational, intramuscular, and intravenous nonmedical ketamine use presented to the ED twice within a week with symptoms of severe atraumatic back pain, abdominal pain, and dyspepsia. A comprehensive workup, including advanced imaging, was unrevealing for identifiable causes, and the patient was discharged with instructions for primary care follow-up for further evaluation. The patient used information shared on Reddit, an online forum and social network, to identify that the cause of his pain was related to chronic ketamine use. Subsequently, upon discontinuation of ketamine, the pain improved in 24 hours. The patient self-navigated to addiction treatment.

Conclusion: Emergency physicians should consider sequelae of chronic ketamine use as a possible cause for gastrointestinal and urologic symptoms in the ED. In addition to thorough examination and assessment for other acute medical problems, patients should be offered education, symptomatic treatment, and linkage to harm reduction and substance use disorder treatment services. [Clin Pract Cases Emerg Med. 2024;8(3)277–281.]

Keywords: *ketamine; case report; harm reduction; substance use disorder; ketamine use disorder.*

INTRODUCTION

Ketamine is becoming increasingly used in the United States (US) for a variety of mental health conditions, most notably treatment-resistant depression.¹ Intranasal esketamine (S-enantiomer of ketamine) was approved in 2019 by the US Food and Drug Administration (FDA) for treatment-resistant depression. There is also widespread off-label medical use of intravenous (IV) ketamine for other mental health conditions, including post-traumatic stress disorder, anxiety, eating disorders, and mood disorders.

Ketamine is also used recreationally for its dissociative and psychedelic effects. Over the last two decades,

self-reported, nonmedical ketamine use and exposures in the US have been gradually increasing, and seizures of illicit ketamine increased 349% from 2017 to 2022.² As rates of recreational and medical use of ketamine rise, physicians need to know how to recognize and treat side effects and complications of ketamine use. However, there is a paucity of US literature discussing how to identify and manage side effects of chronic ketamine use. Studies in the United Kingdom, Hong Kong, and Italy describe a variety of clinical presentations in people with chronic ketamine use, including urological, neurological, and gastrointestinal (GI) symptoms.^{3,4} Common presentations of these symptoms

include dysuria for urological symptoms, intoxication or hallucinations for neurological symptoms, and abdominal pain for GI symptoms. In this case report, we describe clinical presentation and management of recurrent severe abdominal pain—known informally as “K cramps” in the community of people who use ketamine—associated with long-term use.

CASE REPORT

A 31-year-old male with a history of chronic ketamine use, major depressive disorder, and chronic back pain presented to the emergency department (ED) with two days of increasingly severe back pain and chest tightness. He had a similar episode of back pain and chest tightness eight weeks prior that lasted for 10 days, with no other symptoms. He did not seek medical treatment for that episode, and the pain slowly resolved on its own. The patient took intramuscular and IV ketamine daily for eight months, with each day’s doses ranging from 1–3 grams. Before intramuscular and IV use, he had been insufflating 0.5–1 gram every day for three years.

At presentation to the ED, he was afebrile, heart rate of 77 beats per minute, blood pressure of 131/86 millimeters of mercury, and an oxygen saturation of 100% on room air. He was awake and alert and in mild distress. Physical examination revealed mild tenderness on thoracic paraspinal muscle palpation, mild tenderness to palpation in the left upper quadrant, and was otherwise unremarkable. Complete blood count, complete metabolic panel, urinalysis, electrocardiogram, troponin, and D-dimer were within normal limits. Chest radiographs were negative for pneumonia, pneumothorax, pneumomediastinum, or subcutaneous air. Given back pain and injection use, a thoracic spine magnetic resonance imaging (MRI) was performed to rule out an epidural abscess. The MRI revealed no infection, fluid collection, disc disease, fractures, or other acute abnormality that could account for his symptoms. Two sets of blood culture were negative. The patient was treated with acetaminophen and discharged with instructions to continue acetaminophen and ibuprofen at home for pain management.

The following day, the pain migrated to his upper abdomen and he developed dyspepsia. He reported taking famotidine, calcium carbonate, acetaminophen, and ibuprofen daily, with no improvement in symptoms. He continued daily ketamine use for recreational purposes and to control the pain. Every night, the pain woke him up at 4 AM. The pain, which the patient described as a deep aching/cramping sensation, was worse after eating and improved with fasting. The intensity remained severe, and he returned to the ED five days later for reevaluation.

On the second ED visit, the patient reported 9/10 abdominal pain on arrival. Again, vital signs showed no abnormalities. He was awake and alert and in moderate

CPC-EM Capsule

What do we already know about this clinical entity?

Abdominal pain is a common complication from chronic ketamine use, but underlying mechanisms are poorly understood.

What makes this presentation of disease reportable?

This is the first reported case of abdominal pain associated with ketamine use in the United States peer-reviewed literature.

What is the major learning point?

Gastrointestinal side effects should be on the differential when assessing abdominal pain in individuals who use ketamine.

How might this improve emergency medicine practice?

With increases in ketamine use, emergency physicians will need to be able to recognize and care for patients with non-neurologic complications of chronic ketamine use.

distress. Physical examination revealed right lower quadrant tenderness to palpation and mild right upper quadrant tenderness.

He was treated with 4 milligrams IV morphine and 1 liter lactated Ringer’s IV fluid. The pain improved to an 8/10 and the morphine was repeated two hours later, resulting in 6/10 abdominal pain. Computed tomography of the abdomen and pelvis with contrast was performed and revealed no evidence of an acute intra-abdominal process.

A complete abdominal ultrasound was performed, revealing a 2–3 mm adherent gallstone and a 3 mm gallbladder polyp. The patient was discharged with instructions to continue ibuprofen and acetaminophen, follow up with primary care, and return to the ED in two days if there was no improvement.

After discharge, the patient searched for his symptoms on Reddit, where he discovered several discussion forums about “K Cramps/K Pains,” Reddit users describe the pain as feeling like someone was squeezing their organs as hard as they could, pain that reaches down into the upper abdomen and creeps though the chest, and feeling like a hot knife was running through the back to the front of the stomach. He followed peer recommendations to take hot baths and discontinue ketamine. After discontinuing ketamine, the pain improved within 24 hours. He restarted recreational

ketamine 72 hours later, with initial recurrence of dyspepsia four hours after use. The following day he developed the severe abdominal pain again, which lasted for two days until he discontinued ketamine again and admitted himself to a residential substance use disorder (SUD) treatment program. The pain improved 30 hours after starting SUD treatment. The patient communicated this information to his ED treatment team during his residential treatment stay.

DISCUSSION

We report a case of recurrent abdominal pain associated with chronic high doses of ketamine, colloquially known as “K cramps.” The patient initially presented with reported back pain and chest tightness with abdominal tenderness on physical exam that progressed to severe upper abdominal pain. Diagnostics ruled out infection or other life-threatening causes of his symptoms, and the patient was discharged with instructions to continue acetaminophen and ibuprofen and return in two days if the pain had not improved. The patient was open about his ketamine use to the emergency physicians. However, outside of possible epidural abscess or infection due to at-home IV and intramuscular ketamine use, there was no consideration of the possible association of symptoms as a side effect or complication of ketamine use. In addition, there was no recommendation or counseling to reduce use, harm reduction counseling, motivational interviewing, or screening, brief intervention, and referral to treatment.

Cross-sectional studies have described the most common toxicity patterns associated with ketamine, primarily presenting with neurological, urological, and gastrointestinal symptoms.³ A review of 233 ED visits among people who use ketamine in Hong Kong showed that the most common

presenting symptoms were altered consciousness (45%), abdominal pain (21%), urinary symptoms (12%), and dizziness (12%) (Table).⁶ In addition, many forums on the internet describe and verify abdominal pain as a common symptom manifestation for patients.

“K Cramps” is mentioned only one time in peer-reviewed literature, described as “severe abdominal pains” that “can feel like severe gas pains but much worse.”⁵ In one cross-sectional study of patients seeking treatment for ketamine uropathy, 27.5% reported upper GI symptoms, including epigastric pain and recurrent vomiting.⁴ Some case reports indicate the pain is biliary or gastric in etiology. Biliary causes include cholestasis, chronic acalculous biliary colic, and common bile duct dilation.^{7,8} Abnormal liver function tests have also been associated with therapeutic ketamine use, and the mechanism is unknown.^{9,10} Poon et al evaluated GI problems among individuals with inhalational ketamine use. Among 28 patients with GI symptoms, 14 patients had endoscopies, with *Helicobacter pylori*-negative gastritis as the most common histopathological finding, followed by gastroduodenitis.⁹ The only reported treatment for ketamine-associated abdominal pain in the peer-reviewed literature is abstinence, although Reddit threads reveal numerous supportive measures, including hot showers and baths, hot beverages, and small meals, to support patients in managing their pain.

In addition to abdominal pain, emergency physicians should be familiar with the severe neurologic and urologic complications of chronic ketamine use. Patients may experience altered mental status, agitation, muscle rigidity, and dissociative emergence reactions that may include hallucinations, fear, and “out of body” experiences.³ Benzodiazepines are the primary treatment for dissociative

Table. Clinical presentations, mechanisms of action, and treatment of side effects associated with ketamine use.

System affected	Symptom(s)	Findings	Mechanism of action	Treatment
Neurologic	Intoxication	Clinical observation	NMDA-receptor antagonism	Benzodiazepines
	Altered mental status			
	Agitation			
	Muscle rigidity			
	Hallucinations			
	Dissociative emergent reactions			
Gastrointestinal	Abdominal pain	Cholestasis	Unknown	Hot baths Hot beverages Cessation of ketamine use
		Acalculous biliary colic		
		Common bile duct dilation		
		Abnormal liver function tests		
		Gastritis		
	Gastroduodenitis			
Urologic	Dysuria	Sterile urine	Direct damage to urothelial lining by ketamine and ketamine metabolites	Cessation of ketamine use
	Urinary urgency	Ulcerative cystitis		
	Hematuria	Obstructive nephropathy		

NMDA, N-methyl-D-aspartate.

emergence reactions, muscle rigidity, and agitation due to ketamine use.¹¹ The urological side effects of ketamine use are well described and reportedly affect approximately one-third of chronic ketamine users.¹² Clinical symptoms of urological toxicity are dysuria, urinary urgency, and possible progression to painful hematuria. These symptoms are associated with ulcerative cystitis secondary to ketamine and its metabolites that may progress to obstructive nephropathy and bladder fibrosis.^{13,14} Abstinence of ketamine use is described as the only treatment, with no reports of resolution of urological symptoms with persistent ketamine use (Table).¹²

There are limited case reports in the US of clinical presentations associated with ketamine toxicity. Ketamine side effects should be on the differential when assessing abdominal pain and dysuria in individuals who admit to ketamine use. However, it is a diagnosis of exclusion after other emergent or infectious causes are appropriately ruled out. While no pharmacotherapy has been approved by the FDA for ketamine use disorder, primary counseling to address symptoms should focus on reduction or cessation of ketamine use, including motivational interviewing and referral and linkage to addiction treatment. For all patients who inject drugs, emergency physicians should be familiar with and provide resources on sterile consumption equipment and safer injection technique for infection prevention. Furthermore, given the frequent presence of fentanyl adulterants in the drug supply, all patients who use drugs should be offered take-home naloxone (or naloxone prescription) and fentanyl test strips for overdose prevention.¹⁵

CONCLUSION

In this case, lack of clinician knowledge about “K cramps” contributed to delayed addiction treatment engagement and resolution of symptoms. The patient relied on advice and input from an online forum of people who use or have used ketamine to self-guide his treatment. Given that the patient reported using 1–3 grams of ketamine daily he should have been referred for addiction treatment. People who use drugs have historically, and currently, developed—and subsequently tested—strategies to reduce morbidity and mortality among themselves and their peers. This has included harm reduction strategies such as syringe services programs, naloxone distribution, drug checking initiatives, and peer support and information sharing. As nonmedical ketamine use increases in the US, emergency physicians may see more patients with symptoms and complications related to chronic use. Further work is needed to understand the etiology and treatment of GI symptoms related to ketamine use, which should include being aware of the knowledge and perspectives of people who have used ketamine and testing the strategies they have developed to treat GI symptoms.

The authors attest that their institution requires neither Institutional Review Board approval, nor patient consent for publication of this case report. Documentation on file.

Address for Correspondence: Tucker Avra, DVM, UCLA David Geffen School of Medicine, 10833 Le Conte Ave., Los Angeles, CA 90095. Email: TAvra@mednet.ucla.edu

Conflicts of Interest: By the CPC-EM article submission agreement, all authors are required to disclose all affiliations, funding sources and financial or management relationships that could be perceived as potential sources of bias. Dr. Samuels is partially supported by the Centers for Disease Control and Prevention (R01CE003516). The opinions expressed here do not reflect those of the Centers for Disease Control or Prevention.

Copyright: © 2024 Avra et al. This is an open access article distributed in accordance with the terms of the Creative Commons Attribution (CC BY 4.0) License. See: <http://creativecommons.org/licenses/by/4.0/>

REFERENCES

- Walsh Z, Mollaahmetoglu O, Rootman J, et al. Ketamine for the treatment of mental health and substance use disorders: comprehensive systematic review. *BJPsych Open*. 2021;8(1):e19.
- Palamar JJ, Wilkinson ST, Carr TH, et al. Trends in illicit ketamine seizures in the US from 2017 to 2022. *JAMA Psychiatry*. 2023;80(7):750–1.
- Pavarin RM, Marani S, Turino E. Ketamine abusers referring to emergency departments in northern Italy: a cross-sectional study. *Ann Ist Super Sanita*. 2019;55(4):338–44.
- Liu SYW, Ng S, Tam Y, et al. Clinical pattern and prevalence of upper gastrointestinal toxicity in patients abusing ketamine. *J Dig Dis*. 2017;18(9):504–10.
- Jansen KLR. A review of the nonmedical use of ketamine: use, users and consequences. *J Psychoactive Drugs*. 2000;32(4):419–33.
- Ng SH, Tse ML, Ng HW, et al. Emergency department presentation of ketamine abusers in Hong Kong: a review of 233 cases. *Hong Kong Med J*. 2010;16(1):6–11.
- Nyirenda TJ, Shirazi-Nejad A, Soliman AS. Persistent ketamine-induced cholangiopathy: an approach to management. *Cureus*. 2020;12(11):e11611.
- Lo RSC, Krishnamoorthy R, Freeman JG, et al. Cholestasis and biliary dilatation associated with chronic ketamine abuse: a case series. *Singapore Med J*. 2011;52(3):e52–5.
- Poon TL, Wong K, Chan M, et al. Upper gastrointestinal problems in inhalational ketamine abusers. *J Dig Dis*. 2010;11(2):106–10.
- Noppers IM, Niesters M, Aarts L, et al. Drug-induced liver injury following a repeated course of ketamine treatment for chronic pain in CRPS type 1 patients: a report of 3 cases. *Pain*. 2011;152(9):2173–8.

11. Zhou JY, Hamilton P, Macres S, et al. Update on ketamine. *Adv Anesth*. 2020;38:97–113.
12. Kalsi SS, Wood DM, Dargan PI. The epidemiology and patterns of acute and chronic toxicity associated with recreational ketamine use. *Emerg Health Threats J*. 2011;4(1):7107.
13. Shahani R, Streutker C, Dickson B, et al. Ketamine-associated ulcerative cystitis: a new clinical entity. *Urology*. 2007;69(5):810–2.
14. Selby NM, Anderson J, Bungay P, et al. Obstructive nephropathy and kidney injury associated with ketamine abuse. *NDT Plus*. 2008;1(5):310–2.
15. Macias-Konstantopoulos W, Heins A, Sachs C, et al. Between emergency department visits: the role of harm reduction programs in mitigating the harms associated with injection drug use. *Ann Emerg Med*. 2021;77(5):479–92.

Pupil Unleashed: Unraveling the Enigma of an Unusual Traumatic Head Injury: A Case Report

Akash Daswaney, MBBS*
Shuchi Abhishek, MBBS†
Sanjan Asanaru Kunju, MD, DNB‡
Priya Pattath Sankaran, MD§
Ahlam Abdul Rahman, MD||

*Department of Emergency Medicine, Kasturba Medical College, Manipal, Manipal Academy of Higher Education, Manipal, Karnataka, India
†Kasturba Medical College, Manipal, Manipal Academy of Higher Education, Manipal, Karnataka, India
‡Department of Emergency Medicine, Kasturba Medical College, Mangalore, Manipal Academy of Higher Education, Manipal, Karnataka, India
§Department of Radiodiagnosis and Imaging, Kasturba Medical College, Manipal, Manipal Academy of Higher Education, Manipal, Karnataka, India
||Department of Anaesthesiology, Kasturba Medical College, Mangalore, Manipal Academy of Higher Education, Manipal, Karnataka, India

Section Editor: R. Gentry Wilkerson, MD

Submission history: Submitted March 5, 2024; Revision received April 19, 2024; Accepted April 22, 2024

Electronically published August 1, 2024

Full text available through open access at http://escholarship.org/uc/uciem_cpccem

DOI: [10.5811/cpcem.20308](https://doi.org/10.5811/cpcem.20308)

Introduction: Isolated oculomotor nerve palsy after mild traumatic brain injury is unusual and prognostically significant due to unclear mechanisms and recovery challenges. We present a case of isolated oculomotor nerve palsy following minor head trauma, shedding light on this unusual occurrence.

Case Report: A 24-year-old male experienced severe vision loss and right-sided oculomotor nerve palsy after a motor vehicle collision. Initial imaging showed a hemorrhagic focus in the left posterior fossa and a contusion in the corpus callosum, yet no direct cause for the nerve palsy was found. Partial recovery was observed after 12 months.

Conclusion: This case underscores the importance of maintaining a heightened suspicion for occult intracranial findings, especially when the initial non-contrast computed tomography was inconclusive. Timely clinical assessment and appropriate radiological investigations by emergency physicians are crucial for improving the prognosis. [Clin Pract Cases Emerg Med. 2024;8(3)282–286.]

Keywords: *oculomotor nerve palsy; minor head trauma; emergency department; case report.*

INTRODUCTION

Isolated oculomotor nerve palsy following mild head injury is a rare occurrence. The mechanism required to damage the nerve is usually severe and is often associated with basilar skull fracture, orbital injury, subarachnoid hemorrhage, or neurological deficits such as loss of consciousness.¹ Injury to the nerve could be direct due to shearing force between the brainstem and supratentorial structures causing rootlet avulsion and distal fascicular damage or indirect, caused by compression, displacement, or deformity of the nerve due to a space-occupying lesion like an expanding hematoma.² It is

often described to occur following an expanding intracranial mass lesion, causing uncal herniation.³ The recovery rate, in terms of sympathetic and parasympathetic oculomotor function, following complete oculomotor nerve palsy is prolonged, often resulting in incomplete resolution. In this case, we describe a patient who developed isolated right oculomotor nerve palsy following minor closed head trauma (Glasgow Coma Scale [GCS]15). A peculiar feature was the lack of association between the magnetic resonance imaging (MRI) findings and clinical manifestations that gave us insight into the injury mechanism to the nerve.

CASE REPORT

A previously healthy 24-year-old helmeted male, motorbike rider presented to the emergency department (ED) of a tertiary care center after a road traffic accident. Unable to control the speed of his motorcycle, he skidded and fell while taking a sharp turn. On admission, he had severe pain over his right shoulder and hip, diminution of vision on the right side, inability to open his right eye, right-sided diplopia, and inability to recollect any events surrounding the incident. He denied loss of consciousness, nose bleeding, vomiting, or seizures.

At presentation, he was conscious with a GCS score of 15. The vitals recorded were heart rate 90 beats per minute, blood pressure 140/90 millimeters of mercury (mm Hg), respiratory rate 16 breaths per minute, 100% oxygen saturation on room air, and afebrile. Initial neurological examination showed that he was cooperative, alert, and well oriented to person, place, and time. There was ptosis, lateral deviation of the eyeball, and a fixed, dilated, and non-reactive pupil measuring 7 millimeters (mm) on examining the right eye. He was unable to adduct, elevate, or depress the right eyeball ([Image 1](#)). Orbital margins were intact. The conjunctiva appeared normal, the cornea was clear, the anterior chamber looked normal, and the lens was transparent. The left eye appeared normal with no limitation in extraocular movements, and the pupil was 2 mm and reactive. All other ophthalmic examinations, including measurement of intraocular pressure, revealed normal findings. Examination of other cranial nerves and systemic examination was unremarkable.

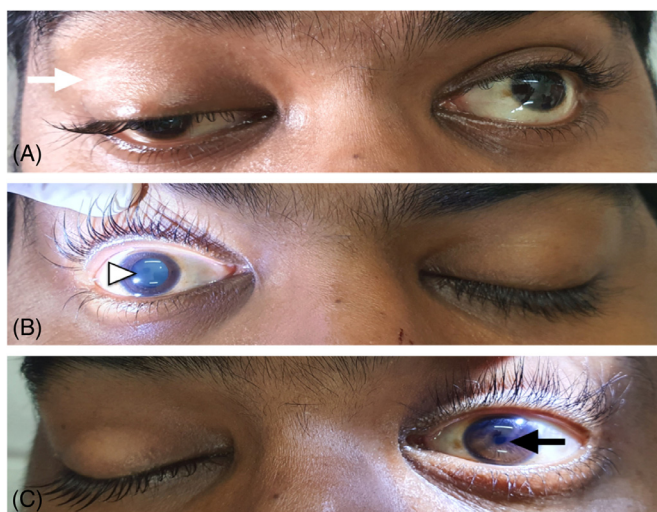

Image 1. Photograph of the patient that showed features of oculomotor nerve palsy on right side: a) ptosis (white arrow), indicative of involvement of the levator palpebrae superioris (sympathetic involvement); b) absent pupillary light reflex—“fully blown out dilated pupil” (white arrowhead) indicative of involvement of the sphincter pupillae (parasympathetic involvement); c) intact left-sided pupillary light reflex (black arrow).

CPC-EM Capsule

What do we already know about this clinical entity?

Isolated oculomotor nerve palsy following mild traumatic brain injury (TBI) is rare, and indirect injuries predominate.

What makes this presentation of disease reportable?

This case underscores isolated oculomotor nerve palsy post-mild TBI, prompting re-evaluation due to absence of focal deficits and correlating radiological findings.

What is the major learning point?

Precise imaging enhances oculomotor nerve palsy management. Thorough assessment and tailored treatment are vital in mild TBI cases.

How might this improve emergency medicine practice?

Thorough clinical assessment and imaging, precise strategies, and advocating standardized evaluation across injury severities elevate emergency medicine standards.

In this case, owing to the intricate nature of the patient's presentation characterized by isolated oculomotor nerve palsy after mild head trauma, a multidisciplinary team comprising experts from emergency medicine, neurology, ophthalmology, and radiology collaborated to deliver meticulous and comprehensive care. Laboratory examinations were normal except for an elevated white blood cell count. Radiographs of the shoulder and hip on the right side revealed a clavicle fracture and an intertrochanteric fracture of the femur, respectively. Non-contrast computed tomography (CT) of the brain and orbits revealed a well-defined hemorrhagic focus measuring $\sim 0.9 \times 2.2$ centimeters in the left posterior fossa that did not correlate to the observed clinical findings ([Image 2](#)). The patient was transferred to the intensive care unit for further monitoring, and a multitude of additional diagnostic scans were performed. Magnetic resonance imaging of the brain revealed a small hemorrhagic contusion over the body of the corpus callosum on the right side and minimal intraventricular hemorrhage in the posterior horn of the right lateral ventricle ([Image 2](#)).

An ophthalmologist recommended to instill antibiotic (to prevent a superimposed bacterial infection) and lubricant eye

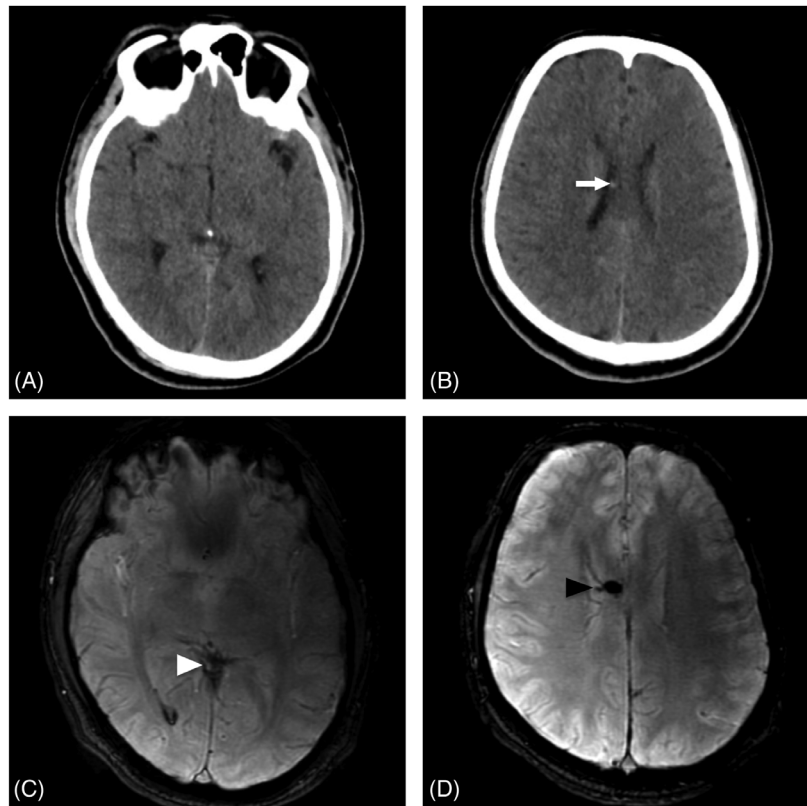


Image 2. Non-contrast computed tomography brain of a 24-year-old male (axial view): a) without any evidence of Intraparenchymal injury; b) showing tiny hemorrhagic foci (white arrow). Magnetic resonance imaging of the brain (axial 3-D susceptibility-weighted angiography) at the corresponding section showed; c) blooming foci in the posterior horn of the right lateral ventricle (white arrowhead) suggestive of minimal intraventricular hemorrhage; d) blooming foci in the body of corpus callosum on the right side (black arrowhead), measuring 6.0×8.0 mm—likely minor hemorrhagic contusion.

drops in the right eye and to do cold compresses over the right eye three times a day for one week. A repeat evaluation two days later showed the pupil size to be 5 mm, fixed, and dilated. This was an improvement compared to the 7 mm noted in the ED. In addition, the fundus examination of the

right eye was normal. He was advised to continue the same treatment and was discharged after nine days. Over the next 12 months, he experienced partial improvement in some aspects of his right oculomotor function (**Image 3**).

DISCUSSION

A patient who presents with blurring of vision, headache, diplopia, ptosis, evidence of trauma, and focal neurological deficits points an emergency physician to a potentially alarming situation. Due to this diverse presentation and the vast differential, an oculomotor nerve palsy encounter should begin with a thorough history, physical examination, and radiological investigation.

Traumatic insults (eg, traumatic brain injury [TBI], subdural hematoma, basilar skull fracture, brain herniation syndromes), autoimmune exacerbations (eg, multiple sclerosis, myasthenia gravis), vascular anomalies (eg, cerebrovascular accidents, posterior communicating artery aneurysm, basilar artery aneurysm, subarachnoid hemorrhage), neoplasms (eg, pituitary apoplexy, skull-based tumors), and infections (eg, orbital cellulitis predisposing a cavernous sinus thrombosis) represent the emergent spectrum of third cranial nerve palsies.⁴

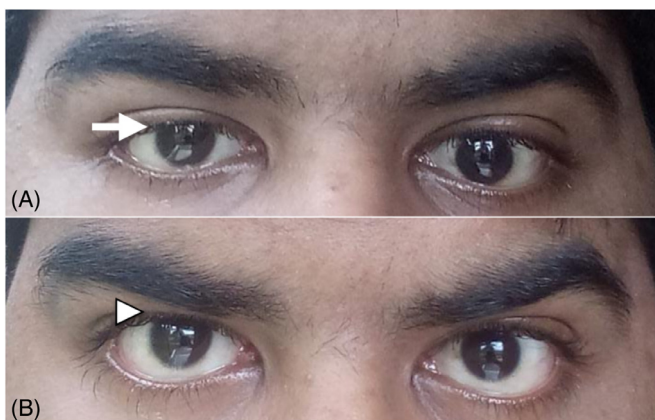

Image 3. Photograph of the same patient taken 10 months after the injury: a) persistence of mild ptosis (white arrow) in the right upper lid at rest; b) improvement of ptosis (white arrowhead) on raising the eyebrows.

Previous studies have employed “the rule of the pupil” to determine how radiological investigations are expedited in such cases.⁵ The subarachnoid location of the pupillary constrictor fibers makes them easily compressible by posterior communicating or basilar artery aneurysms. Therefore, the lack of pupil involvement would often point to a less emergent condition such as ischemia secondary to diabetes mellitus. Similarly, frequent physical examinations and liberal consultations lead to clinical clues (unilateral vs bilateral involvement, immediate vs delayed presentation, complete vs partial extraocular dysfunction, signs of basilar skull fracture, focal neurological deficits, Cushing triad) that help rule out emergent conditions.⁶

In our case, the patient presented with an isolated right-sided oculomotor nerve palsy following a mild TBI. The absence of accompanying red flags, signs, or symptoms and the lack of explanatory radiological findings make this case unique. Contrastingly, in both the Solomons et al and Memon et al studies, no isolated third nerve palsy cases were caused by mild head injury.^{3,7} Only 0.04% of traumatic oculomotor nerve palsy had been reported by a study done in 19,800 mild head injury cases. In our case, the impact was a direct right-sided frontal blow with the radiographic finding that does not correlate with the clinical presentation of the TBI.⁸

However, the exact mechanism of isolated oculomotor nerve palsy caused by mild TBI is not precise. The injury to the oculomotor nerve can occur anywhere along its course from the midbrain to orbit.⁴ Three critical parts where it can be damaged are at the site where the nerve emerges from cerebral peduncles, upon entering the cavernous sinus, and within the cavernous sinus. While indirect injuries (resulting from a disturbance in blood supply or detrimental biomechanical effects following a head injury) have been reported to have a higher incidence than direct injuries (mechanical damage), information is scarce on inconsequential third nerve palsy management in such settings. Furthermore, such patients would have delayed presentation, which was not the case in this scenario.²

According to Kaido et al, a rostrocaudal line of force is generated following a frontal blow. The direction is parallel to the third nerve and can cause traction at fixation points, causing stretching and intraneural hemorrhage.⁹ The “open V formation” of both oculomotor nerves likely prevents bilateral direct third nerve injury, and that is why it is rarely observed clinically.⁷ A shock wave generated at the time of impact can also cause damage to the third nerve.¹⁰ Diffusion tensor imaging and fiber tractography are recent imaging techniques that could assess white fiber damage and may help us in diagnosing, predicting, and prognosticating oculomotor nerve palsy.¹¹

It is uncommon to find a traumatic cause of isolated oculomotor nerve palsy without correlating radiological findings. Multipositional, high-resolution MRI with T1- and

T2-weighted images in most patients with suspected third nerve palsy may show abnormal enhancement of the oculomotor nerve because of ischemia, inflammation, or demyelinating conditions.¹ A few studies reported radiological evidence of injury to the nerve as it passes over the tough petroclinoid ligament.^{9,12} In contrast to the radiological features present in these studies, our findings on MRI included a minor hemorrhagic contusion over the body of the corpus callosum on the right side and minimal intraventricular hemorrhage in the posterior horn of the right lateral ventricle that neither revealed the cause nor location of the injury. The lack of relation between imaging abnormalities and observed clinical findings gave us an insight into the other probable mechanisms of third nerve injury in mild TBI.

Based on current evidence, the appropriate management of isolated oculomotor nerve palsy caused by mild TBI is still unclear. Our recommendation would be, to begin with, a non-contrast CT head to determine the need for immediate surgical intervention (evacuation via a craniotomy or burr hole or resection of a tumor) with or without steroids.¹ If inconclusive, a three-dimensional MRI of brain and blood vessels (including T1- and T2-weighted images, magnetic resonance angiography, and diffusion-weighted images) should be considered. In addition to this, Felix et al suggested an isotropic, high-resolution, T2-weighted constructive interference steady state (CISS) sequence and contrast-enhanced, axial and coronal T1 sequences to detect direct and indirect mechanisms of injury.¹³

Similar to the treatment rationale in patients with delayed facial nerve palsy, some studies have suggested using steroids as it reduces endoneurial edema to prevent secondary neuronal damage.^{1,14} As opposed to other cases, there was no indication for surgical treatment in our patient. Observation and follow-up are the cornerstones of management in patients with no definite intracranial findings. A similar strategy was adopted in our case: instilling antibiotic and lubricant eye drops five times a day and cold compress every eight hours. The pupil size had reduced from 7 mm to 5 mm on the fourth day, indicating slight improvement. A few reports introduce reading-related neurorehabilitation like facial massage and eye-tracking exercises and injecting botulinum toxin into the lateral rectus muscle to prevent contracture and may reduce the morbidity.^{1,2}

The prognosis of third nerve palsy is generally poor, with full recovery being uncommon, resulting in high morbidity.¹⁵ Ptosis has been reported to resolve earlier than impaired extraocular muscle movement, while the pupillary size and light reflex show the least degree of recovery following the course of events. Although the time interval to resolution varied, our review revealed that patients who had mild TBI with initial GCS scores of 13 or more experienced at least partial resolution. Our patient experienced at least partial improvement in some aspects within 12 months (*Image 3*).

CONCLUSION

The presence of fixed and dilated pupils following TBI in the emergency department has been associated with high mortality. However, we highlight the occurrence of isolated third nerve palsy in mild TBI with no other focal neurological deficits through this case. Although the appropriate management of isolated oculomotor nerve palsy caused by mild TBI is still unclear based on current evidence, a review of management and outcomes helps establish goal-oriented treatment plans and rehabilitation. Moreover, we stress the importance of a comprehensive clinical assessment. Also, we recommend radiological imaging tests regardless of injury severity to assess the cause of damage to plan for treatment and improve prognostic outcomes.

Patient consent has been obtained and filed for the publication of this case report.

Address for Correspondence: Sanjan Asanaru Kunju, MD, DNB, Department of Emergency Medicine, Kasturba Medical College, Mangalore, Manipal Academy of Higher Education, Manipal, Karnataka, India-576104, India. Email: sanjan.a@manipal.edu; sanjan.asanar@gmail.com

Conflicts of Interest: By the CPC-EM article submission agreement, all authors are required to disclose all affiliations, funding sources and financial or management relationships that could be perceived as potential sources of bias. The authors disclosed none.

Copyright: © 2024 Daswaney et al. This is an open access article distributed in accordance with the terms of the Creative Commons Attribution (CC BY 4.0) License. See: <http://creativecommons.org/licenses/by/4.0/>

REFERENCES

1. Kim E and Chang H. Isolated oculomotor nerve palsy following minor head trauma: case illustration and literature review. *J Korean Neurosurg Soc.* 2013;54(5):434.
2. Muthu P and Pritty P. Mild head injury with isolated third nerve palsy. *Emerg Med J.* 2001;18(4):310–1.
3. Memon MY and Paine K. Direct injury of the oculomotor nerve in craniocerebral trauma. *J Neurosurg.* 1971;35(4):461–4.
4. Uberti M, Hasan S, Holmes D, et al. Clinical significance of isolated third cranial nerve palsy in traumatic brain injury: a detailed description of four different mechanisms of injury through the analysis of our case series and review of the literature. *Emerg Med Int.* 2021;2021:5550371.
5. Woodruff MM and Edlow JA. Evaluation of third nerve palsy in the emergency department. *J Emerg Med.* 2008;35(3):239–46.
6. Balcer LJ, Galetta SL, Bagley LJ, et al. Localization of traumatic oculomotor nerve palsy to the midbrain exit site by magnetic resonance imaging. *Am J Ophthalmol.* 1996;122(3):437–9.
7. Solomons NB, Solomon DJ, de Villiers JC. Direct traumatic third nerve palsy. *S Afr Med J.* 1980;58(3):109–11.
8. Coello AF, Canals AG, Gonzalez JM, et al. Cranial nerve injury after minor head trauma. *J Neurosurg.* 2010;113(3):547–55.
9. Kaido T, Tanaka Y, Kanemoto Y, et al. Traumatic oculomotor nerve palsy. *J Clin Neurosci.* 2006;13(8):852–5.
10. Dhaliwal A, West AL, Trobe JD, et al. Third, fourth, and sixth cranial nerve palsies following closed head injury. *J Neuroophthalmol.* 2006;26(1):4–10.
11. Jacquesson T, Frindel C, Koccevar G, et al. Overcoming challenges of cranial nerve tractography: a targeted review. *Neurosurgery.* 2019;84(2):313–25.
12. Takeuchi S, Takasato Y, Masaoka H, et al. Isolated traumatic oculomotor nerve palsy caused by minor head trauma. *Brain Nerve Shinkei Kenkyu No Shinpo.* 2008;60(5):555–8.
13. Eisenhut F, Gerner ST, Goelitz P, et al. High-resolution magnetic resonance imaging in isolated, traumatic oculomotor nerve palsy: a case report. *Radiol Case Rep.* 2021;16(2):384–8.
14. Nakagawa Y, Toda M, Shibao S, et al. Delayed and isolated oculomotor nerve palsy following minor head trauma. *Surg Neurol Int.* 2017;8:20.
15. Chen C, Pai Y, Wang R, et al. Isolated oculomotor nerve palsy from minor head trauma. *Br J Sports Med.* 2005;39(8):e34.

Spontaneous Hemothorax from Pulmonary Intralobar Sequestration: A Case Report

Clayton Korson, MD*
Jasmine Yu, BS†
John M. Pester, DO*

*St. Luke's University Health Network Emergency Department, Bethlehem, Pennsylvania
†Rocky Vista University College of Osteopathic Medicine, Parker, Colorado

Section Editor: Lev Libet, MD

Submission history: Submitted October 19, 2023; Revision received April 18, 2024; Accepted May 3, 2024

Electronically published July 31, 2024

Full text available through open access at http://escholarship.org/uc/uciem_cpccem

DOI: [10.5811/cpcem.3259](https://doi.org/10.5811/cpcem.3259)

Introduction: Pulmonary sequestration is a rarely reported phenomenon where aberrant lung tissue exists independently from the rest of the tracheobronchial network. Complications may include hemothorax; however, there is a paucity of descriptions of this condition in the literature.

Case Report: We describe a case of a pulmonary intralobar sequestration resulting in atraumatic tension hemothorax. A 73-year-old woman presented to our facility in extremis and with complaints of acute-onset flank pain. Her evaluation was notable for a large pulmonary sequestration with a presumed, moderate-sized effusion; however, initial review did not reveal an obvious underlying cause for her symptoms. Shortly after her arrival to the emergency department (ED) she experienced a cardiac arrest. On secondary review of her computed tomographic angiography, it was determined that what was previously thought to be a pleural effusion was a large hemothorax. Following this finding, a finger thoracostomy was performed, which resulted in the immediate evacuation of hemothorax. The thoracostomy was then converted into an ED thoracotomy to assess for active hemorrhage with brief return of spontaneous circulation. Prior to proceeding with emergent operative intervention, the patient's spouse requested that all further resuscitative efforts cease, and the patient was allowed to expire. In a review of the case, it was determined that the patient suffered from cardiac arrest due to a spontaneous hemothorax secondary to a large intralobar pulmonary sequestration.

Conclusion: Pulmonary intralobar sequestration can result in spontaneous hemorrhage with fatal results. Early and correct interpretation of imaging and surgical intervention are crucial in ED management. [Clin Pract Cases Emerg Med. 2024;8(3)287–290.]

Keywords: *hemothorax; tension; thoracotomy; intralobar; sequestration.*

INTRODUCTION

Pulmonary sequestration is a rare abnormality in which non-functional lung tissue exists in isolation from the rest of the tracheobronchial tree and receives an anomalous blood supply from the systemic circulation.¹ Cough is the most commonly described presenting sign with hemoptysis noted in severe cases; however, most patients are asymptomatic.^{1,2} Intralobar pulmonary sequestration (IPS) as a cause of hemothorax is a rarely reported entity.^{3–6} We present an uncommon case of IPS complicated by atraumatic hemothorax requiring emergency thoracotomy for stabilization.

CASE REPORT

A 73-year-old woman presented to our facility with complaints of sudden onset, left-sided flank pain. The pain began shortly prior to arrival. It was sharp in nature and located in the left flank region with initial radiation of pain from her left collar bone down to her pelvis. Later, she described the pain as radiating to the midthoracic spine. Of note, she had a complex past medical history that included transcatheter aortic valve replacement, chronic heart failure with a reduced ejection fraction, left intralobar pulmonary sequestration, coronary artery disease, hypertension, and

biventricular pacemaker. She also had chronic osteomyelitis of her sternum status post washout with an antibiotic course.

On arrival, the patient appeared critically ill, diaphoretic, and clammy. Her initial vital signs included a blood pressure of 93/57 millimeters of mercury, oxygen saturation of 90% on room air, respiratory rate of 26 breaths per minute, heart rate of 60 beats per minute, and a temperature of 36.7° Celsius. On physical exam, the patient was ill-appearing, diaphoretic, and uncomfortable. She was alert and oriented and exhibited no neurological deficits. Heart sounds were regular without evidence of rubs or murmurs. Her lungs were clear to auscultation bilaterally. She had 2+ pulses in all four extremities without evidence of bruits, thrills, mottling, or cyanosis. Her capillary refill was less than two seconds. She had no evidence of ecchymoses, deformities, or rashes.

Immediately after the initial evaluation, a broad evaluation was obtained, which included an emergent computed tomography angiography (CTA) to evaluate for aortic dissection, an electrocardiogram (ECG), troponin, complete blood count, metabolic panel, lipase, and hydromorphone for pain control. Her ECG was notable for a biventricularly paced rhythm, at a rate of 103, with frequent premature ventricular complexes and without evidence of acute ischemia. The CTA was reviewed in real time (Image 1) and showed no evidence of acute aortic pathology.

She did have a large, complex, heterogeneous left intralobar mass, consistent with her known pulmonary sequestration, as well as what was presumed to be a moderate, left-sided pleural effusion. Upon reviewing reports from an outside hospital (without the ability to view the

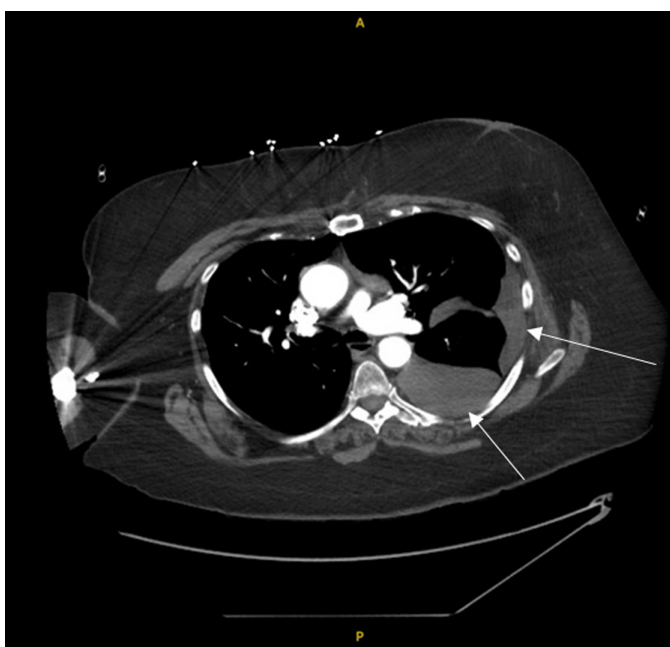

Image 1. Computed tomography angiography of the chest; axial image showing dense left pleural effusion (arrows).

CPC-EM Capsule

What do we already know about this clinical entity?

Intralobar pulmonary sequestration (IPS) occurs when lung tissue is perfused by systemic circulation rather than from pulmonary circulation.

What makes this presentation of disease reportable?

Although rare, fatal hemorrhage due to IPS can occur. The most common presentations of IPS are cough and recurrent pneumonia.

What is the major learning point?

IPS may cause rapid hemorrhage resulting in cardiovascular collapse due to tension hemothorax, or exsanguination. Early surgical intervention may be necessary.

How might this improve emergency medicine practice?

Clinicians should be aware that fatal hemorrhage can result from IPS.

Resuscitative thoracotomy can aid in decompression of tension hemothorax and hemorrhage control.

actual images), it was deemed that these findings were chronic in nature and unchanged. A delayed sequence CTA was obtained shortly after, which did not show evidence of blush on initial review (Image 2).

Her laboratory workup was notable for a white blood cell count of 12.54×10^3 cells per microliter (μL) (reference range $4.5\text{--}11 \times 10^3$ cells/ μL), hemoglobin of 13.5 grams per deciliter (g/dL) ($12.1\text{--}15.1$ g/dL), blood sugar of 161 milligrams (mg)/dL ($70\text{--}100$ mg/dL), and a high sensitivity troponin of 9 nanograms per liter (ng/L) ($0\text{--}4$ ng/L).

The patient continued to deteriorate, becoming progressively more diaphoretic. Repeat ECG showed a biventricularly paced rhythm, rate of 121, without evidence of acute ischemia. Given her worsening status, cardiology was consulted for possible acute coronary syndrome (ACS) that may have been masked by her ventricularly paced rhythm. While cardiology was in the process of obtaining a transthoracic echocardiogram to assess for regional wall movement abnormalities, the patient went into cardiac arrest. Cardiopulmonary resuscitation was started using standard Advanced Cardiac Life Support (ACLS) protocol. Due to a large volume of emesis, esophageal

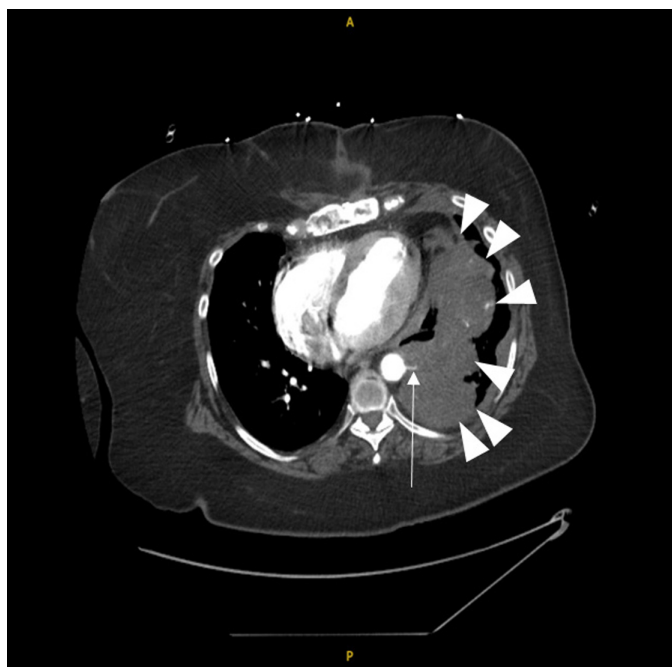


Image 2. Hyperdensity indicating hemorrhage (triangles) supplied by an artery from a small aortic branch (arrow).

diversion intubation was performed, followed by endotracheal intubation.

The ACLS was continued for approximately 20 minutes without return of spontaneous circulation. Systemic thrombolytics were considered for presumed ACS. Prior to

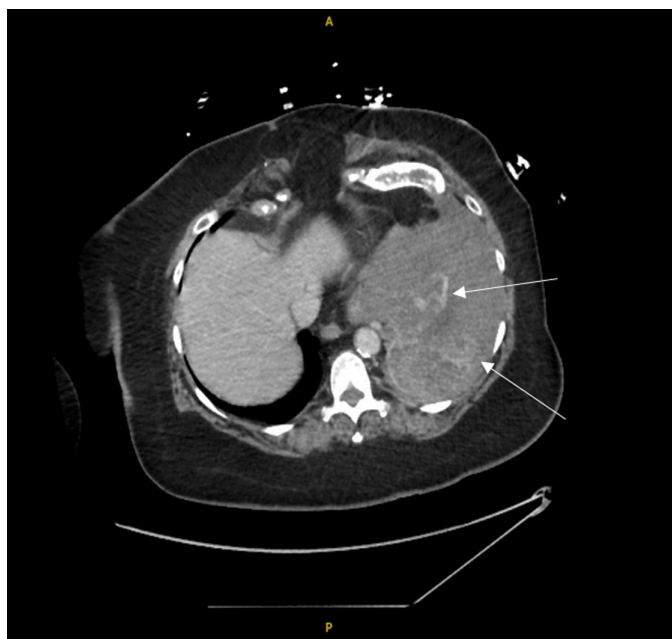

Image 3. Computed tomography angiography axial image. Delayed sequence imaging demonstrating swirling contrast within the hemothorax, consistent with active hemorrhage (arrows).

administration of thrombolytic, however, her CTA was reviewed again, and a blush was noted. What was previously thought to be a pleural effusion was actually a large hemothorax with active hemorrhage (Image 3). Given this finding, a finger thoracostomy was performed on the left side, which resulted in the immediate expulsion of a large volume of blood. This procedure was then converted into an emergent thoracotomy to assess for source of hemorrhage and resulted in the evacuation of approximately 500 milliliters of additional blood. A massive transfusion protocol was commenced, acute care surgery arrived at the bedside, and return of spontaneous circulation was achieved.

Prior to proceeding with further surgical intervention, goals of care were discussed with the patient's husband who wished to cease all further aggressive management. The patient expired thereafter.

In review, it was determined that the patient suffered from cardiac arrest due to a spontaneous, atraumatic hemothorax secondary to a large, hemorrhagic IPS.

DISCUSSION

Pulmonary sequestration is a rare condition in which a segment of abnormal lung tissue exists with no identifiable tracheobronchial communication and receives its arterial blood supply from the systemic circulation. Pulmonary sequestration is further divided into extralobar and intralobar sequestration. In extralobar pulmonary sequestration, the lung mass is enclosed in its own pleural sac, whereas in IPS the mass lies within the visceral pleura.¹

Literature review of IPS case reports describe cough and recurrent respiratory infection as the most common presenting symptoms.² In only a few published cases has hemothorax been reported as a complication of IPS, likely caused by spontaneous rupture of an artery feeding the anomalous pulmonary tissue.³⁻⁶ The literature supports the use of computed tomographic angiography for the diagnosis of pulmonary sequestration and demonstration of the arterial supply. Per prior reports, the most common site of intrapulmonary type sequestration is the left lower lobe of the lung, which is consistent with our patient's findings.⁷ Of the reported cases that describe hemothorax as a rare presentation of IPS, two describe the use of emergency thoracotomy to find the origin of bleeding and to achieve hemostasis in emergent cases with patients presenting with massive intrapulmonary hemorrhage and in shock.^{3,4} Following initial stabilization measures, all studies describing IPS complications advocate for resection of the sequestered tissue for prevention of future major medical complications.

CONCLUSION

This case report describes a rare presentation of intralobar pulmonary sequestration with spontaneous hemothorax resulting in cardiac arrest. Early diagnosis and resection of

the abnormal lung tissue should be considered in all patients with findings of pulmonary sequestration. Our case also adds to the literature a rare instance where emergency department thoracotomy should be considered to aid in the stabilization of a medical patient.

The authors attest that their institution requires neither Institutional Review Board approval, nor patient consent for publication of this case report. Documentation on file.

Address for Correspondence: John Pester, DO, St. Luke's University Health Network, Emergency Medicine Residency, 801 Ostrum Street, Bethlehem, PA 18015. Email: Jonathan.pesther@sluhn.org

Conflicts of Interest: By the *CPC-EM* article submission agreement, all authors are required to disclose all affiliations, funding sources and financial or management relationships that could be perceived as potential sources of bias. The authors disclosed none.

Copyright: © 2024 Korson et al. This is an open access article distributed in accordance with the terms of the Creative Commons Attribution (CC BY 4.0) License. See: <http://creativecommons.org/licenses/by/4.0/>

REFERENCES

1. Chakraborty RK, Modi P, Sharma S. Pulmonary sequestration. [Updated 2023 Jul 24]. In *StatPearls* [Internet]. Treasure Island (FL): StatPearls Publishing. 2024. Available at: <https://www.ncbi.nlm.nih.gov/books/NBK532314/>. Accessed July 2, 2024.
2. Yoshitake S, Hayashi H, Osada H, et al. Emergency laparotomy helped the resection of an intralobar pulmonary sequestration with haemorrhagic shock. *Eur J Cardiothorac Surg*. 2013;43(1):190–2.
3. Hofman FN, Pasker HG, Speekenbrink RG. Hemoptysis and massive hemothorax as presentation of intralobar sequestration. *Ann Thorac Surg*. 2005;80(6):2343–4.
4. Iliás L, Pálffy G, Szónyi P, et al. Massive haemothorax caused by intralobar pulmonary sequestration. *Orv Hetil*. 1996;137(23):1263–5.
5. Zapatero J, Baamonde C, Bellán JM, et al. Hemothorax as rare presentation of intralobar pulmonary sequestration. *Scand J Thorac Cardiovasc Surg*. 1983;17(2):177–9.
6. Arsalane A, Parrot A, Assouad J, et al. Spontaneous hemothorax: a rare but serious complication of intralobular pulmonary sequestration. *Rev Pneumol Clin*. 2006;62(1):30–3.
7. Savic B, Birtel FJ, Tholen W, et al. Lung sequestration: report of seven cases and review of 540 published cases. *Thorax*. 1979;34(1):96–101.

Median Nerve Measurement and Steroid Injection for Carpal Tunnel Syndrome: A Case Report

Gregory Oliva, DO*
Joseph McShannic, MD*
Yonghoon Lee, MD*
Michael Shalaby, MD†

*Mount Sinai Medical Center Miami Beach, Department of Emergency Medicine, Miami Beach, Florida

†Herbert Wertheim College of Medicine at Florida International University, Department of Emergency Medicine and Critical Care, Miami Beach, Florida

Section Editor: R. Gentry Wilkerson, MD

Submission history: Submitted January 11, 2024; Revision received May 6, 2024; Accepted May 6, 2024

Electronically published July 11, 2024

Full text available through open access at http://escholarship.org/uc/uciem_cpem

DOI: [10.5811/cpem.7194](https://doi.org/10.5811/cpem.7194)

Introduction: Carpal tunnel syndrome is an entrapment neuropathy that affects 3% of adults in the United States. The current techniques used for diagnosis have limited specificity/sensitivity, and the techniques used for treatment have limited efficacy.

Case Report: A 34-year-old female presented to the emergency department with two months of worsening painful paresthesias in her right thenar eminence. Ultrasound was performed showing a median nerve area of 20.4 square millimeters within the carpal tunnel. Median nerve block was performed within the carpal tunnel causing complete resolution of her pain.

Conclusion: Emergency physicians skilled in point-of-care ultrasound and needle-guided procedures can diagnose and treat carpal tunnel syndrome. [Clin Pract Cases Emerg Med. 2024;8(3)291–294.]

Keywords: *carpal tunnel syndrome; median nerve; ultrasound; steroid injection; case report.*

INTRODUCTION

Carpal tunnel syndrome (CTS) is a common entrapment neuropathy caused by compression of the median nerve as it travels through the wrist within the carpal tunnel. Carpal tunnel syndrome accounts for 90% of all entrapment neuropathies and affects 3% of adults in the United States.¹ Carpal tunnel syndrome induces pain, numbness, and paresthesias along the palmar aspects of the first, second, third, and lateral portion of the fourth digit, as well as the thenar eminence. In advanced disease, symptoms progress to weakness of thumb abduction, decreased grip strength, and thenar atrophy.¹ While the diagnosis is clinical and is supported by findings such as Tinel sign (percussion of proximal wrist causing paresthesias) and Phalen sign (holding wrists in 60 degrees of flexion eliciting symptoms), physical exam maneuvers have a low sensitivity and specificity.² The gold standard for confirmation of the diagnosis is a nerve conduction study.³

Ultrasound (US) measurements of the median nerve can be used to assess symptomatic patients, revealing an enlarged

nerve area in individuals with CTS.⁴ Numerous strategies have been employed to alleviate the symptoms of CTS. These include diuretics, pyridoxine, non-steroidal anti-inflammatory drugs, yoga, steroid injections, US therapy, and acupuncture.⁵ These techniques can decrease inflammation and provide some relief but do not always cause complete resolution of pain. Herein, we describe a patient with new-onset CTS whose treatment in the emergency department (ED) with combined local anesthetic and corticosteroid injection provided complete relief of symptoms. This is the first case report detailing the utilization of ultrasound-guided median nerve block in the ED setting.

CASE REPORT

A 34-year-old female presented to the ED with two months of worsening painful paresthesias in her right thenar eminence. On physical exam, positive Tinel and Phalen signs were noted, along with reduced sensation of the palmar aspect of her first three digits. Muscular strength was 5/5 in bilateral upper extremities. The differential diagnoses

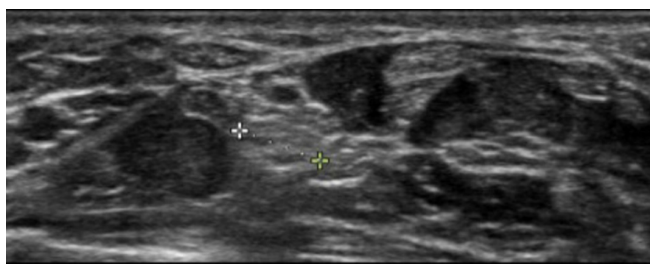


Image 1. Enlarged diameter of the median nerve within the carpal tunnel, measuring 5.1 millimeters, which corresponds to an area of 20.4 square millimeters.

encompassed cervical radiculopathy, thoracic outlet syndrome, pronator teres syndrome, and anterior interosseous neuropathy. Considering the symptom location and absence of sensory alterations, weakness, or tenderness proximal to the wrist, the leading explanation was compression of the median nerve within the carpal tunnel. Ultrasound was performed showing a median nerve area of 20.4 square millimeters (mm^2) (reference range 8.5–10 mm^2) within the carpal tunnel (**Image 1**).

The patient consented to a median nerve block, which was performed within the carpal tunnel with 10 milliliters (mL) of 0.25% bupivacaine and 1 mL of 40 milligrams (mg)/mL triamcinolone. After the procedure, the patient developed complete resolution of her pain. She was placed in a wrist splint and discharged home with information for hand surgery follow-up. Despite numerous phone calls, the patient was unfortunately lost to follow up.

DISCUSSION

The median nerve arises from the anterolateral and anteromedial cords of the brachial plexus and comprises the sixth cervical to first thoracic nerve roots.⁶ Distally, the nerve courses deep to the flexor retinaculum and enters the carpal tunnel, traveling in an anterior and lateral direction alongside the tendons of the flexor digitorum superficialis.⁶ It is at this point that entrapment is most common. Beyond the carpal tunnel, it divides into a motor branch that serves the thenar compartment, as well as the first and second lumbricals, and a sensory branch that divides into four palmar branches for the fingers.⁶ To perform a median nerve block within the carpal tunnel, the nerve is first identified between the flexor digitorum superficialis and flexor digitorum profundus, and then traced distally to its position within the carpal tunnel.⁷ Once at this position, the nerve can be identified medial to the flexor carpi radialis and lateral to the palmaris longus (**Image 2**).

An in-plane approach is used to advance the needle before instilling local anesthetic around the nerve. Usually, ≤ 5 mL local anesthetic suffices for median nerve blockade. Local anesthetics such as bupivacaine and ropivacaine provide longer pain relief and are, therefore, preferred over

CPC-EM Capsule

What do we already know about this clinical entity?

Carpal tunnel syndrome (CTS) is prevalent, affecting 3% of adults in the United States, but diagnosis and treatment methods are limited in efficacy.

What makes this presentation of disease reportable?

Median nerve block in the emergency department (ED) efficiently aids in diagnosis and relieves newly diagnosed CTS.

What is the major learning point?

Emergency physicians skilled in point-of-care ultrasound and needle-guided procedures can diagnose and treat CTS effectively.

How might this improve emergency medicine practice?

Early ED diagnosis allows for prompt intervention, potentially improving patient outcomes.

lidocaine.⁷ While physicians in other specialties have previously employed this procedure, this case report represents the first documentation of ultrasound-guided

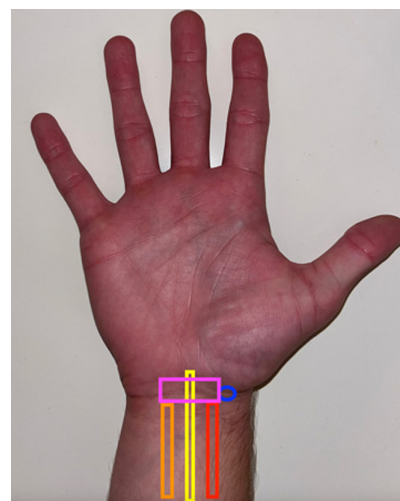


Image 2. The external anatomy of the wrist for optimal ultrasound-guided needle placement is illustrated as follows: the blue circle denotes the needle insertion site, while the pink box represents the placement of the ultrasound probe. Additionally, the red, yellow, and orange boxes indicate the positions of the flexor carpi radialis, median nerve, and palmaris longus, respectively.

median nerve block being used in an ED setting. In general, median nerve area of greater than 8.5–10 mm² at the mid channel is associated with CTS.⁴ In our case, we calculated the median nerve area to be 20.4 mm². With these findings, we deduced that the nerve was exhibiting signs of inflammation.

Carpal tunnel syndrome is a painful condition affecting >8 million people yearly.⁸ Carpal tunnel release is the second most common type of musculoskeletal surgery with over 230,000 cases annually.⁸ While the procedure can be effective at relieving pain, it is invasive and costly, and results are poorer for patients with longstanding disease.⁹ Patients with operative intervention earlier in the course of the disease have been shown to have better outcomes.⁹ To refer patients for treatment in a timely fashion, the diagnosis must be timely. While diagnosis is usually made clinically, calculation of the median nerve cross-sectional area and nerve blockade can provide a definitive diagnosis and timely analgesia. Furthermore, instilling corticosteroid within the sheath can provide prolonged analgesia. The introduction of dexamethasone has been observed to result in prolonged nerve block durations, reduced opioid requirements, and an extended time until the next analgesic dose is needed.^{10–12} When deciding whether corticosteroids should accompany local anesthetics for nerve blocks, the choice should hinge on the desired duration of the blockade and considerations of contraindications. According to the American Society of Regional Anesthesia and Pain Medicine, dexamethasone is among the frequently used agents for extending analgesia. However, official recommendations are impeded by the low quality and clinical diversity of published trials.¹³

Ultrasound guidance facilitates median nerve blockade by allowing emergency physicians to feasibly and precisely target the median nerve within the carpal tunnel. Therefore, instead of performing a median nerve block in the usual mid-forearm location, we opted to instill anesthetic around the nerve within the carpal tunnel to include a corticosteroid at the site of compression. Moreover, injection of anesthetic directly into the carpal tunnel has been shown to provide improved symptom severity and function.¹⁴

Nerve blocks may entail various complications, such as neuronal damage, bleeding, and local anesthetic systemic toxicity (LAST) syndrome.¹⁵ Peripheral nerve injury is an infrequent outcome, with an estimated incidence ranging from 0.5–1.0%.¹⁵ Although nerve injury encompasses a spectrum of issues, permanent nerve damage occurs in approximately 1.5 cases per 10,000.¹⁵ Inadvertent vascular puncture poses risks of bleeding with hematoma formation or, if the anesthetic enters the vessel, triggering LAST syndrome.¹⁵ Symptoms of LAST syndrome can range from mild, such as circumoral numbness, metallic taste, and auditory changes, to severe, including seizures, coma, respiratory arrest, hypotension, ventricular arrhythmias,

and cardiac arrest.¹⁵ Recent studies suggest that using US guidance reduces the likelihood of inadvertent vascular puncture, thereby mitigating these complications.¹⁵

While dexamethasone is commonly employed to extend analgesia's duration in peripheral nerve blocks, its usage is cautioned against in diabetic patients due to the associated hyperglycemic response.¹⁶ Absolute contraindications for corticosteroid injection include local infection, sepsis, and bacteremia, as they pose risks of infection dissemination. Relative contraindications include juxta-articular osteoporosis due to concerns about exacerbating bone density loss, coagulopathy, and injections three times annually or within a six-week period.¹⁷

CONCLUSION

Median nerve block is an effective and efficient way to both diagnose and provide relief of newly diagnosed carpal tunnel syndrome that presents to the ED, and emergency physicians should consider using it within their practice for such.

The authors attest that their institution requires neither Institutional Review Board approval, nor patient consent for publication of this case report. Documentation on file.

Address for Correspondence: Gregory Oliva, DO, Mount Sinai Medical Center Miami Beach, Department of Emergency Medicine, 4300 Alton Rd., Miami Beach, FL 33140. Email: gregory.oliva@msmc.com

Conflicts of Interest: By the CPC-EM article submission agreement, all authors are required to disclose all affiliations, funding sources and financial or management relationships that could be perceived as potential sources of bias. The authors disclosed none.

Copyright: © 2024 Oliva et al. This is an open access article distributed in accordance with the terms of the Creative Commons Attribution (CC BY 4.0) License. See: <http://creativecommons.org/licenses/by/4.0/>

REFERENCES

- Sevy JO, Sina RE, Varacallo M. Carpal Tunnel Syndrome. [Updated 2023 Oct 29]. In: *StatPearls* [Internet]. Treasure Island (FL): StatPearls Publishing; 2024. Available at: <https://www.ncbi.nlm.nih.gov/books/NBK448179/>. Accessed April 14, 2024.
- Arab AA, Elmaghrabi MM, Eltantawy MH. Carpal tunnel syndrome: evaluation of its provocative clinical tests. *Egypt J Neurosurg*. 2018;33(14):14.
- Rosario NB and De Jesus O. Electrodiagnostic Evaluation of Carpal Tunnel Syndrome. [Updated 2023 Aug 23]. In: *StatPearls* [Internet]. Treasure Island (FL): StatPearls Publishing; 2024. Available at: <https://www.ncbi.nlm.nih.gov/books/NBK562235/>. Accessed April 14, 2024.

4. Cartwright MS, Hobson-Webb LD, Boon AJ, et al. Evidence-based guideline: neuromuscular ultrasound for the diagnosis of carpal tunnel syndrome. *Muscle Nerve*. 2012;46(2):287–93.
5. Ebenbichler GR, Resch KL, Nicolakis P, et al. Ultrasound treatment for treating the carpal tunnel syndrome: randomised “sham” controlled trial. *Br Med J*. 1998;316(7133):731–5.
6. Meyer P, Lintingre PF, Pesquer L, et al. The median nerve at the carpal tunnel . . . and elsewhere. *J Belg Soc Radiol*. 2018;102(1):17.
7. Pester JM, Bechmann S, Varacallo M. Median Nerve Block Techniques. [Updated 2023 Aug 4]. In: *StatPearls* [Internet]. Treasure Island (FL): StatPearls Publishing; 2024. Available at: <https://www.ncbi.nlm.nih.gov/books/NBK459141/>. Accessed April 14, 2024.
8. American Academy of Orthopedic Surgeons. 11 astounding carpal tunnel statistics. 2019. Available at: <https://www.orthoarlington.com/contents/patient-info/conditions-procedures/11-astounding-carpal-tunnel-statistics>. Accessed November 16, 2023.
9. Masud M, Rashid M, Malik SA, et al. Does the duration and severity of symptoms have an impact on relief of symptoms after carpal tunnel release? *J Brachial Plex Peripher Nerve Inj*. 2019;14(1):e1–8.
10. Brusich KT. Corticosteroids as adjuvants for peripheral nerve blocks: a mini review. *Int J Anaesth Res*. 2018;1(1):14–7.
11. Rasmussen SB, Saied NN, Bowers C, et al. Duration of upper and lower extremity peripheral nerve blockade is prolonged with dexamethasone when added to ropivacaine: a retrospective database analysis. *Pain Med*. 2013;14(8):1239–47.
12. Giannini F, Passero S, Cioni R, et al. Electrophysiologic evaluation of local steroid injection in carpal tunnel syndrome. *Arch Phys Med Rehabil*. 1991;72(10):738–42.
13. Ranganath YS, Seering MS, Marian AA. Curb your enthusiasm: local anesthetic adjuvants for peripheral nerve blocks. 2020. Available at: <https://www.asra.com/news-publications/asra-newsletter/curb-your-enthusiasm/asra-news/2020/11/01/curb-your-enthusiasm-local-anesthetic-adjuvants-for-peripheral-nerve-blocks>. Accessed April 14, 2024.
14. Karimzadeh A, Esmaily H, Raeissadat SA, et al. Comparison of the effect of intracarpal injection of ketorolac with triamcinolone in carpal tunnel syndrome: A randomized controlled trial. *Ann Pharmacother*. 2024;58(3):205–13.
15. Jeng CL, Torriillo TM, Rosenblatt MA. Complications of peripheral nerve blocks. *Br J Anaesth*. 2010;105(1):i97–107.
16. Williams BA, Murinson BB, Grable BR, et al. Future considerations for pharmacologic adjuvants in single-injection peripheral nerve blocks for patients with diabetes mellitus. *Reg Anesth Pain Med*. 2009;34(5):445–57.
17. Simurina T, Mraovic B, Zupcic M. Local anesthetics and steroids: contraindications and complications – Clinical update. *Acta Clinica Croatica*. 2019;58(1):53–61.

Bezold Abscess in a Case of Eosinophilic Otitis Media

Satoshi Tsuruta, MD
Takashi Fujiwara, MD, PhD

Kurashiki Central Hospital, Department of Otolaryngology, Kurashiki city,
Okayama, Japan

Section Editor: Manish Amin, MD

Submission history: Submitted September 29, 2023; Revision received May 14, 2023; Accepted May 16, 2023

Electronically published June 6, 2024

Full text available through open access at http://escholarship.org/uc/uciem_cpem

DOI: 10.5811/cpem.21313

Case Presentation: A 57-year-old man with a history of bronchial asthma and eosinophilic sinusitis presented to the emergency department with an exacerbation of otitis media. His primary complaints were otopyorrhea, headache, and neck pain with redness. Contrast-enhanced computed tomography revealed a posterior neck abscess contiguous with the mastoid process. The patient underwent mastoidectomy and received antimicrobial therapy. Eosinophilic granulation tissue in the middle ear obstructed the middle ear aditus and directed the inflammatory process toward the mastoid tip.

Discussion: Bezold abscess is a rare extracranial complication of acute mastoiditis. Therefore, clinicians should consider neck pain with redness as an important physical sign that suggests Bezold abscess in patients with otitis media. [Clin Pract Cases Emerg Med. 2024;8(3)295–297.]

Keywords: Mastoiditis; otitis media; abscess; eosinophilic otitis media.

CASE PRESENTATION

A 57-year-old man with a history of bronchial asthma and eosinophilic sinusitis presented to the emergency department with an exacerbation of otitis media. He had previously received treatment with tympanostomy and antimicrobial therapy for acute otitis media of his right ear, but his condition did not improve. He experienced otopyorrhea (Image 1), worsening pain in his right ear and neck with redness, headache, and impaired consciousness. Contrast-enhanced computed tomography revealed bilateral otitis media, thrombosis from the right internal jugular vein to the sigmoid sinus, and a posterior neck abscess contiguous with the mastoid process on the right side (Image 2).

The patient underwent mastoidectomy and was treated with antimicrobial and antithrombotic therapies. During surgery, it was found that the right middle ear was filled with eosinophilic granulation tissue, with the formation of a path between the mastoid part of the temporal bone and the posterior neck (Image 3). Intraoperative intratympanic steroid administration eliminated the granulation tissue a few days after the surgery. The patient was treated with antimicrobial therapy for six weeks. He was discharged with higher functional impairment and gait disturbance.

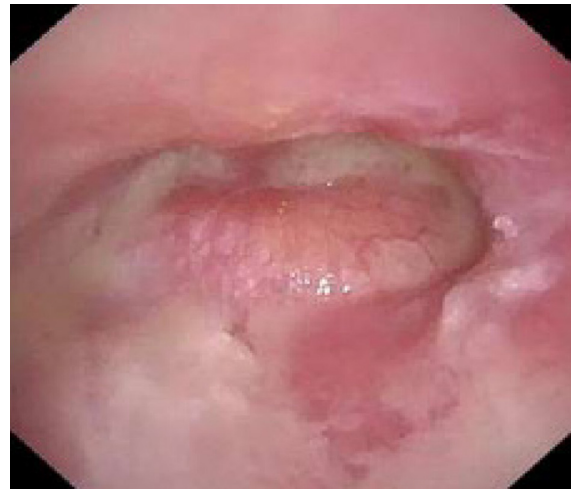

Image 1. Otoscopic view of the middle ear demonstrating an erythematous, bulging tympanic membrane with purulent effusion.

However, he continued his rehabilitation and could drive two months after discharge. Furthermore, the patient successfully reintegrated into society and was found to be in good health one year later.

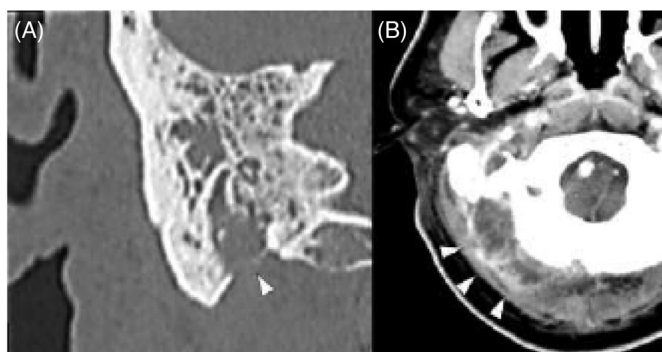

Image 2. (A) Computed tomography (CT) of the mastoid with intravenous (IV) contrast showing mastoid process perforation (arrowhead); (B) CT of the neck with IV contrast demonstrating a posterior neck abscess (arrowheads).

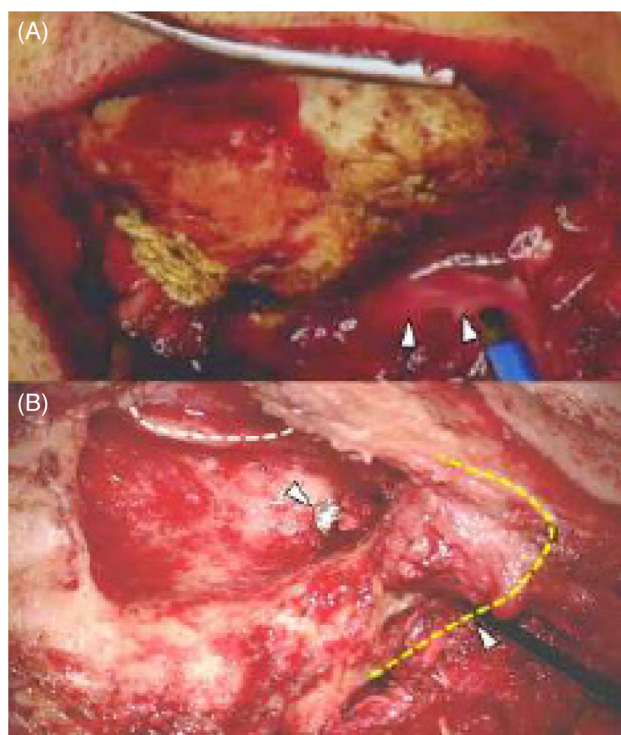


Image 3. Intraoperative images during mastoidectomy. (A) Before mastoidectomy: Drainage of pus from the mastoid process was observed (arrowheads). (B) After mastoidectomy: The dashed white line represents the posterior wall of the ear canal, whereas the dashed yellow line indicates the mastoid tip. A path between the mastoid antrum and neck is visible (arrowhead), through which surgical instruments could be inserted from the neck to the mastoid antrum.

DISCUSSION

Bezold abscess, a rare extracranial complication of acute mastoiditis, occurs when an infection erodes through the lateral mastoid cortex medially toward the neck. Although the incidence of Bezold abscess has decreased with the development of antimicrobial agents and improved nutrition,

CPC-EM Capsule

What do we already know about this clinical entity?

Patients with middle ear disease, particularly cholesteatoma, are at high risk of developing Bezold abscess.

What is the major impact of the image(s)?

This is the first reported case of Bezold abscess due to eosinophilic otitis media.

How might this improve emergency medicine practice?

Emergency physicians should recognize that eosinophilic otitis media can cause the condition.

individuals with middle ear disease, particularly cholesteatoma, remain at a higher risk of developing this condition. The presence of middle ear disease (eg, cholesteatoma) can obstruct the middle ear aditus and direct the inflammatory process toward the mastoid tip. In the present case, Bezold abscess occurred despite the administration of appropriate antimicrobial agents and tympanostomy.

The patient had a history of bronchial asthma and eosinophilic sinusitis, leading to the diagnosis of eosinophilic otitis media. Acute otitis media exacerbates the development of eosinophilic granulation tissue in the middle ear, which can obstruct the middle ear aditus, leading to neck abscess formation. To our knowledge, this is the first case of Bezold abscess due to eosinophilic otitis media. Thus, emergency physicians should recognize that eosinophilic otitis media can cause Bezold abscess.

The authors attest that their institution requires neither Institutional Review Board approval. Patient consent has been obtained for publication of this case report. Documentation on file.

Address for Correspondence: Takashi Fujiwara, MD, Kurashiki Central Hospital, Department of Otolaryngology, Miwa 1-1-1, Kurashiki city, Okayama prefecture, 710-8602, Japan.
Email: t.fujiwarabi@gmail.com.

Conflicts of Interest: By the CPC-EM article submission agreement, all authors are required to disclose all affiliations, funding sources and financial or management relationships that could be perceived as potential sources of bias. The authors disclosed none.

Copyright: © 2024 Tsuruta et al. This is an open access article distributed in accordance with the terms of the Creative Commons Attribution (CC BY 4.0) License. See: <http://creativecommons.org/licenses/by/4.0/>

REFERENCES

1. Alkhalidi AS, Alwabili M, Albilasi T, et al. Bezold's abscess: a case report and review of cases over 20 years. *Cureus*. 2022;14(1):e21533.
2. Uchida Y, Ueda H, Nakashima T. Bezold's abscess arising with recurrent cholesteatoma 20 years after the first surgery: with a review of the 18 cases published in Japan since 1960. *Auris Nasus Larynx*. 2002;29(4):375–8.

Point-of-care Ultrasound Diagnosed Intraocular Breast Metastasis

Hamzah M. Yusuf, MD
Timothy Batchelor, MD
Nicholas Ashenburg, MD

Stanford University, Department of Emergency Medicine, Palo Alto, California

Section Editor: Shadi Lahham, MD

Submission history: Submitted September 25, 2023; Revision received January 22, 2024; Accepted January 29, 2024

Electronically published May 14, 2024

Full text available through open access at http://escholarship.org/uc/uciem_cpchem

DOI: 10.5811/cpcem.1686

Case Presentation: A 60-year-old female presented to the emergency department with unilateral eye pain and vision loss. Point-of-care ultrasound (POCUS) was performed, which demonstrated ocular metastatic lesions of breast cancer.

Discussion: Ocular metastasis is rare, clinically challenging, and may present with a wide range of ophthalmic symptoms. However, POCUS may safely and rapidly identify metastatic lesions to direct further care. [Clin Pract Cases Emerg Med. 2024;8(3)298–299.]

Keywords: POCUS; ocular ultrasound; emergency medicine; breast cancer; metastasis.

CASE PRESENTATION

A 60-year-old female with a history of recently diagnosed breast cancer with liver, lung, and bone metastases pending biopsy results presented to the emergency department with one day of progressive left eye pain, blurry vision, and central scotoma. She denied myodesopsia, photopsia, or recent eye trauma. Fluorescein staining was unremarkable. Her visual acuity was 20/30 bilaterally. She had intraocular pressures of 19 millimeters of mercury (mm Hg) bilaterally (reference range 10–20 mm Hg), and equally round and reactive pupils. She had full extraocular movement. Her slit lamp exam was notable for mild, left eye conjunctival injection.

Using a linear ultrasound probe, we performed point-of-care ultrasound (POCUS) to obtain sagittal and transverse views evaluating the anterior chamber, posterior chamber, retina, lens location, and overall structure of the left eye. Two posterior masses were identified over the optic nerve (Image).

Ophthalmology was consulted and, on dilated fundus exam, identified two, pale yellow choroidal lesions in close proximity to the optic nerve and optic nerve tilting, with strong concern for leptomeningeal involvement. The patient was then admitted to the hospital for enhanced imaging and facilitation of care.

An inpatient magnetic resonance imaging study of the brain with and without contrast demonstrated hypointense nodularity in several areas within the globe, with several,

scattered, small enhancing cerebral lesions. She was started on corticosteroids and offered whole brain vs stereotactic body radiation therapy, as well as external beam therapy for intraocular tumors. She was subsequently discharged for outpatient radiology-oncology care.

DISCUSSION

Ocular metastasis represents a rare and clinically challenging manifestation of advanced cancer. Breast cancer remains a more prevalent source of ocular metastasis due to its high incidence, aggressive nature, and propensity for systemic dissemination. The ocular structures, including the choroid, retina, iris, and optic nerve, serve as potential sites for secondary tumor growth, leading to visual impairment and significant morbidity.¹ A POCUS exam may show a hypoechoic dome or plateau-shaped lesion typically over the choroid with minimal internal vascularization.²

Clinically, ocular metastasis can manifest as a wide range of ophthalmic symptoms, including blurred vision, pain, photophobia, metamorphopsia, or it can be asymptomatic.^{1,3} Estimating the incidence of ophthalmic metastasis has proven challenging as asymptomatic manifestations may go unnoticed, but the prevalence of ocular metastasis in metastatic breast cancer has been estimated between 9.7–30%.⁴ Differential diagnoses may

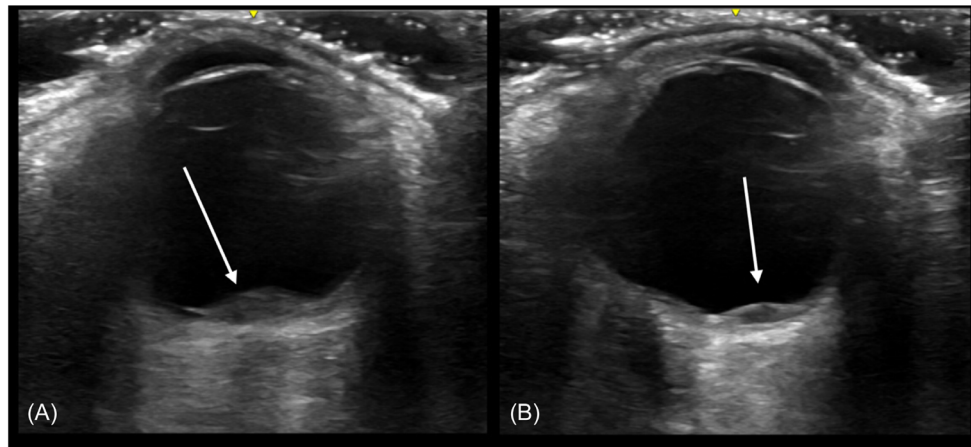


Image. Point-of-care ultrasound using liner 8-megahertz transducer in transverse view demonstrating, (A) hypoechoic lenticular-shaped optic metastasis (3.2 millimeters [mm] by 1.5 mm) over the optic nerve, and (B) a smaller lenticular-shaped metastasis (1.7 mm by 1.0 mm) with the patient in leftward gaze.

include primary ocular malignancies, hemangioma, sclerochoroidal calcification, granuloma, and infection, underscoring the importance of accurate diagnosis to guide appropriate management strategies.

Subclinical metastasis may not indicate targeted treatment. At initial diagnosis, patients may receive systemic adjuvant treatment to eliminate micrometastatic disease and prevent further metastasis.⁵ Systemic treatment may include endocrine treatment, cytotoxic chemotherapy, corticosteroids, or immunotherapy. Targeted treatment to ocular metastases includes external beam radiation, which can be useful in patients with foveal involvement but may result in cataracts or radiation retinopathy.

The authors attest that their institution requires neither Institutional Review Board approval, nor patient consent for publication of this case report. Documentation on file.

Address for Correspondence: Hamzah M. Yusuf, MD, Stanford University, Department of Emergency Medicine, 900 Welch Rd., Suite 350. Palo Alto, CA 94304. Email: hyusuf@stanford.edu

Conflicts of Interest: By the CPC-EM article submission agreement, all authors are required to disclose all affiliations, funding sources and financial or management relationships that could be perceived as potential sources of bias. The authors disclosed none.

Copyright: © 2024 Yusuf et al. This is an open access article distributed in accordance with the terms of the Creative Commons Attribution (CC BY 4.0) License. See: <http://creativecommons.org/licenses/by/4.0/>

REFERENCES

1. Wickremasinghe S, Dansingani KK, Tranos P, et al. Ocular presentations of breast cancer. *Acta Ophthalmol Scand.* 2007;85(2):133–42.

- Blasi MA, Maceroni M, Caputo CG, et al. Clinical and ultrasonographic features of choroidal metastases based on primary cancer site: long-term experience in a single center. *PLoS ONE.* 2021;16(3):e0249210.
- Maheshwari A and Finger PT. Cancers of the eye. *Cancer Metastasis Rev.* 2018;37(4):677–90.
- Barak A, Neudorfer M, Heilweil G, et al. Decreased prevalence of asymptomatic choroidal metastasis in disseminated breast and lung cancer: argument against screening. *Br J Ophthalmol.* 2007;91(1):74–5.
- Cui Y, Yin S, Qin X, et al. Advances in the treatment of intraocular malignancies: a literature review. *Front Med (Lausanne).* 2022;9:975565.

Population Health Research Capsule

What do we already know about this clinical entity?

Ocular metastasis represents a rare, clinically challenging manifestation of advanced cancer.

What is the major impact of the image(s)?

We describe an example of breast cancer metastasis on point-of-care ultrasound (POCUS), its clinical manifestations, and potential treatments.

How might this improve emergency medicine practice?

Emergency physicians may be able to diagnose ocular malignancy using POCUS, a fast and easy-to-use bedside tool.

Spinal Arachnoid Web

Maiya Smith, MD
Morgan Ketterling, DO
Alexander Gallaer, MD
Rowan Kelner, MD
Christine Raps, MD
Allison M. Beaulieu, MD, MAEd

University of Utah, Department of Emergency Medicine, Salt Lake City, Utah

Section Editor: Rachel Lindor, MD, JD

Submission history: Submitted January 10, 2024; Revision received March 7, 2024; Accepted March 8, 2024

Electronically published June 3, 2024

Full text available through open access at http://escholarship.org/uc/uciem_cpem

DOI: [10.5811/cpcem.7189](https://doi.org/10.5811/cpcem.7189)

Case Presentation: We describe a case of a 57-year-old male with multiple medical comorbidities who presented to the emergency department with a two-week history of upper back pain with associated numbness. Physical exam demonstrated sensory loss in a bilateral third and fourth thoracic dermatome distribution. The diagnosis of spinal arachnoid web was made based on neurological exam and imaging findings.

Discussion: Spinal arachnoid web is a rare diagnosis, but consideration is important, as early recognition and surgical intervention can resolve symptoms and prevent worsening neurological sequelae. [Clin Pract Cases Emerg Med. 2024;8(3)300–301.]

Keywords: *spinal arachnoid web; neurology.*

CASE PRESENTATION

A 57-year-old male with history of type II diabetes mellitus, renal transplant, coronary artery disease, and hypertension presented to the emergency department (ED) for numbness in his chest for two weeks, with associated upper back pain radiating to his chest bilaterally, and shortness of breath. He presented to an outpatient clinic for similar complaints one day prior and was started on a four-day course of prednisone for presumed pleurisy.

On examination in the ED, the patient was found to have decreased sensation in his third and fourth thoracic dermatome in a band-like distribution without additional neurologic deficits or skin findings. Magnetic resonance imaging (MRI) of the cervical and thoracic spine were obtained, showing a dorsal spinal arachnoid web (SAW) with slight compression of the spinal cord located at the third and fourth thoracic levels ([Image](#), [Video](#)).

Neurosurgery was consulted, evaluated the patient and reviewed imaging. No surgical intervention was offered at that time due to the patient's significant comorbidities and

moderate symptoms. He was discharged home from the ED with recommended close outpatient follow-up.

DISCUSSION

Spinal arachnoid web is a rare diagnosis. Within the meninges, there are three layers: the dura, arachnoid, and pia. The arachnoid is a thin membrane between the dura and pia that adheres to the brain and spinal cord.¹ A SAW specifically refers to a focal thickening of the arachnoid, typically in the thoracic spine, which causes compression of the spinal cord and interferes with the free flow of spinal fluid within the dorsal subarachnoid space. It is thought that SAW represents a variant of arachnoid cyst formation. While this patient did not have radiographic evidence of syringomyelia, SAW is typically associated with syringomyelia and does not seem to be associated with trauma, hemorrhage, or inflammation.² Presenting symptoms include back pain, upper/lower extremity weakness, and numbness.³

Imaging includes MRI or computed tomography myelography and often demonstrates a “scalpel sign”

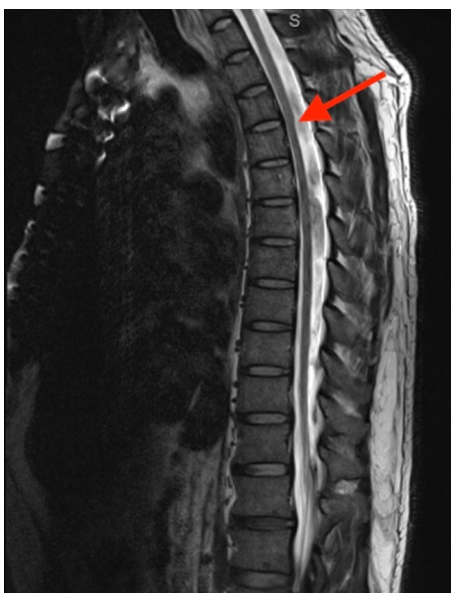

Image. Magnetic resonance imaging with and without contrast showing focal anterior displacement of the thoracic spinal cord at the third and fourth thoracic levels (arrow). In the setting of a prominent dorsal subarachnoid space with altered cerebrospinal fluid flow dynamics, the findings demonstrate a dorsal arachnoid web.

deformity at the site of the SAW, representing the focal dorsal indentation caused by the web, reminiscent of the pointed edge of a scalpel.³ However, the only definitive diagnosis for SAW is through surgical confirmation.

Spinal arachnoid web is likely under-recognized and under-diagnosed given its rarity. Diagnosis usually takes years, and treatment involves surgical lysis of the arachnoid band.²⁻⁴ Surgical intervention can completely resolve symptoms.² Failure to diagnose SAW may result in worsening spinal cord function and neurologic function. Patients who have progressively worsening pain, paresthesia, or weakness in a dermatomal distribution without trauma or prior neurosurgical intervention should prompt consideration of this diagnosis. Emergency physicians need to be aware of this rare diagnosis given its possibly irreversible neurologic sequelae including pain, numbness, weakness, and paralysis.²⁻⁴

Video. Magnetic resonance imaging with and without contrast demonstrating the “scalpel sign” seen at the third and fourth thoracic levels (arrow) due to the spinal arachnoid web.

The Institutional Review Board approval has been documented and filed for publication of this case report.

Patient consent has been obtained and filed for the publication of this case report.

CPC-EM Capsule

What do we already know about this clinical entity?

Spinal arachnoid web is a rare diagnosis that presents with numbness and other neurologic sequelae secondary to thickening of the arachnoid and compression of spinal cord.

What is the major impact of the image(s)?

Thickening of the arachnoid can be seen on magnetic resonance imaging as a “scalpel sign,” aiding in this ultimately surgical diagnosis.

How might this improve emergency medicine practice?

This rare disease is reversible when treated early. Physician awareness and use of imaging will aid in diagnosis and prevention of neurologic morbidity.

Address for Correspondence: Maiya Smith, MD, Department of Emergency Medicine, Helix Building, 5050, 30 N Mario Capecchi Drive, Level 2 South, Salt Lake City, UT 84112. Email: maiya.smith@hsc.utah.edu

Conflicts of Interest: By the CPC-EM article submission agreement, all authors are required to disclose all affiliations, funding sources and financial or management relationships that could be perceived as potential sources of bias. The authors disclosed none.

Copyright: © 2024 Smith et al. This is an open access article distributed in accordance with the terms of the Creative Commons Attribution (CC BY 4.0) License. See: <http://creativecommons.org/licenses/by/4.0/>

REFERENCES

- Ghannam JY and Al Kharazi KA. Neuroanatomy, cranial meninges. *In: StatPearls*. Treasure Island, FL: StatPearls Publishing; 2024. Available at: <http://www.ncbi.nlm.nih.gov/books/NBK539882/>. Accessed February 18, 2024.
- Paramore CG. Dorsal arachnoid web with spinal cord compression: variant of an arachnoid cyst? Report of two cases. *J Neurosurg Spine*. 2000;93(2):287–90.
- Reardon MA, Raghavan P, Carpenter-Bailey K, et al. Dorsal thoracic arachnoid web and the “scalpel sign”: a distinct clinical-radiologic entity. *Am J Neuroradiol*. 2013;34(5):1104–10.
- Brodbeck AR and Stoodley MA. Syringomyelia and the arachnoid web. *Acta Neurochir (Wien)*. 2003;145(8):707–11; discussion 711.

A Woman with Right Shoulder Pain

Kitan Akinosho, MD*
William Weber, MD, MPH†

*Beth Israel Deaconess Medical Center, Department of Emergency Medicine,
Boston, Massachusetts

†Rush University Medical Center, Department of Emergency Medicine, Chicago, Illinois

Section Editor: Jacqueline Le, MD

Submission history: Submitted January 18, 2024; Revision received March 20, 2024; Accepted April 2, 2024

Electronically published June 3, 2024

Full text available through open access at http://escholarship.org/uc/uciem_cpem

DOI: [10.5811/cpcem.7200](https://doi.org/10.5811/cpcem.7200)

Case Presentation: We report a case of an 89-year-old female who presented with pain in her right shoulder following a fall onto her outstretched hand. Upon presentation, her right hand was held behind her head and elbow held above her head in flexion. There was obvious deformity seen and felt in her axilla. Radiograph of the shoulder showed an inferior shoulder dislocation and impacted humeral neck fracture. Given her age and comorbid osteoporosis, a bedside reduction was performed by orthopedics where the humeral head was intentionally dislocated from the humeral shaft. Thirteen days after the initial shoulder dislocation, the patient's shoulder was successfully repaired by open reduction.

Discussion: Luxatio erecta, which means “erect dislocation” in Latin, refers to an inferior shoulder dislocation. It accounts for less than 1% of shoulder dislocations. Our case report highlights an inferior shoulder dislocation with a rare, concomitant humeral neck fracture, managed via staged reduction by orthopedics with intentional dislocation of the humeral head given concern over patient's age and osteoporosis. The patient was eventually successfully repaired via arthroplasty within two weeks. [Clin Pract Cases Emerg Med. 2024;8(3)302–304.]

Keywords: *inferior shoulder dislocation; luxatio erecta; shoulder pain.*

CASE PRESENTATION

An 89-year-old female with a history of osteoporosis presented after a mechanical fall with right shoulder pain. She tripped and fell with her arm raised above her head and in front of her. She reported difficulty moving her right arm from its position above her head. On physical exam, her right arm was neurovascularly intact, but held above her head with palpable inferior displacement of the humeral head in the axilla. Radiograph was performed and is shown below (Image 1).

DISCUSSION

This radiograph shows an inferior shoulder dislocation, also known as luxatio erecta, an uncommon shoulder injury that accounts for less than 1% of shoulder dislocations.¹ Luxatio erecta typically results from sudden hyperabduction, which forces the humeral head inferiorly, often tearing the inferior capsule. Patients generally present with the arm fully abducted and their hand near their head for comfort.² Patients most commonly fracture the greater tuberosity, but

this patient with osteoporosis experienced a humeral neck fracture.

Two important approach considerations differentiate inferior shoulder dislocations from typical anterior or posterior dislocations: rate of concomitant injury and vector of reduction. Physicians should pay close attention for neurovascular compromise, with the axillary nerve and axillary artery very susceptible to injury. Studies have found high rates of bony injury (60%), neurologic injury (29%), and vascular injury (10%) associated with the injury.^{1,3} Reductions for inferior shoulder dislocations typically employ superior and external traction.⁴ Alternatively, anterior traction can convert an inferior dislocation to an anterior dislocation, which can then be reduced with a variety of methods.

In this case, orthopedics was consulted due to the multiple concomitant fractures. Typically, the remainder of the humerus can be used to distract the humeral head and allow reduction, but in this case the humeral head was separated. In this case, orthopedics chose to use traction-countertraction

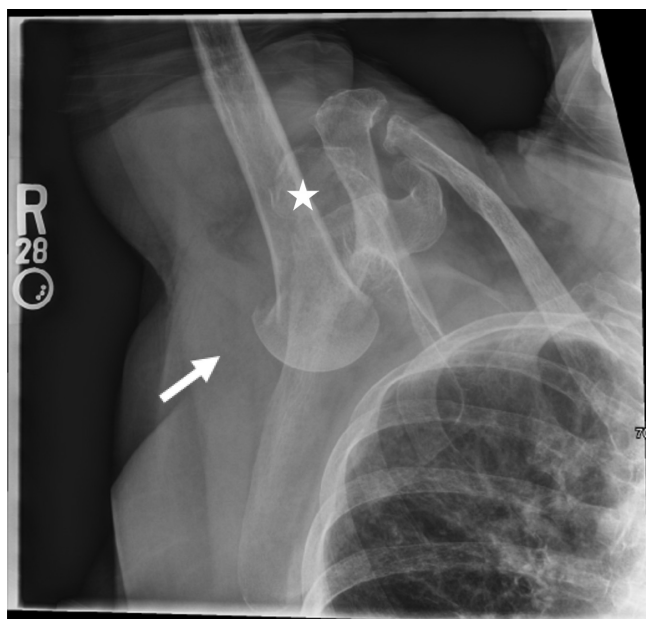


Image 1. Initial radiograph of right shoulder shows a right inferior dislocation [luxatio erecta] with a concomitant impacted humeral neck fracture (arrow). A mildly displaced right glenoid fracture is also noted (star).

with a superior and external vector away from the patient to reduce the remainder of the humerus for comfort and neurovascular safety while leaving the humeral head dislocated for open repair (**Image 2**). The patient was provided a shoulder sling in the interim until cardiac risk

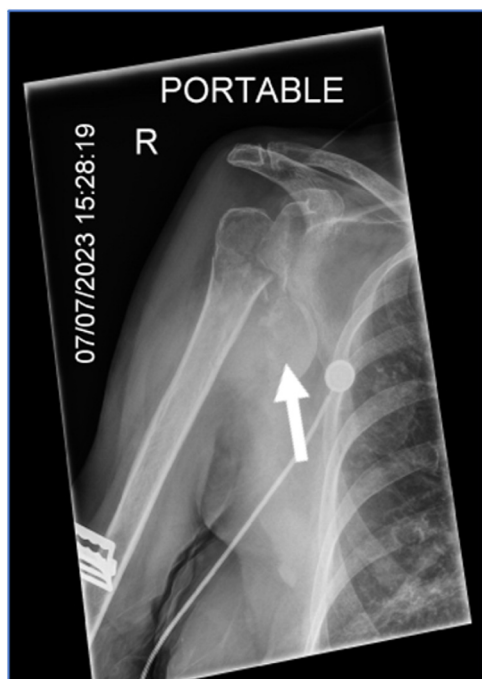

Image 2. Radiograph of right shoulder immediately post-reduction showing humeral fracture (arrow).

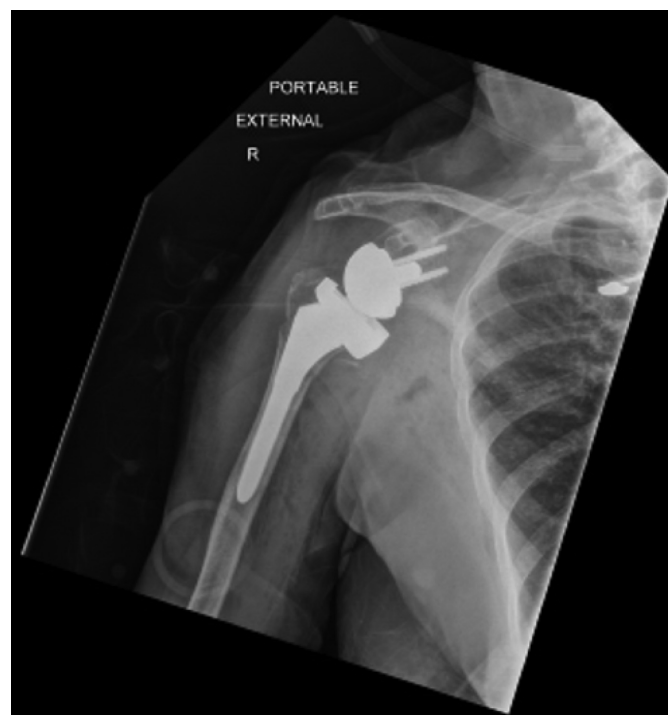

Image 3. Radiograph of right shoulder 13 days post-dislocation following outpatient, right reverse total shoulder arthroplasty.

Population Health Research Capsule

What do we already know about this clinical entity?

Luxatio erecta (inferior shoulder dislocation) is a rare occurrence (<1%) that carries a high rate of concomitant vascular, neurologic, and bony injury.

What is the major impact of the image(s)?

We highlight a luxatio erecta with a superimposed humeral fracture, managed via bedside reduction with intentional dislocation of the humeral head prior to surgery.

How might this improve emergency medicine practice?

The approach to reducing luxatio erecta differs from other shoulder dislocations. Maintain high suspicion for other injuries and consider orthopedic consult.

The authors attest that their institution requires neither Institutional Review Board approval, nor patient consent for publication of this case report. Documentation on file.

Address for Correspondence: Kitan Akinosho, MD, Beth Israel Deaconess Medical Center, One Deaconess Road, Rosenberg 2, Boston, MA 02215. Email: kakinosh@bidmc.harvard.edu

Conflicts of Interest: By the CPC-EM article submission agreement, all authors are required to disclose all affiliations, funding sources and financial or management relationships that could be perceived as potential sources of bias. The authors disclosed none.

Copyright: © 2024 Akinosho et al. This is an open access article distributed in accordance with the terms of the Creative Commons Attribution (CC BY 4.0) License. See: <http://creativecommons.org/licenses/by/4.0/>

REFERENCES

1. Nambiar M, Owen D, Moore P, et al. Traumatic inferior shoulder dislocation: a review of management and outcome. *Eur J Trauma Emerg Surg.* 2018;44(1):45–51.
2. Vasiliadis AV, Kalitsis C, Kantas T, et al. Inferior dislocation of shoulder complicated with undisplaced greater tuberosity fracture, rupture of the supraspinatus tendon, and brachial plexus injury in the elderly: case report and literature review. *Case Rep Orthop.* 2020;2020:9420184.
3. Ostermann RC, Joestl J, Hofbauer M, et al. Associated pathologies following luxatio erecta humeri: a retrospective analysis of 38 cases. *J Clin Med Res.* 2022;11(2):453.
4. Nho SJ, Dodson CC, Bardzik KF, et al. The two-step maneuver for closed reduction of inferior glenohumeral dislocation (luxatio erecta to anterior dislocation to reduction). *J Orthop Trauma.* 2006;20(5):354–7.

Point-of-Care Ultrasound for Earlier Detection of Pediatric Pneumonia

John H. Priester, MD*
Prasanna Kumar, MD[†]
Jesse Naumann, BS, EMT*
Katherine Dolbec, MD*
Peter Weimersheimer, MD*
Christian D. Pulcini, MD, MEd, MPH*[‡]

*University of Vermont, Larner College of Medicine, Department of Emergency Medicine, Burlington, Vermont
[†]Brown University/Rhode Island Hospital, Department of Emergency Medicine, Providence, Rhode Island
[‡]University of Vermont, Larner College of Medicine, Department of Pediatrics, Burlington, Vermont

Section Editor: Shadi Lahham, MD

Submission history: Submitted January 25, 2024; Revision received April 19, 2024; Accepted April 19, 2024

Electronically published July 18, 2024

Full text available through open access at http://escholarship.org/uc/uciem_cpem

DOI: [10.5811/cpcem.7216](https://doi.org/10.5811/cpcem.7216)

Case Presentation: An 8-month-old infant presented to a general emergency department with chief complaints of rhinorrhea, decreased activity, and fever. A point-of-care lung ultrasound (LUS) was performed at bedside with potential early findings of pneumonia. Based on these findings on LUS, a chest radiograph (CXR) was ordered and performed with no acute findings. He was discharged without antibiotics based on these findings; unfortunately, he returned two days later with worsening symptoms requiring chest tube placement, mechanical ventilation, and prolonged hospitalization for complicated bacterial pneumonia.

Discussion: Pneumonia is a major cause of pediatric morbidity and mortality worldwide. Despite evidence supporting the utilization of LUS for the diagnosis of pediatric pneumonia, CXR remains the default imaging for clinical decision-making in most settings. In this case, earlier antibiotics and higher reliance on LUS for clinical decision-making may have prevented the morbidity associated with this hospitalization. [Clin Pract Cases Emerg Med. 2024;8(3)305–307.]

Keywords: *point-of-care ultrasound; pneumonia; lung ultrasound; chest radiograph; pediatrics.*

CASE PRESENTATION

An 8-month-old infant presented to the emergency department (ED) with one week of rhinorrhea, decreased activity, and fever. Reported symptoms over the prior 24 hours included increased work of breathing, decreased oral intake, and fewer wet diapers. On arrival, physical exam findings included grunting, retractions, tachycardia, tachypnea, and fever of 39.3° Celsius. With antipyretics his respiratory symptoms improved. A chest radiograph (Image 1) was performed to follow up on an educational point-of-care lung ultrasound (LUS) (Image 2), which was suggestive of early pneumonia. He was discharged home without antibiotics given his negative chest radiograph (CXR) (Image 1).

He unfortunately returned two days later with continuing fever, decreased oral intake, and emesis. Repeat radiography

demonstrated right lung opacity, and he was diagnosed with methicillin-sensitive *Staphylococcus aureus* community-acquired pneumonia with empyema (Image 3). He was admitted and treated for pneumonia, and his course was complicated by acute hypoxic respiratory failure and empyema, necessitating mechanical ventilation and chest tube placement. He was discharged on hospital day 21.

DISCUSSION

Community-acquired pneumonia is a major cause of pediatric morbidity and mortality.¹ Our case adds to the current literature supporting LUS as superior in identifying pediatric pneumonia compared to CXR, yet CXR remains the most common modality used for clinical decision-making in this population in the ED.² Previous research has compared LUS to CXR in the diagnosis of pneumonia in

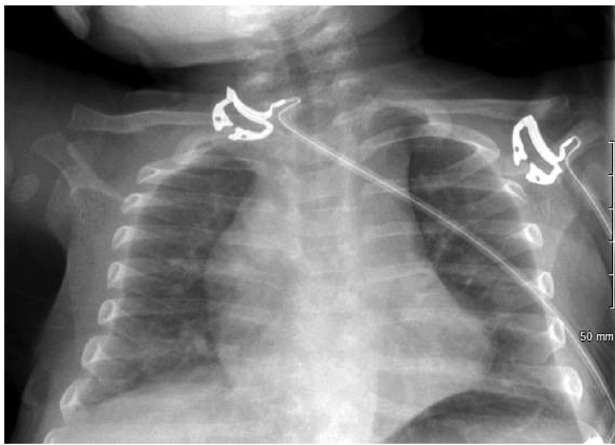


Image 1. Chest radiograph from initial evaluation in the emergency department, without evidence of pneumonia.

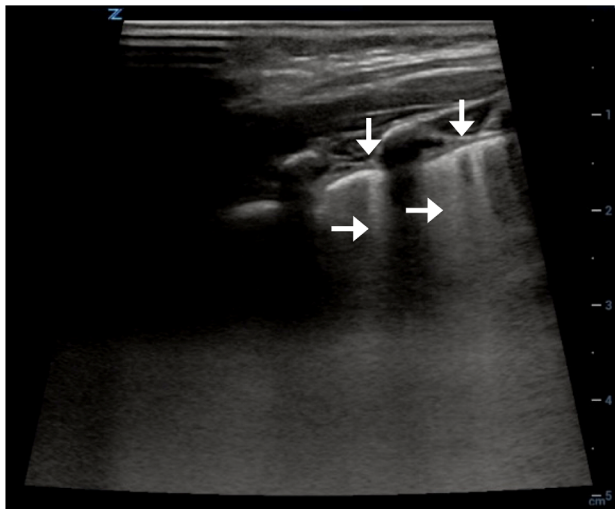


Image 2. Focal pleural irregularities (vertical arrows) and B-lines (horizontal arrows) suggestive of pneumonia from right lung ultrasound performed on initial visit to the emergency department.

children with sensitivity and specificity of LUS as high as 96% and 93%, respectively.² Further, up to 28% of lesions in pediatric pneumonia identified with LUS were not visible with radiograph.³ In the case presented here, significant morbidity may have been avoided had antibiotic therapy been initiated following the initial evaluation with LUS.

The advantages of LUS when compared to CXR extend beyond effectiveness and accuracy. Earlier detection of disease, reduced radiation exposure, and efficient bedside assessment are also clear advantages.^{1,3-5} In addition, LUS can be repeated at bedside to monitor disease progression or regression, allowing for informed ongoing treatment decisions. As point-of-care ultrasonography becomes an integral part of emergency medicine residency programs and standard of care, we hope to see more physicians trained to effectively perform, interpret, and clinically apply LUS, notably in the pediatric population.

Population Health Research Capsule

What do we already know about this clinical entity?

Chest radiography is the conventional imaging modality of diagnosing pediatric pneumonia. However, lung ultrasound offers similar, if not better, sensitivity and specificity.

What is the major impact of the image(s)?

This case demonstrates how lung ultrasound can diagnose pediatric pneumonia earlier than chest radiography and should be the basis for clinical decision making.

How might this improve emergency medicine practice?

In the presence of abnormal lung ultrasound findings and normal chest radiography, emergency medicine physicians should strongly consider initiating treatment.

This case presentation demonstrates the advantages of using LUS for clinical decision-making in the pediatric population. Early initiation of antibiotics based on LUS may help to avoid morbidity and mortality from treatment delay, and our case lends credence to the lingering question among emergency clinicians of whether to treat with antibiotics based on ultrasound findings that are discrepant with a CXR. Emergency clinicians should strongly consider prioritizing

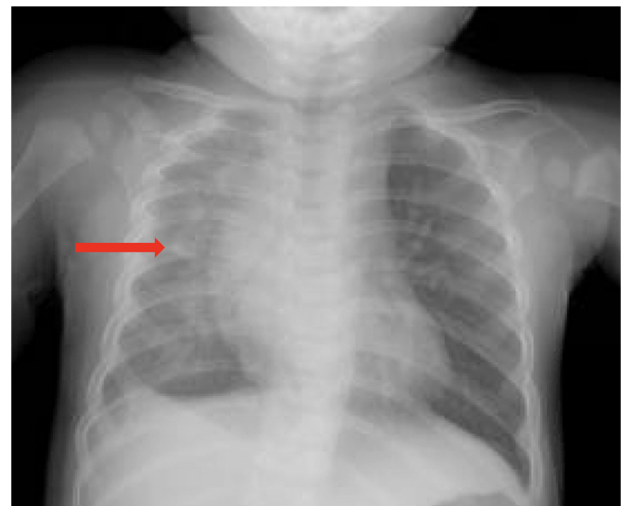


Image 3. Chest radiograph on day 3, following return to the emergency department. Right lung consolidation suggestive of pneumonia is visible.

the findings of LUS in diagnosing and treating pediatric pneumonia, as well as support the training and dissemination of LUS as the superior modality to optimize care of this potentially vulnerable population.

The authors attest that their institution requires neither Institutional Review Board approval, nor patient consent for publication of this case report. Documentation on file.

Address for Correspondence: Prasanna Kumar, MD, Brown University, Alpert Medical School, Department of Emergency Medicine, 55 Claverick St., Suite 100, Providence, RI 02903. Email: Prasanna_kumar@brown.edu

Conflicts of Interest: By the CPC-EM article submission agreement, all authors are required to disclose all affiliations, funding sources and financial or management relationships that could be perceived as potential sources of bias. The authors disclosed none.

Copyright: © 2024 Priester et al. This is an open access article distributed in accordance with the terms of the Creative Commons Attribution (CC BY 4.0) License. See: <http://creativecommons.org/licenses/by/4.0/>

REFERENCES

1. Jones BP, Tay ET, Elikashvili I, et al. Feasibility and safety of substituting lung ultrasonography for chest radiography when diagnosing pneumonia in children: a randomized controlled trial. *Chest*. 2016;150(1):131–8.
2. Najgrodzka P, Buda N, Zamojska A, et al. Lung ultrasound in the diagnosis of pneumonia in children: a meta-analysis and a review of pediatric lung imaging. *Ultrasound Q*. 2019;35(2):157–63.
3. Iorio G, Capasso M, Prisco S, et al. Lung ultrasound findings undetectable by chest radiography in children with community-acquired pneumonia. *Ultrasound Med Biol*. 2018;44(8):1687–93.
4. Ianniello S, Piccolo CL, Buquicchio GL, et al. First-line diagnosis of paediatric pneumonia in emergency: lung ultrasound (LUS) in addition to chest-X-ray (CXR) and its role in follow-up. *Br J Radiol*. 2016;89(1061):20150998.
5. Martínez Redondo J, Comas Rodríguez C, Pujol Salud J, et al. Higher accuracy of lung ultrasound over chest x-ray for early diagnosis of COVID-19 pneumonia. *Int J Environ Res Public Health*. 2021;18(7):3481.

Painful Enlarging Cervical Mass in Young Male

Jacob Lawing, MD
Jeremy Towns, MD
Matthew A. Heimann, MD

University of Alabama at Birmingham, Department of Emergency Medicine,
Birmingham, Alabama

Section Editor: Melanie Heniff, MD

Submission history: Submitted January 7, 2024; Revision received April 15, 2024; Accepted April 24, 2024

Electronically published July 31, 2024

Full text available through open access at http://escholarship.org/uc/uciem_cpem

DOI: [10.5811/cpcem.6664](https://doi.org/10.5811/cpcem.6664)

Case Presentation: A 32-year-old male who recently immigrated from Kenya presented to the emergency department (ED) with a painful, enlarging, right-sided neck mass for eight weeks duration. Point-of-care ultrasound was used to reveal a large cystic mass with internal septations and numerous hypoechoic round lesions. Initial tuberculosis blood test ordered in the ED was positive with cultures ultimately growing *Mycobacterium tuberculosis*.

Discussion: Scrofula should be considered in the differential in patients presenting with enlarging neck masses who have epidemiological risk factors for tuberculosis. [Clin Pract Cases Emerg Med. 2024;8(3)308–310.]

Keywords: *scrofula; neck mass; tuberculosis; lymphadenitis.*

CASE PRESENTATION

A 32-year-old male presented to the emergency department (ED) due to a painful, enlarging, right-sided neck mass for eight weeks. Notably, he had immigrated from Kenya approximately one year prior. He reported subjective fevers but denied weight loss, night sweats, or pulmonary symptoms. Physical exam revealed a moderate-sized area of focal swelling noted to right lateral neck associated with cervical lymphadenopathy (Image 1).

A T-SPOT.TB test (an interferon-gamma release assay) was ordered from the ED and returned positive. Empiric treatment with cefepime was started, and the patient was admitted to the hospital for ultrasound-guided lymph node biopsy. Limited point-of-care ultrasound (Image 2) and computed tomography of the neck with contrast (Image 3) were performed.

DISCUSSION

This diagnosis of scrofula was ultimately made through acid-fast bacillus culture, which grew *Mycobacterium tuberculosis*. Scrofula, or mycobacterial lymphadenitis, is a type of extrapulmonary tuberculosis (TB) caused by hematogenous or lymphatic dissemination of pulmonary TB or reactivation of latent TB. Common presentations include an enlarging mass with or without tenderness and

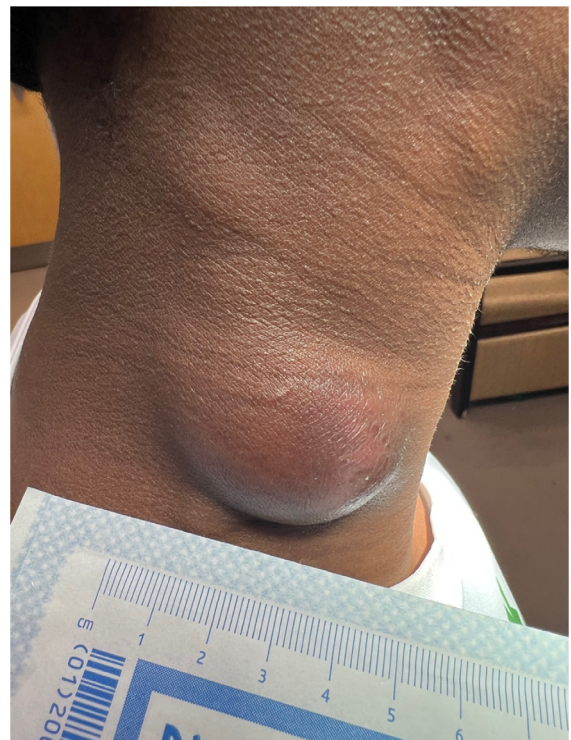

Image 1. Right-sided fluctuant cervical mass with overlying erythema.

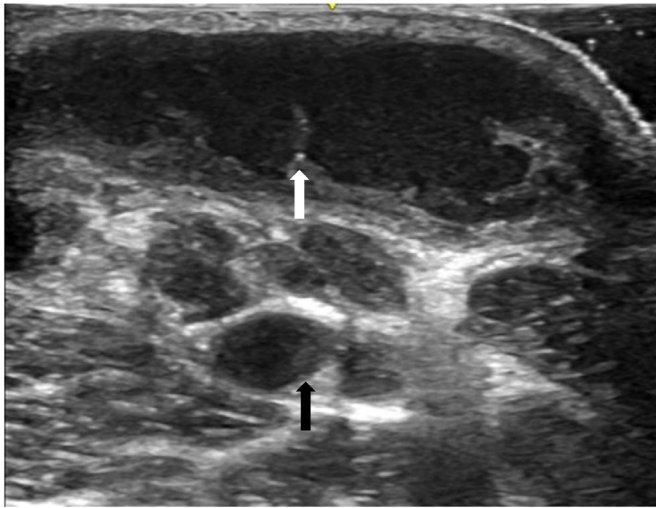


Image 2. Point-of-care ultrasound revealing large cystic mass with internal septations (white arrow) and cervical adenopathy (black arrow).

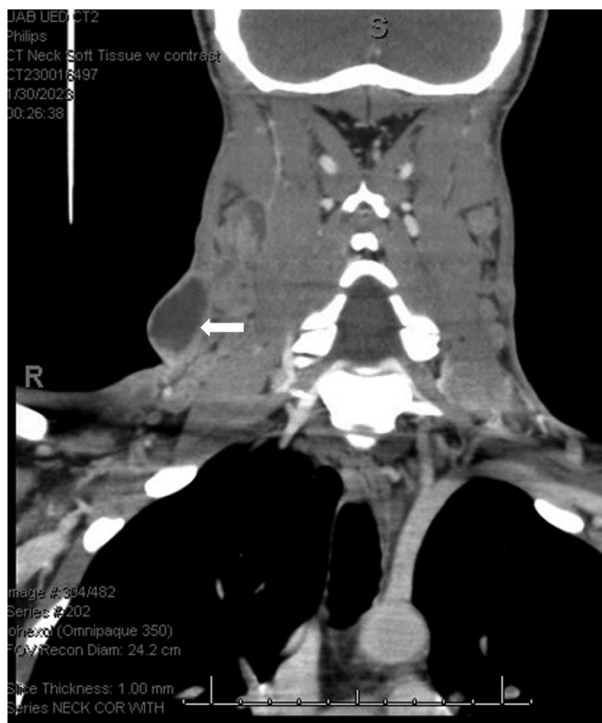


Image 3. Computed tomography of the neck with intravenous contrast revealed multiple necrotic and cystic-appearing lymph nodes (arrow).

erythema located within the cervical or supraclavicular lymph nodes.¹ Associated symptoms include fever, rigors, and night sweats.² Point-of-care ultrasound of tuberculous nodes will be hypoechoic and round, with intranodal cystic necrosis and adjacent soft-tissue edema. Diagnosis is made

Images in EM Capsule

What do we already know about this clinical entity?

Scrofula, or mycobacterial lymphadenitis, is a type of extrapulmonary tuberculosis that commonly presents as an enlarging mass within the cervical or supraclavicular lymph nodes.

What is the major impact of the images?

Identification of a cystic mass with internal septations on point-of-care ultrasound (POCUS) can help distinguish this entity from other causes of cervical masses.

How might this improve emergency medicine practice?

The use of POCUS on cervical masses in patients with endemic risk factors can greatly aid in the diagnosis of scrofula.

by histopathology along with a smear of acid-fast bacilli and culture of lymph nodes. Treatment includes rifampicin, isoniazid, pyrazinamide, and ethambutol. It is imperative to obtain appropriate imaging such as ultrasound or computed tomography in enlarging neck masses with epidemiologic risk factors of TB and ensure close follow-up.

The authors attest that their institution requires neither Institutional Review Board approval, nor patient consent for publication of this case report. Documentation on file.

Address for Correspondence: Jacob Lawing, MD, University of Alabama at Birmingham, Department of Emergency Medicine, 521 19th St. South, Suite 203, Birmingham, AL 35233.
Email: jglawing@uabmc.edu

Conflicts of Interest: By the CPC-EM article submission agreement, all authors are required to disclose all affiliations, funding sources and financial or management relationships that could be perceived as potential sources of bias. The authors disclosed none.

Copyright: © 2024 Lawing et al. This is an open access article distributed in accordance with the terms of the Creative Commons Attribution (CC BY 4.0) License. See: <http://creativecommons.org/licenses/by/4.0/>

REFERENCES

1. Bhandari J and Thada PK. Scrofula. In: *StatPearls [Internet]*. Treasure Island, FL: StatPearls, 2023. Available at: <https://www.ncbi.nlm.nih.gov/books/NBK557700/>. Accessed December 20, 2023.
2. Polesky A, Grove W, Bhatia G. Peripheral tuberculous lymphadenitis: epidemiology, diagnosis, treatment, and outcome. *Medicine (Baltimore)*. 2005;84(6):350–62.
3. Ahuja AT and Ying M. Sonographic evaluation of cervical lymph nodes. *Am J Roentgenol*. 2005;184(5):1691–9.

Atraumatic Infected Septal Hematoma in a Pediatric Patient

Osher Shefer, MD
Jacqueline Le, MD
Eshaan Daas, MD
Eugene Hu, MD

Desert Regional Medical Center, Department of Emergency Medicine, Palm Springs, California

Section Editor: Lev Libet, MD

Submission history: Submitted February 22, 2024; Revision received May 2, 2024; Accepted May 6, 2024

Electronically published June 26, 2024

Full text available through open access at http://escholarship.org/uc/uciem_cpccm

DOI: 10.5811/cpcem.19476

Case Presentation: We present a case of a 10-year-old male who developed an atraumatic, nasal septal hematoma with abscess following several days of rhinorrhea and cough. His chief complaint to the emergency department was a two-day history of nasal swelling and discomfort, associated with difficulty breathing through his nose. The patient was well-appearing with swelling and tenderness along the external nasal ridge and nasal septal swelling that occluded both nares. Contrast-enhanced maxillofacial computed tomography revealed a rim-enhancing, fluid-filled collection to the anterior nasal septum. The patient underwent successful incision and drainage by otolaryngology.

Discussion: Infected septal hematomas are rare but important to recognize as they can result in septal deformity and potentially life-threatening sequelae, such as intracranial infections. Most are secondary to nasal trauma in adult patients. This case highlights a unique presentation of atraumatic septal hematoma with abscess formation in an immunocompetent pediatric patient. [Clin Pract Cases Emerg Med. 2024;8(3)311–313.]

Keywords: nasal septal abscess; nasal septal hematoma; pediatric; atraumatic; ear-nose-throat (ENT).

CASE PRESENTATION

A 10-year-old male with no past medical or surgical history presented to our high-volume community emergency department with a two-day history of nasal swelling and discomfort associated with cough and rhinorrhea that began a few days prior. He had difficulty inhaling through his nose but denied any trauma, dental pain, fevers, or vomiting. No seasonal allergies or allergies to medications were reported by the patient's family.

The patient was well-appearing, with an elevated body mass index of 32 (reference range 18.5–24.9 for healthy weight). Vital signs were within normal limits, with temperature of 37.2° Celsius, heart rate of 95 beats per minute, respiratory rate of 18 breaths per minute, and oxygen saturation of 98% on room air. Physical examination revealed swelling and tenderness of the external aspect of the nose without evidence of skin lesions or trauma. The septum was edematous extending into and obstructing both nares, and clear nasal discharge was present (Image 1). He had no respiratory distress, and oropharynx was clear with normal dentition.

The otolaryngology (ENT) service was consulted, and they recommended maxillofacial computed tomography (CT) with contrast. Computed tomography imaging was significant for a 3.7 × 2.8 × 2.1 centimeter midline rim-enhancing, fluid collection at the anterior nasal septum with obstruction of the bilateral nasal cavity (Image 2). There was mild paranasal mucosal thickening without bony destruction. White blood cell count revealed a leukocytosis of 20.1 × 10⁹/liter (reference range 5.0–14.5 × 10⁹/liter) with left shift of 85.8% neutrophils (42–77%) and 10% lymphocytes (20–40%). Analgesia with acetaminophen and empiric intravenous antibiotics of vancomycin and piperacillin/tazobactam were initiated for suspected nasal septal abscess. The patient was transferred to a tertiary care facility with pediatric ENT services.

The following day, pediatric ENT performed an incision and drainage of the nasal septal collection with reported bloody output and scant purulence. Culture subsequently revealed light growth of *Staphylococcus aureus*, *Corynebacterium amycolatum*, and *S epidermidis*. The

patient was discharged the day after surgery in stable condition without outpatient antibiotics.

DISCUSSION

Nasal septal hematomas and abscesses are collections of blood or purulent material, respectively, within the nasal septum and are rare clinical occurrences. Nasal septal abscesses are almost exclusively described after trauma and are thought to arise secondary to septal hematoma formation.¹⁻⁴ In one case series, all 20 pediatric patients who presented with septal hematoma and/or abscess had a reported history of nasal trauma.¹ Less common causes of septal abscess include dental infection, rhinosinusitis, and postoperative sequelae.^{2,3} Typical pathogens include *S aureus*, *Streptococcus pneumoniae*, *Haemophilus influenzae*, and anaerobic bacteria.² Atraumatic nasal septal abscesses have been more commonly reported in immunocompromised adults, and a spontaneous nasal septal hematoma with abscess has been reported in an adult.⁵ Our case is novel in that we present an atraumatic, infected septal hematoma in an immunocompetent pediatric patient.

A clinical presentation of pain and swelling with examination findings seen in [Images 1 and 2](#) should prompt consideration of septal hematoma or abscess. In our case ENT

CPC-EM Capsule

What do we already know about this clinical entity?

Nasal septal abscess is a complication of traumatic septal hematoma with potential sequelae such as cartilage necrosis, cavernous sinus thrombosis, and meningitis.

What is the major impact of the images?

The images show atraumatic, infected septal hematoma in an immunocompetent pediatric patient, representing a rare clinical presentation in an uncommon demographic.

How might this improve emergency medicine practice?

Infected septal hematomas are rare and require timely diagnosis, which can be achieved with clinical suspicion guided by visual recognition of cardinal features.

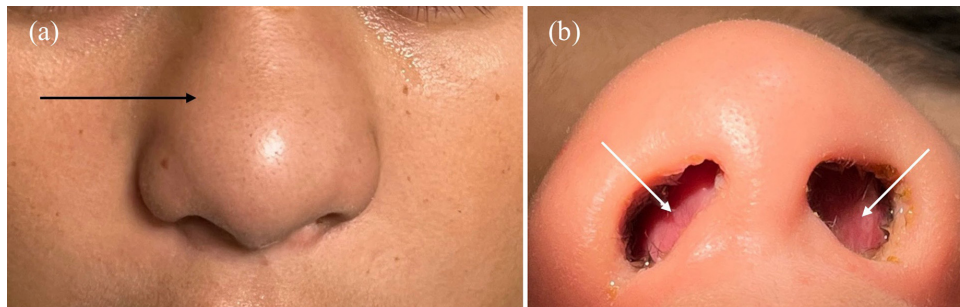


Image 1. External nasal examination (a) of the patient demonstrated diffuse edema superior to both ala (black arrow). Internal nasal examination (b) revealed a markedly edematous nasal septum that extended and occluded both nares (white arrows). Clear rhinorrhea was noted.

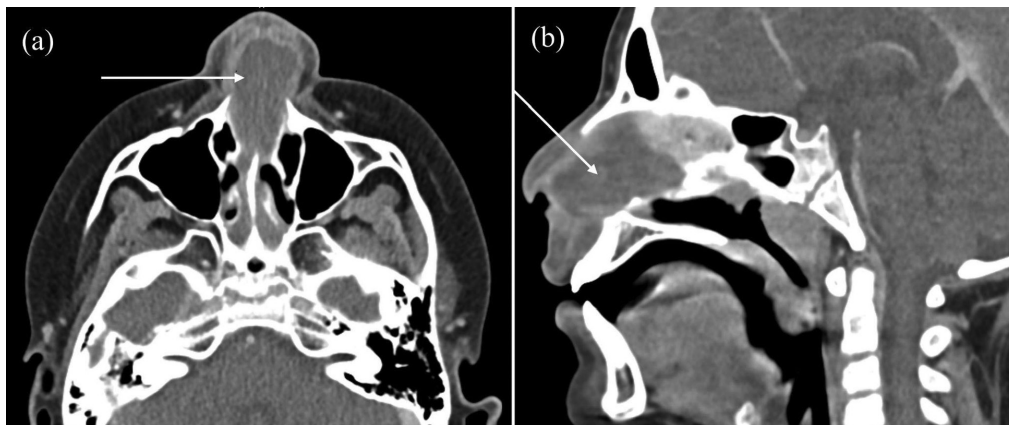


Image 2. Axial (a) and sagittal (b) images of contrast-enhanced maxillofacial computed tomography demonstrating a large midline rim-enhancing, fluid-filled mass at the anterior nasal septum (arrows) with obstruction of both nasal cavities.

recommended advanced imaging and transfer to a site with pediatric ENT availability. Timely recognition and diagnosis is pivotal to optimal patient outcomes and minimizing potential complications including nasal deformity, septal perforation, and intracranial infection.²

Patient consent has been obtained and filed for the publication of this case report.

The authors attest that their institution does not require Institutional Review Board approval for publication of this case report. Documentation on file.

Address for Correspondence: Jacqueline Le, MD, Desert Regional Medical Center, Department of Emergency Medicine, 1150 N. Indian Canyon Dr., Palm Springs, CA 92262.
Email: Jacqueline.Le@vituity.com

Conflicts of Interest: By the CPC-EM article submission agreement, all authors are required to disclose all affiliations, funding sources and financial or management relationships that could be perceived as potential sources of bias. The authors disclosed none.

Copyright: © 2024 Shefer et al. This is an open access article distributed in accordance with the terms of the Creative Commons Attribution (CC BY 4.0) License. See: <http://creativecommons.org/licenses/by/4.0/>

REFERENCES

1. Cauty PA and Berkowitz RG. Hematoma and abscess of the nasal septum in children. *Arch Otolaryngol Head Neck Surg.* 1996;122(12):1373–6.
2. Huang YC, Hung PL, Lin HC. Nasal septal abscess in an immunocompetent child. *Pediatr Neonatol.* 2012;53(3):213–5.
3. Tien DA, Krakovitz P, Anne S. Nasal septal abscess in association with pediatric acute rhinosinusitis. *Int J Pediatr Otorhinolaryngol.* 2016;91:27–9.
4. Alshaikh N and Lo S. Nasal septal abscess in children: from diagnosis to management and prevention. *Int J Pediatr Otorhinolaryngol.* 2011;75(6):737–44.
5. Mooney CP and Rimmer J. Spontaneous nasal septal haematoma and abscess: a case report and literature review. *Rhinol Online.* 2018;1(1):122–6.

Brugada Syndrome and Sudden Cardiac Death: An Electrocardiographic History

Mark L. Moubarek, MD*
Gordon X. Wong, MD[†]
James S. Ford, MD, MAS[‡]

*University of California, Davis Health, Department of Emergency Medicine, Sacramento, California

[†]University of California, Davis Health, Department of Internal Medicine, Division of Cardiovascular Medicine, Sacramento, California

[‡]University of California, San Francisco, Department of Emergency Medicine, San Francisco, California

Section Editor: R. Gentry Wilkerson, MD

Submission history: Submitted February 21, 2024; Revision received May 3, 2024; Accepted May 5, 2024

Electronically published August 2, 2024

Full text available through open access at http://escholarship.org/uc/uciem_cpem

DOI: 10.5811/cpcem.19477

Case Presentation: A 22-year-old male with a history of anti-neutrophil cytoplasmic antibody vasculitis, renal transplant, hypertension, and no known family history of sudden cardiac death suffered a witnessed cardiac arrest. An initial rhythm strip recorded by emergency medical services revealed ventricular fibrillation. Return of spontaneous circulation was achieved after three rounds of cardiopulmonary resuscitation, defibrillation, and intravenous epinephrine. The patient was brought to the emergency department and admitted to the intensive care unit. He was diagnosed with Brugada syndrome, and an automatic implantable cardioverter-defibrillator (AICD) was placed after discharge.

Discussion: Brugada syndrome is characterized electrocardiographically by ≥ 2 millimeters (mm) ST-segment elevation in leads V_1 – V_2 with either “coved type” (type 1) or “saddleback” (type 2) ST-segment morphology, or ≤ 2 mm ST-segment elevation in V_1 – V_2 with either “coved” or “saddleback” morphology (type 3). The absence of these patterns on isolated electrocardiograms (ECG) does not exclude the diagnosis, as dynamic fluctuations in ECG patterns are well-documented and can be induced by various physiologic stressors. This case provides an uncommon, complete electrocardiographic history of Brugada syndrome, from out-of-hospital cardiac arrest to AICD placement and depicts dynamic fluctuations between Brugada patterns and normal ECGs. This highlights the importance of serial ECGs in diagnosis, as sudden cardiac death is often the first or only presentation of Brugada syndrome. [Clin Pract Cases Emerg Med. 2024;8(3)314–317.]

Keywords: *Brugada syndrome; sudden cardiac death; cardiac arrest; coved ST-segment elevation; saddleback ST-segment elevation.*

CASE PRESENTATION

A 22-year-old male, with a history of anti-neutrophil cytoplasmic antibody vasculitis, renal transplant, hypertension, and no known family history of sudden cardiac death, suffered a witnessed out-of-hospital cardiac arrest, receiving bystander cardiopulmonary resuscitation (CPR). An initial electrocardiogram (ECG) rhythm strip in the field revealed ventricular fibrillation (VF) (Image 1). The patient achieved return of spontaneous circulation (ROSC) after three milligrams (mg) of intravenous (IV) epinephrine,

450 mg IV amiodarone, and three rounds of CPR and defibrillation. He was intubated in the field. A post-ROSC ECG demonstrated Brugada type 1 ST-segment elevation in V_1 – V_2 (Image 2A).¹ In the emergency department (ED) an ECG showed dynamic resolution of the Brugada pattern (Image 2B).

The patient was given calcium gluconate empirically for the treatment of presumptive hyperkalemia, given his history of renal transplant. In the ED, labs were notable for a pH of 6.90 (reference range 7.35–7.40); partial pressure of carbon

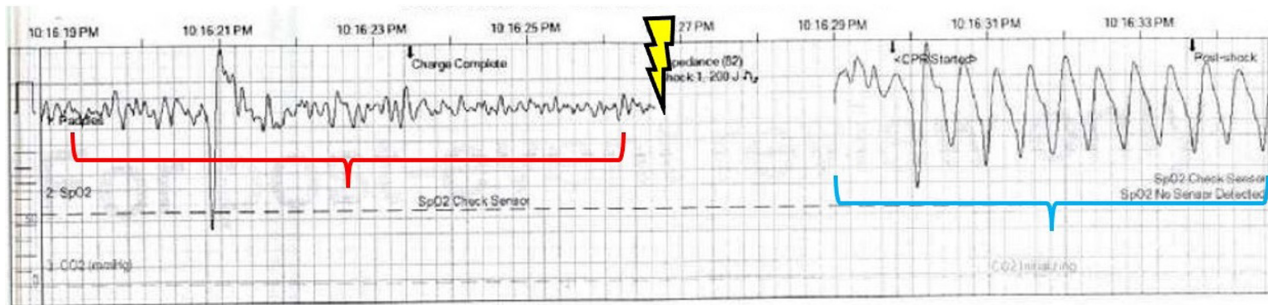


Image 1. Rhythm strip performed by emergency medical services showing ventricular fibrillation (red bracket) followed by defibrillation (lightning symbol), with conversion to a wide-complex tachycardia consistent with ventricular tachycardia (blue bracket).

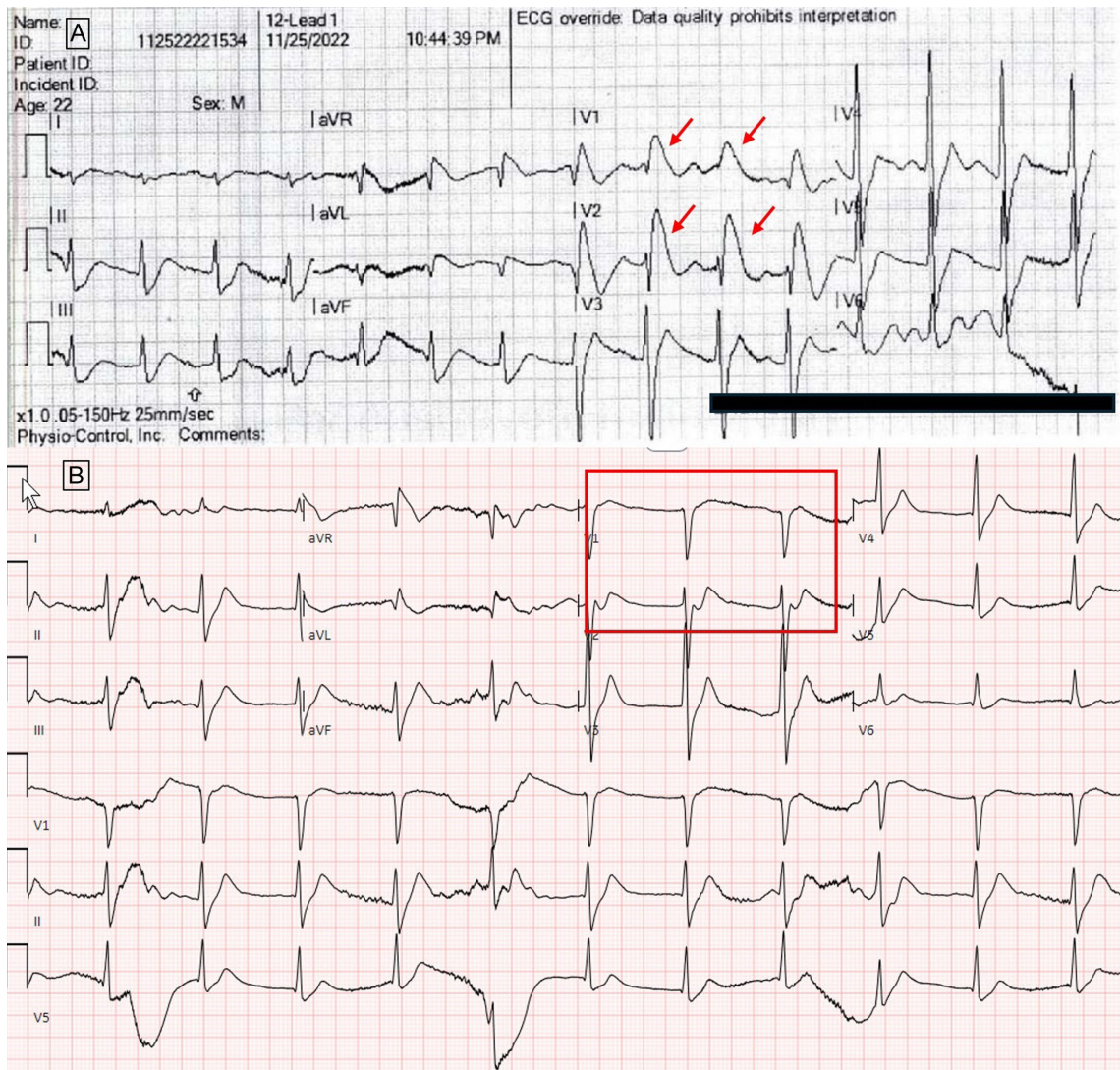


Image 2. A. Electrocardiogram performed by emergency medical services prior to arrival to the emergency department, showing Brugada pattern (type 1) ST-segment elevation in leads V₁–V₂ (red arrows). B. Initial ECG performed in the ED, with resolution of Brugada pattern ST-segment elevations (red box).

dioxide 67 millimeters of mercury (mm Hg) (35–45 mm Hg), bicarbonate 13 milliequivalents per liter (mEq/L) (22–28 mEq/L), and potassium 2.4 mEq/L (3.5–5.2 mEq/L). Four

hours later, pH and potassium normalized without further intervention. The patient briefly required a norepinephrine infusion for low blood pressure and was given empiric broad

spectrum antibiotics to cover for possible sepsis. Antibiotics were discontinued after a negative infectious workup.

An echocardiogram and computed tomography of the head, chest, abdomen, and pelvis were unremarkable. The patient was admitted to the intensive care unit and underwent targeted temperature management. An ECG from hospital day five re-demonstrated a type 1 Brugada pattern (Image 3A), and an ECG from hospital day 10 showed a type 3 Brugada pattern (Image 3B).² Given the re-demonstration of Brugada patterns despite normalization of laboratory derangements and no other identified cause of cardiac arrest, he was diagnosed with Brugada syndrome. No formal

electrophysiologic testing was performed. He was discharged on hospital day 28 with a LifeVest (Zoll Medical Corporation, Pittsburgh, PA) after a near-complete physical and neurologic recovery, and he underwent outpatient automatic-implantable-cardioverter-defibrillator (AICD) placement. Genetic testing performed later as an outpatient was inconclusive.

DISCUSSION

Brugada syndrome is characterized electrocardiographically by ≥ 2 mm ST-segment elevation in leads V_1 – V_2 with either “coved type” (type 1) or

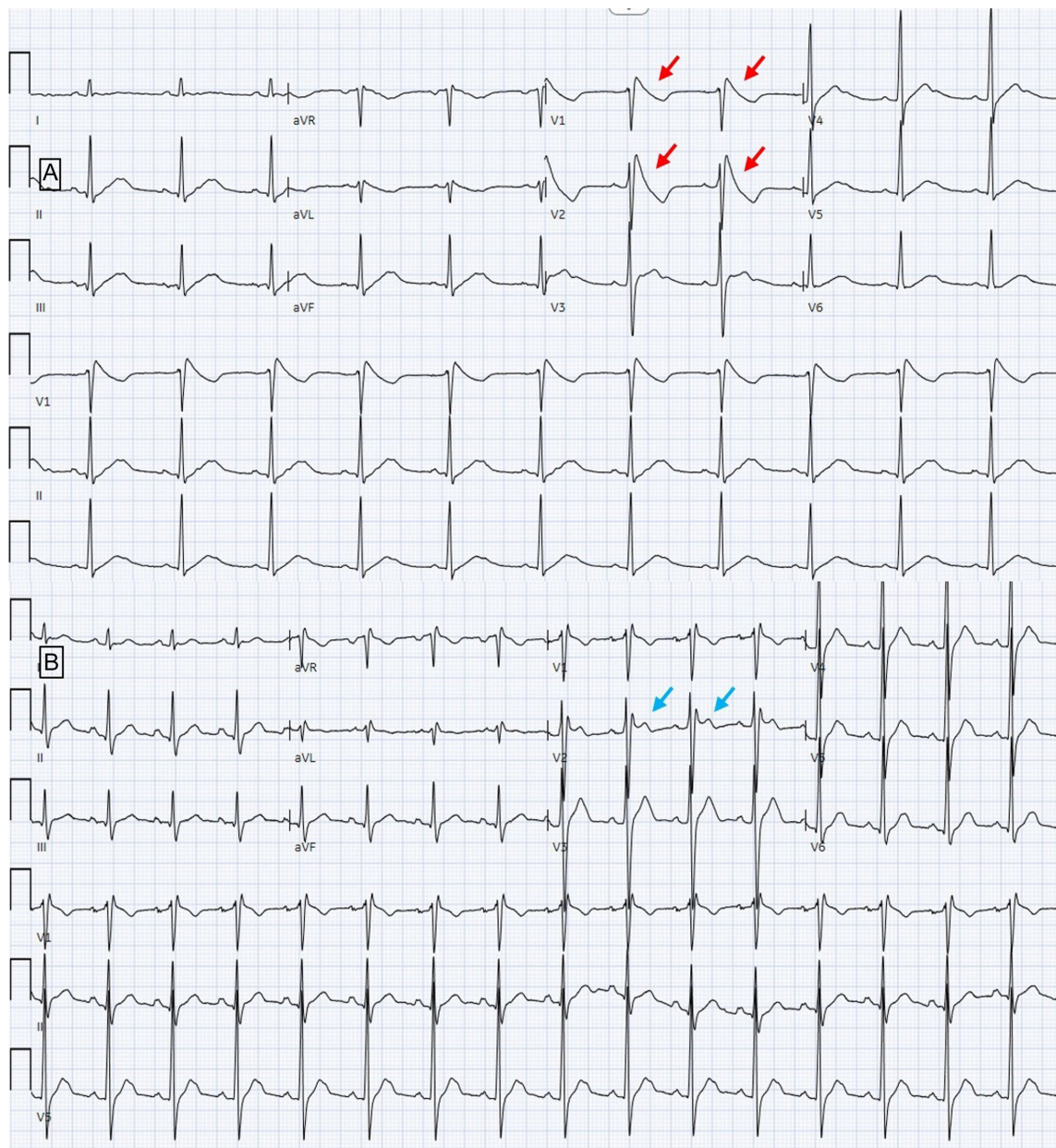


Image 3. A. Electrocardiogram (ECG) performed approximately 60 hours post initial cardiac arrest, again with down-sloping ST-segment (Type 1) elevations in leads V_1 – V_2 (red arrows). B. ECG performed 10 days after initial cardiac arrest showing saddleback ST-segment elevation < 2 mm (type 3) in lead V_2 (blue arrows).

CPC-EM Capsule

What do we already know about this clinical entity?

The absence of classic Brugada patterns (“coved” or “saddleback” ST-segment elevations) on isolated electrocardiograms (ECG) does not exclude the diagnosis.

What is the major impact of the images?

Images depict dynamic changes between Brugada patterns and normal ECGs, from cardiac arrest to automatic implantable cardioverter-defibrillator placement.

How might this improve emergency medicine practice?

Serial ECGs are important in diagnosis, as sudden cardiac death is often the first or only presentation of Brugada syndrome.

patterns and normal rhythms on ECG. This highlights the importance of serial ECGs in diagnosis, as sudden cardiac death is often the first or only presentation of Brugada syndrome.⁴

The authors attest that their institution requires neither Institutional Review Board approval, nor patient consent for publication of this case report. Documentation on file.

Address for Correspondence: Mark L. Moubarek, MD, University of California, Davis, Department of Emergency Medicine, 450 V Street, Patient Support Services Building, Suite 2100, Sacramento, CA 95817. Email: mlmoubarek@ucdavis.edu

Conflicts of Interest: By the CPC-EM article submission agreement, all authors are required to disclose all affiliations, funding sources and financial or management relationships that could be perceived as potential sources of bias. The authors disclosed none.

Copyright: © 2024 Moubarek et al. This is an open access article distributed in accordance with the terms of the Creative Commons Attribution (CC BY 4.0) License. See: <http://creativecommons.org/licenses/by/4.0/>

“saddleback” (type 2) ST-segment morphology, or ≤ 2 mm ST-segment elevation in V_1 – V_2 with either “coved” or “saddleback” morphology (type 3).^{1,2} The absence of these patterns on isolated ECGs does not exclude the diagnosis, as dynamic fluctuations in ECG patterns are well-documented and can occur in response to medications, fever, exercise or other stressors.^{1,3} While this patient did not undergo formal electrophysiologic testing, established diagnostic criteria do not necessitate this, and its utility is questionable in VF-survivors.² Similarly, this patient’s genetic testing was inconclusive; only 10–30% of patients have been successfully genotyped, owing to the broad heterogeneity and complexity of underlying genetic risk factors that can predispose an individual to Brugada syndrome.²

This case provides an uncommon, complete electrocardiographic history of Brugada syndrome, from out-of-hospital cardiac arrest to AICD placement and depicts classic dynamic fluctuations between Brugada

REFERENCES

1. Priori SG, Wilde AA, Horie M, et al. HRS/EHRA/APHR expert consensus statement on the diagnosis and management of patients with inherited primary arrhythmia syndromes: document endorsed by HRS, EHRA, and APHR in May 2013 and by ACCF, AHA, PACES, and AEPC in June 2013. *Heart Rhythm*. 2013;10(12):1932–63.
2. Wilde AA, Antzelevitch C, Borggrefe M, et al. Proposed diagnostic criteria for the Brugada syndrome: consensus report. *Circulation*. 2002;106(19):2514–9.
3. Veltmann C, Schimpf R, Echtermach C, et al. A prospective study on spontaneous fluctuations between diagnostic and non-diagnostic ECGs in Brugada syndrome: implications for correct phenotyping and risk stratification. *Eur Heart J*. 2006;27(21):2544–52.
4. Probst V, Veltmann C, Eckardt L, et al. Long-term prognosis of patients diagnosed with Brugada syndrome: results from the FINGER Brugada syndrome registry. *Circulation*. 2010;121(5):635–43.

JOIN
CAL/AAEM!



CALAAEM

CALIFORNIA CHAPTER MEMBER OF THE
AMERICAN ACADEMY OF EMERGENCY MEDICINE

*Championing
individual physician rights
and workplace fairness*

BENEFITS

- Western Journal of Emergency Medicine Subscription
- CAL/AAEM News Service email updates
- Discounted AAEM pre-conference fees
- And more!

CAL/AAEM NEWS SERVICE

- Healthcare industry news
- Public policy
- Government issues
- Legal cases and court decisions

In collaboration with our official journal

WestJEM Integrating Emergency Care
with Population Health



FACEBOOK.COM/CALAAEM



FOLLOW US @CALAAEM

[HTTP://WWW.CALAAEM.ORG](http://www.calaaem.org)

AdvancED 2024 Conference

Emergency Medicine Reimagined ED

Friday

6

Sept.

Sheraton Park Hotel

Anaheim, CA

www.californiaacep.org

