

UCLA

Proceedings of UCLA Health

Title

Abnormal Breathing after Vagal Nerve Stimulator Implantation (VNS)

Permalink

<https://escholarship.org/uc/item/4802s63q>

Journal

Proceedings of UCLA Health, 28(1)

Authors

Chang, Melisa

Padilla, Alfonso

Rojanapairat, Oragun

Publication Date

2024-04-04

CLINICAL VIGNETTE

Abnormal Breathing after Vagal Nerve Stimulator Implantation (VNS)

Melisa Chang, MD^{1,2}, Alfonso Padilla, MD² and Oragun Rojanapairat, MD³

¹Department of Medicine, Division of Pulmonary, Critical Care, and Sleep Medicine, Veterans Affairs Greater Los Angeles Healthcare System, Los Angeles, CA

²Department of Medicine, Division of Pulmonary, Critical Care, and Sleep Medicine, University of California, Los Angeles, CA

³Department of Medicine, Division of Pulmonary and Critical Care Medicine, Cedars-Sinai Medical Center, Los Angeles, CA

Introduction

Vagal Nerve Stimulation (VNS) is a valuable treatment for medically refractory epilepsy, although the mechanism of action is not fully understood. Common side effects of VNS include sensory abnormalities of the neck, voice alteration, cough, and shortness of breath. This patient demonstrates that OSA may be an additional potential side effect of VNS.

Case Report

A 22-year-old male with autism and intractable focal epilepsy underwent VNS implantation. After surgery, the patient's father noticed abnormal breathing during sleep. The patient underwent a diagnostic polysomnogram (PSG) (Figure 1), which

showed an apnea-hypopnea index (AHI) of 21 events per hour. The apneas and hypopneas correlated with VNS activation. The patient was started on auto-titrating continuous positive airway pressure (APAP) at 4-16 cm H₂O. Post treatment residual AHI remained elevated. He then underwent a PSG titration study (Figure 2) and was titrated to continuous positive airway pressure (CPAP) at 16 cm H₂O or bilevel positive airway pressure (BiPAP) at 21/14 cm H₂O. The PAP setting was changed, but the residual AHI remained elevated and did not improve. The VNS was also deemed ineffective at treating his seizures, and the VNS settings were gradually lowered. With each voltage reduction, the residual AHI improved during PAP moderm checks. Eventually, the residual AHI became normal and CPAP therapy was discontinued.

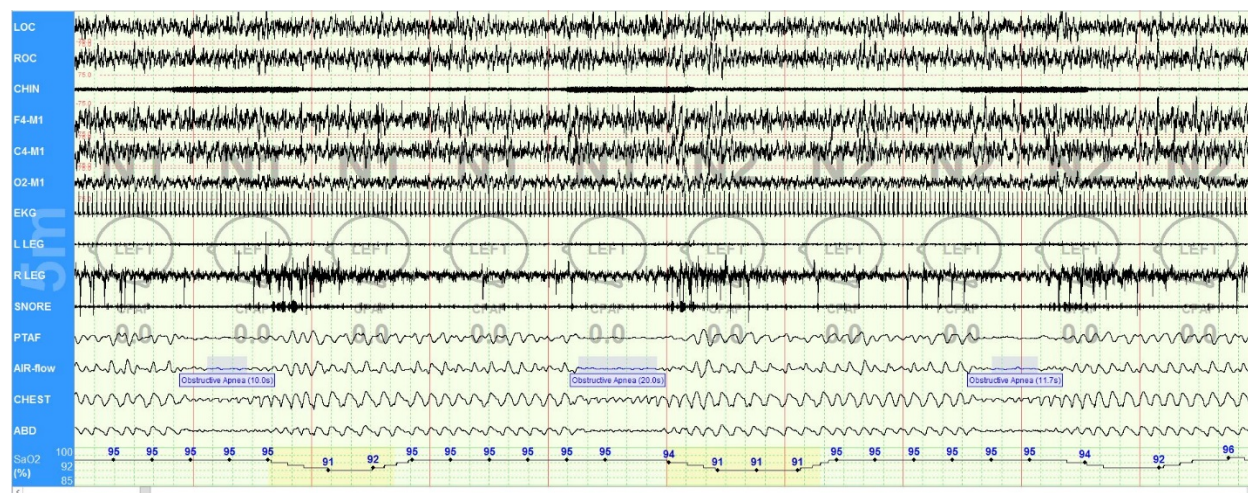


Figure 1. Baseline polysomnogram

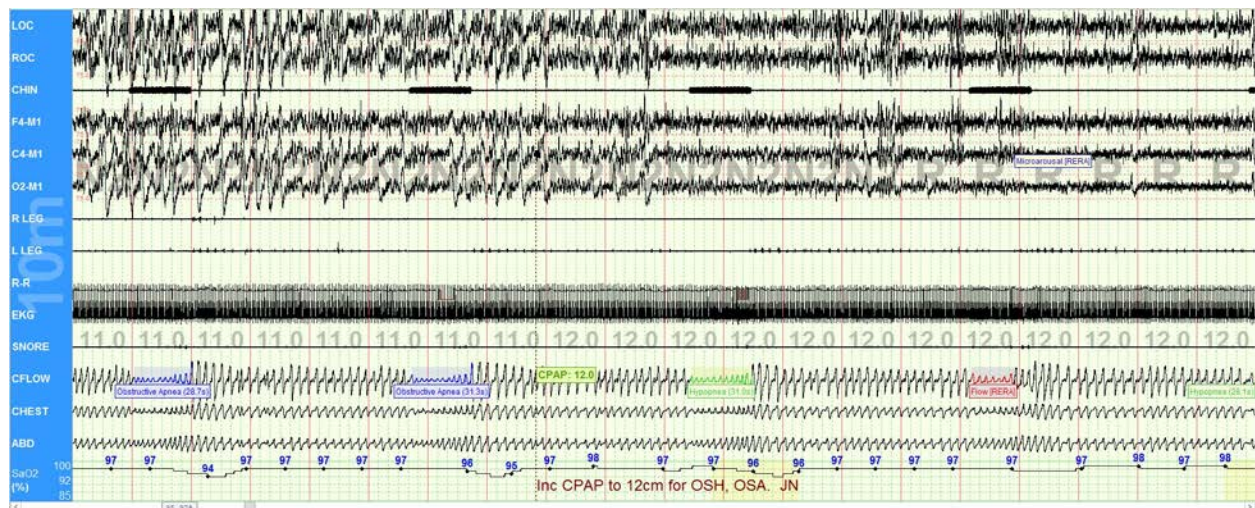


Figure 2. PAP titration.

Discussion

VNS is a neuromodulatory therapy widely used in drug-resistant epilepsy. It has shown to reduced seizure frequency in 26-40% of patients within 1 year.^{1,2} The mechanism of action of VNS in epilepsy is not fully understood, but may be related to the noradrenergic and serotonergic systems, modulation of inflammatory processes, altered activity in the limbic system, and desynchronizing effects of the VNS.²

Common side effects of VNS therapy include voice alteration (50% of patients at 12 months), sensory abnormalities in the neck (15% of patients at 12 months), cough (15% at 12 months), and shortness of breath (15% at 12 months).² VNS has also been reported to affect sleep respirations, including increases in respiratory rate and decreases in respiratory amplitude.³ Marzec et al. reported that 5 out of 16 patients with VNS had significantly increased AHI on PSGs. The respiratory patterns were consistent with obstructive apneas and hypopneas during VNS activation.⁴ It is thought that reduction in the laryngeal space by left vocal cord adduction during VNS stimulation may be contributing to the VNS-triggered hypopneas and apneas.⁵ Once case report noted a patient developed central sleep apnea after VNS implantation. During the PSG, hyperventilation occurred during VNS activation followed by a central apnea.⁶ VNS-induced sleep disordered breathing is a complex phenomenon, and additional research is needed to understand its underlying mechanism.

This patient's obstructive apneas worsened with VNS therapy. Screening for OSA in patients who require VNS therapy should be strongly considered.

REFERENCES

1. **Panebianco M, Rigby A, Weston J, Marson AG.** Vagus nerve stimulation for partial seizures. *Cochrane Database Syst Rev.* 2015 Apr 3;2015(4):CD002896. doi: 10.1002/14651858.CD002896.pub2. Update in: *Cochrane*

Database Syst Rev. 2022 Jul 14;7:CD002896. PMID: 25835947; PMCID: PMC7138043.

2. **Pérez-Carbonell L, Faulkner H, Higgins S, Koutroumanidis M, Leschziner G.** Vagus nerve stimulation for drug-resistant epilepsy. *Pract Neurol.* 2020 May;20(3):189-198. doi: 10.1136/practneurol-2019-002210. Epub 2019 Dec 31. PMID: 31892545.
3. **Murray BJ, Matheson JK, Scammell TE.** Effects of vagus nerve stimulation on respiration during sleep. *Neurology.* 2001 Oct 23;57(8):1523-4. doi: 10.1212/wnl.57.8.1523. Erratum in: *Neurology* 2002 Feb 26;58(4):672. PMID: 11673612.
4. **Marzec M, Edwards J, Sagher O, Fromes G, Malow BA.** Effects of vagus nerve stimulation on sleep-related breathing in epilepsy patients. *Epilepsia.* 2003 Jul;44(7):930-5. doi: 10.1046/j.1528-1157.2003.56202.x. PMID: 12823576.
5. **Zambrelli E, Saibene AM, Furia F, Chiesa V, Vignoli A, Pipolo C, Felisati G, Canevini MP.** Laryngeal motility alteration: A missing link between sleep apnea and vagus nerve stimulation for epilepsy. *Epilepsia.* 2016 Jan;57(1):e24-7. doi: 10.1111/epi.13252. Epub 2015 Nov 20. PMID: 26589721.
6. **Papacostas SS, Myrianthopoulou P, Dietis A, Papathanasiou ES.** Induction of central-type sleep apnea by vagus nerve stimulation. *Electromyogr Clin Neurophysiol.* 2007 Jan-Feb;47(1):61-3. PMID: 17375884.