

# UCLA

## UCLA Previously Published Works

### Title

Harnessing imaging tools to guide immunotherapy trials: summary from the National Cancer Institute Cancer Imaging Steering Committee workshop.

### Permalink

<https://escholarship.org/uc/item/47z9848t>

### Journal

The Lancet Oncology, 24(3)

### Authors

Shankar, Lalitha

Schöder, Heiko

Sharon, Elad

et al.

### Publication Date

2023-03-01

### DOI

10.1016/S1470-2045(22)00742-2

Peer reviewed



# HHS Public Access

Author manuscript

*Lancet Oncol.* Author manuscript; available in PMC 2024 March 01.

Published in final edited form as:

*Lancet Oncol.* 2023 March ; 24(3): e133–e143. doi:10.1016/S1470-2045(22)00742-2.

## Harnessing imaging tools to guide immunotherapy trials: summary from the National Cancer Institute Cancer Imaging Steering Committee workshop

**Lalitha K. Shankar, MD.,**

Clinical Trials Branch, National Cancer Institute, 9609 Medical Center Dr., Rockville, MD, USA

**Heiko Schöder, MD. [Prof.],**

Department of Radiology, Memorial Sloan Kettering Cancer Center, 1275 York Ave., New York, NY, USA

**Elad Sharon, MD.,**

Investigational Drug Branch, National Cancer Institute, 9609 Medical Center Dr., Rockville, MD, USA

**Jedd Wolchok, MD. [Prof.],**

Meyer Cancer Center, Weill Cornell Medicine, 1300 York Avenue, New York, NY, USA

**Michael V. Knopp, MD. [Prof.],**

Department of Radiology, Ohio State University, 395 W. 12<sup>th</sup> Ave, 4<sup>th</sup> fl., Columbus, OH, USA

**Richard L. Wahl, MD. [Prof.],**

Department of Radiology, Washington University, 510 S. Kingshighway Blvd., St. Louis, MO, USA

**Benjamin M. Ellingson, PhD. [Prof.],**

Department of Radiological Sciences, University of California Los Angeles, 924 Westwood Blvd., Los Angeles, CA, USA

**Nathan C. Hall, MD.,**

Department of Radiology, University of Pennsylvania, 3900 Woodland Ave., Philadelphia, PA, USA

**Martin J. Yaffe, PhD. [Prof.],**

Medical Biophysics, University of Toronto, 2075 Bayview Ave., Toronto, ON, Canada, USA

**Alexander J. Towbin, MD. [Prof.],**

---

*Corresponding Author:* lalitha.shankar@nih.gov; 240-276-5936.

Contributors

LKS, HS, ES, JW, MK, RW, BE, NH, MY, AT, MF, DP, TYP, CW, LS, MH, UM, AW, DL, EdV, and SR conceptualised this Policy Review and developed the methods. All authors curated, analysed, and interpreted the data. LKS, JW, MK, RW, AW, EdV, and GB contributed the figures. YT wrote the original first draft. All authors revised, reviewed, and approved the final version.

All other authors declare no competing interests.

**Publisher's Disclaimer:** This is a PDF file of an unedited manuscript that has been accepted for publication. As a service to our customers we are providing this early version of the manuscript. The manuscript will undergo copyediting, typesetting, and review of the resulting proof before it is published in its final form. Please note that during the production process errors may be discovered which could affect the content, and all legal disclaimers that apply to the journal pertain.

Department of Radiology and Medical Imaging, Cincinnati Children's Hospital, 3333 Burnet Ave., Cincinnati, OH, USA

**Michael D. Farwell, MD.,**

Department of Radiology, University of Pennsylvania, 3400 Spruce St., Philadelphia, PA, USA

**Daniel Pryma, MD. [Prof.],**

Department of Radiology, University of Pennsylvania, 3400 Spruce St., Philadelphia, PA, USA

**Tina Young Poussaint, MD. [Prof.],**

Department of Radiology, Boston Children's Hospital, 300 Longwood Ave., Boston, MA, USA

**Chadwick L. Wright, MD.,**

Department of Radiology, The Ohio State University, 395 W. 12<sup>th</sup> Ave, 4<sup>th</sup> fl., Columbus, OH, USA

**Lawrence Schwartz, MD. [Prof.],**

Department of Radiology, Columbia University, 622 W. 168<sup>th</sup> St., New York, NY, USA

**Mukesh Harisinghani, MD. [Prof.],**

Department of Radiology, Massachusetts General Hospital, 55 Fruit St., White 270, Boston, MA, USA

**Umar Mahmood, MD. [Prof.],**

Department of Radiology, Massachusetts General Hospital, 55 Fruit St., #148, Boston, MA, USA

**Anna M. Wu, PhD. [Prof.],**

Department of Immunology & Theranostics, City of Hope Comprehensive Cancer Center, 1500 East Duarte Rd., Duarte, CA, USA

**David Leung, MD.,**

Bristol Myers Squibb, 3551 Lawrenceville Rd., Princeton, NJ, USA

**Elisabeth G.E. de Vries, MD. [Prof.],**

Department of Medical Oncology, University Medical Centre Groningen, University of Groningen, Groningen, Netherlands

**Ying Tang, PhD.,**

CCS Associates, 1420 Spring Hill Road, Suite 335, McLean, VA, USA

**Gillian Beach, PhD.,**

The Emmes Company, 401 N. Washington St., Suite 700, Rockville, MD, USA

**Steven A. Reeves, PhD.**

Coordinating Center for Clinical Trials, National Cancer Institute, 9609 Medical Center Dr., Rockville, MD, USA

## Summary

As the immuno-oncology (IO) field continues the rapid growth witnessed over the past decade, optimizing patient outcomes requires an evolution in the current response assessment guidelines for phase 2 and 3 immunotherapy clinical trials and clinical care. Additionally, investigational tools—including image analysis of standard-of-care scans (such as CT, MR and PET) using analytics such as radiomics, functional MR agents, and novel molecular imaging PET agents—

offer promising advancements for assessment of immunotherapy. In order to document current challenges and opportunities and identify next steps in IO diagnostic imaging, the NCI Clinical Imaging Steering Committee convened a meeting with diverse representation among imaging experts and oncologists to generate a comprehensive review of the state of the field. This report provides the summary of that review.

## Introduction

The past decade has witnessed the success of immunotherapies in treating a range of cancers, primarily driven by immune checkpoint inhibitors and genetically engineered T cells (e.g., chimeric antigen receptor [CAR] T cells). Immunotherapies include several other classes of agents, such as vaccines, cytokines, and antibodies and their derivatives (e.g., radioimmunotherapy, antibody-drug conjugates, and bispecific antibodies).<sup>1</sup> Currently, immune checkpoint inhibitors are the most widely used drugs in this class. It has been recognized that certain aspects of the radiological response patterns of immunotherapies are not adequately accounted for by conventional response criteria such as RECIST (Response Evaluation Criteria in Solid Tumours) and RANO (Response Assessment in Neuro-Oncology). To better guide drug development and patient care, modified criteria have been proposed,<sup>2–7</sup> and novel, complementary molecular imaging approaches are being developed to assess immunotherapy-induced changes in the tumour and its microenvironment that are more closely reflective of clinical outcomes.<sup>8,9</sup>

In order to provide a comprehensive review of the state of the field and offer guidance on next steps, the NCI Clinical Imaging Steering Committee (CISC) convened a virtual meeting entitled “Harnessing Imaging Tools to Guide Immunotherapy Trials” on April 6, 2021. This meeting brought together imaging experts at the forefront of government and industry efforts to advance imaging in immune-oncology (IO) trials with the objectives of (1) reviewing the utility of available diagnostic imaging tools (CT, MR, FDG PET) and the current response assessment guidelines for assessing immunotherapy such as RECIST, iRECIST and iRANO for predicting response in phase 2 and 3 immunotherapy clinical trials or clinical care; and (2) assessing the role of investigational tools including image analysis of standard-of-care (SOC) scans such as CT, MR and PET using more advanced analytics such as texture, volume and radiomics, functional MR agents, and novel molecular imaging PET agents. Particular attention was paid to imaging agents that can be integrated into multicentre phase 2 and phase 3 trials in US National Cancer Institute’s National Clinical Trials Network (NCI NCTN; Figure 1) and the NCI Community Oncology Research Program (NCORP). The following review highlights the landscape of different clinical imaging modalities, including both SOC and investigational approaches, as well as strategies and pathways for validating the novel imaging tools through either prospective trials or retrospective data analysis (see Table 1, Figure 2, and Appendix pp. 1–4).

## Current Clinical Landscape and Standard of Care

### **The global landscape of immunotherapy oncology trials and NCI strategy—**

The IO field has seen continued growth over the past several years with an increasing number of drugs in the development pipeline and in clinical trials covering a wide range

of targets (e.g., LAG3, TIGIT, CTLA4, PD-L1, PD-1).<sup>10</sup> There are currently two CTLA4 agents, 7 PD1/PDL1 agents, and one LAG3 agent which have received FDA approval. There were close to 5,000 IO drugs in development in 2020, and over 6,000 active clinical trials investigating IO agents. This trend is also reflected in the NCI Cancer Therapy Evaluation Program (CTEP) program. There are currently 128 active IO trials across NCI trial networks with an accrual of 8,000 patients, with most investigating anti-programmed cell death-1/programmed cell death-ligand 1 (PD-1/PD-L1) as single agents or in novel combinations.

Immunotherapy has shown remarkable activity in a variety of cancers, but only a minority of patients receive durable benefit.<sup>11,12</sup> Strategies to optimize patient outcomes may rely on the use of biomarkers, including imaging biomarkers, to elucidate the interaction between the tumour and the immune system at the cellular and molecular levels, thereby providing insight into rational combination therapies to overcome intrinsic or acquired resistance. Imaging biomarkers may be useful in the development of immunotherapy in a range of applications providing prognostic, predictive or pharmacodynamic signals or for assessment of response to therapy. The mechanism of action for immunotherapy often involves the activation of tumour-infiltrating lymphocytes and the interplay of immune cells within the tumour microenvironment, which may manifest as enlargement of masses on CT and may be misinterpreted as tumour growth – also known as “pseudoprogression” (see Appendix pp. 1 for an example of this phenomenon). New criteria (e.g., iRECIST<sup>4</sup> and imRECIST, or immune-modified RECIST,<sup>5</sup> among others) that attempt to capture the differing patterns of immunotherapy treatment responses have been developed but have not yet been fully validated. This is primarily because of the need for ongoing data collection or the outright lack of inclusion of the necessary patient-level data to allow for proper validation of these new response criteria.

Despite tremendous progress in IO therapy, more work remains. Collection of additional data and the provision of greater shared data access can allow for evaluations of competing criteria. Further evaluation of pseudoprogression may be improved with biopsy-driven, translational research efforts to help better characterize these phenomena.

### **Clinical characterization and timing of response to checkpoint blockade treatment, and efforts in improving response evaluation of IO therapy—**

The importance of rethinking imaging in response assessment to IO therapy was realized from the initial clinical trials of ipilimumab, a fully human monoclonal antibody that blocks the critical immune checkpoint cytotoxic T-lymphocyte antigen-4 (CTLA-4).<sup>13</sup> In these studies, a transient T cell infiltration in the tumour microenvironment could not be distinguished conclusively from true progression using standard imaging criteria or standard imaging technologies. Also complicating the assessment is the mechanism-based time delay in response to IO therapy as compared with chemo or targeted therapy on which the traditional response criteria are based. There are general response patterns across immune checkpoint inhibitors such as PD-1 and PD-L1 blockade agents. These patterns of response to IO therapy may not be adequately reflected in the conventional RECIST criteria, prompting alternative response assessment metrics based on retrospective analysis of phase 2 and phase 3 IO trial data. These include immune-related response criteria (irRC),<sup>2</sup> irRECIST,<sup>3</sup> iRECIST,<sup>4</sup> and imRECIST.<sup>5</sup> In addition to modified response criteria,

innovative molecular imaging agents are being developed, which could shed light on the possibility of pseudoprogression being due to immune infiltration. Several of them are discussed below. One approach that is currently in the most advanced stage of development is a zirconium-89 labelled CD8 minibody ( $^{89}\text{Zr-Df-IAB22M2C}$ ) PET imaging agent, being studied in phase 2 clinical trials in patients being treated with immune checkpoint blockade agents (NCT03802123; NCT05013099), that has been shown to accumulate in CD8+ T cells in tumour lesions.<sup>14,15</sup>

### **Evolving Tumour Metrics: from morphology to metabolism**

Although consensus guidelines for multiple alternative response metrics (e.g., irRC, irRECIST, iRECIST, and imRECIST) have been published, none has been adequately evaluated. Efforts are being made to assist with collecting additional data elements as proposed in iRECIST and ultimately to facilitate the evaluation of these modified response assessment metrics. Other response assessment criteria, such as PET response criteria in solid tumours (PERCIST) and RANO, are also undergoing similar evolution as IO therapy becomes increasingly available for a broader range of cancer types.

**Modified RECIST metrics: facilitating validation of consensus guidelines for response assessment of immunotherapy**—Evaluation and eventual validation of these proposed consensus guidelines for response assessment of immunotherapy require the imaging community to continue to work closely with the clinical oncology community in implementing these modified RECIST metrics in clinical trials. The primary issue for these modified criteria is to address the concept of new lesions, which may be part of the immune response not necessarily related to progressive disease. With the collection of data, we will be able to assess how often this phenomenon occurs in conjunction with specific therapies and in specific solid tumours. Likewise, iRECIST may be better able differentiate stable and progressive disease both categorically in a clinical trial and in an individual patient. In some cases, stable disease alone provides clinical benefit, so it is critical to make sure that this information is optimally collected. It is imperative that essential data elements recommended in these guidelines are collected in a structured way to not only enable these modified RECIST metrics to be evaluated, but also to provide the “ground truth” for the development of new imaging tools and biomarkers for IO therapy. To facilitate consistent data collection to maximize data usability in validating iRECIST, the NCI Imaging and Radiation Oncology Core (iROC) has developed electronic forms that can be integrated into the workflow of CT and MRI in clinical care and clinical trials, making it easier for radiologists to document and collect data elements per iRECIST. These data recording tools are being made available to the imaging community (<https://iRECIST-Tool.iroco.org>). Other network groups also have similar initiatives to facilitate consistent data collection. These studies are assessing the performance of both RECIST and iRECIST in predicting clinical outcomes such as progression free survival (PFS).

**mRANO, the evolution of response assessment criteria in brain cancer, and the current state of assessing immunotherapies in the brain**—The first radiographic response assessment specific to brain tumours was introduced by Macdonald et al.<sup>16</sup> in 1990 by significantly improving upon the Levin criteria<sup>17</sup> and the WHO

oncology response criteria.<sup>18</sup> The Macdonald criteria were retained as the standard response assessment criteria for over 20 years. In 2010 the RANO (Response Assessment Neuro-Oncology) criteria were developed.<sup>19</sup> RANO is considered to be an extension of the Macdonald criteria. Notably, it includes qualitative assessments of T2/T2 FLAIR hyperintensity, although this is difficult to assess quantitatively. It also includes other important improvements, e.g., defining measurable vs. non-measurable disease, specific inclusion/exclusion criteria, requirement for confirmatory scans, recommendations for dealing with patients with equivocal imaging changes, and criteria for non-enhancing tumour progression. Similar to RECIST, RANO response assessment is divided into four categories, complete response (CR), partial response (PR), stable disease (SD), and progressive disease (PD). iRANO criteria or the Immune Response in Neuro-Oncology was proposed in 2015<sup>6</sup> to allow patients to better tolerate transient changes that might occur during initial treatment due to inflammation or pseudoprogression. A drawback of iRANO is that it includes an arbitrary 3-month window to confirm PD, which causes excessive censoring in glioblastoma (GBM) trials. An updated set of criteria (v2.0) based on new data is in development. A modified RANO (mRANO) was developed in 2017<sup>7</sup> to improve upon RANO and iRANO in assessing immunotherapy. In prospective phase 2 convection-enhanced delivery of an IL4R-targeted immunotoxin (MDNA55–05) in recurrent GBM,<sup>20</sup> mRANO outperformed both RANO and iRANO in demonstrating a correlation between radiographic progression-free survival (PFS) and OS. Currently, mRANO is being used in dozens of trials as secondary and exploratory endpoints for immunotherapy and other therapeutics in GBM (examples include [NCT01564914](#), [NCT01866449](#), [NCT02441322](#), [NCT02326441](#), [NCT03296696](#), [NCT02871843](#)). The conventional RANO is still considered the “gold standard” for response assessment in GBM as the primary endpoint for regulatory purposes.

### Advanced Imaging Techniques

Apart from linear tumour size and metabolism based metrics (e.g., the immune variants of RECIST, PERCIST, and RANO), image analysis of SOC scans such as CT, MR, and PET using more advanced analytics such as volume and radiomics, functional MR agents and metabolic changes, has also shown promise in improving the tumour response assessment for IO therapies.

#### **PERCIST and FDG PET/CT in guiding immunotherapy trials—F-**

*fluorodeoxyglucose* (FDG) uptake is indicative of glucose utilisation and while elevated glucose utilisation is commonly seen in cancers,<sup>21</sup> it is not specific to cancer.<sup>22,23</sup> FDG PET has been mostly used for imaging cancers (see, for example, Appendix pp. 6), but it has also been used to image inflammatory and infectious processes.<sup>22,23</sup>

Challenges exist for FDG PET/CT in assessing response to immune checkpoint inhibitors especially early after treatment is initiated. Immune response in tumours soon after treatment can appear on FDG PET as increased uptake vs baseline signal due to imaging the immune and inflammatory infiltrate by lymphocytes and macrophages in the tumour microenvironment and, therefore, may be misinterpreted as tumour progression (pseudoprogression).<sup>4</sup> Delayed response to immune modulators also leaves a window of

time for tumours to continue to grow before therapeutic effects dominate. FDG-PET has been useful in identifying a variety of IO related adverse events in a variety of organs such as the gastrointestinal and endocrine systems.<sup>24</sup> Early identification and management can decrease the severity of such adverse events.

In addition, immune response in normal tissues can appear to suggest new tumour or tumour progression, which sometimes can be dramatic (e.g., sarcoid-like reactions).<sup>25,26</sup> Caution should be exercised when interpreting FDG PET images, particularly in the period relatively soon, days to weeks to a month or longer, after initiation of immunotherapy.

The PET Response Criteria in Solid Tumours (PERCIST 1.0) was developed to provide a framework for assessing metabolic tumour response with FDG PET.<sup>27</sup> It has been evaluated in patients treated with immune checkpoint inhibitors with more success in melanoma than in lung cancer in predicting patient outcomes (as exemplified in Appendix pp. 7).<sup>28–32</sup> It has also been applied with success in patients treated with other immunomodulators. For example, PERCIST FDG PET assessment at day 9 of anti IGF1R (Insulin-like Growth Factor 1 Receptor) antibody treatment predicted survival in sarcoma;<sup>33</sup> similarly FDG PERCIST-like criteria predicted response to <sup>131</sup>I-anti-B1 (CD20) radioimmunotherapy (RIT) treatment of non-Hodgkin's lymphoma (NHL),<sup>34</sup> and response to CAR T cell therapy.<sup>35</sup>

Given the possibility of new lesions developing or existing lesions demonstrating increased FDG uptake during therapy, PERCIST1.0 can be misleading early in assessing immunotherapy response. Several modifications of PERCIST for patients undergoing immunotherapies have been proposed (e.g., PERCIMT, iPERCIST, or imPERCIST5)<sup>36</sup>, mainly addressing how the appearance of new lesions on PET should be classified. There are currently insufficient data to prefer one set of criteria over another. Regardless, despite the challenges, FDG PET is a valuable tool in clinical studies of immune checkpoint inhibitors. It appears that pseudoprogression is fairly common with CTLA-4 blockade therapies and at early time-point assessments after treatment initiation.<sup>2,37</sup> Assessment of progression with FDG PET at three months post-therapy may reflect true progression more reliably. Currently, it is uncertain how to best assess response or progression with FDG PET at early time points after therapy, and prospective studies could be informative. Some of the considerations regarding interpreting FDG PET following immunotherapy have recently been reviewed.<sup>36,38</sup>

**Advanced analytics for CT images: radiomics**—There is great potential for developing radiomic biomarkers for IO trials by taking advantage of all the existing imaging data and clinical outcome data from completed clinical studies. Radiomics, which extracts quantitative features from medical images using data characterization algorithms, has the potential to uncover disease characteristics that are difficult to identify by visual assessment. While the concept of radiomics is not new, recent advances in computing and feature classification now enable quantification of image features and uncover the relationship of these features or their change over time with other molecular parameters or clinical outcomes. Because of the higher dimensions of data used to derive certain radiomic features, compared to what is typically utilized for conventional imaging assessment, radiomic feature analysis presents tremendous promise to improve understanding of the disease



and its progression with or without treatment. Of particular interest is its potential to address the challenges in evaluating response to IO therapies. In a recent study, the CT radiomic signature of CD8+ cells predicted the immune phenotype of tumours and inferred clinical outcomes for cancer patients who had been treated with anti-PD-1 or anti-PD-L1 immunotherapy.<sup>39</sup> In patients with lung cancer, radiomic phenotypes derived from CT images were associated with underlying molecular pathways.<sup>40</sup> Ongoing efforts to evaluate cohorts of patients from Lung-MAP are underway.<sup>41</sup> In a cohort of patients with melanoma treated with pembrolizumab from two phase 3 trials, a composite radiomic feature outperformed RECIST in predicting overall survival (OS);<sup>42</sup> radiomic signatures also helped identify pseudoprogression in IO trials earlier than iRECIST. Before radiomic signatures may be used for clinical care or regulatory decision-making for drug development, it is important to understand factors that influence the reproducibility of imaging radiomic feature extraction. Several parameters were studied,<sup>43–45</sup> and additional efforts may be needed to define and standardize imaging acquisition and reconstruction parameters to reduce variability of radiomic feature extraction. This could prove to be a challenge in clinical practice. The role and benefit of radiomics in this context, while promising, remains to be assessed and validated in large multi-centre trials.

**Novel MRI contrast agent: ferumoxytol-enhanced MRI**—In addition to PET tracers, MRI may provide complementary information to improve response assessment of immunotherapy, and clinical trials are ongoing.<sup>46</sup>

Cancer and inflammation often co-exist and share the same tissue-infiltrating cells (lymphocytes, macrophages, and mast cells),<sup>47</sup> underscoring the role of inflammation in the tumour microenvironment. This relationship provides opportunities to image the inflammatory components of the cancer microenvironment. A high number of tumour-associated macrophages (TAM) is associated with tumour progression and overall poor prognosis in cancers of the breast, prostate, lung, and pancreas.<sup>48,49</sup> M2 macrophages are particularly important since they can promote progression and migration of tumour cells by secreting pro-angiogenic factors.<sup>50</sup> M2 TAM can be detected by immunohistochemical staining of upregulated CD163. TAM can vary across patients and across tumours and may correlate with resistance to immune checkpoint blockade agents. New therapies targeting these macrophages, are entering into clinical practice. It remains to be seen if combining these agents with the IO agents can lead to more predictable and durable responses. To answer this question, it is important to develop means to image intratumoural inflammation non-invasively to assess the contribution of TAM targeted therapies to the overall response. One approach is to use ferumoxytol, an FDA-approved agent for treatment of iron deficiency anaemia, as a contrast agent for MRI to identify tumours that have a high density of TAM to select patients for treatment with TAM modulating therapies and also for monitoring response.<sup>51,52</sup> Images obtained early (0–15 hours) after the intravenous administration of ferumoxytol largely reflect the vascular distribution of this agent, whereas images obtained at later time points (1–10 days) largely report on its uptake by macrophages. Ferumoxytol-enhanced MRI improved the detection of metastatic lymph nodes<sup>53</sup> and quantify inflammation at the target organ in type 1A diabetics with active insulinitis.<sup>54</sup> Ferumoxytol was found to co-localize with TAM in tumours, suggesting it could potentially

serve as a biomarker for primary tumours, such as in pancreatic cancer,<sup>55,56</sup> as TAMs are one of the most abundant immune cell populations in the pancreatic tumour stroma.<sup>57</sup> Ferumoxytol enhancement on MRI was also found to be correlated with TAM density in the tumours in paediatric and young adult patients with lymphoma and bone sarcoma.<sup>46</sup>

### Molecular Imaging Agents in Clinical Development

One of the main challenges complicating response assessment of IO therapies is pseudoprogression, which can be observed during immunotherapy on traditional imaging such as CT and FDG-PET CT. Novel imaging agents aiming to differentiate true tumour growth from changes in the tumour microenvironment may aid in assessing IO therapies. Imaging can take a broad range of approaches in this regard, by interrogating immune cells directly (CD3, CD8, reporter genes for CAR T), immune modulators (CTLA-4, PD-1, PD-L1), and immune cell activity (granzyme B, nucleoside analogues). A number of novel PET imaging agents currently in clinical development attempt to probe tumour microenvironment changes associated with IO therapy, and a few are highlighted below.

**PET agent targeting granzyme B: <sup>68</sup>Ga-NOTA-hGZP**—Granzyme B is a serine protease that presents in the granules of T cells including natural killer cells (NK cells) and cytotoxic T cells. When the T cells interact with tumour cells, granzyme B is released along with pore forming protein perforin, allowing active granzyme B to enter tumour cells and mediate apoptosis. <sup>68</sup>Ga-NOTA-hGZP, a gallium-68 labelled peptide targeting extracellular granzyme B in the tumour microenvironment, is proposed to be able to detect response to immune checkpoint inhibitors, tumour vaccines and CAR T cell mediated cell therapy for solid tumours.

Data from mouse models showed that <sup>68</sup>Ga-NOTA-hGZP PET imaging correlates with histological granzyme B assessment in tumours; combination therapy of anti-PD-1 plus anti-CTLA 4 antibodies produced higher PET signal intensity than anti-PD-1 monotherapy alone or vehicle. This graded response potentially allows rank ordering of efficacy early in a trial. It predicted responders and non-responders to checkpoint inhibitors before changes in CT tumour volume were present, allowing an early response assessment non-invasively.<sup>8</sup>

The agent is currently being investigated in a multicentre phase 1 trial of 20 patients with metastatic melanoma or non-small cell lung cancer (NSCLC) treated with pembrolizumab (NCT04169321). In this trial, a single <sup>68</sup>Ga-NOTA-hGZP PET is performed between day 14 and day 42 (before cycle two and through cycle three) and CT scan is performed at six months. Excisional biopsy and contrast-enhanced CT scan at the time of imaging is optional. Three sites are recruiting and scanning patients. Preliminary analysis of images showed a favourable biodistribution profile and tracer accumulation at tumour sites.

**PET agent targeting CD8+ T cells: <sup>89</sup>Zr-Df-IAB22M2C (crefmirlimab)**—The PET agent <sup>89</sup>Zr-Df-IAB22M2C (crefmirlimab) is designed to image the distribution and abundance of CD8+ T cells in the tumour microenvironment. It is composed of an engineered fully humanised anti-CD8 minibody IAB22M2C with a high binding affinity to CD8+ cells (Kd = 0.4 nM), conjugated with desferoxamine (DFO) and labelled with <sup>89</sup>Zr. Extensive in vitro study of <sup>89</sup>Zr-Df-IAB22M2C showed no impact on proliferation,

depletion, or cytokine release in normal human T-cells. In humanised mouse models there was no impact on T-cell populations or cytokine release. The anti-CD8-minibody  $^{89}\text{Zr}$ -Df-IAB22M2C revealed a high sensitivity for detecting intratumoural CD8+ T-cell infiltrates in a mouse model.<sup>58</sup>

The first-in-human phase 1 study of  $^{89}\text{Zr}$ -Df-IAB22M2C in cancer patients ([NCT03107663](#)) has been completed in patients with solid tumours eligible for/on checkpoint inhibitor therapy.<sup>14,15</sup> The agent was found to be safe and showed rapid clearance. Uptake was seen in T cell-rich tissues including spleen, bone marrow, lymph nodes; no to low uptake in normal organs (such as muscle, heart, brain, lungs). Tumour uptake was variable (SUVmax ranging from 0 to 20) and seen in 10/15 (67%) patients. The minibody protein dose range with the most favourable distribution was 0.5 to 1.5 mg, and the most favourable imaging time appeared to be 24 hours, although tumours were seen as early as one to two hours post injection.

These results were used to guide the design of the phase 2 study ([NCT03802123](#)) in patients with metastatic solid tumours who are initiating checkpoint inhibitor therapy (ipilimumab/nivolumab/ pembrolizumab SOC).  $^{89}\text{Zr}$ -Df-IAB22M2C PET/CT imaging (1 mCi; 1.5 mg cold minibody; 24 h post injection), with biopsies conducted pre-treatment (baseline) and 4–5 weeks after therapy initiation. The objectives are to investigate safety of repeat dosing and imaging, correlation of CD8 PET with CD8 immunohistochemistry and correlation with RECIST and outcome (see Appendix pp.7). This is a multi-centre ongoing trial with ten sites currently active. Several pharma companies using CD8 immuno-PET in conjunction with ongoing therapy studies are starting trials in the near future. Infrastructure to support conducting phase 2 trials has been established, including PET scanner validation and radiopharmaceutical manufacturing and supply.

Activated T-cells can also be imaged with the PET radiotracer  $^{18}\text{F}$  arabinofuranosyl guanine ( $^{18}\text{F}$ -AraG).<sup>59,60</sup> Following cellular uptake and phosphorylation by mitochondrial dGK and (to lesser degree) cytoplasmatic dCK enzymes,  $^{18}\text{F}$ -AraG becomes trapped inside the cell. While its uptake is not cell-specific, activated CD8+ cells show the greatest increase in uptake as compared to baseline.<sup>60</sup> Initial small clinical phase 2 trials are ongoing in patients with lymphomas and solid tumours, correlating the imaging signal with T-cell infiltrates in tumour biopsies and RECIST responses to treatment with CAR T-cells and immune checkpoint inhibitors ([NCT05096234](#) and [NCT04260256](#) respectively).

**PET agents targeting PD-1 and PD-L1:  $^{18}\text{F}$ -BMS-986192 (anti-PD-L1),  $^{68}\text{Ga}$ -BMS-986192 (anti-PD-L1),  $^{89}\text{Zr}$ -nivolumab (anti-PD-1)**—PET imaging agents targeting PD-1 or PD-L1 can non-invasively quantify their protein levels, therefore, may serve as predictive biomarkers for treatment efficacy of PD-1 or PD-L1 blockade agents. An anti-PD-L1 adnectin (BMS-986192) labelled with  $^{18}\text{F}$  was studied along with  $^{89}\text{Zr}$ -nivolumab for PET imaging in a first-in-human phase 1 study in NSCLC patients treated with nivolumab ([NCT03520634](#)). Uptake of both agents in tumours quantified by PET correlated with PD-L1 and PD-1 expression in tumour biopsies assessed by immunohistochemistry. Tumour uptake of both tracers correlates with response to nivolumab treatment.<sup>61</sup>

An ongoing phase 1 study in patients with recurrent/metastatic head and neck squamous cell carcinoma ([NCT03843515](#)) is evaluating serial PET imaging with  $^{18}\text{F}$ -BMS-986192 (anti-PD-L1) and  $^{18}\text{F}$ -FDG at baseline and after a single dose of nivolumab in the neoadjuvant setting. The primary endpoint is serious adverse events, tumour SUVmax for FDG-PET/anti-PD-L1 PET; the secondary endpoint is to study correlation between PET data and blood/tissue markers.

Advances in radiochemistry also facilitate the development of novel PET agents. The two-step radiolabelling of short-lived  $^{18}\text{F}$  for BMS-986192 presents challenges for clinical application. To optimize the PET tracer for anti-PD-L1 adnectin BMS-986192, a simpler, one-step labelling chemistry was developed for conjugation with  $^{68}\text{Ga}$ .<sup>62</sup>  $^{68}\text{Ga}$ -BMS-986192 has shown favourable imaging properties in PD-L1 positive xenograft tumours in animal models and is to be tested in the clinic.<sup>62</sup>

**Additional PET agents targeting PD-1, PD-L1 and CD8:  $^{89}\text{Zr}$ -atezolizumab (anti-PD-L1),  $^{89}\text{Zr}$ -CX-072 (anti-PD-L1),  $^{89}\text{Zr}$ -pembrolizumab (anti-PD-1),  $^{89}\text{Zr}$ -ZED88082A (anti-CD8)**—Several other PET imaging agents targeting PD-1, PD-L1, or CD8 are showing promise in clinical development. The PET imaging agent  $^{89}\text{Zr}$ -atezolizumab (anti-PD-L1) was administered pre-treatment in patients with solid tumours; these patients were then treated with atezolizumab until disease progression. Part A of the study assessed tracer protein dose for imaging and schedule; Part B implemented imaging using the optimal dose and imaging timepoint (day seven post-injection) ([NCT02453984](#) and [NCT02478099](#)).<sup>63</sup> In total 22 patients were evaluable.  $^{89}\text{Zr}$ -atezolizumab uptake was high in lymphoid tissues and at sites of inflammation; uptake was high in tumours but heterogeneous, varying within and among lesions, patients, and tumour types.  $^{89}\text{Zr}$ -atezolizumab tumour uptake correlated with RECIST response, PFS and OS. PFS and OS correlated not with PD-L1 staining of tumour biopsies.

The second agent is a probody, CX-072, a protease-activatable anti-PD-L1 antibody. CX-072 can be activated in vivo by proteases present in the tumour microenvironment, thereby potentially reducing anti-PD-L1-mediated toxicities. In a mouse model,<sup>64</sup>  $^{89}\text{Zr}$ -CX-072 accumulates specifically in PD-L1-expressing tumours with limited uptake in peripheral lymphoid tissues. The imaging agent may support the development of CX-072 as an immunotherapy<sup>65</sup> ([NCT03013491](#)). The first-in-human biodistribution and pharmacokinetic study showed  $^{89}\text{Zr}$ -CX-072 uptake in tumour and modest uptake in normal lymphoid organs, with no unexpected uptake in other healthy tissues.<sup>66</sup>

A study with  $^{89}\text{Zr}$ -pembrolizumab in 18 patients with melanoma and NSCLC before receiving treatment with anti PD-1 antibody showed  $^{89}\text{Zr}$ -pembrolizumab uptake in tumour lesions correlated with treatment response and patient survival (Appendix pp. 8).  $^{89}\text{Zr}$ -pembrolizumab also showed uptake in lymphoid tissues and at sites of inflammation.<sup>9</sup>

In the PET imaging study with a zirconium-89 ( $^{89}\text{Zr}$ ) labelled one-armed CD8-specific antibody  $^{89}\text{Zr}$ -ZED88082A ([NCT04029181](#)), CD8 two days after tracer injection, uptake can be seen in lymphoid tissues and tumour lesions.<sup>67</sup> Uptake in tumour lesions was heterogeneous within and between patients. It can be concluded that these studies provide insight into

critical characteristics for immunotherapy and in the heterogeneity of their presence between lesions in a patient and between patients, information not obtained with a biopsy from a single tumour site.

## Discussion

Imaging remains the primary tool for assessing treatment effect in solid tumours and lymphomas. Conventional response assessment criteria such as RECIST, RANO, and Response Assessment in Pediatric Neuro-Oncology (RAPNO) are the current standard for regulatory decisions despite shortcomings in differentiating true tumour growth from immune cell infiltration in the tumour microenvironment (i.e., pseudoprogression) subsequent to immune therapies, especially immune checkpoint inhibitors. Modified consensus guidelines for response assessment of immune therapies attempt to tease out the effects of immune response from true tumour growth primarily by delaying the time of tumour imaging assessment after immune therapies until the immune response presumably has subsided. These modified guidelines have shown a better correlation with clinical outcomes in retrospective analyses in a few studies; however, validation is required using a larger number of cases of retrospective data or/and prospective data. Emerging techniques, including radiomics derived from CT or MRI, novel MRI contrast agents enhancing detection of immune cell infiltration, and novel PET tracers specifically probing immune molecular pathways (e.g., PD-1, PD-L1, CD8+ T cells, granzyme B) are promising in filling the void, and will need evaluation in multicentre clinical trials. Combining novel imaging tools to probe different aspects of immune response or combining imaging with tissue- or blood-based biomarkers to assess multi-dimensions of the disease may further improve the assessment of immunotherapy.

## Conclusion

The NCI NCTN continues to encourage and support the assessment of imaging tools and imaging biomarkers, and many of the network's completed, ongoing, and upcoming clinical trials may provide the imaging data to address the challenges in response assessment of immunotherapies and validate the novel imaging tools/biomarkers. Going forward, it will be important to determine their clinical utility (alone or in combination) to predict and monitor treatment response and to study the impact that such imaging tools and biomarkers may have, for instance on selection of differential therapies or early termination of immune checkpoint blockade. Clinical trial design for assessment of these roles are distinct and NCI clinical trial consortia among others, offer a conduit for these important investigations.<sup>68,69</sup> Funding opportunities are available through various mechanisms in NIH to support such discoveries and development (<https://grants.nih.gov/grants/guide/pa-files/PAR-18-560.html>; <https://itcr.cancer.gov/funding-opportunities>; and BIQSFP). Overall, there is significant interest in and support for activities in both current and planned immunotherapy trials utilizing diagnostic imaging for both predictive capabilities as well as response assessment.

## Supplementary Material

Refer to Web version on PubMed Central for supplementary material.

## Acknowledgements

Lalitha K. Shankar, Elad Sharon, and Steven A. Reeves are employed by National Cancer Institute (NCI) at the National Institutes of Health (NIH). No part of this workshop was funded by the NIH. The Clinical Imaging Steering Committee (CISC) is operated and supported by the NCI Coordinating Center for Clinical Trials.

### Declaration of Interests

EdV reports Institutional Financial Support for clinical trials or contracted research from Amgen, Genentech, Roche, CytomX, G1 Therapeutics, Bayer, Synthron, Servier, Regeneron, Crescendo Biologics, GE Healthcare and AstraZeneca; Institutional Financial Support for advisory boards/consultancy from NSABP, Daiichi Sankyo, and Crescendo Biologics; and non-financial interests, including non-remunerated activities and public positions as a member of the ESMO-MCBS working party, Chair of the ESMO Cancer Medicines Working Group, Co-chair of the RECIST committee, and member of the expert panel for selection of Essential Medicine List WHO.

MF reports institutional grant or contract payments from Merck, BMS, ImaginAb, and Carisma Therapeutics, as well as consulting fees and meeting/travel support from ImaginAb.

DL reports stock ownership in Bristol Myers Squibb.

UM reports grants, royalties and license, consulting fees, meeting/travel support, licensed patents, leadership interest, stock, materials receipt, and other financial or non-financial interests in CytoSite Biopharma.

TYP reports grants or contracts from the Pediatric Brain Tumor Consortium Neuroimaging Center; royalties from Springer; and honoraria for grand rounds, visiting professorships and invited lectures.

DP reports grants to or contracts with his institution from Siemens, 511 Pharma, Nordic nanovector, Lantheus, and Fusion Pharmaceuticals, royalties or licenses to self and institution from Trevax, consulting fees from Siemens, Fusion Pharmaceuticals, 511 Pharma, Ipsen, Bayer, MTTI, and Curium, patents from At-211 parthanatrace, participation on an ITG DSMC, and stock with MTTI and Trevax.

LS reports institutional grants or contracts from JNJ, patents from Varian Medical Systems, and DSMB or advisory board participation with Merck, BMS, and Regeneron.

YT (medical writer) reports institutional funding for this manuscript from NCI.

AT reports an institutional research grant from the Cystic Fibrosis Foundation; royalties from Elsevier; consulting fees from Applied Radiology; travel support from KLAS, and unpaid leadership roles in the Society for Imaging Informatics in Medicine and Society for Pediatric Radiology.

RW reports grants or contracts from BMS, Bayer, Actinium Pharmaceuticals, ITM, Siemens, and NIH; consulting fees from Seno medical, Actinium Pharmaceuticals, and Clarity Pharmaceuticals; Payment or honoraria for lectures, presentations, speakers bureaus, manuscript writing or educational events from ITM, Voximetry, ACNM, and NIH (not for this workshop or manuscript); Support for meetings/travel from the Society of Nuclear Medicine and the World Theranostics Conference; DSMB/Advisory Board participation from Bayer; a recent past-presidency at SNMMI; and stock in Clarity Pharmaceuticals and Voximetry.

JW reports grants from Bristol Myers Squibb and Sephora, institutional royalties for Xenogeneic DNA Vaccines, Newcastle Disease viruses for Cancer Therapy, Myeloid-derived suppressor cell (MDSC) assay, and prediction of responsiveness to treatment with immunomodulatory therapeutics and method of monitoring abscopal effects during such treatment, licenses for anti-PD1 Antibody, anti-CTLA4 antibodies, and anti-GITR antibodies and methods of use thereof, consulting fees from Amgen, Apricity, Ascentage Pharma, Astellas, AstraZeneca, Bicara Therapeutics, Boehringer Ingelheim, Bristol Myers Squibb, CellCarta, Chugai, Daiichi Sankyo, Dragonfly, Georgiamune, Idera, Imvaq, Larkspur, Maverick Therapeutics, Merck, Psioxus, Recepta, Trishula, Sellas, Surface Oncology, and Werewolf therapeutics, support for meetings/travel from SITC and Parker Institute for Cancer Immunotherapy, patents for Recombinant Poxviruses for Cancer Immunotherapy, Phosphatidylserine Targeting agents, Immunosuppressive follicular helper-like T cells modulated by immune checkpoint blockade; Identifying And Treating Subjects At Risk For Checkpoint Blockade Therapy Associated Colitis; CAR+ T cells targeting differentiation antigens as means to treat cancer, anti-CD40 agonist monoclonal antibody fused to Monophosphoryl Lipid A (MPL) for cancer therapy, and Engineered Vaccinia Viruses for Cancer Immunotherapy, a leadership or fiduciary role in SITC, and stock in Apricity; CellCarta; Ascentage; Beigene; Imvaq, Linneaus, Georgiamune, Maverick, Tizona Pharma, and Trieza.

AW reports consulting fees, a leadership or fiduciary role (Board member), and stock options in ImaginAb, Inc. and speaker honoraria payments from Roche and AstraZeneca.

## References

1. Sanmamed MF, Chen L. A Paradigm Shift in Cancer Immunotherapy: From Enhancement to Normalization. *Cell* 2018; 175: 313–26. [PubMed: 30290139]
2. Wolchok JD, Hoos A, O’Day S, et al. Guidelines for the evaluation of immune therapy activity in solid tumors: immune-related response criteria. *Clin Cancer Res* 2009; 15: 7412–20. [PubMed: 19934295]
3. Bohnsack O, Hoos A, Ludajic K. Adaptation and modification of the immune related response criteria (IRRC): IrRECIST. *J Clin Oncol* 2014; 32 (15 suppl): abstr e22121.
4. Seymour L, Bogaerts J, Perrone A, et al. iRECIST: guidelines for response criteria for use in trials testing immunotherapeutics. *Lancet Oncol* 2017; 18: e143–52. [PubMed: 28271869]
5. Hodi FS, Ballinger M, Lyons B, et al. Immune-Modified Response Evaluation Criteria In Solid Tumors (imRECIST): Refining guidelines to assess the clinical benefit of cancer immunotherapy. *J Clin Oncol* 2018; 36: 850–8. [PubMed: 29341833]
6. Okada H, Weller M, Huang R, et al. Immunotherapy response assessment in neuro-oncology: a report of the RANO working group. *Lancet Oncol* 2015; 16: e534–42. [PubMed: 26545842]
7. Ellingson BM, Wen PY, Cloughesy TF. Modified criteria for radiographic response assessment in glioblastoma clinical trials. *Neurotherapeutics* 2017; 14: 307–20. [PubMed: 28108885]
8. Goggi JL, Hartimath SV, Hwang Y, et al. Examining Immunotherapy Response Using Multiple Radiotracers. *Mol Imaging Biol* 2020; 22: 993–1002. [PubMed: 32006204]
9. Kok IC, Hooiveld JS, van de Donk PP, et al. 89Zr-pembrolizumab imaging as a non-invasive approach to assess clinical response to PD-1 blockade in cancer. *Ann Oncol Off J Eur Soc Med Oncol* 2022; 33: 80–8.
10. Upadhaya S, Hubbard-Lucey VM, Yu JX. Immuno-oncology drug development forges on despite COVID-19. *Nat Rev Drug Discov* 2020; 19: 751–2. [PubMed: 32948858]
11. Ott PA, Hodi FS, Kaufman HL, Wigginton JM, Wolchok JD. Combination immunotherapy: a road map. *J Immunother Cancer* 2017; 5: 16. [PubMed: 28239469]
12. Sharma P, Allison JP. The future of immune checkpoint therapy. *Science* 2015; 348: 56–61. [PubMed: 25838373]
13. Hodi FS, O’Day SJ, McDermott DF, et al. Improved survival with ipilimumab in patients with metastatic melanoma. *N Engl J Med* 2010; 363: 711–23. [PubMed: 20525992]
14. Pandit-Taskar N, Postow MA, Hellmann MD, et al. First-in-humans imaging with (89)Zr-Df-IAB22M2C anti-CD8 minibody in patients with solid malignancies: Preliminary pharmacokinetics, biodistribution, and lesion targeting. *J Nucl Med* 2020; 61: 512–9. [PubMed: 31586002]
15. Farwell MD, Gamache RF, Babazada H, et al. CD8-targeted PET Imaging of Tumor Infiltrating T cells in Patients with Cancer: A Phase I First-in-Human Study of (89)Zr-Df-IAB22M2C, a Radiolabeled anti-CD8 Minibody. *J Nucl Med* 2021; published online Aug 19. DOI:10.2967/jnumed.121.262485.
16. Macdonald DR, Cascino TL, Schold SC Jr, Cairncross JG. Response criteria for phase II studies of supratentorial malignant glioma. *J Clin Oncol* 1990; 8: 1277–80. [PubMed: 2358840]
17. Levin VA, Crafts DC, Norman DM, Hoffer PB, Spire JP, Wilson CB. Criteria for evaluating patients undergoing chemotherapy for malignant brain tumors. *J Neurosurg* 1977; 47: 329–35. [PubMed: 894339]
18. Miller AB, Hoogstraten B, Staquet M, Winkler A. Reporting results of cancer treatment. *Cancer* 1981; 47: 207–14. [PubMed: 7459811]
19. Wen PY, Macdonald DR, Reardon DA, et al. Updated response assessment criteria for high-grade gliomas: response assessment in neuro-oncology working group. *J Clin Oncol* 2010; 28: 1963–72. [PubMed: 20231676]
20. Ellingson BM, Sampson J, Achrol AS, et al. Modified RANO, immunotherapy RANO, and standard RANO response to convection-enhanced delivery of IL4R-targeted immunotoxin MDNA55 in recurrent glioblastoma. *Clin Cancer Res* 2021; 27: 3916–25. [PubMed: 33863808]

21. Kelloff GJ, Hoffman JM, Johnson B, et al. Progress and promise of FDG-PET imaging for cancer patient management and oncologic drug development. *Clin Cancer Res* 2005; 11: 2785–808. [PubMed: 15837727]
22. Vaidyanathan S, Patel CN, Scarsbrook AF, Chowdhury FU. FDG PET/CT in infection and inflammation—current and emerging clinical applications. *Clin Radiol* 2015; 70: 787–800. [PubMed: 25917543]
23. Shreve PD, Anzai Y, Wahl RL. Pitfalls in oncologic diagnosis with FDG PET imaging: physiologic and benign variants. *Radiographics* 1999; 19: 61–77; quiz 150–1. [PubMed: 9925392]
24. Gandy N, Arshad MA, Wallitt KL, Dubash S, Khan S, Barwick TD. Immunotherapy-related adverse effects on 18F-FDG PET/CT imaging. *Br J Radiol* 2020; 93: 20190832.
25. Kikano EG, Avril S, Marshall H, Jones RS, Montero AJ, Avril N. PET/CT Variants and Pitfalls in Breast Cancers. *Semin Nucl Med* 2021; 51: 474–84. [PubMed: 34088473]
26. Parihar AS, Haq A, Wahl RL, Haghghat Jahromi A. Progression or response: new liver lesions in a patient with responding Hodgkin lymphoma. *J Nucl Med Off Publ Soc Nucl Med* 2022; : jnumed.122.264995.
27. Wahl RL, Jacene H, Kasamon Y, Lodge MA. From RECIST to PERCIST: Evolving considerations for PET response criteria in solid tumors. *J Nucl Med* 2009; 50 Suppl 1: 122s–50s. [PubMed: 19403881]
28. Cho SY, Lipson EJ, Im HJ, et al. Prediction of Response to Immune Checkpoint Inhibitor Therapy Using Early-Time-Point (18)F-FDG PET/CT Imaging in Patients with Advanced Melanoma. *J Nucl Med* 2017; 58: 1421–8. [PubMed: 28360208]
29. Amrane K, Le Goupil D, Quere G, et al. Prediction of response to immune checkpoint inhibitor therapy using 18F-FDG PET/CT in patients with melanoma. *Med Baltim* 2019; 98: e16417.
30. Kitajima K, Watabe T, Nakajo M, et al. Tumor response evaluation in patients with malignant melanoma undergoing immune checkpoint inhibitor therapy and prognosis prediction using (18)F-FDG PET/CT: multicenter study for comparison of EORTC, PERCIST, and imPERCIST. *Jpn J Radiol* 2021; published online July 21. DOI:10.1007/s11604-021-01174-w.
31. Rossi G, Bauckneht M, Genova C, et al. Comparison Between (18)F-FDG PET-Based and CT-Based Criteria in Non-Small Cell Lung Cancer Patients Treated with Nivolumab. *J Nucl Med* 2020; 61: 990–8. [PubMed: 31806768]
32. Donegani MI, Ferrarazzo G, Marra S, et al. Positron Emission Tomography-Based Response to Target and Immunotherapies in Oncology. *Med Kaunas* 2020; 56. DOI:10.3390/medicina56080373.
33. Hyun OJ, Luber BS, Leal JP, et al. Response to early treatment evaluated with 18F-FDG PET and PERCIST 1.0 predicts survival in patients with ewing sarcoma family of tumors treated with a monoclonal antibody to the insulinlike growth factor 1 receptor. *J Nucl Med* 2016; 57: 735–40. [PubMed: 26795289]
34. Torizuka T, Zasadny KR, Kison PV, Rommelfanger SG, Kaminski MS, Wahl RL. Metabolic response of non-Hodgkin's lymphoma to 131I-anti-B1 radioimmunotherapy: evaluation with FDG PET. *J Nucl Med* 2000; 41: 999–1005. [PubMed: 10855624]
35. Shah NN, Nagle SJ, Torigian DA, et al. Early positron emission tomography/computed tomography as a predictor of response after CTL019 chimeric antigen receptor -T-cell therapy in B-cell non-Hodgkin lymphomas. *Cytotherapy* 2018; 20: 1415–8. [PubMed: 30385043]
36. Lopci E, Hicks RJ, Dimitrakopoulou-Strauss A, et al. Joint EANM/SNMMI/ANZSNM practice guidelines/procedure standards on recommended use of [18F]FDG PET/CT imaging during immunomodulatory treatments in patients with solid tumors version 1.0. *Eur J Nucl Med Mol Imaging* 2022; 49: 2323–41. [PubMed: 35376991]
37. Aide N, Hicks RJ, Le Tourneau C, Lheureux S, Fanti S, Lopci E. FDG PET/CT for assessing tumour response to immunotherapy : Report on the EANM symposium on immune modulation and recent review of the literature. *Eur J Nucl Med Mol Imaging* 2019; 46: 238–50. [PubMed: 30291373]
38. Parihar AS, Dehdashti F, Wahl RL. 18F-FDG Positron Emission Tomography (PET) based response assessment in malignancies. *Radiographics* 2023; 43: e220122. (in press) [PubMed: 36995946]



39. Sun R, Limkin EJ, Vakalopoulou M, et al. A radiomics approach to assess tumour-infiltrating CD8 cells and response to anti-PD-1 or anti-PD-L1 immunotherapy: an imaging biomarker, retrospective multicohort study. *Lancet Oncol* 2018; 19: 1180–91. [PubMed: 30120041]
40. Grossmann P, Stringfield O, El-Hachem N, et al. Defining the biological basis of radiomic phenotypes in lung cancer. *Elife* 2017; 6: e23421.
41. Lam VK, Papadimitrakopoulou V. Master protocols in lung cancer: experience from Lung Master Protocol. *Curr Opin Oncol* 2018; 30: 92–7. [PubMed: 29329112]
42. Dercle L, Zhao B, Gönen M, et al. Early Readout on Overall Survival of Patients With Melanoma Treated With Immunotherapy Using a Novel Imaging Analysis. *JAMA Oncol* 2022; 8: 385–92. [PubMed: 35050320]
43. Lu L, Sun SH, Afran A, et al. Identifying Robust Radiomics Features for Lung Cancer by Using In-Vivo and Phantom Lung Lesions. *Tomography* 2021; 7: 55–64. [PubMed: 33681463]
44. Haarburger C, Müller-Franzes G, Weninger L, Kuhl C, Truhn D, Merhof D. Radiomics feature reproducibility under inter-rater variability in segmentations of CT images. *Sci Rep* 2020; 10: 12688. [PubMed: 32728098]
45. Traverso A, Wee L, Dekker A, Gillies R. Repeatability and Reproducibility of Radiomic Features: A Systematic Review. *Int J Radiat Oncol Biol Phys* 2018; 102: 1143–58. [PubMed: 30170872]
46. Aghighi M, Theruvath AJ, Pareek A, et al. Magnetic resonance imaging of tumor-associated macrophages: Clinical translation. *Clin Cancer Res* 2018; 24: 4110–8. [PubMed: 29764855]
47. Trinchieri G. Innate inflammation and cancer: Is it time for cancer prevention? *F1000 Med Rep* 2011; 3: 11. [PubMed: 21876717]
48. Larionova I, Tuguzbaeva G, Ponomaryova A, et al. Tumor-Associated Macrophages in Human Breast, Colorectal, Lung, Ovarian and Prostate Cancers. *Front Oncol* 2020; 10: 566511.
49. Yu M, Guan R, Hong W, et al. Prognostic value of tumor-associated macrophages in pancreatic cancer: a meta-analysis. *Cancer Manag Res* 2019; 11: 4041–58. [PubMed: 31118813]
50. Yoshikawa K, Mitsunaga S, Kinoshita T, et al. Impact of tumor-associated macrophages on invasive ductal carcinoma of the pancreas head. *Cancer Sci* 2012; 103: 2012–20. [PubMed: 22931216]
51. Mohanty S, Yerneni K, Theruvath JL, et al. Nanoparticle enhanced MRI can monitor macrophage response to CD47 mAb immunotherapy in osteosarcoma. *Cell Death Dis* 2019; 10: 36. [PubMed: 30674867]
52. Huang Y, Hsu JC, Koo H, Cormode DP. Repurposing ferumoxytol: Diagnostic and therapeutic applications of an FDA-approved nanoparticle. *Theranostics* 2022; 12: 796–816. [PubMed: 34976214]
53. Harisinghani M, Ross RW, Guimaraes AR, Weissleder R. Utility of a new bolus-injectable nanoparticle for clinical cancer staging. *Neoplasia* 2007; 9: 1160–5. [PubMed: 18084623]
54. Gaglia JL, Guimaraes AR, Harisinghani M, et al. Noninvasive imaging of pancreatic islet inflammation in type 1A diabetes patients. *J Clin Invest* 2011; 121: 442–5. [PubMed: 21123946]
55. Hayano K, Miura F, Wada K, et al. Diffusion-weighted MR imaging of pancreatic cancer and inflammation: Prognostic significance of pancreatic inflammation in pancreatic cancer patients. *Pancreatology* 2016; 16: 121–6. [PubMed: 26596539]
56. Hedgire SS, Mino-Kenudson M, Elmi A, Thayer S, Fernandez-del Castillo C, Harisinghani MG. Enhanced primary tumor delineation in pancreatic adenocarcinoma using ultrasmall super paramagnetic iron oxide nanoparticle-ferumoxytol: an initial experience with histopathologic correlation. *Int J Nanomedicine* 2014; 9: 1891–6. [PubMed: 24790431]
57. Yang S, Liu Q, Liao Q. Tumor-Associated Macrophages in Pancreatic Ductal Adenocarcinoma: Origin, Polarization, Function, and Reprogramming. *Front Cell Dev Biol* 2020; 8: 607209.
58. Olafsen T, Jiang ZK, Romero J, et al. Abstract LB-188: Sensitivity of 89Zr-labeled anti-CD8 minibody for PET imaging of infiltrating CD8+ T cells. *Cancer Res* 2016; 76: LB-188.
59. Namavari M, Chang Y-F, Kusler B, Yaghoubi S, Mitchell BS, Gambhir SS. Synthesis of 2'-Deoxy-2' [18F]Fluoro-9-β-D-Arabinofuranosylguanine: a Novel Agent for Imaging T-Cell Activation with PET. *Mol Imaging Biol* 2011; 13: 812–8. [PubMed: 20838911]
60. Levi J, Lam T, Goth SR, et al. Imaging of Activated T Cells as an Early Predictor of Immune Response to Anti-PD-1 Therapy. *Cancer Res* 2019; 79: 3455–65. [PubMed: 31064845]

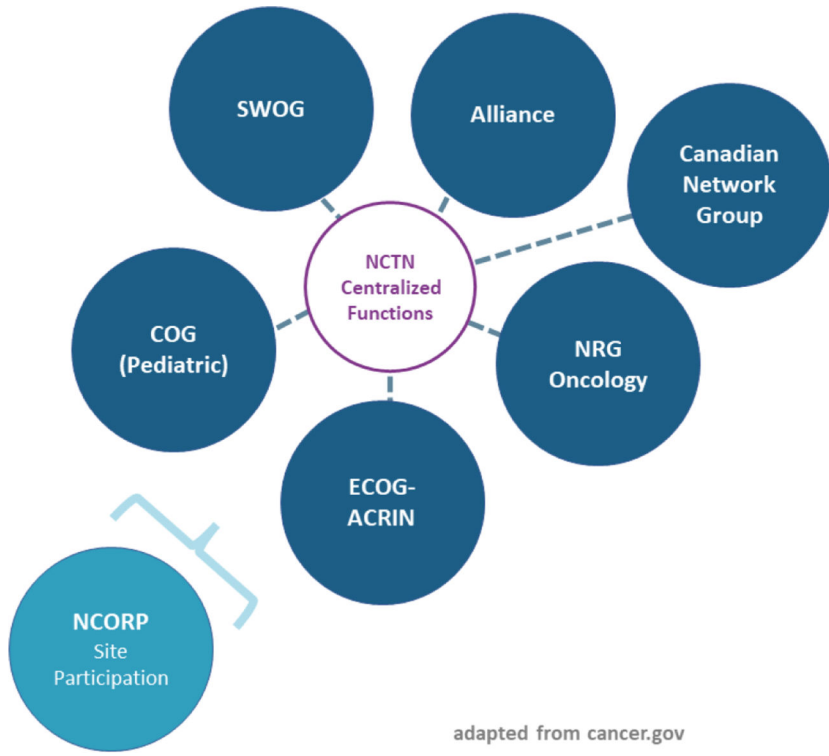
61. Niemeijer AN, Leung D, Huisman MC, et al. Whole body PD-1 and PD-L1 positron emission tomography in patients with non-small-cell lung cancer. *Nat Commun* 2018; 9: 4664. [PubMed: 30405135]
62. Robu S, Richter A, Gosmann D, et al. Synthesis and Preclinical Evaluation of a (68)Ga-Labeled Adnectin, (68)Ga-BMS-986192, as a PET Agent for Imaging PD-L1 Expression. *J Nucl Med* 2021; 62: 1228–34. [PubMed: 33517324]
63. Bensch F, van der Veen EL, Lub-de Hooge MN, et al. (89)Zr-atezolizumab imaging as a non-invasive approach to assess clinical response to PD-L1 blockade in cancer. *Nat Med* 2018; 24: 1852–8. [PubMed: 30478423]
64. Giesen D, Broer LN, Lub-de Hooge MN, et al. Probody therapeutic design of (89)Zr-CX-072 promotes accumulation in PD-L1-expressing tumors compared to normal murine lymphoid tissue. *Clin Cancer Res* 2020; 26: 3999–4009. [PubMed: 31953313]
65. Naing A, Thistlethwaite F, De Vries EGE, et al. CX-072 (pacmilimab), a Probody<sup>®</sup> PD-L1 inhibitor, in advanced or recurrent solid tumors (PROCLAIM-CX-072): an open-label dose-finding and first-in-human study. *J Immunother Cancer* 2021; 9. DOI:10.1136/jitc-2021-002447.
66. Kist de Ruijter L, Hooiveld-Noeken JS, Giesen D, et al. First-in-Human Study of the Biodistribution and Pharmacokinetics of (89)Zr-CX-072, a Novel Immunopet Tracer Based on an Anti-PD-L1 Probody. *Clin Cancer Res* 2021; published online July 12. DOI:10.1158/1078-0432.ccr-21-0453.
67. Kist de Ruijter L, Van de Donk PP, Hooiveld-Noeken JS, et al. LB037 – 89ZED88082A PET imaging to visualize CD8+ T cells in patients with cancer treated with immune checkpoint inhibitor. *AACR Annu Meet* 2021: abstr LB037.
68. Lin FI, Huang EP, Shankar LK. Beyond Correlations, Sensitivities, and Specificities: Case Examples of the Evaluation of Advanced Imaging in Oncology Clinical Trials and Cancer Treatment. *Acad Radiol* 2017; 24: 1027–35. [PubMed: 28410912]
69. Huang EP, Lin FI, Shankar LK. Beyond Correlations, Sensitivities, and Specificities: A Roadmap for Demonstrating Utility of Advanced Imaging in Oncology Treatment and Clinical Trial Design. *Acad Radiol* 2017; 24: 1036–49. [PubMed: 28456570]
70. Saenger YM, Wolchok JD. The heterogeneity of the kinetics of response to ipilimumab in metastatic melanoma: patient cases. *Cancer Immun* 2008; 8:1.

**Recommendations:**

- Use promising imaging modalities prospectively in IO treatment trials to assess how they may inform patient selection or patient care.
- Accelerate data analysis on completed studies and utilise completed trial datasets to assess performance of modified assessment criteria (iRECIST, iRANO, etc.) and radiomics.
- Continue to expand efforts to harmonize data collection and facilitate uniform image assessment across sites and trials in order to assess performance of modified metrics.

### Search strategy and selection criteria

This Policy Review was developed based on a workshop conducted by the Clinical Imaging Steering Committee of the National Cancer Institute; therefore, no formal literature search was done. Additional articles were found through searches of the authors' own files, as well as [pubmed.ncbi.nlm.nih.gov](https://pubmed.ncbi.nlm.nih.gov) and [clinicaltrials.gov](https://clinicaltrials.gov), for articles published in English up until 2022, using search terms PET-CT, MR, RANO, PERCIST, RECIST, 18F-AraG, Radiomics, Response Assessment, Predictive marker, Immunotherapy, Immuno-oncology, Cancer, Molecular Imaging, Functional Imaging, and Clinical Trials.



adapted from cancer.gov

**LEGEND**

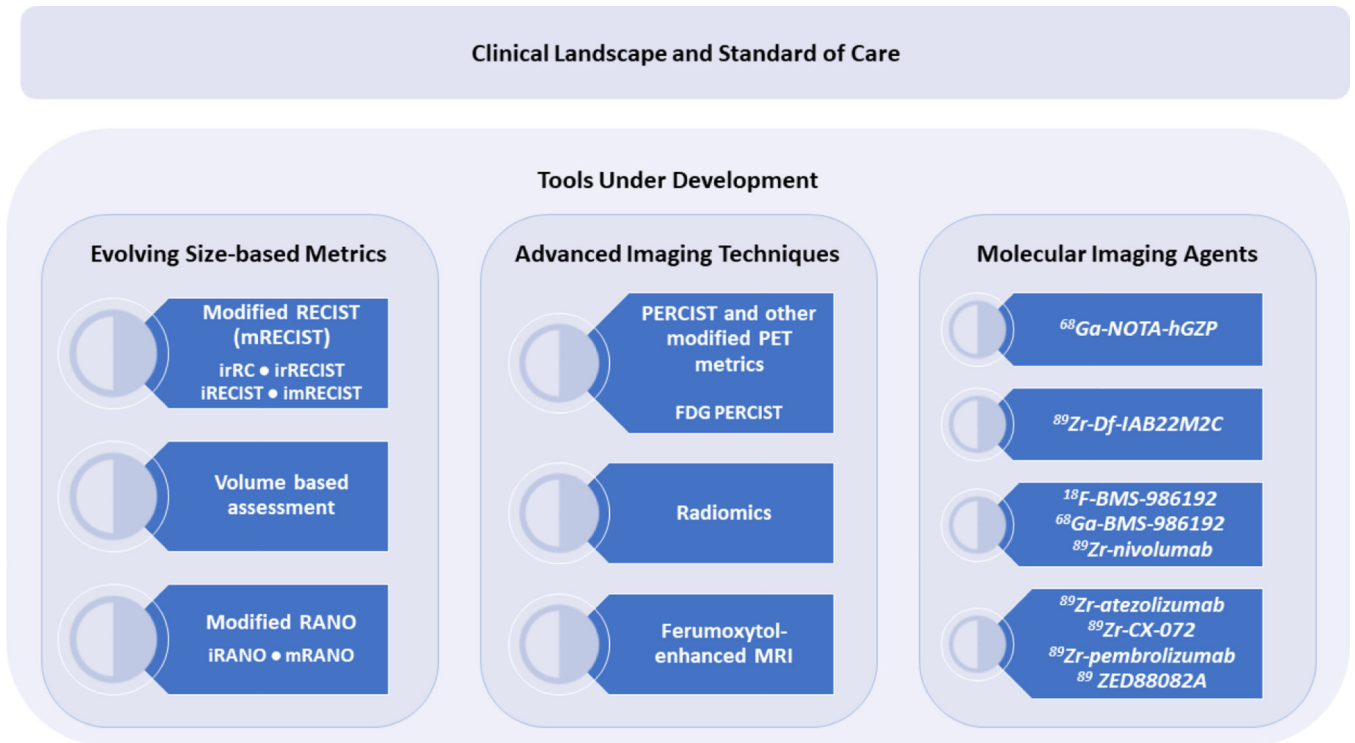
**NCTN Centralized Functions**

- Includes the **Imaging and Radiation Oncology Core (IROC) Group**:
  - IROC Houston
  - IROC Philadelphia
  - IROC Ohio
  - IROC St. Louis
  - IROC Rhode Island
  - IROC Philadelphia

**Network Groups**

- **SWOG Cancer Research Network** (formerly the Southwest Oncology Group)
- **NRG Oncology** (formerly the National Surgical Adjuvant Breast and Bowel Project (NSABP), the Radiation Therapy Oncology Group (RTOG), and the Gynecologic Oncology Group (GOG))
- **ECOG-ACRIN Cancer Research Group** (formerly the Eastern Cooperative Oncology Group and the American College of Radiology Imaging Network's Oncology Program)
- **COG (Children's Oncology Group)**
- **Alliance for Clinical Trials in Oncology**
- **CCTG (Canadian Cancer Trials Group)**
- **NCORP (NCI Community Oncology Research Program)**

**Figure 1.** A diagram of the structure of US National Clinical Trials Network (NCTN), including the six NCTN network groups, NCORP sites, and the six IROC Quality Assurance Centers that operate as part of the NCTN centralized functions (<https://www.cancer.gov/research/infrastructure/clinical-trials/nctn>).



**Figure 2.**  
A figure illustrating the topics covered in this review.

**Table 1:**

Summary of the state of the field and innovations under development

		<b>Current Status</b>	<b>Opportunities</b>	<b>Challenges</b>
<b>Clinical Landscape and Standard of Care</b>		The IO field has necessitated modified response assessment criteria and further development of advanced/ molecular imaging approaches to better guide patient care and drug development	Continue assessment of the tools under investigation to assess IO-induced changes in the tumour and its micro-environment that may predict clinical outcomes	Collection of additional data, the provision of greater access to these data, and additional clinical testing and validation needed; establishing clinical utility in predicting and monitoring clinical response to targeted immunotherapies; broader access to contrast agents and radiotracers; cost of and reimbursement for novel imaging agents
<b>Evolving Size-based Metrics</b>	modified RECIST (mRECIST)	Consensus guidelines for use have been developed	Provide more accurate response assessment	Evaluation and validation needed
	Volume based assessment	Evaluation in prospective studies as secondary or exploratory endpoint ongoing	Utility for total tumour burden measurement and use in alternate endpoints in clinical trials	Identification of sites of disease for volumetric measurements and assessments of the accuracy of these measurements
	modified RANO (mRANO)	Evaluation in prospective studies as secondary or exploratory endpoint	mRANO outperforms both RANO and iRANO in demonstrating a correlation between radiographic PFS and OS	Evaluation and validation as primary endpoint ongoing
<b>Advanced Imaging Techniques</b>	PERCIST & evolving FDG based semi-quantitative metrics	Evaluation and application ongoing	Confirm accuracy in predicting response and identifying true progression	Uneven success in assessment across disease sites
	Radiomics	Advances in computing and feature classification has enabled quantification of image features and correlation with molecular parameters and/or clinical outcomes	Continue assessing improvement in evaluating response, identifying pseudoprogression, and prognosis	Complex array of factors influences the reproducibility of imaging radiomic feature extraction
	Ferumoxetyl-enhanced MRI	Early application as a functional contrast agent for MRI to identify tumours that have a high density of TAM, determine treatment, and assess response	Confirm whether Ferumoxetyl is a biomarker for primary tumours given co-localization with TAM in tumours	Testing is ongoing
<b>Molecular Imaging Agents</b>	<sup>68</sup> Ga-NOTA-hGZP	Agent in multicentre phase 1 trial	Detect response to immune checkpoint inhibitors, tumour vaccines and CAR-T cell mediated cell therapy for solid tumours	Testing is ongoing
	<sup>89</sup> Zr-Df-IAB22M2C	Agent in multicentre phase 2 trial	Image the distribution and abundance of CD8+ T cells in the tumour micro-environment	Confirmation of safety for repeat dosing and imaging, correlation of CD8 PET with CD8 immuno-histochemistry and correlation with RECIST and outcome
	<sup>18</sup> F-BMS-986192 (anti-PD-L1), <sup>68</sup> Ga-BMS-986192 (anti-PD-L1), <sup>89</sup> Zr-nivolumab (anti-PD-1)	Early clinical and pre-clinical testing	Evaluate as predictive biomarkers for treatment efficacy of PD-1 or PD-L1 blockade agents	Testing is ongoing

		<b>Current Status</b>	<b>Opportunities</b>	<b>Challenges</b>
	<i><sup>89</sup>Zr-atezolizumab (anti-PD-L1), <sup>89</sup>Zr-CX-072 (anti-PDL1), <sup>89</sup>Zr-pembrolizumab (anti-PD-1), <sup>89</sup>ZED88082A (anti-CD8)</i>	Study ongoing - Phase 2 ( <sup>89</sup> Zr-atezolizumab); first-in-human ( <sup>89</sup> Zr-CX-072); early clinical ( <sup>89</sup> Zr-pembrolizumab); Phase 1/2 ( <sup>89</sup> ZED88082A)	Investigate results showing uptake in tumour lesions correlated with treatment response and patient survival	Testing is ongoing

Author Manuscript

Author Manuscript

Author Manuscript

Author Manuscript