

UC Davis

Dermatology Online Journal

Title

Linear verrucous epidermal nevus with oral manifestations: report of two cases

Permalink

<https://escholarship.org/uc/item/46n048wn>

Journal

Dermatology Online Journal, 26(1)

Authors

Gomes, Rafael Tomaz
Vargas, Pablo Agustin
Tomimori, Jane
[et al.](#)

Publication Date

2020

DOI

10.5070/D3261047185

Copyright Information

Copyright 2020 by the author(s). This work is made available under the terms of a Creative Commons Attribution-NonCommercial-NoDerivatives License, available at <https://creativecommons.org/licenses/by-nc-nd/4.0/>

Peer reviewed

Linear verrucous epidermal nevus with oral manifestations: report of two cases

Rafael Tomaz Gomes^{1,2} DDS MD, Pablo Agustin Vargas² DDS PhD FRCPath, Jane Tomimori¹ MD PhD, Marcio Ajudarte Lopes² DDS PhD, Alan Roger Santos-Silva² DDS PhD

Affiliations: ¹Department of Dermatology, Paulista School of Medicine, Federal University of Sao Paulo (UNIFESP), Sao Paulo, Brazil, ²Department of Oral Diagnosis, Piracicaba Dental School, University of Campinas (UNICAMP), Piracicaba, Brazil

Corresponding Author: Prof. Dr. Alan Roger Santos-Silva, Faculdade de Odontologia de Piracicaba - UNICAMP, Departamento de Diagnóstico Oral-Semiologia, Avenida Limeira, 901. CEP 13.414-903, Piracicaba - São Paulo, Brazil. Email: alan@unicamp.br

Abstract

Linear verrucous epidermal nevi (LVEN) are characterized by verrucous papules often coalescing into well-demarcated skin-colored or brown plaques following the lines of Blaschko. We present two new cases of LVEN with oral mucosa involvement and briefly discuss this very rare finding. In both cases, oral biopsies showed hyperkeratosis, acanthosis, and papillomatosis. Although several treatment modalities have been reported for the cutaneous lesions, there is no consensus for the management of oral lesions so far.

Keywords: linear epidermal nevus, hamartoma, Blaschko lines

Introduction

Epidermal nevi (EN) are hamartomas characterized by hyperplasia of any part of the epidermis, including adnexal structures. Linear verrucous epidermal nevus (LVEN) originates from keratinocyte hyperplasia, and they are clinically characterized by skin-colored or brown papules and/or plaques, with a verrucous surface, appearing linearly, following the lines of Blaschko [1, 2]. Although the etiology is not completely understood, it seems that this is a mosaic disorder resulting from a postzygotic mutation [3, 4]. Oral involvement of LVEN is very rare and only a few cases have been reported in the scientific literature.

We report two new cases of LVEN affecting the face with oral manifestations.

Case Synopsis

Case 1

A 9-year-old boy was referred to our clinic with a widespread plaque affecting the right side of his face, chin, neck, and oral cavity. His parents recalled the first appearance of lesions at birth. It initially presented as hyperpigmented linear streaks on his right cheek, which gradually increased in size and thickness and became more elevated and verrucous. The plaques followed the lines of Blaschko stopping abruptly at the midline on his chin. He also had a similar solitary plaque on the midline of his anterior neck. He had intraoral verrucous lesions inside his lower lip and at the right buccal mucosa (**Figure 1**). This patient was otherwise healthy and his eye, orthopedic, and neurological examinations were unremarkable.

Case 2

An 8-year-old girl presented with a large, dark-brown verrucous plaque with a linear pattern of distribution on the left side of her face that extended from the scalp and forehead to the neck following the lines of Blaschko. The parents recalled the first appearance of the lesion when she was born and noticed that it was gradually increasing in size and pigmentation. Intraorally, she had a verrucous plaque with a pink, papillary surface that was located on the left side of her hard and soft palate area, upper and lower lips, buccal mucosa, and gingiva (**Figure 2**). She was in

good health and had no ocular, skeletal, or neurologic abnormalities.

An informed consent was obtained from the parents and the patients prior to clinical evaluation as part of an internal protocol of our institution. After informed consent of patients and parents, intraoral lesions were biopsied. On histological examination, both biopsies showed a papillomatous surface with hyperkeratosis and acanthosis, typical of epidermal nevi. In both cases, elongated rete ridges and an increase in melanin in the basal cell layer were observed (**Figures 1** and **2**). In both current cases, patients and parents did not accept any treatment modality. Clinical follow-up twice a year was suggested for both patients.

Case Discussion

Epidermal nevi are defined according to the predominant cell type: predominance of keratinocytes (verrucous epidermal nevus),

sebaceous glands (nevus sebaceous), pilosebaceous units (nevus comedonicus), sweat glands (apocrine and eccrine nevus), and mucosal epithelium (white sponge nevus), [5].

Verrucous epidermal nevus is the most common type of epidermal nevus and it is characterized by verrucous papules that coalesce to form well-demarcated papillomatous plaques that are skin-colored-to-brown. These hamartomas can be located anywhere in the body, including the head, trunk, or extremities. They are usually present at birth or infancy and may enlarge slowly during childhood and adolescence [6]. When these lesions are linear in appearance following the lines of Blaschko — with streaks and whorls stopping abruptly at the midline — they are known as LVEN [1, 5, 7].

The prevalence of epidermal nevi is 0.1 to 0.5% and there is no predilection for gender or race [2]. The incidence of all types of epidermal nevi is estimated to be one in 1000 live births. Most lesions arise

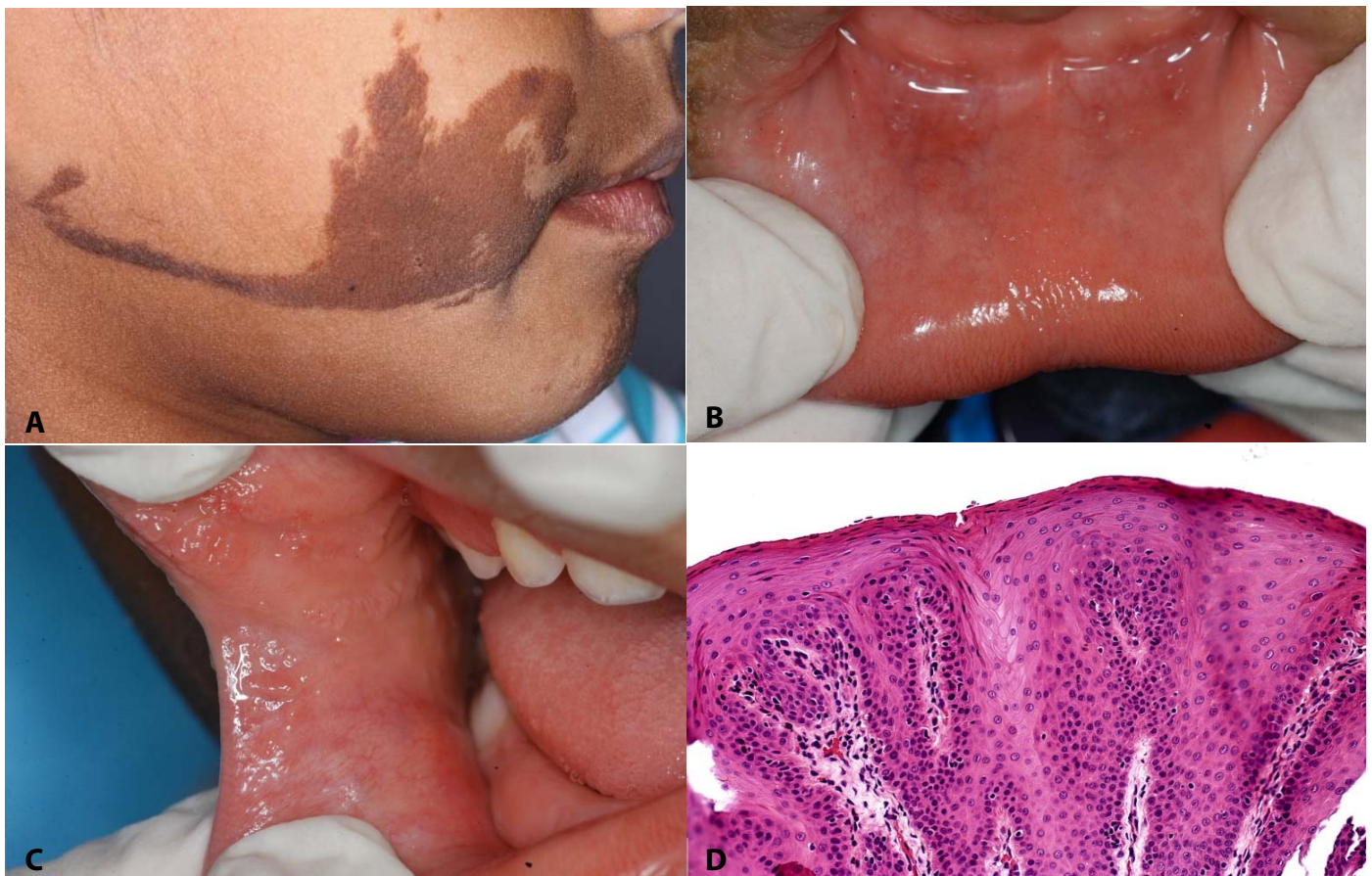

Figure 1. **A)** Hyperpigmented verrucous linear plaques end abruptly at the midline. **B, C)** Pink verrucous lesions inside his lower lip and at the right buccal mucosa. **D)** Oral biopsy revealed hyperkeratosis, acanthosis, and papillomatosis. H&E, 200x.

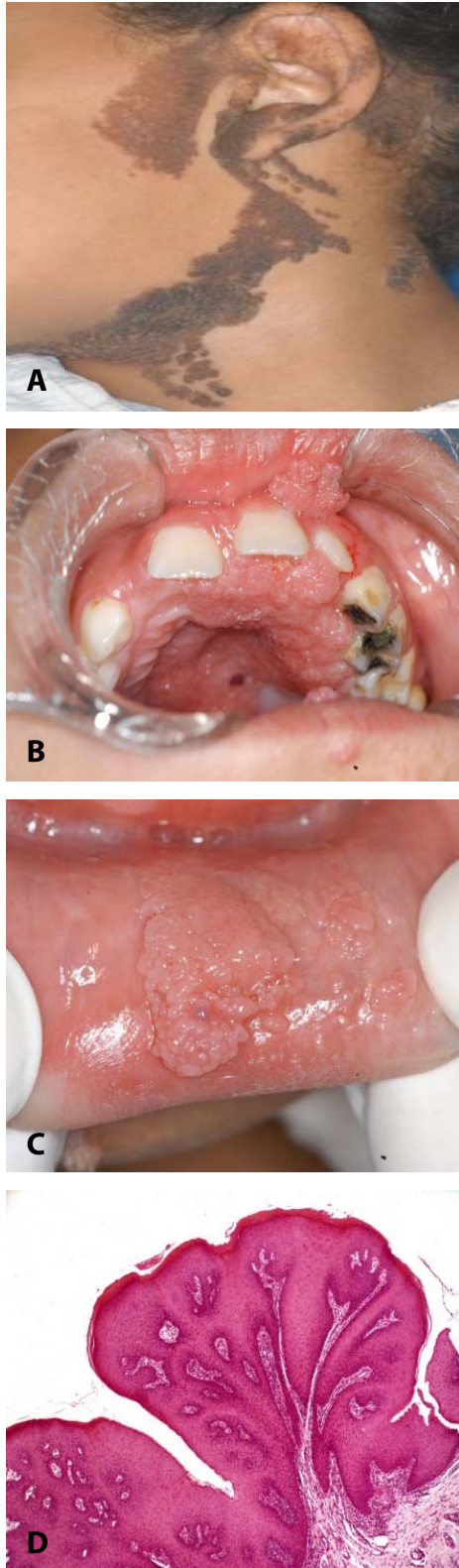


Figure 2. A) Dark-brown verrucous plaque following the lines of Blaschko extending from the scalp and forehead to the neck. (B, C) Pink verrucous plaques on the hard and soft palates, gingiva, upper and lower lips, and buccal mucosa. D) Histopathologic study of oral specimen showed hyperkeratosis, acanthosis with elongation of the rete ridges, and papillomatosis. H&E, 100 \times .

sporadically during the embryonic development phase, but familial patterns of inheritance have been observed [5].

Mosaicism can originate by different mechanisms, but genetic mutation is an essential step that occurs during embryogenesis [3, 6, 8]. A mosaic can be understood as an individual with two or more genetically distinct cell populations derived from a genetically homogeneous zygote [4].

The prototype for patterns of cutaneous mosaicism is exhibited by the lines of Blaschko and they represent the development and migration of the ectoderm. As the growth of the embryo progresses, cells start to proliferate at the midline and grow in a V shape on the back and an S shape on the anterolateral portion of the trunk. On the face they display an hourglass-like arrangement converging on the nasal root. On the scalp they form a spiral configuration. In LVEN, only a group of ectodermal cells carry the genetic alterations that will clinically manifest as cutaneous whorls and swirls [4, 9].

The histopathologic features of both oral and cutaneous LVEN include hyperkeratosis, acanthosis, and papillomatosis. The rete ridges are elongated and focal thickening of the granular layer might be seen. Occasionally, an increase in melanin in the basal cell layer is evident. Granular degeneration of the epidermis can be visualized and is marked by perinuclear vacuolization of the cells. Additionally, the lesion margins are sharply demarcated from the surrounding normal epithelium on microscopic examination [9, 10]. Lesions can also be subcategorized as into epidermolytic and non-epidermolytic [2]. Recent reports in the literature point to a relation between the disease with the *fibroblast growth factor receptor 3 gene (FGFR3)* and the *phosphatidylinositol 3-kinase catalytic subunit alpha (PIK3CA)* oncogene [2, 11].

Epidermal nevus syndromes (ENS) are defined as the presence of epidermal nevi associated with involvement of other organ systems [4, 12]. When lesions are extensive, a work-up for ENS is indicated and should include evaluations for ocular, skeletal, neurologic, and other internal developmental

defects. In a review of 131 cases of epidermal nevi, it was found that 33% of patients had ENS [12].

The vast majority of ENS are not associated with malignancy. In very rare cases, especially for sebaceous nevus, it is possible the occurrence of basal cell carcinomas, keratoacanthomas, spinocellular carcinomas, and malignant eccrine poromas [3]. Malignant change should be raised when lesions exhibit sudden localized growth or ulceration [9]. To date, there have been no reports of oral lesions of LVEN that have undergone malignant transformation.

Oral involvement of LVEN is an uncommon finding and the diagnosis of LVEN exclusively limited to the oral cavity is very rare. Lesions are often characterized by localized pink verrucous growths with well-defined borders on the lips, palate, gingiva, buccal mucosa, and tongue. Less common findings include tongue hypertrophy, dental anomalies, and high arched palate [7, 9, 13]. Oral lesions of LVEN can affect different anatomical sites but they do not cross the midline. This observation suggests that the oral cavity might have a pattern of distribution of the lines of Blaschko similar to the skin [1].

The main entities in the clinical differential diagnosis for intraoral LVEN lesions include human papillomavirus-related lesions (squamous papillomas, condyloma, verruca vulgaris, focal epithelial hyperplasia), lymphangioma, and verrucous carcinoma for lesions observed in adults. The diagnosis is mainly made according to the histopathological findings [7, 9].

The treatment of LVEN is challenging and many different therapeutic modalities have been attempted with variable results. Considering the rarity of LVEN with oral involvement, no definitive treatment guideline is currently available for oral lesions [1].

Treatment of cutaneous lesions of LVEN consists of surgical excision extending into the deep dermis to avoid recurrence. However, surgical removal may not be possible owing to extensive involvement. Other destructive methods including

electrofulguration, cryosurgery, and dermabrasion may be effective, but also tend to produce scarring [14].

Topical agents (calcipotriol, steroids, 5-fluorouracil, podophyllin, and retinoic acid) have usually been ineffective with high recurrence rates [2]. Success with the antipsoriatic agents (isotretinoin, anthralin, and topical calcipotriol) has been reported in treating the inflammatory variant of LVEN, also known as ILVEN, suggesting that this condition represents a linear psoriasis or superimposed psoriasis [5].

The use of lasers in treating epidermal nevi has been reported, but successful eradication appears dependent on the clinical characteristics of the nevus. Softer, flat nevi seem to be more responsive than firm, keratotic forms [5, 15]. Er:YAG laser ablation has a comparable clinical improvement with CO₂ laser, but the rate of recurrence is higher with Er:YAG laser [14].

Patients and caregivers should understand that the lesions can recur after non-surgical procedures and if the involvement is extensive the clinician should consider a conservative approach.

Conclusion

Linear verrucous epidermal nevus is a sporadic hamartomatous condition of the skin and/or mucosal tissue owing to the proliferation of clonal ectodermal cells, which are arranged following the lines of Blaschko. Clinically, they are seen as skin-colored or brown papules, nodules, or plaques with a verrucous surface. These lesions are unilateral and characteristically they do not cross the midline. Oral involvement is a rare manifestation and when it occurs, it can be seen on the lips, tongue, buccal mucosa, hard and soft palate, and gingiva. Histologically, LVEN shows hyperkeratosis, acanthosis, and papillomatosis.

The treatment of cutaneous LVEN is difficult and includes surgical excision, electrofulguration, cryosurgery, and dermabrasion, with an important risk of scarring. Topical agents have been suggested, such as calcipotriol, corticosteroids, 5-fluorouracil, podophyllin, and retinoic acid, but recurrence is

expected when the medication is discontinued. Ablative lasers are also a possibility for the management of this condition. Since oral lesions are extremely rare, uncertainty remains regarding the most effective therapeutic modalities. Further

studies need to be carried out in order to evaluate how mucosal lesions should be managed.

Potential conflicts of interest

The authors declare no conflicts of interests.

References

1. Tesi D, Ficarra G. Oral linear epidermal nevus: a review of the literature and report of two new cases. *Head Neck Pathol.* 2010;4:139-43. [PMID: 20512640].
2. Miranda LQ, Fracaroli TS, Fonseca JCM, et al. Analysis of mutations in the PIK3CA and FGFR3 genes in verrucous epidermal nevus. *An Bras Dermatol.* 2013;88:(6 Suppl 1):36-8. [PMID: 24346875].
3. Kouzak SS, Mendes MST, Costa IMC. Cutaneous mosaicism: concepts, patterns and classifications. *An Bras Dermatol.* 2013;88:507-17. [PMID: 24068120].
4. Asch S, Sugarman JL. Epidermal nevus syndromes: new insights into whorls and swirls. *Ped Dermatol.* 2017;35:21-9. [PMID: 29044700].
5. Kim JJ, Chang MW, Shwayder T. Topical tretinoin and 5-fluorouracil in the treatment of linear verrucous epidermal nevus. *J Am Acad Dermatol.* 2000;43(1 Pt 1):129-32. [PMID: 10863239].
6. Stosiek N, Ulmer R, von den Driesch P, et al. Chromosomal mosaicism in two patients with epidermal verrucous nevus. *J Am Acad Dermatol.* 1994;30:622-5. [PMID: 8157788].
7. Santos MDCF, Duarte ASM, Carvalho GM, et al. Linear epidermal nevus of the oral cavity: a rare diagnosis. *Case Rep Med.* 2012;2012:206836. [PMID: 22811716].
8. Hafner C, Toll A, Gantner S, et al. Keratinocytic epidermal nevi are associated with mosaic RAS mutations. *J Med Genet.* 2012;49:249-53. [PMID: 22499344].
9. Happle R, Assim A. The lines of Blaschko on the head and neck. *J Am Acad Dermatol.* 2001;44:612-5. [PMID: 11260527].
10. Haberland-Carrodegua C, Allen C, Lovas J, et al. Review of linear epidermal nevus with oral mucosal involvement – series of five new cases. *Oral Diseases.* 2008;14:131-7. [PMID: 20512640].
11. Doi H, Matsuo R, Mizumoto T, et al. Widespread epidermal nevus with a postzygotic FGFR3 mutation. *J Dermatol.* 2017;44:e186-7. [PMID: 28664990].
12. Rogers M, McCrossin I, Commens C. Epidermal nevi and the epidermal nevus syndrome: a review of 131 cases. *J Am Acad Dermatol.* 1989;20:476-488. [PMID: 2918116].
13. Özçelik D, Haydar-Parlak A, Öztürk A, Kavak A, Çelikel N. Unilateral linear verrucous epidermal nevus of the face and oral mucosa. *Plast Reconstr Surg.* 2005; 115:e17-19. [PMID: 15692336].
14. Osman MAR, Kassab AN. Carbon dioxide laser versus Erbium:YAG laser in treatment of epidermal verrucous nevus: a comparative randomized clinical study. *J Dermatol Treat.* 2016;28:452-7. [PMID: 27796132].
15. Gianfaldoni S, Tchernev G, Gianfaldoni R, Wollina U, Lotti T. A case of “inflammatory linear verrucous epidermal nevus” (ILVEN) treated with CO₂ laser ablation. *OAMJMS.* 2017;5:454-7. [PMID: 28785331].