

UC Davis
Radiation Oncology

Title

An analysis of daily setup variation in prone breast radiation of early-stage breast cancer

Permalink

<https://escholarship.org/uc/item/45z6q1f7>

Authors

Choudhury, Lamia

Moran, Angel

Zhao, Jason

Publication Date

2021

Data Availability

The data associated with this publication are not available for this reason: N/A

An analysis of daily setup variation in prone breast radiation of early-stage breast cancer

Parvina Choudhury, Angel Moran MD, Jason Zhao MD
 University of California, Davis School of Medicine
 Department of Radiation Oncology

Introduction

Radiation therapy is an integral part of treatment of early-stage breast cancer. Utilizing prone treatment plan can help minimize heart irradiation. However, prone setup is more difficult to replicate than standard supine technique.

Hypothesis

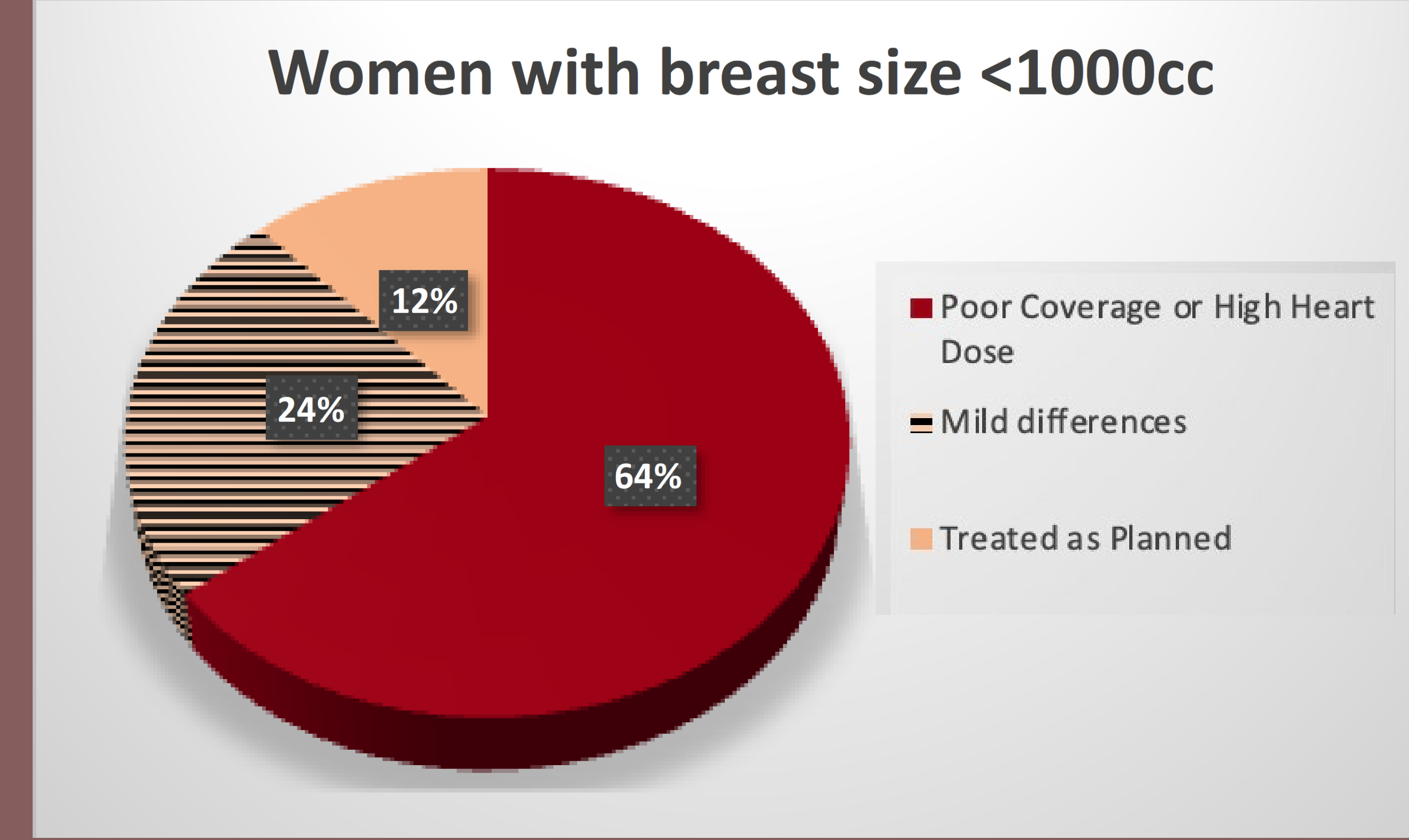
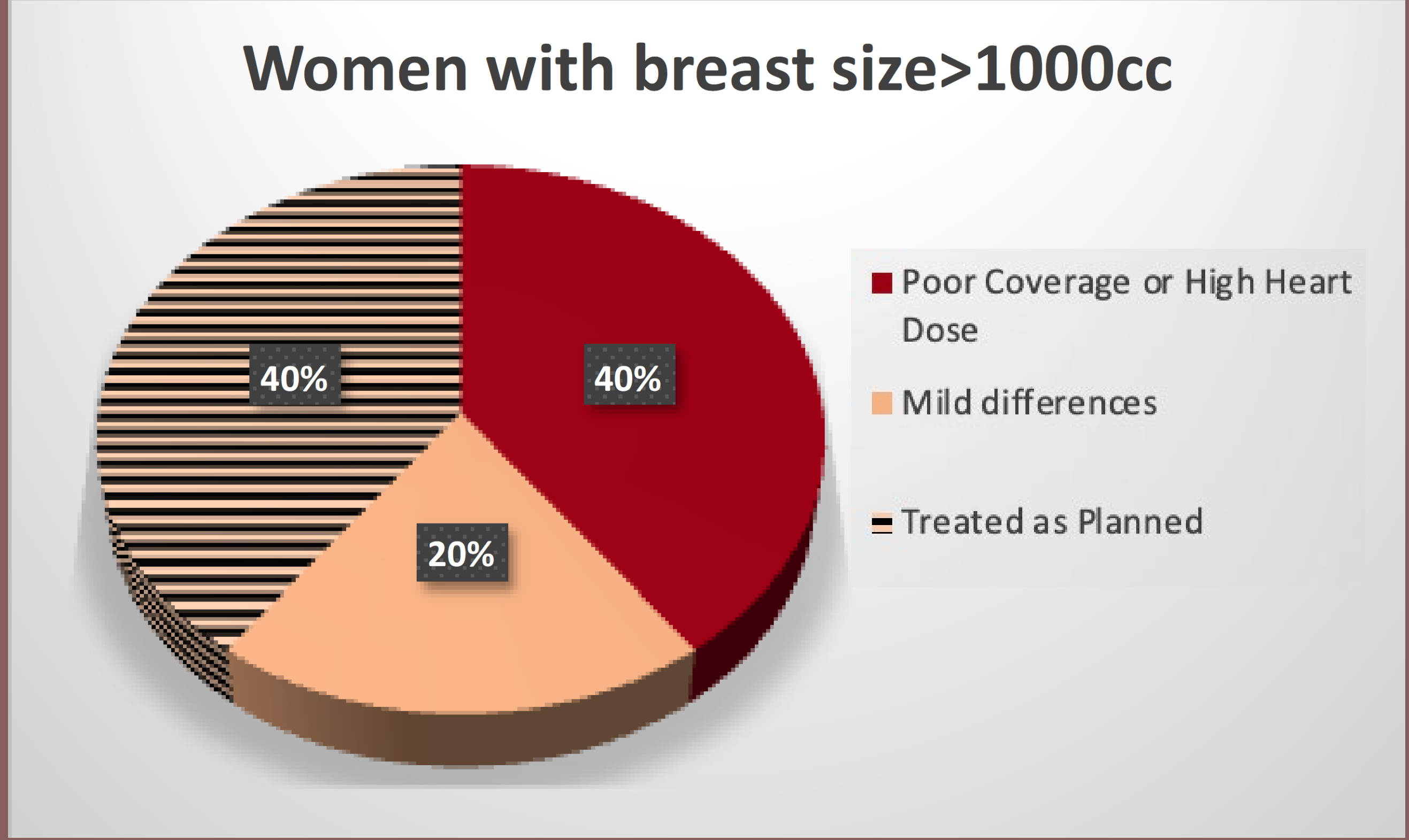
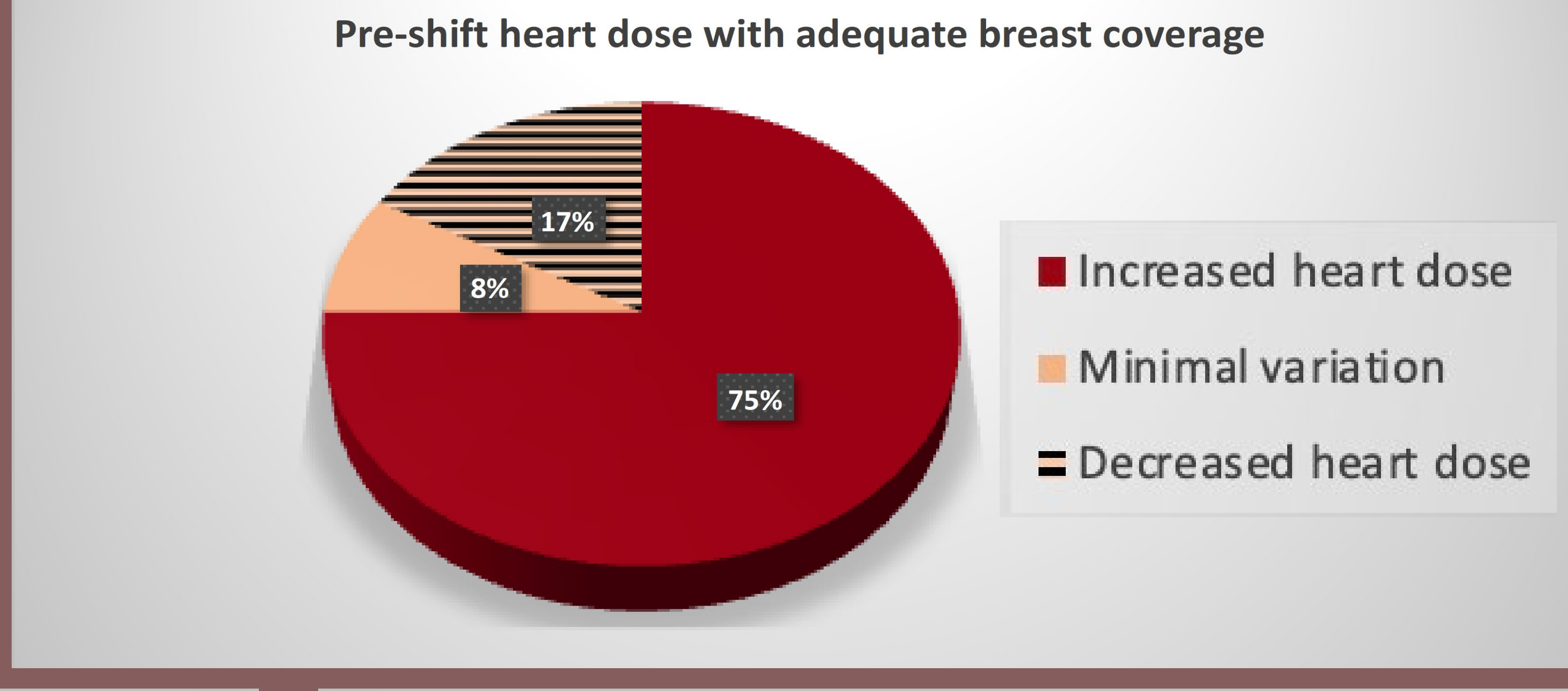
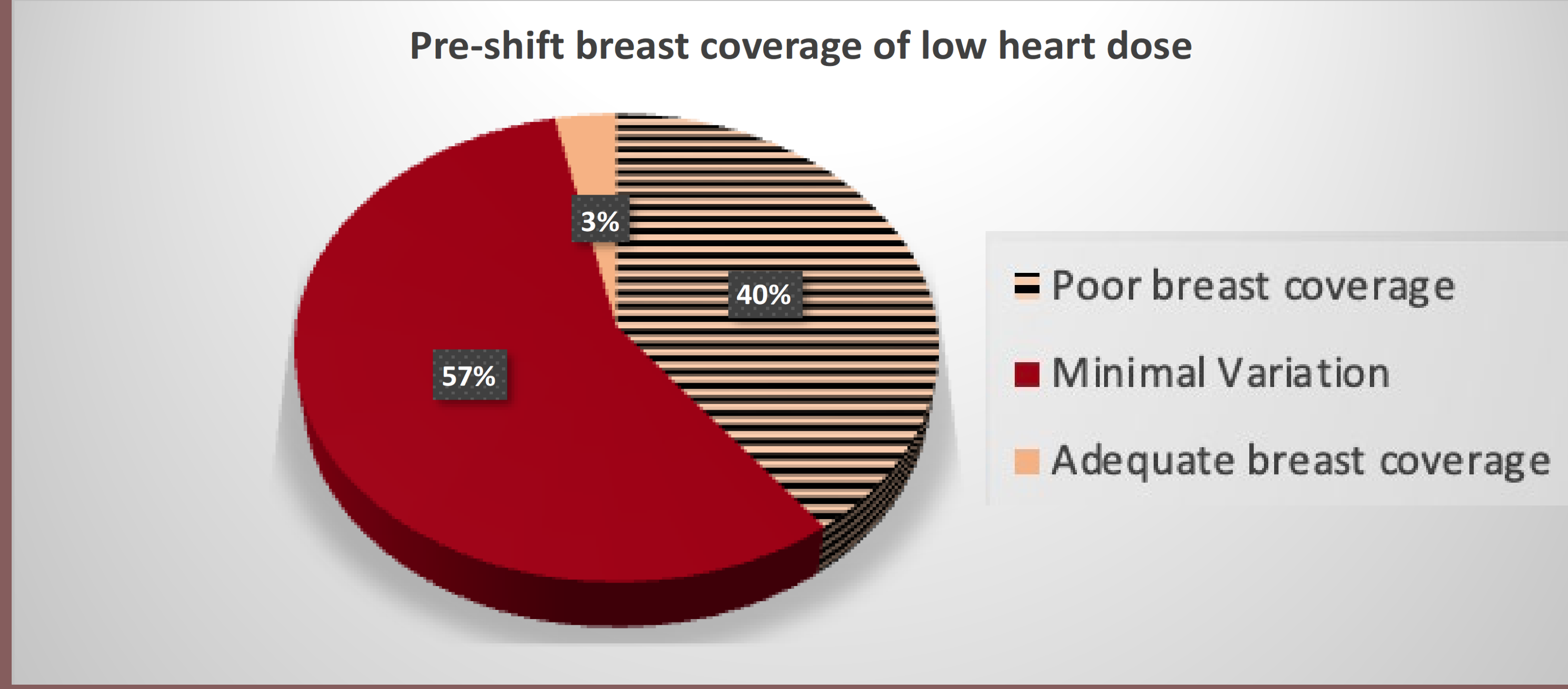
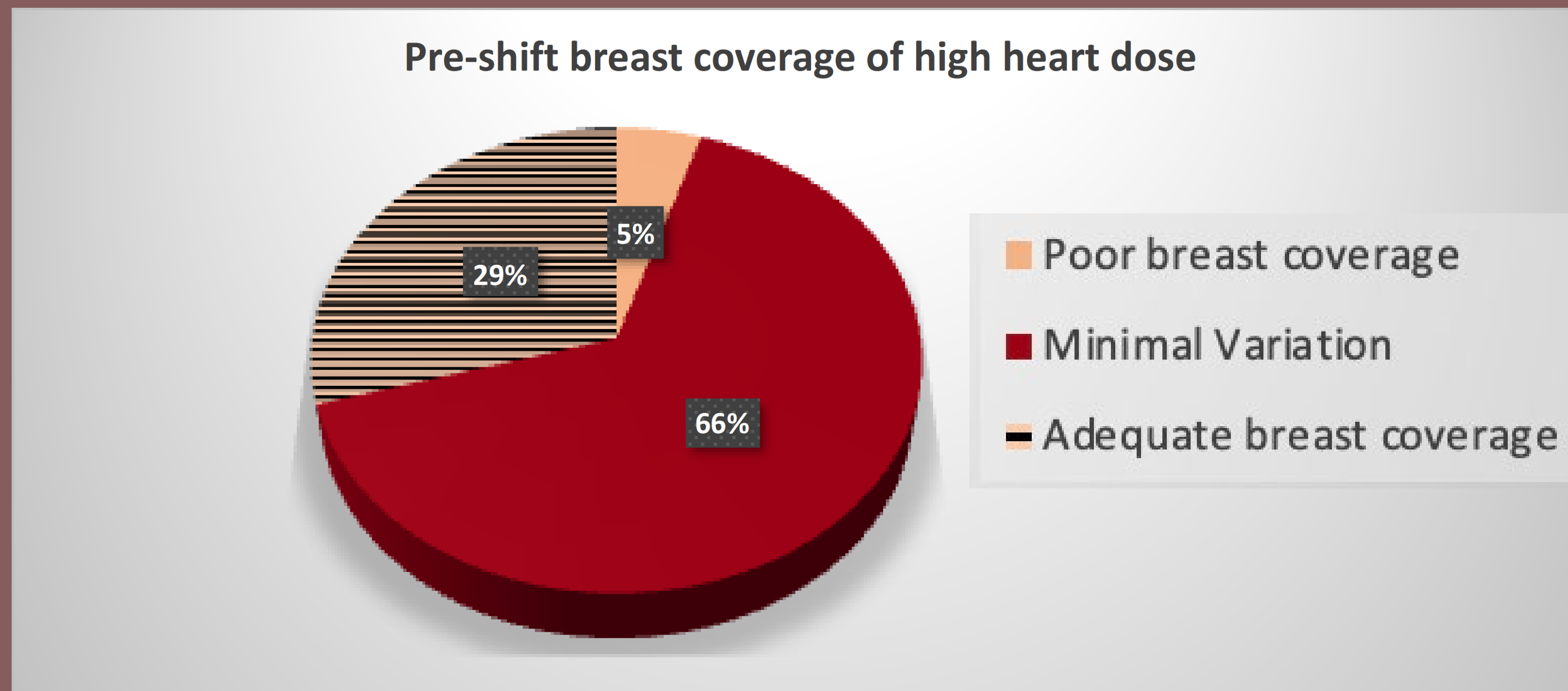
Daily cone beam CT imaging will improve dosimetric outcomes of whole breast radiation therapy.

Methods

- Retrospective chart review of 18 patients treated with prone breast radiotherapy at for a diagnosis of early-stage left sided breast cancer.
- Daily shifts for correct patient positioning were uploaded into the treatment planning system to calculate the dose if these shifts were not performed.

Statistical comparisons were made using student t-tests

Significant variation exists in daily setup for early-stage breast cancer patients receiving prone breast radiation.



Results

Parameters	Mean	Range
Age	61.6	39-80
BMI	28.3	20-45
CBCT's	15.8	13-25

Table 1: Patient demographics

	Minimal Variation (<5%)	Significant variation (>5%)	P-value
Weight/kg	84	63	0.0117
BMI/kg/m ²	34	25	0.0125
Breast volume/cc	1594	890	0.0129

Table 2: Differences in patients who had minimal variation versus those that did not

Discussion

Significant variations exist in daily setup for patients receiving prone breast radiation. Most patients would have either received significantly increased heart dose or suboptimal breast coverage if setup errors were not identified and corrected on pre-treatment CT imaging.

Acknowledgements

Thank you to Dr. Angel Moran and Dr. Jason Zhao for their endless support and mentorship.

