

UCSF

UC San Francisco Previously Published Works

Title

Consensus on melanonychia nail plate dermoscopy.

Permalink

<https://escholarship.org/uc/item/45x9b3qt>

Journal

Anais Brasileiros de Dermatologia, 88(2)

Authors

Di Chiacchio, Nilton

Farias, Débora

Piraccini, Bianca

et al.

Publication Date

2013

DOI

10.1590/S0365-05962013000200029

Peer reviewed

Consensus on melanonychia nail plate dermoscopy*

Consenso sobre dermatoscopia da placa ungueal em melanoniquias

Nilton Di Chiacchio¹
Sergio Henrique Hirata⁴
Ralph Daniel⁷
Beth S Ruben⁹
Eckart Haneke¹²
Richard Scher¹⁵

Débora Cadore de Farias²
Bertrand Richert⁵
Pier Alessandro Fanti³
Philip Fleckman¹⁰
Patricia Chang¹³
Antonella Tosti¹⁶

Bianca Maria Piraccini³
Martin Zaiac⁶
Josette Andre⁸
Phoebe Rich¹¹
Judith Dominguez Cherit¹⁴

Abstract: This statement, focused on melanonychia and nail plate dermoscopy, is intended to guide medical professionals working with melanonychia and to assist choosing appropriate management for melanonychia patients. The International Study Group on Melanonychia was founded in 2007 and currently has 30 members, including nail experts and dermatopathologists with special expertise in nails. The need for common definitions of nail plate dermoscopy was addressed during the Second Meeting of this Group held in February 2008. Prior to this meeting and to date (2010) there have been no evidence-based guidelines on the use of dermoscopy in the management of nail pigmentation.

Keywords: Dermoscopy; Melanoma; Nails; Nail diseases

Resumo: Este consenso, com foco em melanoníquia e dermatoscopia da lâmina ungueal, se destina a orientar os médicos que trabalham com melanoníquia e auxiliar no manejo destes pacientes. O grupo internacional de estudos sobre melanoníquia foi fundada em 2007 e tem agora 30 membros, incluindo dermatologistas e dermatopatologistas com conhecimento especializado em unhas. A necessidade de definições comuns de dermatoscopia da lâmina ungueal foi abordada durante a segunda reunião deste grupo, realizada em fevereiro de 2008. Antes desta reunião e até a presente, não existem orientações com base em evidências sobre a utilização de dermatoscopia da placa ungueal.

Palavras-chave: Dermoscopia; Doenças da unha; Melanoma; Unhas

Received on 05.04.2012.

Approved by the Advisory Board and accepted for publication on 15.06.2012.

* Paper produced by the International Study Group Meeting on Melanonychia (2010) - Miami, USA.

Conflict of interest: None

Financial funding: None

¹ MD - Dermatology Clinic, Hospital do Servidor Público Municipal de São Paulo - São Paulo (SP), Brazil.

² MD - Dermatology Clinic, University Hospital, Federal University of Santa Catarina (HU-UFSC) - Florianópolis (SC) - Brazil.

³ MD - Department of Dermatology, University of Bologna (UNIBO) - Bologna, Italy.

⁴ MD - Department of Dermatology, Federal University of São Paulo (UNIFESP) - São Paulo (SP), Brazil.

⁵ MD - Dermatology Department, University of Liège (ULg) - Liège, Belgium.

⁶ MD - Greater Miami Skin and Laser Center - Miami, USA.

⁷ MD - Department of Dermatology, University of Mississippi; Department of Dermatology, University of Alabama (UA) - Birmingham, USA.

⁸ MD - Department of Dermatology, Université Libre de Bruxelles (ULB) - Brussels, Belgium.

⁹ MD - Departments of Dermatology and Pathology, University of California - California, USA.

¹⁰ MD - Division of Dermatology, University of Washington - Washington, DC USA.

¹¹ MD - Department of Dermatology, University of Oregon - Oregon, USA.

¹² MD - Dermatology Practice, Freiburg (Germany) and Dermatology Department, University of Berne - Berne, Switzerland.

¹³ MD - Department of Dermatology, Hospital Angeles - Mexico City, Mexico.

¹⁴ MD - Department of Dermatology, Hospital General "Dr Manuel Gea González" - Mexico City, México.

¹⁵ MD - Department of Dermatology, University of North Carolina - Chapel Hill, USA.

¹⁶ MD - Department of Dermatology, Miller Medical School, University of Miami - Coral Gables, USA.

This statement, focused on melanonychia and nail plate dermoscopy, is intended to guide medical professionals working with melanonychia and to assist choosing appropriate management for melanonychia patients.

The International Study Group on Melanonychia was founded in 2007 by Professor Antonella Tosti and Professor Nilton Di Chiacchio. The Group includes nail experts and dermatopathologists with expertise in nails from twelve different countries.

Prior to this meeting and to date there have been no evidence-based guidelines on the use of dermoscopy in the management of nail pigmentation.

16 members of the International Study Group on Melanonychia participated in this study.

A detailed literature search on nail dermoscopy, nail pigmentation and melanonychia including Medline, Embase, Cochrane and a hand search were carried out⁽¹⁻¹⁰⁾. Based on the available literature, the Group decided to develop an informal consensus process at S1 level.

The Group reviewed publications on melanonychia and nail plate dermoscopy (Pub med indexed or not), approved by the American Academy of Dermatology, Miami, 2010 (Table 1).

This clinical consensus statement proposes consideration of a number of important points. About the technique used for nail dermoscopy, devices, polarized and non-polarized that can be used for nail plate dermoscopy. No evidence or consensus exists on which instrument and what kind of light source is the most effective. The color and definition of the lines may vary among the different devices. The group suggests using the same device in the follow-up evaluation of the patient, with magnification of 10X (the best). This allows the whole nail plate to be seen in the field, as well as the regularity of lines to be evaluated. The best immersion fluid for the nail plate is ultrasound gel.

According to the patterns found, the group agrees that nail plate dermoscopy is useful to distinguish blood from melanin. Subungual hemorrhages have a distinct pattern of globules, with or without distal streaks, with a range of color varying from red to brown to black (Figure 1A). The risk of coincidental bleeding from a subungual tumor must be taken into consideration. The dermoscopic diagnosis of subungual hematoma does not rule out a coincident nail tumor.

According to the literature, the pattern of benign melanonychia due to melanocyte activation (ethnic-type or drug-induced pigmentation) and lentigo exhibits a homogeneous gray coloration of the background with thin longitudinal gray lines. The group agrees that it is difficult to distinguish a light

brown from a gray background and that a gray background is infrequently observed (Figure 1 B). The color of the background is not a distinctive feature of benign lesions due to melanocyte activation. The color due to the melanin deposition may vary depending on the thickness of the nail and melanin location within the nail plate because of the "Tyndall" effect.

The brown background associated with regular parallel lines of identical color, spacing, and width suggests a benign lesion, either nevus or lentigo. The group agrees, even though this regular pattern is not often observed. Most benign lesions in children and adults show a brown background with longitudinal lines of different color and width. Line distribution within the band is most frequently irregular (Figure 1 C).

The brown background associated with longitudinal lines that are irregular in color, width, spacing, and parallelism is suggestive of malignant melanoma. The group agrees that benign nevi in children often show this pattern. Even in benign lesions of adults, individual lines may be irregular in width and color. The important point is the homogeneity of color and width of each individual longitudinal line. If an individual line shows irregularity in color or width along its length this is considered suspicious of melanoma. Melanoma in adults often shows a diffuse dark background with barely visible lines (Figure 1 D). The group agrees that a dark background with areas of different hue of pigmentation is suggestive of melanoma even in the absence of irregular lines.

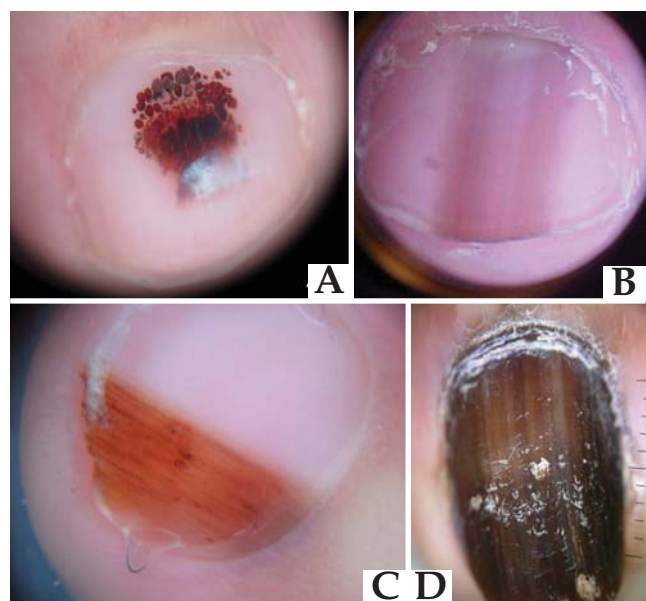


FIGURE 1: A - Subungual hemorrhages showing pattern of globules; B - Benign melanonychia due to melanocyte activation - difficult to distinguish a light brown from a gray background; C - Benign lesions in children (nevus) showing a brown background with longitudinal lines of different color and width; D - A melanoma with dark background with areas of different hue of pigmentation

TABLE 1: Review of the literature

First Author	Number of cases	Nail plate dermoscopy	Pathology
Imakado S, et al ⁶	2	Dermoscopic examination of the site of Hutchinson’s sign showed irregular pigmentation on the ridge. Nail plate dermoscopy not described.	MM <i>in situ</i>
Gencoglan G, et al ³	1	Homogeneous, brownish, regular bandlike pigmentations with indistinct borders were seen on 4 toenails	LHS
Antonovich DD, et al ⁷	1	With dermoscopy the pigmentation was observed as streaky and irregular.	MM <i>in situ</i>
Caseret AS, et al ⁴	1	Homogeneous blue blotch and a regularly-pigmented grayish longitudinal melanonychia	Blue nevus
Iorizzo M, et al ⁸	2	C1: Dark brown to gray background with longitudinal and irregular parallel lines. Edges appeared ill-defined C2: No nail plate dermoscopy	MM <i>in situ</i>
Hirata SH, et al ⁵	10	C1: Brown coloration of the background, brown-black regular lines C2: Brown coloration of the background, regular lines C3: Grayish and brown coloration of the background, regular lines C4: Grayish and brown coloration of the background, regular lines C5: Brown coloration of the background, brown-black regular lines C6: Black coloration of the background C7: Grayish and brown coloration of the background, regular lines C8: Grayish and brown coloration of the background, regular lines C9: Grayish and brown coloration of the background, regular lines C10: Brown coloration of the background, black regular lines	C1: TMH C2: TMH C3: TMH C4: TMH C5: JMN C6:TMH C7:CH C8:CH C9:CH C10: OC
Hass N, et al ²	1	18 individual pseudopods protruded along its longitudinal axis, up to 1.1 mm in length and 0.2 mm wide and of straight or twisted shape	Hemorrhage
Kawabata Y, et al ¹¹	24	6 MM: Initially longitudinal pigmented streaks in the nail plate which increased in breadth, finally involving the whole nail plate, without deformities. Hutchinson’s sign was observed in all cases. 18 BMN: 15 showed partial pigmentation in the nail plate, and in 3 the entire nail plate was involved, without deformities. Pigmented macules of the fingertip were observed in the same 3 cases and another 2 cases. However the surface profiles of the hyponychial pigmentation of subungual melanoma obtained by the dermoscope were different from those of BMN, although dermoscopic features of the nail plates are indistinguishable. The pattern of pigmentation of BMN had a brushy linear structure across the skin marks. In contrast, subungual melanoma <i>in situ</i> exhibited haphazard pigmentation distributed in a disorderly fashion over the entire surface.	6 MM 18 BMN

Continuation

TABLE 1: Review of the literature

First Author	Number of cases	Nail plate dermoscopy	Pathology
Ronger S, et al 1	148	Melanoma (20 cases): association of brown pigmentation of the background (19/20; 95%) with longitudinal brown to black lines irregular in their coloration, spacing, thickness and parallelism. The irregular pattern of the lines was significantly associated with melanoma when compared with all other diagnoses (P=.001, taken either individually or as a group (P=.001 in all 5 differential diagnoses). Melanoma shared with melanocytic nevus the brown coloration of the background.	20 MM
		Melanocytic nevus (37 cases): brown background (37/37; 100%) and the regular pattern of the longitudinal lines (35/37; 95%) . The presence of these lines, regular in their thickness, spacing, coloration, and parallelism, was found statistically sufficient to distinguish nevus from melanoma (P=.001).	37BMN
		Drug-induced nail pigmentation (16cases): grayish coloration of the background (15/16; 94%) and the presence of thin longitudinal gray lines with regular thickness, spacing, coloration and absence of parallelism disruption. These dermoscopic findings were no different from the ones observed in ungual lentigo or ethnic-type pigmentation, but significantly differed from melanoma (P=.001).	16 DHNP
		Nail apparatus lentigo (45 cases): grayish coloration of the background (44/45; 98%) and the presence of thin longitudinal gray lines, regular in their coloration, thickness and spacing (42/45; 93%). The presence of these 2 criteria significantly differentiated nail lentigo from melanoma (P=.001).	45 NAP
		Ethnic-type pigmentation (8 cases): The patterns in these cases were similar to those previously described in ungual lentigo and drug induced nail pigmentation, but significantly different from those of melanoma (P=.001). The two characteristic dermoscopic features of ethnic-type nail pigmentation were the grayish background (7/8; 87.5%) and the thin, regular gray lines (7/8; 87.5%).	8ETP
		Subungual hemorrhage (22 cases): well-defined, rounded proximal edge and a purple to brown coloration were observed in all cases of subungual hemorrhages (22/22; 100%).	22 SH
Bilemjian APJ, et al 10	2	C1: 1st right digit : Lateral side: A light and dark brown color pigmentation, distributed in a linear and parallel fashion throughout the nail from the cuticle to the free edge. Medial part: A totally amorphous and irregular area, affecting the proximal nail fold - the micro-Hutchinson sign.	C1: MM in situ
		C2: 5th left digit: Brown parallel homogeneous longitudinal lines; regular in space, width and color.	C2: TMH

LHS: Laugier Hunziker Syndrome
 TMH: Typical melanocytic hyperplasia
 JMN: Junctional melanocytic nevus
 CH: Constitutional pigmentation (Hypermelanosis)

OC: Onychomycosis
 BMN: Benign melanocytic nevi
 DHNP: Drug-induced nail pigmentation
 NAL: Nail apparatus lentigo

ETP: Ethnic type pigmentation
 SH: Subungual hemorrhage
 MM: Malignant Melanoma

Other applications of dermoscopy at the nail apparatus are reported. Distal edge dermoscopy is helpful for identifying the origin of the pigment producing lesion (distal or proximal matrix). The group agrees that distal edge dermoscopy is not always useful, particularly when the nail plate is thin. The same applies to very dark or very light bands. Dermoscopy of the hyponychium allows to distinguish pigmentation due to melanocytic nevi characterized by linear pigmentation in the furrows or across the skin marks, from pigmentation associated with nail melanoma (Hutchinson's sign), where dermoscopy shows haphazard pigmentation distributed in a parallel ridge pattern in a disorderly fashion.¹¹ The group agrees that dermoscopy of the hyponychium is useful in cases where melanonychia is associated with pigmentation of the hyponychium.

The group agrees that the nail plate dermoscopic patterns stated in the literature, as indicative of nail melanoma, need to be modified as follows:

- Brown bands with lines irregular in color, width and spacing are not indicative of melanoma in children;
- Benign lesions in adults can present with irregular lines and spacing; and
- Melanoma in adults is often present with a very dark background where the lines are difficult to see.

The group also agrees that at present any decision to excise should be based on established clinical criteria (history and physical exam) and not on nail plate dermoscopy patterns. Dermoscopy of the hyponychium is very useful for differential diagnosis between nevi and melanoma in the case of pigmentation of the periungual tissues. □

REFERENCES

1. Ronger S, Touzet S, Ligeron C, Balme B, Villard AM, Barrut D, Collin C, Thomas L. Dermatoscopic examination of nail pigmentation. *Arch Dermatol*. 2002;138:1327-33.
2. Haas N, Henz BM. Pitfall in pigmentation: pseudopods in the nail plate. *Dermatol Surg* 2002;28:966-7
3. Gencoglan G, Gerceker-Turk B, Kilinc-Karaarslan I, Akalin T, Ozdemir F. Dermoscopic findings in Laugier-Hunziker syndrome. *Arch Dermatol*. 2007;143:631-633
4. Caseret AS, Skowron F, Viillard AM, Balme B, Thomas L. Subungual blue nevus. *J Am Acad Dermatol*. 2003;49:310-2.
5. Hirata SH, Yamada S, Almeida FA, Enokihara MY, Rosa IP, Enokihara MM, et al. Dermoscopic examination of the nail bed and matrix. *Int J Dermatol*. 2006;45:28-30.
6. Imakado S, Sato H, Hamada K. Two cases of subungueal melanoma in situ. *J Dermatol*. 2008;35:754-8.
7. Antonovich DD, Grin C, Grant-Kels JM. Childhood subungual melanoma in situ in diffuse nail melanosis beginning as expanding longitudinal melanonychia. *Pediatr Dermatol*. 2005;22:210-2.
8. Iorizzo M, Tosti A, Di Chiacchio N, Hirata SH, Misciali C, Michalany N, et al. Nail melanoma in children: differential diagnosis and management. *Dermatol Clin*. 2008;34:974-8.
9. Braun RP, Baran R, Saurat JH, Thomas L. Surgical Pearl: Dermoscopy of the free edge of the nail to determine the level of nail plate pigmentation and the location of its probable origin in the proximal or distal nail matrix. *J Am Acad Dermatol*. 2006;55:512-3.
10. Bilemjan APJ, Maceira JP, Barcaui CB, Pereira FB. Melanoniquia: importância da avaliação dermatoscópica e da observação da matriz / leito ungueal. *An Bras Dermatol*. 2009;84:185-9.
11. Kawabata Y, Ohara K, Hino H, Tamaki K. Two kinds of Hutchinson's sign, benign and malignant. *J Am Acad Dermatol*. 2001;44:305-7.

MAILING ADDRESS:
 Nilton Di Chiacchio
 Rua Dr. César 62 Conj. 35.
 02013-000 São Paulo (SP)
 Brazil
 E-mail: ndichia@terra.com.br

How to cite this article: Di Chiacchio N, Cadore de Farias D, Piraccini BM, Hirata SH, Richert B, Zaiac M, Fanti PA, Andre J, Ruben BS, Fleckman P, Rich P, Haneke E, Chang P, Cherit JD, Scher R, Tosti A. Consensus on melanonychia nail plate dermoscopy. *An Bras Dermatol*. 2013;88(2):309-13.