

# UC San Diego

## UC San Diego Previously Published Works

### Title

Overview and recent advances in the treatment of neuroblastoma

### Permalink

<https://escholarship.org/uc/item/45m7j5hg>

### Journal

Expert Review of Anticancer Therapy, 17(4)

### ISSN

1473-7140

### Authors

Whittle, Sarah B  
Smith, Valeria  
Doherty, Erin  
[et al.](#)

### Publication Date

2017-04-03

### DOI

10.1080/14737140.2017.1285230

Peer reviewed



## Overview and recent advances in the treatment of neuroblastoma

Sarah B. Whittle, Valeria Smith, Erin Doherty, Sibio Zhao, Scott McCarty & Peter E. Zage

To cite this article: Sarah B. Whittle, Valeria Smith, Erin Doherty, Sibio Zhao, Scott McCarty & Peter E. Zage (2017) Overview and recent advances in the treatment of neuroblastoma, Expert Review of Anticancer Therapy, 17:4, 369-386, DOI: [10.1080/14737140.2017.1285230](https://doi.org/10.1080/14737140.2017.1285230)

To link to this article: <http://dx.doi.org/10.1080/14737140.2017.1285230>



Accepted author version posted online: 01 Feb 2017.  
Published online: 15 Mar 2017.



Submit your article to this journal [↗](#)



Article views: 73

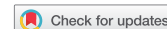

View related articles [↗](#)



View Crossmark data [↗](#)

REVIEW



## Overview and recent advances in the treatment of neuroblastoma

Sarah B. Whittle<sup>a</sup>, Valeria Smith<sup>a</sup>, Erin Doherty<sup>a</sup>, Sibao Zhao<sup>a</sup>, Scott McCarty<sup>b</sup> and Peter E. Zage<sup>b</sup>

<sup>a</sup>Department of Pediatrics, Section of Hematology-Oncology, Texas Children's Cancer and Hematology Centers, Baylor College of Medicine, Houston, TX, USA; <sup>b</sup>Department of Pediatrics, Division of Hematology-Oncology, University of California San Diego, La Jolla, CA and Peckham Center for Cancer and Blood Disorders, Rady Children's Hospital, San Diego, CA, USA

### ABSTRACT

**Introduction:** Children with neuroblastoma have widely divergent outcomes, ranging from cure in >90% of patients with low risk disease to <50% for those with high risk disease. Recent research has shed light on the biology of neuroblastoma, allowing for more accurate risk stratification and treatment reduction in many cases, although newer treatment strategies for children with high-risk and relapsed neuroblastoma are needed to improve outcomes.

**Areas covered:** Neuroblastoma epidemiology, diagnosis, risk stratification, and recent advances in treatment of both newly diagnosed and relapsed neuroblastoma.

**Expert commentary:** The identification of newer tumor targets and of novel cell-mediated immunotherapy agents may lead to novel therapeutic approaches, and clinical trials for regimens designed to target individual genetic aberrations in tumors are underway. A combination of therapeutic modalities will likely be required to improve survival and cure rates for patients with high-risk neuroblastoma.

### ARTICLE HISTORY

Received 14 June 2016  
Accepted 18 January 2017

### KEYWORDS

Neuroblastoma; INRG; MYCN; ALK; immunotherapy; MIBG; dinutuximab

## 1. Introduction

Neuroblastoma is a childhood tumor derived from primordial neural crest cells and is the most common extracranial solid tumor of childhood. Under normal conditions, neural crest cell precursors migrate from the dorsal neural tube and differentiate upon reaching their appropriate locations into tissues and organs of the sympathetic nervous system, but in some cases, defects in neural crest cell migration, maturation, or differentiation, many of which remain to be defined, can lead to the development of neuroblastoma. One of the interesting features of neuroblastoma is the unique clinical and biological heterogeneity of neuroblastoma tumors, with some children having tumors that regress completely or that spontaneously differentiate without treatment, while other children have widespread metastatic tumors with poor outcomes despite aggressive multimodal therapy. Clinical and laboratory research has increased our understanding of the biology of neuroblastoma, and neuroblastoma risk stratification has served as a paradigm for the use of clinical and biological prognostic factors to develop therapies for use in the appropriate patient subsets.

The significant heterogeneity of neuroblastoma has fascinated investigators, and decades of research efforts have identified novel biomarkers for stratification and prognostication as well as novel cellular pathways that can be targeted by new treatment strategies. Prognostic factors identified to date include clinical factors, such as the patient's age at diagnosis and the tumor stage, as well as biologic features of the tumor itself, such as the presence or absence of amplification of the *MYCN* oncogene. In order to address differences in disease risk

classification schemes among large cooperative groups, a new international classification system has been recently adopted that utilizes a new, more uniform staging system incorporating presurgical risk factors for more consistent staging of patients diagnosed and treated worldwide.

Using selected clinical, pathologic, and genetic factors, patients can be subdivided into risk groups for treatment. Current overall survival (OS) rates for patients with non-high-risk neuroblastoma are greater than 90% with limited treatment, and treatment regimens for patients with low- and intermediate-risk neuroblastoma have been designed to further decrease the therapeutic intensity and to reduce associated toxicity. However, the long-term survival rates for patients with high-risk neuroblastoma are currently less than 50% despite aggressive, multimodal treatment and the recent inclusion of immunotherapy with antibodies directed against the GD2 antigen on neuroblastoma tumor cells. Ongoing research to identify novel prognostic factors and therapeutic targets will hopefully lead to the development of improved treatment strategies for these patients.

## 2. Epidemiology & genetics

The estimated incidence of neuroblastoma is 10.5 cases per million children under 15 years of age in North America and Europe, with minimal ethnic or geographic variability [1–4]. Neuroblastoma accounts for approximately 10% of all pediatric cancers but unfortunately also accounts for up to 15% of deaths in children from cancer. Neuroblastoma is predominantly a cancer of small children, as the majority of children

with neuroblastoma are diagnosed before 5 years of age, with a median age of patients at diagnosis of 19 months. Neuroblastoma is also the most common cancer diagnosed in infants and occurs slightly more often in boys than girls. African American and Native American patients are more likely to have more aggressive disease with lower survival rates, although the etiologies of these differences are unclear [5].

Large-scale national screening studies of infants via evaluation of urinary catecholamine levels have led to the diagnosis of neuroblastoma in a higher number of children, although most of the detected tumors were low risk, with favorable clinical and biological features [6–9]. In multiple studies, screening of asymptomatic infants has not resulted in increased detection rates for advanced disease, which usually presents at an older age. Screening also did not improve OS rates for neuroblastoma in these studies [10], suggesting that early detection of low-risk disease does not prevent the subsequent progression of disease to more aggressive, high-risk forms; rather, neuroblastoma tumors likely have established features of either low- or high-risk disease at the time of disease onset.

The underlying etiology of most neuroblastoma tumors remains unknown, and although environmental factors have been suggested as possible causes, direct linkage has not been clearly established [11–13]. The vast majority of neuroblastoma tumors occur in isolation in families, suggesting that the rates of oncogenic germline mutations in patients with neuroblastoma are low. Approximately 1–2% of all cases of neuroblastoma are associated with a positive family history [14], with autosomal dominant inheritance with incomplete penetrance. Cases of familial neuroblastoma often present with multifocal or bilateral adrenal primary tumors and are diagnosed at a median of 9 months of age. Neuroblastoma also occurs in patients with neurocristopathies such as Hirschsprung disease and central hypoventilation syndrome (CHS), and although the underlying etiologies of these associations are not clear, mutations in the *PHOX2B* gene that are associated with Hirschsprung disease and central hypoventilation have also been detected in some cases of familial neuroblastoma [15–17]. Furthermore, although there have been a number of reported cases of neuroblastoma in patients with neurofibromatosis, the role of germline *NF1* mutations in the etiology of neuroblastoma remains unclear [18].

Large-scale genetic linkage studies performed in pedigrees with familial neuroblastoma have identified several candidate chromosomal predisposition regions, including 2p23–36, 12p, and 16p, which subsequently led to the discovery of germline mutations in the anaplastic lymphoma kinase (*ALK*) gene [19–22]. The majority of patients with familial neuroblastoma have germline mutations in *ALK* [19], and sporadic neuroblastoma tumors also occasionally harbor *ALK* abnormalities, including 2–3% of tumors with genomic amplification and approximately 10% with missense mutations [19,21–25].

Genome-wide association studies (GWAS) have also identified additional germline genetic variants in neuroblastoma patients, including single-nucleotide polymorphisms in *LIN28B*, *BARD1*, and *LMO1*, among others [26–29] as well as other polymorphisms in other chromosomal regions yet to be fully characterized [30,31]. These polymorphisms occur

**Table 1.** Neuroblastoma patient symptoms.

Asymptomatic mass
Neck
Thorax
Abdomen/pelvis
Horner syndrome
Spinal cord compression
Back pain, weakness
Bone pain
Limp
Refusal to walk
'Blueberry muffin' skin lesions
Systemic symptoms
Weight loss
Irritability
Fever
Hypertension
Intractable diarrhea (VIP)
Opsoclonus/Myoclonus/Ataxia Syndrome
Cytopenias
Anemia – pallor, fatigue
Thrombocytopenia – bruising, bleeding
Disseminated intravascular coagulation (DIC)
Tumor lysis syndrome

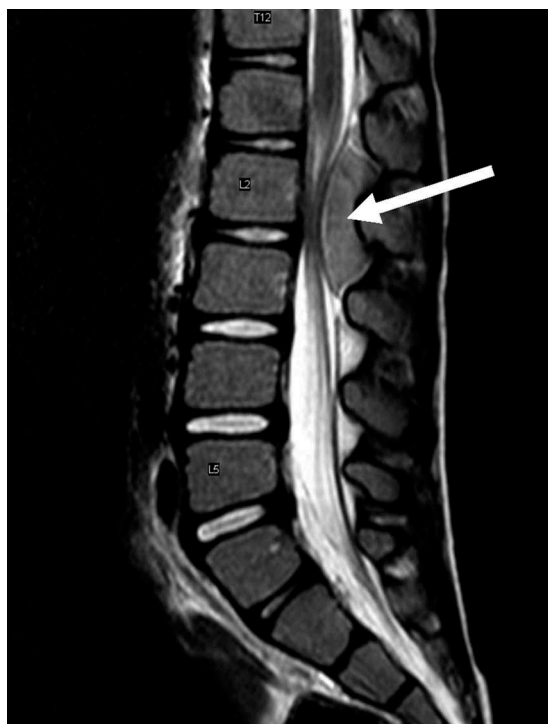relatively frequently in the general population and may contribute to the development of sporadic neuroblastoma, although the functional roles of these germline variants and other somatic alterations remain to be elucidated.

### 3. Symptoms & diagnosis

The presenting symptoms in children with neuroblastoma vary based on the number and location of tumors and can include both local and systemic symptoms (Table 1). Approximately half of patients present with localized or regional disease, with the remainder having distant metastases, with the bones, bone marrow, and liver being common metastatic sites.

Most neuroblastoma tumors arise in the abdomen, and the most common primary site for neuroblastoma is the adrenal gland. Abdominal masses may be asymptomatic or may result in hypertension, abdominal pain, distension, or constipation from local effects on abdominal organs. Approximately 10–15% of patients with neuroblastoma will have tumor extension into the epidural or intradural space that may lead to spinal cord compression and paraplegia [32] (Figure 1). Neuroblastoma also commonly spreads to the orbital bones, resulting in periorbital ecchymoses (raccoon eyes) characteristic of neuroblastoma, along with proptosis and eventual visual impairment. Tumors that originate in either the cervical or thoracic regions are more common in infants and may be associated with Horner syndrome (unilateral ptosis, anhidrosis, and miosis) and respiratory symptoms.

Additional paraneoplastic syndromes associated with neuroblastoma include excess tumor production of vasoactive intestinal peptide (VIP) leading to refractory secretory diarrhea [33] and opsoclonus-myoclonus-ataxia (OMA) syndrome. OMA syndrome occurs in approximately 2–3% of children with neuroblastoma and often occurs in the setting of well-differentiated, low-risk tumors [34,35]. The symptoms of OMA are generally felt to be immune mediated, and children with OMA suffer from myoclonic jerks and random eye movements,



**Figure 1.** Spinal MRI of a patient with spinal cord compression by neuroblastoma tumor mass. A sagittal T2-weighted image demonstrating the tumor mass (white arrow) is shown.

occasionally associated with ataxia. Symptoms of OMA syndrome often persist after resection, and can also be associated with dramatic long-term motor impairment, speech and language delay and significant cognitive dysfunction [36,37].

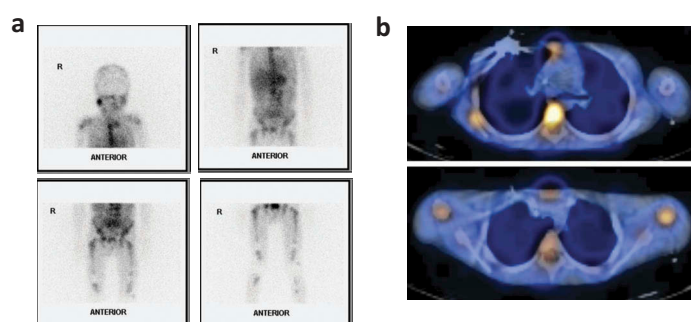
The evaluation to determine the disease stage in children with neuroblastoma commonly includes imaging of the primary tumor site with CT or MRI to determine primary tumor size and regional invasion and spread as well as additional imaging of the chest, abdomen, and pelvis to identify spread to other distant sites (Figure 2). Meta-iodobenzylguanidine (MIBG) scans can be used to detect primary tumors and metastatic sites, with approximately 90% of patients having MIBG-avid tumors. For those patients who do not have MIBG-avid disease, [18 F]-fluorodeoxyglucose positron emission tomography (FDG-PET) scans are recommended for detecting

metastatic disease [38–40]. Either head CT or brain MRI imaging should also be performed when intracranial metastases are suspected or when otherwise clinically indicated. In addition to imaging studies, bone marrow aspirates and biopsies from at least two independent sites are generally obtained to determine tumor involvement [41]. The ultimate diagnosis of neuroblastoma can be confirmed either by tumor tissue biopsy with histopathologic diagnosis or by the combination of either elevated urine or serum catecholamine levels or a positive MIBG scan plus a bone marrow aspirate or biopsy with detectable tumor cells.

#### 4. Prognosis & risk stratification

With the biological and clinical heterogeneity of neuroblastoma tumors, a variety of prognostic features associated with patient outcomes have been identified. Treatment strategies for children with neuroblastoma have been tailored according to the predicted response to therapy and risk of relapse for more than 40 years [42], and treatment stratification has become increasingly important as we obtain a better understanding of clinical and biological risk factors. These prognostic factors range from clinical factors such as tumor stage and the patient's age at diagnosis, to biological features of the tumor such as histology and DNA ploidy, cytogenetic factors including amplification of the *MYCN* oncogene and key chromosomal deletions or gains, and serum tumor markers as well as other molecular markers (Table 2).

Using subsets of known clinical and biological prognostic factors, patients with neuroblastoma can be classified into one of three risk groups: low risk, intermediate risk (IR), and high risk (HR). Factors recently employed by the Children's Oncology Group (COG) for risk stratification included patient age at diagnosis, tumor stage, tumor histopathology using the International Neuroblastoma Pathology Classification (INPC) system [43–45], DNA index (ploidy), and the presence of absence of *MYCN* amplification (Table 3). For many children with neuroblastoma, this risk stratification and subsequent treatment determination has been successful (Figure 3), as the outcomes for children with low- and intermediate-risk neuroblastoma have been excellent, with approximately 90% long-term event-free survival rates. However, children with



**Figure 2.** Image of a patient with meta-iodobenzylguanidine (MIBG) avid neuroblastoma. (a). Abnormal MIBG activity within the head, chest, abdomen and multiple osseous structures in the cervical, thoracic and lumbar spine. Additional abnormal increased uptake is seen within the sternum, bilateral proximal humeri, scapulae, bilateral iliac bones, sacrum, bilateral ischii, bilateral femora and proximal tibiae. (b). Fused MIBG/CT axial imaging demonstrating MIBG uptake in the sternum, vertebral body, and posterior rib (top), and in the bilateral humeri, vertebral body, and sternum (bottom).

**Table 2.** Neuroblastoma prognostic factors and features.

	Favorable	Unfavorable
<b>Clinical factors</b>		
Stage	1, 2, 4S	3, 4
Age at diagnosis	<547 days	>547 days
<b>Biologic tumor features</b>		
Shimada histology	Favorable	Unfavorable
Ganglioneuroblastoma	Intermixed	Nodular
DNA index	Hyperdiploid, near triploid	Near diploid, near tetraploid
Vascularity	Low	High
<b>Cytogenetics</b>		
<i>MYCN</i> oncogene	Non-amplified	Amplified (>10 copies)
Chromosome 1p36	Normal	Deletion/LOH
Chromosome 11q	Normal	Deletion/LOH
Chromosome 17q	Normal	Gain
<b>Serum tumor markers</b>		
Ferritin	Low	High
LDH	Low	High
NSE	Low	High
<b>Other miscellaneous markers</b>		
Caspase 8	Expressed	Repressed (methylation)
RASSF1A	Expressed	Repressed (methylation)
Trk A	High	Low
Trk B		High
CD44	High	Low
MRP	Low	High

**Table 3.** Children's Oncology Group risk stratification.

Tumor stage	Patient age at diagnosis	<i>MYCN</i> amplification	Histology	Ploidy	Risk group
1	Any	Any	Any	Any	Low
2	Any	Not Amplified	Any	Any	Low
4S	<365 days	Not Amplified	Favorable	DI > 1	Low
2 <sup>a</sup>	Any	Not Amplified	Any	Any	Intermediate
3	<547 days	Not Amplified	Any	Any	Intermediate
3	>547 days	Not Amplified	Favorable	Any	Intermediate
4	<365 days	Not Amplified	Any	Any	Intermediate
4	365–547 days	Any	Favorable	DI > 1	Intermediate
4S	<365 days	Not Amplified	Any	DI = 1	Intermediate
4S	<365 days	Not Amplified	Unfavorable	Any	Intermediate
2	Any	Amplified	Any	Any	High
3	>547 days	Not Amplified	Unfavorable	Any	High
3	Any	Amplified	Any	Any	High
4	<365 days	Amplified	Any	Any	High
4	365–547 days	Any	Any	DI = 1	High
4	365–547 days	Any	Unfavorable	Any	High
4	365–547 days	Amplified	Any	Any	High
4	>547 days	Any	Any	Any	High
4S	<365 days	Amplified	Any	Any	High

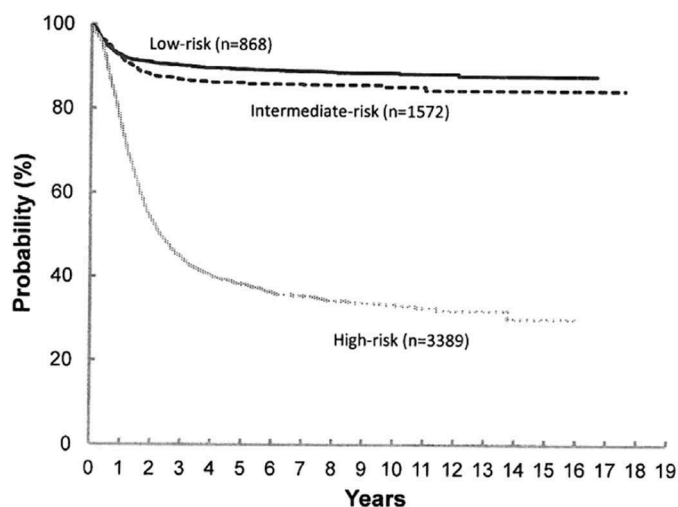
<sup>a</sup>Patients with >50% residual tumor and/or symptomatic disease. DI: DNA index

high-risk neuroblastoma remain a challenge, with long-term survival rates for children with high-risk neuroblastoma currently under 50%.

Until recently, the International Neuroblastoma Staging System (INSS) was used for neuroblastoma tumor staging [46,47]. INSS guidelines were initially developed in 1986 and subsequently revised in 1993, and these guidelines employed the combination of imaging and bone marrow evaluation for appropriate staging of neuroblastoma tumors (Table 4). The development and use of international staging systems such as the INSS has provided consistency in the staging of patients with neuroblastoma worldwide. However, cooperative groups from different regions of the world have not consistently used the same markers to classify patient risk and treatment strategies, and therefore the patient cohorts treated on risk-based

studies have not been uniform, making it difficult to compare the results of clinical trials.

To address this concern, investigators and members of major national and international cooperative groups from North America, Europe, and Asia developed the International Neuroblastoma Risk Group (INRG) classification and staging systems using data from over 8000 international patients with neuroblastoma to update and replace the INSS (Table 5). The INRG staging system (INRGSS) uses preoperative radiological features and image-defined risk factors (IDRFs) to distinguish low-risk tumors from high-risk tumors [48,49]. The INRG classification system was developed based on analysis of 13 clinical and biological variables for effects on event-free survival rates, including patient age at diagnosis, INRGSS tumor stage, serum lactate dehydrogenase and ferritin levels, tumor histological category, grade of differentiation, tumor



**Figure 3.** Event-free survival (EFS) based on Children's Oncology Group (COG) risk stratification. Kaplan-Meier survival curves were calculated from the time of diagnosis for children enrolled onto COG, Children's Cancer Group and Pediatric Oncology Group Neuroblastoma trials who were classified as low, intermediate, or high risk at the time of diagnosis. (From Park JR, Bagatell R, London WB, et al. Children's Oncology Group 2013 blueprint for research: neuroblastoma. *Pediatr Blood Cancer* 2013;60(6):986, with permission. © 2012 Wiley Periodicals, Inc.).

**Table 4.** International Neuroblastoma Staging System (INSS).

Stage	Definition
1	Localized tumor with complete gross excision, with or without microscopic residual disease; representative ipsilateral lymph nodes negative for tumor microscopically (nodes attached to and removed with the primary tumor may be positive)
2A	Localized tumor with incomplete gross excision; representative ipsilateral nonadherent lymph nodes negative for tumor microscopically
2B	Localized tumor with or without complete gross excision; with ipsilateral nonadherent lymph nodes positive for tumor. Enlarged contralateral lymph nodes must be negative microscopically
3	Unresectable unilateral tumor infiltrating across the midline, with or without regional lymph node involvement; or localized unilateral tumor with contralateral regional lymph node involvement; or midline tumor with bilateral extension by infiltration (unresectable) or by lymph node involvement
4	Any primary tumor with dissemination to distant lymph nodes, bone, bone marrow, liver, skin and/or other organs (except as defined for stage 4S)
4S	Localized primary tumor (as defined for stage 1, 2A or 2B), with dissemination limited to skin, liver, and/or bone marrow (limited to infants <1 year of age and bone marrow with <10% tumor cell involvement)

**Table 5.** International Neuroblastoma Risk Group Staging System (INRGSS).

Stage	Definition
L1	Localized tumor not involving vital structures as defined by the list of image-defined risk factors and confined to one body compartment
L2	Localized tumor with the presence of one or more image-defined risk factors (IDRFs)
M	Metastatic disease (except stage MS)
MS	Metastatic disease in children younger than 18 months of age at diagnosis with metastases limited to the skin, liver, and/or bone marrow

Adapted from [49].

mitosis-karyorrhexis index (MKI), *MYCN* gene amplification status, the presence or absence of chromosome 1p or 11q

abnormalities, DNA ploidy, the primary tumor site (adrenal or nonadrenal) and the presence or absence of metastatic disease. Seven clinically relevant and statistically significant factors (tumor stage, patient age, tumor histological category and grade of differentiation, *MYCN* gene amplification status, chromosome 11q aberration, and DNA ploidy) were incorporated into the INRG classification system (Table 6) [48]. This INRG risk stratification is currently in use in multiple national and international clinical trials, with validation of its efficacy and relevance for patient outcomes pending results of these studies [50].

## 5. Treatment – low- and intermediate-risk neuroblastoma

Non-high-risk neuroblastoma is a heterogeneous group comprised of patients with low- and intermediate-risk disease, representing slightly more than half of newly diagnosed patients. The group includes patients with non-*MYCN* amplified localized tumors as well as most infants with metastatic disease. Outcomes are generally excellent for these children, with variable treatment strategies including observation alone, surgical resection, or moderate doses of chemotherapy with surgical resection [51,52] (Figure 3).

For those patients with localized, resectable disease, surgical resection alone is generally curative, and chemotherapy is effective salvage for those with relapses after resection [53–55]. Low-stage tumors with favorable biological features often do not metastasize even after incomplete resection, and therefore, for these patients, chemotherapy is reserved for those with life or organ-threatening symptoms, such as spinal cord compression or respiratory compromise. The COG P9641 study demonstrated excellent OS for these patients with surgical resection alone, with a 5-year OS rate of 99% for those with INSS stage 1 and 96% for patients with asymptomatic INSS 2A or 2B tumors [52]. The European International Society of Pediatric Oncology Neuroblastoma Group trial LNESG1 also demonstrated that surgical resection alone is curative in the vast majority of patients with localized disease, with an OS rate of 99% for stage 1 patients and 93% for stage 2 patients [55].

In recent years, clinical trials for infants with localized adrenal masses have demonstrated excellent outcomes with observation alone. These masses tend to spontaneously regress, and can be observed without surgical resection or chemotherapy. In a COG prospective trial observing infants less than 6-months old with small adrenal masses, 81% of subjects were effectively managed with expectant observation alone, while the remaining 19% eventually underwent resection. None required chemotherapy. 3-year event-free survival (EFS) rates were 97% with OS rates of 100% [56]. This strategy has become standard of practice, and the active COG ANBL1232 study (NCT02176967) has extended the age of observation for a subset of localized tumors up to 12 months to determine whether observation alone is appropriate in this age group as well.

Infants with stage 4S/MS neuroblastoma may demonstrate spontaneous regression, likely due to the unique

**Table 6.** International Neuroblastoma Risk Group (INRG) Risk Stratification.

INRG stage	Patient age (months)	Tumor histology	Tumor differentiation	MYCN Gene amplification	11q Aberration	DNA ploidy	Pre-treatment risk group
L1/L2	Any	GN maturing, GNB intermixed	Any	Any	Any	Any	Very Low
L1	Any	Any*	Any	No	Any	Any	Very Low
MS	<18	Any	Any	No	No	Any	Very Low
L2	<18	Any*	Any	No	No	Any	Low
L2	≥18	GNB nodular, neuroblastoma	Differentiating	No	No	Any	Low
M	<18	Any	Any	No	Any	Hyperdiploid	Low
L2	<18	Any*	Any	No	Yes	Any	Intermediate
L2	≥18	GNB nodular, neuroblastoma	Differentiating	No	Yes	Any	Intermediate
L2	≥18	GNB nodular, neuroblastoma	Poorly Differentiated or Undifferentiated	No	Any	Any	Intermediate
M	<18	Any	Any	No	Any	Diploid	Intermediate
L1	Any	Any*	Any	Yes	Any	Any	High
L2	Any	Any	Any	Yes	Any	Any	High
M	<18	Any	Any	Yes	Any	Any	High
M	≥18	Any	Any	Any	Any	Any	High
MS	<18	Any	Any	Yes	Any	Any	High
MS	<18	Any	Any	Any	Yes	Any	High

\*Except GN maturing, GNB intermixed.

GN: ganglioneuroblastoma; GNB: ganglioneuroblastoma.

biological features of neuroblastoma in infants, including near-triploid DNA content and increases in expression of genes from the chromosome 1p36 region [57]. However, a subset of these patients require immediate treatment due to an increased risk for complications and death due to disease. This group includes those with massive hepatomegaly or very large tumors causing mechanical obstruction, respiratory distress, or liver dysfunction. The youngest of the stage 4S/MS patients (those less than 3-months old) have the highest rates of mortality and require careful observation and immediate treatment for any of the above symptoms [58]. A scoring system evaluating the above symptoms of clinical deterioration is being prospectively evaluated in a current COG study (NCT02176967).

Treatment for intermediate-risk neuroblastoma is comprised of moderate doses of multiagent chemotherapy and surgical resection. Using clinical and genetic data, recent trials have successfully reduced treatment for these patients while maintaining excellent survival. Risk stratification in these studies was performed based on not only the patient's age and tumor stage, but also on biologic features of the tumor, including DNA content, segmental chromosomal aberrations and histologic features. The COG A3961 study subdivided patients with IR neuroblastoma into those with favorable biology (having both favorable histology and a DNA index of more than 1) and those with unfavorable biology (having unfavorable histology, a DNA index of 1 or less, or both), where patients with favorable biology received 4 cycles of chemotherapy and those with unfavorable biology received 8 cycles. The final results demonstrated an 88% EFS rate and a 96% OS rate at 3 years using this stratified treatment approach, suggesting that subgroups of patients could maintain excellent outcomes with reduced treatment [51]. Further reduction in number of cycles given for subsets of patients is being evaluated in subsequent trials, for which follow-up is ongoing.

In a recent European study, children with localized, unresectable neuroblastoma lacking *MYCN* amplification received a reduction in chemotherapy dose intensity before an attempt at surgical resection. Although this strategy demonstrated encouraging results in children older than 12 months, children with favorable clinical features but with tumors with unfavorable genomics or histology had worse outcomes than those with favorable biologic features [59]. Therapy has generally not been reduced for those children with neuroblastoma between 12 and 18 months with stage 4 disease and diploid tumors or for those with localized unresectable disease with unfavorable histology due to worse outcomes for these patients [51,59,60].

Overall, outcomes for patients with low- or intermediate-risk neuroblastoma continue to remain excellent despite significant reductions in therapy in recent years. Efforts to further reduce chemotherapy exposure and surgical morbidity are ongoing in certain subsets of this group. The current COG study ANBL1232 (NCT02176967) is investigating further reduction of therapy for children <18 months of age with localized tumors and favorable biology as well as expanding the observation only strategy to infants <12 months old with small tumors. This study is also investigating a clinical scoring system to guide therapy in non-high-risk patients with the highest mortality rates, namely infants with stage 4S disease with evolving hepatomegaly.

## 6. Treatment – high-risk neuroblastoma

Children with high-risk neuroblastoma account for approximately half of all patients diagnosed with neuroblastoma. Despite a variety of changes in the treatment strategy for patients with high-risk neuroblastoma over the years, this group continues to have poor outcomes and remains one of the most challenging to treat. Long-term survival rates for children with high-risk neuroblastoma are currently around 40–50% in large cooperative group studies [61–64]. Although



the treatment regimens used for children with high-risk neuroblastoma have evolved somewhat over the past decade, the standard regimens continue to have 4 main components: (1) Induction chemotherapy, (2) Local Control, (3) Consolidation, and (4) Maintenance therapy.

### 6.1. Induction

Induction is critical for children with high-risk neuroblastoma, as the response to induction as measured by semi-quantitative MIBG scoring systems is a key prognostic indicator [65]. Although a majority of children with high-risk neuroblastoma do achieve remission after induction chemotherapy, many patients relapse even after additional consolidation therapy. Furthermore, as many as 20% of patients with high-risk neuroblastoma experience disease progression during or have an inadequate response to induction therapy [4]. Tumor response rates are also lower in adolescents and adults, who often have indolent, chemoresistant tumors compared to tumors in younger children that tend to be more responsive to chemotherapy [66,67].

Although the specific induction regimens currently in use differ between different cooperative groups, most currently employed induction regimens for high-risk neuroblastoma utilize a combination of anthracyclines, platinum-containing compounds, alkylating agents and topoisomerase II inhibitors. The most recently completed protocol for high-risk neuroblastoma treatment employed by the COG utilized 6 cycles of induction chemotherapy, including the combination of topotecan and cyclophosphamide for the first 2 induction cycles, cisplatin and etoposide for cycles 3 and 5 and cyclophosphamide, vincristine and doxorubicin for cycles 4 and 6. Data reflecting the efficacy and long-term outcomes in patients treated with this regimen are currently being collected [68].

In contrast to the COG approach, European protocols have utilized OPEC/COJEC regimens, which include vincristine, cisplatin, etoposide, and cyclophosphamide in OPEC, with additional carboplatin for COJEC. In a recent study, a regimen using 'rapid' COJEC aiming to increase treatment dose intensity was evaluated. Rapid COJEC was administered in 8 cycles, separated by 10 day intervals, allowing for completion of induction within 70 days from administration of the first drug. A randomized trial showed no difference in outcomes between patients treated with the rapid COJEC regimen compared to those treated with standard OPEC/OJEC induction therapies [62], and due to the ability to deliver induction over a shorter timeframe, rapid COJEC has been incorporated into the standard treatment regimen for these children with high-risk neuroblastoma.

Patients with high-risk neuroblastoma who do not respond to induction therapy are an even more difficult subgroup of patients to treat, with long-term survival rates less than 20%. Further genomic and proteomic analyses of these patients and their tumors are critical for both understanding the underlying mechanisms of treatment resistance as well as identifying novel targets for therapy. Some investigators have proposed considering these patients for phase I and II clinical trials with

novel agents prior to attempting consolidation in hopes of improving clinical outcomes [69].

### 6.2. Local control

Local control is a critical component of high-risk neuroblastoma therapy to prevent local recurrence of disease. Local control treatment modalities include surgical resection, generally after 4–6 cycles of induction therapy, and external beam radiation to the primary site and other sites of active, residual disease. There are conflicting reports regarding the necessity of gross total resection in achieving the most optimal local control rates. A study from Germany using the NB97 protocol reported that the extent of surgical resection following induction had no impact on survival rates for patients with stage 4 neuroblastoma who were diagnosed at 18 months of age or older [70]. Additionally, a recent study evaluated the utility of surgical resection in a subgroup of patients who were poor responders to induction therapy (tumor volume >50% of initial volume after 6 cycles of induction therapy). Results showed that patients who were poor responders to induction and underwent tumor resection had a statistically significant improvement in 3-year OS over those where no surgery was attempted. However, there was no significant difference in 3-year EFS, and gross total resection versus subtotal resection had no effect on these outcomes [71]. Castel and colleagues reported the results of an analysis of 98 stage IV patients, and determined that the final outcome for patients was determined more by metastatic relapses than by the degree of upfront surgical resection [72]. In addition to the results of these individual studies, the roles of surgeon experience and surgical techniques used in the outcomes of patients have not been adequately addressed, making further analyses of the role of surgical resection in the management of patients with high-risk neuroblastoma difficult.

In addition to surgical resection, another key component of local control is radiotherapy, given the exquisite radio-sensitivity of neuroblastoma tumors. Radiation therapy is typically administered after the completion of consolidation therapy (see below), but until recently there was little published data about its efficacy. A 2014 study where 30 patients received 24–30 Gy to the primary site and 24 Gy to MIBG-avid metastatic lesions showed a 5-year progression-free survival rate of 48%, an OS rate of 59% and a 5-year primary site local control rate of 84%. The 5-year local control rate for metastatic sites was 74%. The 5-year progression-free survival rates for patients with 0, 1, 2, and >3 post-induction MIBG-avid sites were 66%, 57%, 20%, and 0%, respectively, further suggesting that the number of MIBG-avid sites present after induction therapy is predictive of patient outcomes [73]. The most recently completed COG protocol utilized 21.6 Gy external beam radiation to the presurgical tumor volume and an additional 14.4 Gy boost to any gross residual tumor, with hopes that this intervention would reduce both side effects and rates of local recurrence [68].

Late effects in children with cancer are an unfortunate consequence of radiation therapy, likely due to the sensitivity of growing and developing normal tissues and the longer life expectancy for survivors [74]. Many techniques, such as

intensity-modulated radiation therapy (IMRT), have been adopted in an attempt to reduce the exposure of normal tissues to the toxicities of radiation therapy. Proton beam radiation therapy has been shown to reduce the side effects of radiation therapy by minimizing doses of radiation delivered to normal tissues surrounding treated tumors [75]. Although the use of proton beam radiation in children with neuroblastoma has been hampered by both cost and limited access, early studies have suggested that proton beam radiation may provide some benefit to children with advanced neuroblastoma [76,77], and further studies are underway to better evaluate the safety and efficacy of proton beam radiation for children with neuroblastoma (NCT02112617).

### 6.3. Consolidation

Consolidation therapy in most neuroblastoma treatment regimens includes myeloablative chemotherapy and autologous stem cell rescue (ASCR). The benefit of myeloablative therapy with ASCR in high-risk neuroblastoma treatment regimens has been demonstrated in a number of studies, and a meta-analysis from 2015 revealed a statistically significant improvement in EFS when myeloablative therapy combined with ASCR were used for patients [78]. However, the source of stem cells used for stem cell rescue for children with high-risk neuroblastoma has been the subject of some debate. Stem cells to be used for ASCR are typically harvested after 2–3 cycles of induction chemotherapy. Peripheral blood has become the preferred source of these stem cells because of easier collection, higher yield, lower incidence of tumor cell contamination, and faster blood count recovery [79,80]. Continued concerns regarding the potential for circulating neuroblastoma tumor cell contamination led to studies evaluating the efficacy of stem cell purging prior to reinfusion for children with high-risk neuroblastoma. In a recently completed trial for children with high-risk neuroblastoma through COG, 468 patients were randomized to receive purged vs. non-purged stem cells after 6 cycles of induction and myeloablative consolidation therapy. Stem cells to be purged were mixed with immunomagnetic beads with a panel of 5 monoclonal antibodies targeting neuroblastoma tumor cell surface markers. Results of this study showed no statistically significant difference in survival rates between the groups, and the authors concluded that purging does not alter patient outcomes [64].

The optimal myeloablative regimen for patients with high-risk neuroblastoma has also been the subject of numerous studies. The current myeloablative regimen employed in many protocols includes 3 days of melphalan with 4 days of carboplatin and etoposide (CEM). However, recent European data suggests that consolidation with busulfan and melphalan (Bu-Mel) in patients following induction with the rapid COJEC regimen provides superior outcomes with no increased toxicity concerns [81]. This SIOPEN study reported 3-year event-free survival rates of 49% for those who underwent conditioning with Bu-Mel, compared to 33% reported for those with CEM. Early data from a single institution pilot study where patients were treated using the COG induction regimen, followed by consolidation with the Bu-Mel combination, has

shown this combination to be well tolerated. The primary reported side effect was mucositis, but all patients were able to receive ASCR as scheduled and all were reported to have no evidence of disease at time of follow up (median 409 days) [82]. Further trials to further evaluate the efficacy of the Bu-Mel combination are underway.

An additional critical therapeutic question for patients with high-risk neuroblastoma is the utility of repeated cycles of myeloablative therapy with ASCR for patients with high-risk neuroblastoma. The COG pilot study ANBL00P1 was developed to assess the feasibility and toxicity of a repeated cycle of myeloablative therapy with ASCR during treatment for high-risk neuroblastoma. 41 patients were enrolled in this study and received standard COG induction therapy. Those that were allowed to proceed to transplant received myeloablative therapy with thiotepa and cyclophosphamide prior to the first ASCR and then CEM prior to the second. The reported 3-year EFS rate for these patients was 44.8%, with an OS rate of 59.2%, and only 2 patients experienced treatment-related mortality. From these results, it was concluded that the repeated course is feasible and should be assessed further with a larger, randomized trial [83]. The most recently completed COG protocol randomized patients to receive either a single course of myeloablative therapy with ASCR or two courses repeated consecutively. Preliminary data from this trial demonstrate an improvement in outcomes with tandem transplant compared to single transplant, with similar toxicity profiles, and data collection from patients treated on this trial is ongoing [68].

European trials have looked at the utility of repeated courses of myeloablative therapy with stem cell rescues as well, although the myeloablative therapy used included thiotepa prior to the initial ASCR and then Bu-Mel prior to the second. This regimen was employed in patients classified with very high-risk neuroblastoma due to poor response of metastatic sites to induction therapy. Results of the initial 26 patients using this regimen have been reported, with patients having an EFS rate of 37.3% and an OS rate of 69% [84]. Based on these promising results, investigators are likely to incorporate this tandem regimen as part of the next SIOPEN protocol for children with high-risk neuroblastoma.

However, despite these recent results, additional studies have also suggested that the benefit of myeloablative therapy with ASCR is minimal in the setting of current treatment regimens. In a retrospective non-randomized study of historical results at a single institution with extended follow-up, patients with high-risk neuroblastoma treated with or without myeloablative therapy had similar survival rates. Therefore, the authors concluded that courses of myeloablative therapy may not be needed to improve outcome when anti-GD2 immunotherapy is used for consolidation after dose-intensive conventional chemotherapy [85]. These mixed results suggest that the optimal consolidation regimen for patients with high-risk neuroblastoma remains to be determined, likely through carefully controlled, large-scale international clinical trials.

### 6.4. Maintenance

Patients with high-risk neuroblastoma typically enter the maintenance phase of therapy after the completion of

induction chemotherapy, surgical resection, myeloablative therapy with ASCR, and radiation therapy. While many patients achieve complete clinical remission with the above multimodal approach, relapse remains common, suggesting that minimal residual disease is an important factor in neuroblastoma relapse. Over the years, several post-consolidation treatment options have been studied in an attempt to eradicate residual disease and further improve event-free survival rates.

The CCG-3891 study demonstrated the efficacy of isotretinoin (13-*cis*-retinoic acid), a synthetic retinoid that decreases proliferation and induces differentiation in neuroblastoma cells, in patients with minimal residual disease when it was administered after chemotherapy or stem cell rescue. These results established a standard for the use of non-cytotoxic differentiation therapy for maintenance therapy for high-risk neuroblastoma treatment [63,86]. In this study, patients were randomly assigned to receive either six cycles of isotretinoin or no further therapy after consolidation. The 3-year EFS rate was significantly better among the 130 patients who were assigned to receive isotretinoin compared to the rate among the 128 patients assigned to receive no further therapy [86]. Similar trends toward improved survival rates, although not reaching statistical significance, were found in the same patient cohorts with extended follow-up [63].

A number of clinical trials testing antibodies directed against the GD2 ganglioside – a cell-surface marker expressed on the surface of neuroblastoma tumor cells – were performed in the 1980s and 1990s and demonstrated promising results in children with neuroblastoma. A recently completed randomized-controlled phase III trial demonstrated that the addition of the anti-GD2 chimeric monoclonal antibody ch14.18 (dinutuximab) with cytokines granulocyte-macrophage colony-stimulating factor (GM-CSF) and interleukin-2 (IL-2) to standard isotretinoin maintenance therapy significantly improved short-term survival in high-risk patients, with both higher EFS and OS rates compared to standard therapy after two years of follow-up [87], leading to FDA approval of dinutuximab for use in children with high-risk neuroblastoma. Data collection for this study is ongoing to determine whether this difference in survival rates is sustained over longer time periods. However, immunotherapy with ch14.18 is associated with a number of significant side effects, including allergic reactions, fever, hypotension, capillary leak syndrome, and pain related to the cytokine effects, and ch14.18 also requires extended infusion times, triggering searches for alternate forms of immunotherapy that may be better tolerated or require shorter infusion times that can be completed on an outpatient basis.

3F8, another murine monoclonal antibody against the GD2 ganglioside, has also shown efficacy as consolidation therapy for patients in first remission. 3F8 treatment used for maintenance therapy in children with stage IV neuroblastoma resulted in significant improvement in EFS rates compared to historical controls in a cohort of 34 patients [88]. A larger retrospective analysis of 166 patients with high-risk neuroblastoma in first remission who received 3 different treatment regimens (3F8 alone, 3F8 + IV GM-CSF + isotretinoin, or 3F8

+ subcutaneous GM-CSF + isotretinoin) showed an overall improvement in OS in patients treated with the combination regimens [89]. Infusion times for 3F8 are significantly shorter than those for ch14.18, and, although side effects associated with 3F8 infusions are similar to those with ch14.18, a humanized version of the 3F8 antibody is currently under investigation and may represent a better tolerated form of maintenance immunotherapy that can be administered on an outpatient basis.

Another potential approach to reduce the relapse rates for children with neuroblastoma involves re-purposing the anti-protozoal drug difluoromethylornithine (DFMO) for use in maintenance therapy for high-risk neuroblastoma. DFMO is an irreversible inhibitor of ornithine decarboxylase, the rate limiting enzyme in polyamine synthesis and whose gene a known target of *MYCN* [90,91]. An open-label, single-agent, multicenter phase II study through the Neuroblastoma and Medulloblastoma Translational Research Consortium (NMTRC) was developed to evaluate the efficacy of DFMO as maintenance therapy in high-risk neuroblastoma patients that had achieved remission after standard therapy. Subjects received 27 cycles of oral DFMO at doses of 500–1000 mg/m<sup>2</sup>/day daily for 28 day cycles. DFMO was well tolerated, with the most common significant toxicity being grade 3 transaminitis reported in 4% of patients. The EFS and OS rates for these patients were 92% and 98% at 2 years, significantly higher than historical controls. For the group of patients (n = 73) who were previously enrolled on the COG ANBL0032 study incorporating immunotherapy into high-risk neuroblastoma maintenance, the 2-year event-free and OS rates were 95% and 98%, respectively, suggesting increased survival rates for patients who received both anti-GD2 immunotherapy and DFMO [92–93]. These initial promising results will need to be confirmed, however, in larger randomized trials, and the safety and efficacy of extended maintenance therapy for children with high-risk neuroblastoma in first remission is being further explored in an international clinical trial (NCT02395666).

Overall, outcomes for patients with high-risk neuroblastoma have been improving over the past several years with the incorporation of immunotherapy into maintenance therapy regimens, and recent results offer hope that extended maintenance therapy for patients with high-risk neuroblastoma in first remission will result in further improvement in outcomes. Efforts to improve outcomes using molecularly targeted therapies are ongoing as well, with studies to utilize the ALK inhibitor crizotinib in patients with known *ALK* mutations being developed and studies to utilize targeted therapies determined from genomic analysis of initial diagnostic tumor samples already ongoing (NCT02559778). These studies offer the promise of further exciting results contributing to our understanding of neuroblastoma pathogenesis and to our ability to determine the most effective treatment regimens for individual patients.

## 7. Treatment – relapsed and refractory neuroblastoma

Despite recent advances, many patients with high-risk neuroblastoma will have either refractory disease that responds

poorly to therapy or will experience disease recurrence, and to date there are no well-established, curative treatment regimens for the majority of these patients. The reported 5-year OS rate for patients after the first relapse of neuroblastoma is 20% [94], with outcomes dependent on the time of relapse and the initial patient tumor stage [94–96]. A recently published meta-analysis of three phase II clinical trials run through the SIOOPEN group in Europe reported median progression free survival rates of 12.5% and 5.7% for patients with refractory and relapsed disease, respectively, while median OS rates were 27.9 months for patients with refractory disease versus 11.0 months for patients with relapsed disease, confirming the poor outcomes in both cohorts of patients [97].

Recent data reported by Modak and colleagues [98] demonstrate that patients with an isolated relapse can be salvaged successfully, often with surgery and/or focal radiation therapy. When additional chemotherapy is needed for these patients, these authors recommend using agents with known anti-neuroblastoma activity rather than experimental therapy. However, relapsed patients most commonly present with metastatic, chemoresistant disease whose biology is likely significantly different from the initial disease due to mutations and other adaptations induced by prior chemotherapy.

For those patients with relapsed neuroblastoma who are treated with additional chemotherapy, initial regimens are typically based on chemotherapy regimens with mechanisms of action different from those of the agents previously used. Topotecan and irinotecan are topoisomerase inhibitors that are commonly used for treatment of relapsed neuroblastoma, and both have shown single agent activity in preclinical and clinical studies [99–104]. Topotecan is primarily used in combination with cyclophosphamide, and the initial phase II study using cycles of this combination (250 mg/m<sup>2</sup>/day cyclophosphamide and 0.75 mg/m<sup>2</sup>/day topotecan for 5 days each) achieved objective responses in 6 of 13 neuroblastoma patients [105]. Further studies have shown increased response rates in patients treated with the cyclophosphamide/topotecan combination compared to topotecan alone (2 mg/m<sup>2</sup>/day for 5 days), although no difference in OS rates were observed [106]. Higher doses of cyclophosphamide and topotecan combined with vincristine have also shown impressive results, including an overall response rate of 19% for patients with primary refractory neuroblastoma and 52% for those with first relapse [107]. An additional topotecan-containing regimen in widespread use combines topotecan (1.5 mg/m<sup>2</sup>/day for 5 days) with a 48-hour infusion of doxorubicin (45 mg/m<sup>2</sup>) and vincristine (2 mg/m<sup>2</sup>), repeated every 21 days (TVD). The initial phase II study of TVD in patients with relapsed neuroblastoma reported an overall response rate of 64% in 25 patients, with 4 complete responses [108]. The TVD regimen has since been incorporated into the SIOOPEN HR-NBL-1 treatment protocol for high-risk neuroblastoma (NCT01704716) as salvage therapy for patients who do not have sufficient responses in metastatic sites of disease after induction.

Irinotecan is primarily used in combination with the alkylating agent temozolomide, and irinotecan/temozolomide combinations have been reported to have significant response rates in patients with neuroblastoma. Investigators using a

regimen of 50 mg/m<sup>2</sup>/day irinotecan with 150 mg/m<sup>2</sup>/day oral temozolomide over 5 days in a single-institution study reported 2 complete responses among 19 patients with refractory disease, with 7 mixed responses and 10 with stable disease (SD) [109]. A subsequent multi-institutional study used lower doses but still found an overall response rate of 15%, with an additional 53% having stable disease [110].

Additional commonly used chemotherapy regimens for children with relapsed neuroblastoma include combinations of ifosfamide, carboplatin, and etoposide (ICE). A single-institution study demonstrated treatment comprised of ifosfamide (2000 mg/m<sup>2</sup> daily for 5 days), carboplatin (500 mg/m<sup>2</sup> daily for 2 days), and etoposide (100 mg/m<sup>2</sup> daily for 5 days) was well tolerated. Disease regression was achieved in 14 of 17 patients (82%) with a new relapse, 13 of 26 patients (50%) with refractory neuroblastoma, and 12 of 34 patients (35%) who were treated for progressive disease during chemotherapy [111]. The ICE regimen also demonstrated responses in 37% of patients with relapsed or refractory high-risk neuroblastoma, with an additional 17% of patients having stable disease [112], while 15 of 16 patients receiving ICE as front-line treatment for patients older than one year of age with stage 4 neuroblastoma had major responses, with a 37% disease-free survival rate [113], suggesting a role for ifosfamide-based chemotherapy regimens for both frontline and relapsed neuroblastoma treatment.

Additional forms of therapy have focused on cell surface markers specific for neuroblastoma tumor cells. Because neuroblastoma tumors arise from neural crest progenitors, nearly 85% of tumors express the norepinephrine transporter on their cell surface, suggesting that the use of benzylguanidine analogs that bind to this transporter would effectively and selectively target these cells. Approximately 90% of neuroblastoma tumors are MIBG-avid, and infusions of <sup>131</sup>I-MIBG allow for the targeted delivery of radiation therapy directly to any sites of active disease. Initial studies showed overall response rates of 21–47% in patients with neuroblastoma [114–116], and subsequent studies have used ASCR after MIBG treatment, allowing for the administration of higher radiation doses. In a large phase II study, 164 patients with relapsed or refractory neuroblastoma were treated with <sup>131</sup>I-MIBG. Approximately one-third of patients (36%) had evidence of clinical response; with approximately one-third (34%) having stable disease for a median of 6 months [117], leading to efforts to include <sup>131</sup>I-MIBG therapy as a part of upfront consolidation treatment for children with high-risk neuroblastoma. Additional clinical trials are ongoing through the New Agents in Neuroblastoma Therapy (NANT) consortium to identify the best of anticancer agents to combine with MIBG therapy (NCT02035137). However, despite the demonstrated efficacy of MIBG therapy, major challenges continue to include the limited number of institutions capable of administration of radioactive iodine to pediatric patients, and the accompanying need for available stem cells for autologous stem cell rescue.

While these chemotherapy and MIBG-based regimens have demonstrated some success in the treatment of children with

relapsed neuroblastoma, subsequent disease relapses and progression often leave these children with limited further treatment options. Over the past decade, however, extensive investigations into the pathogenesis of neuroblastoma have resulted in a number of novel targets for new therapies, and several agents have been identified that are highly active in preclinical models. Furthermore, clinical trials focused on therapies guided by genomic alterations have shown early promise, with the potential for individualized treatment leading to increased rates of response for patients with relapsed disease.

One of the most exciting recent success stories in neuroblastoma treatment is the recent discovery of a key role for the anaplastic lymphoma kinase (ALK) in the pathogenesis of familial neuroblastoma [19–22]. Activating mutations in *ALK* are found in a large majority of familial cases of neuroblastoma, which account for approximately 2% of all cases of neuroblastoma, and *ALK* gene mutations or gene amplifications have been identified in up to 15% of sporadic high-risk neuroblastoma cases [19,118]. Furthermore, wild-type *ALK* expression is elevated in high-risk compared to low-risk neuroblastoma tumors [119]. A subsequent phase I trial using the *ALK* inhibitor crizotinib in children with relapsed and refractory neuroblastoma has been completed [120], and further studies have identified synergistic combinations of *ALK* and mTOR inhibitors [121], suggesting a potential role for *ALK* inhibitors in the treatment of children with tumors with mutant *ALK*. Novel second-generation *ALK* inhibitors, such as ceritinib (LDK378), that are effective against the *ALK*<sup>F1174L</sup> mutant that is resistant to crizotinib [122,123] are currently being evaluated in clinical trials (NCT01742286).

Other recent studies have identified the Aurora A kinase as a potential therapeutic target in neuroblastoma tumors. The Aurora A kinase has a critical role regulating the mitotic checkpoint complex and is essential for appropriate completion of mitosis [124]. However, when aberrantly overexpressed, Aurora A leads to genomic instability, suppression of p53 function and resistance to apoptosis [125]. In neuroblastoma tumors, expression of Aurora A kinase correlates with advanced stage and high-risk disease [126,127]. Small-molecule inhibitors of this kinase block proliferation and soft agar colony formation of neuroblastoma tumor cells and increase sensitivity to chemotherapy [126]. Subsequent phase I trials in children with relapsed tumors demonstrated some evidence of efficacy of the Aurora A kinase inhibitor MLN8237 (alisertib) both alone and in combination with irinotecan and temozolomide in children with relapsed neuroblastoma [128,129], suggesting a potential role for Aurora A kinase inhibitors in future neuroblastoma therapy.

Numerous additional ongoing clinical trials are exploring the safety and tolerability of novel agents in children with relapsed neuroblastoma. In addition to the ongoing studies of DFMO for extended maintenance therapy (see above), DFMO has been evaluated as a single agent in a phase I clinical trial [130] and is also under investigation in combination with other anticancer agents, including celecoxib (NCT02030964) and the proteasome inhibitor bortezomib (NCT02139397) in clinical trials for children with relapsed

neuroblastoma. SF1126, a pan PI-3 kinase inhibitor, was shown to have potent antitumor activity in neuroblastoma preclinical models [131], suggesting the PI3K/mTOR/Akt pathway as a therapeutic target in neuroblastoma, and SF1126 is also currently being tested in a phase I clinical trial through the NANT consortium for children with neuroblastoma (NCT02337309). Nifurtimox is a nitrofurane compound that has been used since the 1970s as a primary form of therapy for Chagas' disease, a parasitic infection caused by *Trypanosoma cruzi* [132,133]. Preclinical studies have shown that nifurtimox inhibits neuroblastoma cell growth *in vitro* and *in vivo* [134,135], and in early-phase clinical trials tumor responses were seen in patients treated with nifurtimox at a dose of 30 mg/kg/day both as a single agent and in combination with chemotherapy [136], leading to an ongoing national phase II trial (NCT00601003).

More recent clinical trials have focused on the potential of personalized therapy for children with relapsed neuroblastoma, using genomic information to direct molecularly targeted therapies against the tumors in cases most likely to derive clinical benefit. Pilot studies have demonstrated the feasibility of generating therapeutic treatment plans based on genomic profiling in less than 12 days [137], and a follow-up national, multi-institutional phase I trial showed clinical benefit in 64% of patients (defined as disease stabilization for at least one cycle of therapy or partial response), with an overall response rate of 7% and progression free survival time of 59 days [138]. A subsequent separate single-institution study demonstrated that incorporation of tumor DNA sequencing data into clinical management of patients was feasible, revealed potentially actionable findings in nearly half of patients, and directly led to changes in treatment and family genetic counseling for some patients [139]. Although the results of these studies demonstrate the feasibility and safety of performing real-time genomic profiling to guide treatment decision making for pediatric neuroblastoma patients, the lack of control groups has limited the assessments as to whether better clinical outcomes resulted from this targeted therapy approach compared to outcomes that would have occurred with standard care. Ongoing national studies are underway to better determine the efficacy of molecularly guided therapy in these patient populations (NCT02162732, NCT02520713).

Although the efficacy of immunotherapy has been demonstrated in patients with neuroblastoma who have minimal residual disease, the role of immunotherapy in patients with relapsed or refractory disease is the focus of several recent and ongoing studies. A recent trial combining chemotherapy with ch14.18 (dinutuximab) demonstrated promising results. In a small cohort of 6 patients with relapsed or refractory neuroblastoma resistant to multiple prior therapies, 5 of 6 achieved either complete or partial response with the combination therapy. This cohort included 2 patients with bulky soft tissue masses, both with complete resolution, as well as complete response of all subjects with bone marrow disease [140]. These results led to a current COG study combining ch14.18 (dinutuximab) with irinotecan and temozolomide (NCT01767194). In a separate study of the Hu14.18-IL-2 immunocytokine, there were no responses observed in 13 patients with measurable

soft tissue neuroblastoma tumors, whereas in those with only MIBG-avid or bone marrow disease, there were 5 complete responses out of 23 patients [141]. Further analyses have revealed that mismatches for natural killer (NK) cell KIR/KIR-ligand genotypes and polymorphisms in the Fcγ receptor have also been associated with better responses to anti-GD2 immunotherapy [142,143]. With the significant side effects and known limitations of anti-GD2 antibody immunotherapy, many other immunologic approaches have been evaluated recently, including therapy with immunomodulatory CTLA4 checkpoint inhibitors [144], antitumor vaccines [145,146], and cell-based immunotherapy using either NK cells [147] or anti-GD2 targeted autologous T cells [148], which have been shown to have antitumor activity, including activity in cases with measurable disease [149,150]. Next-generation chimeric antigen receptor T cells, in which the constructs will include costimulatory domains to activate the T cell, are currently being developed [151].

In addition to the numerous recently completed and ongoing clinical trials of novel agents in children with relapsed neuroblastoma, a number of additional targets have been identified and are the subject of ongoing studies to identify appropriate targeted therapeutic agents. Because of the association of *MYCN* amplification with high-risk cases of neuroblastoma, it represents an attractive potential therapeutic target [152], and numerous efforts to develop *MYCN* inhibitors have been made in the past. However, as a nuclear transcription factor, *MYCN* is difficult to target therapeutically. A recent screening study of cancer cell lines, however, has identified JQ1, an inhibitor of the bromodomain and extra-terminal (BET) class of proteins, as a potent inhibitor of *MYCN* [153]. JQ1 displaces BRD4 from the *MYCN* promoter, leading to inhibition of *MYCN* transcription, cell cycle arrest and apoptosis, and therefore BRD4 inhibitors represent an exciting new class of therapeutic agents for children with relapsed neuroblastoma.

The role of signaling through the RAS-MAPK pathway in neuroblastoma tumor cells is poorly understood, but activating mutations in the genes of members of this pathway have been identified in subsets of neuroblastoma tumors at diagnosis [154] and at relapse [155]. Furthermore, expression of the gene for the Ras GTPase-activating protein (RasGAP) NF1 is also associated with neuroblastoma patient outcomes, and recent studies have identified a potential role for NF1 as a mediator of retinoid resistance in neuroblastoma cells [156]. Additional studies have demonstrated efficacy of the novel MEK inhibitor binimetinib in preclinical models of neuroblastoma [155,157], suggesting that RAS-MAPK pathway inhibitors may be effective in patients with relapsed neuroblastoma.

Other potential targets in neuroblastoma tumors that have been identified recently include the RET tyrosine kinase, which is expressed primarily on neural crest-derived cells and is required for peripheral nervous system maturation. Studies have demonstrated that RET is required for retinoic acid-induced neuroblastoma differentiation [158], and that RET inhibition is effective in neuroblastoma preclinical models [159]. Other recent studies have identified the polo-like kinase 1 (PLK1) as a potential target for neuroblastoma therapy, based on screens of a library of kinase inhibitors in neuroblastoma preclinical models [160],

while a screening study using an siRNA library identified the checkpoint kinase 1 (CHK1) as a potential target [161]. Transcriptome analysis of neuroblastoma tumor formation in the *MYCN* transgenic mouse model identified the centromere-associated protein E (CENP-E) as an additional potential therapeutic target [162]. Further studies to both identify novel agents targeting these pathways and identify novel critical biological pathways are underway, potentially leading to the development of a number of novel therapeutic approaches to recurrent neuroblastoma in the near future.

## 8. Late effects

As outcomes for neuroblastoma have improved over the last 20 years, so too have the number of long-term survivors. Survivors incur significant late effects directly related to the intensity of their treatment, and as neuroblastoma treatment has become more aggressive, both the incidence and severity of late effects has increased as well. Patients with high-risk disease receive intensive multimodal therapy, with a wide variety of potential late effects. While treatment is less intensive for low- and intermediate-risk patients, potential disease site-specific late effects as well as effects from chemotherapy exposure are still a reality.

Hearing loss is one of the most common late effects for survivors of high-risk neuroblastoma, mainly due to exposure to platinum compounds. High-frequency hearing loss may affect up to 73% of individuals treated [163]. A study of European survivors found that nearly half of patients developed hearing loss, and 9% had severe hearing loss (Brock grade 3 and 4), often requiring the use of hearing aids [164].

Platinum agents are also responsible for the approximately 10–40% of survivors that experience long-term renal toxicities including tubular dysfunction, hypertension, proteinuria/hematuria, and chronic renal failure [165,166]. Survivors of high-risk neuroblastoma treatment also have a relative risk as high as 16.2 for developing cataracts, including a 13.6-fold increase in the risk of blindness if cranial radiation was a component of therapy [167]. Dental disease is a common late effect and may be severe in some cases [168]. Varied neurological conditions, ranging from sensory deficits to overt epilepsy are also potential effects of high-risk treatment. These conditions are directly associated with surgical interventions or radiotherapy but may also be secondary to receiving therapy with vinca-alkaloids.

The subsequent linear growth of neuroblastoma survivors is impacted, both from endocrine and non-endocrine etiologies. Musculoskeletal changes as a result of therapy, primarily scoliosis and osteoporosis, can decrease linear growth [163,167]. Effects on the endocrine system also create growth hormone deficiency, hypothyroidism, insulin resistance, premature ovarian failure and delayed puberty [163]. Most of these endocrinopathies are seen in the high-risk neuroblastoma group and are increased with use of total body irradiation (TBI) [163,167].

Other organ systems such as the pulmonary and cardiac systems may also be affected by treatment with chemotherapy agents and radiation therapy. Cardiac toxicity may be

more related to effects of radiation, since the cumulative doses of anthracyclines used in treating neuroblastoma are not typically high. Late effects may also be related to the primary site of disease. For example, patients with spinal cord compression may have neurologic sequelae including paraplegia or sensory deficits, or alternatively may have significant scoliosis or kyphosis as a result of radiation therapy or laminectomy to treat the cord compression [169]. Learning disabilities are also a potential secondary complication from neuroblastoma treatment, in addition to psychosocial late effects such as low income and lower rates of employment [165].

While rare, second malignant neoplasms are a potentially devastating late effect of neuroblastoma treatment. Between 2% and 7% of neuroblastoma survivors develop a second malignancy as a result of their therapy, with a cumulative 30-year incidence for high-risk patients of approximately 10% [170–172]. High-risk therapy, in particular, contains several known risk factors for secondary malignancies, including alkylating agents, topoisomerase II inhibitors, platinum compounds, and radiotherapy. The types of second malignancies experienced by patients after therapy for high-risk neuroblastoma are broad, with the most common diagnoses including renal cell carcinoma, thyroid carcinoma, acute myeloid leukemia, sarcomas, and lymphoma. Hematologic malignancies tend to develop more rapidly than solid tumors after completion of neuroblastoma treatment [170]. Despite these risks, recurrence of disease still remains more likely than secondary malignancies, particularly in cases of high-risk neuroblastoma.

Further complicating the ability to predict and prevent future side effects is the more widespread use of many types of novel therapies for children with high-risk neuroblastoma, such as MIBG therapy. MIBG therapy in particular has been linked to new-onset thyroid dysfunction, secondary leukemias, and myelodysplastic syndrome in early studies [173,174]. Pharmacogenomics is an evolving field that may assist in the understanding of genetic variations that may allow for prediction of risks for specific chemotherapy toxicities. Continued studies with long-term monitoring will be crucial in helping identify those who are at highest risk, and persistent follow-up with these patients is important in helping address the myriad possible late effects they may experience.

## 9. Expert commentary

Modern treatment for children with neuroblastoma is based on accurate diagnosis and prognostication, with treatment strategies based on known risk factors. Recent international efforts to develop uniformly defined risk groups will greatly facilitate the comparison of risk-based clinical trials conducted worldwide and the future development of international collaborative studies. The treatment of patients with high-risk and relapsed neuroblastoma remains a challenge, however, and identification of novel agents for treatments targeted at biologically relevant pathways and of novel therapies harnessing the innate immune system may provide new opportunities for improved outcomes for these patients.

The future holds promise for making considerable advances in our understanding and treatment of

neuroblastoma. The critical genetic and proteomic aberrations that either directly cause neuroblastoma or influence its response to standard therapy are rapidly being identified, providing the key molecular targets for future drug development and for individualized treatment strategies. A wide range of novel therapies are currently undergoing preclinical and clinical evaluation, and the extensive national and international collaborations currently focused on studying this disease will provide opportunities to test these new approaches in carefully controlled clinical trials that should result in more precise and effective therapeutic regimens. In the meantime, improved international strategies to stratify patients based on established clinical and biological criteria will serve to ensure that patients receive appropriate therapeutic intensity.

## 10. Five-year view

Neuroblastoma is a heterogeneous tumor whose molecular and genetic features dramatically affect clinical behavior. Although a number of genetic aberrations are strongly associated with neuroblastoma patient outcomes, only genetic factors that were routinely evaluated by the large cooperative groups before 2002 were included in the analysis of prognostic criteria for the recently developed INRG classification system. New technologies are now available for genomic, epigenomic, and proteomic analyses, and numerous studies suggest that these analyses will lead to a further improvement in neuroblastoma patient risk stratification. Analyses of chromosomal structure and gene expression profiles have been shown to add critical prognostic information to individual genetic aberrations, and the power of these analyses is clearly shown by the identification of known neuroblastoma risk factors (such as amplification of the *MYCN* gene) in addition to several consistently identified novel genes and pathways whose role in neuroblastoma pathogenesis remains to be elucidated. The results of these studies will need to be validated in larger multinational patient cohorts to establish whether these changes are independent of other genetic risk factors.

Clearly, risk classification will continue to be refined with advances in technology and in our understanding of the fundamental alterations that are associated with tumor behavior and patient outcomes. For patients with non-high-risk cases of neuroblastoma, these factors will help to identify rare patients who still require therapy as treatment intensity continues to be reduced in this population. For those patients with high-risk disease, identification of markers for those patients at highest risk of treatment failure and ultimately of disease recurrence is needed to significantly improve long-term survival rates. The optimal system for risk stratification is likely to require a comprehensive analysis that includes both mRNA and microRNA expression, epigenetic modifications, and genetic and proteomic analyses, which will each require technologies capable of generating rapid and reproducible results. To remain clinically relevant, the INRG classification system will need to undergo continued modification as new information is identified in the clinical setting and confirmed to be prognostic in

prospective studies. With the identification of smaller cohorts of biologically distinct neuroblastoma patients, the need for international consensus will become even more critical. Future studies will likely include more refined risk classifications and more individualized treatments based on specific tumor molecular and genetic aberrations.

### Key issues

- Children with neuroblastoma have widely divergent outcomes, ranging from cure in >90% of patients with low risk disease to <50% for those with high risk disease.
- Treatment strategies designed to target biologically relevant targets and pathways represent the future of neuroblastoma therapy.
- Overall, outcomes for patients with low or intermediate risk neuroblastoma continue to remain excellent despite significant reductions in therapy.
- Despite a variety of changes in the treatment strategy for patients with high-risk neuroblastoma over the years, this group continues to have poor outcomes.
- Over the past decade, extensive investigations have identified a number of novel targets in neuroblastoma tumors for new therapies, and several agents have been identified that are highly active in preclinical models.
- Molecularly guided therapy for children with neuroblastoma represents a safe and potentially effective treatment strategy in children with relapsed neuroblastoma.

### Funding

This paper was not funded.

### Declaration of interest

The authors have no relevant affiliations or financial involvement with any organization or entity with a financial interest in or financial conflict with the subject matter or materials discussed in the manuscript. This includes employment, consultancies, honoraria, stock ownership or options, expert testimony, grants or patents received or pending, or royalties.

### References

Papers of special note have been highlighted as either of interest (\*) or of considerable interest (\*\*\*) to readers.

1. Ries L, Smith M, Gurney J, et al. Cancer incidence and survival among children and adolescents: united States SEER Program 1975–1995, National Cancer Institute, SEER Program. Bethesda (MD): NIH Pub; 1999. p. 99–4649.
2. Stiller CA, Parkin DM. International variations in the incidence of neuroblastoma. *Int J Cancer*. 1992;52:538–543.
3. Heck JE, Ritz B, Hung RJ, et al. The epidemiology of neuroblastoma: a review. *Paediatr Perinat Epidemiol*. 2009;23:125–143.
4. Irwin MS, Park JR. Neuroblastoma: paradigm for precision medicine. *Paediatr Clin NA*. 2015;62:225–256.
5. Henderson TO, Bhatia S, Pinto N, et al. Racial and ethnic disparities in risk and survival in children with neuroblastoma: a Children's Oncology Group study. *J Clin Oncol*. 2011;29:76–82.
6. Yamamoto K, Ohta S, Ito E, et al. Marginal decrease in mortality and marked increase in incidence as a result of neuroblastoma screening at 6 months of age: cohort study in seven prefectures in Japan. *J Clin Oncol*. 2002;20:1209–1214.
7. Hiyama E, Iehara T, Sugimoto T, et al. Effectiveness of screening for neuroblastoma at 6 months of age: a retrospective population-based cohort study. *Lancet*. 2008;371:1173–1180.
8. Schilling FH, Spix C, Berthold F, et al. Neuroblastoma screening at one year of age. *N Engl J Med*. 2002;346:1047–1053.
9. Woods WG, Gao RN, Shuster JJ, et al. Screening of infants and mortality due to neuroblastoma. *N Engl J Med*. 2002;346:1041–1046.
10. Maris JM, Woods WG. Screening for neuroblastoma: a resurrected idea? *Lancet*. 2008;371:1142–1143.
11. Cook MN, Olshan AF, Guess HA, et al. Maternal medication use and neuroblastoma in offspring. *Am J Epidemiol*. 2004;159:721–731.
12. Menegaux F, Olshan AF, Nelgia JP, et al. Day care, childhood infections, and risk of neuroblastoma. *Am J Epidemiol*. 2004;159:843–851.
13. McDermott S, Salzberg DC, Anderson AP, et al. Systematic review of chromium and nickel exposure during pregnancy and impact on child outcomes. *J Toxicol Environ Health A*. 2015;78:1348–1368.
14. Shojaei-Brosseau T, Chompret A, Abel A, et al. Genetic epidemiology of neuroblastoma: a study of 426 cases at the Institut Gustave-Roussy in France. *Pediatr Blood Cancer*. 2004;42:99–105.
15. Trochet D, Bourdeaut F, Janoueix-Lerosey I, et al. Germline mutations of the paired-like homeobox 2B (*PHOX2B*) gene in neuroblastoma. *Am J Hum Genet*. 2004;74:761–764.
16. Rohrer T, Trachsel D, Engelcke G, et al. Congenital central hypoventilation syndrome associated with Hirschsprung's disease and neuroblastoma: case of multiple neurocristopathies. *Pediatr Pulmonol*. 2002;33:71–76.
17. Mosse YP, Laudenslager M, Khazi D, et al. Germline *PHOX2B* mutation in hereditary neuroblastoma. *Am J Hum Genet*. 2004;75:727–730.
18. Clausen N, Andersson P, Tommerup P. Familial occurrence of neuroblastoma, von Recklinghausen's neurofibromatosis, Hirschsprung's agangliosis and jaw-winking syndrome. *Acta Paediatr Scand*. 1989;78:736–741.
19. Mosse YP, Laudenslager M, Longo L, et al. Identification of ALK as a major familial neuroblastoma predisposition gene. *Nature*. 2008;455:930–935.
- **This series of manuscripts (#s 19–22) represent the initial reports detailing the role of ALK mutations in neuroblastoma and identifying ALK as the first molecular therapeutic target in neuroblastoma detected by large-scale DNA sequencing efforts.**
20. Janoueix-Lerosey I, Lequin D, Brugieres L, et al. Somatic and germline activating mutations of the ALK kinase receptor in neuroblastoma. *Nature*. 2008;455:967–970.
21. George RE, Sanda T, Hanna M, et al. Activating mutations in ALK provide a therapeutic target in neuroblastoma. *Nature*. 2008;455:975–978.
22. Chen Y, Takita J, Choi YL, et al. Oncogenic mutations of ALK kinase in neuroblastoma. *Nature*. 2008;455:971–974.
23. Schulte JH, Bachmann HS, Brockmeyer B, et al. High ALK receptor tyrosine kinase expression supersedes ALK mutation as a determining factor of an unfavorable phenotype in primary neuroblastoma. *Clin Cancer Res*. 2011;17:5082–5092.
24. Schleiernmacher G, Javanmardi N, Bernard V, et al. Emergence of new ALK mutations at relapse of neuroblastoma. *J Clin Oncol*. 2014;32:2727–2734.
25. Bellini A, Bernard V, Leroy Q, et al. Deep sequencing reveals occurrence of subclonal ALK mutations in neuroblastoma at diagnosis. *Clin Cancer Res*. 2015;21:4913–4921.
26. Diskin SJ, Capasso M, Schnepp RW, et al. Common variation at 6q16 within HACE1 and LIN28B influences susceptibility to neuroblastoma. *Nat Genet*. 2012;44:1126–1130.
27. Capasso M, Devoto M, Hou C, et al. Common variations in BARD1 influence susceptibility to high-risk neuroblastoma. *Nat Genet*. 2009;41:718–723.
28. Wang K, Diskin SJ, Zhang H, et al. Integrative genomics identifies LMO1 as a neuroblastoma oncogene. *Nature*. 2011;469:216–220.
29. Whittle SB, Reyes S, Du M, et al. A polymorphism in the *FGFR4* gene is associated with risk of neuroblastoma and altered receptor degradation. *J Pediatr Hematol Oncol*. 2016;38:131–138.



30. Maris JM, Mosse YP, Bradfield JP, et al. Chromosome 6p22 locus associated with clinically aggressive neuroblastoma. *N Engl J Med*. 2008;358:2585–2593.
31. Diskin SJ, Hou C, Glessner JT, et al. Copy number variation at 1q21.1 associated with neuroblastoma. *Nature*. 2009;459:987–991.
32. De Bernardi B, Balwierz W, Bejant J, et al. Epidural compression in neuroblastoma: diagnostic and therapeutic aspects. *Cancer Lett*. 2005;228:283–299.
33. Scheibel E, Rechnitzer C, Fahrenkrug J, et al. Vasoactive intestinal polypeptide (VIP) in children with neural crest tumours. *Acta Paediatr Scand*. 1982;71:721–725.
34. Matthay KK, Blaes F, Hero B, et al. Opsoclonus myoclonus syndrome in neuroblastoma: a report from a workshop on the dancing eyes syndrome at the advances in neuroblastoma meeting in Genoa, Italy, 2004. *Cancer Lett*. 2005;228:275–282.
35. Gorman MP. Update on diagnosis, treatment, and prognosis in opsoclonus-myoclonus-ataxia syndrome. *Curr Opin Pediatr*. 2010;22:745–750.
36. De Grandis E, Parodi S, Conte M, et al. Long-term follow-up of neuroblastoma-associated opsoclonus-myoclonus-ataxia syndrome. *Neuropediatrics*. 2009;40:103–111.
37. Catsman-Berrevoets CE, Aarsen FK, Van Hemsbergen ML, et al. Improvement of neurological status and quality of life in children with opsoclonus myoclonus syndrome at long-term follow-up. *Pediatr Blood Cancer*. 2009;53:1048–1053.
38. Sharp SE, Shulkin BL, Gelfand MJ, et al. 123I-MIBG scintigraphy and 18F-FDG PET in neuroblastoma. *J Nucl Med*. 2009;50:1237–1243.
39. Taggart DR, Han MM, Quach A, et al. Comparison of iodine-123 metaiodobenzylguanidine (MIBG) scan and [18F]fluorodeoxyglucose positron emission tomography to evaluate response after iodine-131 MIBG therapy for relapsed neuroblastoma. *J Clin Oncol*. 2009;27:5343–5349.
40. Bleeker G, Tytgat GAM, Adam JA, et al. 123I-MIBG scintigraphy and 18F-FDG-PET imaging for diagnosing neuroblastoma. *Cochrane Database Syst Rev*. 2015;9:CD009263. DOI:10.1002/14651858.CD009263.pub2
41. Cheung NK, Heller G, Kushner BH, et al. Detection of neuroblastoma in bone marrow by immunocytology: is a single marrow aspirate adequate? *Med Pediatr Oncol*. 1999;32:84–87.
42. Zage PE, Louis CU, Cohn SL. New aspects of neuroblastoma treatment: ASPHO 2011 symposium review. *Pediatr Blood Cancer*. 2012;58:1099–1105.
43. Shimada H, Ambros IM, Dehner LP, et al. Terminology and morphologic criteria of neuroblastic tumors: recommendations by the international neuroblastoma pathology committee. *Cancer*. 1999;86:349–363.
44. Peuchmaur M, d'Amore ES, Joshi VV, et al. Revision of the international neuroblastoma pathology classification: confirmation of favorable and unfavorable prognostic subsets in ganglioneuroblastoma, nodular. *Cancer*. 2003;98:2274–2281.
45. Navarro S, Amann G, Beiske K, et al. Prognostic value of international neuroblastoma pathology classification in localized resectable peripheral neuroblastic tumors: a histopathologic study of localized neuroblastoma European Study Group 94.01 Trial and Protocol. *J Clin Oncol*. 2006;24:695–699.
46. Brodeur GM, Seeger RC, Barrett A, et al. International criteria for diagnosis, staging, and response to treatment in patients with neuroblastoma. *J Clin Oncol*. 1988;6:1874–1881.
47. Brodeur GM, Pritchard J, Berthold F, et al. Revisions of the international criteria for neuroblastoma diagnosis, staging, and response to treatment. *J Clin Oncol*. 1993;11:1466–1477.
48. Cohn SL, Pearson AD, London WB, et al. The International Neuroblastoma Risk Group (INRG) classification system: an INRG task force report. *J Clin Oncol*. 2009;27:289–297.
- **These two manuscripts (#'s 48, 49) represent the initial reports describing the new INRG risk classification and staging systems for neuroblastoma patients worldwide.**
49. Monclair T, Brodeur GM, Ambros PF, et al. The International Neuroblastoma Risk Group (INRG) staging system: an INRG task force report. *J Clin Oncol*. 2009;27:298–303.
50. Monclair T, Mosseri V, Cecchetto G, et al. Influence of image-defined risk factors on the outcome of patients with localised neuroblastoma. a report from the LNESG1 study of the European International Society of Paediatric Oncology Neuroblastoma group. *Pediatr Blood Cancer*. 2015;62:1536–1542.
51. Baker DL, Schmidt ML, Cohn SL, et al. Outcome after reduced chemotherapy for intermediate-risk neuroblastoma. *New Engl J Med*. 2010;363:1313–1323.
52. Strother DR, London WB, Schmidt ML, et al. Outcome after surgery alone or with restricted use of chemotherapy for patients with low risk neuroblastoma. *J Clin Oncol*. 2012;30:1842–1848.
53. Alvarado CS, London WB, Look AT, et al. Natural history and biology of stage A neuroblastoma: a Pediatric Oncology Group study. *J Pediatr Hematol Oncol*. 2000;22:197–205.
54. Perez CA, Matthay KK, Atkinson JB, et al. Biologic variables in the outcome of stages I and II neuroblastoma treated with surgery as primary therapy: a Childrens Cancer Group study. *J Clin Oncol*. 2000;18:18–26.
55. De Bernardi B, Mosseri V, Rubie H, et al. Treatment of localized resectable neuroblastoma. Results of the LNESG1 study by the SIOP Europe Neuroblastoma Group. *Br J Cancer*. 2008;99:1027–1033.
56. Nuchtern JG, London WB, Barnewolt CE, et al. A prospective study of expectant observation as primary therapy for neuroblastoma in young infants: a Children's Oncology Group study. *Ann Surg*. 2012;256:573–580.
57. Lavarino C, Cheung N-K, Garcia I, et al. Specific gene expression profiles and chromosomal abnormalities are associated with infant disseminated neuroblastoma. *BMC Cancer*. 2009;9:44.
58. Twist C, London WB, Naranjo A, et al. Maintaining Outstanding outcomes using response and biology based therapy for intermediate risk neuroblastoma: A report from the Children's Oncology Group study ANBL0531. Presented at the Advances in Neuroblastoma Research Conference, Cologne, Germany, 2014 June.
59. Kohler JA, Rubie H, Castel V, et al. Treatment of children over the age of one year with unresectable localised neuroblastoma without MYCN amplification; results of the SIOPEN study. *Eur J Cancer*. 2013;49:3671–3679.
60. Schleiernacher G, Michon J, Ribero A, et al. Segmental chromosomal alterations lead to a higher risk of relapse in infant with MYCN-nonamplified localised unresectable/disseminated neuroblastoma (a SIOPEN collaborative study). *Br J Cancer*. 2011;105:1940–1948.
61. Berthold F, Boos J, Burdach S, et al. Myeloablative megatherapy with autologous stem cell rescue versus oral maintenance chemotherapy as consolidation treatment in patients with high-risk neuroblastoma: a randomised controlled trial. *Lancet Oncol*. 2005;6:649–658.
62. Pearson AD, Pinkerton CR, Lewis IJ, et al. High-dose rapid and standard induction chemotherapy for patients aged over 1 year with stage 4 neuroblastoma: a randomised trial. *Lancet Oncol*. 2008;9:247–256.
63. Matthay KK, Reynolds CP, Seeger RC, et al. Long-term results for children with high-risk neuroblastoma treated on a randomized trial of myeloablative therapy followed by 13-cis-retinoic acid: A Children's Oncology Group study. *J Clin Oncol*. 2009;27:1007–1013.
- **The first international cooperative group trial to demonstrate the benefits of myeloablative therapy with stem cell rescue and 13-cis-retinoic acid therapy for children with high-risk neuroblastoma.**
64. Kreissman SG, Seeger RC, Matthay KK, et al. Purged vs. non-purged peripheral blood stem cell transplantation for high risk neuroblastoma (COG A3973): a randomized phase III trial. *Lancet Oncol*. 2013;14:999–1008.
65. Yanik GA, Parisi MT, Shulkin BL, et al. Semiquantitative MIBG scoring as a prognostic indicator in patients with stage 4 neuroblastoma: a report from the Children's Oncology Group. *J Nucl Med*. 2013;54:541–548.

66. Sorrentino S, Gigliotti AR, Sementa AR, et al. Neuroblastoma in the adult: the Italian experience with 21 patients. *J Pediatr Hematol Oncol.* 2014;36:e499–505.
67. Mosse YP, Deyell RJ, Berthold F, et al. Neuroblastoma in older children, adolescents and young adults: a report from the International Neuroblastoma Risk Group project. *Pediatr Blood Cancer.* 2014;61:627–635.
68. Park JR, Kreissman SG, London WB, et al. A Phase 3 Randomized Clinical Trial (RCT) of Tandem Myeloablative Autologous Stem Cell Transplant (ASCT) Using Peripheral Blood Stem Cell (PBSC) as Consolidation Therapy for High-Risk Neuroblastoma (HR-NB): A Children's Oncology Group Study. Presented at the Advances in Neuroblastoma Research Conference, Cairns, Australia, 2016 June.
69. Schrey D, Vaidya SJ, Levine D, et al. Additional Therapies to improve metastatic response to induction therapy in Children with High Risk Neuroblastoma. *J Pediatr Hematol Oncol.* 2015;37:e 150–153.
70. Simon T, Haberle B, Hero B, et al. Role of Surgery in the treatment of patients with stage 4 Neuroblastoma age 18 months or older at diagnosis. *J Clin Oncol.* 2013;31:752–758.
71. Du L, Liu L, Zhang C, et al. Role of Surgery in the treatment of patients with high risk neuroblastoma who have poor response to induction chemotherapy. *J Pediatr Surg.* 2014;49:528–533.
72. Castel V, Tovar JA, Costa E, et al. The Role of Surgery in Stage IV Neuroblastoma. *J Pediatr Surg.* 2002;37:1574–1578.
73. Mazloom A, Louis CU, Nuchtern J, et al. Radiation Therapy to the primary and post induction chemotherapy MIBG avid sites in high risk neuroblastoma. *Int J Radiat Oncol Biol Phys.* 2014;90:858–862.
74. Rombi B, MacDonald SM, Maurizio A, et al. Proton radiotherapy for childhood tumors: an overview of early clinical results. *J Nucl Med Radiat Ther.* 2013;4:4.
75. Doyen J, Falk AT, Floquet V, et al. Proton beams in cancer treatments: clinical outcomes and dosimetric comparisons with photon therapy. *Cancer Treat Rev.* 2016;43:104–112.
76. Hattangadi JA, Rombi B, Yock TI, et al. Proton Radiotherapy for High-Risk Pediatric Neuroblastoma: early Outcomes and Dose Comparison. *Int J Radiat Oncol Biol Phys.* 2012;83:1015–1022.
77. Oshiro Y, Mizumoto M, Okumura T, et al. Clinical Results of Proton Beam Therapy for Advanced Neuroblastoma. *Radiat Oncol.* 2013;8:142.
78. Yalcin B, Kremer LCM, van Dalen EC. High dose chemotherapy and autologous hematopoietic stem cell rescue for children with high risk neuroblastoma (Review). *Cochrane Database Syst Rev.* 2015;10:CD006301. doi: 10.1002/14651858.CD006301.pub4.
79. Grupp SA, Cohn SL, Wall D, et al. Collection, storage, and infusion of stem cells in children with high-risk neuroblastoma: saving for a rainy day. *Pediatr Blood Cancer.* 2006;46:719–722.
80. Fish JD, Grupp SA. Stem cell transplantation for neuroblastoma. *Bone Marrow Transplant.* 2008;41:159–165.
81. Ladenstein R, Poetschger U, Luksch R, et al. Busulfan-Melphalan as a myeloablative therapy (MAT) for high risk neuroblastoma: results from HR-NBL1/SIOPEN trial. *J Clin Oncol.* 2011;29:2.
- **The first cooperative group report of increased efficacy of Busulfan-Melphalan as a myeloablative regimen for children with high-risk neuroblastoma.**
82. Soni S, Pai V, Gross TG, et al. Busulfan and Melphalan as consolidation therapy with autologous peripheral blood stem cell transplantation following COG induction platform for high risk neuroblastoma; early results from a single institution. *Pediatr Trans.* 2014;18:217–220.
83. Seif AE, Naranjo A, Baker DL, et al. A pilot study of tandem high dose chemotherapy with stem cell rescue as consolidation for high risk neuroblastoma: Children's Oncology Group study ANBL00P1. *Bone Marrow Transplant.* 2013;48:947–952.
84. Pasqualani C, Dufour C, Goma G, et al. Tandem high dose chemotherapy with thiotepa and busulfan-melphalan and autologous stem cell transplantation in very high risk neuroblastoma patients. *Bone Marrow Transplant.* 2016;51:227–231.
85. Kushner BH, Ostrovskaya I, Cheung IY, et al. Lack of survival advantage with autologous stem-cell transplantation in high-risk neuroblastoma consolidated by anti-GD2 immunotherapy and isotretinoin. *Oncotarget.* 2016;7:4155–4166.
- **Large retrospective review demonstrating the lack of benefit of myeloablative therapy with autologous stem cell rescue in children with high-risk neuroblastoma who have received anti-GD2 immunotherapy.**
86. Matthay KK, Villablanca JG, Seeger RC, et al. Treatment of high-risk neuroblastoma with intensive chemotherapy, radiotherapy, autologous bone marrow transplantation, and 13-cis-retinoic acid. *N Engl J Med.* 1999;341:1165–1173.
87. Yu AL, Gilman AL, Ozkaynak F, et al. Anti-GD2 antibody with GM-CSF, interleukin-2, and isotretinoin for neuroblastoma. *N Engl J Med.* 2010;363:1324–1334.
- **A series of manuscripts (#'s 87-89) reporting the efficacy of anti-GD2 immunotherapy in children with high-risk neuroblastoma.**
88. Cheung NK, Kushner BH, Cheung IY, et al. Anti-GD<sub>2</sub> antibody treatment of minimal residual stage 4 neuroblastoma diagnosed at more than 1 year of age. *J Clin Oncol.* 1998;16:3053–3060.
89. Cheung NK, Cheung IY, Kushner BH, et al. Murine anti-GD2 monoclonal antibody 3F8 combined with granulocyte-macrophage colony-stimulating factor and 13-cis-retinoic acid in high-risk patients with stage 4 neuroblastoma in first remission. *J Clin Oncol.* 2012;30:3264–3270.
90. Hogarty MD, Norris MD, Davis K, et al. ODC1 is a critical determinant of MYCN oncogenesis and a therapeutic target in neuroblastoma. *Cancer Res.* 2008;68:9735–9745.
91. Geerts D, Koster J, Albert D, et al. The polyamine metabolism genes ornithine decarboxylase and antizyme 2 predict aggressive behavior in neuroblastomas with and without MYCN amplification. *Int J Cancer.* 2010;126:2012–2024.
92. Sholler G, Ferguson W, Bergendahl G, et al. A phase II prevention trial of DFMO in patients with high risk neuroblastoma in remission prevents relapse and increases event free and overall survival. Presented at the American Society of Pediatric Hematology/Oncology annual meeting. Minneapolis. 2016 May.
93. Sholler G, Ferguson W, Bergandahl G, et al. DFMO maintains remission and increases overall survival in high-risk neuroblastoma: results of a phase ii prevention trial. Presented at the Advances in Neuroblastoma Research Conference, Cairns, Australia, 2016 June.
94. London WB, Castel V, Monclair T, et al. Clinical and biologic features predictive of survival after relapse of neuroblastoma: a report from the International Neuroblastoma Risk Group project. *J Clin Oncol.* 2011;29:3286–3292.
- **The first international report identifying clinical and biologic features associated with outcomes of children with relapsed neuroblastoma.**
95. Lau L, Tai DWeitzman S, et al. Factors influencing survival in children with recurrent neuroblastoma. *J Pediatr Hematol Oncol.* 2004;26:227–232.
96. Garaventa A, Parodi S, De Bernardi B, et al. Outcome of children with neuroblastoma after progression or relapse. A retrospective study of the Italian neuroblastoma registry. *Eur J Cancer.* 2009;45:2835–2842.
97. Moreno L, Rubie H, Varo A, et al. Outcome of children with relapsed or refractory neuroblastoma: A meta-analysis of ITCC/SIOPEN European phase II clinical trials. *Pediatr Blood Cancer.* 2017;64:25–31.
98. Modak S Generation and administration of autologous T cells transduced with a 3rd generation GD2 chimeric antigen receptor for patients with relapsed or refractory neuroblastoma. Presented at the Advances in Neuroblastoma Research Conference, Cologne, Germany, 2014 June.
99. Houghton PJ, Cheshire PJ, Hallman JD, et al. Efficacy of topoisomerase I inhibitors, topotecan and irinotecan, administered at low dose levels in protracted schedules to mice bearing xenografts of human tumors. *Cancer Chemother Pharmacol.* 1995;36:393–403.
100. Carol H, Houghton PJ, Morton CL, et al. Initial testing of topotecan by the pediatric preclinical testing program. *Pediatr Blood Cancer.* 2010;54(7): 07–715.

101. Blaney S, Berg SL, Pratt C, et al. A phase I study of irinotecan in pediatric patients: a Pediatric Oncology Group study. *Clin Cancer Res.* 2001;7:32–37.
102. Blaney SM, Needle MN, Gillespie A, et al. Phase II trial of topotecan administered as 72-hour continuous infusion in children with refractory solid tumors: a Collaborative Pediatric Branch, National Cancer Institute, and Children's Cancer Group study. *Clin Cancer Res.* 1998;4:357–360.
103. Hawkins DS, Bradfield S, Whitlock JA, et al. Topotecan by 21-day continuous infusion in children with relapsed or refractory solid tumors: a Children's Oncology Group study. *Pediatr Blood Cancer.* 2006;47:790–794.
104. Bomgaars LR, Bernstein M, Krailo M, et al. Phase II trial of irinotecan in children with refractory solid tumors: a Children's Oncology Group study. *J Clin Oncol.* 2007;25:4622–4627.
105. Saylor RL, Stine KC, Sullivan J, et al. Cyclophosphamide plus topotecan in children with recurrent or refractory solid tumors: a Pediatric Oncology Group phase II study. *J Clin Oncol.* 2001;19:3463–3469.
106. London WB, Frantz CN, Campbell LA, et al. Phase II randomized comparison of topotecan plus cyclophosphamide versus topotecan alone in children with recurrent or refractory neuroblastoma: a Children's Oncology Group study. *J Clin Oncol.* 2010;28:3808–3815.
107. Kushner BH, Kramer K, Modak S, et al. Differential impact of high-dose cyclophosphamide, topotecan, and vincristine in clinical subsets of patients with chemoresistant neuroblastoma. *Cancer.* 2010;116:3054–3060.
108. Garaventa A, Luksch R, Biasotti S, et al. A phase II study of topotecan with vincristine and doxorubicin in children with recurrent/refractory neuroblastoma. *Cancer.* 2003;98:2488–2494.
109. Kushner BH, Kramer K, Modak S, et al. Irinotecan plus temozolomide for relapsed or refractory neuroblastoma. *J Clin Oncol.* 2006;24:5271–5276.
110. Bagatell R, London WB, Wagner LM, et al. Phase II study of irinotecan and temozolomide in children with relapsed or refractory neuroblastoma: a Children's Oncology Group study. *J Clin Oncol.* 2011;29:208–213.
111. Kushner BH, Modak S, Kramer K, et al. Ifosfamide, carboplatin, and etoposide for neuroblastoma: a high-dose salvage regimen and review of the literature. *Cancer.* 2013;119:665–667.
112. Abdel Rahman H, Moussa EAH, Zekri WZK, et al. Did Salvage ICE chemotherapy improve the outcome in primary resistant/relapsing stage III/IV neuroblastoma? *J Egypt Nat Cancer Inst.* 2011;23:47–53.
113. Donfrancesco A, Jenkner A, Castellano A, et al. Ifosfamide/carboplatin/etoposide (ICE) as front-line, topotecan/cyclophosphamide as second-line and oral temozolomide as third-line treatment for advanced neuroblastoma over one year of age. *Acta Paediatr Suppl.* 2004;445:6–11.
114. Hutchinson RJ, Sisson JC, Shapiro B, et al. 131-I-metaiodobenzylguanidine treatment in patients with refractory advanced neuroblastoma. *Am J Clin Oncol.* 1992;15:226–232.
115. Klingebiel T, Berthold F, Treuner J, et al. Metaiodobenzylguanidine (MIBG) in treatment of 47 patients with neuroblastoma: results of the German neuroblastoma trial. *Med Paediatr Oncol.* 1991;19:84–88.
116. Lashford LS, Lewis IJ, Fielding SL, et al. Phase I/II study of iodine 131 metaiodobenzylguanidine in chemoresistant neuroblastoma: a United Kingdom Children's Cancer Study Group investigation. *J Clin Oncol.* 1992;10:1889–1896.
117. Matthay KK, Yanik G, Messina J, et al. Phase II study on the effect of disease sites, age, and prior therapy on response to iodine-131-metaiodobenzylguanidine therapy in refractory neuroblastoma. *J Clin Oncol.* 2007;25:1054–1060.
118. Caren H, Abel F, Kogner P, et al. High incidence of DNA mutations and gene amplifications of the ALK gene in advanced sporadic neuroblastoma tumors. *Biochem J.* 2008;416:153–159.
119. Passoni L, Longo L, Collini P, et al. Mutation-independent anaplastic lymphoma kinase overexpression in poor prognosis neuroblastoma patients. *Cancer Res.* 2009;69:7338–7346.
120. Mosse YP, Lim MS, Voss SD, et al. Safety and activity of crizotinib for paediatric patients with refractory solid tumours or anaplastic large-cell lymphoma: a Children's Oncology Group phase 1 consortium study. *Lancet Oncol.* 2013;14:472–480.
- **The first report of the safety, tolerability, and efficacy of the ALK inhibitor crizotinib in children with relapsed neuroblastoma.**
121. Moore NF, Azarova AM, Bhatnagar N, et al. Molecular rationale for the use of PI3K/AKT/mTOR pathway inhibitors in combination with crizotinib in ALK-mutated neuroblastoma. *Oncotarget.* 2014;5:8737–8749.
122. Sasaki T, Okuda K, Zheng W, et al. The neuroblastoma-associated F1174L ALK mutation causes resistance to an ALK kinase inhibitor in ALK-translocated cancers. *Cancer Res.* 2010;70:10038–10043.
123. Berry T, Luther W, Bhatnagar N, et al. The ALK(F1174L) mutation potentiates the oncogenic activity of MYCN in neuroblastoma. *Cancer Cell.* 2012;22:117–130.
124. Zhou H, Kuang J, Zhong L, et al. Tumour amplified kinase STK15/BTAK induces centrosome amplification, aneuploidy, and translocation. *Nat Genet.* 1998;20:189–193.
125. Sen S, Katayama H, Sasai K. Functional significance of aurora kinase A in centrosome amplification and genomic instability. *Adv Exp Med Biol.* 2008;617:99–108.
126. Shang X, Burlingame SM, Okcu MF, et al. Aurora A is a negative prognostic factor and a new therapeutic target in human neuroblastoma. *Mol Cancer Ther.* 2009;8:2461–2469.
127. Otto T, Horn S, Brockmann M, et al. Stabilization of N-Myc is a critical function of Aurora A in human neuroblastoma. *Cancer Cell.* 2009;15:67–78.
128. Mosse YP, Lipsitz E, Fox E, et al. Pediatric phase I trial and pharmacokinetic study of MLN8237, an investigational oral selective small-molecule inhibitor of Aurora kinase A: a Children's Oncology Group phase I consortium study. *Clin Cancer Res.* 2012;18:6058–6064.
129. Dubois SG, Marachelian A, Fox E, et al. Phase I study of the aurora A kinase inhibitor alisertib in combination with irinotecan and temozolomide for patients with relapsed or refractory neuroblastoma: A NANT (New Approaches to Neuroblastoma Therapy) Trial. *J Clin Oncol.* 2016;34:1368–1375.
130. Saulnier Sholler GL, Gerner EW, Bergendahl G, et al. A phase I trial of DFMO targeting polyamine addiction in patients with relapsed/refractory neuroblastoma. *Plos ONE.* 2015;10:e0127246.
131. Peirce SK, Findley HW, Prince C, et al. The PI-3 kinase-Akt-MDM2-survivin signaling axis in high-risk neuroblastoma: a target for PI-3 kinase inhibitor intervention. *Cancer Chemother Pharmacol.* 2011;68:325–335.
132. Bern C. Antitrypanosomal therapy for chronic Chagas' disease. *New Engl J Med.* 2011;364:2527–2534.
133. Rassi A, Rassi A, Marin-Neto JA. Chagas disease. *Lancet.* 2010;375:1388–1402.
134. Saulnier Sholler G, Brard L, Straub JA, et al. Nifurtimox induces apoptosis of neuroblastoma cells in vitro and in vivo. *J Pediatr Hematol Oncol.* 2009;31:187–193.
135. Du M, Zhang L, Scorsone KA, et al. Nifurtimox is effective against neural tumor cells and is synergistic with buthionine sulfoximine. *Sci Rep.* 2016;6:27458.
136. Saulnier Sholler GL, Bergendahl GM, Brard L, et al. A phase 1 study of nifurtimox in patients with relapsed/refractory neuroblastoma. *J Pediatr Hematol Oncol.* 2011;33:25–30.
137. Saulnier Sholler GL, Ferguson W, Bergendahl G, et al. A pilot trial testing the feasibility of using molecular-guided therapy in patients with recurrent neuroblastoma. *J Cancer Ther.* 2012;3:602–612.
138. Saulnier Sholler GL, Bond JP, Bergendahl G, et al. Feasibility of implementing molecular-guided therapy for the treatment of patients with relapsed or refractory neuroblastoma. *Cancer Med.* 2015;4:871–886.
- **The first manuscripts (#'s 138,139) to report the feasibility and potential role of personalized therapy based on DNA sequencing and expression profiling in children with cancer.**
139. Mody RJ, Wu Y-M, Lonigro RJ, et al. Integrative clinical sequencing in the management of refractory or relapsed cancer in youth. *JAMA.* 2015;314:913–925.

140. Cha A, Asgharzedeh S, Czarniecki S, et al. Dinutuximab combined with chemotherapy in patients with multiply relapsed/refractory high risk neuroblastoma (HR-NBL). Presented at the Advances in Neuroblastoma Research Conference, Cairns, Australia, 2016 June.
141. Shusterman S, London WB, Gillies SD, et al. Antitumor activity of hu14.18-IL2 in patients with relapsed/refractory neuroblastoma: a Children's Oncology Group (COG) phase II study. *J Clin Oncol.* 2010;28:4969–4975.
142. Delgado DC, Hank JA, Kolesar J, et al. Genotypes of NK cell KIR receptors, their ligands, and Fcγ receptors in the response of neuroblastoma patients to Hu14.18-IL2 immunotherapy. *Cancer Res.* 2010;70:9554–9561.
143. Cheung NK, Sowers R, Vickers AJ, et al. FCGR2A polymorphism is correlated with clinical outcome after immunotherapy of neuroblastoma with anti-GD2 antibody and granulocyte macrophage colony stimulating factor. *J Clin Oncol.* 2006;24:2885–2890.
144. Merchant MS, Baird K, Wexler LH, et al. Ipilimumab: first results of a phase I trial in pediatric patients with advanced solid tumors. *J Clin Oncol.* 2012;30:9545.
145. Russell HV, Strother D, Mei Z, et al. Phase I trial of vaccination with autologous neuroblastoma tumor cells genetically modified to secrete IL-2 and lymphotactin. *J Immunother.* 2007;30:227–233.
146. Krishnadas DK, Shapiro T, Lucas K. Complete remission following decitabine/dendritic cell vaccine for relapsed neuroblastoma. *Pediatrics.* 2013;131:e336–e341.
147. Kanold J, Paillard C, Tchirkov A, et al. NK Cell immunotherapy for high-risk neuroblastoma relapse after haploidentical HSCT. *Pediatr Blood Cancer.* 2012;59:739–742.
148. Lee DW, Barrett DM, Mackall C, et al. The future is now: chimeric antigen receptors as new targeted therapies for childhood cancer. *Clin Cancer Res.* 2012;18:2780–2790.
149. Louis CU, Savoldo B, Dotti G, et al. Antitumor activity and long-term fate of chimeric antigen receptor-positive T cells in patients with neuroblastoma. *Blood.* 2011;118:6050–6056.
150. Pule MA, Savoldo B, Myers GD, et al. Virus-specific T cells engineered to coexpress tumor-specific receptors: persistence and antitumor activity in individuals with neuroblastoma. *Nat Med.* 2008;14:1264–1270.
151. Jena B, Dotti G, Cooper LNJ. Redirecting T-cell specificity by introducing a tumor-specific chimeric antigen receptor. *Blood.* 2010;116:1035–1044.
152. Pession A, Tonelli R. The MYCN oncogene as a specific and selective drug target for peripheral and central nervous system tumors. *Curr Cancer Drug Targets.* 2005;5:273–283.
153. Puissant A, Frumm SM, Alexe G, et al. Targeting MYCN in neuroblastoma by BET bromodomain inhibition. *Cancer Discov.* 2013;3:308–323.
154. Shukla N, Ameer N, Yilman I, et al. Oncogene mutation profiling of pediatric solid tumors reveals significant subsets of embryonal rhabdomyosarcoma and neuroblastoma with mutated genes in growth signaling pathways. *Clin Cancer Res.* 2011;18:748–757.
155. Eleveld TF, Oldridge DA, Bernard V, et al. Relapsed neuroblastomas show frequent RAS-MAPK pathway mutations. *Nat Gen.* 2015;47:864–871.
- **The first report of genetic aberrations specifically associated with relapsed neuroblastoma.**
156. Holzel M, Huang S, Koster J, et al. NF1 is a tumor suppressor in neuroblastoma that determines retinoic acid response and disease outcome. *Cell.* 2010;142:218–229.
157. Woodfield SE, Zhang L, Scorsone K, et al. Binimetinib Inhibits MEK and is effective against neuroblastoma tumor cells with low NF1 expression. *BMC Cancer.* 2016;16:172.
158. Oppenheimer O, Cheung N-K, Gerald WL. The RET oncogene is a critical component of transcriptional programs associated with retinoic acid-induced differentiation in neuroblastoma. *Mol Cancer Ther.* 2007;6:1300–1309.
159. Zage PE, Zeng L, Palla S, et al. A novel therapeutic combination for neuroblastoma: the VEGFR/EGFR/RET inhibitor vandetanib with 13-cis-retinoic acid. *Cancer.* 2010;116:2465–2475.
160. Grinshtein N, Datti A, Fujitani N, et al. Small molecule kinase inhibitor screen identifies polo-like kinase 1 as a target for neuroblastoma tumor-initiating cells. *Cancer Res.* 2011;71:1385–1395.
161. Cole KA, Huggins J, Laquaglia M, et al. RNAi screen of the protein kinome identifies checkpoint kinase 1 (CHK1) as a therapeutic target in neuroblastoma. *Proc Natl Acad Sci USA.* 2011;108:3336–3341.
162. Balamuth NJ, Wood A, Wang Q, et al. Serial transcriptome analysis and cross-species integration identifies centromere-associated protein E as a novel neuroblastoma target. *Cancer Res.* 2010;70:2749–2758.
163. Cohen LE, Gordon JH, Popovsky EY, et al. Late effects in children treated with intensive multimodal therapy for high-risk neuroblastoma: high incidence of endocrine and growth problems. *Bone Marrow Transplant.* 2014;49:502–508.
164. Moreno L, Vaidya SJ, Pinkerton CR, et al. Long-term follow-up of children with high-risk neuroblastoma: the ENSG5 trial experience. *Pediatr Blood Cancer.* 2013;60:1135–1140.
165. Laverdiere C, Cheung NK, Kushner BH, et al. Long-term complications in survivors of advanced stage neuroblastoma. *Pediatr Blood Cancer.* 2005;45:324–332.
166. Trahair TN, Vowels MR, Johnston K, et al. Long-term outcomes in children with high-risk neuroblastoma treated with autologous stem cell transplantation. *Bone Marrow Transplant.* 2007;40:741–746.
167. Laverdiere C, Liu Q, Yasui Y, et al. Long-term outcomes in survivors of neuroblastoma: a report from the Childhood Cancer Survivor Study. *J Natl Cancer Inst.* 2009;101:1131–1140.
168. Hobbie WL, Moshang T, Carlson CA, et al. Late effects in survivors of tandem peripheral blood stem cell transplant for high-risk neuroblastoma. *Pediatr Blood Cancer.* 2008;51:679–683.
169. Fawzy M, El-Beltagy M, Shafei ME, et al. Intraspinal neuroblastoma: treatment options and neurological outcome of spinal cord compression. *Oncol Lett.* 2015;9:907–911.
170. Applebaum MA, Henderson TO, Lee SM, et al. Second malignancies in patients with neuroblastoma: the effects of risk-based therapy. *Pediatr Blood Cancer.* 2015;62:128–133.
171. Federico SM, Allewelt HB, Spunt SL, et al. Subsequent malignant neoplasms in pediatric patients initially diagnosed with neuroblastoma. *J Pediatr Hematol Oncol.* 2015;37:e6–e12.
172. Martin A, Schneiderman J, Helenowski IB, et al. Secondary malignant neoplasms after high-dose chemotherapy and autologous stem cell rescue for high-risk neuroblastoma. *Pediatr Blood Cancer.* 2014;61:1350–1356.
173. Polishchuk AL, DuBois SG, Haas-Kogan D, et al. Response, survival, and toxicity after iodine-131-metaiodobenzylguanidine therapy for neuroblastoma in preadolescents, adolescents, and adults. *Cancer.* 2011;117:4286–4293.
174. Quach A, Ji L, Mishra V, et al. Thyroid and hepatic function after high-dose 131I metaiodobenzylguanidine (131I-MIBG) therapy for neuroblastoma. *Pediatr Blood Cancer.* 2011;56:191–201.