

UC Davis

Dermatology Online Journal

Title

Otophyma: a rare benign clinical entity mimicking leprosy

Permalink

<https://escholarship.org/uc/item/41p4q5xq>

Journal

Dermatology Online Journal, 21(3)

Authors

Shuster, Marina
McWilliams, Ashley
Giambrone, Danielle
et al.

Publication Date

2015

DOI

10.5070/D3213024280

Supplemental Material

<https://escholarship.org/uc/item/41p4q5xq#supplemental>

Copyright Information

Copyright 2015 by the author(s). This work is made available under the terms of a Creative Commons Attribution-NonCommercial-NoDerivatives License, available at <https://creativecommons.org/licenses/by-nc-nd/4.0/>

Peer reviewed

Photo vignette

Otophyma: a rare benign clinical entity mimicking leprosy

Marina Shuster BA¹, Ashley McWilliams BS², Danielle Giambrone BS³, Omar Noor MD³, Jisun Cha MD³

Dermatology Online Journal 21 (3): 22

¹**Harvard Medical School**

²**Virginia Commonwealth University School of Medicine**

³**Rutgers- Robert Wood Johnson Medical School**

Correspondence:

Danielle Giambrone
Department of Dermatology
Rutgers- Robert Wood Johnson Medical School
1 World's Fair Drive
Somerset, NJ 08873
Email: daniellegiam10@gmail.com
Phone: 609-220-7710

Abstract

Otophyma is a rare condition characterized by edematous deformation of the ear that is considered to be the end-stage of an inflammatory process such as rosacea and eczema. This report illustrates a case in an elderly male, originally thought to have leprosy. Biopsy revealed a nodular infiltration of inflammatory cells around adnexal structures and an intraepidermal cyst. No acid-fast organisms were identified. We present a patient who is of a different ethnic group than usually seen with this disease and provide a review of the clinical presentation, histopathological features, and management of this rare condition.

Keywords: Otophyma, Leprosy, Rhinophyma, Rosacea

Case synopsis

A 62-year-old Filipino male presented for evaluation of his grossly enlarged ears. He had a 30-year-history of ear swelling which had recently become very itchy. He has never had his ear evaluated or treated over the past 30 years but most recently started hydrocortisone cream with no relief of his itching. Physical examination was notable for significant bilateral auricular enlargement with scattered pustules (Figure 1). No paraesthesia was noted. A punch biopsy was performed and sent for histologic analysis and culture.

Biopsy was notable for a nodular infiltration of lymphocytes, histiocytes, neutrophils, and eosinophils around adnexal structures and a large ruptured intraepidermal cyst filled with keratinous material with surrounding acute inflammation that extended into the dermis. There was mild sebaceous hyperplasia with enlarged sebaceous lobules (Figure 2). A subtle grenz zone and abundant foamy histiocytes with foreign granules in the cytoplasm were noted. Fite acid fast stain, gram stain, Giemsa, and GMS special staining were negative. No granulomatous inflammation was present and fungal culture was negative. Correlating the pathology report with the clinical picture, otophyma was diagnosed. The patient was referred to plastic surgery for a staged ear reconstruction.

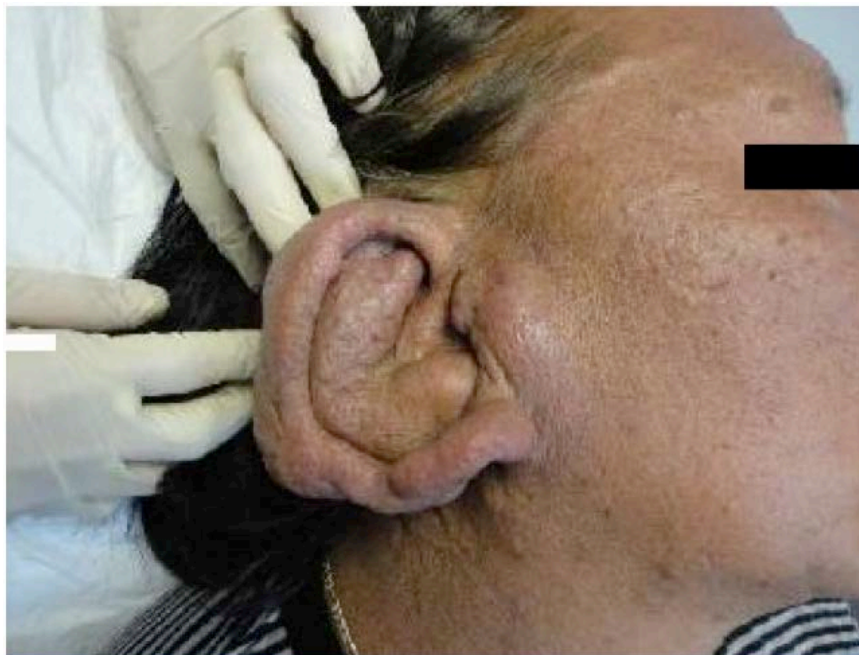
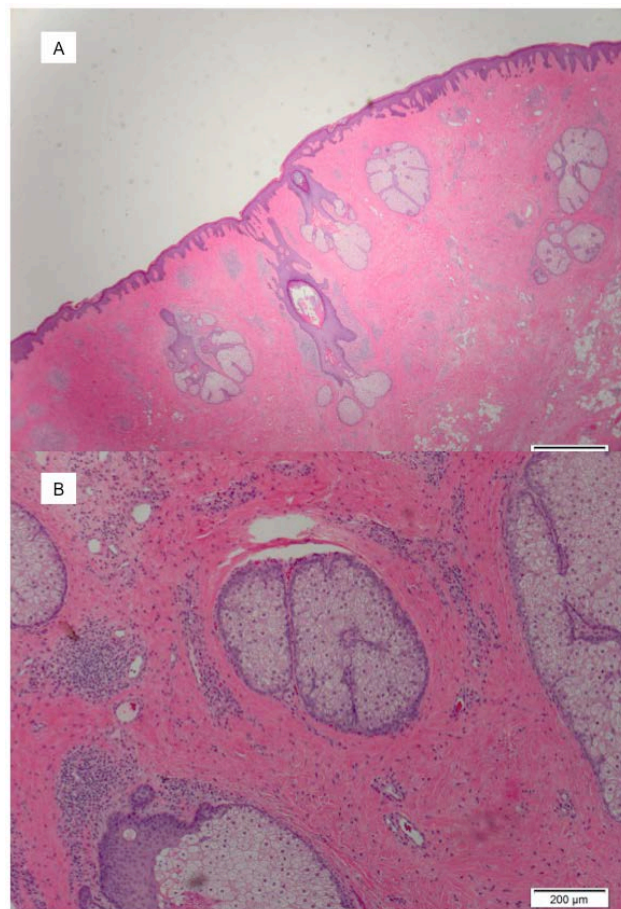


Figure 1. Clinical view of the patient's right ear displaying diffuse fleshy granulomatous enlargement of his entire ear including the concha, helix, and tragus. **Figure 2 (a and b).** Low (a) and high (b) magnification views: Low magnification shows mild sebaceous hyperplasia with mild inflammatory infiltrates. High magnification shows enlarged sebaceous lobules with perifollicular lymphocytic inflammation.



Discussion

Phyma, the Greek word for growth [1], refers to sebaceous hyperplasia, fibrosis, and lymphedema causing local facial soft tissue swelling [2]. The most common area of involvement is the nose (rhinophyma), but may include the forehead (metophyma), chin (gnathophyma), eyelids (blepharophyma), and ears (otophyma) [3].

It is most commonly a result of end-stage rosacea but can occur secondary to eczema, psoriasis, erysipelas, cellulitis, trauma, or primary/congenital lymphedema [3,4]. Phymas most commonly occur in white men between the ages of 40 and 60 with a 20:1 male to female predominance, though rosacea is more common in females [5]. Otophyma tends to occur bilaterally and is predominantly found in men, with reported age ranges from 4 to 66 [6]. Androgenic influence of sebaceous units has been hypothesized to explain the increased occurrence of phymas in males [7].

The majority of medical literature pertaining to phymas involves rhinophyma because it is relatively common, but is similarly applicable to otophyma diagnosis and management. Thus, our discussion includes a review of rhinophyma literature. Rhinophyma can be subdivided into classic and severe forms. Clinically, classic rhinophyma develops in stages, starting with pitting edema that progresses to irreversible sclerotic changes and firm edema with notable follicular and adnexal ostia in an peau d' orange appearance [3]. Severe rhinophyma presents as firm or soft, smooth-surfaced, erythematous nodules [8]. Most rhinophymas occur in Caucasian men with only a handful reported cases of rhinophymas occurring in Asians and African Americans [9]. More specifically otophymas, however, have not yet been reported in the Asian population to our knowledge.

Although the diagnosis can be made clinically, biopsy is useful for ruling out more worrisome conditions including leprosy, sarcoidosis, cutaneous malignancy (basal cell, squamous cell or sebaceous carcinoma), angiosarcoma, and nasal lymphoma [10-19]. Our case was initially concerning for leprosy owing to the infiltrated granulomatous appearance of the patient's ears. In classical phymas, histology is notable for sebaceous gland hypertrophy and hyperplasia as well as occluded and dilated hair follicles with cyst formation. Typically, there is fibrous scar tissue, perivascular and perifollicular infiltrate of lymphohistiocytes and plasma cells, focal edema, and Demodex folliculorum inhabitation of the pilosebaceous unit with a secondary foreign body reaction [1,3]. In contrast, severe forms of phyma share many histological characteristics with elephantiasis caused by chronic lymphedema [20].

Medical management of otophyma has shown mixed efficacy. There are some reports of improvement with tetracyclines, metronidazole, topical retinoids, intralesional steroids, and oral prednisone [3,20,21]. Other sources comment that these medications do not prevent the transition from rosacea to phyma [1]. Surgical treatments involve either partial or full excision.

Partial excision of superficial layers with cryosurgery, electrosurgery, chemical peels, dermabrasion or CO2 lasers [6,22] allows for reepithelization secondary to the proliferation of the remaining sebaceous glands [1]. Alternatively, excision of otophymous skin changes with resurfacing by immediate or delayed full-thickness skin graft [6] has been shown to be effective.

Thus, our case represents a rarely reported presentation of phyma of the ear, in a unique patient population, originally mistaken for leprosy. It is critical to include otophyma when considering ear growths and perform a biopsy to rule out more harmful conditions.

References

1. Gupta M, Gupta M, Narang T. Otophyma: a rare and frequently misdiagnosed entity. *Am J Otolaryngol*. 2010 May-Jun;31(3):199-201. [PMID: 20015739]
2. Burns T, Breathnach S, Cox N, et al. *Rook's Textbook of Dermatology*. London, UK: Blackwell Publishing; 2010.
3. Carlson JA, Mazza J, Kircher K, Tran TA. Otophyma: a case report and review of the literature of lymphedema (elephantiasis) of the ear. *Am J Dermatopathol*. 2008 Feb;30(1):67-72. [PMID: 18212550]
4. Daniels K, Haddow K. Otophyma: a case report. *J Laryngol Otol*. 2008 May;122(5):524-6. [PMID: 17517166]
5. Roberts JO, Ward CM. Rhinophyma. *J R Soc Med*. 1985 Aug;78(8):678-81. [PMID: 3160857]
6. Sharma KS, Pollock J, Hasham S, Brotherston TM. CASE REPORT Treatment of Otophyma: Case Report and Review of the Literature. *Eplasty*. 2013 Apr 3;13:e18. [PMID: 23641297]
7. Rohrich RJ, Griffin JR, Adams WP. Rhinophyma: Review and Update. *Plast Reconstr Surg*. 2002 Sep 1;110(3):860-69 [PMID: 12172152]
8. Aloï F, Tomasini C, Soro E, Pippione M. The clinicopathologic spectrum of rhinophyma. *J Am Acad Dermatol*. 2000 Mar;42(3):468-72. [PMID: 10688718]
9. Madan V, Ferguson JE, August PH. Carbon dioxide laser treatment of rhinophyma: a review of 124 patients. *British Journal of Dermatology*. 161: 814-818 [PMID: 19624541]
10. Lutz ME, Otley CC. Rhinophyma and coexisting occult skin cancers. *Dermatol Surg*. 2001 Feb;27(2):201-2. [PMID: 11207700]
11. Gallardo MA, Bosch RJ, Vidal L, Cabra B, Rodrigo AB, De Galvez MV, Herrera E. Angiosarcoma arising on rhinophyma. *Eur J Dermatol*. 2000 Oct-Nov;10(7):555-8. [PMID: 11056431]
12. McKenna DJ, McKenna K. Basal cell carcinoma lurking within gross rhinophyma. *Clin Exp Dermatol*. 2006 Jan;31(1):173-4. [PMID: 16309536]
13. Murphy A, O'Keane JC, Blayney A, Powell FC. Cutaneous presentation of nasal lymphoma: a report of two cases. *J Am Acad Dermatol*. 1998 Feb;38(2 Pt 2):310-3. [PMID: 9486704]
14. Traaholt L, Eeg Larsen T. Rhinophyma and angiosarcoma of the nose. A case report. *Scand J Plast Reconstr Surg*. 1978;12(1):81-3. [PMID: 149363]
15. Acker DW, Helwig EB. Rhinophyma with carcinoma. *Arch Dermatol*. 1967 Mar;95(3):250-4. [PMID: 4225333]
16. Motley RJ, Douglas-Jones AF, Holt PJ. Sebaceous carcinoma: an unusual cause of a rapidly enlarging rhinophyma. *Br J Dermatol*. 1991 Mar;124(3):283-4. [PMID: 2018736]
17. Keefe M, Wakeel RA, McBride DI. Basal cell carcinoma mimicking rhinophyma. Case report and literature review. *Arch Dermatol*. 1988 Jul;124(7):1077-9. [PMID: 2968781]
18. Ross DA, Davies MP. Squamous cell carcinoma arising in rhinophyma. *J R Soc Med*. 1992 Apr;85(4):236-7. [PMID: 1433070]
19. Kornblut AD, Evers K. Rhinophyma and intranasal carcinoma. *J Laryngol Otol*. 1973 Nov;87(11):1137-41. [PMID: 4270952]
20. Ekmekci TR, Koslu A, Sakiz D. A case of otophyma. *Clin Exp Dermatol*. 2005 Jul;30(4):441-2. [PMID: 15953095]
21. Malak J, Hadi U. Otic rosacea. *Arch Otolaryngol Head Neck Surg*. 1999 Apr;125(4):479. [PMID: 10208695]
22. Sadick H, Goepel B, Bersch C, Goessler U, Hoermann K, Riedel F. Rhinophyma: diagnosis and treatment options for a disfiguring tumor of the nose. *Ann Plast Surg*. 2008 Jul;61(1):114-20. [PMID: 18580161]