

UC Berkeley

UC Berkeley Previously Published Works

Title

Effects of Isotretinoin on Meibomian Glands

Permalink

<https://escholarship.org/uc/item/41k4v4h1>

Journal

Optometry and Vision Science, 92(9)

ISSN

1040-5488

Authors

Moy, Allison
McNamara, Nancy A
Lin, Meng C

Publication Date

2015-09-01

DOI

10.1097/opx.0000000000000656

Peer reviewed

REVIEW

Effects of Isotretinoin on Meibomian Glands

Allison Moy*, Nancy A. McNamara†, and Meng C. Lin‡

ABSTRACT

The authors have reviewed the potential etiology and long-standing consequences of isotretinoin use in the development of dry eye symptoms in the absence of significant clinical findings. Despite the normal appearance of meibomian gland structure on meibography and minimal signs of eyelid margin inflammation, the secretory function of these glands is reduced and symptoms of dryness can greatly impact a patient's quality of life. The available literature indicates that isotretinoin's effect on the meibomian glands likely mimics its effects on the sebaceous glands of the skin in the treatment of acne. Several representative cases seen at the University of California Berkeley School of Optometry Dry Eye Clinic provide a clinical paradigm with the goal of raising awareness of the potential prevalence of this disease in patients who experience symptoms of dry eye. These cases highlight the importance of meibomian gland expression in determining whether there is poor quality and/or quantity of meibum secondary to reduced gland function. Currently, there is no definitive method to restore the structure and function of damaged meibomian glands; thus, treatment options for isotretinoin-associated meibomian gland dysfunction are primarily palliative to manage patient symptoms.

(Optom Vis Sci 2015;92:925–930)

Key Words: isotretinoin, meibomian glands, keratitis sicca, nonobvious meibomian gland dysfunction, acne, Accutane, 13 *cis*-retinoic acid, review

Keratoconjunctivitis sicca, more commonly known as dry eye, is a common condition with a wide array of etiologies. Patients with symptoms of ocular dryness are often classified as having either evaporative dry eye or aqueous-deficient dry eye, although, in reality, dryness is a common symptom that occurs in many disorders affecting the ocular surface. Aqueous-deficient dry eye refers to a deficiency in the watery component of the tear film, whereas evaporative dry eye is most often associated with altered quality or quantity of oils secreted from meibomian glands located along the upper and lower eyelid margins. Evaporative dry eye can be further classified based on meibomian gland secretion: a low-delivery versus high-delivery state.¹ A low-delivery state can be caused by either hyposecretion of meibum or obstruction of the gland, whereas a high-delivery state results in a large volume of lipid secretion that is visible with gland expression.¹ Physical obstruction of the meibomian gland duct is the most common form of meibomian gland dysfunction (MGD) and is referred to clinically as obstructive MGD.² The typical signs of

obstructive MGD are orifice pouting, capped or ulcerated glands, irregular or thickened eyelid margins, telangiectasia, and serration of the eyelid margin.²

Recently, Blackie et al.² proposed a subcategory of MGD, referred to as nonobvious MGD, which they speculated to be a precursor to obstructive MGD. Patients with nonobvious MGD demonstrated characteristic changes in the quality and quantity of sebum secretion but in the absence of clinically apparent inflammation. Blackie et al.² suggested that the prevalence of nonobvious MGD might be higher than expected because its diagnosis requires physical expression of the glands, which is not routinely performed.

Obstruction of meibomian glands in the absence of inflammation was first described in 1980 by Korb and Henriquez.³ In that study, a group of contact lens-intolerant patients (mean age, 34 years; range, 19 to 82 years) demonstrated significant meibomian gland obstruction in the absence of any obvious clinical signs of ocular inflammation. Further analysis of histopathologic smears obtained from scrapings of the eyelid margin in the affected and control groups exhibited differences in cell population.³ In the affected group, the smears revealed an increased turnover rate of epidermal cells along with the presence of desquamated epithelial cells aggregating into keratotic clusters, which were absent in the control group.³ Korb and Henriquez³ suggest that these clusters of desquamated epithelial cells are significant in the mechanism of obstruction to the meibomian glands.

*OD

†OD, PhD

‡OD, PhD, FAAO

School of Optometry (all authors), Vision Science Program (NAMc, MCL), University of California, Berkeley, Berkeley, California; Proctor Foundation, University of California, San Francisco, San Francisco, California (NAMc); and Clinical Research Center, University of California, Berkeley, Berkeley, California (MCL).

The etiology of nonobvious MGD is not entirely understood, but one cause may be the use of systemic medications, such as isotretinoin. Isotretinoin was first marketed as Accutane by Hoffman-La Roche as a treatment of severe acne. Between 30 and 50% of patients report dry eye symptoms while undergoing isotretinoin treatment of acne.⁴⁻⁶ Isotretinoin appears to cause a nonobvious, low-delivery state MGD through hyposecretion of meibum owing to poorly functioning glands.

Here, we review the potential etiology and long-standing consequences of isotretinoin use in the development of nonobvious MGD. We report a series of representative cases to demonstrate the clinical paradigm with the goal of raising awareness of the potential prevalence of this disease in patients who experience symptoms of dry eye in the absence of significant clinical findings.

Isotretinoin's Mechanism of Action for Acne Treatment

Isotretinoin (also known as 13 *cis*-retinoic acid) has been the main drug of choice for severe acne particularly when other treatment modalities fail.⁷ The standard oral dosage for acne treatment ranges from 0.5 to 2 mg/kg per day over a span of 4 to 6 months,⁷ and previous studies have shown that with a dose of 0.5 to 1.0 mg/kg per day, isotretinoin can reduce sebum excretion by 90% within 6 weeks through a mechanism that includes decreased sebocyte proliferation and suppression of sebum production.^{8,9} Isotretinoin also alters the microenvironment in the gland by decreasing the amount of *Propionibacterium acnes* colonization, which in turn decreases inflammation.⁸ The general consensus is that isotretinoin affects the function of meibomian glands in a similar fashion to its effect on sebaceous glands in the skin.^{9,10} Evidence from translational research suggests that isotretinoin's upregulation of FoxO transcription factors is responsible for inhibiting sebocyte lipid synthesis, decreasing sebocyte proliferation, inducing sebocyte apoptosis, and arresting the sebocyte cell cycle.⁹ Isotretinoin-mediated stimulation of FoxO-mediated gene expression could explain the development of dry eye in these patients.⁹

Similarly, Ding et al.¹⁰ used proliferation assays and cell death analyses to show that 13 *cis*-retinoic acid alters meibomian gland epithelial cell gene expression, reduces the activity of cell survival mediators, inhibits proliferation, and induces meibocyte cell death.

Animal Studies Demonstrating Isotretinoin's Effects on Tear Gland Morphology

Using animal models to explore the effects of isotretinoin at a cellular level, studies have shown that low-dose isotretinoin (2 mg/kg per day) administered orally to rabbits for 60 days was found to decrease goblet cells, increase thickening and keratinization of the meibomian gland ducts, and decrease acini size and lipid content of the meibomian glands.¹¹ Similar to findings in human patients, there was also no evidence of an inflammatory reaction in the meibomian glands themselves or the surrounding eyelid tissue.¹¹ Meibomian gland morphology has also been analyzed in hamster models where a reduction of up to 75% in the mean volume of meibomian acinar tissue resulted from the oral intubation of powdered 13 *cis*-retinoic acid over a 30-day period.¹² The selected dosage was based on the clinical dose used for cystic acne therapy. Although ocular surface and

tear composition were not assessed, the hamsters developed eyelid crusting and conjunctival erythema.¹²

Interestingly, isotretinoin's effects appear to be specific to the meibomian gland without impacting the overall level of aqueous tear production. When administered to rabbits over 5 months using a dosage 5 to 10 times higher than that used clinically, there was no significant change in tear secretion measured using the Schirmer test compared with the untreated control group.¹³ Additionally, histologic analysis showed no significant alterations in morphology of the lacrimal gland in treated and untreated rabbits. This further indicates that ocular dryness associated with isotretinoin use is dependent on pathologic changes of the meibomian glands, rather than reduced lacrimal gland function.¹³

Clinical Studies Demonstrating Isotretinoin's Effects on the Ocular Surface

Using meibography, Mathers et al.¹⁴ demonstrated atrophy and reduced density of meibomian glands in patients after a 4-month treatment of acne. A unique finding with meibography indicated that all the glands were equally affected by isotretinoin use, which, in contrast to MGD secondary to blepharitis or rosacea, causes some glands to be severely affected whereas others remain fully intact.¹⁴ The degree of atrophy was determined using a predefined scale from 0 to 4 based on the appearance of atrophy. Before treatment, the amount of atrophy was zero, but increased to 2.5 ± 1.2 ($p < 0.005$). These morphological changes were accompanied by a decrease in meibum volume and an increase in meibum thickness when performing gland expression. The meibum volume and thickness were also graded on a predefined scale based on appearance from 1 to 4. The meibum volume decreased from 1.52 ± 0.68 before treatment to 1.0 ± 0.30 during treatment ($p < 0.05$), whereas the meibum thickness increased from 1.7 ± 0.9 to 3.10 ± 1.26 ($p < 0.005$). Many patients with normal secreta before treatment developed thick, toothpaste-like secreta by the end of the study.¹⁴ Increased viscosity of meibum may be attributed to multiple factors. Isotretinoin is known to alter the composition of meibomian gland secretions by increasing cholesterol content and decreasing waxy esters.¹⁴ It also causes stasis of secretion secondary to increased keratinization of the meibomian gland duct, which could subsequently interfere with the degradation of meibum by resident bacterial or epithelial lipase enzymes.¹⁴ Additionally, isotretinoin increases tear osmolarity during treatment, most likely because of a compromised lipid function and destabilization of the tear film, which facilitates an increased rate of tear evaporation.¹⁴ Tear samples were taken before and during treatment and increased from 304.9 ± 11 to 316.3 ± 10 mOsm/L ($p < 0.005$). Similar to animal studies, aqueous tear production by the lacrimal gland appears to remain stable during treatment as indicated by a normal Schirmer test.¹⁴

In addition to its lipid and aqueous components, the tear film contains a layer of mucus that serves important roles both in innate defense and in maintaining a moist, smooth ocular surface. A study by de Queiroga et al.¹⁵ used conjunctival impression cytology to analyze the effect of isotretinoin on goblet cells, which are responsible for the production of mucin. Subjects were on isotretinoin for 3 months of varying dosage from 0.35 to 0.88 mg/kg per day. Alterations to the conjunctival epithelial tissue includes

squamous metaplasia—a process whereby nonkeratinized mucosal epithelial cells lining the ocular surface are transformed to pathologically keratinized, nonsecretory epithelial cells with a reduced number of mucin-secreting goblet cells.¹⁵ de Queiroga et al. demonstrated an isotretinoin-induced toxicity that was associated with morphologic changes in the conjunctiva. These findings suggested that in addition to altering the composition and secretion of meibum, isotretinoin further compromises tear quality by interfering with the production of gel-forming mucins.¹⁵

Altered tear film stability was noted by Rismondo and Ubels, who measured isotretinoin levels in the tears of both rabbits and human subjects. The presence of isotretinoin in the tear film was believed to exacerbate ocular surface disease by further increasing tear osmolarity.¹⁶ Additionally, Rismondo and Ubels¹⁶ measured isotretinoin levels in the tear film of human subjects after 1, 2, 3, and 4 months of treatment and found that isotretinoin levels were constant, indicating that concentration was not related to duration of treatment. The maximum levels of isotretinoin in the tear film were achieved after 3 days of treatment, suggesting that the amount of isotretinoin secreted by the lacrimal gland is limited.¹⁶ Karalezli et al.¹⁷ found that pretreatment TBUT was 12.84 seconds and decreased to 7.84 seconds after 30 days on isotretinoin. Similarly, Egger et al.¹⁸ found that although none of their subjects had TBUT less than 10 seconds before therapy, after 12 weeks on isotretinoin, 69.1% (38 of 55) developed pathologic TBUT (<10 seconds). Interestingly, tear stability recovered to pretreatment levels 1 month after discontinuing the medication in both studies.^{17,18}

Although isotretinoin's detrimental effects on the meibomian glands and tear film are well established, the extent to which the dosage of isotretinoin influences disease severity is unclear. One study of meibomian gland morphology or excreta composition noted no difference in disease severity,¹⁴ whereas another found clinically significant differences in TBUT values between low-dose (<0.5 mg/kg per day) and high-dose (>0.5 mg/kg per day) treatment groups, which subsequently returned to similarly normal values within 1 month after treatment.¹⁹ Additional studies are required to address the extent to which varying dosage affects the severity of MGD.

Along with isotretinoin's effect on the tear film, the medication also increases the conjunctival bacterial flora. Egger et al.¹⁸ noted an increase in colonization of *Staphylococcus aureus* in the conjunctival sac present in 7.3% of subjects before treatment and that it increased to 61.8% of subjects during therapy, which remained elevated throughout the 16 weeks of treatment. After 1 month of discontinuing isotretinoin, conjunctival flora went back to normal levels.¹⁸ Oner et al.²⁰ also found an increase in *Staphylococcus* in subjects on isotretinoin. *Staphylococcus* was cultured in 22% of subjects before isotretinoin therapy and this increased to 36% during therapy.

The extent to which isotretinoin's effects on meibomian gland structure and function persist after discontinuation of therapy is unclear. Most studies have found that clinical signs related to ocular surface integrity return to normal within 1 to 2 months of discontinuing isotretinoin.^{15,17,19} However, there are several reports of keratoconjunctivitis sicca that persists for several years after isotretinoin therapy.^{20,21} For example, in a retrospective study, Fraunfelder et al.²² found 16 cases among 1741 subjects (1%) with irreversible keratoconjunctivitis sicca. Prospective studies that

delineate the prevalence of long-term damage to meibomian glands after isotretinoin therapy and potential predictors or risk factors are unavailable. Information regarding isotretinoin's long-term effects is incomplete, and until additional studies are performed on human subjects, it is unknown if damage to the meibomian glands persists and in some cases may be permanent.

Treatment for Isotretinoin-Induced MGD

Treatment options for isotretinoin-associated, nonobvious MGD are severely limited, as there are few methods to restore the structure and function of damaged meibomian glands. Most treatment options are primarily palliative in nature but can effectively reduce symptoms and improve quality of life in patients with chronic and often debilitating symptoms of dryness. Patients may benefit from standard MGD treatment to promote sebum secretion. These include warm compresses, eyelid massage, and eyelid hygiene. In addition, supplementing ocular hydration through the complementary use of artificial tears and lubricants may be beneficial. Lastly, LipiFlow by TearScience is an in-office instrument used to heat the meibomian glands from the inner eyelid using a specialized contact lens that protects the cornea while providing therapeutic heat and pulsating pressure to express obstructed meibomian glands. A single LipiFlow treatment is at least as effective as a 3-month, twice-daily eyelid margin hygiene regimen for MGD.²³ This procedure may have a potential benefit, but further research is necessary to look into its effect on isotretinoin-associated MGD.

Oral antibiotics may improve patient symptoms and improve meibum quality; however, there is no evidence that antibiotics can relieve meibomian gland obstruction.² Oral antibiotics such as doxycycline (100 mg bid) or tetracycline (250 mg qid) taken 6 weeks to several months²⁴ alter the fatty acid composition of the meibomian glands, which provides a more stable tear film with less tear evaporation. Studies have also shown that oral azithromycin (i.e., 500 mg/d for 3 days in 7-day intervals for 4 weeks) improves ocular surface signs.^{25,26} Topical azithromycin (1%) rubbed on the eyelid margins twice a day has shown off-label-use success in improving meibomian gland secretion quality, eyelid redness, and overall symptomatic relief.²⁷

In recent *in vitro* studies, azithromycin has been shown to stimulate the function of meibomian glands and may be a promising medication for isotretinoin-associated MGD. Azithromycin has demonstrated its ability to act directly on human meibomian glands to enhance the quality and quantity of meibum and promote their holocrine secretion.^{28–30} Liu et al.²⁸ exposed immortalized human meibomian gland epithelial cells to azithromycin, and within 3 days, the number and size of lipid-containing vesicles markedly increased compared with the control cells. The same group also compared azithromycin to doxycycline, minocycline, and tetracycline and found that only azithromycin increased lipid content in the meibomian glands.²⁹ This makes azithromycin's actions unique, and it is suggested that its cationic amphiphilic structure plays an important role.²⁹ The increase in lipid primarily occurs within lysosomes that subsequently release lipid content by holocrine secretion.²⁹ Cationic amphiphilic compounds are known to promote lysosome propagation and phospholipid accumulation.³⁰ Doxycycline, minocycline, and tetracycline do not contain this structure³⁰; thus, the therapeutic benefits of tetracycline derivatives

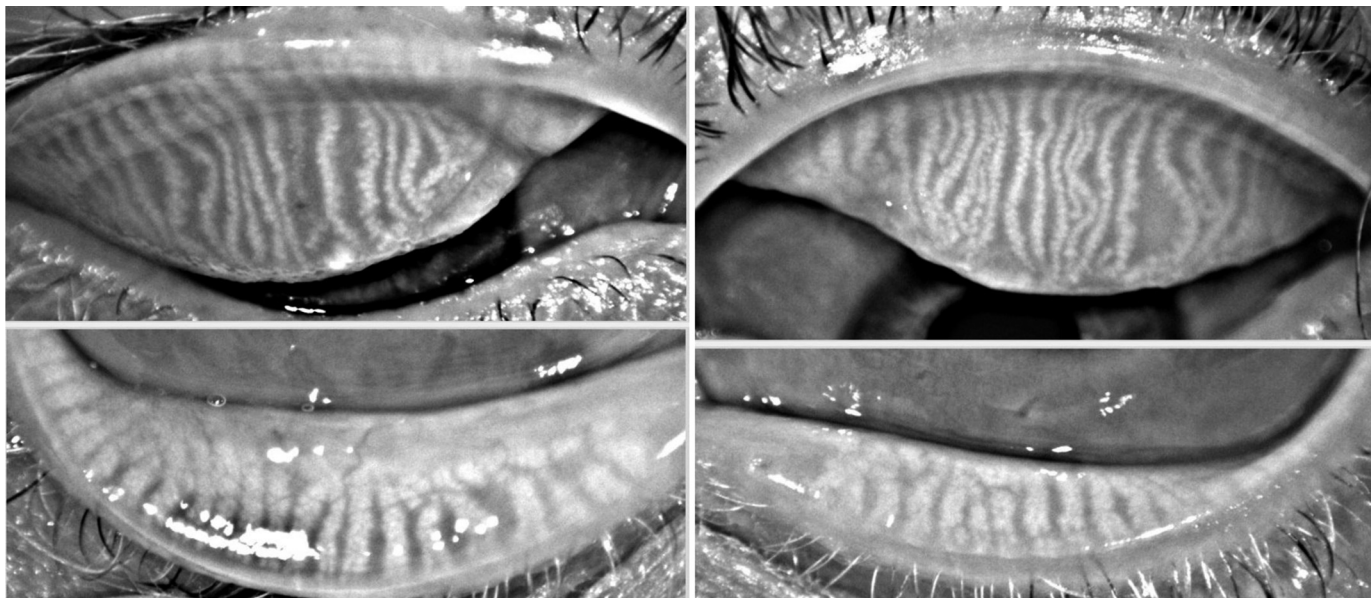


FIGURE 1.
Meibography for case 1 (left, OD; right, OS).

are more likely attributed to their anti-inflammatory and anti-bacterial actions with MGD.²⁹ Although azithromycin has similar anti-inflammatory and antibacterial effects, the additional lipid-promoting quality noted in these studies may prove more beneficial for isotretinoin-associated MGD, as it appears to promote lipid secretion. Further *in vivo* studies are necessary to test the therapeutic benefits of azithromycin in patients with isotretinoin-associated MGD.

CLINICAL CASES

To illustrate the potential long-term consequences of isotretinoin therapy on ocular surface integrity, we present three cases representative of patients with moderate to severe symptoms of ocular

dryness (Ocular Surface Disease Index scores were 27, 72, and 62, respectively), but without clinical signs to support their symptoms. These patients all took isotretinoin in their teens and gradually developed dry eye symptoms that persisted for several years after discontinuing the medication. Before presenting to University of California Berkeley’s Dry Eye Clinic, these patients had pursued multiple treatment modalities, such as warm compresses, fish oil supplements, and artificial tears, but with limited success.

Examination Findings

Several common findings and pertinent negatives were noted in these patients. For example, there was either trace or no corneal

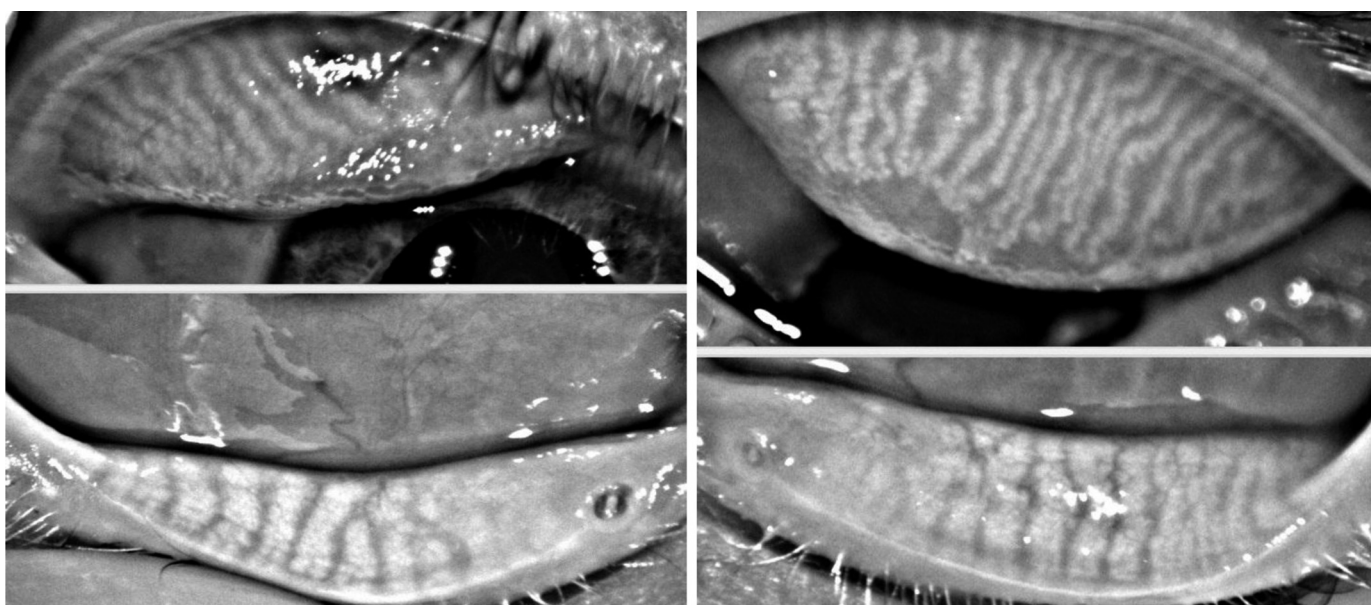


FIGURE 2.
Meibography for case 2 (left, OD; right, OS).

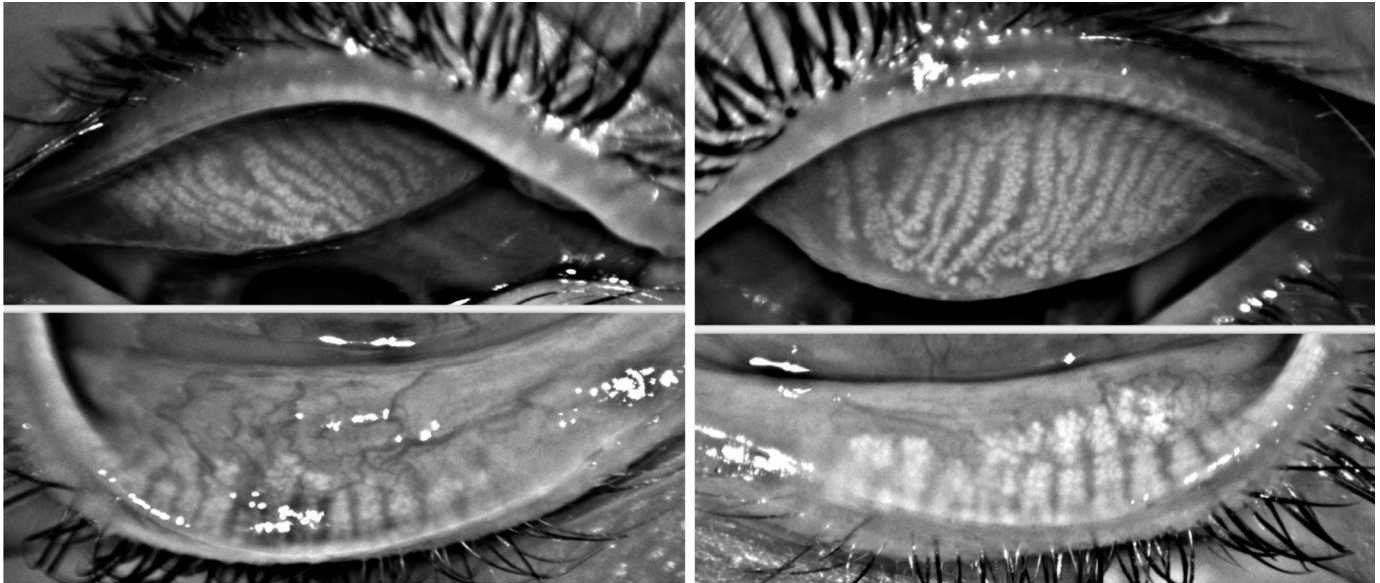


FIGURE 3.
Meibography for case 3 (left, OD; right, OS).

staining with sodium fluorescein and minimal conjunctival staining with lissamine green. Schirmer test without anesthesia resulted in adequate aqueous production with readings well above the normal cutoff of 10 mm. Meibography images demonstrated minimal meibomian gland dropout in upper and lower eyelids, indicating isotretinoin's marginal effect on gland structure (Figs. 1, 2, and 3). On slit lamp examination, there were no signs of eyelid inflammation such as telangiectatic, thickened, and hyperemic eyelid margins. The meibomian glands appeared patent and unobstructed. The most significant findings were noted during meibomian gland expression, which revealed clear but scanty secretion from a majority of the glands, regardless how the glands presented on meibography.

CONCLUSIONS

In our clinical experience, these cases demonstrate a consistent feature of dry eye noted several years after the discontinuation of isotretinoin therapy. Despite the normal appearance of meibomian gland structure on meibography and minimal signs of eyelid margin inflammation, the secretory function of these glands is reduced and symptoms of dryness can significantly impact a patient's quality of life. Because of this unique presentation, it is important to ask patients about history of isotretinoin use to determine a potential explanation for their dry eye symptoms. Available literature indicates that isotretinoin's effect on the meibomian glands is likely to mimic its effects on the sebaceous glands of the skin in the treatment of acne. A decrease in meibum production may also be compounded by alterations to other components of the tear film, including the secretion of gel-forming mucins from goblet cells. Poor meibum and mucin content in the tears can provoke excessive evaporation leading to dry eye that can persist long after the treatment is discontinued. Further studies regarding azithromycin's effects on promoting lipid secretion are necessary to determine if there are clinical benefits for patients with isotretinoin-associated MGD. Until more studies are performed and novel strategies are developed to restore and/or

enhance meibomian gland function, treatment options will remain primarily palliative.

ACKNOWLEDGMENTS

The authors have received no grant/financial support and have no commercial relationship interests to declare.

Received January 31, 2015; accepted April 16, 2015.

REFERENCES

- Nichols KK, Foulks GN, Bron AJ, Glasgow BJ, Dogru M, Tsubota K, Lemp MA, Sullivan DA. The international workshop on meibomian gland dysfunction: executive summary. *Invest Ophthalmol Vis Sci* 2011;52:1922–9.
- Blackie CA, Korb DR, Knop E, Bedi R, Knop N, Holland EJ. Nonobvious obstructive meibomian gland dysfunction. *Cornea* 2010;29:1333–45.
- Korb DR, Henriquez AS. Meibomian gland dysfunction and contact lens intolerance. *J Am Optom Assoc* 1980;51:243–51.
- Fraunfelder FT, LaBraico JM, Meyer SM. Adverse ocular reactions possibly associated with isotretinoin. *Am J Ophthalmol* 1985;100:534–7.
- Hull PR, Demkiw-Bartel C. Isotretinoin use in acne: prospective evaluation of adverse events. *J Cutan Med Surg* 2000;4:66–70.
- McLane J. Analysis of common side effects of isotretinoin. *J Am Acad Dermatol* 2001;45:S188–94.
- Wong J, Lan W, Ong LM, Tong L. Non-hormonal systemic medications and dry eye. *Ocul Surf* 2011;9:212–26.
- Layton A. The use of isotretinoin in acne. *Dermatoendocrinol* 2009;1:162–9.
- Melnik BC. Isotretinoin and FoxO1: a scientific hypothesis. *Dermatoendocrinol* 2011;3:141–65.
- Ding J, Kam WR, Dieckow J, Sullivan DA. The influence of 13-cis retinoic acid on human meibomian gland epithelial cells. *Invest Ophthalmol Vis Sci* 2013;54:4341–50.

11. Kremer I, Gatton DD, David M, Gatton E, Shapiro A. Toxic effects of systemic retinoids on meibomian glands. *Ophthalmic Res* 1994; 26:124–8.
12. Lambert RW, Smith RE. Effects of 13-cis-retinoic acid on the hamster meibomian gland. *J Invest Dermatol* 1989;92:321–5.
13. Rismondo V, Ubels JL, Osgood TB. Tear secretion and lacrimal gland function of rabbits treated with isotretinoin. *J Am Acad Dermatol* 1988;19:280–5.
14. Mathers WD, Shields WJ, Sachdev MS, Petroll WM, Jester JV. Meibomian gland morphology and tear osmolarity: changes with Accutane therapy. *Cornea* 1991;10:286–90.
15. de Queiroga IB, Antonio Vieira L, Barros Jde N, Melo Diniz Mde F, de Moraes LC. Conjunctival impression cytology changes induced by oral isotretinoin. *Cornea* 2009;28:1009–13.
16. Rismondo V, Ubels JL. Isotretinoin in lacrimal gland fluid and tears. *Arch Ophthalmol* 1987;105:416–20.
17. Karalezli A, Borazan M, Altinors DD, Dursun R, Kiyici H, Akova YA. Conjunctival impression cytology, ocular surface, and tear-film changes in patients treated with systemic isotretinoin. *Cornea* 2009; 28:46–50.
18. Egger SF, Huber-Spitzy V, Bohler K, Raff M, Scholda C, Barisani T, Vecsei VP. Ocular side effects associated with 13-cis-retinoic acid therapy for acne vulgaris: clinical features, alterations of tearfilm and conjunctival flora. *Acta Ophthalmol Scand* 1995;73:355–7.
19. Cumurcu T, Sezer E, Kilic R, Bulut Y. Comparison of dose-related ocular side effects during systemic isotretinoin administration. *Eur J Ophthalmol* 2009;19:196–200.
20. Oner A, Ferahbas A, Karakucuk S, Utas S, Karaman B, Kutlugun C, Somdas M, Mirza E. Ocular side effects associated with systemic isotretinoin. *J Toxicol-Cutan Ocul* 2004;23:189–95.
21. Lerman S. Ocular side effects of accutane therapy. *Lens Eye Toxic Res* 1992;9:429–38.
22. Fraunfelder FT, Fraunfelder FW, Edwards R. Ocular side effects possibly associated with isotretinoin usage. *Am J Ophthalmol* 2001; 132:299–305.
23. Finis D, Hayajneh J, Konig C, Borrelli M, Schrader S, Geerling G. Evaluation of an automated thermodynamic treatment (LipiFlow(R)) system for meibomian gland dysfunction: a prospective, randomized, observer-masked trial. *Ocul Surf* 2014;12:146–54.
24. Geerling G, Tauber J, Baudouin C, Goto E, Matsumoto Y, O'Brien T, Rolando M, Tsubota K, Nichols KK. The international workshop on meibomian gland dysfunction: report of the subcommittee on management and treatment of meibomian gland dysfunction. *Invest Ophthalmol Vis Sci* 2011;52:2050–64.
25. Bakar O, Demircay Z, Toker E, Cakir S. Ocular signs, symptoms and tear function tests of papulopustular rosacea patients receiving azithromycin. *J Eur Acad Dermatol Venereol* 2009;23:544–9.
26. Igami TZ, Holzchuh R, Osaki TH, Santo RM, Kara-Jose N, Hida RY. Oral azithromycin for treatment of posterior blepharitis. *Cornea* 2011;30:1145–9.
27. Luchs J. Efficacy of topical azithromycin ophthalmic solution 1% in the treatment of posterior blepharitis. *Adv Ther* 2008;25:858–70.
28. Liu Y, Kam WR, Ding J, Sullivan DA. Effect of azithromycin on lipid accumulation in immortalized human meibomian gland epithelial cells. *JAMA Ophthalmol* 2014;132:226–8.
29. Liu Y, Kam WR, Ding J, Sullivan DA. Can tetracycline antibiotics duplicate the ability of azithromycin to stimulate human meibomian gland epithelial cell differentiation? *Cornea* 2015;34:342–6.
30. Liu Y, Kam WR, Ding J, Sullivan DA. One man's poison is another man's meat: using azithromycin-induced phospholipidosis to promote ocular surface health. *Toxicology* 2014;320:1–5.

Allison Moy
School of Optometry
University of California
Berkeley, CA 94720
e-mail: amoy@berkeley.edu