

UCLA

UCLA Previously Published Works

Title

Association Between CT Angiogram Collaterals and CT Perfusion in the Interventional Management of Stroke III Trial

Permalink

<https://escholarship.org/uc/item/4051f04z>

Journal

Stroke, 47(2)

ISSN

0039-2499

Authors

Vagal, Achala
Menon, Bijoy K
Foster, Lydia D
[et al.](#)

Publication Date

2016-02-01

DOI

10.1161/strokeaha.115.011461

Peer reviewed



Published in final edited form as:

Stroke. 2016 February ; 47(2): 535–538. doi:10.1161/STROKEAHA.115.011461.

Association between CT angiogram collaterals and CT perfusion in the Interventional Management of Stroke (IMS) III Trial

Achala Vagal, MD, MS, Bijoy K. Menon, MD, Lydia D. Foster, MS, Anthony Livorine, MD, Sharon D. Yeatts, PhD, Emmad Qazi, B.S, Chris d’Esterre, PhD, Junzi Shi, MD, Andrew M. Demchuk, MD, Michael D. Hill, MD, MSc, David S. Liebeskind, MD, Thomas Tomsick, MD, and Mayank Goyal, MD

Departments of Radiology (A.V, A.L, J.S, T.T) University of Cincinnati Medical Center, Cincinnati, OH; Department of Public Health Sciences, Medical University of South Carolina, Charleston, SC (L.F, S.Y); Department of Neurology, UCLA Medical Center, Los Angeles, CA (D.L); Department of Clinical Neurosciences (A.D, M.H), Department of Radiology (B.M, E.Q, C.D, M.G, A.D., M.H.), Department of Community Health Sciences (M.H., B.M), Department of Medicine (M.H.), University of Calgary, Alberta, Canada

Abstract

Background and Purpose—Collateral flow can determine ischemic core and tissue at risk.

Using the Interventional Management of Stroke (IMS) III Trial data, we explored the relationship between CT angiogram (CTA) collateral status and CT perfusion (CTP) parameters.

Methods—Baseline CTA collaterals were trichotomized as good, intermediate and poor and CTP studies were analyzed to quantify ischemic core, tissue at risk and mismatch ratios. Kruskal-Wallis and Spearman tests were used to measure the strength of association and correlation between CTA collaterals and CTP parameters.

Results—A total of 95 patients had diagnostic CTP studies in the IMS III trial. Of these, 53 patients had M1/M2 middle cerebral artery ± intracranial internal carotid artery occlusion, where baseline CTA collateral grading was performed. CTA collaterals were associated with smaller CTP measured ischemic core volume ($p=0.0078$) and higher mismatch ($p=0.0004$). There was moderate negative correlation between collaterals and core ($r_s = -0.45$, 95% CI $(-0.64, -0.20)$) and moderate positive correlation between collaterals and mismatch ($r_s = 0.53$, 95% CI $(0.29, 0.71)$).

Corresponding Author: Achala Vagal, MD, MS, University of Cincinnati Medical Center, 234 Goodman Street, Cincinnati, OH-45267, Phone: 513-5851584, Achala.Vagal@uchealth.com.

Disclosures:

A.V: CTSA 8 UL1 TR000077-05 KL2 Grant, Imaging Core Lab, Study of the Efficacy and Safety of Alteplase in Patients With Mild Stroke (PRISMS) Trial, Genentech, Inc.

BKM: Grant support from Canadian Institutes of Health Research (CIHR) and Heart and Stroke Foundation of Canada.

S.D.Y: NIH/National Institute of Neurological Disorders and Stroke (NINDS) U01 NS052220, Consultant, Genentech Inc.

D.L: Research grant NIH/NINDS

A.D: Speaker’s Bureau, Medtronic CME events (Modest)

M.G: Research grant from Covidien AG (Medtronic) for design and conduct of Solitaire with the Intention for Thrombectomy as Primary Endovascular Treatment (SWIFT PRIME) trial, Speaker’s Bureau, Covidien (Significant)

MDH: Research grant from Covidien AG (Medtronic) to the University of Calgary for partial funding of the Endovascular Treatment for Small Core and Anterior Circulation Proximal Occlusion with Emphasis on Minimizing CT to Recanalization Times (ESCAPE) trial (Significant), Ownership interest, Calgary Scientific Inc, Imaging company (Significant).

Other authors report no disclosures

Conclusion—Better collaterals were associated with smaller ischemic core and higher mismatch in the IMS III trial. Collateral assessment and perfusion imaging identify the same biological construct regarding ischemic tissue sustenance.

Keywords

collateral circulation; computed tomography angiography; perfusion imaging

Introduction

Each of the recent positive endovascular trials in acute ischemic stroke used a slightly different imaging paradigm for patient selection with a common goal to identify patients with proximal vessel occlusion and a small ischemic core. A non-contrast head CT ASPECTS score was utilized to evaluate the ischemic core; this was supplemented by CT angiogram (CTA) collateral assessment in ESCAPE¹ or CT perfusion (CTP) core measurement in EXTEND IA² and SWIFT-PRIME³ trials. Collaterals can influence the rate of infarct growth and perfusion may give indirect information regarding this downstream collateral sustenance of ischemic tissue, although the relationship between collaterals and perfusion is uncertain.

Our objective was to explore the relationship between CTA collaterals and perfusion parameters in a cohort of patients with baseline CTA and CTP in the Interventional Management of Stroke (IMS) III trial. We hypothesized that better collaterals are associated with smaller ischemic cores and larger mismatch, reflecting compensation from the collateral network preserving blood flow in the setting of acute ischemia.

Methods

Study population

IMS III was a phase 3, randomized, open label trial of endovascular treatment after intravenous t-PA versus intravenous t-PA alone.⁴ Although not a prerequisite for inclusion, CTA and CTP was performed in a subset of enrolled subjects, depending on the enrolling center's standard of care imaging.

CTP analysis

All CTPs were post processed using commercially available software (Olea Medical 2.3) using oscillatory index-regularized block circular, delay-insensitive algorithms. A semiautomated processing was utilized where all steps including motion correction, smoothing and evaluation of time density curves, arterial and venous input were checked for errors. Tissue at risk of infarction was defined by Tmax >6 seconds and ischemic core was defined by a dual threshold (relative cerebral blood flow (CBF) <30% to the mean of contralateral hemisphere and Tmax > 6 sec).⁵ Using these thresholds, automated volumes of tissue at risk, ischemic core, and mismatch ratios were generated.

CTA collateral grading

Collateral circulation in baseline CTA was measured only in patients with proximal vessel occlusion (middle cerebral artery M1/M2 ± intracranial internal carotid occlusion) because assessment of backfilling pial arteries in distal occlusions using single phase CTA is technically difficult.⁶ Due to significant topographical variability in CTA⁷, the collaterals were divided into two groups; namely anterior cerebral artery– middle cerebral artery (ACA-MCA) and posterior cerebral artery-middle cerebral artery (PCA-MCA). The pial artery grading in each group used a 6-point scale (0-absent, 1-minimal, 2-significantly decreased prominence and extent with regions of no vessels, 3-moderately decreased prominence and extent, 4-mildly decreased prominence and extent, 5-normal or increased prominence and extent) when compared with the opposite normal hemisphere.⁶ Total CTA collateral score, calculated by summing the two regional scores, ranged from 0 to 10.

Statistical analysis

Collateral status was trichotomized as good (8–10), intermediate (6–7), and poor (0–5).⁶ Association of collateral status with CTP parameters was assessed using the Kruskal-Wallis test; if significant at alpha 0.05, pairwise tests were conducted to identify differences. Spearman correlation was used to measure strength of association between CTA collateral score (using total score of 0–10) and CTP parameters.

Results

Subject characteristics

Of 656 subjects enrolled in IMS III, 104 patients had a CTP at baseline. Of these, 9 were excluded due to non-diagnostic CTP. Of the remaining 95 subjects, 85 (89.5%) had a concurrent baseline CTA, and 53/85 (62.4%) patients had M1/M2 MCA ± intracranial ICA occlusion where collateral status was measured (Table 1).

CTA collaterals and CTP

Subjects with good CTA collaterals had smaller CTP measured ischemic cores and larger mismatch than subjects with poor collaterals. (Table 2, Figure 1) There was a moderate negative correlation between collaterals and core volume ($r_s = -0.45$, 95% CI $(-0.64, -0.20)$) and moderate positive correlation between collaterals and mismatch ($r_s = 0.53$, 95% CI $(0.29, 0.71)$). There was insufficient evidence to conclude an association and correlation between collaterals and tissue at risk ($p=0.4484$ and $r_s = -0.14$, 95% CI $(-0.40, 0.12)$) respectively. Pairwise testing for ischemic core did not show a significant difference between good and intermediate ($p=0.3950$) or between intermediate and poor collateral grade ($p=0.0728$).

Discussion

We found that, among patients with M1/M2 ± ICA occlusions, better collaterals are associated with smaller ischemic cores and greater mismatch. The CTA collaterals correlated moderately well with CTP measured core with an inverse relation. The strength of our study is that we have demonstrated association between CTA collateral status and CTP parameters in a randomized trial setting.

It is well established that patients with better collaterals have smaller infarcts and better functional outcomes.^{6, 8, 9} Using this premise, the recent ESCAPE trial utilized collateral assessment using multiphase CTA for patient selection without additional CTP acquisition.¹ Although the EXTEND IA² and SWIFT PRIME³ trials used CTP for patient selection utilizing automated software for CTP processing, it is important to note that there are numerous challenges for CTP imaging when performed outside of a well controlled trial environment. These include variability in CTP acquisition and post processing methodology as well as controversy regarding readiness of CTP for prime time usage.¹⁰

Since the positive endovascular trials, baseline CTA has become standard of care for acute stroke workup. Although, concurrent assessment of collateral status is relatively straightforward and can provide a good estimate of ischemic core, CTA collateral evaluation is a relatively new imaging tool with heterogeneity in CTA acquisition and collateral grading. Our study suggests that collaterals and perfusion are measuring similar aspects of the ischemic pathophysiology. This finding is clinically relevant as CTA collateral assessment may be an alternative for CTP, potentially obviating the need for an additional CTP study.

Our study adds to the accumulating body of evidence related to association of collaterals and perfusion in acute ischemic stroke. A malignant CTA collateral profile, specific for large core volume on baseline MR diffusion study correlated with poor outcomes.¹¹ Better collateral flow measured by MR perfusion was associated with larger diffusion-perfusion mismatch and smaller baseline DWI lesion volume.¹² On the other hand, Bang et al¹³ found no difference in the MR mismatch depending on the angiographic collateral grade, but did show that patients with good collaterals had larger areas of milder perfusion delay than those with poor collaterals. Similarly, Marks et al¹⁴ showed a relationship between angiographic collaterals and severity of MR perfusion deficit but did not show an association between collaterals and DWI core and mismatch. A key explanation for the conflicting findings is the fact that angiographic collaterals were utilized in these studies, which may not necessarily quantify PCA MCA collaterals.

Our study limitations include those inherent in a post hoc analysis along with a small sample size. Another important limitation is that the IMS III Trial was a multi-institutional trial with significant heterogeneity in the CTP acquisition technique, although this resembles real world circumstances. Although CTP techniques have evolved during and beyond the trial period (2006–2012), a large proportion of subjects (86%) had CTP brain coverage of less than 4 cm, and 95% subjects had less than 90 second duration of CTP acquisition. The CTA studies obtained were all single-phase acquisitions, which is dependent on bolus characteristics and can underestimate collateral status as compared to the newer multiphase CTA techniques.

Conclusions

Better collaterals were associated with smaller ischemic core and higher mismatch in the IMS III trial. CTA collateral assessment and perfusion imaging identify the same biological construct regarding ischemic tissue sustenance.

Acknowledgments

Sources of funding: None

References

1. Goyal M, Demchuk AM, Menon BK, Eesa M, Rempel JL, Thornton J, et al. Randomized assessment of rapid endovascular treatment of ischemic stroke. *The New England journal of medicine*. 2015; 372:1019–1030. [PubMed: 25671798]
2. Campbell BC, Mitchell PJ, Kleinig TJ, Dewey HM, Churilov L, Yassi N, et al. Endovascular therapy for ischemic stroke with perfusion-imaging selection. *The New England journal of medicine*. 2015; 372:1009–1018. [PubMed: 25671797]
3. Saver JL, Goyal M, Bonafe A, Diener HC, Levy EI, Pereira VM, et al. Stent-retriever thrombectomy after intravenous t-pa vs. T-pa alone in stroke. *The New England journal of medicine*. 2015; 372:2285–2295. [PubMed: 25882376]
4. Broderick JP, Palesch YY, Demchuk AM, Yeatts SD, Khatri P, Hill MD, et al. Endovascular therapy after intravenous t-pa versus t-pa alone for stroke. *The New England journal of medicine*. 2013; 368:893–903. [PubMed: 23390923]
5. Campbell BC, Christensen S, Levi CR, Desmond PM, Donnan GA, Davis SM, et al. Cerebral blood flow is the optimal ct perfusion parameter for assessing infarct core. *Stroke*. 2011; 42:3435–3440. [PubMed: 21980202]
6. Menon BK, Qazi E, Nambiar V, Foster LD, Yeatts SD, Liebeskind D, et al. Differential effect of baseline computed tomographic angiography collaterals on clinical outcome in patients enrolled in the interventional management of stroke III trial. *Stroke*. 2015; 46:1239–1244. [PubMed: 25791716]
7. Menon BK, O'Brien B, Bivard A, Spratt NJ, Demchuk AM, Miteff F, et al. Assessment of leptomeningeal collaterals using dynamic ct angiography in patients with acute ischemic stroke. *Journal of cerebral blood flow and metabolism: official journal of the International Society of Cerebral Blood Flow and Metabolism*. 2013; 33:365–371.
8. Lima FO, Furie KL, Silva GS, Lev MH, Camargo EC, Singhal AB, et al. The pattern of leptomeningeal collaterals on ct angiography is a strong predictor of long-term functional outcome in stroke patients with large vessel intracranial occlusion. *Stroke*. 2010; 41:2316–2322. [PubMed: 20829514]
9. Tan IY, Demchuk AM, Hopyan J, Zhang L, Gladstone D, Wong K, et al. Ct angiography clot burden score and collateral score: Correlation with clinical and radiologic outcomes in acute middle cerebral artery infarct. *AJNR. American journal of neuroradiology*. 2009; 30:525–531. [PubMed: 19147716]
10. Liebeskind DS, Parsons MW, Wintermark M, Selim M, Molina CA, Lev MH, et al. Computed tomography perfusion in acute ischemic stroke: Is it ready for prime time? *Stroke*. 2015; 46:2364–2367. [PubMed: 26159791]
11. Souza LC, Yoo AJ, Chaudhry ZA, Payabvash S, Kemmling A, Schaefer PW, et al. Malignant cta collateral profile is highly specific for large admission dwi infarct core and poor outcome in acute stroke. *AJNR. American journal of neuroradiology*. 2012; 33:1331–1336. [PubMed: 22383238]
12. Campbell BC, Christensen S, Tress BM, Churilov L, Desmond PM, Parsons MW, et al. Failure of collateral blood flow is associated with infarct growth in ischemic stroke. *Journal of cerebral blood flow and metabolism: official journal of the International Society of Cerebral Blood Flow and Metabolism*. 2013; 33:1168–1172.
13. Bang OY, Saver JL, Buck BH, Alger JR, Starkman S, Ovbiagele B, et al. Impact of collateral flow on tissue fate in acute ischaemic stroke. *Journal of neurology, neurosurgery, and psychiatry*. 2008; 79:625–629.
14. Marks MP, Lansberg MG, Mlynash M, Olivot JM, Straka M, Kemp S, et al. Effect of collateral blood flow on patients undergoing endovascular therapy for acute ischemic stroke. *Stroke*. 2014; 45:1035–1039. [PubMed: 24569816]

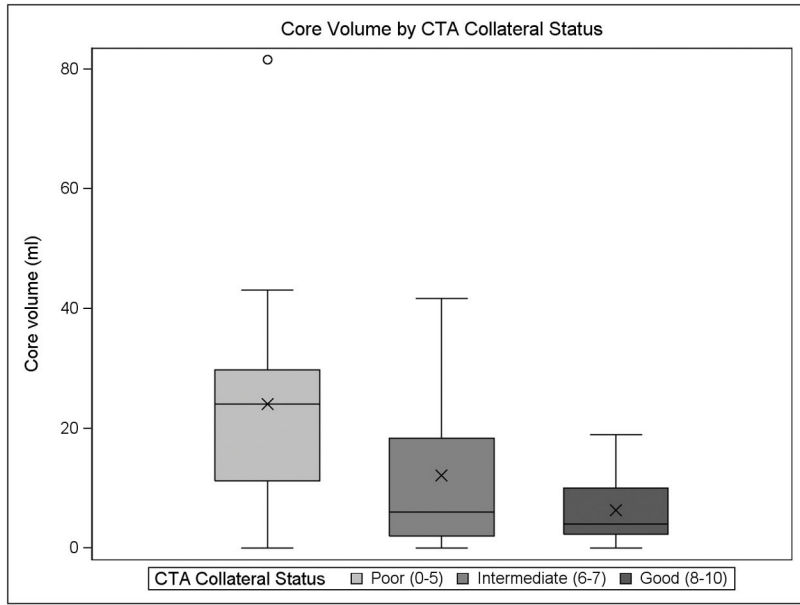


Figure 1. Boxplot of CTA collateral status and CTP ischemic core volume

Author Manuscript

Author Manuscript

Author Manuscript

Author Manuscript

Table 1

Subject characteristics

Variables	Total n =53
Age, y, median (min-max)	69 (33–83)
Male, n (%)	27 (50.9%)
NIHSS ^I , median (min-max)	18 (7–40)
ASPECTS, n (%)	
0 – 5	16 (30.2%)
6 – 10	37 (69.8%)
Core Volume, cc, median (min-max)	8.3 (0.0–81.6)
Hypoperfused Volume, cc, median (min-max)	70.6 (2.1–383.4)
Mismatch Ratio	4.9 (1.0–371.5)
Vessel occlusion	
ICAT	13 (24.5%)
M1	37 (69.8%)
M2	3 (5.7%)
Randomized to Endovascular therapy, n (%)	35 (66.0%)
CTA Collateral Status, n (%)	
Good (8–10)	21 (39.6%)
Intermediate (6–7)	15 (28.3%)
Poor (0–5)	17 (32.1%)

^I Subject missing (n=1)

Author Manuscript

Author Manuscript

Author Manuscript

Author Manuscript

Table 2

Associations between CTA collateral grade and CTP parameters

	CTA Collateral Status			
	Good (n=21)	Intermediate (n=15)	Poor (n=17)	P-value
Core volume (cc), median (min-max)	4.0 (0.0–19.0)	6.0 (0.0–41.7)	24.1 (0.0–81.6)	0.0078
Hypoperfused volumes (cc), median (min-max)	60.3 (2.1–197.5)	80.5 (8.4–248.7)	84.5 (7.2–383.4)	0.4484
Mismatch ratio, median (min-max)	12.4 (1.7–371.5)	8.0 (1.0–314.2)	2.8 (1.1–8.4)	0.0004

Author Manuscript

Author Manuscript

Author Manuscript

Author Manuscript