

# UC Davis

## Dermatology Online Journal

### Title

Acquired trichorrhexis nodosa: how to diagnose it?

### Permalink

<https://escholarship.org/uc/item/3zw9c8zt>

### Journal

Dermatology Online Journal, 24(11)

### Authors

Turra, Nelson  
Navarrete, Jorge  
Magliano, Julio  
et al.

### Publication Date

2018

### DOI

10.5070/D32411042012

### Copyright Information

Copyright 2018 by the author(s). This work is made available under the terms of a Creative Commons Attribution-NonCommercial-NoDerivatives License, available at <https://creativecommons.org/licenses/by-nc-nd/4.0/>

Peer reviewed

# Acquired trichorrhexis nodosa: how to diagnose it?

Nelson Turra<sup>1</sup>, Jorge Navarrete<sup>1</sup>, Julio Magliano<sup>1</sup>, Carlos Bazzano<sup>1</sup>

Affiliations: <sup>1</sup>Cátedra de Dermatología, Hospital de Clínicas, Dr. Manuel Quintela, Montevideo, Uruguay

Corresponding Author: Nelson Turra, Avenida Italia N/N, Montevideo, Uruguay, Tel: 598-91419695, Email: [nelsonturra85@gmail.com](mailto:nelsonturra85@gmail.com)

## Abstract

Acquired trichorrhexis nodosa is an uncommon hair disorder, defined as a cuticle response to extrinsic or environmental insults, such as certain chemical agents. In the following report, we present a clinical case of acquired trichorrhexis nodosa and make a critical comparison by trichoscopy, optical microscopy, and scanning electron microscopy. Some diagnostic tools can provide high quality information, but their high cost and low access make them an inconvenient option. When comparing the cost-benefit ratio of each one, we conclude that acquired trichorrhexis nodosa can be easily diagnosed with a careful clinical history and examination using a dermatoscope with non-polarized light.

*Keywords: trichorrhexis nodosa syndrome, dermoscopy, microscopy, scanning electron microscopy.*

## Introduction

Acquired trichorrhexis nodosa is an uncommon hair disorder, defined as a cuticle response to extrinsic or environmental insults, which causes hair breakage [1]. Frequently, it is the result of the irritant effects of certain chemical agents applied topically on the hair [2]. Clinically, it is characterized by dry and brittle hair, with the presence of tiny whitish nodes along the hair shaft [1]. These nodes are related to loss of cuticle along with split cortical fibers [3]. Many times, acquired trichorrhexis nodosa represents a great diagnostic challenge, which is why multiple diagnostic tools have been proposed for its recognition [4-6]. In the following report, we present a clinical case of acquired trichorrhexis nodosa and make a critical comparison by trichoscopy, optical microscopy, and scanning electron microscopy.

## Case Synopsis

An 18-year-old man, with no relevant medical history, attended our hospital with a three-month history of increased hair fragility and multiple tiny whitish nodules, mainly in the distal segment of the hair of the temporal regions (**Figure 1**). There was no evidence of any underlying skin disorder. The patient reported washing his hair several times a day and using various cosmetic products for topical application. Trichoscopy using a dermatoscope with non-polarized light and a magnification of 10x, showed multiple whitish nodules in the distal part of the hairs (**Figure 2**). The diagnosis of acquired trichorrhexis nodosa was established and suspension of chemical irritants was recommended. For academic purposes, some hairs were extracted for complementary examinations. Trichoscopy using videodermoscopy was performed (non-polarized mode, 70x magnification), showing the presence of broken hair shafts in the affected areas (**Figure 3**). Optical microscopy (40x magnification), showed the characteristic image of two paint brushes thrust together, in the affected areas (**Figure 4**). Scanning electron microscopy (390x magnification), showed



**Figure 1.** Acquired trichorrhexis nodosa, clinical presentation. Multiple small whitish nodules in the hair stems.



**Figure 2.** Acquired trichorrhexis nodosa, trichoscopy. Multiple whitish nodules in the hair stems are evident. (Non-polarized mode, 10 $\times$ ).




**Figure 3.** Acquired trichorrhexis nodosa, trichoscopy with videodermoscopy. Broken hair stems in multiple foci are evident. (Non-polarized mode, 70 $\times$ ; FotoFinder<sup>®</sup>).

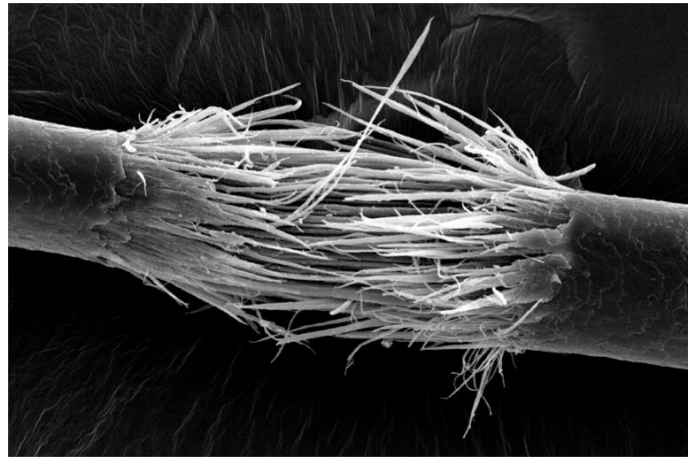
in great detail the loss of cuticle along with frayed cortical fibers, a characteristic image that mimics two brushes crushed and opposing each other (**Figure 5**). The diagnosis of acquired trichorrhexis nodosa was reaffirmed by the good clinical response after a two month avoidance of topical irritants on his hair.

### Case Discussion

Multiple diagnostic tools for acquired trichorrhexis nodosa have been described, but few studies compare the cost-benefit ratio of each one. Trichoscopy is a cheap and accessible tool, which can provide valuable information for the diagnosis. Although the damage of the hair shafts can also be seen with polarized light [7], the use of non-polarized light allows us to differentiate acquired trichorrhexis



**Figure 4.** Acquired trichorrhexis nodosa, optical microscopy. Splitting of the hair shaft in the affected areas is appreciated. (40 $\times$ ).



**Figure 5.** Acquired trichorrhexis nodosa, scanning electron microscopy. Image similar to two brushes crushed and opposing each other. (390 $\times$ ).

nodosa from other conditions, such as trichothiodystrophy, in which the transmission of polarized light through the birefringent hair structure creates the optical effect of “tiger tail banding,” a phenomenon which is not possible to appreciate with non-polarized light [8]. Also, trichoscopy can be optimized with the support of videodermoscopy. However, its low access makes it an unfeasible option. Optical microscopy can be very a useful tool, but it is not always available, nor is scanning electron microscopy, which could be cataloged as the “gold standard” for the diagnosis of acquired trichorrhexis nodosa. However, it is very expensive and requires an extensive preparation process in which the hair has to be covered by a gold-palladium alloy to improve the resolution and contrast [9].

## Conclusion

Acquired trichorrhexis nodosa can be easily diagnosed with a careful clinical history and with the support of a dermatoscope with non-polarized light.

Additionally, other tools can provide useful complementary information, but their low access, difficult processing, and high costs do not justify their use.

## References

1. Martínez Z, González M, Díaz J. Trichorrhexis nodosa localizada. *Actas Dermosifiliogr.* 2009;100:522-524. [PMID: 19709565].
2. Haskin A, Kwatra S, Aguh C. Breaking the cycle of hair breakage: pearls for the management of acquired trichorrhexis nodosa. *J Dermatolog Treat.* 2017;28:322-326. [PMID: 27718775].
3. Kharkar V, Gutte R, Thakkar V, Khopkar U. Trichorrhexis nodosa with nail dystrophy: diagnosis by dermoscopy. *Int J Trichology.* 2011;3(2):105-106. [PMID: 22223972].
4. Miyamoto M, Tsuboi R, Oh-I T. Case of acquired trichorrhexis nodosa : Scanning electron microscopic observation. *J Dermatol.* 2009;36:109-110. [PMID: 19284457].
5. Swapnil S, Balachandra S. Trichoscopy of an isolated trichorrhexis nodosa: a case report. *Indian Dermatol Online J.* 2017;8:386-387. [PMID: 28979886].
6. Dandale A, Shanshanwal S, Wankhede P, Dhurat R. Trichorrhexis nodosa due to repetitive trivial trauma. *Indian J Dermatol Venereol Leprol.* 2017;83:683. [PMID: 28656909].
7. Smith VV, Anderson G, Malone M, Sebire NJ. Light microscopic examination of scalp hair samples as an aid in the diagnosis of paediatric disorders: retrospective review of more than 300 cases from a single centre. *J Clin Pathol.* 2005;58:1294-8. [PMID: 16311350].
8. Yang YW, Yarbrough K, Mitkov M, Russi D, Price HN, Swanson DL. Polarized transilluminating dermoscopy: Bedside trichoscopic diagnosis of trichothiodystrophy. *Pediatr Dermatol.* 2018;35(1):147-149. [PMID: 28944975].
9. Fourie JT. Gold in electron microscopy. *Gold Bul.* 1982;15(1):2-6. <https://doi.org/10.1007/BF03216564>