

UC Irvine

Western Journal of Emergency Medicine: Integrating Emergency Care with Population Health

Title

Images in Emergency Medicine : Lisfranc Fracture-Dislocation

Permalink

<https://escholarship.org/uc/item/3z46j3vn>

Journal

Western Journal of Emergency Medicine: Integrating Emergency Care with Population Health, 9(1)

ISSN

1936-900X

Authors

Schofer, Joel M
O'Brien, Sean

Publication Date

2008

Copyright Information

Copyright 2008 by the author(s). All rights reserved unless otherwise indicated. Contact the author(s) for any necessary permissions. Learn more at <https://escholarship.org/terms>

Peer reviewed

Images in Emergency Medicine : Lisfranc Fracture-Dislocation

Joel M. Schofer, MD
Sean O'Brien, MD

Department of Emergency Medicine, Naval Hospital Okinawa

Submission history: Submitted September 21, 2007; Accepted November 2, 2007.
Reprints available through open access at www.westjem.org
[WestJEM. 2008;9:56-57.]

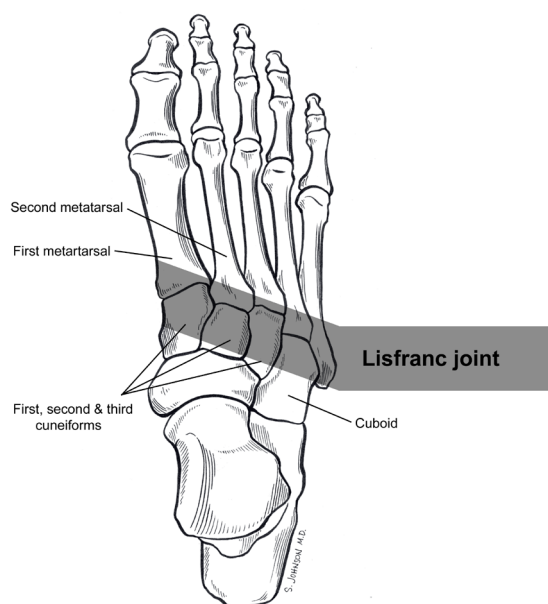
The views expressed in this article are those of the authors and do not reflect the official policy or position of the Department of the Navy, Department of Defense, or the United States Government.

Patient Presentation

A 22-year-old intoxicated male presented to the emergency department after jumping from a second-story window, landing on his right foot. He was able to ambulate with a great deal of pain across the dorsum of his foot. Physical examination revealed significant tenderness to palpation over the second metatarsal with minimal edema.

Final Diagnosis/Relevant Teaching Points

Radiographs of the foot reveal a fracture-dislocation of the tarsometatarsal or Lisfranc joint. A diastasis between the proximal 1st and 2nd metatarsals is seen and indicates an unstable injury (Figures 1 & 2). A bone fragment is present



With thanks to Sonia Johnson, MD for her illustration of the Lisfranc joint.

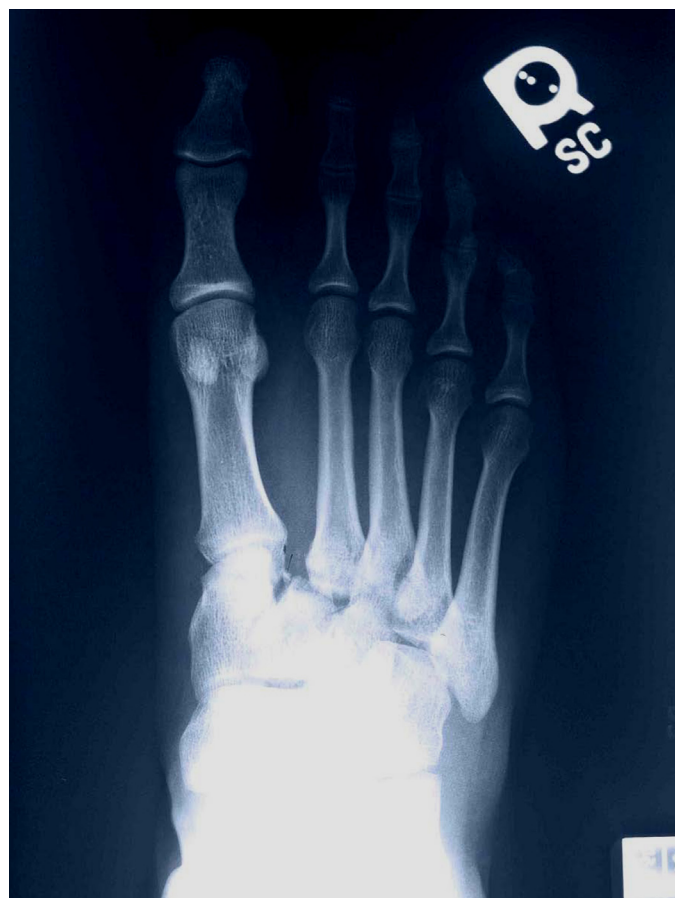

Figure 1.

in this area due to an avulsion of the Lisfranc ligament. In addition, the lateral edge of the medial cuneiform does not align with the lateral aspect of the first metatarsal. This malalignment can be the only indication of injuries to the Lisfranc joint in more subtle presentations, which can easily be missed.

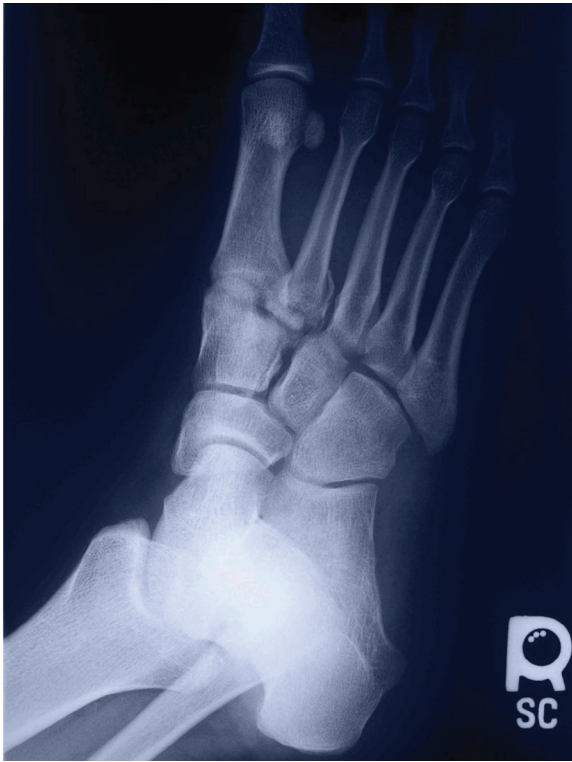

Figure 2.

Lisfranc fracture-dislocations are uncommon, but should be suspected in high-energy injuries, such as motor vehicle collisions and falls, as well as sports involving fixation of the forefoot (horseback riding, windsurfing). They can be caused by lower energy mechanisms, such as trips and falls.¹ Any suspected Lisfranc fracture-dislocation requires orthopedic consultation as the treatment requires operative fixation.

Address for correspondence: Joel M. Schofer, MD.
Department of Emergency Medicine, Naval Hospital Okinawa,
PSC 482 Box 2827, FPO, AP 96362
Email: jschofer@gmail.com

REFERENCES

1. Ho K, Abu-Laban RB. Ankle and foot. In: Marx JA, ed. *Rosen's Emergency Medicine: Concepts and Clinical Practice*. 6th ed. Philadelphia PA: Mosby Elsevier; 2006:828-829.