

UC Davis

Dermatology Online Journal

Title

Interstitial granulomatous dermatitis in a patient with chronic hepatitis C and mixed cryoglobulinemia

Permalink

<https://escholarship.org/uc/item/3x33s9m7>

Journal

Dermatology Online Journal, 24(1)

Authors

Rato, M
Gil, F
Monteiro, AF
[et al.](#)

Publication Date

2018

DOI

10.5070/D3241037965

Copyright Information

Copyright 2018 by the author(s). This work is made available under the terms of a Creative Commons Attribution-NonCommercial-NoDerivatives License, available at <https://creativecommons.org/licenses/by-nc-nd/4.0/>

Peer reviewed

Interstitial granulomatous dermatitis in a patient with chronic hepatitis C and mixed cryoglobulinemia

M Rato, F Gil, AF Monteiro, J Aranha, E Tavares

Affiliations: Dermatology Department of Hospital de Santarém EPE, Santarém, Portugal

Corresponding Author: Margarida Rato, Hospital de Santarém EPE, Dermatology Department, Avenida Bernardo Santarém, 2005-177 Santarém – Portugal, Email: margaridagiorato@gmail.com

Abstract

A 55-year-old man presented with a history of asymptomatic, bilateral, figurate dermatosis consisting of erythematous, annular, linear, and arciform, indurated nodules and plaques on the lateral walls of thorax, flanks, and hypogastrium. His medical history was positive for chronic hepatitis C. Skin biopsy was compatible with the diagnosis of interstitial granulomatous dermatitis. Additional investigation revealed positive rheumatoid factor, antinuclear antibodies, and cryoglobulins. The patient started treatment with high-potency topical corticosteroid. After 12 weeks of treatment there was a partial clinical improvement of the dermatosis. Interstitial granulomatous dermatitis exhibits a distinct histopathological pattern with a diverse clinical appearance, which can be associated with autoimmune systemic diseases, neoplasms, several drugs, and infections. Optimal therapy for this condition is yet to be established, but topical corticosteroids have been a mainstay of treatment.

Keywords: granulomatous dermatitis; interstitial granulomatous disease; hepatitis C; mixed cryoglobulinemia

Introduction

Interstitial granulomatous dermatitis (IGD) is a histologic inflammatory reaction, with variable cutaneous expression. It is an uncommon dermatosis that has been reported in association with autoimmune disorders (such as rheumatoid arthritis, systemic lupus erythematosus, thyroiditis, and vasculitis), lymphoproliferative diseases, solid organ cancer, systemically administered drugs (including antihypertensives, hypolipidemic

agents, anticonvulsants, antihistamines, and TNF blockers) and recently with infections (borreliosis, coccidioidomycosis) [1-15, 21, 22]. We report a case of IGD which occurred in a patient with chronic hepatitis C and mixed cryoglobulinemia

Case Synopsis

A 55-year-old man presented to our department with a three-month history of an asymptomatic, bilateral, figurate dermatosis consisting of erythematous, annular, linear, and arciform, sharply demarcated, indurated, non-scaly nodules and plaques on the lateral walls of thorax, flanks, and hypogastrium (**Figures 1, 2**). The patient denied any systemic complaints, including arthralgias. His medical history was positive for chronic hepatitis C (former injection drug user) with no follow-up for several years. He denied any drug intake. General physical examination revealed no contributing findings.

Skin biopsy showed a dense interstitial histiocytic infiltrate in superficial and deep dermis exhibiting large cells with clear cytoplasm. Multinucleated cells of foreign body and Touton types, some containing fiber fragments were noted. There were numerous eosinophils, forming some “flame figures” (**Figures 3, 4**). These findings were compatible with the diagnosis of IGD.

Additional investigations revealed elevation of transaminases (AST 48 U/L, range reference. 5-34; ALT 75 U/L, reference <55) and positive rheumatoid factor (53.7 UI/mL, reference <30), antinuclear antibodies (1:640) and cryoglobulins (type IIb cryoglobulinemia - oligoclonal IgG and IgM and polyclonal IgA). Other important tests were also done with negative/normal results including serology for HBV, HIV, *Treponema pallidum* and *Borrelia burgdorferi*, anti-

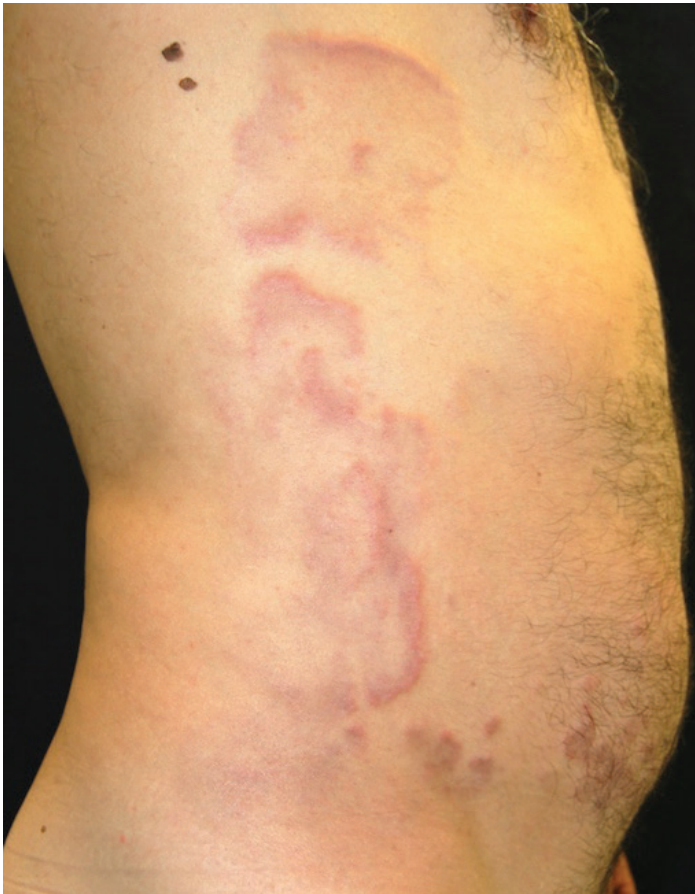

Figure 1: Lesions on the right wall of the trunk, right flank and hypogastrium.

cyclic citrullinated peptide antibody, anti-double stranded DNA, p-ANCA, c-ANCA, anti-SSA and SSB antibodies, complement C3 and C4, TSH, T4, anti-thyroid antibodies, alpha-fetoprotein, and abdominal ultrasound.

Our patient started treatment with topical betamethasone dipropionate (ointment) and was referred to an infectious disease specialist. After 12 weeks of treatment there was a partial clinical improvement of the dermatosis (**Figure 5**). After 12 months of follow-up patient exhibits only residual erythematous macules, with no relapses or systemic complaints.

Case Discussion

Interstitial granulomatous dermatitis was initially described by Ackerman et al. in 1993 [4]. It is an infrequent dermatosis, more common in women with a previous diagnosis of rheumatoid arthritis [5]. Although the original manifestation had been described as subcutaneous indurated linear cords along the lateral walls of the trunk, also known as

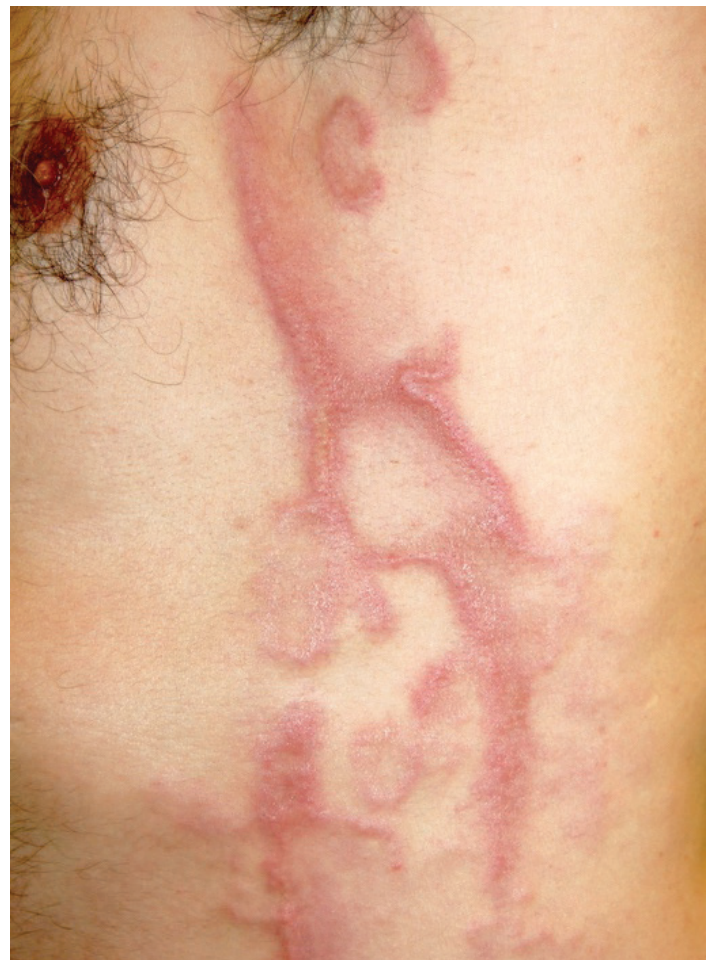

Figure 2: Lesions on the left wall of the thorax in detail.

the “rope sign” [4], later reports showed a clinical spectrum quite heterogeneous, as it may also manifest as patches, papules, nodules, plaques, or annular lesions, and at different body sites [6-9]. In fact, although considered the classical clinical manifestation of IGD, according to some authors cord-like lesions are present in only a minority of patients [10]. Lesions are usually asymptomatic, but can be slightly pruritic or painful [6]. Arthritis is also an inconsistent feature, which may occur prior to, simultaneously with, after the onset of the cutaneous lesions, or not at all [11-13]. This variety of clinical presentations makes the diagnosis difficult and so histological examination is essential for a correct diagnosis.

The typical microscopic presentation should be that of granulomatous dermatitis, with palisading or interstitial histiocytes, variable numbers of neutrophils and eosinophils, and scattered areas of degenerating collagen bundles [6, 10]. Histologically, the main condition in the differential diagnosis

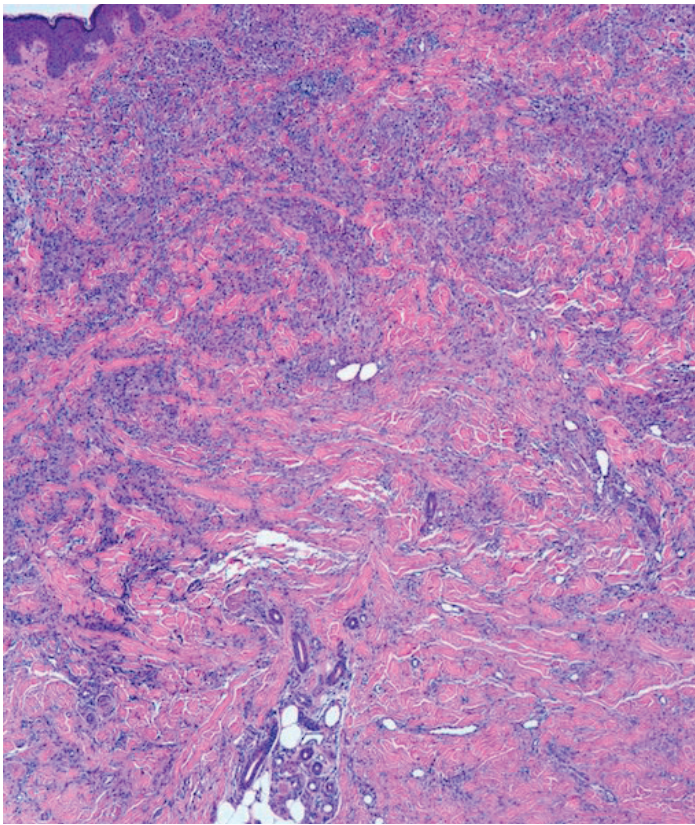


Figure 3: Dense interstitial histiocytic infiltrate occupying all the dermis. H&E, 40%.

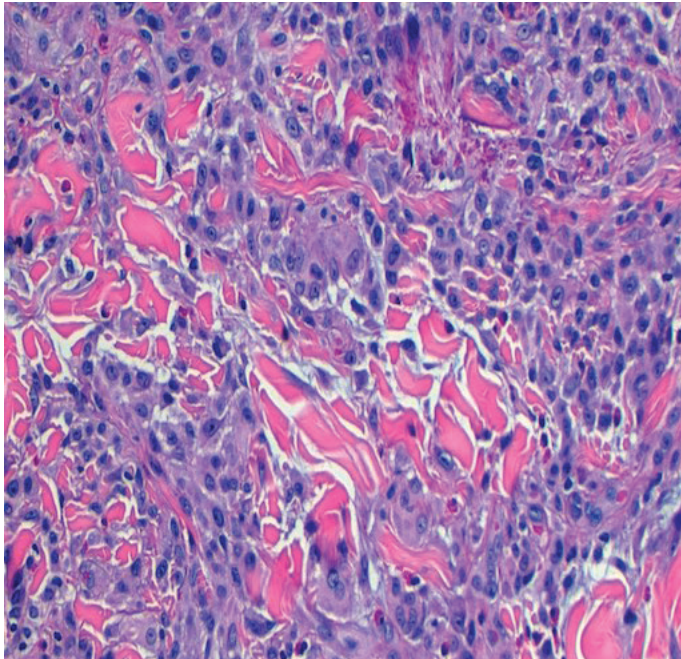


Figure 4: Detail of the infiltrate with multinucleated cells and numerous eosinophils with some "flame figures." H&E, 200%.

includes interstitial granuloma annulare, palisaded neutrophilic granulomatous dermatitis, drug-induced granulomatous dermatitis, histiocytoid Sweet syndrome and Churg-Strauss granulomatosis [2].

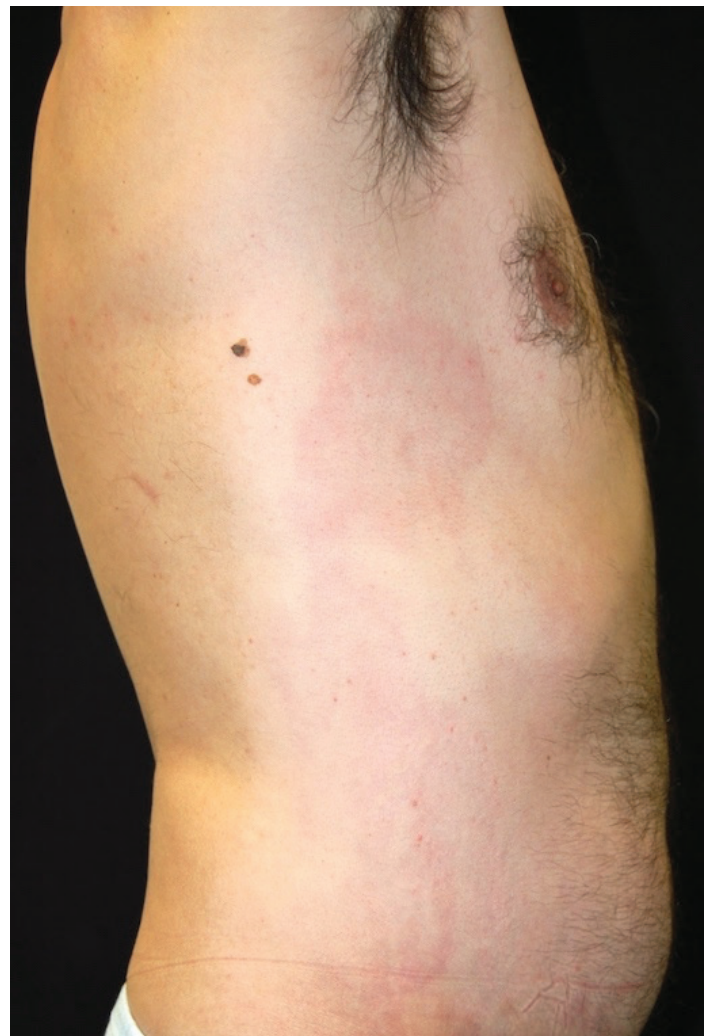


Figure 5: Lesions on the right wall of the trunk after 12 weeks of treatment.

The precise etiology of IGD remains unknown. However, the association with autoimmune diseases and vasculitis suggests a mechanism mediated by immune complexes [6, 14]. One hypothesis suggests that the deposition of immune complexes in the dermal vessels may be the trigger, which is then followed by complement and neutrophil activation and damage of dermal collagen, which in response gives rise to a granulomatous infiltrate [15].

Mixed cryoglobulinemia (MC) is a systemic vasculitis of small-to-medium sized vessels characterized by the presence of serum cryoglobulins, which precipitate at cold temperatures. Patients may be asymptomatic (MC, like the patient described) or have mixed cryoglobulinemia syndrome (MCS), [16]. This latter is characterized by a typical clinical triad (palpable purpura, arthralgias, and weakness), low C4 level, cutaneous leucocytoclastic vasculitis, and multiple

visceral organ involvement [17]. Dermatologically, patients most commonly have purpura, but pruritus, ulcers, livedo, and Raynaud phenomenon may be additional findings [16]. Mixed cryoglobulinemia and MCS are strongly associated with HCV. Serum cryoglobulins are found in approximately 30-40% of HCV patients, with 5 to 30% of these patients presenting with MCS [18-20]. The exact pathophysiology of this association is unknown, with both direct and indirect theories proposed. The direct theory, supported by evidence that HCV is lymphotropic and that the cryoprecipitate contains high concentrations of viral genome, proposes that HCV induces B cells to produce the immunoglobulins. Alternatively, the indirect theory proposes that the virus incites MC via chronic immune stimulation [16]. At this point, a possible association between the physiopathology of IGD and MC (and the role of both immune complexes) is interesting, but purely speculative.

Our patient also had positive ANA serology. According to a retrospective study performed by Peroni et al. [10], ANA were present in about 50% of patients with IGD at low (1:80-1:160) or medium-high titre (1:320 - 1:1280) without clear association with articular manifestations. Mixed cryoglobulins are also associated with rheumatoid factor activity, as is the case of the patient described. In patients with arthralgias or arthritis, finding the presence of rheumatoid factor activity may be confusing as it is positive in both classical rheumatoid arthritis and MCS. However, we should be aware of the main clinical, radiological and serological parameters that help to differentiate between arthritis complicating HCV infection and classical RA. In particular, HCV-related arthritis is non-erosive and seronegative (absence of anti-cyclic citrullinated peptide antibodies), [17].

The optimal therapy for IGD is still not well-defined. Topical corticosteroids appear to be only moderately effective, but are still a first line treatment, especially in patients with localized disease [6]. In the case of our patient, topical betamethasone dipropionate was capable of improving the lesions. Other treatment options reported in literature include systemic corticosteroids, antimalarials, cyclosporine, methotrexate, dapsone, cyclophosphamide, anti-tumor necrosis factor agents, or offending drug

withdrawal, with different degrees of success [13, 21, 22]. Spontaneous resolution and alternating periods of flares and remission may also occur, making the outcome of this dermatosis unpredictable [1, 6].

Conclusion

This is the first case to our knowledge in which IGD has been reported in a patient with chronic hepatitis C and MC. Once a diagnosis of IGD is made, it is mandatory to thoroughly screen the patient to exclude an associated condition (like autoimmune diseases, neoplasms, and infections) or a causative drug. Dermatologists should be aware of this condition as they may be likely to see the patient early because of the skin eruption.

References

1. Isis Suga Veronez, Fernando Luiz Dantas, Neusa Yuriko Valente, Priscila Kakizaki, Thaís Helena Yasuda, Thaís do Amaral Cunha. Interstitial granulomatous dermatitis: rare cutaneous manifestation of rheumatoid arthritis. *An Bras Dermatol.* 2015;90(3): 391–393. [PMID: 26131871].
2. Di Meo N, Stinco G, Trevisan G. Interstitial granulomatous dermatitis due to borreliosis. *Indian J Dermatol Venereol Leprol.* 2015;81(3):327. [PMID: 25851752].
3. Mangold AR, DiCaudo DJ, Blair JE, Sekulic A. Chronic interstitial granulomatous dermatitis in coccidioidomycosis. *Br J Dermatol.* 2016;174(4):881-884. [PMID: 26574343].
4. Ackerman AB, Guo Y, Vitale P, Vossaert K. Clues to diagnosis in dermatopathology. 3v. Chicago: ASCP Press; 1993. p.309-12.
5. Marmon S, Robinson M, Meehan SA, Franks AG Jr. Lupus-erythematosus associated interstitial granulomatous dermatitis. *Dermatol Online J.* 2012;18:31. [PMID: 23286821].
6. Antunes J, Pacheco D, Travassos AR, Soares-Almeida LM, Filipe P, Sacramento-Marques M. Autoimmune thyroiditis presenting as interstitial granulomatous dermatitis. *An Bras Dermatol.* 2012;87:748-51. [PMID: 23044569].
7. Marmon S, Robinson M, Meehan SA, Franks AG Jr. Lupus-erythematosus associated interstitial granulomatous dermatitis. *Dermatol Online J.* 2012;18:31 [PMID: 23286821].
8. Jabbari A, Cheung W, Kamino H, Soter NA. Interstitial granulomatous dermatitis with arthritis. *Dermatol Online J.* 2009;15:22. [PMID: 19891930].
9. Sayah A, English JC. Rheumatoid arthritis: A review of the cutaneous manifestations. *J Am Acad Dermatol.* 2005;53:191-209 [PMID: 16021111].
10. Peroni A, Colato C, Schena D, Gisondi P, Girolomoni G. Interstitial granulomatous dermatitis: a distinct entity with characteristic histological and clinical pattern. *Br J Dermatol.* 2012; 166(4):775-83. [PMID:22059717].
11. Deng A, Harvey V, Sina B, Strobel D, Badros A, Junkins-Hopkins JM, et al. Interstitial granulomatous dermatitis associated with the use of tumor necrosis factor alpha inhibitors. *Arch Dermatol.* 2006;142:198-202. [PMID: 16490847].
12. Swing DC Jr, Sheehan DJ, Sangüeza OP, Woodruff RW. Interstitial granulomatous dermatitis secondary to acute promyelocytic leukemia. *Am J Dermatopathol.* 2008;30:197-9. [PMID: 18360133].
13. Busquets-Pérez N, Narvaez J, Valverde-García J. Interstitial granulomatous dermatitis with arthritis (Ackerman syndrome). *J*

- Rheumatol.* 2006;33:1207-9. [PMID: 16755676].
14. Serra S, Monteiro P, Pires E, Vieira R, Telechea O, Inês L, et al. Relapsing polychondritis, interstitial granulomatous dermatitis and antiphospholipid syndrome: an unusual clinical association. *Acta Reumatol Port.* 2011;36:292-7. [PMID: 22113604].
 15. Chu P, Connolly MK, LeBoit PE. The histopathologic spectrum of palisaded neutrophilic and granulomatous dermatitis in patients with collagen vascular disease. *Arch Dermatol* 1994; 130: 1278-83 [PMID: 7944509].
 16. Wiznia LE, Laird ME, Franks AG Jr. Hepatitis C virus and its cutaneous manifestations: treatment in the direct-acting antiviral era. *J Eur Acad Dermatol Venereol.* 2017. [PMID: 28252812].
 17. Ferri C, Ramos-Casals M, Zignego AL, Arcaini L, Roccatello D, Antonelli A et al. International diagnostic guidelines for patients with HCV-related extrahepatic manifestations. A multidisciplinary expert statement. *Autoimmun Rev.* 2016 Dec;15(12):1145-1160 [PMID: 27640316].
 18. Cacoub P, Saadoun D. Hepatitis C virus infection induced vasculitis. *Clin Rev Allergy Immunol* 2008;35:30-9 [PMID: 18196478].
 19. Gagnani L, Fognani E, Piluso A, et al. Long-term effect of HCV eradication in patients with mixed cryoglobulinemia: a prospective, controlled, open-label, cohort study. *Hepatology* 2015;61:1145- 53. [PMID: 25431357].
 20. Frangeul L, Musset L, Cresta P, Cacoub P, Huraux JM, Lunel F. Hepatitis C virus genotypes and subtypes in patients with hepatitis C, with and without cryoglobulinemia. *J Hepatol* 1996;25:427-32. [PMID: 8912140].
 21. Felcht M, Faulhaber J, Göttmann U, Koenen W, Goerdt S, Goebeler M. Interstitial granulomatous dermatitis (Ackerman's syndrome). *Eur J Dermatol.* 2010;20:661-2 [PMID: 20627851].
 22. Dubey S, Merry P. Interstitial granulomatous dermatitis (Ackerman's syndrome) in SLE presenting with the 'rope sign'. *Rheumatology (Oxford).* 2007;46:80 [PMID: 16935918].