

**UCSF**

**UC San Francisco Previously Published Works**

**Title**

Chapter 28 Acute inflammatory myelopathies

**Permalink**

<https://escholarship.org/uc/item/3wk5v9h9>

**Author**

Cree, Bruce AC

**Publication Date**

2014

**DOI**

10.1016/b978-0-444-52001-2.00027-3

Peer reviewed

# Acute inflammatory myelopathies

BRUCE A.C. CREE\*

*Department of Neurology, University of California, San Francisco, USA*

## INTRODUCTION

Spinal cord inflammation can present with symptoms similar to those of compressive myelopathies: bilateral weakness and sensory changes below the spinal cord level of injury, often accompanied by bowel and bladder impairment and sparing cranial nerve and cerebral function. Because of the widespread availability of magnetic resonance imaging (MRI) and computed tomography (CT) imaging, compressive etiologies can be rapidly excluded, leading to the consideration of non-compressive etiologies for myelopathy. The differential diagnosis of non-compressive myelopathy is broad and includes infectious, parainfectious, toxic, nutritional, vascular, and systemic as well as idiopathic inflammatory etiologies (Table 28.1).

This review will focus on the idiopathic forms of spinal cord inflammation and their relationship to central nervous system (CNS) demyelinating diseases, systemic inflammatory or autoimmune disease, and as manifestations of paraneoplastic illness (Table 28.2). Although the pathoetiologies vary widely, the clinical presentations of these myelopathies are similar, therefore differentiating between these and other causes of non-compressive myelopathy can be challenging. In addition to the clinical presentation, imaging studies of the spinal cord and brain, spinal fluid analysis, and serological studies can help reveal a diagnosis in many cases.

Although controlled treatment trials have not been undertaken, the treatment strategy for acute myelitis uses high-dose corticosteroids in nearly all circumstances in an effort to reduce tissue injury caused by inflammation. In cases refractory to corticosteroid treatment, plasmapheresis is sometimes utilized to reduce the serum concentrations of autoantibodies presumed to damage the blood–spinal cord barrier or gray and white-matter spinal cord structure. The prognosis for recovery depends largely on the extent of spinal cord

injury caused by the acute inflammation and the likelihood of recurrence differs depending on the etiology. Additional important diagnostic and prognostic features include whether the myelitis is partial or transverse, febrile illness, the number of vertebral spinal cord segments involved on MRI at the time of acute attack, the rapidity from symptom onset to maximum deficit, and the severity of involvement.

## METHODOLOGIC CONSIDERATIONS

Large observational cohort studies or randomized controlled trials concerning myelitis have never been undertaken. Consequently, nearly the entire neurologic knowledge is based on case series and reports. As such, a review of the literature faces the methodologic challenge of not being able to systematically review all cases and case series. Therefore, unintentional biases are inherent in the selection and interpretation of case series. Despite this limitation, certain observations, particularly when made by more than one group of investigators, may be clinically useful for formulating a differential diagnosis and treatment plan. Potentially useful clinical and laboratory studies will be reviewed with citation of relevant case series. The primary literature consists exclusively of case reports for certain etiologies of myelitis. Because keyword indexing is not consistent for case reports, systematic review of all case reports for each pathoetiology is not practical. Therefore, only select case reports containing observations not found in case series are reviewed and cited.

## CLINICAL PRESENTATION AND DEFINITIONS

Recognition of these clinical syndromes localizes the lesion and helps with ordering appropriate imaging studies that can verify the anatomic lesion and provide

---

\*Correspondence to: Bruce A.C. Cree, M.D., Ph.D., M.C.R., Associate Professor of Clinical Neurology, Clinical Research Director, UCSF Multiple Sclerosis Center, 675 Nelson Rising Lane, Suite 221, San Francisco, CA 94158, USA. Tel: +1-415-514-2466, Fax: +1-415-514-2470, E-mail: bruce.cree@ucsf.edu

Table 28.1

## Differential diagnosis of non-inflammatory myelopathy

Traumatic/compressive	Toxic/metabolic
Trauma	Vitamin deficiency (B <sub>12</sub> , B <sub>1</sub> , E, folate)
Disc herniation	Nitrous oxide abuse
Cervical spondylosis with stenosis	Abetalipoproteinemia
Epidural abscess or hematoma	Medication-induced (amiodarone, methotrexate, amphotericin, etc.)
Extramedullary and extradural tumors	Organophosphates
Cyst (synovial or arachnoid)	Konzo (cassava ingestion)
Congenital spinal stenosis	Lathyrism (legume ingestion)
Posterior longitudinal ligament ossification	Heroin/hepatic myelopathy
Epidural lipomatosis	Fluorosis
Arnold–Chiari malformation	Clioquinol
Rheumatoid arthritis or ankylosing spondylitis-associated subluxation	Hashimoto’s encephalopathy
Osteomyelitis	<b>Neoplastic</b>
Paget disease	Lymphoma (primary CNS or metastatic)
Diffuse idiopathic skeletal hyperostosis	Leukemia
Extramedullary hematopoiesis	Glioma
<b>Hereditary/neurodegenerative</b>	<b>Vascular</b>
Hereditary spastic paraplegia (HSP)	Thromboembolic infarct
Friedreich’s ataxia	Arteriovenous fistula
Leukodystrophies	Fibrocartilaginous embolism
Motor neurone disease (ALS, PLS)	Hypoperfusion injury
Mitochondrial	Prothrombotic disorders (infection, neoplasm, vasculitis, DIC, etc.)
Krabbe’s disease	Arteriovenous malformation
<b>Other</b>	Decompression sickness (Caisson disease)
Syringomyelia	
Radiation myelopathy	
Superficial siderosis	
HIV vacuolar myelopathy	

ALS, amyotrophic lateral sclerosis; CNS, central nervous system; DIC, disseminated intravascular coagulation; HIV, human immunodeficiency virus; PLS, primary lateral sclerosis.

important clues as to pathoetiology. Although classic examples of non-compressive myelopathies are given for each spinal cord syndrome, in practice inflammation of different etiologies can present with any of these anatomic syndromes.

The term transverse myelitis is often used synonymously with any form of spinal cord inflammation; however, it more specifically refers to inflammation that involves both the anterior and posterior portion of the spinal cord, i.e., the inflammation is transverse from the anterior to posterior in the horizontal plane. As such, transverse myelitis typically presents with subacute bilateral limb weakness and sensory changes accompanied by bowel and bladder dysfunction without impairment of cranial nerve and cerebral function. Additional clinical features that help localize the area of injury include a spinal sensory level, diminished or absent reflexes at the level of the lesion, hyperreflexia below the level of the lesion, presence of respiratory compromise, and a

Lhermitte’s symptom. When transverse myelitis is bilateral and complete, all spinal cord tracts are involved, causing pyramidal, sensory, and autonomic dysfunction below the level of the lesion. Examples of etiologies that can cause complete transverse myelitis include neuro-myelitis optica (NMO), paraneoplastic myelopathies, and necrotizing infectious myelitis.

Transverse myelitis may also be unilateral, meaning the right or left side, as long as there is clinical involvement of both anterior and posterior cord function, i.e., motor weakness and sensory symptoms consistent with dorsal column injury, often with contralateral spinothalamic injury. This pattern is also known as the hemicord or Brown-Séquard syndrome (Brown-Séquard, 1849). In this setting, pyramidal weakness is accompanied by ipsilateral dorsal column dysfunction and contralateral spinothalamic loss. Bowel and bladder impairment often still occurs but may be less obvious than with bilateral, complete transverse myelitis. Although the classic

Table 28.2

## Differential diagnosis of acute transverse myelitis

<b>Demyelinating</b>	<b>Viral – Herpesviruses (DNA)</b>
<b>Multiple sclerosis</b>	<b>Herpes simplex virus type-2 (HSV)</b>
<b>Neuromyelitis optica</b>	<b>Varicella-zoster virus (VZV)</b>
<b>Idiopathic transverse myelitis</b>	<b>Cytomegalovirus (CMV)</b>
<b>Acute disseminated encephalomyelitis (ADEM)</b>	Human herpesvirus 6 and 7 (HHV)
Postvaccinial	Epstein–Barr virus (EBV)
Associated with acute demyelinating polyneuropathy	<b>Viral – Paramyxoviruses (RNA)</b>
<b>Systemic autoimmune disease</b>	Measles
<b>Systemic lupus erythmatosus (SLE)</b>	Mumps
<b>Primary Sjögren syndrome</b>	<b>Viral – Orthomixovirus (RNA)</b>
Neurosarcoidosis	Influenza A virus (including H1N1)
Behçet’s disease	<b>Viral – Picornaviruses (RNA)</b>
Mixed connective tissue disease (MCTD)	Coxsackieviruses A and B
Systemic sclerosis	Enterovirus-70 and -71
Vogt–Koyanagi–Harada	Echovirus 30
<b>Primary angiitis of the central nervous system</b>	Hepatitis B, C, E
<b>Atopic myelitis</b>	Poliovirus 1, 2, and 3
<b>Paraneoplastic</b>	<b>Viral – Flaviviruses (RNA)</b>
Anti-amphiphysin (breast carcinoma)	West Nile virus
Anti-CRMP-5 (small cell lung cancer)	Japanese encephalitis virus
Necrotizing myelopathy	Tick-borne encephalitis virus
<b>Bacterial</b>	St. Louis encephalitis virus
<i>Mycoplasma pneumoniae</i>	Dengue virus
<i>Borrelia burgdorferi</i> (Lyme disease)	<b>Orthoretroviruses (RNA)</b>
<i>Treponema pallidum</i> (syphilis)	HTLV-1 and 2
<i>Mycobacterium tuberculosis</i> (TB)	HIV
<i>Brucella melitensis</i> (brucellosis)	<b>Parasitic</b>
Salmonella non-typhi	Neurocysticercosis
Salmonella para-typhi B	<i>Schistosoma</i>
Scrub typhus	<i>Gnathostoma angiostrongylosis</i>
<i>Bartonella henselae</i> (cat-scratch)	Larva migrans
<i>Listeria monocytogenes</i>	<i>Angiostrongylosis cantonensis</i>
Leptospirosis	Toxoplasmosis
<i>Trophymera whipplei</i> (Whipple’s)	Trypanosomiasis
<i>Coxiella burnetii</i>	
<b>Fungal</b>	
<i>Actinomyces</i>	
<i>Coccidioides</i>	
<i>Aspergillus</i>	
<i>Blastomyces dermatides</i>	
<i>Cladophialophoro bantiana</i>	
<i>Cryptococcus</i>	

Those in **bold** indicate common causes for transverse myelitis.

HIV, human immunodeficiency virus; HTLV, human T-lymphotropic virus; TB, tuberculosis.

Brown-Séquard syndrome is caused by penetrating or compressive injury to the spinal cord, multiple sclerosis (MS) may also present with this syndrome.

Spinal cord inflammation that spares either the anterior or posterior portion of the cord is not considered transverse myelitis but is rather classified as partial myelitis. Partial myelitis may be either unilateral or bilateral and can be associated with sphincter impairment. As in

transverse myelitis, alterations in deep tendon reflexes, a sensory level, and Lhermitte symptom can help localize the level, although respiratory impairment is highly unusual for partial myelitis. Thus the symptoms of partial myelitis may be restricted to only unilateral or even monomelic forms with incomplete sensory or motor impairment. In these circumstances the only clinical feature that may help localize the injury to the spinal cord is

the absence of cortical or cranial nerve symptoms. By far the most common cause of partial myelitis is MS.

One form of a partial myelitis is the posterior cord syndrome in which only the dorsal columns are affected either unilaterally or bilaterally, resulting in loss of fine touch, vibration, and proprioception but without corticospinal or anterior spinothalamic tract involvement. Clinically, patients will manifest limb incoordination due to proprioceptive loss but will have full strength and intact pain and temperature sensation.

When the anterior cord is selectively partially affected, pyramidal weakness will be the primary clinical manifestation. The spinal thalamic tracts may also be affected, resulting in loss of pain and temperature sensation. Autonomic impairment is also common with loss of sphincter function. As with other types of partial myelitis, the involvement may be unilateral or bilateral. When the anterior horn cells are damaged the weakness will be flaccid and deep tendon reflexes will be absent at the level of injury. Because the dorsal columns are spared, vibration and proprioception sensation remain intact. The classic example of an anterior cord syndrome is infarction of the spinal cord caused by anterior spinal artery occlusion, although MS can also cause this syndrome. Selective involvement of the anterior horns of the spinal cord resulting in flaccid ascending paralysis is a hallmark of poliomyelitis, an infection that was nearly eradicated but is on the resurgence due to failure of global vaccination efforts (Heymann and Aylward, 2004).

Inflammatory injury to the central cord results in a clinical syndrome similar to that caused by a syrinx. The crossing spinothalamic fibers are affected, resulting in dissociated sensory loss. Pain and temperature sensation are impaired below the level of the lesion whereas fine touch, vibration, and proprioception remain intact. Central cord injury is often accompanied by corticospinal and autonomic impairment below the level of the lesion. Although a central cord syndrome occurs in NMO, it is relatively uncommon in MS.

The conus medullaris may be selectively affected, causing sphincter dysfunction and sacral sensory loss. Although motor impairment can occur, it is typically relatively mild compared to the autonomic and sensory loss because of selective involvement of the sacral spinal cord segments. Conus medullaris inflammation may spread caudally, resulting in an ascending transverse myelitis. Parainfectious etiologies such as postviral myelitis typify the conus syndrome.

Cauda equina inflammation can occur, resulting in sensory loss, motor impairment, and autonomic dysfunction in the distribution of the affected nerve roots. Flaccid weakness affects the lower limbs and is often asymmetric. Although cauda equina inflammation is a polyradiculitis and not myelitis, it sometimes can extend

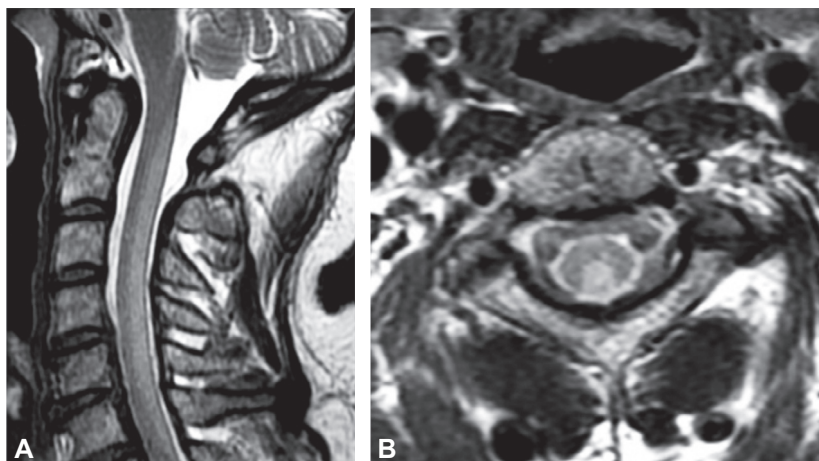
into the conus medullaris, resulting in a mixed polyradiculitis with myelitis syndrome. Infectious and parainfectious causes of ascending polyradiculopathies include neuroborreliosis, cytomegalovirus, and acute inflammatory demyelinating polyradiculopathy.

The exception to the rule that cranial nerve symptoms are spared with spinal cord injury is the trigeminal nerve. Afferent sensory fibers of the trigeminal nerve descend through the upper cervical cord prior to decussating and ascending to the thalamic nuclei. Therefore, with high cervical cord lesions, partial facial sensory loss may occur.

## DIAGNOSTIC EVALUATION

The diagnostic evaluation of patients presenting with acute myelopathy begins with a detailed clinical history, including full review of systems, as well as past medical, family, social, and travel histories. Important clues to diagnostic etiology can be garnered from basic laboratory studies that include a complete blood count with differential, serum chemistries, as well as tests for common metabolic diseases that may present with acute myelopathy such as vitamin B<sub>12</sub> deficiency (Fig. 28.1). Neuroimaging and cerebrospinal fluid (CSF) evaluation are also crucial diagnostic studies. Additional laboratory studies may include visual evoked potentials (VEPs) and somatosensory evoked potentials (SSEPs) if structural imaging is not revealing. If an infectious etiology is suspected by the presence of fever, cough, rash, or history of exposure, then specific tests can be ordered to confirm the precise infectious etiology. A comprehensive approach to the diagnostic evaluation of acute myelopathies, with consideration of the potentially very broad differential, is presented in Table 28.3.

Although beyond the scope of this review, numerous infectious etiologies have been associated with myelitis (Table 28.2). Additional symptoms, signs, and aspects of the patient's history may suggest an infectious etiology. For example, the presence of fever, meningismus, rash (lyme, zoster, enterovirus), cough (*Mycoplasma pneumoniae*, *Chlamydia pneumoniae*), diarrhea (enterovirus, *Salmonella*), an immunocompromised state (herpes zoster, cytomegalovirus), a history of recent travel (tuberculosis, parasitic infections), recurrent genital infection (herpesvirus), mosquito bite (West Nile virus), radicular burning pain with or without vesicles suggestive of zoster radiculitis, or adenopathy may suggest specific infectious etiologies. Infectious etiologies of myelitis can be viral, bacterial, fungal, and, rarely, parasitic. It is always important to consider treatable infections such as syphilis, herpesviruses, human immunodeficiency virus (HIV), Lyme disease, and tuberculosis. The most commonly implicated viruses are West Nile virus, varicella-zoster, herpes simplex type-2, and cytomegalovirus.



**Fig. 28.1.** Vitamin B<sub>12</sub> deficiency. Woman with tingling and cramping sensations in both arms and legs and low serum B<sub>12</sub>. Sagittal (A) and axial (B) T2-weighted images show well-defined, confluent T2 signal abnormality in the dorsal columns of the cervical cord without cord expansion. (Copyright Bruce Cree.)

**Table 28.3**

#### Diagnostic evaluation

---

Complete history (including travel and animal contacts), physical, and neurologic examination  
 Basic laboratory studies: complete blood count, serum chemistries, vitamin B<sub>12</sub>, urinalysis with microscopic examination, chest X-ray with PA and lateral views, HIV testing, and PPD placement with controls for anergy  
 MRI: spinal cord with and without gadolinium contrast administration; brain with and without gadolinium contrast administration and with sagittal T2 or proton density-weighted images  
 Electrophysiology studies: visual evoked potentials and nerve conduction studies  
 Collagen vascular disease and autoantibody studies: ESR, ANA, dsDNA, ENA, RF, anti-SSA, anti-SSB, anticardiolipin antibodies, and p-ANCA; thyroid function tests, antimicrobial antibodies, and antithyroglobulin antibodies for Hashimoto's encephalopathy (myelopathy)  
 In a patient with serologic markers for Sjögren syndrome or a history of xerostomia and xerophthalmia consider a Schirmer test (lacrimation), salivary gland scintigraphy, and salivary/lacrimal gland biopsies.  
 CSF studies: cell counts, protein, glucose, IgG index, IgG synthetic rate, oligoclonal bands, ACE, IL-6 level  
 CSF infectious etiology studies: PCR for varicella-zoster, Epstein-Barr, herpes simplex type 1 and 2, and cytomegalovirus viruses; antibody studies for human T-cell lymphotropic virus-1, *Borrelia burgdorferi*, *Mycoplasma pneumoniae*, and *Chlamydia pneumoniae*; viral cultures for enteroviruses; cultures and stains for aerobic and anaerobic bacteria, fungi, *Mycobacterium tuberculosis* and *Brucella melitensis*; and VDRL  
 Serum infectious etiology studies: IgG and IgM enterovirus antibody titers, IgM mumps, measles, and rubella antibodies, West Nile antibodies, dengue antibodies (group B Arboviridae), *Brucella melitensis* antibodies, *Chlamydia psittaci* antibodies, *Bartonella henselae* antibodies, schistosomal antibodies; cultures for *Brucella melitensis*, hepatitis A, B, and C studies, and RPR  
 Additional studies for infection: nasal-pharyngeal and anal swabs/cultures for enteroviruses; stool O&P for *Schistosoma* ova; wound cultures for *Clostridium tetani* (if applicable)  
 Sarcoidosis evaluation: serum ACE, serum calcium, and 24-hour urine calcium. In patients with hilar adenopathy or elevated ACE consider CT of chest, total body PET scan, and tissue biopsy to search for systemic sarcoidosis. In cases of neurosarcoidosis without systemic illness, a spinal cord biopsy may be necessary  
 Serum and 24-hour urine for very-long-chain fatty acids for adrenomyeloneuropathy  
 CT myelogram and spinal angiogram for spinal dural arteriovenous malformation

---

ANA, antinuclear antibody; ANCA, antineutrophil cytoplasmic antibody; ACE, angiotensin-converting enzyme; CSF, cerebrospinal fluid; CT, computed tomography, dsDNA, double-stranded DNA; ENA, extractable nuclear antigen; ESR, erythrocyte sedimentation rate; HIV, human immunodeficiency virus; IgG, immunoglobulin G; IL-6, interleukin-6; MRI, magnetic resonance imaging; O&P, ova and parasites; PA, posteroanterior; PCR, polymerase chain reaction; PET, positron emission tomography; PPD, purified protein derivative; RF, rheumatoid factor; RPR, rapid plasma reagin; VDRL, Venereal Disease Research Laboratory.



## Neuroimaging

Once a clinician has recognized that a spinal cord injury has occurred, a next step in the diagnostic evaluation is to determine whether the myelopathy is non-compressive or caused by compression of the cord using imaging. MRI is the preferred imaging modality because of the significantly superior ability to visualize the spinal cord itself as well as other soft-tissue structures compared to CT. When the cause of the myelopathy is unknown, in almost all cases infusion of the MRI contrast agent gadolinium-diethylenetriaminepentaacetate (DTPA) is indicated. Gadolinium-DTPA is useful to demonstrate disruption of the blood–spinal cord barrier, as in the setting of active spinal cord inflammation or infarct, or to show increased blood flow such as found with tumors and arteriovenous malformations.

However, if an MRI cannot be obtained emergently, CT myelography is a reasonable alternative. The main disadvantage of this imaging modality is the limited ability to visualize the spinal cord. It is important to keep in mind that determining the region of the spinal cord to image based on clinical features in some cases can miss a compressive lesion just superior to the field of imaging that could be surgically decompressed. This is especially the case if the suspected lesion is near the cervicothoracic or thoracolumbar junction because cord lesions can cause clinical deficits that localize to lower spinal cord segment. For this reason, it is always best to image the region where the clinical signs and symptoms localize, as well as the superior spinal cord, possibly using a sagittal survey.

Once the MRI excludes compressive etiology, additional imaging characteristics may be helpful with the differential diagnosis, particularly the appearance and pattern of the lesion(s). [Table 28.4](#) describes the imaging patterns associated with some of the more common causes of acute transverse myelitis (ATM). Following review of the spinal imaging, a brain MRI should be performed to determine if other demyelinating lesions within the CNS are present. Patients with MS and NMO are much more likely to have lesions on the brain MRI. In addition, MS-associated spinal cord lesions tend to be asymmetric, peripherally located within the cord axis, and tend to extend over fewer than two spinal cord segments ([Fig. 28.2](#)). Patients with NMO are more likely to have lesions that extend over three or more spinal cord segments and tend to be centrally located. Approximately 25% are associated with cord swelling, and may have patchy gadolinium enhancement ([Fig. 28.3](#)).

## Cerebrospinal fluid

Once neuroimaging has excluded a compressive etiology, the next step in the diagnostic work-up is a lumbar

puncture to determine if there are signs of inflammation within the CSF. If the CSF is non-inflammatory then vascular, toxic/metabolic, neurodegenerative, or neoplastic myelopathies become much more likely and the subsequent work-up should focus on these etiologies.

CSF is an essential component of the evaluation of every patient with suspected myelitis ([Table 28.5](#)). After measuring the opening pressure, CSF studies should include cell count with differential, protein, and glucose. Measurements of intrathecal immunoglobulin synthesis with oligoclonal bands (OCBs) and an immunoglobulin G (IgG) index or synthesis rate must be sent on every patient. This requires drawing a serum sample at the time of the lumbar puncture for comparative analysis of gammaglobulins and should be performed on every patient with suspected myelitis. In addition, cytology for evaluation of neoplasm should be included. If the CSF shows signs of inflammation (pleiocytosis, elevated protein, OCBs, or elevated IgG index), then the subsequent diagnostic studies should focus on demyelinating, infectious, or other inflammatory causes of acute myelitis (AM).

The evaluation of common infectious causes of myelitis includes: Venereal Disease Research Laboratory (VDRL), Lyme Western blot, and polymerase chain reaction (PCR) studies for Herpesviridae (varicella-zoster virus, herpes simplex virus types 1 and 2, cytomegalovirus, human herpesvirus 6 and 7, Epstein–Barr virus), West Nile virus, and tuberculosis ([Table 28.6](#)). In addition, bacterial, fungal, and acid-fast bacillus cultures should be considered. One milliliter of acellular supernatant should be sent for interleukin-6 (IL-6) enzyme-linked immunosorbent assay (see section on immunology, below). Lastly, several milliliters of frozen CSF sample should be reserved for additional PCR studies. As in neuroimaging, certain CSF patterns or findings may be helpful in narrowing the differential diagnosis.

A low CSF glucose (less than 60% of serum glucose) generally suggests an infection (fungal, bacterial, or mycobacterial), especially when associated with elevated CSF protein. However, an isolated low CSF glucose can occur in neurosarcoidosis, leptomeningeal carcinomatosis, subarachnoid hemorrhage, and even systemic lupus erythematosus (SLE) with CNS involvement. An elevated protein is the most common CSF abnormality in patients with spinal cord disease and is present in approximately 50% of patients with transverse myelitis. However, elevated CSF protein is non-specific and is associated with spinal cord tumors, paraneoplastic myelopathies, radiation myelopathies, vascular malformations, infection, syringomyelia with spinal block, and spinal cord trauma.

Elevation in the CSF white blood cell count (WBC) defines inflammatory myelitis. The WBC differential can be very helpful in understanding whether an infectious or autoimmune process is at play. The presence

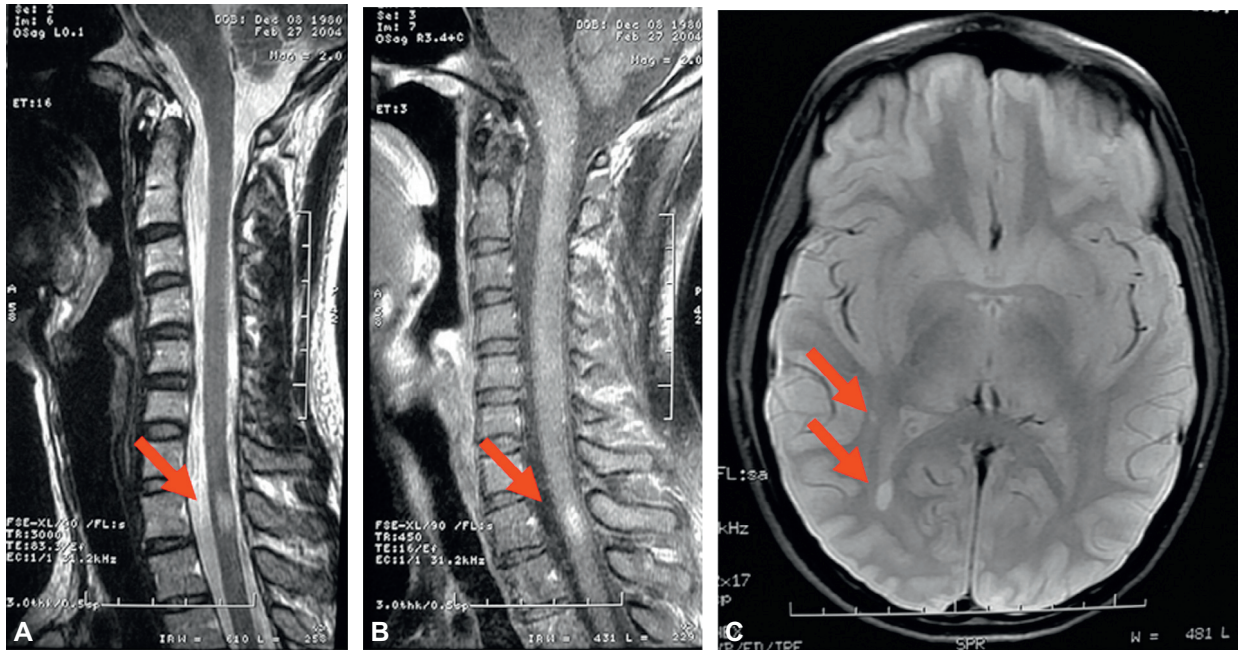
**Table 28.4**

**Imaging in acute myelitis**

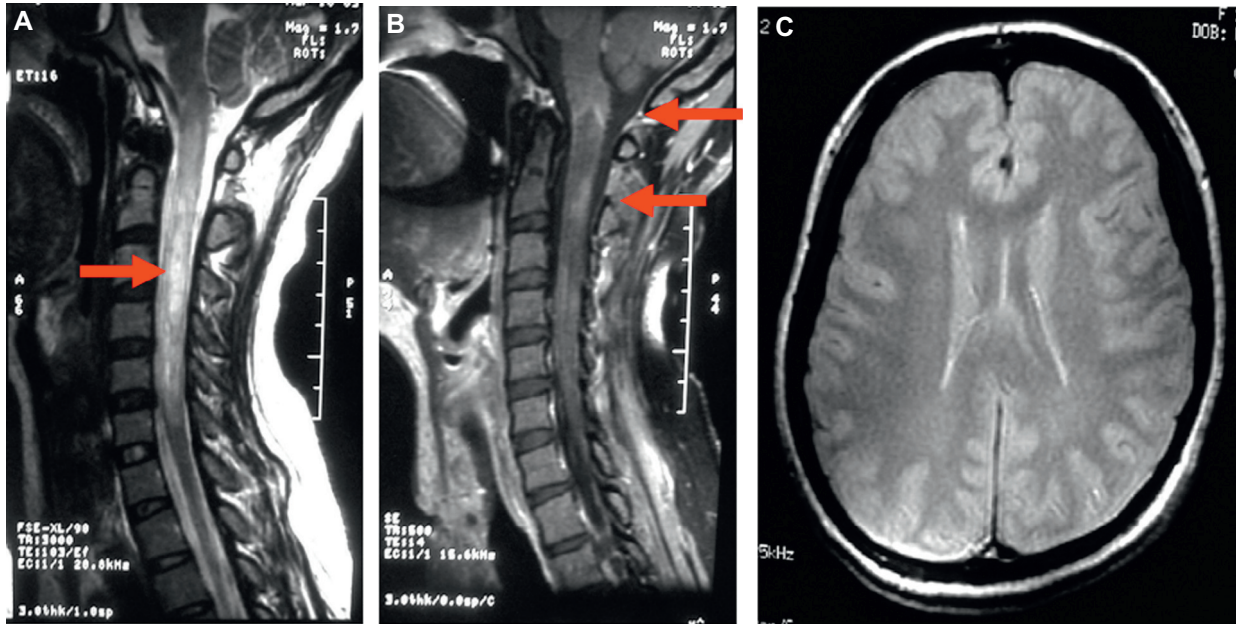
Etiology of myelitis	Location	Lesion length	Pattern of T2 involvement	Pattern of contrast enhancement	Cord swelling (enlargement)	Other characteristics
MS	60–75% cervical	≤2 cord segments	Peripheral, ovoid, paracentral	~15% of cord plaques enhance	Atypical (atrophy more common)	>50% have multiple lesions, of which ~50% are clinically silent
NMO	~80% cervical	≥3 cord segments	Centrally located, can be dorsal	Patchy	~25%	~25% will have an average of 3–4 brain lesions
Idiopathic TM	Usually thoracic	≥3 cord segments	Diffuse, patchy, or peripheral	Variable (diffuse, patchy, peripheral)	Variable	Many infectious etiologies have same profile (diagnosis of exclusion)
ADEM	Usually thoracic	Variable	Multifocal, flame-shaped, and can be large	Variable	Common	Myelitis occurs in 11–28% of cases; meningeal enhancement is unusual
Sarcoidosis	Cervical or thoracic	Variable	Central (62%) > anterior, lateral, posterior	Usually patchy, but can be diffuse, nodular, multifocal, leptomeningeal	Up to 35	May involve the intradural nerve roots. Thickening of the roots may occur. About 25% with >1 lesion
VZV	Usually thoracic	Variable	Typically posterior (Hirai et al., 1996)	Patchy or focal at dermatomal level	Common	Enhancement may involve the dorsal root
CMV	Cauda equina and conus medullaris	Variable	Thickened cauda equina	Leptomeningeal, dorsal root, and diffuse nerve enhancement	Can cause a focal space-occupying lesion	Usually a polyradiculitis
HSV		Variable	Can be >1 lesion	Diffuse	Can occur	HSV-2 >> HSV-1 causes myelitis. Can have associated hemorrhage.
Poliomyelitis		Variable	Increased signal in anterior horns	Anterior horns	Focal	Can also be seen in postvaccinal poliomyelitis, West Nile virus, enterovirus-71, or Lyme
Lyme		Variable	Can be normal or nodular, increased signal	Nodular leptomeningeal, intraspinal or anterior horn cell	Focal	Can cause ATM, meningomyelitis, or polio-like paralytic syndrome
Paraneoplastic		Variable	Variable, can be holocord, or highly specific symmetric tract involvement	Patchy		Antiampiphysin

ADEM, acute disseminated encephalomyelitis; ATM, acute transverse myelitis; CMV, cytomegalovirus; HSV, herpes simplex virus; MS, multiple sclerosis; NMO, neuromyelitis optica; TM, transverse myelitis; VZV, varicella-zoster virus.





**Fig. 28.2.** Multiple sclerosis. Sagittal T2-weighted (A) and sagittal T1 plus gadolinium (B) cervical spine images in a patient with multiple sclerosis presenting with partial myelitis. Note the sharply margined, short-segment plaque that is peripherally located within the cord axis and predominantly located within the white matter of the cervical spinal cord. The patient also had multiple plaques in the periventricular white matter (C). (Copyright Bruce Cree.)



**Fig. 28.3.** Neuromyelitis optica (NMO). Magnetic resonance images shown include sagittal T2 (A), axial gadolinium-enhanced T1 (B), and axial T2 (C). Longitudinally extensive T2 signal abnormality in the cervical cord (A), accompanied by patchy intramedullary enhancement on gadolinium-enhanced T1-weighted imaging (B). The patient subsequently developed monocular vision loss and was seropositive for the NMO-immunoglobulin G (IgG) antibody. The brain magnetic resonance imaging scan was normal (C). (Copyright Bruce Cree.)

Table 28.5

## Cerebrospinal fluid (CSF) studies for evaluation of acute transverse myelitis

Studies	Volume CSF	Method	Considerations
Cell count with differential	1 mL	1. Hemocytometer for count 2. Wright-stained cytocentrifuge preparation for differential	CSF specimens should be transported at ambient temperature as soon as possible after collection. Cellular degeneration of CSF can begin within 1 hour of collection
Glucose	0.5 mL	Spectrophotometric (glucose oxidase)	Measure the serum glucose as well. CSF levels are usually >55% of serum glucose and >40 mg/dL. As serum glucose rises above 200 mg/dL, the CSF/serum ratio falls from about 0.55 to a minimum of 0.31. Sample can be stable for up to 10 days if refrigerated
Total protein	0.5 mL	Spectrophotometric (pyrogallol red)	Sample can be stable for up to 10 days if refrigerated
Oligoclonal bands (OCB)	2 mL (and 2 mL of blood)	Isoelectric focusing with immunoblotting, preferably with antihuman IgG labeled with alkaline phosphatase	It is important to include a serum sample to test in parallel with the CSF. If serum collected the same day as the CSF is unavailable, a sample collected within 72 hours of the CSF is acceptable. Isoelectric focusing is superior to immunofixation with sensitivity for detecting OCBs in excess of 95%
IgG index	1 mL (and 1 mL of blood)	Rate nephelometry	As with OCB, a serum sample must accompany the CSF sample. A bloody contamination of CSF due to a traumatic lumbar puncture can significantly elevate the IgG index

IgG, immunoglobulin G.

Table 28.6

## Infections associated with acute myelitis and the utility of biomarkers used in the diagnosis of their most commonly associated infections and clinical syndromes

CSF studies	Sensitivity	Specificity	Associated CNS infection
VDRL	71%	99%	Neurosyphilis
Lyme ( <i>Borrelia</i> ) PCR	17–21%		Neuroborreliosis (Lyme)
Enterovirus PCR	>90%		Aseptic meningitis
Herpes simplex virus (HSV-1) PCR	98%	94%	Encephalitis
Herpes simplex virus (HSV-2) PCR	100%*	99%*	Encephalitis
Varicella-zoster virus (VZV) PCR	80%*	98%*	Varied CNS infections (including myelitis)
Cytomegalovirus (CMV) PCR	82–100%*	89–100%*	Encephalitis or polyradiculitis
Epstein–Barr virus (EBV) PCR	88–100%*	89–100%*	Primary CNS lymphoma
<b>Serologic assays</b>			
Rapid plasma reagin (RPR)	75%	99%	Neurosyphilis
West Nile virus (WNV)	50%	95%	Encephalitis
IgM	86%	69%	
IgG			
Early Lyme	40–78%	89–94%	Borreliosis (Lyme) <sup>†</sup>
IgM ELISA			
IgM Western blot	32%	100%	Borreliosis (Lyme) <sup>†</sup>
Late Lyme	89–100%	72–89%	Borreliosis (Lyme) <sup>†</sup>
IgG ELISA			
IgG Western blot	83%	95%	Borreliosis (Lyme) <sup>†</sup>

\*Among HIV + patients.

<sup>†</sup>Systemic borreliosis (Lyme), not CNS.

CNS, central nervous system; CSF, cerebrospinal fluid; ELISA, enzyme-linked immunosorbent assay; HIV, human immunodeficiency virus; PCR, polymerase chain reaction; VDRL, Venereal Disease Research Laboratory.

of eosinophils can suggest NMO, parasitic or fungal infection, or the presence of a foreign material such as surgical hardware following a spinal operation. The presence of neutrophils in the CSF is highly suggestive of bacterial or mycobacterial infection, but can also be seen in sarcoidosis, NMO, or other autoimmune causes of transverse myelitis as well as acute viral infections. The presence of eosinophils in the CSF, >5% neutrophils in the CSF, or a pleiocytosis of >50 cells/cm<sup>3</sup> is atypical for MS, and increases the suspicion for other diagnoses. If infection is likely, the use of CSF cultures and PCR analysis is invaluable for identifying the cause. [Table 28.6](#) reviews the sensitivity and specificity of some common CSF tests.

The presence of two or more OCBs in the CSF that are not found in the corresponding serum sample is considered indicative of intrathecal synthesis of gammaglobulins. OCBs are present in >95% of patients with clinically definite MS (CDMS), and can be a confirmatory test for this diagnosis once systemic inflammatory and infectious etiologies have been excluded.

The presence of intrathecal synthesis of OCBs can be found in other conditions that cause inflammation in the CNS, including NMO, paraneoplastic disorders, SLE, neurosarcoidosis, Behçet's disease, various forms of

cerebral angiitis, and many CNS infections, including aseptic meningitis, neuroborreliosis, and neurosyphilis. Within NMO, OCBs are positive in as many as one-third of cases. Thus, although OCBs are a sensitive test for MS, they are not specific.

The IgG index is calculated by the following equation:  $\text{IgG index} = (\text{CSF IgG/albumin})/(\text{serum IgG/albumin})$ . This ratio generally falls between 0.3 and 0.6 for normal patients depending on the laboratory. Like OCBs, this test assesses an abnormal intrathecal humoral response. Similar caveats to the interpretation of OCB also hold for interpreting the IgG index. Accurate calculation of the IgG index requires that the CSF sample not be contaminated by a significant amount of blood caused by a traumatic lumbar puncture.

### Serologic studies

Serologic tests for autoimmune or inflammatory disease can be very helpful in determining the underlying etiology of ATM. Screening tests for these diseases should be assessed in every patient presenting with ATM and are listed in [Table 28.7](#), along with each test's sensitivity and specificity. The NMO antibody (also known as aquaporin-4 or NMO IgG) is a specific

**Table 28.7**

#### Autoimmune and inflammatory diseases associated with acute transverse myelitis and the utility of common biomarkers used in their diagnosis

CSF studies	Sensitivity	Specificity	Associated diseases
Oligoclonal bands (performed by isoelectric focusing with immunoblotting)	>95% 61% 24%		MS CIS NMO
Elevated IgG index	70–80%		MS
Angiotensin-converting enzyme (ACE)	24–55%	94–95%	Neurosarcoidosis
<b>Serologic assays</b>			
Anti-aquaporin-4 antibody (NMO-IgG)	54–73%	91%	NMO
Angiotensin-converting enzyme (ACE)	~60%	80–95%	Sarcoidosis
Antinuclear antibodies (ANA)	93%	57%	SLE
	85%	54%	Systemic sclerosis
	48%	52%	Sjögren syndrome
	44%		NMOSD
	66%	99.5%	SLE
Anti-double-stranded DNA (dsDNA)	63%		Sjögren syndrome
Anti-SSA (anti-Ro52)	35%		Myositis
	19%		Systemic sclerosis
	16%		NMOSD
	5%		SLE
	34%	88%	SLE
Anti-ribonucleoprotein (when ANA is also +)	39%	84%	SLE
Anti-scl70 (ELISA)	43%	90%	Systemic sclerosis

CIS, clinically isolated syndrome; CSF, cerebrospinal fluid; ELISA, enzyme-linked immunosorbent assay; IgG, immunoglobulin G; MS, multiple sclerosis; NMO, neuromyelitis optica; NMOSD, neuromyelitis optica spectrum disorder; SLE, systemic lupus erythematosus.



serum autoantibody that binds to the dominant CNS water channel protein aquaporin-4 (AQP4). A seropositive result effectively establishes a diagnosis of NMO, or NMO spectrum disorder if the patient has not had a prior optic neuritis (see section on NMO, above).

Several systemic inflammatory diseases are associated with ATM and include SLE, Sjögren syndrome, antiphospholipid antibody syndrome (APLS), sarcoidosis, or mixed connective tissue disease (MCTD). Many collagen vascular diseases are associated with myelitis and are reviewed in further detail in the section on systemic inflammatory diseases, below. A screening panel of serologic studies to assess for systemic inflammatory disease includes: erythrocyte sedimentation rate, C-reactive protein, antinuclear antibodies (ANA), double-stranded DNA antibodies (ds-DNA), extractable nuclear antigen panel, Sjögren's antibodies, antiphospholipid panel, rheumatoid factor, thyroid function tests, antimicrobial antibodies, and antithyroglobulin antibodies.

Numerous infectious etiologies are associated with myelitis (Table 28.2). There is no straightforward approach to determining which of the myriad possible diagnostic tests should be ordered in AM patients. Prospective studies that could determine which tests provide the greatest yield have not been done and therefore a comprehensive evaluation for infectious etiologies requires many laboratory assessments. A summary of diagnostic studies to consider is included in Table 28.3. The presence of additional signs or symptoms of infectious disease, e.g., fever, cough, diarrhea, can be useful in determining which additional studies to pursue to establish an infectious cause. Even in the absence of systemic signs of infection screening, serologic tests for AM should include: HIV, West Nile virus antibodies, *Mycoplasma* antibodies, *Chlamydia pneumoniae* antibodies, rapid plasma regain, and Lyme serology.

### **HISTORIC ASPECTS OF MYELITIS AND THE PROGRESSIVE NECROTIC MYELOPATHY DEBATE**

Early accounts attributed spinal cord necrosis to an inflammatory process (Gowers, 1899). Pathologic “softening of the spinal cord” was assumed to be secondary to inflammation from all causes, including trauma, compressive injuries, malignancies, infections, acute rheumatism, and other chronic systemic illnesses. However, not everyone accepted the premise that all spinal cord softening was inflammatory and a dissenting opinion suggested that vascular thrombosis was the primary cause of spinal cord softening and that inflammation was usually a secondary event (Bastian, 1882). These perspectives framed a debate over the cause of

progressive necrotic myelopathy, with opposing authors maintaining that either thrombosis or inflammation was the underlying etiology. This history of this debate is worth considering because even today, with the advances in MRI and CSF analysis, there remain many acute myelopathy cases wherein a vascular or inflammatory etiology is not clearly established. Even the most recently proposed ATM diagnostic criteria (Transverse Myelitis Consortium Working Group, 2002) do not definitively distinguish between vascular and inflammatory etiologies, generating etiological uncertainty in many cases.

Naturally, the causes of myelitis have evolved over the last century. In 1900 syphilis was widespread, the causative agent, *Treponema pallidum*, was not yet discovered (Schaudinn, 1905), and the first antimicrobial treatment, Salvarsan, was not yet developed. Several reported cases of myelitis were due to syphilitic complications, including arteritic thrombosis (Singer, 1902). With the evolving understanding that encephalomalacia could be caused by vascular thrombosis it was suggested that “acute myelitis” was not due to inflammation but secondary to thrombosis and myelomalacia was likened to thrombotic encephalomalacia (Bastian, 1910). Infectious myelitis was proposed to be a consequence of endarteritis, resulting in thrombosis and secondary spinal cord injury. In 1926, Foix and Alajouanine coined the term “subacute necrotic myelitis” in describing two cases of spinal necrosis, where an “endomesovascularitis” was described associated with vascular hyperplasia (Foix and Alajouanine, 1926). Subsequent similar cases of subacute necrotic myelitis enjoyed the “Foix and Alajouanine” eponym. One of the pathologic features of these cases was intramedullary and extramedullary vascular hyperplasia and this feature, among other observations, led to the hypothesis that these cases were due to “angioma racemosum venosum,” now known as spinal dural arteriovenous malformations (Wyburn-Mason, 1943; Ferrell et al., 2009). Other opinions considered the cases of subacute necrotic myelitis to be caused by spinal thromboplebitis (Mair and Folkerts, 1953; Blackwood, 1963). Since it became clear that more than one etiology contributed to subacute necrotic myelitis, the Foix and Alajouanine eponym was eventually abandoned.

The clinical characteristics of progressive necrotic myelopathy were not strongly indicative of a unifying etiology. The average age of onset was in mid 30s to late 40s, with a range of 3–74 years (Spiegel, 1936; Mancall and Rosales, 1964). Men were affected as often as women and no clear preceding illness could be identified, although many cases were characterized by an infectious prodrome. Other associated concurrent illnesses included carcinoma, trauma, exposure to heavy metals, recent childbirth, hypertension, and radiotherapy (Folliss and Netsky, 1970). That an inflammatory etiology could contribute to the clinical syndrome of

progressive necrotic myelopathy is indicated by the observation of a pleocytosis in several cases (Van Gehuchten, 1927; Low, 1929; Moersch and Kernohan, 1934; Jaffe and Freeman, 1943; Hoffman, 1955; Behar et al., 1957).

In these early case series the prognosis for acute myelopathy was dismal. In one series, acute spinal necrosis of obscure origin was uniformly fatal in from 10 days to 3 months (Jaffe and Freeman, 1943). Other series found that if death did not occur in the acute stage, invariably patients succumbed from the effects of bedsores and urinary infection (Hoffman, 1955; Veron et al., 1974). However, the possibility of long-term survival was also described in certain cases (Moersch and Kernohan, 1934; Adams and Kubik, 1952). As with Foix and Alajouanine, these case series grouped together patients with myelopathies of vacular and inflammatory etiologies.

The term “acute transverse myelitis” was first used by Suchett-Kaye in 1948 in describing a case of postinfectious myelitis as a complication of pneumonia. A possible causal link between recent infection and myelitis was suggested in a review of 25 pediatric cases of transverse myelitis in which 15 cases were associated with recent infection. Presentations included weakness (9/25), limb pain or paresthesias (7/25), back pain (4/25), abdominal pain (2/25), and sphincter disturbance (3/25). Ten cases showed sensory dissociation suggestive of anterior spinal artery involvement and two cases were presumed to be arteriovenous malformations. CSF was characterized by a leukocytosis (21/25) and elevated protein (20/25). Patients presenting with a high and mid thoracic sensory level were less likely to have experienced a prior infection, suggesting possibly a vascular etiology in these cases due to the more limited blood supply in the upper thoracic cord (Paine and Byers, 1953).

Further evidence for an infectious etiology for transverse myelopathy came from a case series from Columbia University of 44 adults and 23 children affected by transverse myelopathy. A potential link with prior infection or vaccination was found in 20/67 patients (11 upper respiratory tract infections, 2 bacterial skin infections, 1 varicella primary infection, 1 dengue fever, 1 shingles, 3 infections of unknown etiology and 1 vaccination). Neither gender nor age of onset provided insight into pathogenesis. Presenting symptoms included weakness (25%), sensory disturbance (25%), back pain (25%), radicular pain (21%), and sphincter disturbance (3%). During the course of illness, virtually all patients were afflicted by weakness, sensory disturbance, and sphincter dysfunction. CSF results were not tabulated but counts as high as 8800 were reported and >50% of patients had elevated protein. In the majority of cases the causative etiology remained obscure, although in 8 patients a plausible etiology was identified: MS (4), carcinoma (2), syphilis (1), and

an arteriovenous malformation (1). Recovery was described as “good” in a third, “fair” in a third, and “poor” in a third of patients (Altrocchi, 1963a, b).

### Predictors of outcomes

Clinical predictors of recovery were first reported in a case series of acute transverse myelopathy from Johns Hopkins Hospital (Lipton and Teasdale, 1973). Twelve of 34 patients experienced a viral prodrome. Acute transverse myelopathy was defined as paralysis of both legs, associated with bilateral sensory loss and urinary and fecal retention in patients with no antecedent neurologic or systemic illness. The presenting symptoms and deficits during the course of the illness were similar to those described in other series. The time to maximum deficit varied between 1 hour and 14 days. CSF pleocytosis was reported in 50% and elevated protein in 33%. Patients who retained deep tendon reflexes and postcolumn function tended to have a better prognosis, whereas those who developed spinal shock with lost reflexes had a poor prognosis. The overall outcomes were “good” in 9 patients, “fair” in 9 patients, and “poor” in 11 patients. Five died from complications of ATM and 8 died later. At follow-up, only 1 patient developed MS. Infarctions were identified in 2 patients, non-specific necrosis in 2 patients, meningomyelitis in 1 patient, and an intramedullary capillary telangiectasia in 1 patient at autopsy.

Additional clinical predictors of recovery were reported in a case series of 52 patients with acute transverse myelopathy from Massachusetts General Hospital (Ropper and Poskanzer, 1978). The clinical manifestations, including presenting symptoms, were similar to those described in other series and as in other series patient demographics provided no etiologic clues. Unfortunately, CSF results were not well summarized and the presence of OCBs was not reported. Eleven of 52 patients had a hyperacute, catastrophic course. In 10/11 of these patients back pain was the presenting symptom. Seven of 11 of these patients had a poor outcome; only 1/11 had a good outcome. Thirty-six of 52 patients had a subacute, progressive onset with ascending paresthesias or leg weakness evolving over days to weeks. In this group, 15/32 had a good outcome, and 17/32 had a fair outcome. Seventeen of 52 had antecedent illness; 1 patient had recent chickenpox and 1 had recently received oral polio vaccination. Seven patients had coexisting medical conditions (including cancer, Felty syndrome, postoperative state, pregnancy, type 1 diabetes mellitus). Seven patients ultimately developed MS, although 3/7 had the NMO phenotype.

In a case series of 31 patients with ATM in whom MS and NMO were excluded, severity of the clinical deficit during the nadir of the attack, radiographic involvement on MRI affecting two or more vertebral levels, and

abnormal SSEPs were predictors of a poor outcome (al Deeb et al., 1997). Interestingly, treatment with corticosteroids did not appear to influence the outcome. The authors concluded that ATM was a restricted form of postinfectious encephalomyelitis.

Additional predictors of outcome were reported in a series of 53 patients who presented with AM and were followed for a median time of 6.2 years (Gajofatto et al., 2010). Forty-two patients were eventually diagnosed with MS, 6 with monophasic AM, and 5 with recurrent AM. A history of connective tissue disease was associated with recurrent AM and not for MS (OR = 0.2,  $p < 0.001$ ). As expected, patients with brain MRI abnormalities were at increased risk for MS. Patients presenting with motor dysfunction at onset, and especially those with symmetric motor dysfunction, were at higher risk for having a residual expanded disability status scale score (EDSS) score  $>2$  compared to patients who presented with asymmetric or without motor dysfunction ( $p = 0.01$ ). In contrast, the presence of OCBs was protective and was associated with an odds ratio of 0.1 for EDSS score  $>2$  compared to patients without OCBs. Motor dysfunction at presentation also was associated with a shorter time to relapse (9.0 versus 17.9 months,  $p = 0.01$ ). In a subset of 11 patients who underwent CSF analysis, the cystatin C densitometric value was correlated with increased EDSS scores at last follow-up ( $\rho = 0.69$ ,  $p = 0.03$ ). CSF 14-3-3 protein and tau were also examined; however, correlation between these CSF biomarkers and disease recurrence or severity was not found.

### Estimates of prevalence

The first estimate of the relative prevalence of ATM compared to MS came from a study of Jewish patients from Israel between 1955 and 1975 (Berman et al., 1981). During this time, 62 patients developed ATM whereas 747 patients in Israel were diagnosed with MS. ATM was defined as: (1) acute paraparesis with motor, sensory, and sphincter impairment; (2) spinal sensory level (patients with patchy deficits or Brown-Séquard syndrome were excluded); (3) non-progressive clinical course; (4) no spinal cord compression; and (5) absence of other known neurologic disease to account for the symptoms, such as syphilis, trauma, malignancy, encephalitis, or spinal cord irradiation. The estimated annual incidence of acute transverse myelitis was 1.34 cases/million/year. As with other prior case series there was no gender preference and the age range was broad. Thirty-seven percent of patients had either a viral or bacterial infection prior to symptom onset by 5–21 days. Infection was more common in the  $<40$  years age group. Thirty-one of 50 had abnormal CSF. Recovery followed

a similar distribution described in other case series. Only 1 patient with ATM developed MS.

Using the same definition of acute transverse myelopathy, similar observations were made in a Danish series of 31 patients with respect to antecedent illness (41%) and prognosis (one-third with good, one-third with fair, and one-third with poor outcomes) (Christensen et al., 1990). As was previously observed, spinal shock and back pain were associated with a poor prognosis. Only one of the patients in this series developed MS 10 years after the onset of myelitis. OCBs were identified in 1/13 patients (whether the patient with MS had OCBs was not specified). Nevertheless, this observation suggests that OCBs are uncommon in postinfectious acute transverse myelopathy and might be useful for distinguishing MS cases.

Another population-based approach using a similar definition of ATM estimated the incidence to be 4.6 cases/million/year (Jeffery et al., 1993). Thirty-three cases were identified in five New Mexico hospitals between 1980 and 1990. Cases were divided into: parainfectious (15), MS (7), spinal cord ischemia clinically defined by lack of dissemination and preservation of posterior column sensation (4), and idiopathic (7). Seventy-three percent of postinfectious cases had antecedent respiratory illnesses. Postinfectious cases tended to be weaker, showed ascending spinal cord dysfunction, and had edema on imaging. OCBs were identified in 3/5 MS, 0/4 postinfectious patients, and in 1/2 idiopathic cases, but were not reported in the ischemic cases. Relapses occurred in 2/14 postinfectious, 3/5 MS, 1/6 idiopathic, and 0/4 ischemic cases. Unfortunately, the predictive value of OCBs with respect to myelitis recurrence was not reported. Ischemia cases tended to be older, although one patient was age 13. A good prognosis occurred in the majority of MS cases (5/6), about a third of post-infectious cases (5/16), and did not occur in the ischemic cases.

The observation that OCBs may not be identified in postinfectious cases of myelitis (as suggested by the New Mexico experience) was replicated in a case series of 31 patients with ATM in whom MS and NMO were excluded by follow-up (al Deeb et al., 1997). Myelitis followed a febrile illness in 81% of patients and OCBs were not present in any patient.

A retrospective study of 45 patients who presented with AM found that 22% of patients eventually were diagnosed with MS (Harzheim et al., 2004). Patients with known MS at the time of ATM were excluded, as were other patients presenting with myelopathy of compressive, traumatic, vascular etiologies or patients who had a history of spinal cord radiation. Single vertebral segment spinal cord lesions were most common in patients who developed MS (8/10 patients). Importantly, the



definition of “transverse” myelitis used in this study could have allowed inclusion of cases of partial myelitis. Unfortunately, the duration of follow-up was not specified. Additional diagnostic etiologies included parainfectious myelitis (38%), rheumatoid arthritis (1 case), and hypersensitivity vasculitis (1 case). An infectious cause was found in only 3 patients (*Borrelia burgdorferi*, *Treponema pallidum*, *Staphylococcus aureus*). An etiology for myelitis could not be identified in 38% of cases. An interesting feature of this case series is that 12 patients (27%) had electrophysiologic evidence of peripheral nerve impairment (6 patients with parainfectious ATM, 4 with idiopathic ATM, 1 with hypersensitivity vasculitis, and 1 with rheumatoid arthritis). None of the patients who developed MS had evidence of peripheral nerve involvement. MRI documented spinal cord pathology in 96% of cases. In patients who ultimately developed MS or those with possible MS the MRI showed a single vertebral segmental lesion, whereas in other cases spinal cord lesions spanned more than one segment.

A retrospective chart review of patients presenting with ATM between January 1997 and December 2000 identified 45 patients. Thirty-eight percent of patients had an antecedent febrile illness. Thirty-six percent of patients were diagnosed with idiopathic ATM. Eleven percent of patients were ultimately diagnosed with MS during follow-up and another 11% were thought to have possible MS. Additional etiologies were attributed to rheumatoid arthritis and hypersensitivity vasculitis each in a single patient.

However, in a retrospective case series of 21 ATM patients, methylprednisolone was more often associated with a good outcome (non-significant trend) (Kalita and Misra, 2001b). Nine patients received methylprednisolone treatment and 12 did not; 67% of methylprednisolone patients had a good outcome (Barthel index  $\geq 12$ ) compared to 33% of patients who were not treated with methylprednisolone. Patients with complete paraplegia who had evidence of denervation on electromyogram and unrecordable central motor conduction time to tibial SSEP had a poor outcome regardless of treatment. This study is limited by a small sample size and confounded by imbalance between the methylprednisolone-treated and untreated groups with respect to severity of myelitis and age at presentation.

### IDIOPATHIC ACUTE TRANSVERSE MYELITIS

In 2002, the Transverse Myelitis Consortium Working Group (TMCWG) proposed diagnostic criteria for idiopathic ATM based on expert opinion. The diagnostic criteria require clinical evidence of bilateral sensory, motor, or autonomic dysfunction referable to the spinal

cord, with a clearly defined sensory level that progresses to the nadir over 4–21 days from onset. Neuroimaging must eliminate structural etiologies. Evidence supporting an inflammatory etiology is also required either by MRI evidence of gadolinium enhancement within the cord or by CSF findings of pleiocytosis or elevation of the IgG index. In addition, there must be no history of radiation near the spine for 10 years, no serologic evidence of connective tissue disease or infection, no brain MRI abnormalities consistent with MS, no history of optic neuritis, and no clinical evidence of an anterior spinal artery infarct. If all diagnostic criteria are met, this is considered to be definite idiopathic ATM. A diagnosis of possible idiopathic ATM can be made if the inflammatory criteria (MRI or CSF) are not met. The intent of these criteria was to identify a relatively homogeneous patient cohort for the purpose of forwarding research (Cree and Wingerchuk, 2005).

When the TMCWG-proposed diagnostic criteria are applied to a cohort of patient with ATM, a relatively small proportion of patients meet criteria for idiopathic transverse myelitis. In a cohort of 288 patients with clinically diagnosed ATM from nine French hospitals, 45 patients (15.6%) met criteria for idiopathic transverse myelitis (de Seze et al., 2005). Of these patients T2 signal abnormality extended beyond two vertebral segments in 95% of patients. When performed, brain MRI and VEPs were normal. OCBs were identified in 8 patients (18%). Twenty-nine patients were described as having a good outcome and 16 as having a poor outcome. As in other case series, spinal shock at presentation was associated with a poor outcome. The authors concluded that the TMCWG criteria identified a relatively homogeneous group of patients.

However, not all case series found that patients meeting TMCWG criteria had a homogeneous idiopathic disease. In a retrospective study of 24 patients who met proposed TMCWG diagnostic criteria for ATM, and 21 patients who met diagnostic criteria for possible ATM, 5 patients (11%) developed MS during a mean follow-up of 3.5 years (Bruna et al., 2006). Women and younger patients were at increased risk for developing MS. The highest Rankin score reached was associated with a poor outcome. Sixty-seven percent of patients received methylprednisolone; a discernible benefit favoring treatment was not detected. Similarly, a retrospective review of medical records of cases of ATM who met TMCWG diagnostic criteria from a single university hospital in Pakistan identified 20 patients (Kahloon et al., 2007). In this series, 60% of patients ultimately were classified as having idiopathic ATM, 30% with parainfectious ATM, and 10% with MS. The medical record review was conducted prior to the development of NMO-IgG.

In contrast, in a population-based study of ATM using the TMCWG criteria at a single center in North Canterbury, New Zealand, none of 15 idiopathic ATM cases developed MS (Young et al., 2009). Patients were classified depending on whether lesions consistent with demyelination were identified on brain MRI. In addition, another category of myelitis was defined, “partial ATM,” that allowed inclusion of patients with myelitis who had unilateral signs or symptoms or did not have a clear sensory level. Sixty-one patients were included in the analysis and at a mean of 30 months of follow-up, 36% of patients met diagnostic criteria for MS. The subgroup of patients who most frequently developed CDMS was the “partial” ATM with brain lesions group (71%), followed by ATM patients with brain lesions (50%), and then followed by partial ATM without brain lesions (41%). None of the 15 patients classified as definite or possible idiopathic ATM developed MS. The overall incidence of ATM was 24.6 (18.2–31.1, 95% confidence interval (CI)) per million, considerably higher than prior estimates (Berman et al., 1981; Jeffery et al., 1993). However, when cases of partial ATM and ATM with brain lesions were excluded, the incidence was 6.2 (2.9–9.6, 95% CI). Anti-AQP4 antibody serologic assessment was not available at the time this cohort was identified.

### Immunology

CSF IL-6 levels may be useful both prognostically and diagnostically. CSF IL-6 levels are markedly elevated in patients with ATM (Kaplin et al., 2005). Furthermore, there is a strong correlation between CSF IL-6 obtained at the time of acute clinical evaluation and long-term disability. A similar correlation was observed in NMO patients (Icoz et al., 2010). Taken together, these studies demonstrate that IL-6 levels can be useful for distinguishing inflammatory from non-inflammatory myelopathies and may be useful prognostically. For these reasons CSF IL-6 should be measured in all patients presenting with ATM. Accurate measurement requires that the assessment be made prior to treatment with corticosteroids and that the assay be performed on acellular CSF supernatant.

The pathologic effects of IL-6 were investigated in tissue culture and animal experiments. (Kaplin et al., 2005). IL-6 induced cellular injury in organotypic spinal cord tissue cultures through activation of the JAK/STAT pathway that resulted in increased activity of iNOS and poly(ADP-ribose) polymerase. In contrast, brain organotypic cell cultures were not injured by incubation with IL-6 due to increased expression of soluble IL-6 receptor. Rats were intrathecally infused with IL-6 and developed a progressive inflammatory myelopathy with

demyelination and axonopathy. In contrast, intraventricular injection of IL-6 did not induce cerebral injury. The authors suggest that increased expression of soluble IL-6 receptors in rat brain antagonizes IL-6 signaling and thereby reduces IL-6 activation of the JAK/STAT pathway. The relative facility of IL-6 signaling may underlie the spinal cord’s particular susceptibility to inflammatory injury.

Because CSF IL-6 levels are elevated in transverse myelitis and because IL-17 is known to regulate IL-6 expression, IL-17 levels were measured in stimulated peripheral blood mononuclear cell supernatants from patients with transverse myelitis, MS, and other neurologic diseases, as well as healthy controls (Graber et al., 2008). Both IL-17 and IL-6 levels were increased in transverse myelitis patients relative to MS patients, patients with other neurologic diseases, and healthy controls. Additional experiments showed that stimulated peripheral blood mononuclear cell secretion of IL-6 induces astrocyte IL-6 production. These findings suggest that IL-17 and IL-6 production from peripheral blood mononuclear cells may induce astrocyte IL-6 production.

### Treatment

The initial treatment of ATM is determined by the presenting clinical symptoms, the appearance on MRI, and the findings on CSF. Once an inflammatory etiology is identified by CSF analysis, the clinician must decide whether or not infection is a likely etiology. Any systemic symptoms suggestive of infection must prompt a thorough infectious work-up (fever, chills, rash, etc.). If the clinical symptoms, CSF profile, and appearance on MRI are indicative of an autoimmune or inflammatory myelitis, serologies looking for systemic autoimmune or inflammatory diseases should be obtained and intravenous (IV) corticosteroids initiated. Although corticosteroid treatment appears to help resolve acute inflammation in the setting of MS and NMO-associated myelitis, not all studies have found a benefit of IV corticosteroids for all causes of myelitis (Kalita and Misra, 2001a, b; Pidcock et al., 2007). Several small studies in pediatric patients found improved outcomes with IV methylprednisolone (Sebire et al., 1997a; Lahat et al., 1998; Defresne et al., 2001a). A more recent study looking at ATM treatment in adults also found IV methylprednisolone beneficial, but not in patients affected by complete loss of motor and sensory function (Greenberg et al., 2007). In this study, 122 patients who presented with ATM were analyzed retrospectively for response to treatment. Patients were grouped in four treatment categories: IV methylprednisolone (IVMP,  $n=66$ ), plasmapheresis (PLEX,  $n=32$ ),

IV cyclophosphamide (CTX,  $n = 13$ ), and PLEX plus CTX ( $n = 11$ ). The decision as to which of these treatments was utilized was made on a per-patient, per-physician basis. Patients with recurrent ATM and with higher American Spinal Injury Association (ASIA) scores were more likely to receive CTX with or without PLEX. Patients with systemic autoimmune disease were more likely to receive CTX. Patients with longer spinal cord lesions were more likely to receive PLEX or CTX with or without PLEX. Patients treated with CTX, PLEX, or CTX plus PLEX appeared to experience greater degrees of neurologic recovery compared to patients treated with IVMP. However, these patients also had higher nadir EDSS scores compared to patients treated with IVMP alone. Patients with ASIA A scores (complete impairment of sensory and motor function) appeared not to benefit from treatment with IVMP or PLEX but appeared to benefit from treatment with CTX with or without PLEX. This study is limited by its retrospective design, lack of standardization with respect to assignment to treatment group, and the overrepresentation of patients with systemic autoimmune disease in the groups treated with CTX. Nevertheless, the observations suggest that, for patients with greater degrees of neurologic impairment, treatment with CTX with or without PLEX may be of greater benefit than IVMP or PLEX alone.

Prospective studies and randomized controlled trials are needed to determine whether the potential benefits of CTX and PLEX outweigh their known risks. Until convincing data regarding efficacy of these potentially harmful treatments are established, the decision as to which patient should receive these therapies will need to be made on a case-by-case basis. In contrast, even in the absence of convincing efficacy data, the potential benefits of high-dose glucocorticoids probably outweigh their risks, thereby justifying use in the majority of patients.

Plasma exchange was found to be helpful following failure of IV corticosteroid treatment, especially in patients with NMO or NMO spectrum disorders (independent of NMO-IgG positivity (Keegan et al., 2002; Paus et al., 2003; Bonnan et al., 2009) and in one patient in whom corticosteroids treatment was contraindicated (Yucesan et al., 2007).

IV immunoglobulin (IVIg) is also proposed to be helpful in corticosteroid-refractory myelitis associated with acute disseminated encephalomyelitis (ADEM) (Ravaglia et al., 2007). Nineteen patients with ADEM were treated with 2 g/kg IVIg after failure to respond to 6–8 grams of IVMP. The Scripps Neurological Rating Scale was used to assess outcome. Ten of 19 patients appeared to respond to IVIg with improvement of motor function. Milder disability and lower CSF albumin were

associated with a beneficial response. This study did not directly assess the effect of IVIg in the setting of myelitis; however, 23 of the 24 patients had myelitis as a component of encephalomyelitis ( $n = 2$ ), combined encephalomyelitis and radiculoneuritis ( $n = 9$ ), or myeloradiculoneuritis ( $n = 12$ ). It is possible that corticosteroid-refractory myelitis patients might benefit from treatment with IVIg.

In addition to PLEX and IVIg, uncontrolled case series suggest that use of immune suppressants including CTX (idiopathic transverse myelitis, SLE) (D’Cruz et al., 2004; Greenberg et al., 2007), rituximab (NMO) (Cree et al., 2005; Jacob et al., 2008a), and azathioprine (NMO), (Bichuetti et al., 2010) might be helpful.

An interesting case reported functional recovery in a patient with chronic myelopathy from ATM following intradural injections of acidic fibroblast growth factor (Lin et al., 2006). A total of 20  $\mu\text{g}$  was administered over a 15-month period by three intradural injections. During 18 months of follow-up after the first injection, the patient gradually improved clinically. This is the first case report that suggests use of a neurotrophic factor could be of benefit in patients with chronic myelopathy from ATM. Further investigation into intrathecal administration of neurotrophic factors seems warranted.

## PEDIATRIC ACUTE TRANSVERSE MYELITIS

Although more commonly described in adults, ATM also occurs in children. One estimate suggested that 280 children are affected by ATM annually in the United States (Banwell, 2007). Approximately 20% of ATM cases are diagnosed before the age of 18 (Kerr et al., 2005). Most studies of ATM in children are single-center retrospective case series, although a few population-based studies have been performed. ATM in children does not have a consensus definition and the TMCWG-proposed diagnostic criteria have not been applied consistently to studies of acquired myelopathy in children. As such, variation in prevalence and outcome across different studies is likely to be due, at least in part, to different inclusion and exclusion criteria.

Three population-based studies attempted to estimate the incidence of pediatric ATM. The Canadian Paediatric Surveillance Program estimated the incidence of ATM to be 0.2 per 100 000 children (Banwell et al., 2009). This survey found that ATM affected girls about as often as boys (0.81:1) and found no seasonal variation or peak age at symptom onset. A prospective study of pediatric ATM in the United Kingdom found a similar incidence of ATM in children under the age of 16 years – 0.172 per 100 000 per year (De Goede et al., 2010). This study was started prior to the publication of the TMCWG criteria

and patients were acquired based on a diagnosis of “acquired myelopathy.” Of the 41 cases identified, there were 25 boys and 16 girls. The substantial male predominance found in this study underscores the clinical differences between ATM and MS. Abnormalities on spinal cord imaging were identified in 27/39 children (69%). Twenty-six children underwent brain MRI and abnormalities were identified in 17 suggestive of either MS or ADEM. Outcomes with respect to further episodes of CNS demyelination consistent with MS were not described and follow-up was limited to only 6 months. In 27/41 patients a parainfectious etiology was thought possible. Hopefully, this study will continue to recruit, apply the TWCWG criteria, and provide the basis for longer-term follow-up of this important pediatric cohort.

Finally, a population-based study of ADEM in Fukuoka prefecture, Japan identified only 4 pediatric ATM patients. The estimated incidence was 0.11 per 100 000 person-years (Torisu et al., 2010). The mean age of onset was 6.3 years and 3/4 patients were girls. Two of the 4 patients had an antecedent febrile illness and none had a recent history of recent vaccination exposure.

### Observations from case series

As with adults, ATM overlaps with other CNS demyelinating diseases, including MS, NMO, and ADEM. The first case series of ATM in children described the clinical characteristics of 25 patients (Paine and Byers, 1953). The mean age of onset was 8 years (range 6 months to 15 years) and girls were affected twice as often as boys. Antecedent febrile illness was reported in 60% of cases with a mean time from infection to symptom onset of 10 days. Pain was present in 90% of children and sphincter dysfunction occurred in 95%. Thoracic sensory levels were present in the majority of patients (60%), followed by lumbar (26%) and cervical (11%). MS was eventually diagnosed in 4% of children.

The second published case series of pediatric ATM was a single-center retrospective case series and described the clinical characteristics of 21 children with acute transverse myelopathy (Dunne et al., 1986). Compressive, traumatic, and radiation-induced etiologies were excluded. Five children presented acutely and 16 presented with progressive symptoms. A midsummer seasonal distribution was noted. A bimodal age distribution was also present, with peak incidences in children under 4 and adolescents. An antecedent illness was identified in 8/21 children (67%). Twelve of 21 patients (57%) presented with pain. In addition to motor and sensory impairments consistent with myelopathy, bladder dysfunction occurred in 18/21 (86%) patients and constipation in 9/21 (43%) patients. None of the patients developed MS.

Another single-center (Hôpital de Bicêtre, Paris, France) retrospective case series described the clinical characteristics in 22 children with ATM (Defresne et al., 2003). The mean age of symptom onset was 7 years and the ratio of boys to girls was 0.85. Pain (88%) and fever (56%) were the most common presenting symptoms and a history of an antecedent illness was found in 58%. Optic neuritis was present in 4 patients consistent with NMO, MS, or ADEM, although at 1 year of follow-up MS and NMO were not diagnosed in any patient.

Transverse myelitis often can be the presenting manifestation of MS or ADEM in children. In a study of 296 children presenting with an initial CNS demyelinating event, 42 children presented with transverse myelitis, although details of the inclusion/exclusion criteria were not provided (Mikaeloff et al., 2004). Of these, 13 (30%) were eventually diagnosed with MS, 2 (5%) were diagnosed with monophasic ADEM, and 27 (64%) remained monosymptomatic during  $2.9 \pm 3$  years of follow-up (range 0.5–14.9 years). This study did not examine the predictive value of abnormal brain MRI scans based on clinical presentation.

Another single-center (Johns Hopkins Medical Institutions) retrospective case series described the clinical characteristics and outcomes of 47 children with ATM (Pidcock et al., 2007). The majority of children (42/47 or 89%) had a monophasic illness. Two patients had recurrent ATM, and one child developed SLE, NMO, and MS. The age of onset had a bimodal distribution, with 15/47 (38%) children presenting before the age of 3 and 23/47 (49%) children presenting in adolescence, similar to prior observations from another case series (Dunne et al., 1986). At nadir, 80% of children were paraplegic and required catheterization. An antecedent illness occurred in 47% of children and vaccination was administered within 30 days of symptom onset in 28%. However, 38% of children were in an age associated with vaccination. Anti-NMO IgG antibodies were not measured in this series. OCBs were present in only 2 patients (5%).

A review of the Japanese literature identified 50 children with ATM found similar demographics and outcomes to those of western pediatric ATM series. The following criteria were used: loss of motor and sphincter function, bilateral segmental sensory loss, radiographic or electrophysiologic confirmation, absence of compressive disease, and maximum severity reached by 4 weeks (Miyazawa et al., 2003). It is important to recognize that these criteria do not exclude myelopathies with catastrophic onset that could possibly be associated with spinal cord infarcts. Seventeen boys, 26 girls, and 7 children of unspecified sex were identified. The mean age was 8.0 years ( $SD \pm 3.8$  years). A preceding infection was identified in 22/33 patients (67%). Seventeen of 20 patients (85%) had an abnormal spinal cord MRI.



## Radiographic features

The imaging characteristics of pediatric ATM were described in a retrospective case series of 35 children who presented with either definite or possible ATM using the TMCWG criteria (Alper et al., 2011). Two patients developed optic neuritis and were seropositive for NMO-IgG and were excluded from the study. Six patients were excluded because MRI data were not available or were not obtained in a timely manner. None of the remaining 27 patients developed NMO or MS at a mean follow-up of 5.2 years. Twenty-one of 27 patients (28%) had abnormal spinal cord MRI scans and 7 patients had multifocal lesions. In all patients with MRI abnormalities, the central gray matter was hyperintense and in 7 patients there was white-matter involvement as well. Fourteen of 21 patients (67%) had spinal cord lesions  $\geq 3$  vertebral segments and the mean length was 6.4 segments. None of 22 patients tested had OCBs in their CSF. Two of 7 patients tested positive for NMO IgG and both these patients experienced relapses consistent with this diagnosis. The brain MRI studies were normal in all but one child. The disease course was monophasic in all 27 children. This study highlighted the distinct imaging characteristics of pediatric ATM affecting the central gray matter with or without also causing signal changes in white-matter tracts and having a preponderance to be longitudinally extensive.

## Comparison to ADEM

The clinical features of pediatric patients with ATM and ADEM with spinal cord involvement were compared at a single hospital (Royal Children's Hospital in Melbourne, Australia). A radiology database was used to identify 22 children with ATM that met TMCWG criteria and 12 with ADEM that met the consensus definition (Yiu et al., 2009). The mean age of onset for ATM was 7.5 years (range 4 months–15 years) and for ADEM was 7.2 years (range 2–14 years). Children with ATM were more likely to be hyporeflexic or areflexic whereas children with ADEM were more likely to be hyperreflexic. A sensory level was more often present in ATM than ADEM. Severe urinary retention requiring catheterization was similar between the two groups. Fever was more common in ADEM than ATM. All other clinical characteristics were similar. A good to normal outcome occurred in 82% of ATM and 100% of ADEM cases. Poor prognostic factors for ATM included flaccid paraparesis, respiratory failure, and age  $< 6$  months. That so many clinical features are common to ATM and ADEM with spinal cord involvement suggests that ATM might be a localized form of ADEM. However, histopathology of ATM and ADEM cases was not

available for comparison. Thus it is possible that the two conditions simply share common clinical manifestations but are unrelated pathophysiologically. Overlap of ATM with acute axonal polyneuropathy has also been reported in a single case (Howell et al., 2007) and peripheral nervous system involvement also occurs in ADEM (Bernard et al., 2008).

## Possible infectious etiologies

That pediatric ATM might be triggered by infection is suggested by the high frequency of antecedent illnesses reported in case series and population-based studies. In one small case series, putative infectious triggers were identified in 5/6 cases. This study utilized a retrospective chart review to identify 6 patients with ATM from a pediatric neurology database of 3159 patients in Cape Town, South Africa (Govender et al., 2010). The median age was 6.5 years (range 5–10) and there were two boys and four girls. Antecedent infections occurred in five children and included herpes simplex virus 1, cytomegalovirus, Epstein–Barr virus, and *Mycoplasma pneumoniae*. Diffuse involvement of the spinal cord on MRI including gray- and white-matter structures was present in all children. All children received treatment with corticosteroids and recovery was complete in 3/6.

A specific infectious etiology was identified in two other studies. In a UK population-based study an infection was found in 3/41 patients – one case each of influenza A, influenza B, and human herpesvirus 6 (De Goede et al., 2010). Lastly, in a Chinese case series an infectious etiology was identified in four cases: *Mycoplasma pneumoniae* (1), varicella-zoster (1), and Epstein–Barr virus (2) (Shian and Chi, 1994). That no single infectious cause was found in these studies suggests either that multiple infectious agents can trigger ATM or that infection with these common organisms is coincidental. Infections associated with ATM are listed in Table 28.2.

Based on the experience with acute inflammatory demyelinating polyneuropathy, investigators in India sought to determine whether *Campylobacter jejuni* and subsequent development of anti-GM1 antibodies might be associated with pediatric ATM (Kalra et al., 2009). This prospective study examined the possible association of anti-GM1 antiganglioside antibodies in 15 children with ATM and 15 age- and sex-matched controls. ATM was defined as: (1) no prior neurologic illness; (2) acute-onset bilateral spinal cord dysfunction; and (3) absence of other plausible etiology by MRI. The mean age was 7.9 years and the male-to-female ratio was 1.5:1. Sixty percent of children had a preceding illness (either gastrointestinal or upper respiratory tract infection). Stool cultures for *C. jejuni* were negative. One patient had positive IgG and IgM antibodies.

Anti-GM1 ganglioside IgG antibodies were present in 7/15 patients (46%) compared to 1/15 controls (6.6%,  $p=0.035$ ). Spinal cord MRI was abnormal in all children, with 13/15 having longitudinally extensive lesions. All children were treated with corticosteroids. By 1 year, eight children completely recovered, four partially recovered, and three remained non-ambulatory. Seven children had persistent urologic dysfunction. None of the children developed MS or NMO at 1 year of follow-up, although NMO-IgG was not evaluated. The authors speculated that antiganglioside antibodies could have a pathogenic role in some patients with ATM.

### Outcomes and treatment

Children affected by acute transverse myelopathy may have a somewhat better prognosis compared to adults. In the first reported pediatric cases series of ATM, recovery was good to complete in 15/25 cases, whereas 4/25 failed to recover function (Paine and Byers, 1953). However, 38% were afflicted by chronic bladder dysfunction. The second pediatric ATM case series found an overall good prognosis in the majority of cases (12/21) (Dunne et al., 1986). A poor outcome in 5 patients was associated with severe deficits evolving over 3 hours, suggestive of spinal cord ischemia, although without the expected sparing of dorsal column sensory function. Recovery occurred within 3 months and further improvement did not occur after 6 months, except in 1 patient. Twelve had a normal or good recovery and 9 had a fair or poor recovery. The patients with acute catastrophic presentations had poor recoveries, with 2 patients permanently wheelchair-bound. Fourteen patients were treated with corticosteroids and no overt improvement was observed following treatment.

A Chinese case series of seven children with transverse myelitis found that recovery was complete in 6/7 (86%) within 1–6 months of the acute illness (Shian and Chi, 1994). The mean age was 8.6 years and five boys and two girls were included in this series. An infectious etiology was identified in four cases: *Mycoplasma pneumoniae* (1), varicella-zoster (1) and Epstein–Barr virus (2), perhaps suggesting that infectious etiologies of ATM were predictive of good recoveries.

The population-based study from Fukuoka prefecture in Japan also reported full recovery in all 4 patients; 3 patients received corticosteroids and 1 received IVIG (Torisu et al., 2010). In the review of the Japanese case literature, several clinical features were identified that favored a better prognosis and included older age at symptom onset, hyperreflexia, and the presence of Babinski signs signifying corticospinal tract involvement without anterior horn cell injury. Use of corticosteroids

was not associated with a more favorable outcome (Miyazawa et al., 2003).

The population-based UK study also reported generally favorable prognosis. Outcomes were normal in 19, good in 8, fair in 3, and poor in 6 (De Goede et al., 2010). Factors associated with a poor outcome included flaccid paraplegia, sphincter impairment, and reaching a nadir within 24 hours of onset. Factors associated with a good prognosis included preceding infection (similar to the Chinese case series), recovery in <7 days, age <10 years, and a lumbar versus thoracic or cervical level. Thirty patients received treatment with high-dose corticosteroids and, of these, 7 (23%) were left with a fair or poor outcome. Because the majority of patients were treated with corticosteroids, and confounding by the indication to treat, any conclusions with regard to corticosteroid treatment efficacy cannot be reached from this study.

That treatment with high-dose corticosteroids might improve neurologic recovery was suggested by several studies from the Hôpital de Bicêtre. Five children with acute transverse myelopathy were treated with IV methylprednisolone and compared to a historic group of 10 untreated patients (Sebire et al., 1997b). Treatment with methylprednisolone was associated with a shorter median time to independent ambulation (23 versus 97 days). Furthermore, the proportion of patients with a full recovery within 12 months was significantly higher (80% versus 10%) in the methylprednisolone-treated group. The authors suggested that high-dose methylprednisolone might be an effective treatment for pediatric acute transverse myelopathy. A follow-up study of 12 children with ATM, that also used historic controls found similar results (Defresne et al., 2001b).

The Hôpital de Bicêtre series of 22 patients similarly reported a generally favorable prognosis and also found clinical features that were predictive of poor recovery. Thirty-one percent of patients recovered completely, minimal sequelae were present in 25%, and mild to severe sequelae were present in 44% (Defresne et al., 2003). A poor prognosis was associated with paraplegia and a nadir was reached within 24 hours (suggestive of vascular compromise), similar to the observations from other case series (Dunne et al., 1986; De Goede et al., 2010). This series found that use of high-dose corticosteroids was associated with a favorable outcome. The longitudinal extent of spinal cord involvement appears not to be correlated with recovery because a case series of 3 patients with longitudinally extensive ATM described complete recovery following treatment with high-dose corticosteroids (Andronikou et al., 2003). Based on these studies, high-dose corticosteroids became the standard of care for treatment of pediatric ATM.

However, favorable outcomes were not reported in all case series. In the Johns Hopkins Medical Institutions



study, two children died from respiratory failure (Pidcock et al., 2007). At a mean time of follow-up of 3.2 years, 40% of children were left wheelchair-bound, 80% had severe bladder symptoms, and 27% required assistance for activities of daily living. Poor outcomes were associated with a longer time from symptom onset to diagnosis, requirement for respiratory support, higher WBC counts in CSF, higher sensory levels, longitudinal extent of the lesion, and younger age of onset.

### Urologic complications

A common theme to most studies of pediatric myelitis is that many children experience long-term urologic dysfunction despite treatment. A retrospective case series of 21 children (mean age 5.4 years) with ATM found that major residual sphincter impairment was present in 23% of patients, minor sequelae were present in 39% of patients, and normal function was restored in 38% of patients (Leroy-Malherbe et al., 1998). Factors associated with a favorable recovery included early return of motor function and early management of bladder dysfunction. Another case series found that residual bladder dysfunction was present in the majority (4/5) of children with ATM 2–10 years after onset (Cheng et al., 1999). A single-center retrospective case series of 10 pediatric ATM patients found that residual bladder dysfunction occurred in all patients and that antispasmodic treatment was only partially effective in the majority of patients. Antispasmodic therapy completely resolved symptoms in only 4 patients (Ganesan and Borzyskowski, 2001).

The high frequency of sphincter control impairment was found in another retrospective medical record review of 22 children with ATM in which 19/22 children (86%) were affected by bladder dysfunction. Furthermore, 17/22 (77%) were affected by bowel dysfunction, with a mean follow-up time of 7.2 years (Tanaka et al., 2006). Motor recovery and absence of leg spasticity were not paralleled by normal sphincter function. When initiated within 2 years of onset, clean intermittent catheterization appeared to preserve bladder compliance and decreased upper urinary tract disease. In contrast, another study of 14 children found that motor and bladder outcomes in ATM were correlated (DaJusta et al., 2008). Children who had residual motor impairment tended also to have residual bladder dysfunction.

### Acute myelopathy

A consistent feature associated with a poor prognosis of pediatric myelopathy is acute onset (Dunne et al., 1986; Defresne et al., 2003; De Goede et al., 2010). A case series of 5 adolescent patients who presented with rapid myelopathy with maximum deficit between 10 minutes and 6 hours also experienced poor recovery

(Wilmshurst et al., 1999). MRI showed involvement of the anterior cord in all patients and electrophysiologic studies showed drop-out of anterior horn cells in 5/5 patients studied. None of the patients underwent spinal angiography. The authors speculate that fibrocartilaginous emboli might be causative in some cases (Toro et al., 1994).

## IDIOPATHIC DEMYELINATING DISEASE

### Multiple sclerosis

The most common cause of myelitis is MS. Whereas MS infrequently presents with acute transverse myelitis, partial myelitis is one of the most common presentations of bout onset MS. Furthermore, the transition from relapsing MS to progressive MS is characterized by a clinical myelopathy in the majority of patients. Many patients who present with myelopathies of unclear etiology will ultimately be diagnosed with MS.

For example, in a case series of 264 patients that included all forms of myelopathy, 72 patients had myelopathies of unknown etiology (Marti-Fabregas et al., 1989). Clinical follow-up at a mean of 28 months was available for 57 patients. Twenty-three had either definite or probable MS, 7 patients had monophasic myelitis without developing MS, 4 amyotrophic lateral sclerosis, 1 *Brucella*, and 1 cervical spondylosis. Twenty-one cases remained classified as myelopathy of unknown etiology.

Although the hallmark of MS is multifocal disease, meaning signs and symptoms referable to multiple areas of the CNS, some patients experience clinical involvement restricted to the spinal cord. Case series in the pre-MRI era describe spinal cord-restricted MS characterized by recurrent myelitis. In a survey of 269 MS patients in Israel identified by chart review between 1955 and 1959, relapsing spinal cord-restricted disease occurred in 18 of 269 patients (7%) (Leibowitz et al., 1967). In another case series, 37 of 1271 MS patients (3%) experienced recurrent symptoms solely referable to the spinal cord (Poser et al., 1978).

As with brain MRI, spinal cord imaging in MS greatly expanded the understanding of the anatomic characteristics of the disease in vivo. The MRI features of spinal cord MS plaques were summarized in a case series of 68 MS patients who underwent spinal cord imaging (Tartaglino et al., 1995). Of 124 spinal cord plaques identified, 112 were no more than two vertebral segments in length. Plaques  $\geq 3$  vertebral segments were associated with cord swelling or atrophy. A total of 108 plaques were identified on cross-sectional imaging. Eighty-one percent occupied less than half the cord. Eighty percent of plaques were distributed in the dorsal and lateral portions of the cord and 20% were distributed in the anterior cord. These observations are consistent with the

impression that most spinal cord MS plaques are <3 vertebral segments in length, tend to affect restricted portions of the spinal cord rather than the entire cross-sectional area of the cord, and in the majority of cases involve the dorsal column. Although this study has certain limitations, e.g., not all patients received both cervical and thoracic spine studies and contrast was not administered for all scans, its description of the radiographic features of MS spinal cord plaques is consistent with clinical experience. Despite myelitis being a major manifestation of MS, spinal cord imaging has not received the comparable technical attention that brain MRI has enjoyed in MS clinical research. Consequently, fewer advances in spinal cord imaging have been made compared to brain MRI in MS and the quality of spinal cord imaging is often inferior in comparison.

#### CLINICALLY ISOLATED SPINAL CORD SYNDROME AND RISK OF MS

That partial myelitis is often the heralding manifestation of MS was shown in several case series. In recent clinical trials of patients presenting with a clinically isolated syndrome (CIS) who also had abnormalities on brain MRI consistent with MS, spinal cord presentations constituted 19–22% of cases (Beck et al., 2002; Polman et al., 2008). These and other studies showed that disease-modifying therapies used for the treatment of MS were effective in delaying the time to a second clinical attack in patients who presented with CIS and who had brain MRI scans suggestive of MS (Filippi et al., 2004; Comi et al., 2009).

The prognostic utility of abnormal brain MRI scans was first demonstrated in a prospective observational cohort study of CIS patients who presented with either a brainstem or spinal cord CIS (Miller et al., 1989). Thirty-three patients with a clinically isolated spinal cord syndrome were identified. All patients underwent baseline brain MRI. Eighteen of 33 (56%) had multifocal white-matter lesions at baseline. Of the 18 patients with multifocal white-matter brain MRI lesions, 13 patients (72%) were eventually diagnosed with MS using combined clinical/MRI criteria at an average of 14.1 months of follow-up. In contrast, of the 15/33 patients (44%) who had a normal brain MRI at baseline at an average of 18.2 months of follow-up, only 1 patient (7%) had a relapse and the same patient developed new lesions on brain MRI. The relative risk for development of MS for patients with spinal cord CIS and abnormal baseline brain MRI was 36 times that for patients with normal baseline brain MRI ( $p < 0.001$ ). The caveats of this important study are the potential for referral bias and a relatively short period of follow-up (under 2 years).

A follow-up study of the same cohort found similar results (Morrissey et al., 1993b). Fifty-nine percent of patients with abnormal brain MRI and 9% with a normal brain MRI developed CDMS. In this study the odds of developing CDMS (as opposed to the combined clinical/radiographic endpoint used in the earlier study) with spinal cord CIS and abnormal brain MRI at presentation were 15.7 times the odds of developing CDMS with spinal cord CIS and normal brain MRI at presentation.

A small case series of 15 spinal cord CIS patients that excluded patients with ATM also found that white-matter lesions on brain MRI were prognostically useful (Ford et al., 1992). Of the 15 cases of partial myelitis, 12 (80%) had abnormal brain MRI scans. During an average follow-up period of 38 months, 11 of these 12 patients (92%) developed CDMS. One patient with an abnormal brain MRI did not develop CDMS during 53 months of follow-up. Of the 3 patients with a normal brain MRI, 1 patient developed MS and the other 2 did not. Thus the estimated risk for developing MS for a partial myelitis patient with an abnormal brain MRI is 92%, whereas, the estimated risk for a partial myelitis patient with a normal brain MRI is 33%. Despite the small numbers and retrospective nature of this case series, this study illustrated the utility of brain MRI in patients who present with a partial myelitis. This study is also consistent with subsequent work that showed that partial myelitis is often associated with an abnormal brain MRI and is the initial presentation of MS in the majority of cases.

Several small case series found different estimates for the risk of developing MS following myelitis. In a series of 24 patients who presented with partial myelitis, 22 (92%) developed CDMS, 1 (4%) developed probable MS, and 1 (4%) developed NMO during up to 13 years of follow-up (Simnad et al., 1997). Fourteen of these 24 patients presented with spinal cord-restricted symptoms and, of these, 11 (79%) had an abnormal brain MRI and 3 patients (21%) had a normal brain MRI. All 3 patients with a normal brain eventually developed CDMS. In contrast, another case series found that only 1/15 patients with spinal cord CIS and a normal brain MRI developed MS during 14 months of follow-up (Miller et al., 1989). In a third case series, 4 of 12 patients who presented with spinal cord CIS who had normal brain MRI scans developed CDMS after a mean of 4.1 years (range:  $1.5 \pm 10.4$  years) (Bashir and Whitaker, 2000).

An early prospective study designed to determine the long-term risk of MS studied 81 patients with CIS who underwent a brain MRI study at presentation and were followed for 10 years (O'Riordan et al., 1998). Twenty-three patients presented with spinal cord CIS. Two of 8 patients (25%) with a normal baseline brain MRI developed MS compared to 10/15 (67%) patients with an abnormal baseline brain MRI. The odds ratio for

developing MS is approximately 2.6-fold higher for patients with abnormal brain MRI scans relative to those with a normal brain MRI, although this result was not statistically significant, as would be expected from such a small study. Important considerations that limit the interpretation of these studies are their small sizes, retrospective study designs, varying duration of follow-up, and different definitions of AM used by the study inclusion criteria.

VEPs and brainstem auditory evoked potentials (BAEPs) can be used to look for evidence of disseminated disease in patients who present with myelopathy that could herald the onset of MS. As part of a larger study of patients with possible MS, 32 patients with clinical symptoms restricted to the spinal cord underwent VEPs, BAEPs, and SSEPs (Hume and Waxman, 1988). Of these 32 patients, 14 (44%) had either abnormal VEPs or BAEPs, indicating disseminated disease. At 2.5 years of follow-up, only 4 patients developed CDMS and all 4 had abnormal VEPs or BAEPs. Although MRI was not performed in all patients, abnormal evoked potentials were found in 5 of 8 patients who had normal brain MRIs, suggesting that in some patients electrophysiologic studies could provide complementary evidence of disseminated disease.

That at least some patients who present with acute myelopathy do not develop MS was found in a case series of 42 patients at the University of Milan, Italy, who presented with myelopathy of unclear etiology (Filippi et al., 1990). Most of the patients described in this series presented with progressive myelopathy; however, 13 patients were included who presented with an acute spinal cord syndrome with either motor and/or sensory involvement but did not experience a second clinical attack, with a mean time of follow-up of 13 years (range 3–30 years). Four of these patients had normal brain MRI studies, VEPs, BAEPs, and CSF. Thus, at least some patients who present with spinal cord CIS appear to have a true CIS and do not develop evidence of multifocal disease or progression consistent with MS. Unfortunately, patients who presented with spinal cord CIS and then developed MS (second attack) were not included. Therefore the risk of MS based on acute spinal cord presentations could not be inferred by this study.

The negative prognostic value of a normal brain MRI in spinal cord CIS patients may be enhanced by CSF analysis that does not show intrathecal synthesis of gammaglobulins. Twenty-seven patients presenting with clinical myelopathy of unclear etiology underwent comprehensive evaluation at presentation to determine the diagnostic and prognostic value of neuroimaging, electrophysiologic assessments, and CSF analysis (Martinelli et al., 1995). The inclusion criteria were similar to those of another study of ATM (Jeffery et al.,

1993). Spinal cord MRI was abnormal in 15 patients (56%). Patients were followed for an average for 24 months (range 6–60 months). Six patients (22%) were diagnosed with CDMS after experiencing supraspinal involvement. The remaining 21 patients did not experience further clinical relapses. Five of these patients had abnormalities on brain MRI consistent with CNS demyelination and two of these patients had OCBs in their CSF. Sixteen patients had normal brain MRI scans and, of these patients, 9 had normal spinal cord MRI scans. Only 1 patient had OCBs present in the CSF. The negative predictive value of having a normal brain MRI scan and CSF without OCBs present was 100% in this case series. Clinical characteristics overrepresented in the spinal cord CIS group relative to the MS group included pain and sudden onset. Absent cortical SSEPs or motor evoked potentials were significantly more common in patients who experienced either a partial or no recovery, demonstrating the prognostic utility of SSEPs in AM.

Another prospective study of patients with acute partial myelitis examined the predictive value of clinical signs, spinal cord and brain MRI, CSF, and VEPs for development of MS in 55 patients (Cordonnier et al., 2003). After a mean follow-up of 35 months (range 12–86), 30 were diagnosed with MS. Sensory symptoms, posterior lateral spinal cord lesions, abnormal brain MRI, and OCBs in CSF were predictive of the MS diagnosis. The number of spinal cord lesions on MRI was predictive of a poor outcome for patients who developed MS and was correlated with a higher number of relapses.

To further address the question of the risk for developing MS in patients who have normal brain MRI scans at the time of myelitis presentation, 30 spinal cord CIS patients were followed prospectively for a mean of 61 (range 24–126) months (Scott et al., 2005). Only 3 patients (10%) experienced second clinical relapses that led to a diagnosis of CDMS within 5 years of disease onset. All 3 patients also developed cerebral MRI lesions; however, OCBs were present in only 1 patient at the time of the heralding myelitis. Interestingly, in this cohort 14 patients (46.6%) experienced further spinal cord relapses, raising alternate diagnostic possibilities of NMO spectrum disorder, recurrent transverse myelitis, as well as reconsideration of MS. In 13 patients (43%) myelitis remained a monophasic disease.

A study that is particularly useful for informing patients who present with spinal cord CIS and have no evidence of dissemination in space by MRI as to their risk for developing MS followed 58 spinal cord CIS, who had a normal brain MRI and VEPs, prospectively for a mean of 61.8 ( $\pm 2.6$ ) months (Perumal et al., 2008). Patients with longitudinally extensive myelitis were excluded from this study and, although the study

described the cases of myelitis as “ATM,” the entry criteria allowed for inclusion of partial myelitis. During this time 17 patients (22%) developed MS during the first 2 years of follow-up and no patients developed MS after 2 years of follow-up. Abnormal intrathecal synthesis of gammaglobulins was found in 100% of patients who developed MS and in 37% of patients who did not develop MS ( $r=0.6$ ,  $p<0.001$ ). Recurrent myelitis was not described in any patient and spinal cord CIS remained a monophasic illness in 78% of patients. This study also underscores the utility of CSF analysis in helping further stratify individual patient risk.

A retrospective case series of 73 patients with acute partial myelitis were followed for a mean of 46 months (range 12–90 months) (Sellner et al., 2008). Thirty-two patients were diagnosed with MS (44%), whereas spinal cord CIS remained a monophasic event in 35 patients (48%) and recurred as relapsing myelitis in 6 patients (8.2%). Patients who developed MS were more likely to have a family history of MS, a higher EDSS at onset, and to have lesions on brain MRI compared to patients who maintained a diagnosis of spinal cord CIS.

The largest study of partial myelitis to date examined the predictive value of brain MRI and CSF with respect to the risk for MS in 114 patients with partial myelitis. Partial myelitis was confirmed by spinal cord imaging (Ruet et al., 2011). Compressive, vascular, and acute transverse etiologies (including NMO) were excluded. During the mean time of follow-up of  $4.0 \pm 1.9$  years, 78 patients (68%) developed MS. Importantly, no partial myelitis patient received disease-modifying therapy until after the MS diagnosis was confirmed. Thirty-six patients (32%) did not experience a second relapse during follow-up, with 78% of patients followed for at least 2 years. Patients who developed MS were younger and lacked bladder involvement at the time of myelitis compared to patients who maintained a diagnosis of spinal cord CIS. In addition, patients who developed MS were more likely to have  $\geq 2$  cord lesions on MRI,  $\geq 9$  brain lesions,  $\geq 3$  periventricular lesions, and intrathecal IgG synthesis compared to patients who maintained a diagnosis of spinal cord CIS. Multivariate logistic modeling identified three predictors of MS: (1) age  $\leq 40$  years at onset; (2) inflammatory CSF; and (3)  $\geq 3$  periventricular lesions on brain MRI. In this dataset, these variables were more accurate than the proposed dissemination in space International Panel criteria for MS (Polman et al., 2005). As with most studies of partial myelitis, the conclusions of this study are limited by its retrospective nature.

That spinal cord CIS patients with abnormal brain studies are at high risk for experiencing a second clinical attack was confirmed in a subgroup analysis of the CHAMPS clinical trial, a randomized, blinded, placebo-controlled study of the impact of once-weekly

interferon  $\beta$ -1a on the risk of conversion from an initial demyelinating event to CDMS (Beck et al., 2002). Eighty-three enrolled patients presented with spinal cord CIS and had two or more brain lesions typical of MS. Forty-one received interferon  $\beta$ -1a and 42 received placebo. Because of the favorable results of an interim analysis, the study was stopped 22 months after the last patient was enrolled. At the end of the study 19/42 placebo-treated patients developed CDMS (Kaplan–Meier cumulative probability 44%) and, using a combined MRI/CDMS outcome measure, 33/42 developed MS (Kaplan–Meier cumulative probability 82%). In contrast, 9/41 patients receiving interferon  $\beta$ -1a developed CDMS (Kaplan–Meier cumulative probability 19%), and 21/41 patients developed MS using the combined MRI/CDMS outcome measure (Kaplan–Meier cumulative probability 55%). Thus this study showed that, for spinal cord CIS patients with an abnormal brain MRI scan, the 2-year risk of a second relapse was 82%. Furthermore, treatment with interferon significantly reduces this risk.

In contrast to partial myelitis, patients who present with ATM are at lower risk for being eventually diagnosed with MS. That patients who are ultimately diagnosed with typical MS rarely experience ATM was supported by a case series of Japanese patients with CNS demyelinating disease (Fukazawa et al., 1990). Sixty-two Japanese MS patients were separated into two groups: those with a history of ATM (16) and those without (46). Patients with a history of ATM were significantly less likely to have brainstem, cerebellar, or cerebral clinical or MRI involvement than patients without a history of ATM. This study supports the proposition that there is a discrete form of opticospinal MS in Japanese (and other Asian) patients that has predominant involvement of the optic nerve and spinal cord. A limitation of this and other studies of Japanese opticospinal MS is that many of these patients, in retrospect, probably had NMO, as evidenced by more recent case series that showed that many Japanese opticospinal MS patients will test seropositive for the anti-AQP4 antibody (Lennon et al., 2004).

In a retrospective study of 24 patients who met proposed TMCWG diagnostic criteria for ATM and 21 patients who met diagnostic criteria for possible ATM, 5 patients (11%) developed MS during a mean follow-up of 3.5 years (Bruna et al., 2006). Women and younger patients were at increased risk for developing MS. The highest Rankin score reached was associated with a poor outcome.

Taking these studies together, the majority of patients with partial myelitis have abnormalities on brain MRI that are consistent with MS and will experience additional relapses. A minority of patients presenting with AM have normal brain MRI at the time of presentation.



Although some of these patients will experience other clinical relapses consistent with MS, their overall risk appears to be substantially less than that of patients who have MS-like lesions on brain MRI. Even with extended follow-up, some patients will not experience evidence of an ongoing disease process. Such patients have a true “clinically isolated syndrome,” meaning a one-time neurologic CNS inflammatory event. Patients presenting with ATM carry a substantially lower risk for developing MS. In addition to heralding the onset of NMO, some patients with ATM experience a monophasic disease.

### PROGRESSIVE MYELOPATHY AND RISK OF MS

Although partial myelitis is strongly suggestive of MS, patients presenting with progressive myelopathy can pose a significant diagnostic challenge, especially in the pre-MRI era. Several case series describing chronic progressive myelopathy had to rely on either long-term clinical follow-up or autopsy in order to establish an MS diagnosis. In a series of adult-onset chronic spastic paraplegia, 10 of 52 cases from physicians' records and 11 of 35 autopsied cases were diagnosed with MS (Marshall, 1955). In a later case series, MS was the leading cause of patients presenting with spastic paraplegia and affected 166/255 patients (65%), followed by amyotrophic lateral sclerosis and malignancies (Hubbe and Mouritzen Dam, 1973). Only 22 patients in this series remained without a diagnosis.

As with relapsing forms of MS, VEPs and CSF ophthalmologic examination are helpful in establishing a diagnosis of MS (Bynke et al., 1977). In a case of chronic myelopathy, 13 of 24 patients (54%) had laboratory-supported evidence of MS with disseminated demyelination. With the development of CT imaging, additional evidence of disseminated disease could be found in patients with chronic progressive myelopathy (Paty et al., 1979). In a series of 72 patients, CT imaging showed cortical atrophy in 38 patients, slightly outperforming VEPs, blink responses, and CSF analysis for laboratory-supported evidence of MS. Although the majority of patients had at least one abnormal test, and 44% of patients had OCBs and abnormal VEPs consistent with MS, 17% of patients with chronic progressive myelopathy had normal values for all tests.

Several case series in the pre-MRI era describe spinal cord-predominant forms of MS. In a survey of 269 MS patients in Israel identified by chart review between 1955 and 1959, spinal cord-restricted disease was described in 75/269 patients (29%) (Leibowitz et al., 1967). Of these 75 patients, 57 (76%) had a progressive course. Of the 57 with a progressive course, 20 cases of a pure pyramidal syndrome were included (clinically reminiscent of

primary lateral sclerosis). Thus, of all cases of MS, 22% had a spinal progressive course. The mean age of onset of the spinal progressive course was older than that for all other cases (37.4 versus 30 years), consistent with the observation that primary progressive MS (PPMS) patients have an older age of onset compared to bout onset patients.

In another case series of 1271 MS patients, 109 (8.6%) experienced symptoms solely referable to the spinal cord (Poser et al., 1978). As in the case series from Israel, the mean age of onset for the spinal cord-restricted cases was older (35.4 versus 31.1 years for the entire series). Of the spinal cord-restricted cases, 36% had a progressive course from onset. In contrast, the non-spinal cord-restricted cases, i.e., multifocal cases, were less likely to have a progressive-from-onset disease course (17%). This observation is consistent with the clinical impression that patients with PPMS tend to experience progressive myelopathy from disease onset.

As with relapsing forms of MS, MRI substantially improved the ability to detect disseminated disease. In an early case series of myelopathy of unclear etiology, 7 patients presented with a progressive paraparesis (Edwards et al., 1986). Brain MRI and CSF analysis allowed diagnosis of PPMS in only a single case. In two other cases, the brain MRI was consistent with MS; however, the CSF was normal and PPMS was not diagnosed. In four cases, brain MRI studies were normal. CSF was abnormal in 2 of these 4 patients, suggesting an inflammatory etiology. Thus, of these 7 patients with a progressive myelopathy, 5 had evidence of either disseminated disease or inflammatory CSF. The diagnostic evaluation, including MRI, CSF, and evoked potentials, was unrevealing in 2 patients. A comprehensive evaluation for hereditary spastic paraplegias or adult-onset leukodystrophies was not described.

The utility of cranial MRI for diagnosis of MS was subsequently demonstrated in a case series of 20 patients with a myelopathy of undetermined etiology. Thirteen of the 20 patients had brain lesions consistent with MS. Ten of these 13 patients also underwent CSF analysis and OCBs were detected in 9. Similarly, VEPs were performed in 9 of the 10 patients who underwent CSF analysis and were abnormal in 5. This study suggested that cranial MRI was a more sensitive method for detecting evidence of disseminated demyelination than either CSF analysis or VEPs. Nevertheless, 3 patients in this series had normal brain MRI scans but had OCBs, suggesting that MS might be confined to the spinal cord in some patients. This study also showed that a diagnosis of PPMS can be established in the majority of patients with myelopathy of unclear etiology (Miska et al., 1987).

In the University of Milan case series, 29 of 42 patients presented with an insidious myelopathy with

either a motor or motor-sensory onset (Filippi et al., 1990). Thirteen patients (45%) met diagnostic criteria for PPMS. Six additional patients had brain lesions but were OCB-negative. These patients are likely to have MS despite the absence of OCBs; however, adult-onset leukodystrophies were not excluded. Thus, 66% of progressive myelopathies have either MS or (much less likely) a hereditary leukodystrophy. This study also demonstrated the utility of paraclinical studies, brain MRI scans, evoked potentials, and CSF analysis for OCBs in establishing, or ruling out, a diagnosis of MS.

Eleven of the 29 patients presented with a progressive pure motor myelopathy. Nine patients (82%) had abnormal tibial SSEPs, indicating involvement of sensory pathways. The 2 patients with normal SSEPs had disease duration of 19 and 30 years and did not develop MS, as evidenced by brain MRI studies without white demyelination, normal CSF, and normal BAEPs. Five of the 9 patients with abnormal SSEPs had either an abnormal brain MRI or abnormal VEP, demonstrating dissemination in space, and all of these patients had OCBs, confirming the diagnosis of PPMS. Thus, 45% of patients presenting with insidious motor myelopathy meet diagnostic criteria for PPMS. Interestingly, an abnormal SSEP in patients presenting with insidious-onset motor impairment did not add further diagnostic value to brain MRI and CSF studies. Nevertheless, a normal SSEP was helpful in effectively excluding MS in 2 patients.

Eighteen of the 29 patients presented with progressive mixed motor and sensory myelopathy and, of these, 13 (72%) had multiple brain lesions on MRI strongly suggestive of MS. OCBs were present in 8/18 (44%) patients; all of these had abnormal brain MRI studies. Five patients had multiple brain lesions but did not have OCBs; 3 of these patients had abnormal VEPs consistent with MS. VEPs also were abnormal in 1 patient who had a single lesion on brain MRI and did not have OCBs. BAEPs were abnormal in 2 patients who had normal brain MRIs and did not have CSF OCBs. Thus, of 18 patients who presented with a sensory-motor myelopathy, 8 (44%) filled diagnostic criteria for PPMS, with OCBs present in CSF. Eight other patients (44%) who did not have OCBs present in CSF had evidence of dissemination in space either by MRI or evoked potentials. Only 2 patients had disease restricted to the spinal cord and OCBs were absent in these 2 patients. These observations support the use of brain MRI studies as well as VEPs and BAEPs to document dissemination in space for patients presenting with motor and sensory myelopathy. Another smaller study of 19 patients made similar observations regarding a relatively greater representation of MS in patients presenting with chronic sensory and motor myelopathy versus pure motor myelopathy (Jeffery, 1996).

## Neuromyelitis optica

NMO is an inflammatory, demyelinating, chronic CNS disease characterized by recurrent severe attacks of myelitis and optic neuritis. The disease was first described in the late 18th century and was the source of much debate as to whether it constituted a distinct disease or was a form of MS. Recently, a biomarker for NMO, NMO-IgG, was identified. This autoantibody binds to AQP4, a water channel ubiquitously expressed throughout the CNS and in the stomach and kidneys. Because this autoantibody is reasonably sensitive and highly specific for NMO, it is useful diagnostically in distinguishing NMO from typical MS. A pathogenic role for the autoantibody is now established; however, additional as yet to be elucidated mechanisms are required for disease pathogenesis. Apparently successful treatments with plasmapheresis for acute flares and B-cell depletion for maintenance of remission support the concept that NMO may be, at least in part, a humorally mediated disease.

The NMO-IgG was discovered at the Mayo Clinic through recognition of an unusual immunohistochemical staining pattern using a rat brain slice preparation to identify novel paraneoplastic autoantibodies (Lennon et al., 2004). A distinct pattern characterized by staining of the subpial and Virchow–Robin spaces of unclear etiology was recognized. When serum from an NMO patient was found to have the same staining pattern, the researchers obtained serum samples from additional NMO patients from North America and a cohort of Japanese patients with opticospinal MS. Thirty-five of 45 patients who had NMO based on clinical criteria were found to have the same unique staining pattern (73% sensitivity). An additional cohort of 14 patients whose serum had undergone paraneoplastic antibody assessment and were known to have this staining pattern was retrospectively identified and their medical records were obtained. Remarkably, every case reviewed was found to have a history consistent with NMO or recurrent transverse myelitis. Subsequent investigation in a cohort of 22 patients who presented with optic neuritis and myelitis, but who were considered to have MS and not NMO, identified only 2 patients as testing positive for the antibody (91% specificity). Thus, without knowing the target for the antibody, a biomarker for NMO was found.

Clues to the antigen recognized by the antibody came from the immunohistochemical staining pattern. The antibody stained the abluminal face of cerebral microvessels and the pericapillary regions of astrocytes. Furthermore, it colocalized with laminin. The antibody also recognized distal urine-collecting tubules in the renal medulla and parietal cells in the gastric mucosa.



This distribution pattern led to the hypothesis that the antigen recognized by the NMO-IgG was AQP4, a water channel (Agre and Nielsen, 1996). AQP4 is the predominant water channel in the CNS (Tait et al., 2008). It is expressed at high concentrations in astrocyte foot processes facing microvessels, interneuronal synaptic junctions, and ventricular ependyma. It is coexpressed with the potassium channel Kir4.1, is associated with the dystrophin protein complex, and regulates water flux between brain and blood and brain and spinal fluid (Amiry-Moghaddam et al., 2004). AQP4 appears to be crucial for elimination of interstitial water, and deletion of AQP4 appears to exacerbate vasogenic edema.

That the NMO-IgG bound to AQP4 was demonstrated by the following series of experiments (Lennon et al., 2005). First, NMO-IgG serum was found not to bind to CNS tissue from transgenic mice carrying deletions of the AQP4 genes. Second, NMO-IgG serum recognized human embryonic kidney (HEK) cells transfected with the AQP4 gene. Third, NMO-IgG serum immunoprecipitates green fluorescent protein-labeled AQP4 but not other members of the dystroglycan complex proteins. These elegant experiments conclusively proved that the antigen recognized by the NMO-IgG antibody was AQP4. Both the immunohistochemical and the AQP4-transfected HEK cell assays for detecting anti-AQP4 antibody from patient sera were subsequently validated by several groups (Takahashi et al., 2006; Paul et al., 2007; Marignier et al., 2008; Kalluri et al., 2010). These studies definitively prove that the NMO-IgG is an anti-AQP4 antibody. Hence, NMO-IgG can also be referred to as the anti-AQP4 antibody.

### Diagnostic criteria and utility of the anti-AQP4 antibody

Several sets of diagnostic criteria for NMO have been used (Cree et al., 2002). Current diagnostic criteria incorporate use of the anti-AQP4 antibody because it can reliably differentiate NMO from typical MS (Wingerchuk et al., 2006). The currently accepted diagnostic criteria are as follows: (1) optic neuritis; (2) AM; and (3) at least two of three supportive criteria: (a) contiguous spinal cord lesion extending three or more spinal cord segments; (b) brain MRI not meeting criteria for MS; and (c) anti-AQP4 antibody seropositivity. These criteria allowed inclusion of NMO patients who tested seropositive for the anti-AQP4 antibody but who had brain MRI lesions, extraoptic nerve and spinal cord clinical manifestations, or milder attacks. These criteria were 99% sensitive and 90% specific for differentiating NMO from MS with optic nerve and spinal cord presentations. The utility of these criteria was validated in an independent, prospectively gathered dataset that found the

revised criteria to have greater specificity (83.3% versus 25%) but lower sensitivity (87.5% versus 93.7%) than earlier proposed criteria that did not include the anti-AQP4 antibody (Wingerchuk et al., 1999; Saiz et al., 2007). Furthermore, both positive (87.5% versus 62.5%) and negative (83.3% versus 75%) predictive values were improved with the newer criteria.

Anti-AQP4 antibody is clinically useful not only for differentiating between NMO and MS with optic nerve and spinal cord presentations, but also for its predictive value following acute attacks of myelitis. In a retrospective study, 55% of patients presenting with myelitis who were seropositive for the anti-AQP4 antibody experienced a second demyelinating event of either recurrent myelitis or optic neuritis during the next year compared with 0% of seronegative patients (Weinshenker et al., 2006). Interestingly, in a study of recurrent optic neuritis, seropositivity for the anti-AQP4 antibody was associated with only a 50% risk of myelitis over an 8.9-year median follow-up interval (Matiello et al., 2008). Three separate cases of seropositive recurrent optic neuritis during 9–12 years of follow-up never developed transverse myelitis (Dinkin et al., 2008). These cases of anti-AQP4 antibody-seropositive recurrent optic neuritis suggest that either another factor in addition to anti-AQP4 antibody is necessary for patients to develop myelitis or that an inhibitor of myelitis may be present in some patients, restricting involvement to the optic nerves.

### Anti-AQP4 antibodies and pathogenesis

A correlation between anti-AQP4 antibody titer and optic neuritis and myelitis severity was found in one study (Takahashi et al., 2007). Spinal cord MRI at the nadir of myelitis also correlated with higher anti-AQP4 antibody titers. Anti-AQP4 antibody titers declined following treatment with high-dose methylprednisolone and remained low during periods of remission induced by immune suppression. These observations provide supportive evidence that the anti-AQP4 antibody is also a biomarker for disease activity in NMO.

Because the anti-AQP4 antibody bound to a CNS water channel, it raised the possibility that the antibody might be pathogenic and that NMO could be an autoimmune channelopathy. Several lines of evidence suggested that AQP4 is a pathogenic target. A case report of an acute NMO spinal cord lesion found diminished AQP4 staining by immunohistochemistry (Misu et al., 2006). Loss of AQP4 was found in central gray matter, particularly in a periventricular pattern where staining for glial fibrillary astrocytic protein (GFAP) was also substantially reduced. Furthermore, the periventricular areas characterized by loss of AQP4 and GFAP staining

correspond to the areas where antibody and complement are known to deposit in NMO lesions (Lucchinetti et al., 2002). In the areas surrounding the lesions, reactive gliosis with intense GFAP staining was present. Unlike AQP4 and GFAP, myelin basic protein staining was relatively preserved in the lesions. In contrast to the NMO case, spinal cord lesions from MS cases did not show loss of AQP4 and GFAP. The fact that tissue staining for GFAP was reduced and was lost for AQP4 in NMO spinal cord lesions suggests astrocytic podocytes could be degraded by anti-AQP4 autoantibodies and complement deposition. This study did not specify the stage of demyelination associated with the lesion, degree of astrocyte loss, or extent of tissue necrosis – factors that could confound the interpretation that AQP4 is targeted in NMO pathogenesis. It is also possible that AQP4 was endocytosed by astrocytes in response to the acute attack or that AQP4 staining was blocked by the presence of anti-AQP4 antibodies.

In a pathologic series of nine cases, AQP4 immunohistochemical reactivity in MS and NMO lesions was further examined (Roemer et al., 2007). In contrast to a stage-dependent loss of AQP4 in MS lesions, AQP4 was always lost in NMO lesions. Furthermore, the pattern of NMO loss corresponded to the pattern of IgG and complement deposition observed in NMO lesions. Interestingly, two types of NMO lesions were noted. One type, seen primarily in optic nerve and spinal cord, was associated with inflammatory infiltrates, IgG and complement deposition, AQP4 loss, and demyelination. The second type, seen in the spinal cord and medulla, particularly the area postrema, showed inflammation, IgG and complement deposition, and AQP4 loss without demyelination. These observations suggest that AQP4 loss could occur independently of demyelination.

The observation of loss of AQP4 reactivity in the area postrema is particularly interesting because reversible T2 signal abnormalities were found on brain MRI studies of NMO patients who experienced intractable hiccups and vomiting (Misu et al., 2005). It is possible that the reversible aspect of these symptoms and imaging findings associated with NMO plaques at this location are the consequence of autoantibody-mediated focal disruption of AQP4 function.

A follow-up series found consistent loss of AQP4 in acute inflammatory NMO lesions with or without active demyelination (Misu et al., 2007). However, in more chronic lesions, AQP4 staining could be detected regardless of whether demyelination accompanied the lesions. This observation correlates loss of AQP4 reactivity with the acute pathogenic process in NMO and suggests that loss of AQP4 reactivity may be reversible because of the return of AQP4 reactivity in chronic lesions. Loss of AQP4 reactivity in NMO spinal cord and optic nerve

lesions was found in another study (Sinclair et al., 2007). That NMO lesions lost AQP4 reactivity, whereas chronic MS lesions showed increased gene expression of AQP4 and osteopontin, highlights the differences in pathogenesis between these two disease states.

Taken together, these pathologic studies have important implications for NMO. First, AQP4 appears to be targeted in acutely forming lesions by the anti-AQP4 antibody. Second, it appears that demyelination occurs after loss of AQP4 because acute spinal cord plaques show loss of AQP4 but preserved myelin basic protein reactivity (Misu et al., 2006, 2007). In contrast, more chronic plaques show loss of both myelin basic protein and AQP4 (Roemer et al., 2007). It is not known whether loss of AQP4 function results in demyelination or whether demyelination occurs through other mechanisms. Third, depending on the lesion location, such as the area postrema, loss of AQP4 is associated with intense inflammation but apparently is uncoupled from demyelination.

The NMO autoantibody is an IgG subclass I antibody and is capable of fixing complement. The pathogenic potential of the AQP4 autoantibody was studied using AQP4-transfected HEK cell line that does not normally express AQP4 (Hinson et al., 2007). First, anti-AQP4 antibodies from NMO patient sera were shown to bind to the extracellular domain of AQP4. Second, binding of anti-AQP4 antibodies resulted in the rapid endocytosis of AQP4, which subsequently formed large cytoplasmic aggregates. Interestingly, removal of anti-AQP4 serum was followed by redistribution of AQP4 to the cell surface, implying reversibility of AQP4 loss under some conditions. Third, the anti-AQP4 serum could cause C9neo complement deposition on cell membranes mediating cell lysis. This process was found to be specific for anti-AQP4-IgG antibodies and not for anti-AQP4-IgM antibodies. Taken together, these studies show that anti-AQP4 antibody can cause endocytosis of AQP4 from plasma membranes and can fix complement, causing cell lysis. An important caveat to these *in vitro* observations is that the studies were performed on transfected HEK cells. Nevertheless, the implication is that anti-AQP4 antibodies could have direct pathogenic effects on AQP4, thereby explaining the loss of AQP4 reactivity from NMO lesions.

Proof that anti-AQP4 antibodies have a direct pathogenic effect on astrocytes came from a series of studies in which human anti-AQP4 antibodies were shown to have pathogenic effects in animals. Anti-AQP4 antibodies were cloned from plasma cells isolated from the CSF of NMO patients (Bennett et al., 2009). These human antibodies were expressed and purified and then parenterally administered to mice. In the setting of experimental autoimmune encephalomyelitis the recombinant human

anti-AQP4 antibodies caused astrogliaopathy with loss of AQP4, demonstrating for the first time in an experimental system a role for an antigen-specific human autoantibody in the pathogenesis of a CNS demyelinating disease. In a second study, human serum containing anti-AQP4 antibodies induced astrogliaopathy in mice with T-cell-mediated experimental autoimmune encephalomyelitis (Bradl et al., 2009). Finally, in a third study human sera containing anti-AQP4 antibodies and human complement were injected directly into mouse brain and caused astroglial injury (Saadoun et al., 2010). Taken together these studies prove the pathogenic potential of anti-AQP4 antibodies. Importantly, all three studies used various methods to allow the antibodies access to their CNS targets. This indicates that the anti-AQP4 antibodies are unable to induce astroglial injury on their own. Another process by which the blood–brain barrier is disrupted must occur to allow the antibodies access to their targets on astroglial podocytes.

Why spinal cord and optic nerve lesions in NMO are demyelinated is not immediately obvious from studies on AQP4. AQP4 localizes to the astrocytic podocytes surrounding nodes of Ranvier and paranode processes (Hinson et al., 2007). It is plausible that if the complement cascade is activated at these paranodal processes by anti-AQP4 antibodies, then an inflammatory response could cause secondary injury to oligodendroglial cells that are in contact with the astrocytes. Alternatively, axonal injury at the nodes of Ranvier could result in secondary demyelination. Glutamate toxicity could also contribute to injury in NMO because expression of the astrocytic glutamate transporter GLT1 is in part dependent on the presence of AQP4 (Zeng et al., 2007). Thus, it is possible that oligodendroglial cells might be susceptible to focal increases in glutamate concentration as a consequence of downregulation of astrocytic AQP4 by the anti-AQP4 antibody (Hinson et al., 2007).

Because the AQP4 water channel is expressed ubiquitously in astrocytes, it is perhaps difficult to understand restriction of NMO for the optic nerves and spinal cord. With the revised NMO diagnostic criteria, it became clear that brain MRI lesions were present in up to 50% of individuals with anti-AQP4 antibody (Pittock et al., 2006b). Most of these lesions were non-specific; however, 10% were similar to lesions seen in MS, whereas 5% had cerebral, brainstem, or diencephalic involvement that was unusual for MS. Interestingly, hypothalamic and periventricular lesions in NMO correspond to areas of high AQP4 expression (Pittock et al., 2006a).

Although many brain lesions in NMO are asymptomatic, hypothalamic involvement in NMO was associated with endocrinopathies (Kira et al., 1991; Vernant et al., 1997; Yamasaki et al., 2000; Poppe et al., 2005). It is not known why brain lesions in NMO are often

asymptomatic, in contrast to spinal cord and optic nerve lesions that rarely, if ever, are asymptomatic. Furthermore, NMO brain lesions that are hyperintense on T2-weighted imaging are typically not hypointense on T1-weighted imaging and often resolve over time (Cabrera-Gomez et al., 2008). It is possible that such lesions could correspond to a more transient pathologic process, such as edema, rather than demyelination. Thus, asymptomatic lesions may be associated with temporary loss of AQP4 without demyelination, whereas symptomatic lesions could be associated with both loss of AQP4 and demyelination.

It seems likely that the pathologic process in NMO is more complex than complement-mediated tissue injury caused by anti-AQP4 antibodies. That at least one of four NMO cases are not seropositive for anti-AQP4 antibodies demonstrates that the clinical manifestations of NMO can occur completely independently of the anti-AQP4 antibody. It is possible that in such cases other autoantibodies may be involved. Indeed, a pilot study found three novel autoantibodies in a case of NMO (Lalive et al., 2006). One of these antibodies directed against cleavage and polyadenylation specificity factor 73 declined following treatment with rituximab. Although potentially interesting, a relationship between this or other autoantibodies and NMO is speculative.

### NMO treatment

Based on the experience in MS, high-dose glucocorticoids are the primary therapy for acute attacks of transverse myelitis and optic neuritis in NMO. Unfortunately, NMO attacks often only partially respond, or do not respond at all, to treatment with glucocorticoids. In this setting, plasmapheresis is often used. A randomized, sham-controlled trial of plasma exchange in glucocorticoid-refractory CNS demyelinating diseases included two cases of NMO (Weinshenker et al., 1999). An NMO patient who received active plasma exchanges experienced a positive response to treatment whereas the other patient who received sham exchange did not.

A retrospective case series of plasmapheresis used to treat glucocorticoid-refractory severe attacks of CNS demyelination in MS, NMO, and transverse myelitis found a marked or moderate improvement in 60% of NMO patients (Keegan et al., 2002). A study of 6 anti-AQP4 seropositive patients who suffered from glucocorticoid-refractory attacks found moderate clinical improvement in three cases following plasmapheresis treatment. The clinical response was brisk in these cases, with onset of improvement following the first or second exchange (Watanabe et al., 2007b). Two case reports also describe benefit for lymphocytapheresis (Aguilera et al., 1985; Nozaki et al., 2006).

Maintenance of remission in NMO is challenging. Disability in NMO is largely caused by severe attacks of demyelination. Unlike MS, only some NMO patients develop secondary progressive changes (Wingerchuk et al., 2007). Thus, preventing attacks in NMO may prevent cumulative disability. Anecdotal experience found that NMO does not respond to immunomodulatory therapy (Wingerchuk et al., 1999). A multicenter, retrospective case series of 26 patients found that NMO patients ( $n = 19$ ) treated with immune suppression were less likely to relapse than NMO patients treated with interferon ( $n = 7$ ) (Papeix et al., 2007). All 7 (100%) of the interferon-treated patients relapsed by 12 months, whereas only 25% of immune suppressive-treated patients relapsed by 36 months. Indeed, one study suggested that interferon  $\beta$ -1b treatment increased relapses in Japanese optico-spinal MS patients (Warabi et al., 2007). The optico-spinal MS patients in this study were not assessed for anti-AQP4 seropositivity; however, their clinical features were more consistent with NMO (longitudinally extensive spinal cord lesions, severe optic nerve injury, and CSF pleocytosis).

That interferon might cause flares in NMO was suggested by a study of 56 Japanese patients with RRMS treated with interferon  $\beta$ -1b (Shimizu et al., 2010). Fourteen patients subsequently tested seropositive for anti-AQP4 antibody. Seven of 14 anti-AQP4-seropositive patients (NMO and NMO spectrum disorder) had severe transverse myelitis relapses (EDSS  $\geq 7$ ) within 3 months of starting treatment with interferon  $\beta$ -1b. Although cause and effect could not clearly be established, this report suggests that interferon treatment, at least in some NMO patients, may trigger exacerbations. If this observation is correct, then interferon is not safe for treatment in NMO. The other important implication for these studies is that, in all open-label studies of NMO in which pre- and posttreatment relapse rates are compared, if some NMO patients were treated with interferon then the pretreatment relapse rate might be exaggerated by interferon-caused relapses. This will inadvertently bias these open-label studies to favor a treatment effect when the reduction in relapsing activity could be due, at least in part, to cessation of interferon use.

The first of these studies used combined treatment of azathioprine and prednisone in 7 newly diagnosed NMO patients (two attacks) (Mandler et al., 1998). Azathioprine is a broad-spectrum immune suppressant and is approved by the US Food and Drug Administration (FDA) for renal transplant rejection and severe rheumatoid arthritis. Serious complications of azathioprine treatment include myelosuppression, lymphoma, malignancies, hepatotoxicity, and opportunistic infections. During 18 months of follow-up, no patients experienced

further relapses and the median EDSS gradually declined. Based on this series, azathioprine plus prednisone became the standard of care in NMO patients. Unfortunately, some patients continue to suffer from relapses despite treatment with azathioprine and prednisone.

A retrospective case series of 9 NMO patients compared the annualized relapse rates for each patient during periods when they received or did not receive daily glucocorticoids (Watanabe et al., 2007a). Relapse rates were significantly lower during periods when patients were treated with at least 10 mg/day of prednisone. The investigators suggested that daily glucocorticoids could be beneficial in preventing NMO relapses. Because daily glucocorticoid treatment was typically initiated in response to ongoing disease activity, it is not clear whether the purported treatment response reflects a change in the disease activity because of disease duration or a treatment effect. Some NMO patients become glucocorticoid-dependent; nevertheless, daily glucocorticoids are inexpensive and have the potential to be combined with other immune-suppressing therapies. Two case reports also suggested that IVIg may be beneficial in preventing NMO relapses (Bakker and Metz, 2004; Okada et al., 2007).

Mitoxantrone is a broad-spectrum immunosuppressant and is FDA-approved for the treatment of MS, acute myeloid leukemia, and symptomatic hormone-refractory prostate cancer. Known serious adverse reactions include leukemia, cardiotoxicity, hepatotoxicity, myelosuppression, ovarian failure, and infections. In an open-label case series of 5 NMO patients treated with mitoxantrone, 3 of them did not experience relapses during the average follow-up time of 13 months (Weinstock-Guttman et al., 2006). Although a statistical analysis was not performed, the investigators noted clinical and radiographic improvement in mitoxantrone-treated NMO patients. A 20-patient, open-label, retrospective South Korean study of mitoxantrone in NMO spectrum disorder patients, all of whom tested seropositive for the anti-AQP4 antibody, found similarly favorable responses to treatment (Kim et al., 2010). The annualized relapse rate pretreatment was 2.8 (1–5.7) and posttreatment was 0.7 (0–2.3), a statistically significant decrease. Ten of 20 (50%) patients became relapse-free. EDSS scores also significantly improved posttreatment. The mean pretreatment EDSS score was 5.6 (1.5–9) and posttreatment EDSS score was 4.4 (1–7). Mitoxantrone was well tolerated. No cases of promyelocytic leukemia were reported in this series. One patient discontinued treatment due to asymptomatic change in left ventricular ejection fraction. To date, mitoxantrone is the only medication that may be beneficial in NMO that is FDA-approved for MS.



Mycophenolate mofetil is a reversible inhibitor of inosine monophosphate dehydrogenase, an enzyme necessary for de novo purine biosynthesis. Mycophenolate mofetil inhibits lymphocyte proliferation and activation and is US FDA-approved for prevention of solid-organ transplant rejection. A retrospective case series from the Mayo Clinic in 24 patients with NMO spectrum disorder who all were seropositive for anti-AQP4 found that the annualized relapse rate declined after treatment with mycophenolate mofetil was initiated (Jacob et al., 2009). Seventeen of 24 patients were previously treated with other immune therapies. The annualized relapse rate pretreatment was 1.28 (0.23–11.78) and posttreatment was 0.09 (0–1.56). Nineteen of 24 (79%) patients had an improvement in relapse rate. Although statistically significant benefits on relapses were found, disability scores were not significantly improved. The median pretreatment EDSS score was 6 (0–8) and posttreatment was 5.5 (0–10). Overall, mycophenolate mofetil was well tolerated. Importantly, 9/25 patients received concomitant treatment with corticosteroids. Thus independent benefits of mycophenolate mofetil could not be determined in this study. Nonetheless, because of its excellent tolerability, ease of administration, and relatively low cost, mycophenolate mofetil should be considered as a first-line treatment in NMO.

Rituximab was also used in treatment-refractory NMO cases (Cree et al., 2005). Rituximab is a monoclonal antibody directed against CD20, a cell surface marker expressed on pre-B and B cells. Rituximab causes depletion of B cells and is FDA-approved for the treatment of non-Hodgkin's lymphoma and rheumatoid arthritis. Because several lines of evidence suggest that NMO is at least in part a humorally mediated disease, B-cell depletion in NMO might be expected to be beneficial. Serious complications of rituximab included severe and even fatal infusion reactions, hepatitis, new or reactivated viral infections, and progressive multifocal leukoencephalopathy. In this open-label case series, 7 of 8 NMO patients experienced a substantial reduction in relapsing activity following rituximab treatment, with a compensatory improvement in neurologic function. A retrospective follow-up study of 26 patients and preliminary results from an open-label clinical trial of 20 NMO patients found similar results (Jacob et al., 2008b). Some patients with very aggressive disease do not appear to respond immediately to treatment with rituximab, indicating that if rituximab has benefit in NMO, its effects may not be immediate (Capobianco et al., 2007; Jacob et al., 2008b).

Eculizumab is a monoclonal antibody directed against the complement protein C5, thereby preventing cleavage by C5 convertase and halting complement-dependent cell lysis. Eculizumab is US FDA-approved for treatment of

paroxysmal nocturnal hemoglobinuria and is administered by IV infusion every 2 weeks (Hillmen et al., 2006). Because the anti-AQP4 antibody-mediated astroglial injury is complement-dependent, eculizumab might block humorally mediated injury in NMO. A single-center, open-label study of eculizumab in NMO is currently underway. Preliminary observations suggest that NMO relapses may be inhibited by eculizumab.

The identification of anti-AQP4 antibodies as a biomarker for NMO is of proven diagnostic value. In the setting of diagnostic uncertainty, a seropositive test for anti-AQP4 can be very helpful for prognosis and potentially for selecting treatment options. Because the biomarker is a pathogenic autoantibody targeting AQP4, a water channel abundant on astrocytic podocytes, NMO is, at least in part, a humorally mediated disease. Why NMO has a predilection for the optic nerves and spinal cord is hard to explain given the ubiquitous expression of AQP4. Furthermore, anti-AQP4 antibodies do not readily explain the link between AQP4 loss and demyelination, nor the striking inflammation seen in NMO. Indeed, it seems more likely that vigorous inflammation, perhaps initiated by Th17 T cells, is needed initially in order to expose astrocytic targets to anti-AQP4 antibodies. Lastly, the fundamental cause of the presumed autoimmunity in NMO remains elusive. In this regard, NMO is very similar to MS.

### Recurrent myelitis

Although many myelitis cases are monophasic, recurrence can occur. MS and NMO account for the majority of recurrent cases. However, when MS and NMO are excluded, some cases of recurrent idiopathic myelitis remain. Recurrence in this setting can be at the same level as the initial injury or at different spinal cord levels. In a Malaysian study of 52 patients with a demyelinating spinal cord syndrome, 24 patients had no recurrence at a mean time of follow-up of 5.6 years (Tan, 1989). Twenty-eight patients relapsed, 18 developed MS, with 12 described as opticospinal MS (possible NMO). Ten patients had recurrent myelitis involving the same segment of the cord. In this series women were more likely to relapse than men. An important caveat of this study is that MRI was not performed and thus the anatomic characteristics of the spinal cord lesions are unknown.

That recurrent ATM may be a syndrome distinct from MS was proposed in two case series. In the first series, three cases of recurrent ATM with normal brain MRI and no clinical involvement above the cord were reported (Tippett et al., 1991). All patients had inflammatory CSF but OCBs were not present. In the second series, three cases of recurrent ATM with normal VEPs were described (Pandit and Rao, 1996). CSF showed a

lymphocytic predominance and OCBs were present in 1 patient. Two patients underwent brain MRI and both studies were normal. Two of 2 had cord edema.

Nine cases of progressive idiopathic myelopathy were defined by persistent lower motor neuron signs and spinal cord atrophy identified by MRI changes or gliosis or necrosis seen on biopsy or at autopsy (Katz and Ropper, 2000). The average age of onset was 59. One patient developed optic neuritis, consistent with NMO, and also had a history of myasthenia gravis. Two patients had abnormal VEPs and 1 patient had changes on brain MRI consistent with MS. The remaining 5 patients had a relapsing course and none had OCBs. The course was saltatory, with pain and lower motor neuron signs common at presentation. Treatments included high-dose corticosteroids, cyclophosphamide, plasmapheresis, and lomustine (for presumed primary malignancy), but were not obviously effective. The authors suggest that these cases are indistinguishable from a spinal cord-restricted form of NMO.

Thirty-seven cases of recurrent transverse myelitis were described, 15 of which were idiopathic, and 22 of which were associated with MS (Kim, 2003). For the idiopathic group the mean age of onset was 43 years and men were affected more often than women (4:1). Recurrences occurred as often as four times, with an average of 2.5. Fifty-three percent had paresthesias and numbness, 33% had weakness, and 14% had pain. Forty percent had symmetric sensory and motor disturbance as well as bladder dysfunction, thereby meeting proposed criteria for ATM. Thirty-three percent of patients presented with cervical and 67% presented with thoracic myelitis. Only one of the five cervical myelitis cases had cervical recurrence, whereas all thoracic presenting cases had thoracic myelitis. On average three vertebral segments were involved. Cord lesions were most likely to involve the posterior columns, followed by the spinothalamic tracts, followed by the spinocerebellar tracts on MRI. OCBs were absent in all 15 cases and only three cases had elevation in the IgG index. MS patients with recurrent transverse myelitis had a similar age of onset (41 years) but were more often women (16:6: 73%). Recurrences of transverse myelitis were less frequent (2.09). Presentation of transverse myelitis was similar, as were the imaging characteristics. CSF showed intrathecal synthesis of gammaglobulins in 50% of cases: OCBs were present in 7/20 cases and the IgG index was elevated in 7/20 cases in the CSF, with elevations in both in two cases.

Thirteen cases of recurrent ATM, as defined by the TMCWG criteria, were identified by medical record review (Hummers et al., 2004). Of these 13 cases, 10 tested seropositive for anti-Ro antibodies. Anti-Ro antibodies were seropositive in 4/12 control ATM patients, 11 of whom had monophasic ATM. The authors conclude that

anti-Ro antibodies are associated with recurrent myelitis. However, 3 of the patients with recurrent myelitis also had optic neuritis consistent with NMO. Because anti-Ro antibodies are common in NMO patients, it is not clear whether the anti-Ro antibodies are associated with recurrent myelitis or are biomarkers for NMO. NMO-IgG was not available at the time of this study.

A case series of recurrent transverse myelitis not secondary to MS, collagen vascular disease, or detectable infection describes 3 patients with spinal cord involvement >3 segments (Seifert et al., 2005). The mean age of onset was  $57 \pm 6$  years, with 3–7 years of follow-up. VEPs and brain MRI were normal. When assessed, a CSF pleocytosis was present during each attack of myelitis. OCBs were present in 2/3 patients. All patients became severely disabled despite a variety of treatments. The authors note the rarity of the condition (only three cases identified over a 10-year period) and speculate as to the potential relationship between recurrent myelitis and NMO. In each of these case series the AQP4 serologic assay was not available. Thus, it is uncertain as to whether cases of recurrent myelitis have NMO.

Recurrent transverse myelitis was also found in a minority of ATM patients identified by a retrospective chart review from a university-based hospital in Hong Kong (Chan et al., 2006). Forty-five patients who presented with ATM were identified. During a mean follow-up of 64 months, 20 had non-recurrent idiopathic ATM (63%), 5 patients developed NMO or NMO spectrum disorder, 3 patients developed recurrent ATM, 2 patients developed SLE, 1 patient developed anti-Ro antibodies, and 1 patient developed classic MS.

## SYSTEMIC INFLAMMATORY DISEASES

In ATM patients, the presence of other findings on general physical examination may suggest a systemic autoimmune disease. These could include: xerostomia, xerophthalmia (Sjögren syndrome), a history of venous thrombosis or multiple miscarriages (antiphospholipid syndrome), malar rash, arthritis, pericarditis, anemia, nephropathy, SLE, uveitis, pulmonary symptoms (sarcoidosis), or arthralgias, malaise, Raynaud phenomenon, Sjögren syndrome, sclerodactyly and myopathy (mixed connective tissue disease), or oral/genital ulcerations (Behçet's).

Table 28.7 lists the common available labs and their associated conditions. In addition to these studies, a urinalysis with microscopic analysis for hematuria may be warranted and, depending on the clinical level of suspicion, lip/salivary gland biopsy, chest CT scan with IV contrast agent, and Schirmer test should be considered. That myelitis occurs in the setting of systemic collagen vascular diseases underscores the need for a detailed



history and examination (both general and neurologic), including a full review of systems.

### Systemic lupus erythematosus

The most common autoantibodies associated with lupus myelitis are ANA and are reported in nearly all cases of lupus myelitis. Antiphospholipid antibodies are reported in 43–73% of lupus myelitis. When longitudinally extensive, SLE-associated myelitis can be associated with anti-AQP4 antibodies overlapping with NMO. The overlap between NMO and SLE myelitis is underscored by the co-occurrence of myelitis and optic neuritis in some cases. The extent of myelitis can be variable, involving only a single spinal cord segment or multiple segments, typically affecting the thoracic cord. Myelitis can be the presenting manifestation of SLE or occur as a later complication.

Myelopathy as a complication of SLE was first reported in a 19-year-old woman who presented with paraplegia and succumbed to a febrile illness. At autopsy, her lumbar spinal cord was found to be necrosed secondary to arterial thrombosis (Piper, 1953). In following years cases of paraplegia and myelitis were reported as complications of SLE (Clark and Bailey, 1954; Siekert and Clark, 1955). Over 100 additional case reports of myelitis associated with SLE have subsequently accrued in the rheumatologic literature, although a few case series from centers serving large numbers of SLE patients have emerged in the last decade. In a review of large case series myelitis, paraparesis and quadraparesis were described as rare manifestations of SLE, affecting only 7 patients of 2316 cases (0.3%) (West, 1994).

A survey of approximately 600 patients with SLE receiving care at two academic institutions found 14 cases of myelopathy (estimated prevalence is 2.3%) (Kovacs et al., 2000). These cases were added to the existing English and German-language literature that comprised 91 cases from 35 publications. The age of onset was available for 98/105 total cases and was 32 for SLE and 33 for myelitis (range 9–77 years). Myelitis was the initial manifestation of SLE in 39% of patients. Ninety-one percent of cases were women. The most common level of involvement was mid thoracic, extending from T5 to T8. Optic neuritis was described in 27/55 cases (48%) and was not reported on in the remaining 50 cases. The co-occurrence of optic neuritis and myelitis raises the question as to whether these patients had NMO. Antiphospholipid antibodies were assessed in 64/105 patients and were identified in 41 (64%), raising the possibility that spinal cord injury might be mediated by arterial or venous thrombosis rather than inflammatory injury. MRI of the spinal cord was reported in 55 patients and was consistent with

myelitis in 39 patients (70%). Outcome data were available for 86/105 cases. Complete recovery occurred in 50%, partial recovery in 29%, and no improvement or deterioration occurred in 21%. Treatment consisted primarily of IV corticosteroids and seemed to be associated with improved outcomes, although controlled data were not available. The addition of cyclophosphamide to corticosteroids appeared to be associated with improved outcomes relative to corticosteroids alone. Any additional benefit of plasmapheresis to corticosteroids and cyclophosphamide could not be discerned.

In a case series of 15 patients who presented with clinical myelopathy as the initial manifestation of SLE, 9/15 had radiographic evidence of spinal cord inflammation and 1 other patient, who could not tolerate MRI, had evidence of a leukocytosis on CSF analysis (D’Cruz et al., 2004). Seven of these 10 patients met diagnostic criteria for SLE and the other 3 had a lupus-like illness that did not fulfill American College of Rheumatology classification criteria for neuropsychiatric SLE. All 10 patients were seropositive for ANA and 70% (7/11) were antiphospholipid antibody-positive. Treatment consisted of corticosteroids alone in 3 patients, cyclophosphamide alone in 2 patients, and combined corticosteroids with cyclophosphamide in 5 patients. All patients experienced some recovery in function. One patient completely recovered. Five patients had partial recovery and were able to walk without assistance and 4 patients required either a cane or crutches to ambulate.

In a retrospective case series of 22 SLE myelitis patients from a single center, two distinct patterns of spinal cord injury were described (Birnbau et al., 2009). Eleven patients presented with signs of gray-matter injury (flaccid paralysis with hyporeflexia) and 11 patients presented with signs of corticospinal injury (spasticity and hyperreflexia). Patients with gray-matter involvement were more likely reach the nadir of weakness in less than 6 hours (8/11), to have irreversible paraplegia (10/11), to have a monophasic course (10/11), and to present with proteomes of fever (11/11) and urinary retention (10/11). In contrast, patients with corticospinal tract injury were more likely to be seropositive for lupus anticoagulant (6/11 patients), to meet diagnostic criteria for NMO (5/11), and to test positive for anti-AQP4 antibodies (4/11). Spinal fluid abnormalities were common to both categories with leukocytosis, neutrophilia, and elevated protein; however, CSF glucose was low (mean 33 mg/dL) and inflammatory features were much more prominent in patients with gray-matter presentations. The authors proposed that SLE myelitis is comprised of two distinct clinical syndromes rather than being a single entity. However, the clinical distinction does not necessarily represent separate pathologic processes. As an end-organ that may be targeted by systemic

inflammatory disease, the severity of acute inflammation could determine which of these clinical subtypes becomes manifest. Rapid swelling of the spinal cord restricted to the spinal canal space likely results in compression of the dorsal venous plexus and subsequent diminished perfusion of the central gray matter from centripetally oriented radicular arteries. Central cord gray matter is critically dependent on perfusion from these arteries and ischemia could result in necrosis of these gray-matter structures. Reduced perfusion would be associated with less contrast enhancement despite prominence of inflammatory CSF. The arguments against this inflammatory severity hypothesis are the observations regarding lupus anticoagulant and anti-AQP4 antibodies that are present in the corticospinal tract form of SLE myelitis that argue for separate pathologic targets of autoantibodies.

Longitudinally extensive myelitis affecting four or more vertebral segments on MRI can be a presenting manifestation of SLE (Espinosa et al., 2010). The clinical manifestations of 22 cases (20 from the literature plus two additional cases) were reviewed. Seventy-seven percent were women with a mean age at onset of myelitis being  $29.3 \pm 9.4$  years. Of these cases only 1 patient had SLE-associated antiphospholipid antibody syndrome. Myelitis was the first symptom of SLE in 5/11 (23%) patients. Fifty percent of patients had hematologic, articular, or dermatologic involvement concurrent with the symptoms of myelitis. One patient also had optic neuritis, raising the possible diagnosis of NMO. The anti-AQP4 antibody was not assessed in this patient. The two cases reported by these authors were seronegative for the anti-AQP4 antibody. Eleven of 17 (65%) patients were seropositive for anti-double-stranded DNA antibodies, 14/19 (74%) had low complement levels, and 9/15 (60%) had both findings. Increased signal on T2 imaging was most frequently found in the cervical and upper thoracic spinal cord. Eight patients presented with fever, areflexia, and urinary sphincter dysfunction similar to the gray-matter involvement cases described by Birnbaum et al. (2009). Patients presenting with fever had a significantly greater CSF leukocytosis than the patients who did not present with fever (758 versus 57 white blood cells,  $p = 0.007$ ), similar to a prior report (Birnbaum et al., 2009). However, there was no difference in whether patients experienced plegia or paresis and recovery was similar between the patients presenting with fever and those who did not.

One limitation to interpreting the rheumatological myelitis literature is that anti-AQP4 antibody testing did not become commercially available until 2005. Because most of the literature describes earlier cases, assessment for this biomarker could not have been done. Since the NMO IgG assay became commercially

available, several cases of SLE myelitis have been reported to be seropositive for anti-AQP4 antibodies (Birnbaum and Kerr, 2007, 2008; Mehta et al., 2008; Nasir et al., 2009; Squatrito et al., 2010). In the series of 22 SLE myelitis patients from Johns Hopkins University, the anti-AQP4 antibody was assessed in all patients: 4 patients tested seropositive, 5 patients met diagnostic criteria for NMO, and 4 additional patients satisfied criteria for NMO spectrum disorder. In 1976 the first case of co-occurrence of SLE and NMO was reported (April and Vansonnenberg, 1976). Subsequently over 40 cases of NMO and SLE co-occurrence have been reported. Given that the prevalence of SLE is estimated to be 53 cases per 100 000 and the prevalence of NMO is estimated to be 1 case per 100 000, the co-occurrence of these two diseases in so many reported patients cannot be due to chance.

A case series of 88 NMO patients and 83 patients with longitudinally extensive myelitis also found that SLE could co-occur with NMO (Pittock et al., 2008). Five of 171 (2.9%) patients met the diagnostic criteria for SLE. All of these patients tested seropositive for NMO IgG. Forty-six patients with either SLE or Sjögren syndrome without myelitis were assessed for anti-AQP4 antibodies and these patients tested seronegative. That only patients with NMO or longitudinally extensive myelitis tested seropositive for the anti-AQP4 antibody argues that this antibody is specifically associated with myelitis.

Although no treatment trials specific for lupus myelitis have been performed, the impression from case series is that cyclophosphamide in conjunction with corticosteroids is associated with better outcomes than corticosteroids alone. A small controlled trial investigated IV cyclophosphamide versus IV methylprednisolone in 32 patients with acute neuropsychiatric manifestations of SLE (Barile-Fabris et al., 2005). All patients were treated with 3 days of IV methylprednisolone 1 gram/day followed by one of two regimens: methylprednisolone 1 gram daily for 3 days, monthly for 4 months, then bimonthly for 6 months, and subsequently every 3 months for 1 year or cyclophosphamide  $0.75 \text{ g/m}^2$  body surface monthly for 1 year then every 3 months for 1 year. Oral prednisone (1 mg/kg/day) was started on the fourth day of treatment, for no more than 3 months, and tapered according to disease activity/remission. Overall, 18/19 patients treated with cyclophosphamide responded to treatment compared to 7/13 patients treated with methylprednisolone ( $p < 0.03$ ). Of patients with myelitis in this study, 2 were assigned to the methylprednisolone arm. One of these patients discontinued treatment due to pregnancy and 1 patient experienced a relapse of myelitis when she was switched to receive methylprednisolone every 3 months. Three patients with myelitis were treated with cyclophosphamide. Two of the patients died from

Evans syndrome (hemolytic anemia in conjunction with thrombocytopenic purpura); the third patient initially improved with treatment but discontinued cyclophosphamide after the fifth infusion and subsequently succumbed to abdominal vasculitis. A case report describes response to mycophenolate mofetil and dexamethasone in a woman with longitudinally extensive transverse myelitis that was refractory to treatment with cyclophosphamide (Tomietto et al., 2007). The patient presented with intractable hiccuping, a presenting manifestation of NMO; however, the anti-AQP4 antibody was not assessed.

The European League Against Rheumatism (EULAR) current recommendations for SLE myelitis include: (1) diagnostic studies (gadolinium-enhanced MRI and CSF analysis); (2) timely (as soon as possible) induction treatment with high-dose glucocorticoids followed by IV cyclophosphamide; and (3) maintenance therapy with less intensive immunosuppression to prevent recurrence may be considered (Bertsias et al., 2010). EULAR recommendations also consider plasmapheresis for cases refractory to induction therapy (Neuwelt, 2003; Bartolucci et al., 2007). In addition, plasmapheresis may be beneficial in patients in whom corticosteroids are contraindicated (Yucesan et al., 2007). Taken together, these studies suggest that myelitis is associated with SLE in a minority of patients. Some, but not all, SLE patients with myelitis will test seropositive for the anti-AQP4 antibodies, placing these patients at risk for further attacks of myelitis or optic neuritis. Because SLE and NMO co-occur at a higher rate than what would be expected by chance for these two rare diseases, this suggests that NMO can be a manifestation of SLE, and vice versa. That SLE patients can be seropositive for the anti-AQP4 antibody suggests that the predisposition for autoantibody production in SLE can also result in this organ-specific antibody as a manifestation of underlying breakdown of immune tolerance to self-antigens. When myelitis occurs in SLE patients, assessment for the NMO IgG antibody should be routine. However, not all SLE patients should be routinely assessed for the anti-AQP4 antibody because this antibody appears to be restricted to SLE patients affected by myelitis.

### Antiphospholipid antibody syndrome

The term “lupoid sclerosis” was first applied to 6 patients with an MS like-illness, 5 of whom presented with progressive myelopathy (Fulford et al., 1972). Laboratory findings were suggestive of SLE with positive ANA, false-positive reactions for syphilis, antimitochondrial antibodies, raised serum IgM levels, and antithyroid antigastatic antibodies. One patient developed arthralgia, fever, and a pleural effusion 3 years after the onset of neurologic signs and would be considered

to have SLE. In the other patients 2 had arthralgias, 3 had skin manifestations, and 1 had iridocyclitis, but none would have met diagnostic criteria for SLE. In the 5 patients with progressive myelopathy the CSF showed elevated protein, normal cell counts, and a “paretic curve” for the Lange reaction, a now obsolete test that assessed the presence of gammaglobulins in the CSF. The paretic curve was characteristic of patients with general paresis (tertiary neurosyphilis) and MS.

A similar case of “lupoid sclerosis” was described in which a patient presented with progressive myelopathy and had a positive ANA, false-positive VDRL, and was also found to have antiphospholipid antibodies, leading the authors to speculate that the myelopathy was related to the presence of the antiphospholipid antibodies (Harris et al., 1985). Although the term lupoid sclerosis is no longer used in describing patients with clinical overlap of MS and SLE, these early observations were important in highlighting the need for systematic assessment of autoantibodies in patients presenting with myelitis.

The association between antiphospholipid antibodies and SLE myelitis was further illustrated in a case series in which 11/12 SLE patients with a history of transverse myelitis from two institutions tested positive for anticardiolipin antibodies. Eight of 11 had both IgG and IgM antibodies. The patient who was seronegative for anticardiolipin antibodies had a false-positive VDRL and prolonged partial thromboplastin time at the time of myelitis. Thus, all 12 patients with SLE and transverse myelitis had evidence of antiphospholipid antibodies. The authors concluded that there was a strong correlation between transverse myelitis in SLE and antiphospholipid antibodies (Lavalle et al., 1990). In contrast, antiphospholipid antibodies were detected in only 2/18 myelitis patients who did not have SLE, suggesting that antiphospholipid antibodies may have a role in SLE myelitis (Medina-Rodriguez et al., 1990).

Antiphospholipid antibodies have also been proposed to have a pathogenic role in pediatric SLE, although the extreme rarity of the condition makes strong conclusions impossible. In a case series of 57 children with SLE, one child had transverse myelitis and was persistently positive for both IgM and IgG anticardiolipin antibodies but had no other manifestations of antiphospholipid syndrome (Campos et al., 2003). In a study of 137 children with neuropsychiatric SLE, two children had transverse myelitis. Both tested positive for anticardiolipin antibodies and anti- $\beta_2$  glycosylphosphatidylinositol antibodies (1 was positive for lupus anticoagulant) (Avcin et al., 2008).

However, not all case series of SLE myelitis have found a correlation with antiphospholipid antibodies.

In a case series of 10 patients, anticardiolipin antibodies were moderately positive in 2 patients and weakly positive in 4 patients. Lupus anticoagulant was present in only 1 patient (Mok et al., 1998). Similar findings were observed in a case series of 667 SLE patients, 52 of whom met criteria for antiphospholipid antibody syndrome. Livedo reticularis and deep venous thrombosis were the two most common clinical manifestations of antiphospholipid antibody syndrome. Although the authors regarded transverse myelitis as a clinical manifestation of the antiphospholipid antibody syndrome, reanalysis of their data argues that the association is by chance. Of the 52 patients with definite antiphospholipid antibody syndrome, only 1 patient had transverse myelitis, whereas there were 4 transverse myelitis patients of the 615 SLE patients who did not meet criteria for definite antiphospholipid antibody syndrome. This observation demonstrates that SLE myelitis is not overrepresented in patients with antiphospholipid antibody syndrome ( $p=0.33$ , chi-square Fisher exact) (Aларcon-Segovia et al., 1992).

Antiphospholipid antibodies have also been found in SLE patients who may also have NMO. A case report described a 32-year-old woman with antiphospholipid antibodies who presented with intractable hiccups followed by transverse myelitis (Ruiz-Arguelles et al., 1998). D-dimers at the time of the myelitis were negative, suggesting that the etiology of myelitis was inflammatory rather than thrombotic. Her symptoms resolved following treatment with corticosteroids, heparin, and plasmapheresis. That the patient presented with intractable hiccups followed by myelitis raises the question whether this patient could have had anti-NMO antibodies as well. Antiphospholipid antibodies have also been reported in NMO patients; however, whether the presence of antiphospholipid antibodies is related to transverse myelitis is not at all clear (Fukazawa et al., 1993; Karussis et al., 1998; Ferreira et al., 2005; Mehta et al., 2008). Given that the anti-AQP4 antibody is proven to have a pathogenic role, and that when tested many SLE myelitis patients are seropositive for NMO, it seems more likely that the presence of antiphospholipid antibodies in SLE myelitis is incidental rather than causal.

The possible relationship between antiphospholipid antibodies and transverse myelitis in SLE was recently explored by grouping data from case reports and case series (Katsiari et al., 2011). Seventy SLE patients were identified who met proposed criteria for ATM in whom antiphospholipid antibodies were reported. Thirty-eight patients (54%) were seropositive for antiphospholipid antibodies, a rate similar to that for the overall population of SLE patients. Antiphospholipid antibody-positive and -negative patients did not differ with respect to demographics or clinical and laboratory SLE manifestations. The presence of antiphospholipid antibodies did

not correlate with relapsing ATM, additional CNS lupus manifestations, or outcome. Although anticoagulation was more frequently used in antiphospholipid antibody-positive patients, no additional therapeutic benefit was found, suggesting either that SLE myelitis was non-thrombotic or that anticoagulation was an ineffective treatment for spinal cord thromboses. Antiphospholipid antibody-negative patients more often presented with paralysis (50% versus 21%,  $p=0.01$ ) and were less likely to recover neurologic function. It is possible that seronegative status served as a proxy for gray-matter involvement, as has been proposed (Birnbbaum et al., 2009). However, unlike lupus anticoagulant, the presence of antiphospholipid antibodies was not previously correlated with gray versus white-matter disease. Given the small numbers it is also possible that this association is due to chance.

### Sjögren syndrome

Sjögren syndrome is a connective tissue disease characterized primarily by mononuclear infiltration of the lacrimal and salivary glands, causing xerophthalmia and xerostomia (Sjögren, 1933). Similar mononuclear infiltrates or vasculitic lesions are associated with extraglandular manifestations, including involvement of the peripheral nervous system and CNS (Sjögren, 1935; Attwood and Poser, 1961). Case series of Sjögren syndrome with neurologic involvement have described an MS-like illness (Alexander et al., 1986; de Seze et al., 2001). Whether Sjögren syndrome can cause an MS-like illness, or whether patients with MS and Sjögren syndrome have the misfortune of two separate illnesses, is debated (Noseworthy et al., 1989; Miro et al., 1990; Sandberg-Wollheim et al., 1992).

That myelopathy is associated with Sjögren syndrome perhaps is more clear. The first report of the co-occurrence of myelopathy with Sjögren syndrome described three different forms of spinal cord involvement: (1) necrotizing vasculitis of the anterior spinal artery; (2) transverse myelitis; and (3) a chronic progressive myelopathy (Alexander et al., 1981). Additional case reports of the co-occurrence of Sjögren syndrome with myelopathy followed (Manabe et al., 2000). In a series of 82 patients with neurologic involvement in primary Sjögren syndrome, 29/82 (35%) had spinal cord involvement (Delalande et al., 2004). Of these 29 patients, 12 had acute myelopathy, 16 had a chronic myelopathy (mimicking PPMS in 13 patients), and 1 had a progressive myeloradiculitis. Of the 12 who had an ATM, 2 had a concomitant optic neuritis, suggesting NMO. Extended lesions involving much of the spinal cord were described for any of the patients with acute myelopathy. As with SLE myelitis, there are no controlled trials



for Sjögren myelitis; however, case reports describe positive responses to plasmapheresis and corticosteroids (Konttinen et al., 1987).

It seems that these cases could be reclassified as having neuromyelitis spectrum disorder. In the 1999 Mayo Clinic NMO series, 4/71 (5.6%) patients were reported to have Sjögren syndrome, although details were not provided. Additional cases describing the co-occurrence of Sjögren syndrome with NMO were reported prior to the general availability of the anti-AQP4 antibody assay (Mochizuki et al., 2000; Arabshahi et al., 2006; Gokcay et al., 2007). Subsequent to the commercial availability of the anti-AQP4 antibody test, multiple cases of Sjögren syndrome-associated myelopathy have tested seropositive for the anti-AQP4 antibody (Hamnik et al., 2008; Javed et al., 2008; Sofat and Venables, 2008; Kim et al., 2009; Min et al., 2009; Wandinger et al., 2010; Kahlenberg, 2011). As with SLE, there appears to be overlap between NMO and Sjögren syndrome. In a series of 153 NMO spectrum disorder patients, 2 had concomitant Sjögren syndrome, and both were anti-AQP4 antibody seropositive. In the same study, 4/10 patients from a French NMO cohort had Sjögren syndrome. Unfortunately, how many of these patients were seropositive for anti-AQP4 antibodies was not specified, although 5/14 (36%) of patients with NMO disorder and either SLE or Sjögren syndrome were seropositive in this series. NMO IgG was not detected in SLE or Sjögren syndrome patients without a history of myelitis or optic neuritis.

It appears that when NMO IgG antibody testing was assessed, the majority of cases of Sjögren myelitis tested seropositive (21/25 cases). That a minority of cases of Sjögren syndrome-associated NMO tested seronegative for the NMO antibody is to be expected because the antibody, although highly specific, is not 100% sensitive for NMO (Javed et al., 2008; Chahin et al., 2009; Kim et al., 2009; Rabadi et al., 2010). As with SLE, the co-occurrence of these rare autoimmune diseases is unlikely to be due to chance. Rather, the autoantibody production that typifies both Sjögren syndrome and NMO is likely related to a common breach in immune tolerance, giving rise to production of ANA, anti-SSA, anti-SSB, and anti-AQP4 antibodies.

### Mixed connective tissue disease

MCTD combines features of SLE, rheumatoid arthritis, scleroderma, and myositis and is considered an overlap syndrome (Sharp et al., 1972). MCTD causes arthralgias, malaise, Raynaud phenomenon, Sjögren syndrome, sclerodactyly, and myopathy. The ANA is positive with a speckled pattern and anti-U1 antibodies are present. Neurologic symptoms can occur in up to 10% of MCTD patients and typically involve trigeminal neuralgia,

peripheral neuropathy, aseptic meningitis, cerebellar dysfunction, seizures, and psychiatric symptoms (Sharp, 1975). Only eight cases of myelitis are described with MCTD (Weiss et al., 1978; Pedersen et al., 1987; Obara and Tanaka, 1991; Yamaguchi et al., 1991; Miyata et al., 1993; Flechtner and Baum, 1994; Mok and Lau, 1995; Weatherby et al., 2000; Bhinder et al., 2007). Unlike with SLE and Sjögren syndrome, whether these cases of myelitis represent the random co-occurrence of two autoimmune conditions or whether there is causal overlap is not clear. The anti-AQP4 antibody status of these cases was not described; however, the longitudinally extensive lesions on MRI for one case (Bhinder et al., 2007), the presence of optic neuropathy in a second case (Flechtner and Baum, 1994), and pathologic features of an autopsied case (Weiss et al., 1978) are consistent with the diagnosis of NMO. Treatment typically consisted of corticosteroids with azathioprine with recovery of neurologic function in some cases.

### Behçet's disease

Behçet's disease is a chronic, relapsing multiorgan inflammatory disorder characterized by aphthous and genital ulcerations and uveitis (Behçet, 1937). The CNS manifestations of the disease are protean and include meningoencephalitis, cranial neuropathies, cerebrovenous sinus thrombosis, seizures, movement disorders, ataxia, cognitive dysfunction, and psychosis (Siva and Saip, 2009). Myelitis is a rare complication of Behçet's disease. In a series of 162 patients with parenchymal CNS involvement in Behçet's disease, spinal cord involvement as manifested by clinical signs of myelopathy occurred in 23 patients. In 10 of these 23 patients, the spinal cord was the only portion of the CNS involved (Akman-Demir et al., 1999). Spinal cord involvement was described in 7 of 50 patients in another case series of neuro-Behçet's disease (Kidd et al., 1999). Of these 7 patients the myelitis was partial in 3, transverse in 2, and presented as a Brown-Séquard syndrome in 2. In addition to this series a number of case reports describe myelopathic involvement in Behçet's disease (Morrissey et al., 1993a; Yoshioka et al., 1996; Mascalchi et al., 1998; Kocer et al., 1999; Green and Mitchell, 2000; Harmouche et al., 2000; Lee et al., 2001; Lannuzel et al., 2002; Moskau et al., 2003; Calguneri et al., 2005; Deshpande et al., 2005; Mullins et al., 2009; Fukae et al., 2010; Metreau-Vastel et al., 2010). Behçet's associated myelitis is typically longitudinally extensive and extension of upper cervical cord lesions into brainstem structures can occur. Single vertebral segment involvement is reported (Kidd et al., 1999; Calguneri et al., 2005). Unlike in SLE and Sjögren syndrome,

NMO has not yet been associated with Behçet's disease. Only one case of longitudinally extensive myelitis reported assessment of the anti-AQP4 antibody and the patient tested seronegative (Fukae et al., 2010). Although pathology in Behçet's associated myelitis is not available, autopsy studies in neuro-Behçet's found intraparenchymal plasma cell and monocellular infiltrates as well as thrombosed medium-size veins consistent with a vasculitic process (Kocer et al., 1999). Corticosteroids and broad-spectrum immune suppressants are the primary therapy used in neuro-Behçet's myelitis, with improvement in function reported in the majority of cases. Interferon- $\alpha$  has been used with apparent success in corticosteroid-refractory cases (Calguneri et al., 2005; Monastirli et al., 2010).

### Vogt–Koyanagi–Harada syndrome

Vogt–Koyanagi–Harada syndrome, also known as uveomeningoencephalitis, is a syndrome of presumed autoimmune etiology characterized by multiorgan involvement of melanin-making cells. It is characterized by: (1) bilateral chronic iridocyclitis; (2) posterior uveitis; (3) neurologic dysfunction including tinnitus, meningismus, cranial neuropathy, or CSF pleocytosis or other central nervous dysfunction; and (4) cutaneous findings of vitiligo, alopecia, or poliosis (Snyder and Tessler, 1980). Two cases of Vogt–Koyanagi–Harada-associated myelitis were reported (Lubin et al., 1981; Dahbour, 2009). Although NMO serologies were not assessed in either case, the radiographic features in the second case are not consistent with longitudinally extensive myelitis. Cases of co-occurrence of Vogt–Koyanagi–Harada and MS have been reported and the neurologic follow-up of these two cases of myelitis with respect to the development of other neurologic dysfunction consistent with MS is unknown.

### Granulomatous angiitis of the CNS (primary CNS vasculitis)

Myelitis is an uncommon complication of granulomatous angiitis of the CNS. A review of granulomatous angiitis of the CNS documented spinal cord involvement in 7/61 cases (Sigal, 1987). Perhaps the first documented case of primary CNS angiitis described a 26-year-old woman who presented with myelopathy and experienced relentless progression, leading to death 2 years later. At autopsy arteritis of unclear etiology was found (Harbitz, 1922). Several other autopsied cases of granulomatous CNS angiitis with spinal cord involvement have been reported (Newman and Wolf, 1952; Kolodny et al., 1968; Harrison, 1976; Rawlinson and Braun, 1981; Ropper et al., 2003). In each of these cases of CNS angiitis with myelitis, autopsy typically revealed widespread

vasculitis affecting the brain, spinal cord, and leptomeninges. Primary CNS angiitis restricted to the spinal cord has been described in a single case of fulminant, treatment-refractory, cervical myelopathy that was fatal within 6 months of onset. Autopsy showed acute and chronic inflammatory changes affecting intramedullary vessels with moderate necrosis of the vessel walls associated with patchy necrosis and demyelination of the entire cervical spinal cord (Feasby et al., 1975).

When reported, the CSF associated with myelitic vasculitis is inflammatory with leukocytosis and elevated protein. Patient demographics do not provide clues to pathogenesis. Men and women appear to be equally at risk and the age at onset varies from young adulthood to late in life. Overall the prognosis appears to be dismal: until recently, all reported cases of granulomatous angiitis of the CNS with myelitis succumbed to complications of the disease within months to 3 years. A recent case of biopsy-proven spinal cord vasculitis involving a 65-year-old man who presented with a progressive myelopathy is noteworthy because he recovered with corticosteroid and cyclophosphamide treatment (Rourke et al., 2009).

### Other systemic vasculitides

There are two cases of antineutrophil cytoplasmic antibody (ANCA)-associated myelitis. One involved a 34-year-old man with a history of chronic hepatitis C infection who also had markers of systemic autoimmunity, including ANA, ds-DNA, p-ANCA, and c-ANCA, and who developed myelitis. He was treated with corticosteroids with only partial improvement (Zandman-Goddard et al., 2003). The second report describes a 65-year-old man with p-ANCA-associated renal and pulmonary vasculitis who developed a longitudinally extensive transverse myelitis (Hamilton et al., 2010). This patient was seronegative for the anti-AQP4 antibody and had a poor response to treatment with rituximab; however, he recovered with high-dose corticosteroids and plasmapheresis. Biopsies were not performed in these cases and the spinal cord inflammation is presumed to be vasculitic. A single case of recurrent longitudinally extensive myelitis in a 65-year-old man with a history of urticarial vasculitis was described. An elevated erythrocyte sedimentation rate was the only marker of systemic inflammation. Although CNS biopsies were not performed, vasculitis affecting the CNS is presumed because the patient also developed seizures and had atrophic areas on brain MRI consistent with prior ischemic events (Bolla et al., 1998). A case of inflammatory myelopathy in a 64-year-old man associated with immune complex cutaneous vasculitis caused by antibiotic treatment for bacterial

endocarditis has also been described (Nikol et al., 1996). MRI was not performed because of the presence of a pacemaker and a spinal cord biopsy was not done.

### Rheumatoid arthritis

Rheumatoid arthritis is usually not associated with CNS complications, although rare cases of rheumatoid cerebral vasculitis are recognized (Sigal, 1987). There appears to be a single case of rheumatoid arthritis-associated myelitis affecting an 81-year-old woman. Noteworthy features of this case include a normal MRI of the brain and spinal cord, floridly inflammatory CSF (1400 WBC, 80% polymorphonuclear), and positive tests for the lupus anticoagulant and anticardiolipin antibodies (Staub et al., 1992).

### Psoriatic arthritis

Although historically thought to be a form of rheumatoid factor-seronegative rheumatoid arthritis, psoriatic arthritis is now considered to be a distinct disease entity (Rath et al., 2010). A case of longitudinally extensive transverse myelitis was also reported in a patient with long-standing psoriatic arthritis. Anti-AQP4 antibodies were assessed and were negative. A causal relationship was proposed because the myelitis followed an exacerbation of oligoarthritis.

### Reactive arthritis

Reactive arthritis is a postinfectious arthropathy that follows episodes of urinary tract infections or diarrhea. Extra-articular involvement can affect the skin, eyes, heart, and urogenital and musculoskeletal systems. CNS involvement is uncommon and only two cases of myelitis are documented in the literature (Montanaro and Bennett, 1984; Agarwal et al., 2009). In neither case was anti-AQP4 antibody status assessed.

### Scleroderma

Systemic sclerosis is an autoimmune disease that causes multiorgan fibrosis and is associated with antitopoisomerase, anti-U3, and anti-RNA polymerase antibodies. CNS manifestations of scleroderma are rare and the co-occurrence of myelopathy in patients with scleroderma is reported in only a few cases (Brown and Murphy, 1985). In a series of 50 scleroderma patients, 20 patients were found to have nervous system involvement and 4 of these patients had myelopathy (Averbuch-Heller et al., 1992). However, the CSF was non-inflammatory and imaging was not reported, therefore it is unclear whether the clinical signs in these cases can be attributed to myelitis. Similarly, transverse myelopathy of unclear etiology was reported in a case of linear scleroderma; however, the

spinal cord appeared normal on MRI and the CSF was non-inflammatory. Thus it seems doubtful that this case was caused by myelitis and perhaps could have been more accurately classified as a myelopathy (Littman, 1989). A single case describes an association of progressive sclerosis with longitudinally extensive transverse myelitis (anti-AQP4 antibody-seropositive) (Franciotta et al., 2011). Yet, in another case, myelitis associated with scleroderma was associated with CSF leukocytosis and was not longitudinally extensive, and therefore is unlikely to be related to NMO (Torabi et al., 2004). The extreme rarity of scleroderma associated myelopathy, and absence of a consistent clinical pattern, suggests that the neurological syndromes observed in these cases could be due to chance.

### Ankylosing spondylitis

Ankylosing spondylitis is an autoimmune, chronic inflammatory arthropathy affecting the joints of the spine and pelvis (Graham and Ogryzlo, 1947). There is a strong association with human leukocyte antigen (HLA)-B27, with 90% of patients carrying this genotype. Extra-articular manifestations are also common: approximately 40% of patients are affected by uveitis. CNS complications can include compressive myelopathy as a consequence of arthropathy and cauda equina syndrome (Ramos-Remus et al., 1995; Ahn et al., 2003). However, intraparenchymal CNS complications of ankylosing spondylitis are very unusual. Only a few cases of myelopathy have been associated with the disease (Dolan and Gibson, 1994). CSF may show a pleocytosis; however, in some cases spinal cord imaging is normal (Oh et al., 2001). In one case myelitis and arachnoiditis co-occurred in a patient with long-standing ankylosing spondylitis (Lan et al., 2007). The mechanism by which ankylosing spondylitis causes arachnoiditis and myelitis is not known.

### Sarcoidosis

Sarcoidosis is a systemic granulomatous disease of undetermined etiology whose histopathologic hallmark is the presence of non-caseating granulomas in affected tissues. The lungs, mediastinal and peripheral lymph nodes, liver, skin, spleen, eyes, phalangeal bones, and parotid glands are commonly affected; however, other organs may be involved. Myelopathy attributed to systemic sarcoidosis was first noted in 1941; however, details of the case and pathologic confirmation were not provided (Longcope, 1941). Multiple cases of intraparenchymal and meningeal spinal cord sarcoidosis were described in the pre-MRI literature, although many of these cases did not present with a clinical myelopathy (Erickson et al., 1942; Jefferson, 1957; Walker, 1961; Silverstein et al., 1965; Matthews, 1965; Wiederholt and Siekert, 1965; James et al., 1967; Herring and

Urich, 1969). The first detailed description of sarcoidosis with symptomatic involvement of the spinal cord was reported in a 52-year-old woman who had presented with a slowly progressive thoracic myelopathy (Aszkanazy, 1952). At autopsy a diffusely thinned spinal cord with infiltrative granulomatous nodules was found.

In the pre-MRI literature several similar cases of sarcoidosis presenting as a spinal cord tumor have been described (Banerjee and Hunt, 1972; Semins et al., 1972; Snyder et al., 1976; Day and Sypert, 1977). Symptoms of systemic sarcoidosis preceded the onset of myelopathy in most cases. When reported, CSF typically showed elevation in protein, consistent with a spinal block, and a lymphocytic leukocytosis was sometimes present. Sarcoidosis causing a compressive myelopathy from leptomeningeal granulomas has also been described (Wood and Bream, 1959; Baruah et al., 1978). These cases are noteworthy because the patients recovered following debulking of the extramedullary mass and treatment with corticosteroids.

A review of case series published from 1941 to 1972 identified 5092 cases of sarcoidosis. Neurologic involvement occurred in 244 patients and 17 patients (0.3%) had spinal cord involvement (Delaney, 1977). In a more recent Mayo Clinic cohort, 83 of 2894 sarcoidosis patients had neurologic involvement. Myelopathy was present in 15 (0.5%) (Aksamit, 2008). Of these patients, 63% had an abnormal MRI. Linear signal abnormality on T2-weighted imaging associated with patchy gadolinium enhancement was the most common abnormal finding. Other radiographic manifestations include: enlargement of the spinal cord with T2 hyperintensity without enhancement, subpial enhancement, and thickening with enhancement of the cauda equina.

Diagnostic criteria for neurosarcoidosis have been proposed based on a series of 68 patients with neurologic manifestations of sarcoidosis (Zajicek et al., 1999). Nineteen patients had clinical signs of spinal cord disease. In 10 patients clinical signs of sarcoidosis were restricted to the spinal cord, whereas other portions of the neuroaxis were involved in the other 9. Twelve patients met diagnostic criteria for definite neurosarcoidosis (histologic demonstration of non-caseating granulomas in the affected tissue). Spinal cord biopsy led to a diagnosis of definite neurosarcoidosis in 2 patients. Meningeal enhancement was present in 38% of all cases and in 57% of biopsy-proven cases. Because meningeal enhancement is an infrequent pattern for other inflammatory myelopathies, when observed, this finding provides an important clue for suspecting neurosarcoidosis (or other infiltrative processes).

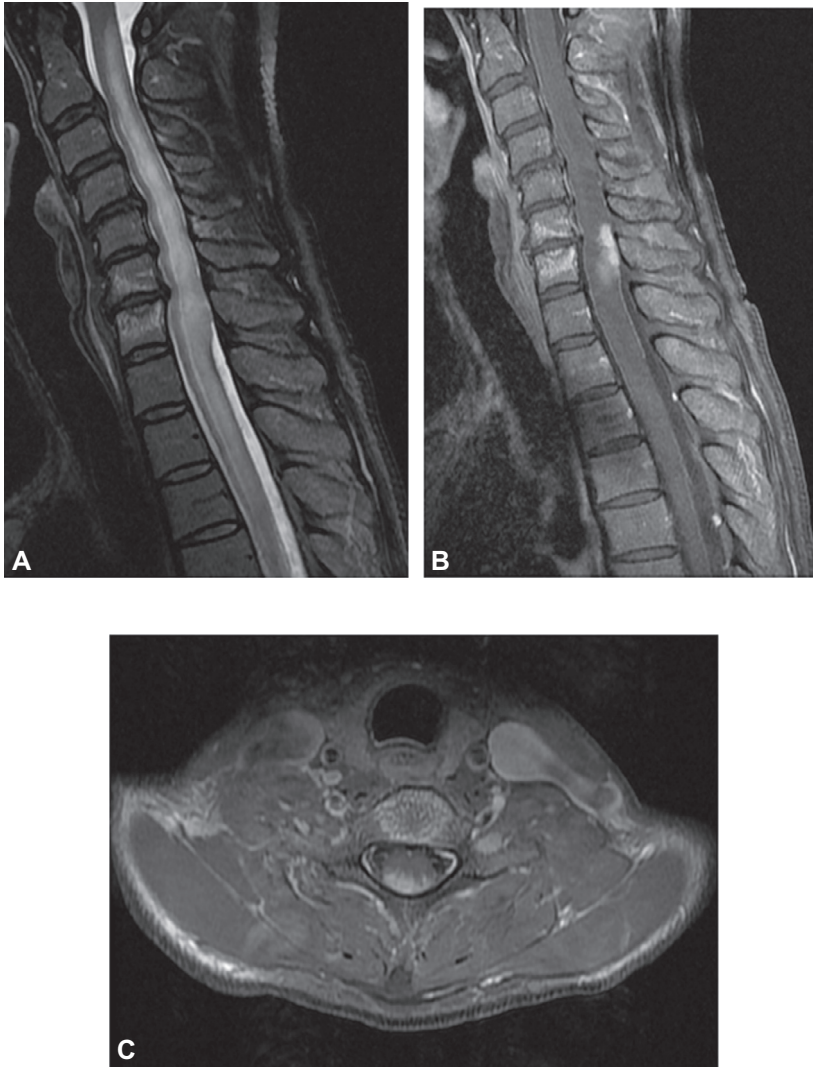
A recent case series of neurosarcoidosis from Vanderbilt University found that 10/54 (19%) patients had a clinical myelopathy and 13/54 (24%) had radiographic

evidence of spinal cord involvement on MRI (Pawate et al., 2009). Only 1 patient had radiographic involvement restricted to the spinal cord. Tissue confirmation by biopsy of spinal dural nodule was reported in 1 patient. This series illustrates the rarity of spinal cord-restricted neurosarcoidosis and the utility of MRI in identifying the pathologic extent of involvement, given that the brain MRI is in most cases also abnormal. The imaging characteristics of spinal cord lesions are similar to those of other inflammatory myelopathies, with increased signal on T2-weighted imaging, expansion of the cord, and the presence of contrast enhancement. Longitudinally extensive lesions, reminiscent of NMO, also can occur. Given the risks associated with spinal cord biopsy, when possible, biopsy of affected meninges or brain may establish a diagnosis of definite neurosarcoidosis in patients presenting with a myelopathy.

In another recent case series of 30 patients with presumed neurosarcoidosis, clinical involvement of the spinal cord was reported in 5 patients. None of these patients had a benign outcome. One patient had involvement of the conus medullaris on contrast-enhanced MRI and subsequently underwent a meningeal biopsy to confirm the diagnosis (Joseph and Scolding, 2009). Sarcoidosis of the cauda equina is rare, with only 19 cases reported in the literature (Goodman et al., 2007).

These recent case series underscore the utility of plain chest X-rays in the evaluation of possible neurosarcoidosis because this study is abnormal in 50–60% of patients with neurosarcoidosis. In the only published case-control study of spinal cord sarcoidosis, 31 patients with sarcoidosis (22 biopsy-proven) who presented with myelopathy were compared to 29 patients with myelopathies of other etiologies, e.g., MS, NMO, Sjögren's, tumor, degenerative, and infectious (Cohen-Aubart et al., 2010). Patients with sarcoidosis were more likely to have elevated C-reactive protein, lactate dehydrogenase, lymphopenia, and hypergammaglobulinemia than the controls. In contrast, and somewhat counterintuitively, angiotensin-converting enzyme levels were not significantly different between cases and controls. Chest X-rays, chest CT scans, and total body gallium scans were abnormal in 45–55% of patients (see Table 28.3 for a diagnostic approach to sarcoidosis-associated myelitis). On spinal cord MRI, sarcoidosis patients were more likely to have longitudinally extensive lesions, to have medullary and meningeal enhancement, and to have central cord signal changes compared to controls (Fig. 28.4). Treatment consisted primarily of corticosteroids in combination with a variety of immune suppressants. The overall prognosis was poor: only 2 patients recovered completely and 19/31 (61%) patients had moderate to severe handicaps at approximately 5 years of follow-up.





**Fig. 28.4.** Sarcoidosis. Magnetic resonance images shown include sagittal T2 (A), gadolinium-enhanced sagittal T1, and (C) axial gadolinium-enhanced T1 in a woman with gradual onset of weakness in legs and inflammatory cerebrospinal fluid. Note extensive nodular enhancement that appears to originate from the meninges and spread inward into the spinal cord consistent with sarcoid granulomatous disease in this patient with pulmonary sarcoidosis. (Copyright Bruce Cree.)

Neurosarcoidosis remains a challenging diagnosis and tissue is required to establish a definite diagnosis. Several recent studies found that 18 F-fluorodeoxyglucose (FDG) was useful in detecting spinal cord sarcoidosis (Dubey et al., 2002; Bolat et al., 2009; Ota et al., 2009; Kim et al., 2011). One case series found that the standard uptake value of FDG-positron emission tomography was higher in spinal sarcoidosis than in myelopathies caused by canal stenosis, underscoring its potential diagnostic utility (Sakushima et al., 2011).

Given the markedly unfavorable prognosis of spinal cord sarcoidosis, more aggressive treatment than corticosteroids may be warranted. Several case reports suggest that infliximab, a tumor necrosis- $\alpha$  inhibitor, is useful in cases of spinal cord sarcoidosis refractory to

more conservative management (Pritchard and Nadarajah, 2004; Sollberger et al., 2004; Saleh et al., 2006; Santos et al., 2010). Given the extreme rarity of spinal cord sarcoidosis, its overall dismal prognosis with traditional management, and the impressive results reported with infliximab, clinicians should be aware of its potential application to this often disabling disease and consider early treatment.

### Common variable immunodeficiency (CVID)

CVID is a clinically heterogeneous group of primary immune deficiency disorders characterized by hypogammaglobulinemia, resulting in an increased propensity for

infection, and is caused by a variety of predisposing genetic alleles (Weiler and Bankers-Fulbright, 2005). Treatment consists primarily of supplementation with IVIg. Myelitis has been associated with several cases of CVID. In a case series of neurologic complications of CVID, 5 patients presented with a thoracic myelopathy. The clinical manifestations in 1 patient were similar to those of PPMS. A myelopathy that was followed by encephalopathy characterized the other 4 patients. CSF was inflammatory in these 4 patients (Rudge et al., 1996). CVID has been associated with increased levels of tumor necrosis factor- $\alpha$  (Aukrust et al., 1996). This observation suggested that tumor necrosis factor- $\alpha$  inhibitors could have a role in the treatment of cases of CVID refractory to IVIg treatment. Infliximab was used successfully in 1 patient with myelitis and CVID (Kumar et al., 2008).

### Atopic myelitis (Kira's disease)

The occurrence of partial myelitis in patients with atopic dermatitis and other atopic disorders was first described in 4 Japanese patients with hyperIgEemia who presented with a cervical myelitis (Kira et al., 1997). Two of the patients had a history of atopic dermatitis and 2 were acutely affected at the time of the myelitis. The myelitis was characterized by dorsal column involvement spanning a single vertebral segment. Intrathecal synthesis of gammaglobulins was not present and none of the patients developed MS over the follow-up interval of 1–4 years. HyperIgEemia, atopic dermatitis, and mite antigen-specific IgEs were subsequently found to be more common in cases of partial myelitis of unknown etiology compared to MS patients and healthy controls (Kira et al., 1998). Subsequent single-center and nationwide surveys found an association between atopic dermatitis and myelitis in Japan (Kira et al., 2002; Osoegawa et al., 2003).

Because most patients recover with corticosteroid treatment there are few pathologic studies of atopic myelitis. Two patients with atopic myelitis who underwent spinal cord biopsy because of concern for gliomas were found to have perivascular cuffing with CD8+ T-cell and eosinophilic infiltrates, findings consistent with an atopic pathoetiology (Kikuchi et al., 2001). In subsequent studies atopic myelitis was found to span potentially several spinal cord segments, raising the question as to whether atopic myelitis was related to NMO. However, atopic myelitis is distinguished from NMO by the absence of the anti-AQP4 antibody. In addition, CSF levels of IL-9 and CCL11/eotaxin are elevated in atopic myelitis cases, whereas in NMO patients CSF levels of IL-17 and interferon- $\gamma$  levels are elevated (Tanaka et al., 2008).

Although initially described in Japan, cases of atopic myelitis have been described in European patients (Zoli et al., 2005; Gregoire et al., 2006). Interestingly, several

patients with atopic myelitis have developed focal amyotrophy, suggesting a potential link between atopic myelitis and Hopkin's syndrome, a rare poliomyelitis-like illness associated with acute asthma in children (Hopkins, 1974; Kira et al., 2008).

### PARANEOPLASTIC MYELITIS

In 1897 Lubarsch first proposed that malignancies could cause myelitis indirectly, possibly through elaboration of a toxin, based on a case of necrotic myelopathy that occurred in a patient who had gastric carcinoma. Subsequently, cases of otherwise unexplained necrotizing myelopathy were associated with a wide variety of malignancies, including prostate cancer (Nonne, 1903; Whiteley et al., 1979; Gray et al., 1980), lung cancer (Nonne, 1919; D'Antona, 1926; L'hermitte and Bussière de Robert, 1941; Mancall and Rosales, 1964; Ojeda, 1984; Glantz et al., 1994; Lins et al., 2003), leg sarcoma (Feindel, 1921), squamous cell skin cancer (Moersch and Kernohan, 1934), stomach cancer (Juba, 1938), thyroid cancer (Jaffe and Freeman, 1943; Kuroda et al., 1993), non-Hodgkin's lymphoma (Williams et al., 1962; Richter and Moore, 1968; Nishida and Ziegler, 1973; Whiteley et al., 1979; Gray et al., 1980; Grignani et al., 1992; Drach et al., 1996; Anderson and Borsaru, 2008), breast cancer (Mancall and Rosales, 1964; Sieben et al., 1981; Ojeda, 1984; Mueller et al., 2008), ovarian cancer (Case records of the Massachusetts General Hospital, 1976), leukemia (Reznik, 1979; Grisold et al., 1980; Gieron et al., 1987), Hodgkin's lymphoma (Lester et al., 1979; Dansey et al., 1988; Hughes et al., 1992), renal cell carcinoma (Handforth et al., 1983; Wilson et al., 1983), hepatocellular carcinoma (Misumi et al., 1988), multiple myeloma (Storey and McKelvie, 1991), and squamous cell esophageal cancer (Urai et al., 2009). No single tumor type is clearly associated with paraneoplastic myelopathy, although lung and breast cancer account for approximately one-third of reported cases, as might be expected based on the prevalence of these malignancies.

### Clinical presentation

Presenting symptoms are typical of thoracic myelopathy and include back pain, numbness, and bilateral leg weakness. The myelopathy is rapidly progressive and transverse, with paraparesis, sphincter disturbance, and a sensory level. The paraparesis frequently progresses to a flaccid, areflexic plegia and can ascend to involve the cervical cord, causing arm weakness and respiratory compromise. Necrosis of anterior horn cells is thought to account for the flaccid, areflexia plegia and the ascending quality can be mistaken for acute inflammatory demyelinating polyneuropathy, although the loss of cutaneous sensation and sphincter impairment point to a myelopathic process.

## Pathology

The pathologic extent of myelopathy spanned a minimum of three spinal cord segments and in most cases was far more extensive, sometimes involving the entire spinal cord. Macrophage infiltration was present in nearly all cases, with varying degrees of other inflammatory cells. Most pathologists considered the inflammatory changes to be insufficient to cause the observed extent of tissue necrosis. Hyalinization and hyperplasia of the vascular endothelium were present in many cases. Patchy tissue necrosis of both gray and white matter was always present in all autopsied or biopsied cases. Metastatic involvement of the spinal cord, roots, meninges, or epidural spaces was, by definition, not present. Macrophage infiltration and the vascular proliferative changes and hyalinization were thought to be secondary, reactive processes. The unusual vasculature, originally described by Foix and Alajouanine (Foix and Alajouanine, 1926), and now thought to represent spinal dural arteriovenous malformations, was not present in these cases.

The pathologic process is usually restricted to the spinal cord, with a predilection to involve the thoracic cord. In some cases there is involvement of the cerebellum (Renkawek and Kida, 1983; Ojeda, 1984), thalamus (Nishida and Ziegler, 1973), brainstem, mammillary bodies, and temporal lobe (Gieron et al., 1987), internal capsule (Richter and Moore, 1968), centrum semiovale (Ojeda, 1984), and parietal lobe (Whiteley et al., 1979; Gray et al., 1980). That necrosis is not restricted to the spinal cord implies that a common pathologic process afflicts multiple areas of the nervous system simultaneously. This argues against vascular injury, or other focal pathologies, and suggests causation by a more diffuse process such as toxic, metabolic, or immune-mediated injury.

## Evidence for autoimmunity

That the underlying pathology is immune-mediated comes from the observation that treatment with immune suppression may stabilize and even improve the neurologic deficit (Dansey et al., 1988; Grignani et al., 1992; Hughes et al., 1992; Glantz et al., 1994; Drach et al., 1996; Anderson and Borsaru, 2008; Mueller et al., 2008). Furthermore, in some cases intrathecal synthesis of gammaglobulins, a common laboratory abnormality found in MS and other paraneoplastic syndromes, was present (Dansey et al., 1988; Hughes et al., 1992; Kuroda et al., 1993; Anderson and Borsaru, 2008). Activated T-helper cells were found in one case (Kuroda et al., 1993) and antioligodendroglial antibodies were identified in another (Lins et al., 2003), although the antigenic target was not identified.

## Imaging

Most cases were reported prior to the availability of spinal cord imaging by MRI. The first case that included MRI of the spinal cord was reported in a 14-year-old boy with myelomonocytic leukemia and progressive myelopathy (Gieron et al., 1987). The cervical spine MRI showed extensive T2 signal abnormality in the upper cervical cord. Additional cases in which spinal cord MRI was performed typically showed spinal cord swelling with multisegmental T2-hyperintensity and corresponding patchy contrast enhancement (Glantz et al., 1994; Drach et al., 1996; Anderson and Borsaru, 2008; Mueller et al., 2008; Urai et al., 2009). These MRI changes are similar to the longitudinally extensive lesions characteristically observed during AM in NMO (Wingerchuk et al., 1999). When CSF results were reported, a mild to marked pleocytosis was sometimes, but not always, present, as was elevation in protein.

## Prognosis and treatment

Survival is measured in weeks to months and the proximal cause of death is often bronchopneumonia or respiratory failure. In untreated patients the outcome was uniformly fatal; spontaneous remission of neurologic symptoms was not reported. In the last 20 years there have been several cases reports suggesting stabilization or improvement in neurologic function following immune suppression and treatment of the underlying malignancy (Dansey et al., 1988; Grignani et al., 1992; Hughes et al., 1992; Glantz et al., 1994; Drach et al., 1996; Anderson and Borsaru, 2008; Mueller et al., 2008; Urai et al., 2009). Furthermore, spinal cord MRI signal changes may improve or resolve with immune suppression (Glantz et al., 1994; Drach et al., 1996; Anderson and Borsaru, 2008; Mueller et al., 2008). Nevertheless, relentless neurologic decline occurs in some patients despite treatment (Storey and McKelvie, 1991; Kuroda et al., 1993; Glantz et al., 1994). Many patients ultimately succumbed to complications from the underlying malignancy (Hughes et al., 1992; Glantz et al., 1994; Urai et al., 2009). Only three cases surviving both the malignancy and the myelopathy were reported (Dansey et al., 1988; Grignani et al., 1992; Anderson and Borsaru, 2008). In the surviving cases, histologic examination of the cord is not possible for confirmation of the pathologic changes described in earlier cases of malignancy-associated necrotizing myelopathy (with the exception of 1 patient in whom a spinal cord biopsy was performed) (Glantz et al., 1994). Therefore the relationship between the surviving cases to those autopsied is speculative.

Nevertheless, assuming that the surviving cases are pathologically related to the autopsied series has important ramifications. First, cases of transverse myelitis not related to collagen vascular disease, idiopathic inflammatory demyelinating diseases, or infections should be comprehensively assessed for occult malignancies. Second, immunologic treatments of the myelopathy may be clinically beneficial. Based on the available case reports, corticosteroids including intrathecal dexamethasone should be considered and broad-spectrum immune suppression with cyclophosphamide, or other cytotoxic agents, can be employed if treatment with corticosteroids does not yield the hoped-for clinical response. Third, repeat imaging with MRI and CSF sampling may be helpful in following the paraneoplastic syndrome's response to treatment.

### Association with neuromyelitis optica

Sometimes, the optic nerves and chiasm are also involved in necrotizing myelopathy (Richter and Moore, 1968; Kuroda et al., 1993). These cases are strikingly similar to NMO, whose pathology also involves both gray- and white-matter necrosis as well as vascular hyalinization (Lucchinetti et al., 2002). The potential relationship between paraneoplastic myelopathy and NMO has previously been suggested (Katz and Ropper, 2000; Okai et al., 2006). Vascular hyalinization, frequently observed in cases of necrotizing myelopathy, is a pathologic hallmark of NMO. Demyelination is observed in necrotizing myelopathy but is considered to be secondary to the necrotic lesions and may also be a secondary event following astroglial injury in NMO (Hinson et al., 2007). Necrotic changes in the brainstem and cerebrum sometimes occur in necrotizing myelopathy and brainstem and cerebral involvement in NMO is frequent (Pittock et al., 2006a). At least 20 cases of NMO occurred in the setting of malignancy (Richter and Moore, 1968; Kuroda et al., 1993; Antoine et al., 2004; Mueller et al., 2008; Pittock and Lennon, 2008; De Santis et al., 2009). Anti-AQP4 autoantibodies, present in approximately 70% of typical NMO cases (Lennon et al., 2004, 2005), have been reported in 17 cases of NMO or paraneoplastic myelopathy (Mueller et al., 2008; Pittock and Lennon, 2008; De Santis et al., 2009). Taken together, the overlap between these conditions is considerable and it seems possible anti-AQP4 autoantibodies may participate in the pathogenesis of at least some cases of paraneoplastic myelopathy. If so, then one might expect to find astroglial pathology that seems to be the hallmark of NMO (Misu et al., 2007), also in cases of necrotizing myelopathy. However, not all cases of paraneoplastic myelopathy are seropositive for the anti-AQP4 antibody (Urai et al.,

2009). Paraneoplastic syndromes develop as a consequence of immune-mediated attack of tumor cells and subsequent production of autoantibodies. Paraneoplastic autoantibodies may be involved in controlling tumor spread and it is possible that anti-AQP4 antibodies could be protective against metastasis because AQP4 expression enhances the migration of metastatic potential of tumor cells (Hu and Verkman, 2006).

### Anti-Ri autoantibodies

Anti-Ri antibodies, also known as ANNA-2 antibodies, are syndromically associated with paraneoplastic opsoclonus (Luque et al., 1991). However, the spectrum of neurologic disorders associated with ANNA-2 is broad and includes myelopathy (Pittock et al., 2003). Of 31 ANNA-2-seropositive patients for whom clinical information was available, 5 (18%) manifested signs of myelopathy as some point during their neurologic illness. However, none of these patients presented with syndromic myelopathy: all already had other manifestations of paraneoplastic disease, including ataxia, oscillopsia, Lambert–Eaton syndrome, and radiculopathy. Thus, although some patients seropositive for ANNA-2 antibodies will develop myelopathy, ANNA-2 seropositivity has not yet been described in patients presenting with isolated myelopathy. Of the patients with available follow-up information, 1 patient improved neurologically following radiation and chemotherapy for breast cancer and 1 patient who had surgery for small cell lung cancer did not improve. There are two other reports of anti-Ri-associated myelopathy and in both cases the myelopathy was not syndromic but rather a late manifestation of the paraneoplastic syndrome. In one case, remission of neurologic symptoms was attributed to treatment with corticosteroids (Rajabally et al., 2008) and to treatment with cyclophosphamide plus corticosteroids in the other (Stich and Rauer, 2006).

A report of myelitis associated with anti-Ri antibodies in the absence of a detectable tumor in a 65-year-old woman is included in this section because of possible benefit from immune-suppressive treatment (Leyboldt et al., 2006). This patient had a contrast-enhancing myelopathy with radiographic involvement by MRI extending from C6 to T3 and from T8 to T12. CSF showed a mild pleocytosis (up to 25 WBCs) and evolution of OCBs. The clinical course was characterized by multiple steroid-responsive recurrences, followed by additional treatments with cyclophosphamide, azathioprine, mycophenolate mofetil, and finally IVIg. The patient eventually stabilized, presumably because of use of aggressive immune suppression.



### ANNA-3 autoantibodies

Anti-ANNA-3 autoantibodies were found in an 83-year-old woman with adenocarcinoma who presented with insidious thoracic myelopathy. An MRI scan of the thoracic cord was unrevealing. The patient's myelopathy improved with local chest irradiation; however, she succumbed to recurrence of the malignancy 3 years later (Chan et al., 2001).

### Antiamphiphysin autoantibodies

Antiamphiphysin antibodies, syndromically associated with stiff-person syndrome (De Camilli et al., 1993), have also been associated with myelopathy (Pittock et al., 2005). Of a series of 63 patients with antiamphiphysin antibodies, 18 manifested evidence at some point during the course of their illness and in 6 the myelopathy was the only neurologic manifestation (one man with malignant melanoma and five women: three with breast cancer, one with small cell lung cancer, and one without detected tumor). The man had a rapidly progressive spastic paraparesis resulting in wheelchair confinement within 6 weeks associated with a T2 lesion spanning more than three vertebral segments on MRI that enhanced following contrast administration. The woman with small cell lung cancer was seropositive for anti-CRMP-5 antibodies and had a rapidly progressive quadraparesis with a non-contrast-enhancing longitudinally extensive spinal cord lesion. Anti-CRMP 5 antibodies were previously associated with myelopathy and optic neuropathy mimicking NMO (Cross et al., 2003) and may have contributed to the myelopathy in this patient. The woman without detectable tumor had an insidiously progressive paraparesis associated with a contrast, long spinal cord lesion. Clinical and radiographic information on the three patients with breast cancer was not available.

### CONCLUSIONS

Paraneoplastic myelopathy is associated with a wide variety of tumors. The initial recognition of this syndrome described a rapidly progressive, usually fatal thoracic myelopathy that destroyed both gray and white-matter structures. Compressive and thrombotic lesions were not found and the etiology was elusive. The clinical course and pathologic features are also found in patients who do not have a malignancy (idiopathic necrotizing myelopathy). The identification of several autoantibodies, including anti-AQP4, anti-Ri, anti-ANNA3 and antiamphiphysin, in more recently characterized cases suggests that paraneoplastic myelopathy may be immunologically mediated, although the mechanism of tissue injury does not appear to be cellularly mediated.

One of the features of paraneoplastic necrotizing myelopathy that is somewhat different from other paraneoplastic conditions is the relative male predominance. Of the pathologically definite cases reviewed for whom the sex was specified, 19 of 34 (56%) were men, whereas there is a strong female predominance in paraneoplastic cases in general (76% in one case series) (Candler et al., 2004). Given the relative rarity of the diagnosis, and the potential ascertainment bias in a literature review of case reports, it remains possible that the male predominance observed in this review of necrotizing myelopathy is due to artifact.

The recognition that myelopathy can be associated with neoplasia should prompt a comprehensive evaluation for occult malignancy in every patient presenting with transverse myelopathy of unclear etiology. Treatment trials of paraneoplastic myelopathy are unlikely to be undertaken because of the scarcity of the syndrome. Nevertheless, treatment with immune suppression should be considered based on the available case reports because of the high risk of mortality in this syndrome.

### SUMMARY

ATM is a clinical syndrome associated with diverse etiologies. Idiopathic transverse myelitis remains the default diagnosis for unexplained non-compressive myelopathy with radiographic or CSF evidence of inflammation. In a recent large case series of 170 patients presenting with acute non-compressive myelopathy, 40.6% (69/170) of patients had an identifiable cause on initial evaluation; however, on follow-up, an etiology was secured in 71.2% (121/170) of cases (mean follow-up of 73.2 months). The most commonly identified causes were demyelinating disease (MS 27%, NMO 6%), infarction (15%), parainfectious myelitis (12%), and systemic inflammatory disease (8%, e.g., SLE and Sjögren syndrome) (Debette et al., 2009).

Determining the etiology of transverse myelitis is a major diagnostic challenge due to the broad differential diagnosis that includes a myriad of infectious, systemic inflammatory and idiopathic CNS diseases. Effective interpretation of clinical symptoms and signs, high-quality neuroimaging, and biomarkers such as CSF IL-6 levels and the NMO-IgG can help identify the cause of the myelitis, and potentially guide treatment. Despite the absence of randomized trials needed to demonstrate proof of efficacy, empiric treatment with IV corticosteroids for idiopathic cases is warranted. In some cases refractory to treatment with glucocorticoids, plasma pheresis, IVIg and possibly immune suppression might be justified. Validated diagnostic criteria, biomarkers, and improved imaging will enhance study of ATM, its

idiopathic form, and its associated causes. Hopefully, with improved understanding of ATM, treatments tailored to the underlying disease can be developed.

## REFERENCES

- Adams RD, Kubik CS (1952). The morbid anatomy of the demyelinating disease. *Am J Med* 12: 510–546.
- Agarwal MP, Giri S, Sharma V et al. (2009). Concurrent reactive arthritis and myelitis – a case report. *Int Arch Med* 2: 17.
- Agre P, Nielsen S (1996). The aquaporin family of water channels in kidney. *Nephrologie* 17: 409–415.
- Aguilera AJ, Carlow TJ, Smith KJ et al. (1985). Lymphocytoplasmapheresis in Devic's syndrome. *Transfusion* 25: 54–56.
- Ahn BO, Kang KK, Ahn GJ et al. (2003). Efficacy of DA-8159, a new PDE5 inhibitor, for inducing penile erection in rabbits with acute spinal cord injury. *Int J Impot Res* 15: 405–411.
- Akman-Demir G, Serdaroglu P, Tasci B (1999). Clinical patterns of neurological involvement in Behçet's disease: evaluation of 200 patients. The Neuro-Behçet Study Group. *J Neurol Brain* 122: 2171–2182.
- Aksamit AJ (2008). Neurosarcoidosis. *Continuum* 14: 181–196.
- al Deeb SM, Yaqub BA, Bruyn GW et al. (1997). Acute transverse myelitis. A localized form of postinfectious encephalomyelitis. *J Neurol Brain* 120: 1115–1122.
- Alarcon-Segovia D, Perez-Vazquez ME, Villa AR et al. (1992). Preliminary classification criteria for the antiphospholipid syndrome within systemic lupus erythematosus. *Arth Rheum Semin Arthritis Rheum* 21: 275–286.
- Alexander GE, Provost TT, Stevens MB et al. (1981). Sjögren syndrome: central nervous system manifestations. *Neurology* 31: 1391–1396.
- Alexander EL, Malinow K, Lejewski JE et al. (1986). Primary Sjögren's syndrome with central nervous system disease mimicking multiple sclerosis. *Ann Intern Med* 104: 323–330.
- Alper G, Petropoulou KA, Fitz CR et al. (2011). Idiopathic acute transverse myelitis in children: an analysis and discussion of MRI findings. *Mult Scler* 17: 74–80.
- Altrocchi PH (1963a). Acute transverse myelopathy. *Arch Neurol* 9: 111–119.
- Altrocchi PH (1963b). Acute transverse myelopathy. *Trans Am Neurol Assoc* 88: 186–188.
- Amiry-Moghaddam M, Frydenlund DS, Ottersen OP (2004). Anchoring of aquaporin-4 in brain: molecular mechanisms and implications for the physiology and pathophysiology of water transport. *Neuroscience* 129: 999–1010.
- Anderson DW, Borsaru A (2008). Case report: Lymphoma-related resolving paraneoplastic myelopathy with MRI correlation. *Br J Radiol* 81: e103–e105.
- Andronikou S, Albuquerque-Jonathan G, Wilmschurst J et al. (2003). MRI findings in acute idiopathic transverse myelopathy in children. *Pediatr Radiol* 33: 624–629.
- Antoine JC, Camdessanche JP, Absi L et al. (2004). Devic disease and thymoma with anti-central nervous system and antithymus antibodies. *Neurology* 62: 978–980.
- April RS, Vansonnenberg E (1976). A case of neuromyelitis optica (Devic's syndrome) in systemic lupus erythematosus. Clinicopathologic report and review of the literature. *Neurology* 26: 1066–1070.
- Arabshahi B, Pollock AN, Sherry DD et al. (2006). Devic disease in a child with primary Sjögren syndrome. *J Child Neurol* 21: 285–286.
- Aszkanazy CL (1952). Sarcoidosis of the central nervous system. *J Neuropahtol Exp Neurol* 11: 392–400.
- Attwood W, Poser CM (1961). Neurologic complications of Sjögren's syndrome. *Neurology* 11: 1034–1041.
- Aukrust P, Lien E, Kristoffersen AK et al. (1996). Persistent activation of the tumor necrosis factor system in a subgroup of patients with common variable immunodeficiency – possible immunologic and clinical consequences. *Blood* 87: 674–681.
- Avcin T, Benseler SM, Tyrrell PN et al. (2008). A followup study of antiphospholipid antibodies and associated neuropsychiatric manifestations in 137 children with systemic lupus erythematosus. *Arth Rheum* 59: 206–213.
- Averbuch-Heller L, Steiner I, Abramsky O (1992). Neurologic manifestations of progressive systemic sclerosis. *Arch Neurol* 49: 1292–1295.
- Bakker J, Metz L (2004). Devic's neuromyelitis optica treated with intravenous gamma globulin (IVIg). *Can J Neurol Sci* 31: 265–267.
- Banerjee T, Hunt WE (1972). Spinal cord sarcoidosis. Case report. *J Neurosurg* 36: 490–493.
- Banwell BL (2007). The long (-itudinally extensive) and the short of it: transverse myelitis in children. *Neurology* 68: 1447–1449.
- Banwell B, Kennedy J, Sadovnick D et al. (2009). Incidence of acquired demyelination of the CNS in Canadian children. *Neurology* 72: 232–239.
- Barile-Fabris L, Ariza-Andraca R, Olguin-Ortega L et al. (2005). Controlled clinical trial of IV cyclophosphamide versus IV methylprednisolone in severe neurological manifestations in systemic lupus erythematosus. *Ann Rheum Dis* 64: 620–625.
- Bartolucci P, Brechignac S, Cohen P et al. (2007). Adjunctive plasma exchanges to treat neuropsychiatric lupus: a retrospective study on 10 patients. *Lupus* 16: 817–822.
- Baruah JK, Glasauer FE, Sil R et al. (1978). Sarcoidosis of the cervical spinal canal: case report. *Neurosurgery* 3: 216–218.
- Bashir K, Whitaker JN (2000). Importance of paraclinical and CSF studies in the diagnosis of MS in patients presenting with partial cervical transverse myelopathy and negative cranial MRI. *Mult Scler* 6: 312–316.
- Bastian HC (1882). Special disease of the spinal cord. In: R Quain (Ed.), *A Dictionary of Medicine*, 5th edn. D. Appleton, New York, pp. 1474–1477.
- Bastian HC (1910). Observations on thrombotic softening of the spinal cord: a misuse of so called "acute myelitis". *Lancet* 176: 1531–1534.
- Beck RW, Chandler DL, Cole SR et al. (2002). Interferon beta-1a for early multiple sclerosis: CHAMPS trial subgroup analyses. *Ann Neurol* 51: 481–490.
- Behar AJ, Feldman S, Halpern L (1957). Subacute necrotic myelopathy with bulbar involvement. *Confin Neurol* 17: 329–338.

- Behçet H (1937). Über residivierende, aphtöse, durch ein virus verursachte Geschwüre am Mund, am Auge und an den Genitalien. *Derm Wochenschr* 105: 1152–1157.
- Bennett JL, Lam C, Kalluri SR et al. (2009). Intrathecal pathogenic anti-aquaporin-4 antibodies in early neuromyelitis optica. *Ann Neurol* 66: 617–629.
- Berman M, Feldman S, Alter M et al. (1981). Acute transverse myelitis: incidence and etiologic considerations. *Neurology* 31: 966–971.
- Bernard G, Riou E, Rosenblatt B et al. (2008). Simultaneous Guillain-Barré syndrome and acute disseminated encephalomyelitis in the pediatric population. *J Child Neurol* 23: 752–757.
- Bertsias GK, Ioannidis JP, Aringer M et al. (2010). EULAR recommendations for the management of systemic lupus erythematosus with neuropsychiatric manifestations: report of a task force of the EULAR standing committee for clinical affairs. *Ann Rheum Dis* 69: 2074–2082.
- Bhinder S, Harbour K, Majithia V (2007). Transverse myelitis, a rare neurological manifestation of mixed connective tissue disease – a case report and a review of literature. *Clin Rheumatol* 26: 445–447.
- Bichuetti DB, Lobato de Oliveira EM, Oliveira DM et al. (2010). Neuromyelitis optica treatment: analysis of 36 patients. *Arch Neurol* 67: 1131–1136.
- Birnbaum J, Kerr D (2007). Devic's syndrome in a woman with systemic lupus erythematosus: diagnostic and therapeutic implications of testing for the neuromyelitis optica IgG autoantibody. *Arth Rheum* 57: 347–351.
- Birnbaum J, Kerr D (2008). Optic neuritis and recurrent myelitis in a woman with systemic lupus erythematosus. *Nat Clin Pract Rheumatol* 4: 381–386.
- Birnbaum J, Petri M, Thompson R et al. (2009). Distinct subtypes of myelitis in systemic lupus erythematosus. *Arth Rheum* 60: 3378–3387.
- Blackwood W (1963). Spinal thrombophlebitis. In: WH Blackwood, A Meyer, RM Norman et al. (Eds.), *Greenfield's Neuropathology*, Wilkins & Wilkins, Baltimore.
- Bolat S, Berding G, Dengler R et al. (2009). Fluorodeoxyglucose positron emission tomography (FDG-PET) is useful in the diagnosis of neurosarcoidosis. *J Neurol Sci* 287: 257–259.
- Bolla G, Disdier P, Verrot D et al. (1998). Acute transverse myelitis and primary urticarial vasculitis. *Clin Rheumatol* 17: 250–252.
- Bonnan M, Valentino R, Olindo S et al. (2009). Plasma exchange in severe spinal attacks associated with neuromyelitis optica spectrum disorder. *Mult Scler* 15: 487–492.
- Bradl M, Misu T, Takahashi T et al. (2009). Neuromyelitis optica: pathogenicity of patient immunoglobulin in vivo. *Ann Neurol* 66: 630–643.
- Brown JJ, Murphy MJ (1985). Transverse myelopathy in progressive systemic sclerosis. *Ann Neurol* 17: 615–617.
- Brown-Séquard CM (1849). De la transmission des impressions sensibles par la moelle épinière. *Compt Rend Soc Biol* 1: 192–194.
- Bruna J, Martinez-Yelamos S, Martinez-Yelamos A et al. (2006). Idiopathic acute transverse myelitis: a clinical study and prognostic markers in 45 cases. *Mult Scler* 12: 169–173.
- Bynke H, Olsson JE, Rosen I (1977). Diagnostic value of visual evoked response, clinical eye examination and CSF analysis in chronic myelopathy. *Acta Neurol Scand* 56: 55–69.
- Cabrera-Gomez J, Saiz-Hinarejos A, Graus F et al. (2008). Brain magnetic resonance imaging findings in acute relapses of neuromyelitis optica spectrum disorders. *Mult Scler* 14: 248–251.
- Calguneri M, Onat AM, Ozturk MA et al. (2005). Transverse myelitis in a patient with Behçet's disease: favorable outcome with a combination of interferon-alpha. *Clin Rheumatol* 24: 64–66.
- Campos LM, Kiss MH, D'Amico EA et al. (2003). Antiphospholipid antibodies and antiphospholipid syndrome in 57 children and adolescents with systemic lupus erythematosus. *Lupus* 12: 820–826.
- Candler PM, Hart PE, Barnett M et al. (2004). A follow up study of patients with paraneoplastic neurological disease in the United Kingdom. *J Neurol Neurosurg Psychiatry* 75: 1411–1415.
- Capobianco M, Malucchi S, di Sapio A et al. (2007). Variable responses to rituximab treatment in neuromyelitis optica (Devic's disease). *Neurol Sci* 28: 209–211.
- Case records of the Massachusetts General Hospital (1976). Weekly clinicopathological exercises. Case 26-1976. *N Engl J Med* 294: 1447–1454.
- Chahin S, Garwood MD, St Louis EK et al. (2009). Intramedullary Sjögren syndrome. *Neurology* 73: 2041–2042.
- Chan KH, Vernino S, Lennon VA (2001). ANNA-3 anti-neuronal nuclear antibody: marker of lung cancer-related autoimmunity. *Ann Neurol* 50: 301–311.
- Chan KH, Tsang KL, Fong GC et al. (2006). Idiopathic inflammatory demyelinating disorders after acute transverse myelitis. *Eur J Neurol* 13: 862–868.
- Cheng W, Chiu R, Tam P (1999). Residual bladder dysfunction 2 to 10 years after acute transverse myelitis. *J Paediatr Child Health* 35: 476–478.
- Christensen PB, Wermuth L, Hinge HH et al. (1990). Clinical course and long-term prognosis of acute transverse myelopathy. *Acta Neurol Scand* 81: 431–435.
- Clark EC, Bailey AA (1954). Neurologic and psychiatric findings in lupus erythematosus. *Trans Am Neurol Assoc* 13: 15–18.
- Cohen-Aubart F, Galanaud D, Grabli D et al. (2010). Spinal cord sarcoidosis: clinical and laboratory profile and outcome of 31 patients in a case-control study. *Medicine* 89: 133–140.
- Comi G, Martinelli V, Rodegher M et al. (2009). Effect of glatiramer acetate on conversion to clinically definite multiple sclerosis in patients with clinically isolated syndrome (PreCISe study): a randomised, double-blind, placebo-controlled trial. *Lancet* 374: 1503–1511.
- Cordonnier C, de Seze J, Breteau G et al. (2003). Prospective study of patients presenting with acute partial transverse myelopathy. *J Neurol* 250: 1447–1452.

- Cree BA, Wingerchuk DM (2005). Acute transverse myelitis: is the "idiopathic" form vanishing? *Neurology* 65: 1857–1858.
- Cree BA, Goodin DS, Hauser SL (2002). Neuromyelitis optica. *Semin Neurol* 22: 105–122.
- Cree BA, Lamb S, Morgan K et al. (2005). An open label study of the effects of rituximab in neuromyelitis optica. *Neurology* 64: 1270–1272.
- Cross SA, Salomao DR, Parisi JE et al. (2003). Paraneoplastic autoimmune optic neuritis with retinitis defined by CRMP-5-IgG. *Ann Neurol* 54: 38–50.
- D'Antona S (1926). Sulla necrosi spinale acuta nel corso dei tumori maligni, con un contributo alla conoscenza delle "ernie spinali malaciche". *Neurologica* 3: 65.
- Dahbour SS (2009). MRI documented acute myelitis in a patient with Vogt–Koyanagi–Harada syndrome: first report. *Clin Neurol Neurosurg* 111: 200–202.
- DaJusta DG, Wosnitzer MS, Barone JG (2008). Persistent motor deficits predict long-term bladder dysfunction in children following acute transverse myelitis. *J Urol* 180 (Suppl): 1774–1777.
- Dansey RD, Hammond-Tooke GD, Lai K et al. (1988). Subacute myelopathy: an unusual paraneoplastic complication of Hodgkin's disease. *Med Pediatr Oncol* 16: 284–286.
- Day AL, Sybert GW (1977). Spinal cord sarcoidosis. *Ann Neurol* 1: 79–85.
- D'Cruz DP, Mellor-Pita S, Joven B et al. (2004). Transverse myelitis as the first manifestation of systemic lupus erythematosus or lupus-like disease: good functional outcome and relevance of antiphospholipid antibodies. *J Rheumatol* 31: 280–285.
- De Camilli P, Thomas A, Cofield R et al. (1993). The synaptic vesicle-associated protein amphiphysin is the 128-kD autoantigen of stiff-man syndrome with breast cancer. *J Exp Med* 178: 2219–2223.
- De Goede CG, Holmes EM, Pike MG (2010). Acquired transverse myelopathy in children in the United Kingdom – a 2 year prospective study. *Eur J Paediatr Neurol* 14: 479–487.
- De Santis G, Caniatti L, De Vito A et al. (2009). A possible paraneoplastic neuromyelitis optica associated with lung cancer. *Neurol Sci* 30: 397–400.
- de Seze J, Devos D, Castelnovo G et al. (2001). The prevalence of Sjögren syndrome in patients with primary progressive multiple sclerosis. *Neurology* 57: 1359–1363.
- de Seze J, Lanctin C, Lebrun C et al. (2005). Idiopathic acute transverse myelitis: application of the recent diagnostic criteria. *Neurology* 65: 1950–1953.
- Debette S, de Sèze J, Pruvo JP et al. (2009). Long-term outcome of acute and subacute myelopathies. *J Neurol* 256: 980–988.
- Defresne P, Meyer L, Tardieu M et al. (2001a). Efficacy of high dose steroid therapy in children with severe acute transverse myelitis. *J Neurol Neurosurg Psychiatry* 71: 272–274.
- Defresne P, Meyer L, Tardieu M et al. (2001b). Efficacy of high dose steroid therapy in children with severe acute transverse myelitis. *J Neurol Neurosurg Psychiatry* 71: 272–274.
- Defresne P, Hollenberg H, Husson B et al. (2003). Acute transverse myelitis in children: clinical course and prognostic factors. *J Child Neurol* 18: 401–406.
- Delalande S, de Seze J, Fauchais AL et al. (2004). Neurologic manifestations in primary Sjögren syndrome: a study of 82 patients. *Medicine* 83: 280–291.
- Delaney P (1977). Neurologic manifestations in sarcoidosis: review of the literature, with a report of 23 cases. *Ann Intern Med* 87: 336–345.
- Deshpande DM, Krishnan C, Kerr DA (2005). Transverse myelitis after lumbar steroid injection in a patient with Behçet's disease. *Spinal Cord* 43: 735–737.
- Dinkin MJ, Cestari DM, Stein MC et al. (2008). NMO antibody-positive recurrent optic neuritis without clear evidence of transverse myelitis. *Arch Ophthalmol* 126: 566–570.
- Dolan AL, Gibson T (1994). Intrinsic spinal cord lesions in 2 patients with ankylosing spondylitis. *J Rheumatol* 21: 1160–1161.
- Drach LM, Enzensberger W, Fabian T et al. (1996). Paraneoplastic necrotising myelopathy in a case of AIDS with lymphoma. *J Neurol Neurosurg Psychiatry* 60: 237.
- Dubey N, Miletich RS, Wasay M et al. (2002). Role of fluorodeoxyglucose positron emission tomography in the diagnosis of neurosarcoidosis. *J Neurol Sci* 205: 77–81.
- Dunne K, Hopkins IJ, Shield LK (1986). Acute transverse myelopathy in childhood. *Dev Med Child Neurol* 28: 198–204.
- Edwards MK, Farlow MR, Stevens JC (1986). Cranial MR in spinal cord MS: diagnosing patients with isolated spinal cord symptoms. *AJNR Am J Neuroradiol* 7: 1003–1005.
- Erickson TC, Odom G, Stern K (1942). Boeck's disease (sarcoid) of the central nervous system: report of a case, with complete clinical and pathologic study. *Arch Neurol Psychiatry* 48: 613–621.
- Espinosa G, Mendizabal A, Minguez S et al. (2010). Transverse myelitis affecting more than 4 spinal segments associated with systemic lupus erythematosus: clinical, immunological, and radiological characteristics of 22 patients. *Semin Arthritis Rheum* 39: 246–256.
- Feasby TE, Ferguson GG, Kaufmann JC (1975). Isolated spinal cord arteritis. *Can J Neurol Sci* 2: 143–146.
- Feindel R (1921). Über akute aufsteigende Rückenmarksnekrose. *Z ges Neurol Psychiat* 68: 147.
- Ferreira S, Marques P, Carneiro E et al. (2005). Devic's syndrome in systemic lupus erythematosus and probable antiphospholipid syndrome. *Rheumatology* 44: 693–695.
- Ferrell AS, Tubbs RS, Acakpo-Satchivi L et al. (2009). Legacy and current understanding of the often-misunderstood Foix–Alajouanine syndrome. Historical vignette. *J Neurosurg* 111: 902–906.
- Filippi M, Martinelli V, Locatelli T et al. (1990). Acute- and insidious-onset myelopathy of undetermined aetiology: contribution of paraclinical tests to the diagnosis of multiple sclerosis. *J Neurol* 237: 171–176.
- Filippi M, Rovaris M, Inglese M et al. (2004). Interferon beta-1a for brain tissue loss in patients at presentation with syndromes suggestive of multiple sclerosis: a randomised, double-blind, placebo-controlled trial. *Lancet* 364: 1489–1496.



- Flechtnr KM, Baum K (1994). Mixed connective tissue disease: recurrent episodes of optic neuropathy and transverse myelopathy. Successful treatment with plasmapheresis. *J Neurol Sci* 126: 146–148.
- Foix C, Alajouanine T (1926). La myélite nécrotique subaiguë. Myélite centrale angio-hypertrophique à évolution progressive, paraplégie amyotrophique lentement ascendante, d'abord spasmodique, puis flasque, s'accompagnant de dissociation albuminocytologique. *Rev Neurol* 33: 1–42.
- Folliss AGH, Netsky MG (1970). Progressive necrotic myelopathy. In: PJ Vinken, GW Bruyn (Eds.), *Handbook of Clinical Neurology*, Vol. 9. North-Holland Publishing, Amsterdam, pp. 452–468.
- Ford B, Tampieri D, Francis G (1992). Long-term follow-up of acute partial transverse myelopathy. *Neurology* 42: 250–252.
- Franciotta D, Zardini E, Caporali R et al. (2011). Systemic sclerosis in aquaporin-4 antibody-positive longitudinally extensive transverse myelitis. *J Neurol Sci* 303: 139–141.
- Fukae J, Noda K, Fujishima K et al. (2010). Subacute longitudinal myelitis associated with Behçet's disease. *Intern Med* 49: 343–347.
- Fukazawa T, Hamada T, Tashiro K et al. (1990). Acute transverse myelopathy in multiple sclerosis. *J Neurol Sci* 100: 217–222.
- Fukazawa T, Moriwaka F, Mukai M et al. (1993). Anticardiolipin antibodies in Japanese patients with multiple sclerosis. *Acta Neurol Scand* 88: 184–189.
- Fulford KW, Catterall RD, Delhanty JJ et al. (1972). A collagen disorder of the nervous system presenting as multiple sclerosis. *Brain* 95: 373–386.
- Gajofatto A, Monaco S, Fiorini M et al. (2010). Assessment of outcome predictors in first-episode acute myelitis: a retrospective study of 53 cases. *Arch Neurol* 67: 724–730.
- Ganesan V, Borzyskowski M (2001). Characteristics and course of urinary tract dysfunction after acute transverse myelitis in. *Dev Med Child Neurol* 43: 473–475.
- Gieron MA, Margraf LR, Korthals JK et al. (1987). Progressive necrotizing myelopathy associated with leukemia: clinical, pathologic, and MRI correlation. *J Child Neurol* 2: 44–49.
- Glantz MJ, Biran H, Myers ME et al. (1994). The radiographic diagnosis and treatment of paraneoplastic central nervous system disease. *Cancer* 73: 168–175.
- Gökçay F, Celebisoy N, Gökçay A et al. (2007). Primary Sjögrens syndrome presenting as neuromyelitis optica. *Pediatr Neurol* 36: 58–60.
- Goodman BP, Driver-Dunckley ED, Leslie KO et al. (2007). A case of gait unsteadiness—an atypical manifestation of an unusual disease. *Lancet Neurol* 6: 1029–1032.
- Govender R, Wieselthaler NA, Ndondo A et al. (2010). Acquired demyelinating disorders of childhood in the Western Cape, South Africa. *J Child Neurol* 25: 48–56.
- Gowers WR (1899). In: WRS Gowers, S Taylor (Eds.), *A Manual of Diseases of the Nervous System*, 3rd edn. Disease of the nerves and spinal cord, Vol. 1. P. Blackstone's, Philadelphia, pp. 344–376.
- Graber JJ, Allie SR, Mullen KM et al. (2008). Interleukin-17 in transverse myelitis and multiple sclerosis. *J Neuroimmunol* 196: 124–132.
- Graham W, Ogryzlo MA (1947). Ankylosing (Marie-Strumpell) spondylitis; an analysis of 100 cases. *Can Med Assoc J* 57: 16–21.
- Gray F, Hauw JJ, Escourrolle R et al. (1980). Necrotic myelopathies and neoplastic pathologie. Three clinico-pathological cases (author's transl). *Rev Neurol* 136: 235–246.
- Green AL, Mitchell PJ (2000). Spinal cord Neurobehçet's disease detected on magnetic resonance imaging. *Australas Radiol* 44: 201–203.
- Greenberg BM, Thomas KP, Krishnan C et al. (2007). Idiopathic transverse myelitis: corticosteroids, plasma exchange, or cyclophosphamide. *Neurology* 68: 1614–1617.
- Gregoire SM, Mormont E, Laloux P et al. (2006). Atopic myelitis: a clinical, biological, radiological and histopathological diagnosis. *J Neurol Sci* 247: 231–235.
- Grignani G, Gobbi PG, Piccolo G et al. (1992). Progressive necrotic myelopathy as a paraneoplastic syndrome: report of a case and some pathogenetic considerations. *J Intern Med* 231: 81–85.
- Grisold W, Lutz D, Wolf D (1980). Necrotizing myelopathy associated with acute lymphoblastic leukemia. Case report and review of literature. *Acta Neuropathol* 49: 231–235.
- Hamilton AJ, Whitehead DJ, Bull MD et al. (2010). Systemic panca-associated vasculitis with central nervous involvement causing recurrent myelitis: case report. *BMC Neurol* 10: 118.
- Hamnik SE, Hacein-Bey L, Biller J et al. (2008). Neuromyelitis optica (NMO) antibody positivity in patients with transverse myelitis and no visual manifestations. *Semin Ophthalmol* 23: 191–200.
- Handforth A, Nag S, Sharp D et al. (1983). Paraneoplastic subacute necrotic myelopathy. *Can J Neurol Sci* 10: 204–207.
- Harbitz F (1922). Unknown forms of arteritis with special reference to their relation to syphilitic arteritis and periarteritis nodosa. *Am J Med Sci* 163: 250–272.
- Harmouche H, Mouti O, el-Alaoui Faris M et al. (2000). Acute myelitis and Behçet's disease: three case reports. *Rev Med Interne* 21: 1047–1051.
- Harris EN, Gharavi AE, Mackworth-Young CG et al. (1985). Lupoid sclerosis: a possible pathogenetic role for antiphospholipid antibodies. *Ann Rheum Dis* 44: 281–283.
- Harrison Jr PE (1976). Granulomatous angitis of the central nervous system. Case report and review. *J Neurol Sci* 29: 335–341.
- Harzheim M, Schlegel U, Urbach H et al. (2004). Discriminatory features of acute transverse myelitis: a retrospective analysis of 45 patients. *J Neurol Sci* 217: 217–223.
- Herring AB, Urich H (1969). Sarcoidosis of the central nervous system. *J Neurol Sci* 9: 405–422.
- Heymann DL, Aylward RB (2004). Eradicating polio. *N Engl J Med* 351: 1275–1277.

- Hillmen P, Young NS, Schubert J et al. (2006). The complement inhibitor eculizumab in paroxysmal nocturnal hemoglobinuria. *N Engl J Med* 355: 1233–1243.
- Hinson SR, Pittock SJ, Lucchinetti CF et al. (2007). Pathogenic potential of IgG binding to water channel extracellular domain in neuromyelitis optica. *Neurology* 69: 2221–2231.
- Hirai T, Korogi Y, Hamatake S et al. (1996). Case report: varicella-zoster virus myelitis – serial MR findings. *Br J Radiol* 69: 1187–1190.
- Hoffman HL (1955). Acute necrotic myelopathy. *Brain* 78: 377–394.
- Hopkins IJ (1974). A new syndrome: poliomyelitis-like illness associated with acute asthma in childhood. *Aust Paediatr J* 10: 273–276.
- Howell KB, Wanigasinghe J, Leventer RJ et al. (2007). Concomitant transverse myelitis and acute motor axonal neuropathy in an adolescent. *Pediatr Neurol* 37: 378–381.
- Hu J, Verkman AS (2006). Increased migration and metastatic potential of tumor cells expressing aquaporin water channels. *FASEB J* 20: 1892–1894.
- Hubbe P, Mouritzen Dam A (1973). Spastic paraplegia of unknown origin. A follow-up of 32 patients. *Acta Neurol Scand* 49: 536–542.
- Hughes M, Ahern V, Kefford R et al. (1992). Paraneoplastic myelopathy at diagnosis in a patient with pathologic stage IA Hodgkin disease. *Cancer* 70: 1598–1600.
- Hume AL, Waxman SG (1988). Evoked potentials in suspected multiple sclerosis: diagnostic value and prediction of clinical course. *J Neurol Sci* 83: 191–210.
- Hummers LK, Krishnan C, Casciola-Rosen L et al. (2004). Recurrent transverse myelitis associates with anti-Ro (SSA) autoantibodies. *Neurology* 62: 147–149.
- Icoz S, Tuzun E, Kurtuncu M et al. (2010). Enhanced IL-6 production in aquaporin-4 antibody positive neuromyelitis optica patients. *Int J Neurosci* 120: 71–75.
- Jacob A, Weinshenker BG, Violich I et al. (2008a). Treatment of neuromyelitis optica with rituximab: retrospective analysis of 25 patients. *Arch Neurol* 65: 1443–1448.
- Jacob A, Weinshenker BG, Violich I et al. (2008b). Treatment of neuromyelitis optica with rituximab: retrospective analysis of 25 patients. *Arch Neurol* 65: 1443–1448.
- Jacob A, Matiello M, Weinshenker BG et al. (2009). Treatment of neuromyelitis optica with mycophenolate mofetil: retrospective analysis of 24 patients. *Arch Neurol* 66: 1128–1133.
- Jaffe D, Freeman W (1943). Spinal necrosis and softening of obscure origin. Necrotic myelitis versus myelomalacia; review of literature and clinicopathological case studies. *Arch Neurol Psychiatr (Chic)* 49: 683–707.
- James DG, Sharma OP, Bradstreet P (1967). The Kveim–Siltzbach test. Report of a new British antigen. *Lancet* 2: 1274–1275.
- Javed A, Balabanov R, Arnason BG et al. (2008). Minor salivary gland inflammation in Devic’s disease and longitudinally extensive myelitis. *Mult Scler* 14: 809–814.
- Jefferson M (1957). Sarcoidosis of the nervous system. *Brain* 80: 540–556.
- Jeffery DR (1996). Chronic progressive myelopathy: diagnostic analysis of cases with and without sensory involvement. *J Neurol Sci* 142: 153–156.
- Jeffery DR, Mandler RN, Davis LE (1993). Transverse myelitis. Retrospective analysis of 33 cases, with differentiation of cases associated with multiple sclerosis and parainfectious events. *Arch Neurol* 50: 532–535.
- Joseph FG, Scolding NJ (2009). Neurosarcoidosis: a study of 30 new cases. *J Neurol Neurosurg Psychiatry* 80: 297–304.
- Juba A (1938). Myelitis necroticans subacuta (Foix–Alajouanine). *Deutsch Z Nervenheilk* 148: 17.
- Kahlenberg JM (2011). Neuromyelitis optica spectrum disorder as an initial presentation of primary Sjögren’s syndrome. *Semin Arthritis Rheum* 40: 343–348.
- Kahloon AA, Arif H, Baig SM et al. (2007). Characteristics of acute transverse myelitis at Aga Khan University Hospital, Karachi. *J Pak Med Assoc* 57: 215–218.
- Kalita J, Misra UK (2001a). Is methyl prednisolone useful in acute transverse myelitis? *Spinal Cord* 39: 471–476.
- Kalita J, Misra UK (2001b). Is methyl prednisolone useful in acute transverse myelitis? *Spinal Cord* 39: 471–476.
- Kalluri SR, Illes Z, Srivastava R et al. (2010). Quantification and functional characterization of antibodies to native aquaporin 4 in neuromyelitis optica. *Arch Neurol* 67: 1201–1208.
- Kalra V, Sharma S, Sahu J et al. (2009). Childhood acute transverse myelitis: clinical profile, outcome, and association with antiganglioside antibodies. *J Child Neurol* 24: 466–471.
- Kaplan AI, Deshpande DM, Scott E et al. (2005). IL-6 induces regionally selective spinal cord injury in patients with the neuroinflammatory disorder transverse myelitis. *J Clin Invest* 115: 2731–2741.
- Karussis D, Leker RR, Ashkenazi A et al. (1998). A subgroup of multiple sclerosis patients with anticardiolipin antibodies and unusual clinical manifestations: do they represent a new nosological entity? *Ann Neurol* 44: 629–634.
- Katsiari CG, Giavri I, Mitsikostas DD et al. (2011). Acute transverse myelitis and antiphospholipid antibodies in lupus. No evidence for anticoagulation. *Eur J Neurol* 18: 556–563.
- Katz JD, Ropper AH (2000). Progressive necrotic myelopathy: clinical course in 9 patients. *Arch Neurol* 57: 355–361.
- Keegan M, Pineda AA, McClelland RL et al. (2002). Plasma exchange for severe attacks of CNS demyelination: predictors of response. *Neurology* 58: 143–146.
- Kerr D, Krishnan C, Pidcock F (2005). Acute transverse myelitis. In: H Singer, EH Kossoff, AL Hartman, TO Crawford (Eds.), *Treatment of Pediatric Neurologic Disorders*. Taylor and Francis, Boca Raton, FL, pp. 445–451.
- Kidd D, Steuer A, Denman AM et al. (1999). Neurological complications in Behçet’s syndrome. *Brain* 122: 2183–2194.
- Kikuchi H, Osoegawa M, Ochi H et al. (2001). Spinal cord lesions of myelitis with hyperIgEemia and mite antigen specific IgE (atopic myelitis) manifest eosinophilic inflammation. *J Neurol Sci* 183: 73–78.

- Kim KK (2003). Idiopathic recurrent transverse myelitis. *Arch Neurol* 60: 1290–1294.
- Kim SM, Waters P, Vincent A et al. (2009). Sjögren's syndrome myelopathy: spinal cord involvement in Sjögren's syndrome might be a manifestation of neuromyelitis optica. *Mult Scler* 15: 1062–1068.
- Kim SK, Im HJ, Kim W et al. (2010). F-18 fluorodeoxyglucose and F-18 fluorothymidine positron emission tomography/computed tomography imaging in a case of neurosarcoidosis. *Clin Nucl Med* 35: 67–70.
- Kim SH, Kim W, Park MS et al. (2011). Efficacy and safety of mitoxantrone in patients with highly relapsing neuromyelitis optica. *Arch Neurol* 68: 473–479.
- Kira J, Harada M, Yamaguchi Y et al. (1991). Hyperprolactinemia in multiple sclerosis. *J Neurol Sci* 102: 61–66.
- Kira J, Yamasaki K, Kawano Y et al. (1997). Acute myelitis associated with hyperIgEemia and atopic dermatitis. *J Neurol Sci* 148: 199–203.
- Kira J, Kawano Y, Yamasaki K et al. (1998). Acute myelitis with hyperIgEaemia and mite antigen specific IgE: atopic myelitis. *J Neurol Neurosurg Psychiatry* 64: 676–679.
- Kira J, Osoegawa M, Horiuchi I et al. (2002). History of allergic disorders in common neurologic diseases in Japanese patients. *Acta Neurol Scand* 105: 215–220.
- Kira J, Isobe N, Kawano Y et al. (2008). Atopic myelitis with focal amyotrophy: a possible link to Hopkins syndrome. *J Neurol Sci* 269: 143–151.
- Kocer N, Islak C, Siva A et al. (1999). CNS involvement in neuro-Behçet syndrome: an MR study. *AJNR Am J Neuroradiol* 20: 1015–1024.
- Kolodny EH, Rebeiz JJ, Caviness Jr VS et al. (1968). Granulomatous angiitis of the central nervous system. *Arch Neurol* 19: 510–524.
- Kontinen YT, Kinnunen E, von Bonsdorff M et al. (1987). Acute transverse myelopathy successfully treated with plasmapheresis and prednisone in a patient with primary Sjögren's syndrome. *Arth Rheum* 30: 339–344.
- Kovacs B, Lafferty TL, Brent LH et al. (2000). Transverse myelopathy in systemic lupus erythematosus: an analysis of 14 cases and review of the literature. *Ann Rheum Dis* 59: 120–124.
- Kumar N, Hagan JB, Abraham RS et al. (2008). Common variable immunodeficiency-associated myelitis: report of treatment with infliximab. *J Neurol* 255: 1821–1824.
- Kuroda Y, Miyahara M, Sakemi T et al. (1993). Autopsy report of acute necrotizing opticomyelopathy associated with thyroid cancer. *J Neurol Sci* 120: 29–32.
- Lahat E, Pillar G, Ravid S et al. (1998). Rapid recovery from transverse myelopathy in children treated with methylprednisolone. *Pediatr Neurol* 19: 279–282.
- Lalive PH, Menge T, Barman I et al. (2006). Identification of new serum autoantibodies in neuromyelitis optica using protein microarrays. *Neurology* 67: 176–177.
- Lan HH, Chen DY, Chen CC et al. (2007). Combination of transverse myelitis and arachnoiditis in cauda equina syndrome of long-standing ankylosing spondylitis: MRI features and its role in clinical management. *Clin Rheumatol* 26: 1963–1967.
- Lannuzel A, Lamaury I, Charpentier D et al. (2002). Neurological manifestations of Behçet's disease in a Caribbean population: clinical and imaging findings. *J Neurol* 249: 410–418.
- Lavalle C, Pizarro S, Drenkard C et al. (1990). Transverse myelitis: a manifestation of systemic lupus erythematosus strongly associated with antiphospholipid antibodies. *J Rheumatol* 17: 34–37.
- Lee SH, Yoon PH, Park SJ et al. (2001). MRI findings in neuro-Behçet's disease. *Clin Radiol* 56: 485–494.
- Leibowitz U, Halpern L, Alter M (1967). Clinical studies of multiple sclerosis in Israel. 5. Progressive spinal syndromes and multiple sclerosis. *Neurology* 17: 988–992.
- Lennon VA, Wingerchuk DM, Kryzer TJ et al. (2004). A serum autoantibody marker of neuromyelitis optica: distinction from multiple sclerosis. *Lancet* 364: 2106–2112.
- Lennon VA, Kryzer TJ, Pittock SJ et al. (2005). IgG marker of optic-spinal multiple sclerosis binds to the aquaporin-4 water channel. *J Exp Med* 202: 473–477.
- Leroy-Malherbe V, Sebire G, Hollenberg H et al. (1998). Neurogenic bladder in children with acute transverse myelopathy. *Arch Pediatr* 5: 497–502.
- Lester EP, Feld E, Kinzie JJ et al. (1979). Necrotizing myelopathy complicating Hodgkin's disease. *Arch Neurol* 36: 583–585.
- Leypoldt F, Eichhorn P, Saager C et al. (2006). Successful immunosuppressive treatment and long-term follow-up of anti-Ri-associated paraneoplastic myelitis. *J Neurol Neurosurg Psychiatry* 77: 1199–1200.
- L'hermitte J, Bussière de Robert MME (1941). Myélomalacie et cancers viscéraux. *Rev Neurol* 73: 611–614.
- Lin PH, Chuang TY, Liao KK et al. (2006). Functional recovery of chronic complete idiopathic transverse myelitis after administration of neurotrophic factors. *Spinal Cord* 44: 254–257.
- Lins H, Kanakis D, Dietzmann K et al. (2003). Paraneoplastic necrotizing myelopathy with hypertrophy of the cauda equina. *J Neurol* 250: 1388–1389.
- Lipton HL, Teasdall RD (1973). Acute transverse myelopathy in adults. A follow-up study. *Arch Neurol* 28: 252–257.
- Littman BH (1989). Linear scleroderma: a response to neurologic injury? Report and literature review. *J Rheumatol* 16: 1135–1140.
- Longcope WT (1941). Sarcoidosis, or Benier-Boeck-Schumann disease. *JAMA* 117: 1321–1327.
- Low AA (1929). Acute ascending myelomalacia with clinical picture of Landry's paralysis. CPC report of a case. *Arch Neurol Psychiatr (Chic)* 21: 594–606.
- Lubarsch K (1897). Ueber Rückenmarksveränderungen bei Carcinomatosen. *Z Klin Med* 31: 389.
- Lubin JR, Loewenstein JJ, Frederick Jr AR (1981). Vogt-Koyanagi-Harada syndrome with focal neurologic signs. *Am J Ophthalmol* 91: 332–341.
- Lucchinetti CF, Mandler RN, McGavern D et al. (2002). A role for humoral mechanisms in the pathogenesis of Devic's neuromyelitis optica. *Brain* 125: 1450–1461.
- Luque FA, Furneaux HM, Ferziger R et al. (1991). Anti-Ri: an antibody associated with paraneoplastic opsoclonus and breast cancer. *Ann Neurol* 29: 241–251.

- Mair WG, Folkerts JF (1953). Necrosis of the spinal cord due to thromboplebitis (subacute necrotic myelitis). *Brain* 76: 563–577.
- Manabe Y, Sasaki C, Warita H et al. (2000). Sjögren's syndrome with acute transverse myelopathy as the initial manifestation. *J Neurol Sci* 176: 158–161.
- Mancall EL, Rosales RK (1964). Necrotizing myelopathy associated with visceral carcinoma. *Brain* 87: 639–656.
- Mandler RN, Ahmed W, Dencoff JE (1998). Devic's neuromyelitis optica: a prospective study of seven patients treated with prednisone and azathioprine. *Neurology* 51: 1219–1220.
- Marignier R, De Seze J, Vukusic S et al. (2008). NMO-IgG and Devic's neuromyelitis optica: a French experience. *Mult Scler* 14: 440–445.
- Marshall J (1955). Spastic paraplegia of middle age; a clinicopathological study. *Lancet* 268: 643–646.
- Marti-Fabregas J, Martinez JM, Illa I et al. (1989). Myelopathy of unknown etiology. A clinical follow-up and MRI study of 57 cases. *Acta Neurol Scand* 80: 455–460.
- Martinelli V, Comi G, Rovaris M et al. (1995). Acute myelopathy of unknown aetiology: a clinical, neurophysiological and MRI study of short- and long-term prognostic factors. *J Neurol* 242: 497–503.
- Mascalchi M, Cosottini M, Cellerini M et al. (1998). MRI of spinal cord involvement in Behçet's disease: case report. *Neuroradiology* 40: 255–257.
- Matiello M, Lennon VA, Jacob A et al. (2008). NMO-IgG predicts the outcome of recurrent optic neuritis. *Neurology* 70: 2197–2200.
- Matthews WB (1965). Sarcoidosis of the nervous system. *J Neurol Neurosurg Psychiatry* 28: 23–29.
- Medina-Rodriguez F, Garcia E, Fraga A (1990). Transverse myelitis and antiphospholipid antibodies. *J Rheumatol* 17: 1250.
- Mehta LR, Samuelsson MK, Kleiner AK et al. (2008). Neuromyelitis optica spectrum disorder in a patient with systemic lupus erythematosus and anti-phospholipid antibody syndrome. *Mult Scler* 14: 425–427.
- Metreau-Vastel J, Mikaeloff Y, Tardieu M et al. (2010). Neurological involvement in paediatric Behçet's disease. *Neuropediatrics* 41: 228–234.
- Mikaeloff Y, Suissa S, Vallee L et al. (2004). First episode of acute CNS inflammatory demyelination in childhood: prognostic factors for multiple sclerosis and disability. *J Pediatr* 144: 246–252.
- Miller DH, Ormerod IE, Rudge P et al. (1989). The early risk of multiple sclerosis following isolated acute syndromes of the brainstem and spinal cord. *Ann Neurol* 26: 635–639.
- Min JH, Kim HJ, Kim BJ et al. (2009). Brain abnormalities in Sjögren syndrome with recurrent CNS manifestations: association with neuromyelitis optica. *Mult Scler* 15: 1069–1076.
- Miro J, Pena-Sagredo JL, Berciano J et al. (1990). Prevalence of primary Sjögren's syndrome in patients with multiple sclerosis. *Ann Neurol* 27: 582–584.
- Miska RM, Pojunas KW, McQuillen MP (1987). Cranial magnetic resonance imaging in the evaluation of myelopathy of undetermined etiology. *Neurology* 37: 840–843.
- Misu T, Fujihara K, Nakashima I et al. (2005). Intractable hiccup and nausea with periaqueductal lesions in neuromyelitis optica. *Neurology* 65: 1479–1482.
- Misu T, Fujihara K, Nakamura M et al. (2006). Loss of aquaporin-4 in active perivascular lesions in neuromyelitis optica: a case report. *Tohoku J Exp Med* 209: 269–275.
- Misu T, Fujihara K, Kakita A et al. (2007). Loss of aquaporin 4 in lesions of neuromyelitis optica: distinction from multiple sclerosis. *Brain* 130: 1224–1234.
- Misumi H, Ishibashi H, Kanayama K et al. (1988). Necrotizing myelopathy associated with hepatocellular carcinoma. *Jpn J Med* 27: 333–336.
- Miyata M, Suzuki K, Sakuma F et al. (1993). Anticardiolipin antibodies are associated with pulmonary hypertension in patients with mixed connective tissue disease or systemic lupus erythematosus. *Int Arch Allergy Immunol* 100: 351–354.
- Miyazawa R, Ikeuchi Y, Tomomasa T et al. (2003). Determinants of prognosis of acute transverse myelitis in children. *Pediatr Int* 45: 512–516.
- Mochizuki A, Hayashi A, Hisahara S et al. (2000). Steroid-responsive Devic's variant in Sjögren's syndrome. *Neurology* 54: 1391–1392.
- Moersch FP, Kernohan JW (1934). Progressive necrosis of the spinal cord. *Arch Neurol Psychiatr (Chic)* 31: 504–526.
- Mok CC, Lau CS (1995). Transverse myelopathy complicating mixed connective tissue disease. *Clin Neurol Neurosurg* 97: 259–260.
- Mok CC, Lau CS, Chan EY et al. (1998). Acute transverse myelopathy in systemic lupus erythematosus: clinical presentation, treatment, and outcome. *J Rheumatol* 25 (3): 467–473.
- Monastirli A, Chroni E, Georgiou S et al. (2010). Interferon-alpha treatment for acute myelitis and intestinal involvement in severe Behçet's disease. *Q J Med* 103: 787–790.
- Montanaro A, Bennett RM (1984). Myelopathy in Reiter's disease. *J Rheumatol* 11: 540–541.
- Morrissey SP, Miller DH, Hermaszewski R et al. (1993a). Magnetic resonance imaging of the central nervous system in Behçet's disease. *Eur Neurol* 33: 287–293.
- Morrissey SP, Miller DH, Kendall BE et al. (1993b). The significance of brain magnetic resonance imaging abnormalities at presentation with clinically isolated syndromes suggestive of multiple sclerosis. A 5-year follow-up study. *Brain* 116: 135–146.
- Moskau S, Urbach H, Hartmann A et al. (2003). Multifocal myelitis in Behçet's disease. *Neurology* 60: 517.
- Mueller S, Dubal DB, Josephson SA (2008). A case of paraneoplastic myelopathy associated with the neuromyelitis optica antibody. *Nat Clin Pract Neurol* 4: 284–288.
- Mullins GM, Elamin M, Saidha S et al. (2009). Acute aseptic meningitis and diffuse myelitis as the presenting features of neurological Behçet disease. *J Clin Neurosci* 16: 1702–1704.
- Nasir S, Kerr DA, Birnbaum J (2009). Nineteen episodes of recurrent myelitis in a woman with neuromyelitis optica and systemic lupus erythematosus. *Arch Neurol* 66: 1160–1163.



- Neuwelt CM (2003). The role of plasmapheresis in the treatment of severe central nervous system neuropsychiatric systemic lupus erythematosus. *Ther Apheresis Dialys* 7: 173–182.
- Newman W, Wolf A (1952). Non-infectious granulomatous angiitis involving the central nervous system. *Trans Am Neurol Assoc* 56: 114–117.
- Nikol S, Huehns TY, Pilz G et al. (1996). Immune-complex allergic vasculitis in association with the development of transverse myelitis. A case report. *Angiology* 47: 1107–1110.
- Nishida T, Ziegler DK (1973). Acute necrotic myelopathy in association with lymphoma cells of the reticulo-endothelial system, acute torticollis, and recurrent cardiac arrest. *Confin Neurol* 35: 346–355.
- Nonne M (1903). Über acute Querlahmung bei maligner Neubildung der Wirbelsäule. *Berl Klin Wschr* 40: 728.
- Nonne M (1919). Myelodegeneratio transversa carcino-toxaemica. *Med Klinik* 15: 943.
- Noseworthy JH, Bass BH, Vandervoort MK et al. (1989). The prevalence of primary Sjögren's syndrome in a multiple sclerosis population. *Ann Neurol* 25: 95–98.
- Nozaki I, Hamaguchi T, Komai K et al. (2006). Fulminant Devic disease successfully treated by lymphocytapheresis. *J Neurol Neurosurg Psychiatry* 77: 1094–1095.
- Obara K, Tanaka K (1991). A case of mixed connective tissue disease (MCTD) associated with transverse myelitis responding to pulse therapy. *Rinsho shinkeigaku* 31: 1197–1201.
- Oh DH, Jun JB, Kim HT et al. (2001). Transverse myelitis in a patient with long-standing ankylosing spondylitis. *Clin Exp Rheumatol* 19: 195–196.
- Ojeda VJ (1984). Necrotizing myelopathy associated with malignancy. A clinicopathologic study of two cases and literature review. *Cancer* 53: 1115–1123.
- Okada K, Tsuji S, Tanaka K (2007). Intermittent intravenous immunoglobulin successfully prevents relapses of neuromyelitis optica. *Intern Med* 46: 1671–1672.
- Okai AF, Muppidi S, Bagla R et al. (2006). Progressive necrotizing myelopathy: part of the spectrum of neuromyelitis optica? *Neurol Res* 28: 354–359.
- O'Riordan JI, Thompson AJ, Kingsley DP et al. (1998). The prognostic value of brain MRI in clinically isolated syndromes of the CNS. A 10-year follow-up. *Brain* 121: 495–503.
- Osoegawa M, Ochi H, Minohara M et al. (2003). Myelitis with atopic diathesis: a nationwide survey of 79 cases in Japan. *J Neurol Sci* 209: 5–11.
- Ota K, Tsunemi T, Saito K et al. (2009). 18 F-FDG PET successfully detects spinal cord sarcoidosis. *J Neurol* 256: 1943–1946.
- Paine RS, Byers RK (1953). Transverse myelopathy in childhood. *Am J Dis Child* 85: 151–163.
- Pandit L, Rao S (1996). Recurrent myelitis. *J Neurol Neurosurg Psychiatry* 60: 336–338.
- Papeix C, Vidal JS, de Seze J et al. (2007). Immunosuppressive therapy is more effective than interferon in neuromyelitis optica. *Mult Scler* 13: 256–259.
- Paty DW, Blume WT, Brown WF et al. (1979). Chronic progressive myelopathy: investigation with CSF electrophoresis, evoked potentials, and CT scan. *Ann Neurol* 6: 419–424.
- Paul F, Jarius S, Aktas O et al. (2007). Antibody to aquaporin 4 in the diagnosis of neuromyelitis optica. *PLoS Med* 4: e133.
- Paus S, Promse A, Schmidt S et al. (2003). Treatment of steroid-unresponsive tumefactive demyelinating disease with plasma exchange. *Neurology* 61: 1022, author reply 1022.
- Pawate S, Moses H, Sriram S (2009). Presentations and outcomes of neurosarcoidosis: a study of 54 cases. *Q J Med* 102: 449–460.
- Pedersen C, Bonen H, Boesen F (1987). Transverse myelitis in mixed connective tissue disease. *Clin Rheumatol* 6: 290–292.
- Perumal J, Zabad R, Caon C et al. (2008). Acute transverse myelitis with normal brain MRI : long-term risk of MS. *J Neurol* 255: 89–93.
- Pidcock FS, Krishnan C, Crawford TO et al. (2007). Acute transverse myelitis in childhood: center-based analysis of 47 cases. *Neurology* 68: 1474–1480.
- Piper PG (1953). Disseminated lupus erythematosus with involvement of the spinal cord. *JAMA* 153: 215–217.
- Pitcock SJ, Lennon VA (2008). Aquaporin-4 autoantibodies in a paraneoplastic context. *Arch Neurol* 65: 629–632.
- Pitcock SJ, Lucchinetti CF, Lennon VA (2003). Anti-neuronal nuclear autoantibody type 2: paraneoplastic accompaniments. *Ann Neurol* 53: 580–587.
- Pitcock SJ, Lucchinetti CF, Parisi JE et al. (2005). Amphiphysin autoimmunity: paraneoplastic accompaniments. *Ann Neurol* 58: 96–107.
- Pitcock SJ, Weinshenker BG, Lucchinetti CF et al. (2006a). Neuromyelitis optica brain lesions localized at sites of high aquaporin 4 expression. *Arch Neurol* 63: 964–968.
- Pitcock SJ, Lennon VA, Krecke K et al. (2006b). Brain abnormalities in neuromyelitis optica. *Arch Neurol* 63: 390–396.
- Pitcock SJ, Lennon VA, de Seze J et al. (2008). Neuromyelitis optica and non organ-specific autoimmunity. *Arch Neurol* 65: 78–83.
- Polman CH, Reingold SC, Edan G et al. (2005). Diagnostic criteria for multiple sclerosis: 2005 revisions to the “McDonald criteria”. *Ann Neurol* 58: 840–846.
- Polman C, Kappos L, Freedman MS et al. (2008). Subgroups of the BENEFIT study: risk of developing MS and treatment effect of interferon beta-1b. *J Neurol* 255: 480–487.
- Poppe AY, Lapierre Y, Melancon D et al. (2005). Neuromyelitis optica with hypothalamic involvement. *Mult Scler* 11: 617–621.
- Poser S, Herrmann-Gremmels I, Wikstrom J et al. (1978). Clinical features of the spinal form of multiple sclerosis. *Acta Neurol Scand* 57: 151–158.
- Pritchard C, Nadarajah K (2004). Tumour necrosis factor alpha inhibitor treatment for sarcoidosis refractory to conventional treatments: a report of five patients. *Ann Rheum Dis* 63: 318–320.
- Rabadi MH, Kundi S, Brett D et al. (2010). Neurological pictures. Primary Sjögren syndrome presenting as neuromyelitis optica. *J Neurol Neurosurg Psychiatry* 81: 213–214.
- Rajabally YA, Qaddoura B, Abbott RJ (2008). Steroid-responsive paraneoplastic demyelinating neuropathy and myelopathy associated with breast carcinoma. *J Clin Neuromusc Dis* 10: 65–69.

- Ramos-Remus C, Gomez-Vargas A, Guzman-Guzman JL et al. (1995). Frequency of atlantoaxial subluxation and neurologic involvement in patients with ankylosing spondylitis. *J Rheumatol* 22: 2120–2125.
- Rath JJ, Ronday HK, Wirtz PW (2010). Acute transverse myelitis in psoriatic arthritis. *J Neurol* 257: 457–458.
- Ravaglia S, Piccolo G, Ceroni M et al. (2007). Severe steroid-resistant post-infectious encephalomyelitis: general features and effects of IVIg. *J Neurol* 254: 1518–1523.
- Rawlinson DG, Braun CW (1981). Granulomatous angiitis of the nervous system first seen as relapsing myelopathy. *Arch Neurol* 38: 129–131.
- Renkawek K, Kida E (1983). Combined acute necrotic myelopathy (ANM) and cerebellar degeneration associated with malignant disease. *Clin Neuropathol* 2: 90–94.
- Reznik M (1979). Acute ascending poliomyelomalacia after treatment of acute lymphocytic leukemia. *Acta Neuropathol* 45: 153–157.
- Richter RB, Moore RY (1968). Non-invasive central nervous system disease associated with lymphoid tumors. *Johns Hopkins Med J* 122: 271–283.
- Roemer SF, Parisi JE, Lennon VA et al. (2007). Pattern-specific loss of aquaporin-4 immunoreactivity distinguishes neuromyelitis optica from multiple sclerosis. *Brain* 130: 1194–1205.
- Ropper AH, Poskanzer DC (1978). The prognosis of acute and subacute transverse myelopathy based on early signs and symptoms. *Ann Neurol* 4: 51–59.
- Ropper AH, Ayata C, Adelman L (2003). Vasculitis of the spinal cord. *Arch Neurol* 60: 1791–1794.
- Rourke T, Hamidian JA, Pretorius P et al. (2009). Intraoperative, imaging and pathological features in spinal cord vasculitis. *J Clin Neurosci* 16: 1093–1095.
- Rudge P, Webster AD, Revesz T et al. (1996). Encephalomyelitis in primary hypogammaglobulinaemia. *Brain* 119: 1–15.
- Ruet A, Deloire MS, Ouallet JC et al. (2011). Predictive factors for multiple sclerosis in patients with clinically isolated spinal cord syndrome. *Mult Scler* 17: 312–318.
- Ruiz-Arguelles GJ, Guzman-Ramos J, Flores-Flores J et al. (1998). Refractory hiccough heralding transverse myelitis in the primary antiphospholipid syndrome. *Lupus* 7: 49–50.
- Saadoun S, Waters P, Bell BA et al. (2010). Intra-cerebral injection of neuromyelitis optica immunoglobulin G and human complement produces neuromyelitis optica lesions in mice. 133: 349–361.
- Saiz A, Zuliani L, Blanco Y et al. (2007). Revised diagnostic criteria for neuromyelitis optica (NMO). Application in a series of suspected patients. *J Neurol* 254: 1233–1237.
- Sakushima K, Yabe I, Shiga T et al. (2011). FDG-PET SUV can distinguish between spinal sarcoidosis and myelopathy with canal stenosis. *J Neurol* 258: 227–230.
- Saleh S, Ghodsian S, Yakimova V et al. (2006). Effectiveness of infliximab in treating selected patients with sarcoidosis. *Respir Med* 100: 2053–2059.
- Sandberg-Wollheim M, Axell T, Hansen BU et al. (1992). Primary Sjögren's syndrome in patients with multiple sclerosis. *Neurology* 42: 845–847.
- Santos E, Shaunak S, Renowden S et al. (2010). Treatment of refractory neurosarcoidosis with infliximab. *J Neurol Neurosurg Psychiatry* 81: 241–246.
- Schaudinn H (1905). Vorläufiger Bericht über das Vorkommen von Spirochaeten in syphilitischen Krankheitsprodukten und bei Papillomen. *Arbeit Kaiserlich Gesundheit XXII*: 527–534.
- Scott TF, Kassab SL, Singh S (2005). Acute partial transverse myelitis with normal cerebral magnetic resonance imaging: transition rate to clinically definite multiple sclerosis. *Mult Scler* 11: 373–377.
- Sebire G, Hollenberg H, Meyer L et al. (1997a). High dose methylprednisolone in severe acute transverse myelopathy. *Arch Dis Child* 76: 167–168.
- Sebire G, Hollenberg H, Meyer L et al. (1997b). High dose methylprednisolone in severe acute transverse myelopathy. *Arch Dis Child* 76: 167–168.
- Seifert T, Enzinger C, Ropele S et al. (2005). Relapsing acute transverse myelitis: a specific entity. *Eur J Neurol* 12: 681–684.
- Sellner J, Luthi N, Buhler R et al. (2008). Acute partial transverse myelitis: risk factors for conversion to multiple sclerosis. *Eur J Neurol* 15: 398–405.
- Semins H, Nugent GR, Chou SM (1972). Intramedullary spinal cord sarcoidosis. Case report. *J Neurosurg* 37: 233–236.
- Sharp GC (1975). Mixed connective tissue disease. *Bull Rheum Dis* 25: 828–831.
- Sharp GC, Irvin WS, Tan EM et al. (1972). Mixed connective tissue disease – an apparently distinct rheumatic disease syndrome associated with a specific antibody to an extractable nuclear antigen (ENA). *Am J Med* 52: 148–159.
- Shian WJ, Chi CS (1994). Acute transverse myelitis in children: clinical analysis of seven cases. *Chin Med J* 54: 57–61.
- Shimizu J, Hatanaka Y, Hasegawa M et al. (2010). IFNbeta-1b may severely exacerbate Japanese optic-spinal MS in neuromyelitis optica spectrum. *Neurology* 75: 1423–1427.
- Sieben GM, De Reuck JL, De Bruyne JC et al. (1981). Subacute necrotic myelopathy. Its appearance eight years after cure of a breast carcinoma. *Arch Neurol* 38: 775–777.
- Siekert RG, Clark EC (1955). Neurologic signs and symptoms as early manifestations of systemic lupus erythematosus. *Neurology* 5: 84–88.
- Sigal LH (1987). The neurologic presentation of vasculitic and rheumatologic syndromes. A review. *Medicine* 66: 157–180.
- Silverstein A, Feuer MM, Siltzbach LE (1965). Neurologic sarcoidosis. Study of 18 cases. *Arch Neurol* 12: 1–11.
- Simnad VI, Pisani DE, Rose JW (1997). Multiple sclerosis presenting as transverse myelopathy: clinical and MRI features. *Neurology* 48: 65–73.
- Sinclair C, Kirk J, Herron B et al. (2007). Absence of aquaporin-4 expression in lesions of neuromyelitis optica but increased expression in multiple sclerosis lesions and normal-appearing white matter. *Acta Neuropathol* 113: 187–194.

- Singer DH (1902). Pathology of so-called myelitis. *Brain* 25: 332–340.
- Siva A, Saip S (2009). The spectrum of nervous system involvement in Behçet's syndrome and its differential diagnosis. *J Neurol* 256: 513–529.
- Sjögren H (1933). Zur Kenntnis der Keratoconjunctivitis sicca: Keratitis filiformis bei Hypofunktion der Tranendrüsen. *Acta Ophthalmol (Suppl. 2)*: 1–151.
- Sjögren H (1935). Zur Kenntnis der Keratoconjunctivitis sicca. II. Allgemeine Symptomatologie und Aetiologie. *Acta Ophthalmol* 13: 1–39.
- Snyder DA, Tessler HH (1980). Vogt–Koyanagi–Harada syndrome. *Am J Ophthalmol* 90: 69–75.
- Snyder R, Towfighi J, Gonatas NK (1976). Sarcoidosis of the spinal cord. Case report. *J Neurosurg* 44: 740–743.
- Sofat N, Venables PJ (2008). Is Sjögren myelopathy Devic disease? *Ann Rheum Dis* 67: 730–731.
- Sollberger M, Fluri F, Baumann T et al. (2004). Successful treatment of steroid-refractory neurosarcoidosis with infliximab. *J Neurol* 251: 760–761.
- Spiegel HA (1936). Myelomalacia in a three year old child. Report of a case. *Arch Pediatr* 53: 500–504.
- Squatrito D, Colagrande S, Emmi L (2010). Devic's syndrome and primary APS: a new immunological overlap. *Lupus* 19: 1337–1339.
- Staub HL, Capobianco K, Neto PR et al. (1992). Rheumatoid arthritis, transverse myelitis and antiphospholipid antibodies. *Clin Exp Rheumatol* 10: 626–627.
- Stich O, Rauer S (2006). Qualitative evidence of anti-Ri specific intrathecal antibody synthesis and quantification of anti-Ri antibodies in serial samples from a patient with anti-Ri syndrome. *J Neurol Neurosurg Psychiatry* 77: 282–283.
- Storey E, McKelvie PA (1991). Necrotizing myelopathy associated with multiple myeloma. *Acta Neurol Scand* 84: 98–101.
- Suchett-Kaye AI (1948). Acute transverse myelitis complicating pneumonia; report of a case. *Lancet* 2: 417.
- Tait MJ, Saadoun S, Bell BA et al. (2008). Water movements in the brain: role of aquaporins. *Trends Neurosci* 31: 37–43.
- Takahashi T, Fujihara K, Nakashima I et al. (2006). Establishment of a new sensitive assay for anti-human aquaporin-4 antibody in neuromyelitis optica. *Tohoku J Exp Med* 210: 307–313.
- Takahashi T, Fujihara K, Nakashima I et al. (2007). Anti-aquaporin-4 antibody is involved in the pathogenesis of NMO: a study on antibody titre. *Brain* 130: 1235–1243.
- Tan CT (1989). Prognosis of patients who present with an episode of myelopathy of unknown origin in Malaysia: a retrospective study of 52 patients. *Aust N Z J Med* 19: 297–302.
- Tanaka ST, Stone AR, Kurzrock EA (2006). Transverse myelitis in children: long-term urological outcomes. *J Urol* 175: 1865–1868, discussion 1868.
- Tanaka M, Matsushita T, Tateishi T et al. (2008). Distinct CSF cytokine/chemokine profiles in atopic myelitis and other causes of myelitis. *Neurology* 71: 974–981.
- Tartaglino LM, Friedman DP, Flanders AE et al. (1995). Multiple sclerosis in the spinal cord: MR appearance and correlation with clinical parameters. *Radiology* 195: 725–732.
- Tippett DS, Fishman PS, Panitch HS (1991). Relapsing transverse myelitis. *Neurology* 41: 703–706.
- Tomietto P, D'Agostini S, Annese V et al. (2007). Mycophenolate mofetil and intravenous dexamethasone in the treatment of persistent lupus myelitis. *J Rheumatol* 34: 588–591.
- Torabi AM, Patel RK, Wolfe GI et al. (2004). Transverse myelitis in systemic sclerosis. *Arch Neurol* 61: 126–128.
- Torisu H, Kira R, Ishizaki Y et al. (2010). Clinical study of childhood acute disseminated encephalomyelitis, multiple sclerosis, and acute transverse myelitis in Fukuoka Prefecture, Japan. *Brain Dev* 32: 454–462.
- Toro G, Roman GC, Navarro-Roman L et al. (1994). Natural history of spinal cord infarction caused by nucleus pulposus embolism. *Spine* 19: 360–366.
- Transverse Myelitis Consortium Working Group (2002). Proposed diagnostic criteria and nosology of acute transverse myelitis. *Neurology* 59: 499–505.
- Urai Y, Matsumoto K, Shimamura M et al. (2009). Paraneoplastic necrotizing myelopathy in a patient with advanced esophageal cancer: An autopsied case report. *J Neurol Sci* 280: 113–117.
- Van Gehuchten P (1927). Un cas de myélite nécrotique aiguë. *Rev Neurol* 1: 505–519.
- Vernant JC, Cabre P, Smadja D et al. (1997). Recurrent optic neuromyelitis with endocrinopathies: a new syndrome. *Neurology* 48: 58–64.
- Veron JP, Escourrolle R, Buge A et al. (1974). Acute necrotic myelopathy. *Eur Neurol* 11: 83–96.
- Walker AG (1961). Sarcoidosis of the brain and spinal cord. *Postgrad Med J* 37: 431–436.
- Wandinger KP, Stangel M, Witte T et al. (2010). Autoantibodies against aquaporin-4 in patients with neuropsychiatric systemic lupus erythematosus and primary Sjögren's syndrome. *Arth Rheum* 62: 1198–1200.
- Warabi Y, Matsumoto Y, Hayashi H (2007). Interferon beta-1b exacerbates multiple sclerosis with severe optic nerve and spinal cord demyelination. *J Neurol Sci* 252: 57–61.
- Watanabe S, Misu T, Miyazawa I et al. (2007a). Low-dose corticosteroids reduce relapses in neuromyelitis optica: a retrospective analysis. *Mult Scler* 13: 968–974.
- Watanabe S, Nakashima I, Misu T et al. (2007b). Therapeutic efficacy of plasma exchange in NMO-IgG-positive patients with neuromyelitis optica. *Mult Scler* 13: 128–132.
- Weatherby SJ, Davies MB, Hawkins CP et al. (2000). Transverse myelopathy, a rare complication of mixed connective tissue disease: comparison with SLE related transverse myelopathy. *J Neurol Neurosurg Psychiatry* 68: 532–533.
- Weiler CR, Bankers-Fulbright JL (2005). Common variable immunodeficiency: test indications and interpretations. *Mayo Clin Proc* 80: 1187–1200.
- Weinshenker BG, O'Brien PC, Petterson TM et al. (1999). A randomized trial of plasma exchange in acute central nervous system inflammatory demyelinating disease. *Ann Neurol* 46: 878–886.

- Weinshenker BG, Wingerchuk DM, Vukusic S et al. (2006). Neuromyelitis optica IgG predicts relapse after longitudinally extensive transverse myelitis. *Ann Neurol* 59: 566–569.
- Weinstock-Guttman B, Ramanathan M, Lincoff N et al. (2006). Study of mitoxantrone for the treatment of recurrent neuromyelitis optica (Devic disease). *Arch Neurol* 63: 957–963.
- Weiss TD, Nelson JS, Woolsey RM et al. (1978). Transverse myelitis in mixed connective tissue disease. *Arth Rheum* 21: 982–986.
- West SG (1994). Neuropsychiatric lupus. *Rheum Dis Clin North Am* 20: 129–158.
- Whiteley AM, Hauw JJ, Escourolle R (1979). A pathological survey of 41 cases of acute intrinsic spinal cord disease. *J Neurol Sci* 42: 229–242.
- Wiederholt WC, Siekert RG (1965). Neurological manifestations of sarcoidosis. *Neurology* 15: 1147–1154.
- Williams RA, Billings JJ, De Gruchy GC (1962). Acute myelitis complicating lymphosarcoma. *Med J Aust* 49: 128–133.
- Wilmshurst JM, Walker MC, Pohl KR (1999). Rapid onset transverse myelitis in adolescence: implications for pathogenesis and prognosis. *Arch Dis Child* 80: 137–142.
- Wilson JW, Morales A, Sharp D (1983). Necrotizing myelopathy associated with renal cell carcinoma. *Urology* 21: 390–392.
- Wingerchuk DM, Hogancamp WF, O'Brien PC et al. (1999). The clinical course of neuromyelitis optica (Devic's syndrome). *Neurology* 53: 1107–1114.
- Wingerchuk DM, Lennon VA, Pittock SJ et al. (2006). Revised diagnostic criteria for neuromyelitis optica. *Neurology* 66: 1485–1489.
- Wingerchuk DM, Pittock SJ, Lucchinetti CF et al. (2007). A secondary progressive clinical course is uncommon in neuromyelitis optica. *Neurology* 68: 603–605.
- Wood EH, Bream CA (1959). Spinal sarcoidosis. *Radiology* 73: 226–233.
- Wyburn-Mason R (1943). Venous abnormalities. In: *The vascular abnormalities and tumours of the spinal cord and its membranes*, Henry Kimpton, London, pp. 1–196.
- Yamaguchi Y, Yoshimura T, Hosokawa S et al. (1991). A case of mixed connective tissue disease with subacute transverse myelopathy. *Rinsho shinkeigaku* 31 (10): 1099–1102.
- Yamasaki K, Horiuchi I, Minohara M et al. (2000). Hyperprolactinemia in optico-spinal multiple sclerosis. *Intern Med* 39: 296–299.
- Yiu EM, Kornberg AJ, Ryan MM et al. (2009). Acute transverse myelitis and acute disseminated encephalomyelitis in childhood: spectrum or separate entities? *J Child Neurol* 24: 287–296.
- Yoshioka H, Matsubara T, Miyanomae Y et al. (1996). Spinal cord MRI in neuro-Behçet's disease. *Neuroradiology* 38: 661–662.
- Young J, Quinn S, Hurrell M et al. (2009). Clinically isolated acute transverse myelitis: prognostic features and incidence. *Mult Scler* 15: 1295–1302.
- Yucesan C, Arslan O, Arat M et al. (2007). Therapeutic plasma exchange in the treatment of neuroimmunologic disorders: review of 50 cases. *Transfus Apher Sci* 36: 103–107.
- Zajicek JP, Scolding NJ, Foster O et al. (1999). Central nervous system sarcoidosis – diagnosis and management. *Q J Med* 92: 103–117.
- Zandman-Goddard G, Levy Y, Weiss P et al. (2003). Transverse myelitis associated with chronic hepatitis C. *Clin Exp Rheumatol* 21: 111–113.
- Zeng XN, Sun XL, Gao L et al. (2007). Aquaporin-4 deficiency down-regulates glutamate uptake and GLT-1 expression in astrocytes. *Mol Cell Neurosci* 34: 34–39.
- Zoli A, Mariano M, Fusari A et al. (2005). Atopic myelitis: first case report outside Japan? *Allergy* 60: 410–411.