

UCLA

UCLA Previously Published Works

Title

In Vivo Evaluation of the Limbus Using Anterior Segment Optical Coherence Tomography

Permalink

<https://escholarship.org/uc/item/3v41f1s4>

Journal

Translational Vision Science & Technology, 7(4)

ISSN

2164-2591

Authors

Le, Qihua
Cordova, Daniel
Xu, Jianjiang
et al.

Publication Date

2018-08-07

DOI

10.1167/tvst.7.4.12

Peer reviewed

In Vivo Evaluation of the Limbus Using Anterior Segment Optical Coherence Tomography

Qihua Le^{1,2}, Daniel Cordova¹, Jianjiang Xu², and Sophie X. Deng¹

¹ Stein Eye Institute, Cornea Division, David Geffen School of Medicine, University of California, Los Angeles, CA, USA

² Department of Ophthalmology, Eye & ENT Hospital of Fudan University, Shanghai, China

Correspondence: Sophie X. Deng, MD, PhD, 100 Stein Plaza, Los Angeles, CA 90095, USA. e-mail: deng@jsei.ucla.edu

Jianjiang Xu, MD, PhD, No. 83 Fenyang Road, Shanghai, 20031, China. e-mail: jianjiangxu@126.com

Received: 5 March 2018

Accepted: 12 June 2018

Published: 7 August 2018

Keywords: anterior segment optical coherence tomography; limbal epithelium; limbus; limbal stem cells; limbal stem cell deficiency

Citation: Le Q, Cordova D, Xu J, Deng SX. In vivo evaluation of the limbus using anterior segment optical coherence tomography. *Trans Vis Sci Tech.* 2018;7(4):12, <https://doi.org/10.1167/tvst.7.4.12>
Copyright 2018 The Authors

Purposes: To investigate the limbal structure using anterior segment optical coherence tomography (AS-OCT) and compare the difference between a Chinese Han population and a Caucasian population.

Methods: Sixty healthy Chinese Han subjects (109 eyes, Chinese group) and 32 healthy Caucasian subjects (51 eyes, Caucasian group) were included in this comparative cross-sectional study. The central cornea and the superior, inferior, nasal, and temporal limbal regions of each subject underwent Fourier-domain AS-OCT. The following parameters were measured: corneal epithelial thickness (CET), maximum limbal epithelial thickness (LET), the mean LET, the width of limbus, distance between scleral spur and the location where limbal epithelium was the thickest (S-T), and limbal epithelial area between scleral spur and the end of Bowman's layer (LEA).

Results: CET was similar in both groups ($P = 0.577$). The width of limbus was more than 32.8% greater in all limbal quadrants in the Caucasian group (range, 1.25–2.20 mm) than in the Chinese group (range, 0.81–1.40 mm). S-T and LEA were also significantly higher in all limbal quadrants in the Caucasian group (all $P < 0.001$). The maximum LET and mean LET were 7.8% and 6.9% thicker at the nasal limbus and 8.1% and 8.7% thicker in the temporal limbus in Caucasian subjects than in Chinese subjects.

Conclusions: The limbal structures can be visualized using AS-OCT and differ significantly between the Caucasian and Chinese eyes.

Translational Relevance: Research of the limbus and surgeons performing procedures involving the limbal area should take into consideration of the anatomic differences especially when limbus is used as an anatomic reference.

Introduction

The junction between the cornea and conjunctiva is an important anatomic site for many vision-related biological activities. The internal zone of this junction contains the principal pathway of aqueous humor outflow, and the external surface of this junction is covered by limbal epithelium. Limbal stem cells (LSCs), which are essential for maintaining the integrity of the corneal surface and transparency of the cornea,¹ are located at the basal layer of limbal epithelium. Under slit lamp biomicroscopy, the limbus is a thin blue gray ring transiting between the cornea and sclera (Fig. 1A). Nevertheless, the

border of the “anatomical” limbus defined by histologic methods is different: the anterior border of the limbus is the line between the ending point of Bowman's layer and Descemet's membrane at the peripheral cornea, whereas the posterior border is the line that extends from the scleral spur and is perpendicular to the tangent of the external surface globe (Figs. 1B–E).²

Because of the opacity of the sclera, slit-lamp biomicroscopy cannot visualize the details of the deep limbal structure. Ultrasound biomicroscopy cannot provide high-quality images of limbal epithelium for further analysis because of its axial resolution of 25 μm .³ In addition, in eyes with limbal stem cell

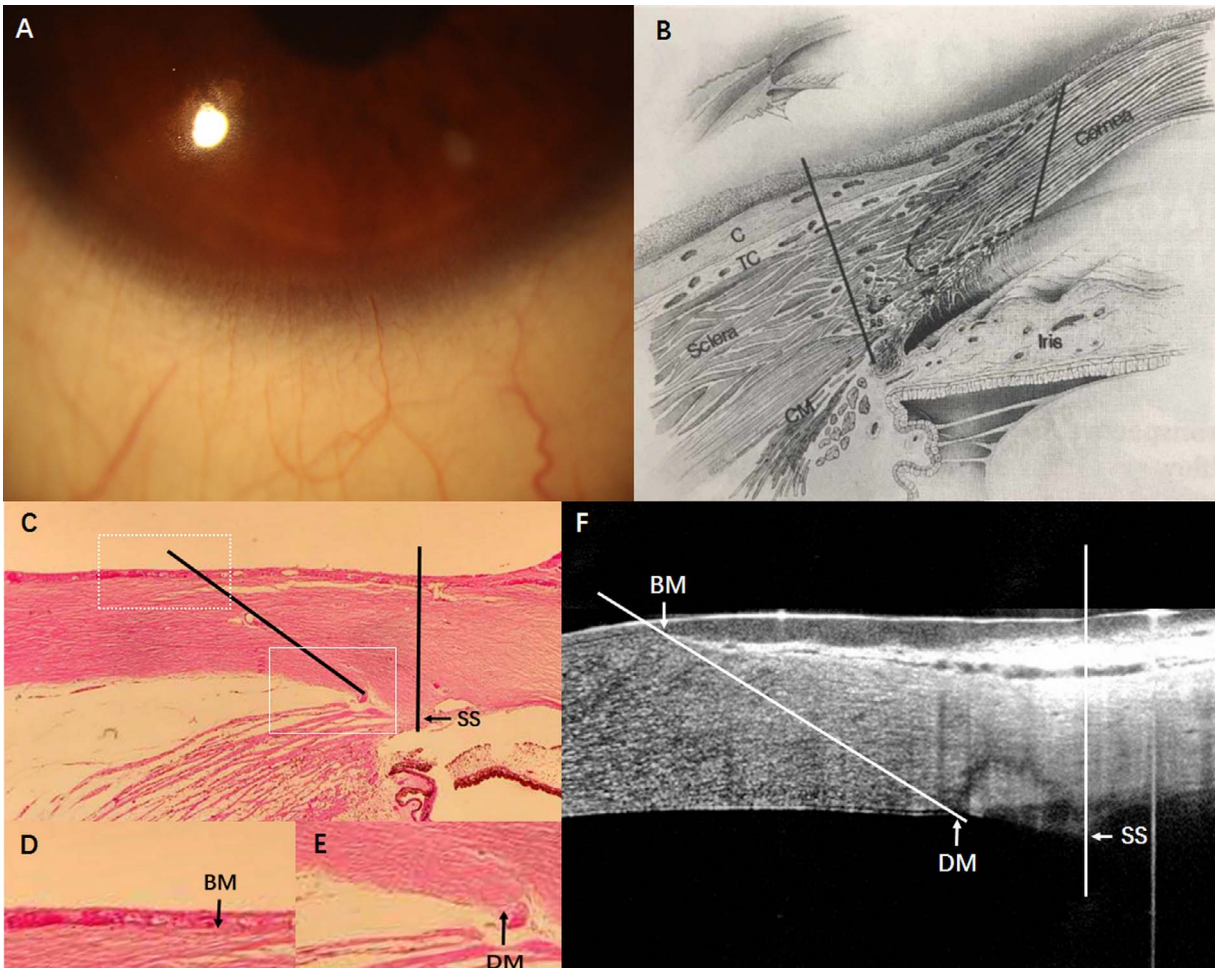


Figure 1. The outline of the limbus under various examinations. The limbus is defined as the *grayish zone* in the slit lamp photo (A). From “The anatomy of the limbus,” by E. M. Van Buskirk, 1989, *Eye (Lond)*, 3, p. 102. Copyright 1989 by Springer Nature. Reprinted with permission. The range of the “anatomical” limbus is defined by two *black solid lines* in the schematic diagram of the limbus (B), by two *black straight lines* in the histological section (C), and by two *white straight lines* in the AS-OCT image (F). The *white frames* in C were magnified to show the ending points of Bowman’s layer (D) and Descemet’s membrane (E). BM, Bowman’s membrane; C, conjunctiva; CM, ciliary muscle; DM, Descemet’s membrane; SC, Schlemm’s canal; SS, scleral spur; TC, Tenon’s capsule; TM, trabecular meshwork.

deficiency (LSCD), the exact location of limbus cannot be identified using slit lamp microscopy because the normal well delineated sclera-cornea junction is often lost. Histologic method to define the location of limbus is not applicable in live patients. Therefore, anterior segment optical coherence tomography (AS-OCT), a completely noninvasive and noncontact technique that acquires cross-sectional tomographic imaging of ocular anterior segment, could be a more accurate objective method to define the location and structure of limbus in both normal and pathologic conditions. Fourier-domain AS-OCT, with an axial resolution of 5 μm , is a promising method in the visualization of the structural details of the limbus.^{4–6} The cross-sectional images of the limbus obtained by AS-OCT (Fig. 1F)

reflect those seen in the histological section (Fig. 1C). The border of “anatomical” limbus can be clearly defined, and the measurements are feasible. AS-OCT has been shown to be a promising diagnostic tool in many ocular surface disorders with involvement of the limbus.^{7–11}

Recently, several parameters of the limbus, such as limbal epithelial thickness (LET), could be used to evaluate the function of LSCs.^{9,11} There are anatomic variations of the limbus due to aging,^{7,8} and the difference among different ethnic backgrounds is unknown. The detailed anatomic structure of limbus defined by AS-OCT has not been described. Identification of normal variation in the limbal structures among different races is also essential to establish a standardized method to assess the degree of LSCD by

AS-OCT. In the current study, we used Fourier-domain AS-OCT to investigate the anatomic features of the limbus and performed a comparative observational study of the limbal structures between a Chinese Han population and a Caucasian population in the United States.

Materials and Methods

Subjects

This study was conducted in accordance with the Declaration of Helsinki and approved by the Institutional Review Board at the University of California, Los Angeles, and the Ethics Committee of Eye & Ear, Nose Throat Hospital of Fudan University. Written informed consent was obtained from all subjects. Chinese volunteers were recruited from April 2016 to August 2016 (i.e., the Chinese group). All of them were from a Chinese Han population. Volunteers in the United States (i.e., the US group) who were all Caucasians were enrolled from October 2015 to August 2017. Before enrollment, all participants underwent a comprehensive ophthalmic examination that included slit-lamp biomicroscopy, intraocular pressure measurement, and refraction. The exclusion criteria included prior ocular trauma or surgery, active ocular pathology, current or long-term topical medication, ocular or systemic diseases that may affect the cornea, and a history of contact lens wear, glaucoma, or dry eye.

Image Acquisition

A Fourier-domain OCT system (RTVue-100; Optovue, Inc., Fremont, CA) with a corneal anterior module long adaptor lens was used in this study. To obtain the images of the central cornea, the pachymetry scan mode was used, and the scans were centered on the coaxially fixating corneal light reflex identified by the central bright reflection on the OCT scan. The cross-line scan mode was used to obtain images of each limbus quadrant (superior, inferior, nasal, and temporal) as subjects looked upward, downward, left, and right. During image acquisition, the subjects were asked to fix their gaze at a peripheral target to maintain perpendicularity with the OCT beam at the surface of the targeted tissue; this action was essential for accurate measurement. A minimum of three scans at each limbus location was performed. The images in which scleral spur cannot be clearly discriminated were excluded from analysis.

Measurement

The corneal epithelial thickness (CET) map was automatically generated by the built-in software of AS-OCT (version 2015.0.0.69; Optovue, Inc.). The thickness of epithelium in the central 2-mm diameter zone was considered to be the CET. The measurements were performed by an experienced ophthalmologist and were based on a manual four-step segmentation method shown in [Figure 2](#). The width of the limbus which was defined as the distance between the lines crossing the scleral spur and the end of Bowman's layer, and the limbal epithelium area (LEA) between these two lines was measured with a built-in measuring tool. The maximum LET and the distance between the scleral spur and the line that crossed the maximum LET (S-T) were also measured, which was defined as the location of limbus from the scleral spur. The mean LET was calculated by dividing LEA by width of limbus because the posterior surface of the limbal epithelium was curve-shaped in the majority of cases and accurate measurement of mean LET could not be made directly by the built-in software. For each parameter, the value was determined as the average of three independent measurements.

Statistical Analysis

Statistical analyses were performed with statistical software (SPSS for Windows, version 19.0; SPSS, Inc., Chicago, IL). Basic descriptive statistics were calculated on all data gathered, and values were reported as mean values \pm SD. Comparisons between groups were conducted with Student's *t*-test (or Mann-Whitney *U* test where appropriate). Differences in each parameter among different quadrants were tested by one-way ANOVA with the post hoc Tukey test. Two-tailed *P* values $<$ 0.05 were considered to indicate statistical significance.

Results

A total of 60 Chinese Han subjects (109 eyes) and 32 Caucasian subjects in the United States (51 eyes) were recruited to this study. There were 27 men and 33 women in the Chinese group and 14 men and 18 women in the US group ($P = 0.908$). The average and median ages were 49.1 ± 19.3 and 53 years in the Chinese group (range, 21–80), and 51.6 ± 19.4 and 52 years in the US group (range, 18–87), respectively ($P = 0.583$).

As shown in the [Table](#) and [Figure 3](#), the width of

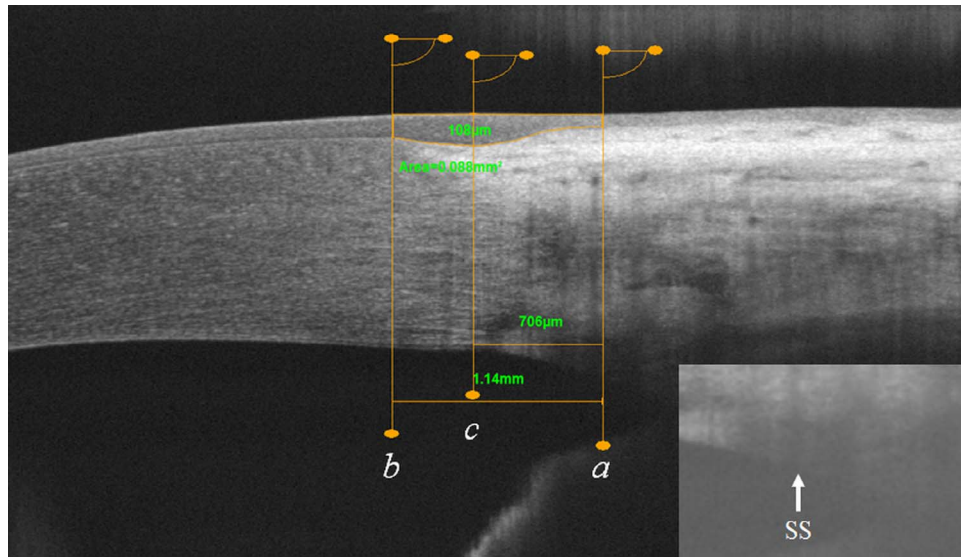


Figure 2. Measurement based on a manual four-step segmentation method in a cross-line scan image. First, one line crossing the scleral spur (line *a*) is drawn, which is perpendicular to the tangent of the external surface of the limbus. If the scleral spur (SS) cannot be visualized clearly, the brightness and contrast is adjusted to obtain the best visualization, as shown in the small figure at *bottom right*. Then, the maximum LET was manually measured at the thickest part of limbal epithelium. Third, two lines running parallel to line *a* are drawn, one crossing the ending point of Bowman's layer at the peripheral cornea (line *b*) and the other crossing the maximum LET (line *c*). Finally, the distance between line *a* and line *b* (the width of limbus), the distance between line *a* and line *c* (S-T), and the limbal epithelium area between line *a* and line *b* (LEA) were measured.

the limbus was 36.3% greater in the superior quadrant, 32.8% greater in the inferior quadrant, 35.2% greater in the nasal quadrant, and 32.8% greater in the temporal quadrant in the Caucasian group than in the Chinese group (all $P < 0.001$). Similarly, the distance from the center of the limbus to the scleral spur (S-T) was 33.1% greater in the superior quadrant, 18.5% greater in the inferior quadrant, 27.9% greater in the nasal quadrant, and 26.7% greater in the temporal quadrant in the Caucasian group than in the Chinese group (all $P < 0.001$). In these two groups, the width of the limbus was the greatest, and the limbus was located furthest away from the scleral spur in the superior limbus, followed by the inferior, temporal, and nasal limbus. Further subgroup comparisons of the widths of limbus and S-T among the four quadrants were all statistically significant, except the comparison between the nasal and temporal quadrants in Caucasian eyes. LEA in the Caucasian eyes was 37.7%, 34.6%, 41.2%, and 40.7% larger in the superior, inferior, nasal, and temporal quadrants, respectively, than those in the corresponding quadrants in the Chinese eyes (all $P < 0.001$; [Table](#); [Fig. 3](#)).

Epithelial thickness within the central 2-mm cornea was $53.2 \pm 3.9 \mu\text{m}$ in the Chinese group and $53.6 \pm 3.6 \mu\text{m}$ in the Caucasian group ($P = 0.577$).

The maximum LET and the mean LETs at different locations are listed in the [Table](#). In both groups, the maximum LET and the mean LET were significantly thinner in the nasal and temporal areas than they were in the superior and inferior area (all $P < 0.001$). The maximum LET and the mean LET did not have significant differences between the superior and inferior quadrants or between the nasal and temporal quadrants. The maximum LETs at the nasal and temporal quadrants were 7.8% and 8.1% thicker in the Caucasian group than in the Chinese group ($P = 0.003$ and $P = 0.002$, respectively). The mean LETs in the nasal and temporal quadrants in the Caucasian group was 6.9% and 8.7% thicker ($P = 0.002$ and <0.001 , respectively). The maximum LET and the mean LET at the superior and inferior limbus were similar between the two groups.

Discussion

The anatomic structure of the limbus was predominantly analyzed in ex vivo histologic studies before in vivo imaging techniques became available. The measurements of the structures were probably not accurate after fixation and dehydration during the preparation of tissue sections. In vivo imaging

Table. Comparisons of Limbal Parameters Between the Chinese Han and Caucasian Population

| | Superior | Inferior | Nasal | Temporal | <i>P</i> Value ^a | Subgroup Comparisons |
|--------------------------------|-----------------|-----------------|-----------------|-----------------|-----------------------------|--|
| Limbus width ^b (mm) | | | | | | |
| CH | 1.40 ± 0.24 | 1.21 ± 0.17 | 0.81 ± 0.19 | 0.86 ± 0.17 | <0.001 | S vs. I*, S vs. N*, S vs. T*, I vs. N*, I vs. T*, N vs. T* |
| CA | 2.20 ± 0.33** | 1.80 ± 0.23** | 1.25 ± 0.27** | 1.28 ± 0.28** | <0.001 | S vs. I*, S vs. N*, S vs. T*, I vs. N*, I vs. T* |
| S-T (mm) | | | | | | |
| CH | 1.03 ± 0.16 | 0.88 ± 0.15 | 0.62 ± 0.14 | 0.66 ± 0.11 | <0.001 | S vs. I*, S vs. N*, S vs. T*, I vs. N*, I vs. T*, N vs. T* |
| CA | 1.54 ± 0.33** | 1.08 ± 0.32** | 0.86 ± 0.31** | 0.90 ± 0.24** | <0.001 | S vs. I*, S vs. N*, S vs. T*, I vs. N*, I vs. T* |
| LEA (mm ²) | | | | | | |
| CH | 0.096 ± 0.021 | 0.085 ± 0.020 | 0.047 ± 0.014 | 0.048 ± 0.012 | <0.001 | S vs. I*, S vs. N*, S vs. T*, I vs. N*, I vs. T* |
| CA | 0.154 ± 0.031** | 0.130 ± 0.035** | 0.080 ± 0.018** | 0.081 ± 0.018** | <0.001 | S vs. I*, S vs. N*, S vs. T*, I vs. N*, I vs. T* |
| Maximum LET (μm) | | | | | | |
| CH | 96.9 ± 15.9 | 97.2 ± 17.0 | 74.3 ± 11.2 | 73.9 ± 11.9 | <0.001 | S vs. N*, S vs. T*, I vs. N*, I vs. T* |
| CA | 102.5 ± 21.8 | 100.6 ± 27.7 | 80.6 ± 13.5** | 80.4 ± 12.4** | <0.001 | S vs. N*, S vs. T*, I vs. N*, I vs. T* |
| Mean LET (μm) | | | | | | |
| CH | 71.4 ± 11.7 | 72.3 ± 12.7 | 61.1 ± 8.3 | 59.8 ± 8.1 | <0.001 | S vs. N*, S vs. T*, I vs. N*, I vs. T* |
| CA | 70.3 ± 14.0 | 72.0 ± 15.8 | 65.6 ± 9.2** | 65.5 ± 7.9** | 0.012 | S vs. N*, S vs. T*, I vs. N*, I vs. T* |

CH, Chinese eyes; CA, Caucasian eyes; I, inferior; LEA, limbal epithelial area; LET, limbal epithelial thickness; N, nasal; S, superior; S-T, distance.

* *P* < 0.05; ** *P* < 0.05 when compare CH and CA groups.

^a *P* values of ANOVA performed among four limbal regions.

^b Width of the limbus was the distance between the scleral spur and the ending point of Bowman's membrane.

techniques, such as AS-OCT, provide an opportunity to study the structures of the limbus more rapidly and accurately in patients.

It is generally accepted that the width of the limbus is between 1 and 2 mm.^{2,12,13} However, our study shows that the limbal width in the superior quadrant in Caucasian eyes is longer than 2 mm and that the limbal width in the nasal and temporal quadrants in

Chinese Han eyes is shorter than 1 mm. Compared with the limbal widths in the Chinese group, the limbal widths in the US Caucasian population are 32.8% to 36.7% longer in all four limbal quadrants. It has been considered that the Chinese eyes have smaller cornea than Caucasian eyes. The differences of corneal diameter, which is measured based on the horizontal visible iris diameter or angle-to-angle

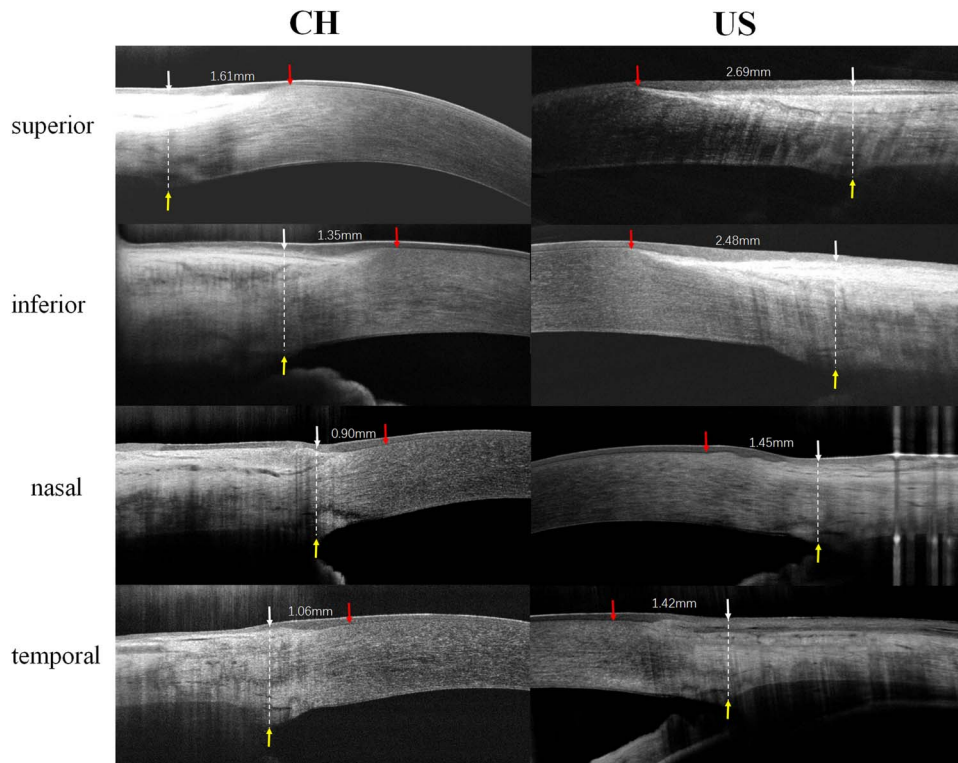


Figure 3. Representative images of the limbal region in each quadrant of eyes of Chinese Han and US subjects. The *left columns* are the limbal images of eyes of Chinese subjects, and the *right* are limbal images of eyes of US subjects. *Yellow arrows* show the scleral spur; *red arrows* show the ending points of the Bowman's membrane. The width of limbus (distance between the *red arrow* and the *white arrow*) is shown in each picture.

distance in many studies, ranges from 0.36 to 0.49 mm,^{14–16} which suggests that the Caucasian corneas are 3.0% to 4.2% larger than the Chinese ones. However, the current study shows that the limbal width was more than 32.8% longer in the Caucasian eyes in all four quadrants of limbus. Therefore, the anatomic difference of the limbus is not due to the small difference in the size of the cornea between these two races.

Compared with studies of the central cornea, few investigations using AS-OCT have focused on the limbal epithelium. Two reports have been published about the average LET in Chinese eyes. One study defined the limbus as having a 1-mm width extending centripetally from the scleral spur. The mean LETs were 75.23 μm in the superior quadrant, 75.29 μm in the inferior quadrant, 61.18 μm in the nasal quadrant, and 61.02 μm in the temporal quadrant,¹⁷ all of which are in agreement with our measurements made in the Chinese group. However, in another study on a Han population that arbitrarily defined the limbus located 1.5-mm extending centripetally from the scleral spur in every limbal quadrant, the mean LETs in the four

quadrants were found to be significantly less than the value observed in the current study.⁸ This discrepancy is likely due to the closer location of limbus in Han population observed in the current study, which showed that the limbal location from the scleral spur in the Chinese Han group was 1.03 mm in the superior quadrant, 0.88 mm in the inferior quadrant, 0.62 mm in the nasal quadrant, and 0.66 mm in the temporal quadrants. Therefore, LET measured further away from the actual location of limbus would be thinner. Taking these findings together, measurement of LET and LEA would be more accurate if it is based on the actual limbal location rather than on a single fixed value.

The current study shows that the mean LET and maximum LET are thicker at the superior and inferior quadrants than at the nasal and temporal areas in both groups. This finding is consistent with previous reports that the superior and inferior limbal regions reportedly have a larger number of LSCs and a higher density of limbal crypts than the nasal and temporal regions.^{18,19} The mean LET and maximum LET at the nasal and temporal limbus in the Chinese group are thinner than

those in the US group although the difference is less than 9%. However, the CETs are similar between the two groups indicating an overall normal homeostasis and function of the LSCs. The difference of LET between the Chinese and Caucasians might be due to normal variation among races. To elucidate the potential differences in LSC densities at the nasal limbus and temporal limbus, further studies using molecular markers of LSCs would be necessary.

In addition, the actual location of the sclera spur or the angle is important in ocular surgeries that use limbus as an anatomic reference, such as sclera-fixated posterior chamber intraocular lens and pars plana vitrectomy. The current technique uses the limbus as a landmark to position the intraocular lens (IOL) and the entry of the vitrector. The limbus locates more anterior in Caucasian than Chinese. A more accurate location of the IOL would result in a better reflective when the normal variation of limbus location is taken into consideration. Potential damage to the retina could be avoided in Chinese eyes in which the limbus is closer to the angle.

One limitation of this study is that the Caucasian subjects all come from the Southern California area, which might not be representative of all Caucasians. Another limitation is the small sample size. As no prior studies have been conducted to measure the length and anatomical features of limbus in different races, it was not possible to calculate sample size as there were no values from literature that could serve as the reference. Nevertheless, the current study shows that the difference between the two races is statistically significant. The findings of our study may provide the evidence for prospective sample size calculation in future studies.

In conclusion, detailed anatomic structure of the limbus can be evaluated using AS-OCT. There are anatomic variations in the limbus among races. The length of the limbus is longer and the location of the limbus is farther away from the scleral spur in the US Caucasian population than in the Chinese Han population. Investigators conducting studies involving pathologic alterations of the limbus and surgeons performing surgical intervention involving the limbal area should take into consideration these anatomic differences.

Acknowledgments

The authors thank Yujing Yang for her help in the volunteer recruitment and data collection, and

Yingwen Bi for her technical support in the histological work.

This study was supported by California Institute for Regenerative Medicine (CLIN1-08686; SXD) and in part by an unrestricted grant from Research to Prevent Blindness to the Stein Eye Institute. SXD received grant support from the National Eye Institute grants (5P30EY000331 and 1R01EY021797). XJ received grant support from the National Natural Science Foundation of China (81670820, 81670818) and the New Technology Joint Research Project in Shanghai Hospitals (SHDC12014114). The funding organizations had no role in the design or conduct of this research.

Disclosure: **Q. Le**, None; **D. Cordova**, None; **J. Xu**, None; **S.X. Deng**, None

References

1. Sangwan V. Limbal stem cells in health and disease. *Biosci Rep*. 2001;21:385–405.
2. Van Buskirk EM. The anatomy of the limbus. *Eye (Lond)*. 1989;3:101–108.
3. Maslin JS, Barkana Y, Dorairaj SK. Anterior segment imaging in glaucoma: an updated review. *Indian J Ophthalmol*. 2015;63:630–640.
4. Feng Y, Simpson T. Comparison of human central cornea and limbus in vivo using optical coherence tomography. *Optom Vis Sci*. 2005;82:416–419.
5. Haagdorens M, Behaegel J, Rozema J, et al. A method for quantifying limbal stem cell niches using OCT imaging. *Br J Ophthalmol*. 2017;101:1250–1255.
6. Li P, An L, Reif R, Shen TT, Johnstone M, Wang RK. In vivo microstructural and microvascular imaging of human corneo-scleral limbus using optical coherence tomography. *Biomed Opt Express*. 2011;2:3109–3118.
7. Lin HC, Tew TB, Hsieh YT, et al. Using optical coherence tomography to assess the role of age and region in corneal epithelium and palisades of Vogt. *Medicine (Baltimore)*. 2016;95:e4234.
8. Yang Y, Hong J, Deng SX, Xu J. Age-related changes in human corneal epithelial thickness measured with anterior segment optical coherence tomography. *Invest Ophthalmol Vis Sci*. 2014;55:5032–5038.

9. Le Q, Yang Y, Deng SX, Xu J. Correlation between the existence of the palisades of Vogt and limbal epithelial thickness in limbal stem cell deficiency. *Clin Exp Ophthalmol*. 2017;45:224–231.
10. Liang Q, Liang H, Liu H, Pan Z, Baudouin C, Labbé A. Ocular surface epithelial thickness evaluation in dry eye patients: clinical correlations. *J Ophthalmol*. 2016;2016:1628469.
11. Alonso-Caneiro D, Shaw AJ, Collins MJ. Using optical coherence tomography to assess corneal morphology after soft contact lens wear. *Optom Vis Sci*. 2012;89:1619–1626.
12. Hogan MJ, Alvarado JA, Weddell JE. The cornea. In: MJ, Hogan Alvarado JA, Weddell JE, ed. *Histology of the Human Eye*. Philadelphia: WB Saunders, 1971:112–182.
13. Remington LA. Cornea and sclera. In: Remington LA, ed. *Clinical Anatomy and Physiology of the Visual System*. St. Louis, MO: Elsevier Butterworth-Heinemann; 1998:9–29.
14. Hickson-Curran S, Brennan NA, Igarashi Y, Young G. Comparative evaluation of Asian and white ocular topography. *Optom Vis Sci*. 2014;91:1396–1405.
15. Gao R, Chen H, Savini G, et al. Comparison of ocular biometric measurements between a new swept-source optical coherence tomography and a common optical low coherence reflectometry. *Sci Rep*. 2017;7:2484.
16. Pinero DP, Plaza Puche AB, Alio JL. Corneal diameter measurements by corneal topography and angle-to-angle measurements by optical coherence tomography: evaluation of equivalence. *J Cataract Refract Surg*. 2008;34:126–131.
17. Le Q, Chen Y, Yang Y, Xu J. Measurement of corneal and limbal epithelial thickness by anterior segment optical coherence tomography and in vivo confocal microscopy. *BMC Ophthalmol*. 2016;16:163.
18. Grieve K, Ghoubay D, Georgeon C, et al. Three-dimensional structure of the mammalian limbal stem cell niche. *Exp Eye Res*. 2015;140:75–84.
19. Wiley L, SundarRaj N, Sun TT, Thoft RA. Regional heterogeneity in human corneal and limbal epithelia: an immunohistochemical evaluation. *Invest Ophthalmol Vis Sci*. 1991;32:594–602.