

# UCLA

## UCLA Previously Published Works

### Title

Novel pathogenic COX20 variants causing dysarthria, ataxia, and sensory neuropathy

### Permalink

<https://escholarship.org/uc/item/3s51m3n7>

### Journal

Annals of Clinical and Translational Neurology, 6(1)

### ISSN

2328-9503

### Authors

Otero, Maria G  
Tiongson, Emmanuelle  
Diaz, Frank  
et al.

### Publication Date

2019

### DOI

10.1002/acn3.661

Peer reviewed

## BRIEF COMMUNICATION

**Novel pathogenic *COX20* variants causing dysarthria, ataxia, and sensory neuropathy**

Maria G. Otero<sup>1,a</sup>, Emmanuelle Tiongson<sup>2,a</sup>, Frank Diaz<sup>3</sup>, Katrina Haude<sup>4</sup>, Karin Panzer<sup>5</sup>, Ashley Collier<sup>6</sup>, Jaemin Kim<sup>1</sup>, David Adams<sup>7,8</sup>, Cynthia J. Tiffet<sup>7,8</sup>, Hong Cui<sup>4</sup>, Francisca Millian Zamora<sup>4</sup>, Margaret G. Au<sup>9</sup>, John M. Graham Jr<sup>9</sup>, David J. Buckley<sup>10</sup>, Richard Lewis<sup>3</sup>, Camilo Toro<sup>7,8</sup>, Renkui Bai<sup>4</sup>, Lesley Turner<sup>11</sup>, Katherine D. Mathews<sup>6,12</sup>, William Gahl<sup>7,8</sup> & Tyler Mark Pierson<sup>1,3,9</sup>

<sup>1</sup>Board of Governors Regenerative Medicine Institute, Cedars-Sinai Medical Center, Los Angeles, California

<sup>2</sup>Division of Neurology, Children's Hospital of Los Angeles, Los Angeles, California

<sup>3</sup>Department of Neurology, Cedars-Sinai Medical Center, Los Angeles, California

<sup>4</sup>GeneDx, Gaithersburg, Maryland

<sup>5</sup>Department of Pediatrics, University of Iowa Stead Family Children's Hospital, Iowa City, Iowa

<sup>6</sup>Provincial Medical Genetics Program, Eastern Health, St. John's, Newfoundland and Labrador, Canada

<sup>7</sup>NIH Undiagnosed Diseases Program, NIH Office of Rare Diseases Research and NHGRI, Bethesda, Maryland

<sup>8</sup>Office of the Clinical Director, NHGRI, NIH, Bethesda, Maryland

<sup>9</sup>Department of Pediatrics, Cedars-Sinai Medical Center, Los Angeles, California

<sup>10</sup>Department of Pediatrics, Janeway Health Centre, St. John's, Newfoundland and Labrador, Canada

<sup>11</sup>Faculty of Medicine, Memorial University of Newfoundland, St. John's, Newfoundland, Canada

<sup>12</sup>Department of Neurology, University of Iowa Stead Family Children's Hospital, Iowa City, Iowa

**Correspondence**

Tyler M. Pierson, Cedars-Sinai Medical Center, 8700 Beverly Blvd. AHSP 8401, Los Angeles, CA 90048. Tel: 310-423-4441; Fax: 310-423-1244; E-mail: tyler.pierson@cshs.org

**Funding Information**

During this study D.A., C.J.T. & C.T. were supported by the National Institutes of Health Undiagnosed Diseases Network; W.A.G. was supported by the Intramural Research Program of the National Human Genome Research Institute of the National Institutes of Health. TMP was funded by Cedars-Sinai Institutional funding program and the Cedars-Sinai Diana and Steve Marienhoff Fashion Industries Guild Endowed Fellowship in Pediatric Neuromuscular Diseases.

Received: 26 May 2018; Revised: 4 September 2018; Accepted: 10 September 2018

*Annals of Clinical and Translational Neurology* 2019; 6(1): 154–160

doi: 10.1002/acn3.661

<sup>a</sup>Contributed equally to this work.

**Abstract**

*COX20/FAM36A* encodes a mitochondrial complex IV assembly factor important for COX2 activation. Only one homozygous *COX20* missense mutation has been previously described in two separate consanguineous families. We report four subjects with features that include childhood hypotonia, areflexia, ataxia, dysarthria, dystonia, and sensory neuropathy. Exome sequencing in all four subjects identified the same novel *COX20* variants. One variant affected the splice donor site of intron-one (c.41A>G), while the other variant (c.157+3G>C) affected the splice donor site of intron-two. cDNA and protein analysis indicated that no full-length cDNA or protein was generated. These subjects expand the phenotype associated with *COX20* deficiency.

## Introduction

COX20 (also known as *FAM36A*; MIM#614698) encodes a protein with a role in the assembly and stability of mitochondrial complex IV (CIV).<sup>1,2</sup> Complex IV is the final component of the respiratory chain and is responsible for the reduction of molecular oxygen and oxidation of cytochrome C. Several disorders have been associated with mutations of both nuclear- and mitochondrial-encoded proteins that cause CIV deficiency, and have presented with encephalopathies, myopathies, and metabolic acidoses.<sup>3–7</sup> Previous work indicated that COX20 is important for CIV function since COX20-deficient mitochondria accumulated respiratory chain assembly intermediates and showed reduced respiratory capacity.<sup>2,8</sup> This dysfunction was linked to COX20's role in the maturation of the COX2 protein and COX2's integration into the CIV holocomplex.<sup>8</sup>

Two previous reports identified a rare neurological disorder associated with COX20 deficiency.<sup>2,9</sup> Three subjects from two separate consanguineous Turkish families were found to possess the same homozygous *COX20* mutation (c.154A>C; p.T52P) and presented with hypotonia, dystonia, dysarthria, ataxia, and sensory neuropathy.<sup>1,9</sup> One family had a child with additional findings of microcephaly, mildly elevated serum and CSF lactate, and a normal brain MRI.<sup>1</sup> The other family had two siblings, a 32-year-old sister and 25-year-old brother, with childhood-onset of symptoms along with cerebellar atrophy and sensory neuropathy.<sup>9</sup> Analysis of muscle biopsies from all subjects showed decreased CIV activity. Protein analysis of fibroblasts revealed an absence of COX20 protein.<sup>1,9</sup> Analysis of fibroblast mRNA indicated the shared missense variant was also associated with decreased expression of the full-length mRNA and increased expression of a splice variant that excluded exon 2 ( $\Delta$ EXON2).<sup>9</sup>

We describe four additional subjects with a COX20-related neurological disorder with features that included childhood hypotonia, areflexia, ataxia, dysarthria, dystonia, and sensory neuropathy. Exome sequencing identified the same novel *COX20* variants in all four subjects, which included a splice site variant (c.157+3G>C) on one allele, while the other allele possessed two separate variants (c.41A>G; p.K14R and c.340G>A; p.G114S). mRNA and protein analysis in fibroblasts showed an absence of full-length mRNA and COX20 protein. Further analysis revealed this was the result of the c.157+3G>C splice donor site variant affecting the splicing of exon two and the c.41A>G variant affecting the splicing of exon one.

## Materials and Methods

### Protocol, patients, and consents

Protocols were approved through the National Human Genome Research Institute and Cedars-Sinai Medical Center (CSMC) institutional review boards (Protocols 76-HG-0238 and Pro00037131, respectively) and the families gave informed consent. The patients were evaluated at the University of Iowa Stead Family Children's Hospital, Eastern Health in Newfoundland, Canada, CSMC and at the NIH Clinical Center through the NIH Undiagnosed Diseases Program.<sup>10,11</sup>

### Exome sequencing

Exome sequencing was performed on family trios as per previous protocols and the identified genetic variants were evaluated and classified according to published guidelines (GeneDx, Gaithersburg, MD).<sup>12,13</sup>

### Cell culture and expression analysis

More detailed information can be found in Appendix S1. Subject-1's fibroblasts were grown at 37°C under 5% CO<sub>2</sub> in Dulbecco's Modified Eagles Medium (Thermo Fisher Scientific, Waltham, MA) supplemented with 10% bovine serum and 1% of penicillin/streptomycin (Thermo Fischer Scientific). RNA was extracted from cells and reverse transcribed into cDNA. Transcripts were amplified with primers localizing to exons 1 or 4, separated on an agarose-gel, and quantified with ImageJ (NIH, Bethesda, MD). Western blots of protein extracts were transferred to a membrane and incubated with primary and secondary antibodies and quantified with ImageJ.

## Results

### Subject-1

Thirteen-year-old female with infantile hypotonia who walked at 14 months and developed progressive ataxia associated with areflexia and dysmetria at 23 months. At 5 years, she developed a stuttering dysarthria and episodic dystonia. Her gait progressively worsened and she became nonambulatory at 7 years. She has continued with age-appropriate schoolwork.

Nerve conduction studies at 13 years demonstrated a marked sensory neuropathy. The right median sensory nerve action potentials (SNAPs) had severely decreased

amplitude of 3  $\mu V$  (normal >20  $\mu V$ ). The right ulnar, sural, and radial SNAPs could not be elicited; in contrast, her motor studies were normal. MRI of the brain at 23 months, 6 years, and 12 years were normal. Spinal MRI at 12 years reported that the spinal cord that was “thinner than normal, particularly in the thoracic region” (Fig. S1). At 5 years, cerebrospinal fluid analysis showed a normal basic profile and neurotransmitter metabolites. Serum evaluation for neuropathy was normal. At 7 years, mitochondrial respiratory chain enzyme analysis of her fibroblasts was normal (this is not uncommon with mitochondrial fibroblast studies)<sup>14,15</sup> (Baylor Genetics, Houston, TX).

On examination at 12 years, she was awake, alert, and followed commands. Cognition was normal. She was dysarthric with a staccato whispering quality and a pronounced stammer. Her receptive language was unimpaired. Naming and repetition were normal. She had oculomotor apraxia and disruption of her smooth pursuits, otherwise her cranial nerves were normal. She had increased tone in her lower extremities and contractures at the knees. She had truncal weakness and was unable to sit unsupported. She had decreased strength at the hips and knees and ankles. Her left foot had a pes cavus deformity. She was areflexic and had extensor plantar responses bilaterally. Significant dysmetria and dysdiadochokinesia were present. She had dystonic posturing of both hands during her attempts to walk. These movements involved the twisting and clenching of her hands. She also had dystonic posturing of both feet with inversion and in toeing. Her right side was more affected by these movements than the left. Her gait was significant for some toe walking associated with spasticity.

### Subject-2

Thirty-two-year-old female is the sister of Subject-3. She was without developmental concerns until age 2 years when she was felt to become “clumsy”. Strabismus was present at 3 years. She then developed progressive ataxia (truncal, then appendicular) and dysarthria. By age 7, she was areflexic and unable to climb stairs safely due to unsteadiness. At 10 years, she started using a walker. She was also treated for attention-deficit hyperactivity syndrome (ADHD), but did well in regular classes. She developed bilateral foot drop at age 11 years. She required increasing assistance at school. At age 16, she had increasing frequency of falls and exam started to show mildly increased tone in the legs with upgoing toes. She reported normal sensation to all modalities on exam. At 17 years, she started having episodic dystonic posturing of her feet, which did not respond to carbidopa/levodopa treatment.

During this period, she developed depression, which responded to Selective Serotonin Reuptake Inhibitor treatment; however, she developed more significant psychiatric issues that required antipsychotic medication. Formal neuropsychological testing at 18 yo showed low-average overall cognitive functioning. She became nonambulatory and developed incontinence at 19 years. Cognitive and social skills continued to decline. In her 20s, she developed painful muscle spasms that were treated with baclofen. Through her 20s, her condition stabilized with significant disability.

Normal diagnostic testing included several MRIs of brain and an MRI of the spine at 19 years. Nerve conduction studies at 6 years had absent sensory action potentials in the left median and ulnar nerves and very low amplitude in the left sural nerve consistent with a sensory neuropathy.

At examination at 31 years, she had significant psychomotor retardation, perseverative speech, dysarthria, and was nonambulatory. She had increased tone throughout. Her legs were held in tonic extension with inversion of feet. She had dysmetria with arm movements. She was areflexic. Sensation testing was not reliable.

### Subject-3

Twenty-eight year-old brother of Subject-2 that was always more severely affected than his sister. He had infantile hypotonia, and early milestones were delayed with him starting to walk at 17 months and started speaking around 2 years. He had progressive ataxia (truncal, then appendicular) and dysarthria. He had mild cognitive disability and required special education throughout his schooling. At 10 years, he developed bilateral foot drop and ataxia, but was still ambulating with a walker. Sensation could not be tested accurately. At 13 years, he was using a wheelchair and soon started having inverted dystonic posturing of his feet. His dystonia progressed to involve his upper and lower extremities. He also developed frequent choreiform movements. His tone became progressively increased at this time. Cognitive function remained stable, although in young adulthood he developed some variable symptoms of depression.

At 3 years, he had a very limited electromyography and nerve conduction study that was read as normal. He has never had an MRI of the brain or spine.

Examination at 28 years showed limited voluntary speech with appropriate content that was accompanied by moderate to severe dysarthria. He was nonambulatory, was hypertonic throughout with frequent dystonic posturing of his hands. Deep tendon reflexes were absent.

**Subject-4**

Seven-year-old male with childhood hypotonia who met normal language and motor milestones until 18 months when he developed a progressive wide-based gait associated with bilateral ankle pronation and frequent falls. At 5 years, he started having slurred dysarthric speech and longer walks became more difficult. His gait progressively worsened and he became nonambulatory at 7 years. He recently developed issues with bowel and bladder control. His speech has also continued to worsen. He is noted to have some mild cognitive disability and attention-deficit hyperactivity disorder, although he has continued with age-appropriate schoolwork. Family notes he has a “high pain threshold” and will have blisters on his feet that do not concern him. He currently has not developed any dystonic movements.

Nerve conduction studies at 5 years demonstrated a sensory neuropathy with absent left ulnar, median, and sural SNAPs; motor studies were normal. MRI of the brain (5 and 6 years) and spine (6 years) and EEG were also normal. Other genetic testing was unrevealing (see Appendix S1).

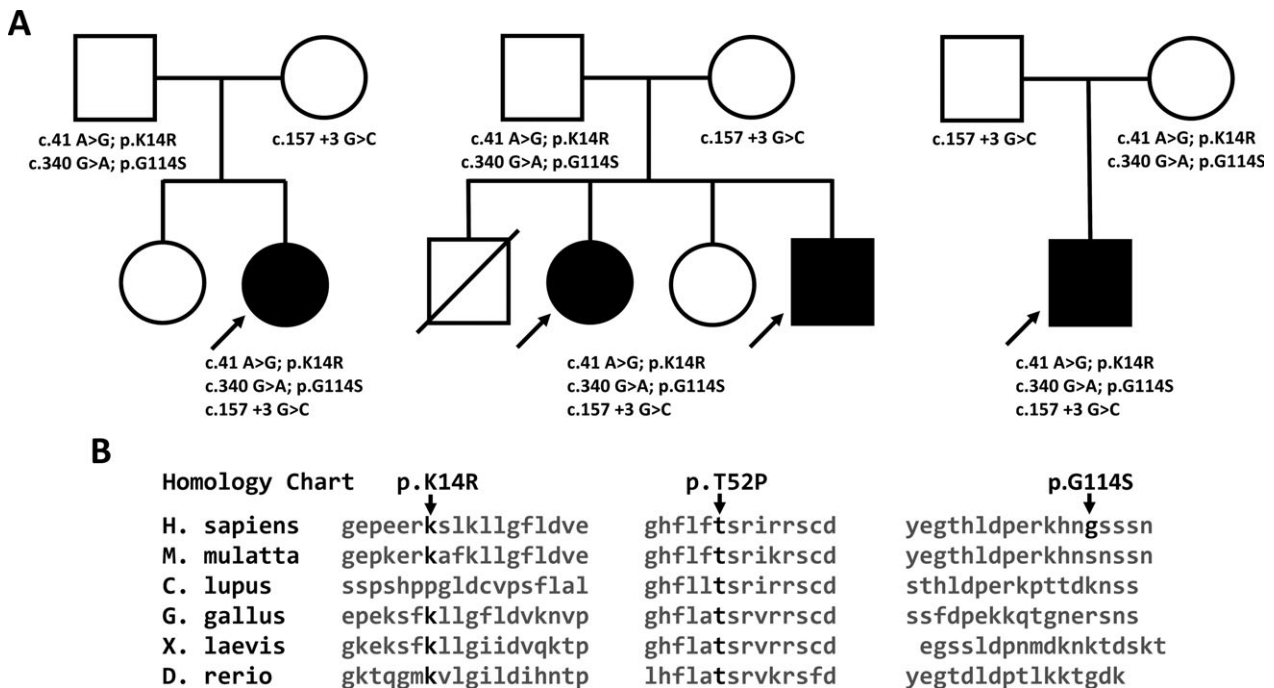
On examination at 7 years, he had mild hypotonia, ligamentous laxity, hyperextension of knees, and calcaneal valgus deformities of feet. He has numerous dental caries and

hypomineralized teeth. Ophthalmological exam showed some limitation of his smooth pursuits. He was alert and interactive. His speech was slow without a scanning quality. He had appendicular hypotonia, but good strength. He had significant dysmetria and ataxia. He had a wide-based gait with bilateral ankle pronation. He was areflexic. He had a normal temperature and vibration testing.

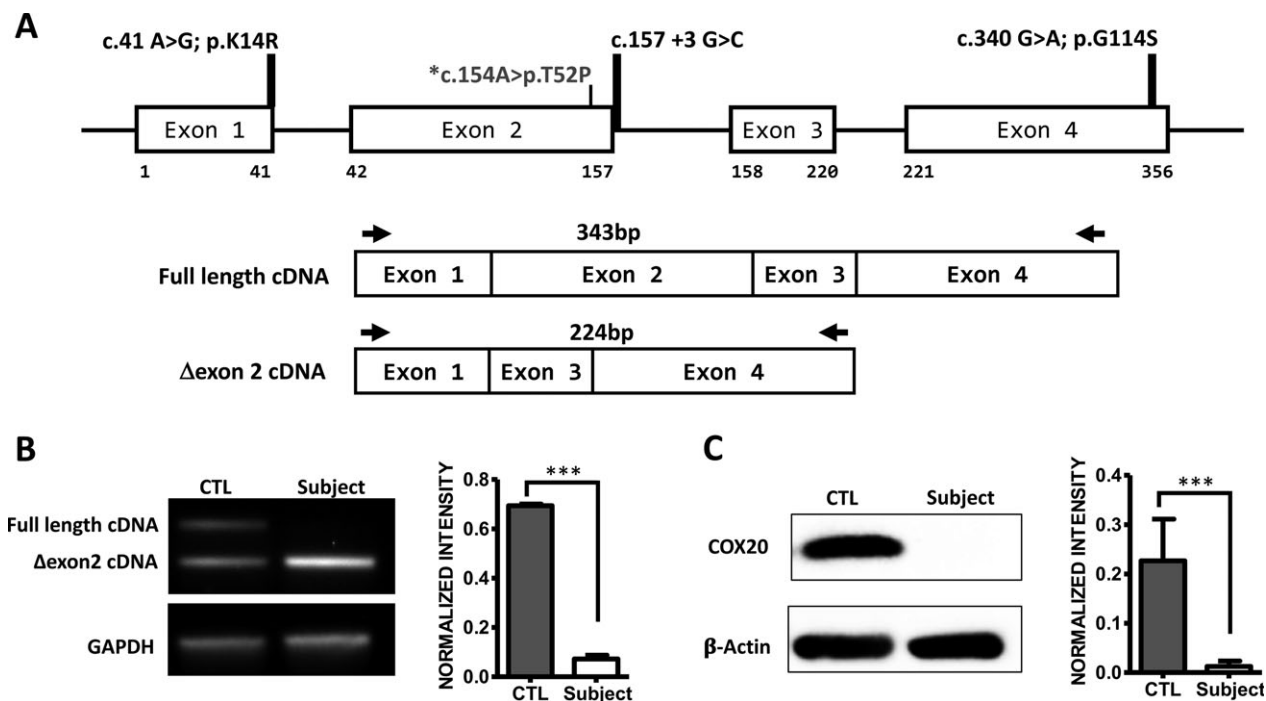
None of the subjects have had any history of seizures, migraines, head trauma, or meningitis. None of them have any family history of similar presentations, ataxia, dystonia, or sensory neuropathy.

**Exome sequencing**

Exome sequencing revealed three novel compound heterozygous variants in the *COX20* gene in all four subjects. One allele possessed a variant (c.157+3G>C) involving the splice donor site of intron 2 (IVS2; Fig. 1). The other allele possessed two missense variants. One variant (c.340G>A, p.G114S) involved an amino acid substitution near the C-terminus that has not been conserved across species and so was believed to be benign. The other variant consisted of a conservative amino acid substitution (c.41A>G, p.K14R), but its proximity to the splice donor site of intron-1 (IVS1) indicated a splicing defect could also be playing a role (Fig. 1).



**Figure 1.** Pedigrees and *COX20* mutations. (A) Family pedigrees. Affected individuals are indicated in black. From left to right: Subject-1 family pedigree, Subject-2 and Subject-3 family pedigree, and Subject-4 family pedigree (B) Protein homology across species. The p.K14 and p.T52 residues are conserved across species; however, the C-terminal p.G114 residue is not.



**Figure 2.** Gene, mRNA, and protein analysis (A) *COX20* gene and mRNA schematic. The gene schematic indicates the location of *COX20* mutations. The previously reported c.154A>C; p.T52P is shown, along with c.157+3G>C intron 2 splice site mutation and missense mutations c.41A>G; p.K14R and c.340G>A; p.G114S. Schematic of alternative splice products of *COX20* mRNA with primers and the 343 bp full-length and 224 bp ΔEXON2 mRNA products (B) cDNA products of RT-PCR of cellular mRNA with control cells expressing both the full-length and ΔEXON2. Only the ΔEXON2 cDNA is expressed, there is no full-length cDNA. GAPDH cDNA expression is shown as the loading control. Bar graph shows the normalized intensity of COX20/GAPDH signal in controls and subject. (C) Western blot indicates that subject cells had no identifiable COX20 expression in comparison to control cells. β-actin expression is shown as the loading control. Bar graph shows the normalized intensity of COX20/β-actin signal in controls and subject. Statistical analysis used two-tailed Student's *t*-test. Values are expressed as means ± standard deviation (SD) for two independent experiments. \*\*\**P* > 0.002.

## Expression analysis

Similar to a previous report,<sup>9</sup> control fibroblasts possessed two distinct transcripts, a full-length transcript and another consistent with a ΔEXON2 transcript. In Subject-1's fibroblasts, only the noncoding transcript was detected, with no full-length transcript being expressed. Consistent with this finding, protein analysis revealed no detectable COX20 protein present (Fig. 2).

## Discussion

COX20 is a nuclear-encoded assembly factor that is important for mitochondrial complex IV function.<sup>1</sup> COX20 deficiency is a rare recessive mitochondrial disorder associated with a unique phenotype that includes early-onset hypotonia, ataxia, areflexia, dystonia, dysarthria, and sensory neuropathy. Three affected children were previously reported from two separate consanguineous Turkish families, all with the same homozygous pathogenic mutation (c.154A>C; p.T52P).<sup>1,9</sup> This

substitution was initially reported to decrease expression of COX20 and reduce the levels of associated CIV proteins and activity.<sup>1</sup> Further analysis indicated that altered splicing of intron 2 due to the variant's proximity to the splice donor site also played a role. This alteration caused a reduction in full-length mRNA and an increase in the amount of an alternatively spliced ΔEXON2 mRNA, which when combined with any altered protein function of the T52P substitution led to the decrease in COX20 activity.<sup>9</sup>

All four of our subjects presented with the same novel compound heterozygous *COX20* mutations that also altered mRNA splicing and protein expression. One variant (IVS2+3G>C), located near intron-2's splice donor site, resulted in increased expression of the ΔEXON2 mRNA. Two linked missense variants were also identified. The G114S substitution was near the C-terminal end of the protein and was at a residue that is not conserved among mammals. This likely had little or no effect on any expressed protein. Alternatively, the K14R substitution occurred at a residue that is conserved in mammals;



more importantly, the associated c.41A>G variant is located at the -1 site of the intron 1 splice donor site altering splicing of intron 1 in this allele. This alteration explains why mRNA analysis revealed that little or no full-length mRNA was produced, resulting in absent COX20 expression. All four subjects had very similar presentations that included childhood hypotonia that progressed to hypertonia as they grew older. Other prominent features included dysarthria, ataxia, areflexia, and sensory neuropathy without motor neuropathy. The three older subjects had developed dystonia in late childhood/early adolescence, while the youngest subject has not developed this feature. Whether dystonia will be a consistent feature of the disorder will require identification of more affected subjects.

Sensory neuropathy is a prominent feature of COX20 deficiency, but is not a very common feature in many neurogenetic disorders. When present, the use of this symptom as a defining diagnostic feature can provide a more limited differential diagnosis for a patient's evaluation. Friedreich ataxia is a more common disorder with sensory neuropathy, while other less common disorders include the later-onset disorder cerebellar ataxia with neuropathy and bilateral vestibular areflexia syndrome (CANVAS) that consists of vestibulopathy, ataxia, areflexia, and sensory neuropathy.<sup>16</sup> In addition, several of the spinocerebellar ataxias (SCAs) also have ataxia associated with sensory neuropathy, including SCA4 and SCA25 (and occasionally SCA1, SCA8, and SCA27).<sup>17,18</sup> Furthermore, sensory neuropathy has been associated with other mitochondrial disorders, including CPEO, MERRF, and MNGIE.<sup>19–21</sup> POLG mutations have also caused a mitochondrial disorders with sensory neuropathy.<sup>19–21</sup> In contrast to these disorders, COX20 deficiency has a unique phenotype that can include ataxia, areflexia, dysarthria, and dystonia. Previous to this report, there have only been three reported COX20 deficiency cases, all of them associated with consanguinity and homozygosity of the same variant. These nonconsanguineous subjects and their compound heterozygous COX20 variants further confirm this unique phenotype's association with COX20 deficiency.

## Acknowledgments

We are grateful to Kelli DeJohn, Carmela Brito, Joanne Baez, and Barrington Burnett for clinical and technical assistance, and critical analysis. We especially thank the families of our patients for the loving care for their children and cooperation with our work. T.M.P. was funded by the Cedars-Sinai institutional funding program and the Cedars-Sinai Diana and Steve Marienhoff Fashion Industries Guild Endowed Fellowship in Pediatric Neuromuscular Diseases.

## Author Contributions

M.G.O., E.T., F.D., K.H., A.C., K.M., and T.M.P. designed the experiments and wrote the manuscript. M.T.O., H.H., J.K., F.D., C.T., C.T., and H.Y. performed the biological experiments and analyzed biological data. E.T., K.H., A.C., K.P., R. B., D.A., C.T., H.C., F.M.Z., M.A., J.M.J., R.L., C.T., R.B., L.T., K.M., W.G. and T.M.P. collected clinical information and evaluated the patients, provided clinical assessments and whole-exome sequencing data. All authors discussed the results and implications and commented on the manuscript.

## Conflict of Interest

None declared.

## References

1. Szklarczyk R, Wanschers BF, Cuypers TD, et al. Iterative orthology prediction uncovers new mitochondrial proteins and identifies C12orf62 as the human ortholog of COX14, a protein involved in the assembly of cytochrome c oxidase. *Genome Biol* 2012;13:R12.
2. Szklarczyk R, Wanschers BFJ, Nijtmans LG, et al. A mutation in the FAM36A gene, the human ortholog of COX20, impairs cytochrome c oxidase assembly and is associated with ataxia and muscle hypotonia. *Hum Mol Genet* 2013;22:656–667.
3. Keightley JA, Hoffbuhr KC, Burton MD, et al. A microdeletion in cytochrome c oxidase (COX) subunit III associated with COX deficiency and recurrent myoglobinuria. *Nat Genet* 1996;12:410–416.
4. Massa V, Fernandez-Vizarrá E, Alshahwan S, et al. Severe infantile encephalomyopathy caused by a mutation in COX6B1, a nucleus-encoded subunit of cytochrome c oxidase. *Am J Hum Genet* 2008;82:1281–1289.
5. Melchionda L, Haack TB, Hardy S, et al. Mutations in APOPT1, encoding a mitochondrial protein, cause cavitating leukoencephalopathy with cytochrome c oxidase deficiency. *Am J Hum Genet* 2014;95:315–325.
6. Watanabe S, Shimazu K, Hosokawa T, et al. [A case of paraneoplastic autonomic and sensorimotor neuropathy with dysfunction in the afferent limb of baroreflex arc]. *Rinsho Shinkeigaku* 1993;33:646–651.
7. Hallmann K, Kudin AP, Zsurka G, et al. Loss of the smallest subunit of cytochrome c oxidase, COX8A, causes Leigh-like syndrome and epilepsy. *Brain* 2016;139:338–345.
8. Bourens M, Boulet A, Leary SC, Barrientos A. Human COX20 cooperates with SCO1 and SCO2 to mature COX2 and promote the assembly of cytochrome c oxidase. *Hum Mol Genet* 2014;23:2901–2913.

9. Doss S, Lohmann K, Seibler P, et al. Recessive dystonia-ataxia syndrome in a Turkish family caused by a COX20 (FAM36A) mutation. *J Neurol* 2014;261:207–212.
10. Gahl WA, Boerkoel CF, Boehm M. The NIH Undiagnosed Diseases Program: bonding scientists and clinicians. *Dis Model Mech* 2012;5:3–5.
11. Gahl WA, Mulvihill JJ, Toro C, et al. The NIH Undiagnosed Diseases Program and Network: applications to modern medicine. *Mol Genet Metab* 2016;117:393–400.
12. Tanaka AJ, Cho MT, Millan F, et al. Mutations in SPATA5 are associated with microcephaly, intellectual disability, seizures, and hearing loss. *Am J Hum Genet* 2015;97:457–464.
13. Richards S, Aziz N, Bale S, et al. Standards and guidelines for the interpretation of sequence variants: a joint consensus recommendation of the American College of Medical Genetics and Genomics and the Association for Molecular Pathology. *Genet Med* 2015;17:405–424.
14. Thorburn DR, Chow CW, Kirby DM. Respiratory chain enzyme analysis in muscle and liver. *Mitochondrion* 2004;4:363–375.
15. Koenig MK. Presentation and diagnosis of mitochondrial disorders in children. *Pediatr Neurol* 2008;38:305–313.
16. Szmulewicz DJ, Waterston JA, Halmagyi GM, et al. Sensory neuropathy as part of the cerebellar ataxia neuropathy vestibular areflexia syndrome. *Neurology* 2011;76:1903–1910.
17. Flanigan K, Gardner K, Alderson K, et al. Autosomal dominant spinocerebellar ataxia with sensory axonal neuropathy (SCA4): clinical description and genetic localization to chromosome 16q22.1. *Am J Hum Genet* 1996;59:392–399.
18. Stevanin G, Bouslam N, Thobois S, et al. Spinocerebellar ataxia with sensory neuropathy (SCA25) maps to chromosome 2p. *Ann Neurol* 2004;55:97–104.
19. Luigetti M, Sauchelli D, Primiano G, et al. Peripheral neuropathy is a common manifestation of mitochondrial diseases: a single-centre experience. *Eur J Neurol* 2016;23:1020–1027.
20. Mancuso M, Orsucci D, Angelini C, et al. “Mitochondrial neuropathies”: a survey from the large cohort of the Italian Network. *Neuromuscul Disord* 2016;26:272–276.
21. Menezes MP, Rahman S, Bhattacharya K, et al. Neurophysiological profile of peripheral neuropathy associated with childhood mitochondrial disease. *Mitochondrion* 2016;30:162–167.

## Supporting Information

Additional supporting information may be found online in the Supporting Information section at the end of the article.

**Appendix S1.** Additional methods and clinical information.  
**Figure S1.** Neuroimaging. MRI of the brain and spinal cord at 12 years. (A) MRI brain was within normal limits (B) MRI of the spine was reported as her spinal cord “thinner than normal, particularly in the thoracic region”.