

# UC Riverside

## UC Riverside Previously Published Works

### Title

From Gut to Heart: A rare case of Salmonella Typhimurium Bacteremia and native valve endocarditis.

### Permalink

<https://escholarship.org/uc/item/3r98382v>

### Authors

Winicki, Nolan

Desai, Darshi

Desai, Aditya

et al.


### Publication Date

2023

### DOI

10.1016/j.idcr.2023.e01787

Peer reviewed



## Case report

# ‘From Gut to Heart’: A rare case of *Salmonella Typhimurium* Bacteremia and native valve endocarditis

Nolan M. Winicki<sup>a,\*</sup>, Darshi Desai<sup>b</sup>, Aditya Desai<sup>b</sup>, Prinka Perswani<sup>b</sup>, Khaled Al Smadi<sup>b</sup>, Kieran Doyle<sup>b</sup>, Hareesh Gandhi<sup>b</sup>, Prabhdeep S. Sethi<sup>b</sup>, Ashis Mukherjee<sup>b</sup>

<sup>a</sup> University of California Riverside, School of Medicine, Riverside, CA, USA

<sup>b</sup> Department of Internal Medicine, University of California Riverside, School of Medicine, Riverside, CA, USA



## ARTICLE INFO

## Keywords:

Endocarditis  
Salmonella  
Typhimurium  
Native aortic valve  
Gastroenteritis

## ABSTRACT

**Background:** *Salmonella* species are very rarely associated with infective endocarditis, accounting for less than 0.01–2.9 % of total bacterial endocarditis cases. Since 1976, there have been less than 90 reported cases of non-Typhoidal *Salmonella* bacteremia and endocarditis.

**Case presentation:** We present the case of a 57-year-old homeless man with a past medical history significant only for polysubstance abuse. He presented to the emergency department with a 3-day history of severe, non-bloody diarrhea, nausea, chills, and oliguria. Due to the patient's history of substance use, screening laboratory tests were conducted and were positive for rapid plasma reagin, treponemal antibodies, and hepatitis C. For the profuse diarrhea and severe volume loss, *C. difficile*, stool white blood cells and stool ova and parasites were ordered but were ultimately negative. Both sets of blood cultures were found to be positive for *Salmonella Typhimurium* bacteremia. Further workup with transthoracic and transesophageal echocardiogram displayed small mobile masses attached to the aortic surface of the right and non-coronary cusps, confirming endocarditis on the aortic valve. Treatment included penicillin-G once a week for 3 weeks for latent syphilis and ceftriaxone and levofloxacin for bacteremia and endocarditis.

**Conclusions:** Patients with *Salmonella* typically present early with gastrointestinal symptoms, but clinicians should consider cardiovascular imaging if blood cultures are found to be positive in order to potentially identify and promptly treat highly fatal *Salmonella* endocarditis.

## Introduction

*Salmonella* species are estimated to cause more than 1.2 million illnesses each year in the United States with more than 23,000 hospitalizations and 450 deaths [1]. Infections with *Salmonella* typically present with mild gastroenteritis but can become severe invasive infections especially in infants, the elderly, and immunocompromised hosts [2]. Cardiac involvement with *Salmonella* is rare and previous reports have focused on non-Typhoidal infections due to their increased relative prevalence [3]. For patients with *Salmonella* myocarditis or endocarditis, the mortality rates are high, up to 42 %, but have improved over recent years [3–5]. The majority of reported *Salmonella* cases with cardiac involvement have included patients with an underlying cardiac pathology, most notably, rheumatic heart disease or prosthetic valve replacement [5,6]. Additionally, the mitral valve has shown to be the most likely valve to be affected [3]. Here, we report the case of a

57-year-old man who developed bacteremia and infective endocarditis on his native aortic valve as a result of *Salmonella Typhimurium*.

## Case presentation

We present the case of a 57-year-old homeless man with a past medical history significant for polysubstance abuse (alcohol, tobacco, methamphetamines, cocaine, and marijuana), with most recent use 4 months ago. He otherwise denies any other known significant past medical history. He presented to the emergency department with a 3-day history of severe, non-bloody diarrhea, nausea, chills, and oliguria. Laboratory data was significant for elevated creatinine, hyperkalemia, metabolic acidosis and lactic acidosis therefore hemodialysis was initiated. Physical exam was unremarkable upon admission. Due to the patient's history of substance use, screening laboratory tests were conducted and were positive for rapid plasma reagin, treponemal

\* Correspondence to: University of California Riverside, School of Medicine, 900 University Ave, Riverside, CA 92521, USA.

E-mail address: [Nwini001@ucr.edu](mailto:Nwini001@ucr.edu) (N.M. Winicki).

<https://doi.org/10.1016/j.idcr.2023.e01787>

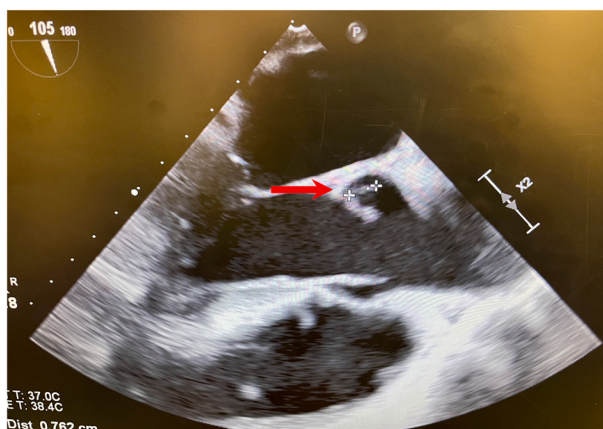Received 10 April 2023; Received in revised form 27 April 2023; Accepted 2 May 2023

Available online 4 May 2023

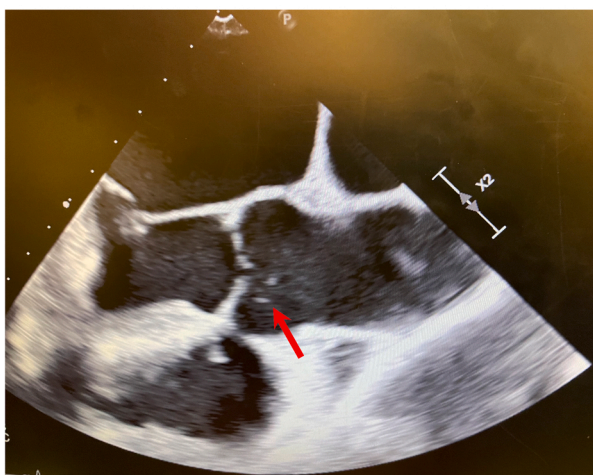
2214-2509/© 2023 The Authors. Published by Elsevier Ltd. This is an open access article under the CC BY-NC-ND license (<http://creativecommons.org/licenses/by-nc-nd/4.0/>).

antibodies, and hepatitis C. Serum antibody against human immunodeficiency virus-1 was not present. Urine drug screen was negative for all substances. Computed tomography of the chest, abdomen, and pelvis was grossly normal with no bowel wall thickening and normal abdominal solid organ appearance. For the profuse diarrhea and severe volume loss, *C. difficile*, stool white blood cells and stool ova and parasites were ordered but were ultimately negative. Interestingly, both sets of blood cultures were found to be positive for *Salmonella Typhimurium*. The patient recalled a potential ingestion of undercooked chicken several weeks prior but was unable to specify any exact ingestion of raw chicken or eggs. Follow up physical exams found a 2/6 systolic murmur that was loudest at the left sternal border. Further workup with transthoracic and transesophageal echocardiogram displayed an ejection fraction of 65–70 % and small mobile masses attached to the aortic surface of the right and non-coronary cusps of the aortic valve consistent with vegetations (Fig. 1). Treatment included penicillin-G once a week for 3 weeks for latent syphilis and ceftriaxone and levofloxacin for bacteremia and endocarditis, based on culture sensitivities. The patient recovered well after a week-long hospital stay and was discharged to a skilled nursing facility with a peripherally inserted central catheter to continue ceftriaxone and levofloxacin for a total course of 6 weeks. On follow up, two sets of repeat blood cultures were negative at the end of the antibiotics course and there were no reported readmissions or complications.

A.



B.



**Fig. 1.** Echocardiography displays small mobile masses attached to the aortic surface of the right and non-coronary cusps of the aortic valve consistent with vegetations.

## Discussion

*Salmonella* species are estimated to cause more than 1.2 million illnesses each year in the United States with more than 23,000 hospitalizations and 450 deaths [1]. Infections with *Salmonella* typically present with mild gastroenteritis but can become severe invasive infections especially in infants, the elderly, and immunocompromised hosts [2]. *Salmonella Typhimurium* infection can be caused by various food sources, including street food, contaminated chocolate, and poultry products [7–9]. Cardiac involvement with *Salmonella* is rare and previous reports have focused on non-Typhoidal infections due to increased relative prevalence [3]. As such, the typical presentation has not been clearly defined. Our case presents a patient with numerous undiagnosed infections, Syphilis and Hepatitis C, but with the most urgent condition of *Salmonella Typhimurium* gastroenteritis, bacteremia, and endocarditis.

Since 1976, there have been less than 100 reported cases of Typhoidal and non-Typhoidal *Salmonella* bacteremia and endocarditis [3]. Non-Typhoidal *Salmonella* endocarditis constitutes the majority of recent reports; however, our patient was infected with *Salmonella Typhimurium*, which has been reported less than 10 times over the past 10 years. The most common symptom for patients infected with *Salmonella* species upon presentation is gastrointestinal distress, similarly, seen in our patient. We chose to image our patient based on his clinical deterioration and the initial lack of an infectious source; however, there is currently no specific imaging recommended for *Salmonella* infection. However, imaging may be used as a diagnostic tool to identify potential complications associated with confirmed infection, such as in our case, with the development of endocarditis. Our case was unique in the fact that the native aortic valve was infected, while infection of the mitral valve and of prosthetic valves appears highest in previous literature and is more likely to require cardiac surgery [4]. Mortality for *Salmonella* endocarditis is as high as 69 %, with native valve and mural endocarditis constituting the majority of deaths [3,4]. Clinical management of the cardiovascular complications of *Salmonella* infections requires potent antimicrobial therapy with or without surgical intervention [10]. However, the optimal treatment for *Salmonella* valvular or mural endocarditis is not clearly defined. We suggest our prescribed antimicrobial regimen of ceftriaxone and levofloxacin for 6 weeks, the first- and second-line options for disseminated *Salmonella* bacteremia. Additionally, we propose that patients with severe *Salmonella* gastroenteritis with bacteremia must undergo transthoracic and transesophageal echocardiogram so as to not miss a potential lethal diagnosis of associated endocarditis.

In conclusion, patients with *Salmonella* typically present early with gastrointestinal symptoms but clinicians should consider cardiovascular imaging if blood cultures are found to be positive in order to potentially identify and promptly treat highly fatal *Salmonella* endocarditis.

## Consent for publication

Written informed consent was obtained from the patient for publication of this case report and accompanying images. A copy of the written consent is available for review by the Editor-in-Chief of this journal on request.

## CRedit authorship contribution statement

Nolan M. Winicki – Conceptualization, methodology, formal analysis, investigation, writing – original draft, writing – review & editing. Darshi Desai MD – Conceptualization, methodology, formal analysis, investigation, writing – original draft, writing – review & editing. Aditya Desai MD – Conceptualization, methodology, formal analysis, writing – review & editing. Prinka Perswani MD – Conceptualization, methodology, formal analysis, writing – review & editing. Khaled Al Smadi, MD – Conceptualization, methodology, formal analysis, writing – review & editing. Kieran Doyle MD – Conceptualization, methodology, writing –

review & editing, supervision. Haresh Gandhi MD - Conceptualization, methodology, writing – review & editing, supervision. Prabhdeep S. Sethi MD - Conceptualization, methodology, writing – review & editing, supervision. Ashis Mukherjee MD - Conceptualization, methodology, writing – review & editing, supervision.

### Conflict of Interest

The authors declare that they have no competing interests.

### References

- [1] Scallan E, Hoekstra RM, Angulo FJ, Tauxe RV, Widdowson MA, Roy SL, et al. Foodborne illness acquired in the United States—major pathogens. *Emerg Infect Dis* 2011;17(1):7.
- [2] Galofré J, Moreno A, Mensa J, Miró JM, Gatell JM, Almela M, et al. Analysis of factors influencing the outcome and development of septic metastasis or relapse in *Salmonella* bacteremia. *Clin Infect Dis* 1994;18(6):873–8.
- [3] Cheng WL, Li CW, Li MC, Lee NY, Lee CC, Ko WC, et al. *Salmonella* infective endocarditis. *J Microbiol Immunol Infect* 2016;49(3):313–20.
- [4] Khan GQ, Kadri SM, Hassan G, Shahid IT, Gazanfar A, Kak M, et al. *Salmonella typhi* endocarditis: a case report. *J Clin Pathol* 2003;56(10):801–2.
- [5] Cohen JI, Bartlett JA, Corey GR. Extra-intestinal manifestations of *Salmonella* infections. *Medicine* 1987;66(5):349–88.
- [6] Ghadage DP, Bal AM. Infective endocarditis due to an unusual serotype of *Salmonella*. *Indian Heart J* 2001;53(3):350–1.
- [7] Singh S. Isolation and antibiotic sensitivity of *Salmonella typhimurium* isolates from poultry farms and slaughterhouses of Chitwan, Nepal. *J Agric* 2022.
- [8] Kapperud G, Gustavsen S, Hellesnes I, Hansen AH, Lassen J, Hirn J, et al. Outbreak of *Salmonella typhimurium* infection traced to contaminated chocolate and caused by a strain lacking the 60-megadalton virulence plasmid. *J Clin Microbiol* 1990;28(12):2597–601.
- [9] Prabhu N, Innocent D, Robert A. Prevalence of *Salmonella typhimurium* infection related to street food consumption. *Int J Curr Microbiol Appl Sci* 2013.
- [10] Fernández Guerrero ML, Aguado JM, Arribas A, Lumbreras C, de Gorgolas M. The spectrum of cardiovascular infections due to *Salmonella enterica*: a review of clinical features and factors determining outcome. *Medicine* 2004;83(2):123–38.