

UCSF

UC San Francisco Previously Published Works

Title

Detecting Pulmonary Nodules in Lung Cancer Patients Using Whole Body FDG PET/CT, High-resolution Lung Reformat of FDG PET/CT, or Diagnostic Breath Hold Chest CT

Permalink

<https://escholarship.org/uc/item/3qp4b0ps>

Journal

Academic Radiology, 23(9)

ISSN

1076-6332

Authors

Flavell, Robert R
Behr, Spencer C
Mabray, Marc C
[et al.](#)

Publication Date

2016-09-01

DOI

10.1016/j.acra.2016.04.007

Peer reviewed

Detecting Pulmonary Nodules in Lung Cancer Patients Using Whole Body FDG PET/CT, High-resolution Lung Reformat of FDG PET/CT, or Diagnostic Breath Hold Chest CT

Robert R. Flavell, MD, PhD, Spencer C. Behr, MD, Marc C. Mabray, MD, Miguel Hernandez-Pampaloni, MD, PhD, David M. Naeger, MD

Rationale and Objectives: Pulmonary nodules can be missed on the non-breath hold computed tomography (CT) portion of 18F-fluorodeoxyglucose positron emission tomography/computed tomography (FDG PET/CT), and for this reason prior studies have advocated for routinely performing dedicated breath hold CT of the chest in addition to PET/CT for routine staging of malignancy. We evaluated the rate of pulmonary nodule detection on standard CT images from whole body PET/CT studies (WB-PET/CT), high-resolution lung reconstruction CT images from PET/CT studies (HR-PET/CT), and diagnostic breath hold chest CT (BH-CT).

Materials and Methods: A cohort of 25 patients was identified who had a history of lung cancer as well as a PET/CT staging or restaging scan and BH-CT within 30 days of each other. All PET/CTs included a set of CT images using a soft tissue algorithm filter and 3.75- to 5-mm slice thickness, as well as high-resolution reformats with a sharp reconstruction filter and 2-mm slice thickness. The CT images from WB-PET/CT, HR-PET/CT, and BH-CT were reviewed by three radiologists. Significance was analyzed by two-way repeated measures analysis of variance.

Results: There were 2.84 nodules found per patient with WB-PET/CT, 3.85 nodules with HR-PET/CT, and 3.91 nodules with BH-CT. When only nodules less than or equal to 8 mm in size were considered, WB-PET/CT also demonstrated significantly fewer nodules (1.98) compared to the HR-PET/CT (2.94) or a BH-CT (2.86) ($P < 0.001$). No difference in detection rate was noted between the two higher resolution modalities.

Conclusions: More pulmonary nodules are detected on the CT portion of PET/CT studies when high-resolution reformatted images are created and reviewed. The ability to detect nodules with the reformatted images was indistinguishable from dedicated BH-CT. Overall, high-resolution reformats of PET/CT images of the lungs can increase the sensitivity for pulmonary nodule detection, approaching that of dedicated BH-CT. These data suggest that if HR-PET/CT reformats are used, additional dedicated BH-CT is unnecessary for routine staging of lung cancer.

Key Words: PET/CT; pulmonary nodule; high-resolution reconstruction; breath hold; non-small cell lung cancer.

© 2016 The Association of University Radiologists. Published by Elsevier Inc. All rights reserved.

INTRODUCTION

18F-Fluorodeoxyglucose (FDG) positron emission tomography combined with whole body computed tomography (PET/CT) has become the standard of

care imaging test for staging of patients with non-small cell lung cancer (NSCLC) (1). Staging of NSCLC is performed using the tumor, node, metastasis (TNM) classification system (2–5). Multiple prior studies have demonstrated that PET/CT is superior to CT alone for staging the primary mass (T stage) (6), associated nodal disease (N stage) (7), and distant metastasis (M stage) (8). For these reasons, PET/CT has become widely used for this application.

The presence or absence of pulmonary nodules, distinct from the primary mass, is an important contributor to the overall stage of NSCLC (3–5). Specifically, the presence of other nodules in the same lobe as the primary tumor confers the T3 stage, and the presence of nodules in the same side, different lobe, results in a T4 tumor. Metastatic pulmonary nodules

Acad Radiol 2016; 23:1123–1129

From the Department of Radiology and Biomedical Imaging, University of California, San Francisco, 505 Parnassus Ave, M-391, San Francisco, CA 94143-0628. Received December 17, 2015; revised April 15, 2016; accepted April 17, 2016. Funding: R.R.F. and M.C.M. acknowledge the NIH T32 5T32EB0011631-10, and R.R.F. acknowledges an RSNA Fellow Grant and an SNMMI-ERF Mitzi and William Bland MD Pilot Research grant. **Address correspondence to:** D.M.N. e-mail: david.naeger@ucsf.edu

© 2016 The Association of University Radiologists. Published by Elsevier Inc. All rights reserved.
<http://dx.doi.org/10.1016/j.acra.2016.04.007>

in the contralateral lung confer M1a disease. An accurate assessment for nodules suggestive of metastatic disease can only be accomplished via imaging; therefore, it is critical to accurately assess the presence of even small pulmonary nodules.

Several investigators have previously investigated the ability of PET/CT to detect pulmonary nodules, and compared against conventional breath hold chest CT (BH-CT) (9–12). Overall, these studies have found that small pulmonary nodules can be missed on PET/CT in comparison with conventional CT, because of the non-breath-hold technique on PET/CT, as well as the low spatial resolution of the CT component of the examination (including generally thick slices and lower in-plane resolution with large fields of view). Furthermore, small pulmonary nodules below 1 cm in size are often not seen on the PET portion of the examination (13,14). This has led some authors to conclude that PET/CT is insufficient to completely stage malignancies because of the missed nodules (10–12). In most routine PET/CT scans, the images are reconstructed using a relatively thick slices (typically 5 mm), with soft tissue reconstruction algorithm. Prior studies have demonstrated that using thinner slices (1.25 mm) can improve the rate of pulmonary nodule detection on routine BH-CT (15). At our institution, we commonly reformat CT images from PET/CT studies with a high-resolution reconstruction to improve the detection of pulmonary nodules, although the added value from these reformations is unknown.

The objective of this study was to assess the ability to detect pulmonary nodules on high-resolution reformatted CT images compared to standard CT images obtained as part of whole body PET-CT (WB-PET/CT) studies. Although it is likely that improved resolution should yield some improvement in nodule detection, this has not been previously investigated in the PET/CT context. We compared the ability to detect nodules on both sets of images to that of diagnostic BH-CTs. We hypothesized that the high-resolution reformats would reveal more nodules than the standard CT images from WB-PET/CT, and that the increased sensitivity would be similar to those obtained via dedicated chest CT studies.

METHODS

Patient Selection

This retrospective study was approved by our institution's institutional review board (IRB) and informed consent was waived. We searched our database of all PET/CT performed between February 2012 and July 2013 at our institution for the presence of the term "lung cancer." Scans of patients who met the following inclusion criteria were included up to our target enrollment of 25 patients:

1. Biopsy-proven diagnosis of NSCLC at the time of the imaging studies
2. No definitive evidence of distant metastatic disease (thereby restricting the cohort to patients for whom an accurate identification of pulmonary nodules could matter to the stage)

3. PET/CT and BH-CT imaging studies obtained at our institution within 30 days of each other were available in picture archiving and communications system (PACS)

Scan Technique

FDG PET/CT examinations were performed on either a Biograph 16 (Hi-Rez) PET/CT scanner (Siemens AG, Erlangen, Germany) with an integrated PET and 16-MDCT scanner, or a Discovery VCT PET/CT scanner (GE Medical Systems, Milwaukee, WI) with an integrated PET and 64-MDCT scanner. All patients fasted with hydration for at least 6 hours. Patients had blood glucose levels <200 mg/dL. Of ^{18}F -FDG, 0.45 ± 0.09 GBq (12.2 ± 2.4 mCi) was injected intravenously, followed by a 10-mL normal saline flush. Patients rested for 60 ± 15 minutes and voided before being positioned supine on the scanner table. The CT portion of the PET/CT was performed in neutral breath hold after the injection of 150 mL of iohexol (Omnipaque 350; GE Healthcare, Wauwatosa, Wisconsin, USA) at 3 mL/s. Acquisition was performed at a kVp of 120 with auto-mAs. Whole body CT images were reconstructed as contiguous 3.75- or 5-mm slices. Lung reformation CT images were generated using 2-mm slice thickness and a sharp reconstruction algorithm. PET was performed immediately following CT, without patient repositioning. PET images were obtained in 3D mode at 7–10 bed positions per patient, with an acquisition time of 3–4 minutes per station, from the skull vertex through the mid-thigh.

BH-CT examinations were performed on 16- or 64-slice General Electric Lightspeed VCT scanners, at a kVp of 120 with auto-mAs. Images were reconstructed as contiguous 1.25-mm transaxial slices using standard chest CT reconstruction algorithms that were optimized for both lung and soft tissue evaluation (the degree of edge enhancement was in between that used for abdominal CTs and those used for high resolution computed tomography (HRCT)s to evaluate for interstitial lung disease). A portion of the BH-CT was performed with contrast: 70–150 mL of Omnipaque 350.

Imaging and Chart Review

The medical charts of patients included in the study were reviewed for demographic data and histologic confirmation of diagnosis. All cases were reviewed independently for the presence of pulmonary nodules by three radiologists with 4, 9, and 9 years of CT experience. One reader was a radiology resident with 3 years experience, one was an abdominal imaging and nuclear medicine with 9 years of CT experience, and fellowship training in abdominal imaging and nuclear medicine, and one was a thoracic radiology and nuclear medicine with 9 years of CT experience, and fellowship training in thoracic radiology and nuclear medicine. Each reader reviewed the three sets of images of all 25 patients, thereby resulting in 75 reviewed studies. The order the studies were reviewed was randomized and divided into three separate blocks of 25 examinations. Each set of 25 examinations was reviewed

separately, and all examinations were reviewed over a course of 3 months. All examinations were interpreted for the presence of pulmonary nodules, which were defined using standard criteria: discrete, rounded opacities between 3 and 30 mm in diameter. Nodules with definitively benign imaging characteristics, such as dense uniform calcification or macroscopic fat (16), were excluded. The location of all nodules was recorded, as was the size (longest dimension on transaxial CT images). The total number of nodules was summed up for both the right and left lungs for each reader, scan type, and patient. The quality of the scan for detecting pulmonary nodules was assessed using a qualitative scale from 1 to 10, where 1 is poor or nondiagnostic and 10 is optimal in technique.

Statistical Analysis

Statistical analysis was performed with MedCalc for Windows, version 14.8.1 (MedCalc Software, Ostend, Belgium). Two-way repeated measures analysis of variance (ANOVA) was used to evaluate the differences in the number of nodules detected by modality and reader. This was repeated for nodules less than or equal to 8 mm and for nodules greater than 8 mm. Two-way repeated measures ANOVA was also used to evaluate the differences in quality rating between modality and reader. As the datasets were not perfectly normally distributed, in order to ensure that results were not driven by deviations from the underlying assumptions of ANOVA, the analyses were repeated after a rank transformation to achieve a more normal distribution. The statistical significance of comparisons was not significantly changed, and thus the more easily understood non-rank-transformed results are presented. Generally, $P < 0.05$ was used to signify statistical significance, although for pairwise comparisons in which three statistics were available, a Bonferroni correction was applied; therefore, $P < 0.05/3 = 0.0167$ was considered statistically significant.

RESULTS

Patient Demographics

Patient demographics are summarized in Table 1. Sixteen of the 25 BH-CTs were performed with intravenous contrast (64%), as well as all of the PET/CTs (25/25; 100%).

Scan Interpretation

WB-PET/CT, high-resolution PET/CT (HR-PET/CT), and BH-CT were interpreted for the presence and size of nodules, as outlined in the Methods section. Three representative cases are shown in Figure 1.

When averaged across the three readers, 69.3, 96.3, and 97.7 nodules were found across 25 patients on WB-PET/CT, HR-PET/CT, and BH-CT, respectively. Overall, this yields 2.77 nodules per patient on WB-PET/CT, 3.85 nodules per patient on HR-PET/CT, and 3.91 nodules per patient on BH-CT (statistical analyses for differences are reported in the

TABLE 1. Patient Demographics

Age	70.3 ± 7.2 years
Sex	
Male	14/25 (56%)
Female	11/25 (44%)
Average time between PET and CT scan	17.8 ± 8.0 days
Indication for CT	
Restaging/treatment response/surveillance	19/25 (76%)
Initial staging	4/25 (16%)
Suspected pulmonary embolism	2/25 (8%)
Indication for PET/CT	
Restaging/treatment response/surveillance	21/25 (86%)
Initial staging	4/25 (16%)

PET/CT, positron emission tomography/computed tomography.

next section). When only nodules less than or equal to 8 mm in size were considered, an average of 1.98, 2.94, and 2.86 nodules were found per patient on WB-PET/CT, HR-PET/CT, and BH-CT, respectively. When nodules greater than 8 mm were considered, an average of 1.04, 0.99, and 0.85 nodules were found on BH-CT, HR-PET/CT, and WB-PET/CT, respectively. The results analyzed on a per-reader basis are shown in Figure 2.

Each reader analyzed each scan for overall quality, with a rating ranging from 1 to 10, where 1 is nondiagnostic and 10 is optimal for detection of pulmonary nodules. These results are summarized in Figure 3. When averaged across all three readers, the average quality score for WB-PET/CT was 7.36, for HR-PET/CT it was 8.43, and for BH-CT it was 8.81 (statistical analysis for differences is reported in the following section).

Statistical Analysis

For nodules of all sizes, two-way repeated measures ANOVA was statistically significant for differences in the mean number of nodules by modality ($F = 11.78$, $P < 0.001$) but not statistically significantly different by reader ($F = 0.028$, $P = 0.927$). For pairwise comparisons between modalities, there was a statistically significant difference between WB-PET/CT and HR-PET/CT ($P < 0.001$), and a statistically significant difference between WB-PET/CT and BH-CT ($P < 0.001$). There was no statistically significant difference between HR-PET/CT and BH-CT ($P = 0.9181$).

For the smallest nodules, those less than 8 mm, a two-way repeated measures ANOVA was statistically significant for differences in the mean number by modality ($F = 8.74$, $P < 0.001$) but not by reader ($F = 0.17$, $P = 0.846$). Pairwise comparisons again demonstrated a statistically significant difference between WB-PET/CT and the two higher resolution modalities ($P < 0.001$, for comparisons of BH-CT and HR-PET/CT), but not between the two higher resolution modalities ($P = 0.754$).

When nodules greater than 8 mm in size were considered, two-way repeated measures ANOVA was not statistically

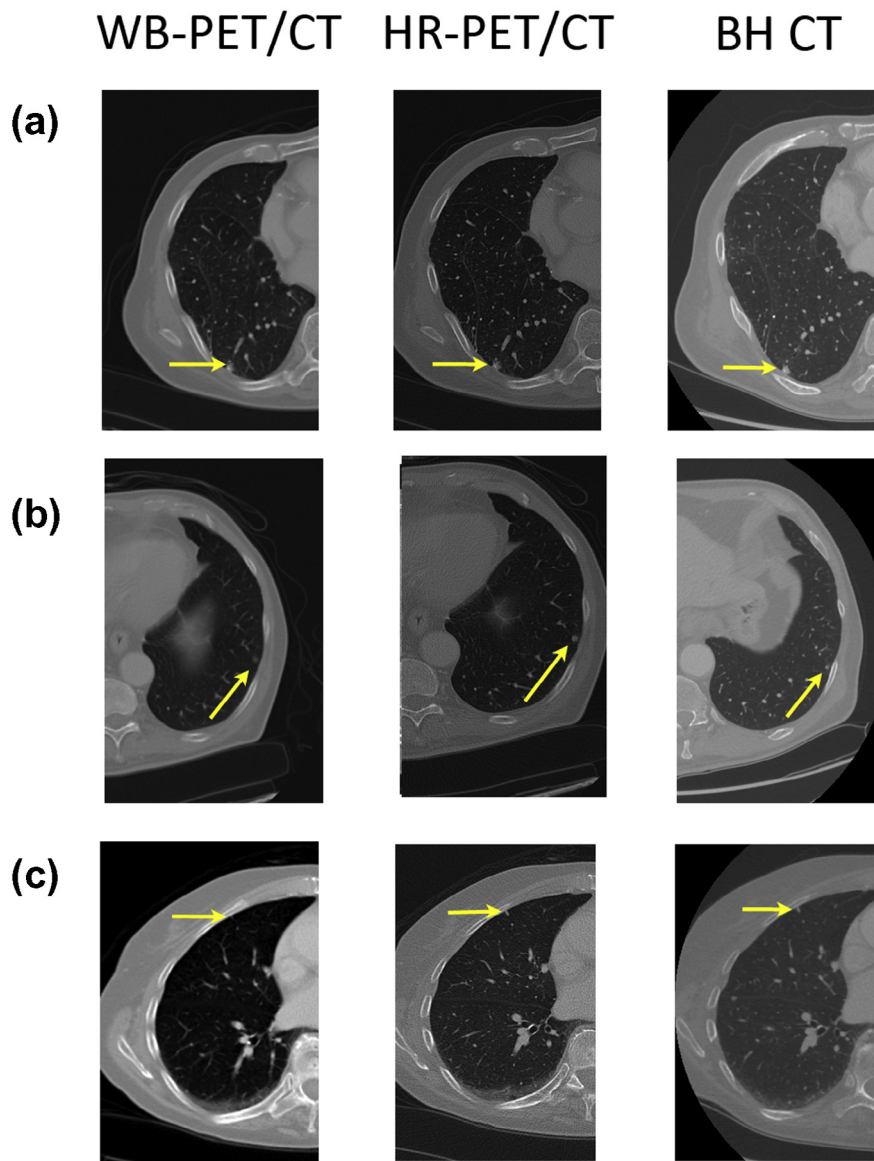


Figure 1. Examples of pulmonary nodules detected using various methods. (a) A 67-year-old man with history of non-small cell lung cancer (NSCLC) post-resection with a 4-mm nodule found along the suture line. The nodule was detected on whole body positron emission tomography/computed tomography (WB-PET/CT) by one out of three radiologists, on high-resolution PET/CT (HR-PET/CT) by three out of three radiologists, and on breath hold chest CT (BH-CT) by three out of three radiologists. (b) A 67-year-old man with history of NSCLC post-resection (same patient as [a]) with a 4-mm left lower lobe pulmonary nodule. The nodule was detected on WB-PET/CT by one of three radiologists, on HR-PET/CT by three out of three radiologists, and on BH-CT by three out of three radiologists. (c) A 78-year-old woman with history of NSCLC with recurrence. Images demonstrate a 3-mm subpleural right upper lobe nodule, detected on WB-PET/CT by none of three radiologists, on HR-PET/CT by two out of three radiologists, and on BH-CT by two out of three radiologists.

significant for differences in the mean number of nodules >8 mm by modality ($F = 2.24$, $P = 0.110$) or by reader ($F = 0.78$, $P = 0.461$).

Two-way repeated measures ANOVA was statistically significant for differences in the mean quality rating by modality ($F = 51.72$, $P < 0.001$) and by reader ($F = 31.05$, $P < 0.001$). Pairwise differences revealed reader #3 differed in the use of the scoring system from the other two (mean score given was 9.09, compared to 7.73 and 7.77, respectively; $P < 0.001$). There was no statistically significant difference in ratings between readers #1 and #2 ($P = 0.839$). Pairwise differences in quality by modality demonstrated a statistically significant difference between WB-PET/CT and BH-CT ($P < 0.001$), a statistically significant difference between WB-PET/CT and HR-PET/CT ($P < 0.001$), and a statistically significant difference between HR-PET/CT and BH-CT ($P = 0.011$).

DISCUSSION

The presence or absence of pulmonary nodules identified on imaging can affect staging, and therefore management, in patients with NSCLC and other malignancies. The objective of this study was to evaluate the relative performance of three diagnostic methods for detecting pulmonary nodules, including standard CT images from WB-PET/CT, HR-PET/CT, and BH-CT. The key new finding in our study is that HR-PET/CT is superior in the detection of pulmonary nodules to standard CT images from WB-PET/CT studies and indistinguishable from that of BH-CT. Readers also qualitatively rated high-resolution reformatted images as higher than standard images, approaching the ratings of BH-CT images.

We have not identified any prior studies directly assessing the performance of high-resolution CT images from PET/CT

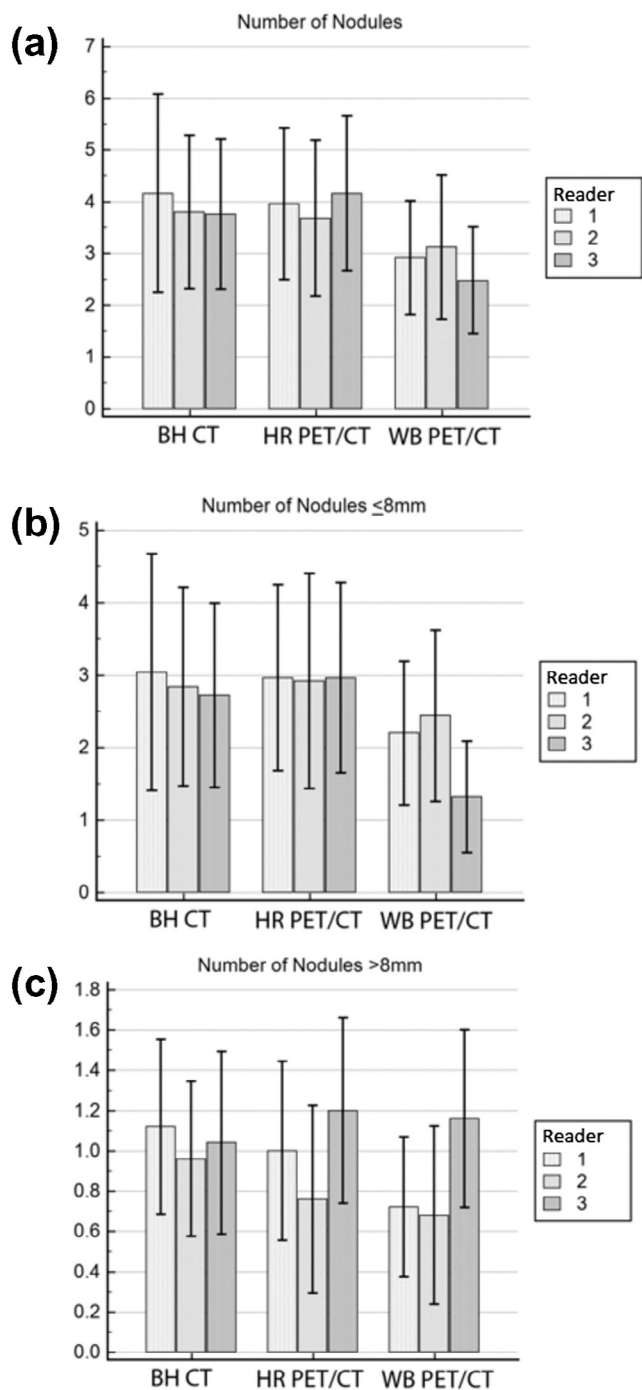


Figure 2. Summary of nodules detected by readers, reported \pm standard deviation. (a) The average number of nodules identified per reader, per patient, using breath hold computed tomography (BH-CT), high-resolution positron emission tomography/computed tomography (HR-PET/CT), and whole body PET/CT (WB-PET/CT). (b) The average number of nodules less than or equal to 8 mm in size, per reader, per patient, using BH-CT, HR-PET/CT, and WB-PET/CT. (c) The average number of nodules greater than 8 mm in size, per reader, per patient, using BH-CT, HR-PET/CT, and WB-PET/CT.

studies for detecting pulmonary nodules. Many studies, however, have demonstrated that BH-CT is superior to standard WB-PET/CT images. Several studies have demonstrated that pulmonary nodules are missed on WB-PET/CT, in com-

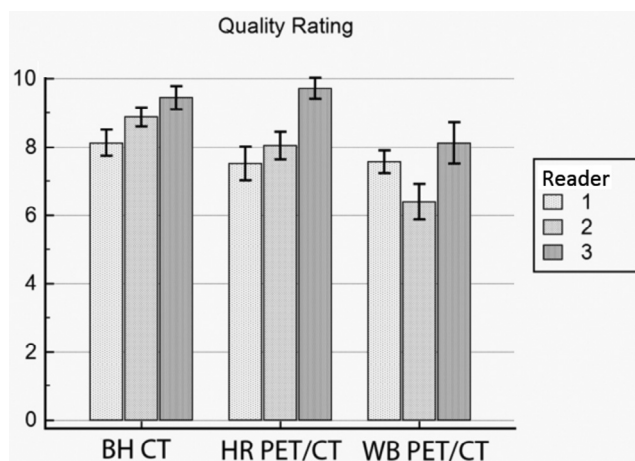


Figure 3. Quality rating from 1 to 10 per reader for breath hold computed tomography (BH-CT), high-resolution positron emission tomography/computed tomography (HR-PET/CT), and whole body PET/CT (WB-PET/CT).

parison to BH-CT, ranging from 0.56 to 0.88 nodules per patient (9–12). In our study, 29 nodules were missed in 25 patients, for an average of 1.16 nodules per patient. This slight increase from previous reports may be because of the greater overall prevalence of pulmonary nodules in our study population. In comparison to other studies, we reviewed exclusively NSCLC patients, whereas other studies included many different malignancies. Furthermore, our study was conducted in a region with high levels of endemic coccidioidomycosis and a high prevalence of benign nodules (17). Taken together, our data are consistent with the previously described reports and confirm the finding that WB-PET/CT is inferior to BH-CT for detection of pulmonary nodules.

In detecting pulmonary nodules, WB-PET/CT is inferior in comparison to BH-CT for two reasons. First, the CT portion of PET/CT cannot be performed with a maximal inspiration because of the attenuation correction and misregistration artifacts that would result (18), instead it is typically performed in a neutral breath hold. Second, there is lower in-plane resolution because of the large field of view in order to include the shoulders as well as low z-axis resolution, which allows the whole body to be covered in a manageable number of images. In our study, high-resolution reformations of the lungs allow for nodule detection similar to BH-CT; the performance of these reformats appears to be due to the improved special resolution in the z-axis (2 mm vs 5 mm) and the use of an edge-enhancing algorithm that simulates an improved in-plane resolution (Fig 1). This technique optimizes the properties of the CT for pulmonary nodule detection without giving additional radiation dose.

Although no prior reports could be located assessing high-resolution reformats of the lung as part of PET/CT scans, high-resolution targeted images of the neck have been shown to improve the accuracy of staging of head and neck squamous cell cancer (19). Unlike this previously reported technique, which requires an additional scan, our

method does not require additional radiation or scanner time to perform.

The primary limitation of our study is that we were not able to directly assess the clinical significance detecting additional nodules with this technique. First, we were not able to determine in this retrospective analysis whether the additionally detected nodules were benign or malignant; many prior studies, however, have shown that a reasonable minority of detected nodules in lung cancer patients are indeed malignant, including some nodules detectable by higher resolution techniques that were missed by PET/CT. In a study of 551 patients with lung cancer who had a staging BH-CT, 11% of small noncalcified pulmonary nodules were malignant (20). In a pathologically verified study of 65 pulmonary nodules 1 cm or smaller, 58% were malignant (21). In a second pathologically verified study of 160 nodules of less than or equal to 0.5 cm resected at surgery, 58% were malignant (22). In a study incorporating patients with a variety of malignancies, Thipphavong et al. found that 6 of 159 (3.7%) nodules missed on PET/CT but found on BH-CT were malignant lesions (9). Kim et al. (23) found that 6 of 138 nodules (4.3%) in NSCLC patients in the non-primary cancer lobe were malignant.

Second, on the new *malignant* nodules that could be detected, we could not assess via this study the ultimate importance of finding such nodules with regard to altering management or staging. Such a study would require a large number of patients and high-level longitudinal follow-up. That said, many prior investigators have concluded that BH-CT should be performed in addition to WB-PET/CT for staging of malignancies (10–12); these HR reformats approximate BH-CT in the accuracy of detecting nodules and may be a sufficient substitute in some cases.

This study has a few additional smaller limitations. First, we studied a small patient cohort, which was necessary given the multiple reads required for each patient; we nonetheless were able to detect a statistically significant difference between the modalities. Potentially a larger sample could have resulted in identifying a small difference between HR-PET/CT and BH-CT, although the difference is not likely to be clinically significant. Second, the study is limited because of its retrospective design. Third, the CT technique in the BH-CT group used reconstruction algorithms that were optimized for both lung and soft tissue evaluation, and it is possible that a true edge-enhancing reconstruction algorithm may have detected additional pulmonary nodules. Finally, given that we did not detect differences in readers' sensitivities, we could not evaluate the factors that could have been associated with a greater or lesser ability to detect nodules.

Our data indicate that HR reformations from PET/CT images are superior for the detection of pulmonary nodules compared to standard PET/CT images, and are overall similar to diagnostic BH-CTs. To our knowledge, we are the first to demonstrate that HR-PET/CT improves pulmonary nodule detection, and specifically to a level indistinguishable from

routine BH-CT, which is widely recommended in the staging of multiple malignancies. It is likely that HR-PET/CT obviates the need for dedicated BH-CT for the detection of pulmonary nodules. Similarly, we have demonstrated that the quality score of such high-resolution reformats was higher than for standard WB-PET/CT images. HR-PET/CT is a simple intervention that requires no additional scan time or radiation and can easily be incorporated into routine clinical practice.

REFERENCES

1. Kligerman S, Digumarthy S. Staging of non-small cell lung cancer using integrated PET/CT. *AJR Am J Roentgenol* 2009; 193:1203–1211.
2. UyBico SJ, Wu CC, Suh RD, et al. Lung cancer staging essentials: the new TNM staging system and potential imaging pitfalls. *Radiographics* 2010; 30:1163–1181.
3. Rami-Porta R, Ball D, Crowley J, et al. The IASLC Lung Cancer Staging Project: proposals for the revision of the T descriptors in the forthcoming (seventh) edition of the TNM classification for lung cancer. *J Thorac Oncol* 2007; 2:593–602.
4. Postmus PE, Brambilla E, Chansky K, et al. The IASLC Lung Cancer Staging Project: proposals for revision of the M descriptors in the forthcoming (seventh) edition of the TNM classification of lung cancer. *J Thorac Oncol* 2007; 2:686–693.
5. Goldstraw P, Crowley J, Chansky K, et al. The IASLC Lung Cancer Staging Project: proposals for the revision of the TNM stage groupings in the forthcoming (seventh) edition of the TNM classification of malignant tumours. *J Thorac Oncol* 2007; 2:706–714.
6. De Wever W, Stroobants S, Coolen J, et al. Integrated PET/CT in the staging of nonsmall cell lung cancer: technical aspects and clinical integration. *Eur Respir J* 2009; 33:201–212.
7. Cerfolio RJ, Ojha B, Bryant AS, et al. The accuracy of integrated PET-CT compared with dedicated PET alone for the staging of patients with nonsmall cell lung cancer. *Ann Thorac Surg* 2004; 78:1017–1023, discussion 1017–1023.
8. Schrevels L, Lorent N, Dooms C, et al. The role of PET scan in diagnosis, staging, and management of non-small cell lung cancer. *Oncologist* 2004; 9:633–643.
9. Thipphavong S, Lim R, Zabor E, et al. Clinical significance of pulmonary nodules missed on non-breath-hold PET/CT. *J Nucl Med Radiat Ther* 2013; 4:159.
10. Allen-Auerbach M, Yeom K, Park J, et al. Standard PET/CT of the chest during shallow breathing is inadequate for comprehensive staging of lung cancer. *J Nucl Med* 2006; 47:298–301.
11. Juergens KU, Weckesser M, Stegger L, et al. Tumor staging using whole-body high-resolution 16-channel PET-CT: does additional low-dose chest CT in inspiration improve the detection of solitary pulmonary nodules? *Eur Radiol* 2006; 16:1131–1137.
12. Aquino SL, Kuester LB, Muse VV, et al. Accuracy of transmission CT and FDG-PET in the detection of small pulmonary nodules with integrated PET/CT. *Eur J Nucl Med Mol Imaging* 2006; 33:692–696.
13. Nomori H, Watanabe K, Ohtsuka T, et al. Evaluation of F-18 fluorodeoxyglucose (FDG) PET scanning for pulmonary nodules less than 3 cm in diameter, with special reference to the CT images. *Lung Cancer* 2004; 45:19–27.
14. Khalaf M, Abdel-Nabi H, Baker J, et al. Relation between nodule size and 18F-FDG-PET SUV for malignant and benign pulmonary nodules. *J Hematol Oncol* 2008; 1:13.
15. Fischbach F, Knollmann F, Griesshaber V, et al. Detection of pulmonary nodules by multislice computed tomography: improved detection rate with reduced slice thickness. *Eur Radiol* 2003; 13:2378–2383.
16. Takashima S, Sone S, Li F, et al. Small solitary pulmonary nodules (< or =1 cm) detected at population-based CT screening for lung cancer: reliable high-resolution CT features of benign lesions. *AJR Am J Roentgenol* 2003; 180:955–964.
17. Huang JY, Bristow B, Shafir S, et al. Coccidioidomycosis-associated deaths, United States, 1990–2008. *Emerg Infect Dis* 2012; 18:1723–1728.

18. Goerres GW, Burger C, Kamel E, et al. Respiration-induced attenuation artifact at PET/CT: technical considerations. *Radiology* 2003; 226:906–910.
19. Chatziioannou SN, Georgakopoulos AT, Pianou NK, et al. Recurrent thyroid cancer diagnosis: ROC study of the effect of a high-resolution head and neck 18F-FDG PET/CT scan. *Acad Radiol* 2014; 21:58–63.
20. Keogan MT, Tung KT, Kaplan DK, et al. The significance of pulmonary nodules detected on CT staging for lung cancer. *Clin Radiol* 1993; 48:94–96.
21. Munden RF, Pugatch RD, Liptay MJ, et al. Small pulmonary lesions detected at CT: clinical importance. *Radiology* 1997; 202:105–110.
22. Ginsberg MS, Griff SK, Go BD, et al. Pulmonary nodules resected at video-assisted thoracoscopic surgery: etiology in 426 patients. *Radiology* 1999; 213:277–282.
23. Kim YH, Lee KS, Primack SL, et al. Small pulmonary nodules on CT accompanying surgically resectable lung cancer: likelihood of malignancy. *J Thorac Imaging* 2002; 17:40–46.