

# UC San Diego

## UC San Diego Previously Published Works

### Title

Longitudinal Macular Retinal and Choroidal Microvasculature Changes in High Myopia.

### Permalink

<https://escholarship.org/uc/item/3pr507nq>

### Journal

Investigative ophthalmology & visual science, 62(15)

### ISSN

0146-0404

### Authors

Lin, Fengbin  
Zhao, Zhenni  
Li, Fei  
et al.

### Publication Date

2021-12-01

### DOI

10.1167/iovs.62.15.1

### Copyright Information

This work is made available under the terms of a Creative Commons Attribution-NonCommercial-NoDerivatives License, available at <https://creativecommons.org/licenses/by-nc-nd/4.0/>

Peer reviewed

# Longitudinal Macular Retinal and Choroidal Microvasculature Changes in High Myopia

Fengbin Lin,<sup>1</sup> Zhenni Zhao,<sup>2</sup> Fei Li,<sup>1</sup> Zhen Qiu,<sup>3</sup> Xinbo Gao,<sup>1</sup> Yunhe Song,<sup>1</sup> Peiyuan Wang,<sup>1</sup> Jian Xiong,<sup>1,4</sup> Weijing Cheng,<sup>1</sup> Kun Hu,<sup>1</sup> Meiling Chen,<sup>1</sup> Xiaohong Liang,<sup>1</sup> Yifeng Yu,<sup>4</sup> Bin Yang,<sup>5</sup> Chunman Yang,<sup>6</sup> Fanyin Wang,<sup>7</sup> Mingkui Tan,<sup>3</sup> and Xiulan Zhang<sup>1</sup>; for the GSHM Study Group

<sup>1</sup>State Key Laboratory of Ophthalmology, Zhongshan Ophthalmic Center, Sun Yat-sen University, Guangzhou, China

<sup>2</sup>Department of Pediatric Ophthalmology, Guangzhou Children's Hospital and Guangzhou Women and Children's Medical Center, Guangzhou Medical University, Guangzhou, China

<sup>3</sup>School of Software Engineering, South China University of Technology, Guangzhou, China

<sup>4</sup>Department of Ophthalmology, The Second Affiliated Hospital of Nanchang University, Nanchang, China

<sup>5</sup>Zigong Third People's Hospital, Zigong, China

<sup>6</sup>The Second Affiliated Hospital of Guizhou Medical University, Guizhou, China

<sup>7</sup>Shenzhen Nanshan District Shekou People's Hospital, Shenzhen, China

Correspondence: Xiulan Zhang, State Key Laboratory of Ophthalmology, Zhongshan Ophthalmic Center, Sun Yat-sen University, No.7 Jinsui Road, Guangzhou 510060, China; [zhangxl2@mail.sysu.edu.cn](mailto:zhangxl2@mail.sysu.edu.cn).

Mingkui Tan, School of Software Engineering, South China University of Technology, No. 381 Wusan Road, Guangzhou 510006, China; [mingkuitan@scut.edu.cn](mailto:mingkuitan@scut.edu.cn).

FL and ZZ contributed equally to this work.

**Received:** August 6, 2021

**Accepted:** November 9, 2021

**Published:** December 1, 2021

Citation: Lin F, Zhao Z, Li F, et al. Longitudinal macular retinal and choroidal microvasculature changes in high myopia. *Invest Ophthalmol Vis Sci.* 2021;62(15):1. <https://doi.org/10.1167/iovs.62.15.1>

<https://doi.org/10.1167/iovs.62.15.1>

**PURPOSE.** The purpose of this study was to determine the longitudinal changes in macular retinal and choroidal microvasculature in normal healthy and highly myopic eyes.

**METHODS.** Seventy-one eyes, including 32 eyes with high myopia and 39 healthy control eyes, followed for at least 12 months and examined using optical coherence tomography angiography imaging in at least 3 visits, were included in this study. Fovea-centered 6 × 6 mm scans were performed to measure capillary density (CD) of the superficial capillary plexus (SCP), deep capillary plexus (DCP), and choriocapillaris (CC). The rates of CD changes in both groups were estimated using a linear mixed model.

**RESULTS.** Over a mean 14-month follow-up period, highly myopic eyes exhibited a faster rate of whole image CD (wiCD) loss (−1.44%/year vs. −0.11%/year,  $P = 0.001$ ) and CD loss in the outer ring of the DCP (−1.67%/year vs. −0.14%/year,  $P < 0.001$ ) than healthy eyes. In multivariate regression analysis, baseline axial length (AL) was negatively correlated with the rate of wiCD loss (estimate = −0.27, 95% confidence interval [CI] = −0.48 to −0.06,  $P = 0.012$ ) and CD loss in the outer ring (estimate = −0.33, 95% CI = −0.56 to −0.11,  $P = 0.005$ ), of the DCP. The CD reduction rates in the SCP and CC were comparable in both groups (all  $P$  values > 0.05).

**CONCLUSIONS.** The rate of CD loss in the DCP is significantly faster in highly myopic eyes than in healthy eyes and is related to baseline AL. The CD in the outer ring reduces faster in eyes with longer baseline AL.

**Keywords:** retinal capillary density, choriocapillaris, high myopia, longitudinal study

The prevalence of high myopia has increased rapidly in recent years.<sup>1,2</sup> It is estimated that by 2050, approximately 5 billion people will have myopia worldwide, with 1 billion having high myopia.<sup>2</sup> High myopia is particularly important because it can cause irreversible vision loss and even blindness.<sup>3–6</sup> Macular pathologies, including chorioretinal atrophy, choroidal neovascularization, and lacquer crack formation, which are associated with retinal and choroidal vascular alterations, are the major causes of vision loss and blindness in high myopia.<sup>1,4,7,8</sup> Therefore, it is essential to observe the vascular changes that occur in high myopia.

Optical coherence tomography (OCT) angiography (OCTA) is a novel, noninvasive imaging modality that allows for the visualization of retinal and choroidal microvasculature in vivo.<sup>9</sup> Previous studies conducted using OCTA have shown that eyes with high myopia have lower perfusion than

those with emmetropia.<sup>10,11</sup> Furthermore, decreased retinal vessel density and increased flow deficit in the choriocapillaris (CC) have been reported to be significantly correlated with axial length (AL) elongation.<sup>11–16</sup> However, only few studies have investigated the changes in the macular microvasculature of highly myopic eyes over time, especially with simultaneous evaluation of the retina and choroid.

Swept-source OCTA (SS-OCTA) utilizes a longer wavelength (1050 nm) light source and features significantly reduced signal roll-off compared to conventional spectral-domain OCTA, which is more suitable for imaging highly myopic eyes with long AL.<sup>17,18</sup> In this study, we evaluated the longitudinal changes in the macular retinal and choroidal microvasculature of highly myopic eyes using SS-OCTA and assessed whether these changes are associated with demographic and ocular parameters.

## METHODS

### Study Participants

This prospective longitudinal study was conducted according to the tenets of the Declaration of Helsinki and was approved by the Ethics Committee of the Zhongshan Ophthalmic Center, Sun Yat-sen University, China. The participants were enrolled and examined between January 2019 and May 2021. Informed consent forms were filled out and signed by all participants prior to enrollment.

The inclusion criteria were as follows: (1) age  $\geq 18$  years; (2) best-corrected visual acuity (BCVA) of 20/40 or better; (3) intraocular pressure (IOP)  $< 21$  mm Hg; (4) normal optic disc appearance with intact neuroretinal rim and retinal nerve fiber layer; and (5) at least 3 visits over a period of at least 12 months. The exclusion criteria included: (1) history of ocular surgery; (2) any kind of ophthalmic disease that can affect the ocular microvasculature, such as glaucoma, retinal diseases, and neuro-ophthalmic diseases; (3) myopic maculopathy equal to or more serious than “diffuse chorioretinal atrophy” (equal to category 2 based on the International Meta-analysis for Pathological Myopia classification system), and/or the presence of posterior staphyloma<sup>19,20</sup>; (4) systemic hypertension and/or diabetes mellitus; (5) smoking history; and (6) intake of coffee or alcohol within 24 hours before the procedure. Eligible participants were divided into 2 groups according to their baseline AL: the high myopia group, which included eyes with an AL of 26.0 mm or more, and the normal healthy group, which included those with an AL of less than 26.0 mm.

### Examinations

All participants were evaluated every 6 months and underwent a comprehensive ophthalmologic examination, including slit-lamp biomicroscopy, measurement of BCVA, refractive error assessment using an autorefractor (KR-800, Topcon, Japan), IOP measurement using the Goldmann applanation tonometry, measurement of AL and central corneal thickness (CCT) using an IOL Master (IOL Master 700, Carl Zeiss Meditec, Germany), digital stereo fundus photography (Nonmyd WX3D, KOWA, Japan), and OCT and OCTA imaging. Additionally, systolic blood pressure and diastolic blood pressure were measured, and a detailed medical history of each participant was recorded. The examinations were performed at the same time of the day to minimize the effect of the diurnal fluctuation for every participant.

### OCT and OCTA Imaging

The participants underwent OCT and OCTA imaging at the same visit. Both procedures were performed using an SS-OCT equipment (Triton, DRI-OCT 2; TOPCON, Japan). The instrument has a light source with a wavelength of 1050 nm at a speed of 100,000 A scans per second and provides both thickness and vascular measurements. All scans performed were centered on the fovea, with a macular  $6 \times 6$  mm.

The en face OCTA images were generated by the inbuilt software of the SS-OCT equipment (IMAGENet6, version 1.28.17642, Basic License 1). Slabs of the superficial capillary plexus (SCP), deep capillary plexus (DCP), and CC were automated and segmented by the software. The SCP was delineated from 2.6  $\mu\text{m}$  below the internal limiting

membrane to 15.6  $\mu\text{m}$  below the junction between the inner plexiform and inner nuclear layers. The DCP was delineated from 15.6  $\mu\text{m}$  below the inner plexiform and inner nuclear layers to 70.2  $\mu\text{m}$  below these layers. The CC was delineated from the lower boundary of Bruch's membrane to 10.4  $\mu\text{m}$  below this membrane.<sup>17,21,22</sup> The effects of projection and eye motion-related artifacts were minimized by the OCTA algorithm and the instrument's inbuilt active eye tracker.<sup>17</sup> All scans were reviewed by two trained graders (authors F. Lin and F. Li) to ensure that the images were of sufficient quality. Any image with a quality score of less than 50, artifacts, blurry regions, inaccurate segmentation, poor centration, and/or signal loss was excluded.<sup>23,24</sup> Eligible OCTA images were then corrected for ocular magnification effects based on AL, using the Littman and the modified Bennett formulae (scaling factor =  $3.382 \times 0.013062 \times [\text{AL} - 1.82]$ ).<sup>25,26</sup> A customized Python (version 3.5) script was used to quantify capillary density (CD) according to the regions of the Early Treatment Diabetic Retinopathy Study (ETDRS) grid (Fig. 1). The ETDRS grid divides the macula into an inner ring, which has an inner diameter of 1 mm and an outer diameter of 3 mm, and an outer ring, which has an inner diameter of 3 mm and an outer diameter of 6 mm. The CD of the sectors, inner ring, outer ring, and whole image were calculated (the center sector of the SCP and DCP was analyzed using the foveal avascular zone [FAZ] area). The repeatability and reproducibility of CD were assessed using the intra-class correlation coefficient. The repeatability and reproducibility of the measurements are good, as shown in Supplementary Table S1.

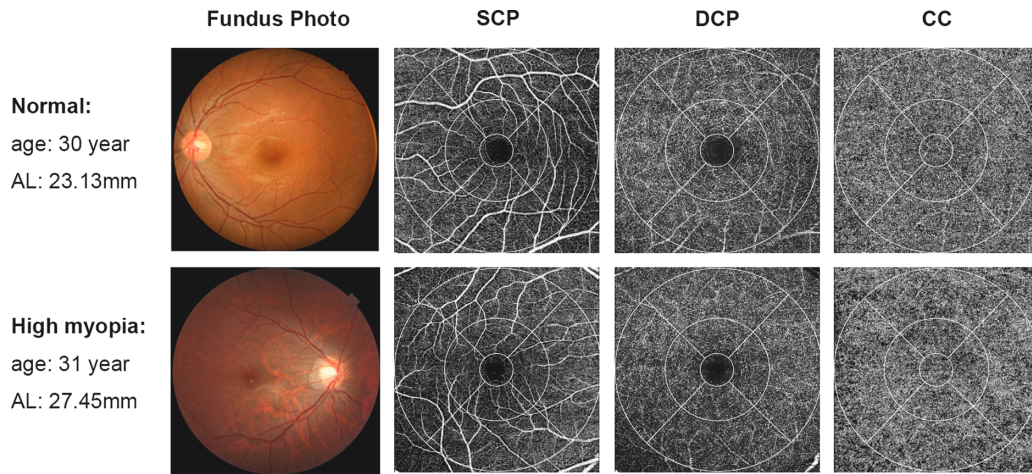
The ganglion cell–inner plexiform layer (GC-IPL) and choroidal thicknesses of the  $6 \times 6$  mm macular region were measured using the OCT scans. Only images of good quality, defined as scans with a quality score  $\geq 50$  and without artifacts and segmentation failure, were included. The overall average GC-IPL and choroidal thicknesses were used in this analysis.

### Sample Size

According to our previous study, density in the DCP reduced more quickly in primary open-angle glaucoma eyes with high myopia than in those without high myopia.<sup>21</sup> In this study, using the two-sample *t*-test, we calculated that a sample size of 31 per group with 80% power was required to detect a mean difference of 1.1% per year between the rates of the changes in CD in the DCP in the normal and high myopia groups, assuming means of  $-0.4\%$  and  $-1.5\%$ , respectively, with a common standard deviation of 1.5.<sup>27,28</sup> The sample size calculations were performed using the PASS 16.0 software (NCSS LLC, East Kaysville, UT, USA) and were based on a 2-sided significance level ( $\alpha$ ) of 0.05.

### Statistical Analysis

The normality of the distribution of all variables was examined using the Shapiro–Wilk test. Continuous and categorical data are presented as mean  $\pm$  standard deviation and count, respectively. The significance of differences in characteristics between the two groups was determined using the two-sample *t*-test for continuous variables and Pearson's chi-squared test for categorical variables. Linear mixed models were used to estimate the rates of the changes in CD in each group. Models were fitted with macular CD measurements as response variable with follow-up duration, age, sex,



**FIGURE 1.** Representative fundus photos and 6 × 6 mm macular optical coherence tomography (OCTA) scans (superficial capillary plexus, deep capillary plexus, and choriocapillaris) of normal and highly myopic eyes. The capillary density is automatically calculated according to the regions of the ETDRS grid. The inner ring is an area with an inner diameter of 1 mm and an outer diameter of 3 mm, whereas the outer ring is an area with an inner diameter of 3 mm and an outer diameter of 6 mm.

group, and interaction between groups and duration as fixed effects. A univariate linear mixed model was first used to investigate the association between the rates of change in CD and demographic or ocular parameters in all eyes. All the variables with a *P* value ≤ 0.1 were further analyzed

in the multivariable model. The generalized estimated equation was used to adjust for inter-eye correlation in the same subject. All statistical analyses were performed using SPSS software (version 24.0; IBM Corporation, Armonk, NY, USA). Statistical significance was set at *P* < 0.05.

**TABLE 1.** Demographic and Ocular Characteristics of the Study Participants

Characteristics	Normal	High Myopia	<i>P</i> Value
By subject, no.	31	27	
Age at diagnosis, years	38.3 ± 8.67	37.3 ± 8.83	0.678*
Sex, male/female	13/18	14/13	0.450†
Self-reported history of Diabetes, no.	0	0	—
Self-reported history of Hypertension, no.	0	0	—
Systolic blood pressure, mm Hg	114.3 ± 15.2	115.5 ± 15.0	0.759*
Diastolic blood pressure, mm Hg	73.4 ± 9.83	69.5 ± 9.98	0.140*
Follow-up duration, month	14.1 ± 2.70	14.3 ± 3.00	0.824*
Number of visits, median (IQR)	3 (3, 4)	3 (3, 4)	0.685*
By eye, no	39	32	
Baseline BCVA, logMAR	−0.00 ± 0.03	0.01 ± 0.02	0.168*
Baseline IOP, mm Hg	13.4 ± 3.29	13.9 ± 2.10	0.474*
Spherical equivalent, diopter	−2.68 ± 2.82	−8.38 ± 2.84	<0.001*
Axial length, mm	24.0 ± 1.02	27.1 ± 1.12	<0.001*
Central corneal thickness, um	549.8 ± 28.9	548.6 ± 39.6	0.879*
Anterior chamber depth, um	3.50 ± 0.32	3.65 ± 0.27	0.039*
Lens thickness, um	3.84 ± 0.31	3.79 ± 0.36	0.536*
Baseline average GC-IPL, um	71.1 ± 5.70	65.3 ± 4.85	<0.001*
Baseline average choroid thickness, um	239.4 ± 64.9	183.1 ± 67.1	0.001*
Baseline whole image capillary density, %			
Superficial capillary plexus	33.9 ± 1.88	34.9 ± 2.24	0.059*
Deep capillary plexus	47.4 ± 2.46	46.3 ± 1.96	0.039*
Choriocapillaris	56.6 ± 0.68	56.3 ± 0.83	0.094*

Abbreviations: BCVA, best corrected visual acuity; GC-IPL, ganglion cell-inner plexiform layer; IOP, intraocular pressure; IQR, interquartile range.

Boldface values indicate statistical significance.

\* Two-sample *t* test.

† Pearson chi-squared test.



**RESULTS**

**Demographic and Ocular Characteristics of the Participants**

Initially, the study enrolled 81 eyes of 66 subjects, of which 10 eyes were excluded because of poor quality OCT ( $n = 3$ ) or OCTA images ( $n = 7$ ). Finally, a total of 71 eyes (32 eyes with high myopia and 39 normal eyes) of 58 subjects were included in the analysis. The mean follow-up duration was  $14.2 \pm 2.75$  months. None of the eyes showed any signs of glaucomatous or retinal disease changes during the study period. The baseline demographic and ocular characteristics

of the study participants are summarized in Table 1. Age, sex, systolic blood pressure, diastolic blood pressure, BCVA, IOP, CCT, lens thickness, follow-up duration, and number of visits were not significantly different between the groups (all  $P$  values  $> 0.05$ ). The differences in spherical equivalent, AL, anterior chamber depth, average GC-IPL thickness, and average choroidal thickness were statistically significant (all  $P$  values  $< 0.05$ ). The whole image CD (wiCD) of the DCP was significantly lower in the eyes with high myopia than in the normal eyes ( $P = 0.039$ ), whereas the CDs of the SCP and CC were not significantly different between the groups (both  $P$  values  $> 0.05$ ).

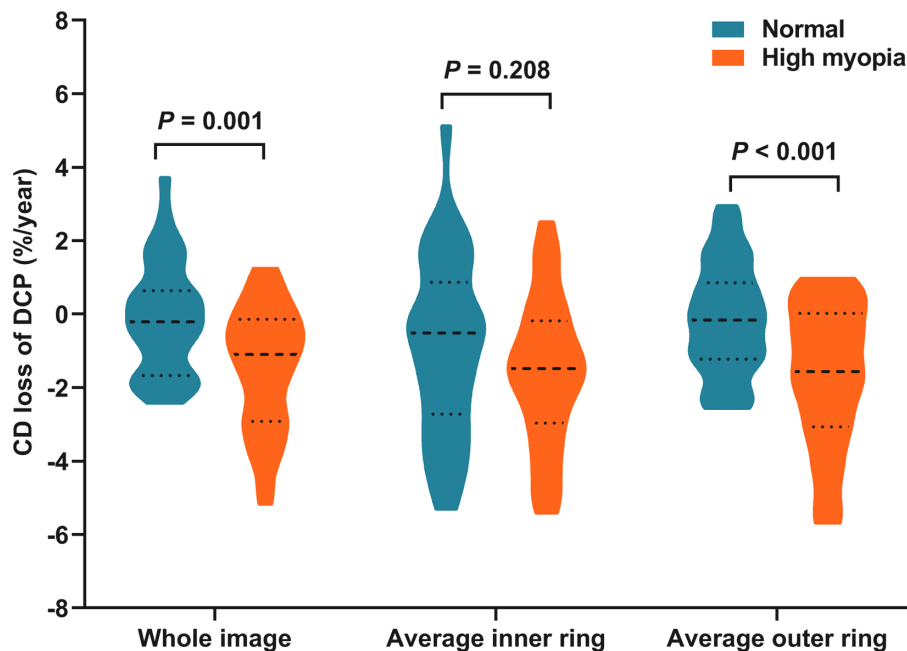
**TABLE 2.** Rates of Changes in Macular Capillary Density in Normal and Highly Myopic Eyes

Rate of Change	Normal (Mean, 95% CI)	High Myopia (Mean, 95% CI)	<i>P</i> Value
<b>Superficial capillary plexus</b>			
Whole image, %/year	-0.46 (-1.01 to 0.07)	-0.33 (-1.11 to 0.41)	0.775
FAZ area, mm <sup>2</sup> /year*	0.01 (-0.02 to 0.05)	0.02 (-0.01 to 0.04)	0.899
Average inner ring, %/year	-0.30 (-1.39 to 0.73)	-0.35 (-1.61 to 0.91)	0.959
Average outer ring, %/year	-0.69 (-1.26 to -0.12)	-0.44 (-1.38 to 0.42)	0.635
<b>Deep capillary plexus</b>			
Whole image, %/year	-0.11 (-0.57 to 0.40)	-1.44 (-1.99 to -0.92)	<b>0.001</b>
FAZ area, mm <sup>2</sup> /year*	0.02 (-0.02 to 0.06)	0.03 (-0.01 to 0.07)	0.903
Average inner ring, %/year	-0.90 (-1.65 to -0.10)	-1.58 (-2.26 to -0.90)	0.208
Average outer ring, %/year	-0.14 (-0.63 to 0.34)	-1.67 (-2.34 to -1.04)	<b>&lt;0.001</b>
<b>Choriocapillaris</b>			
Whole image, %/year	-0.00 (-0.16 to 0.14)	-0.00 (-0.26 to 0.30)	0.986
Foveal, %/year	-0.01 (-0.21 to 0.21)	-0.01 (-0.16 to 0.14)	0.974
Average inner ring, %/year	-0.03 (-0.22 to 0.16)	-0.04 (-0.33 to 0.28)	0.955
Average outer ring, %/year	-0.04 (-0.20 to 0.13)	0.10 (-0.16 to 0.40)	0.379

Abbreviations: CI, confidence interval; FAZ, foveal avascular zone.

Boldface values indicate statistical significance.

\* The center sector of the superficial capillary plexus and deep capillary plexus was analyzed using the foveal avascular zone area.



**FIGURE 2.** Violin plots showing rates of change in macular CD in the DCP in normal and highly myopic eyes. Highly myopic eyes showed faster rates of CD loss in the whole image and the outer ring of the DCP, but not the inner ring, than healthy eyes.

**TABLE 3.** Linear Mixed Model Analysis of Factors Associated With Changes in Capillary Density in the Deep Capillary Plexus in all Eyes

Characteristics	Univariate		Multivariate*	
	Estimate (95% CI)	P Value	Estimate (95% CI)	P Value
<b>Change of CD within whole image</b>				
Baseline age, year	0.04 (−0.00 to 0.09)	0.071	0.03 (−0.01 to 0.08)	0.153
Sex, male	−0.16 (−0.96 to 0.65)	0.704		
Baseline BCVA, logMAR	2.91 (−12.34 to 18.15)	0.705		
Baseline IOP, mm Hg	−0.03 (−0.17 to 0.12)	0.731		
Baseline axial length, mm	−0.29 (−0.50 to −0.09)	<b>0.006</b>	−0.27 (−0.48 to −0.06)	<b>0.012</b>
Baseline central corneal thickness, um	−0.00 (−0.01 to 0.01)	0.883		
Baseline anterior chamber depth, um	−0.94 (−2.27 to 0.40)	0.166		
Baseline lens thickness, um	0.71 (−0.50 to 1.93)	0.245		
Baseline average GC-IPL thickness (um)	0.04 (−0.02 to 0.11)	0.206		
Baseline average choroid thickness, um	0.00 (−0.00 to 0.01)	0.294		
<b>Change of FAZ area†</b>				
Baseline age, year	−0.00 (−0.00 to 0.00)	0.622		
Sex, male	0.01 (−0.05 to 0.07)	0.686		
Baseline BCVA, logMAR	−0.21 (−1.28 to 0.85)	0.689		
Baseline IOP, mm Hg	−0.00 (−0.01 to 0.01)	0.470		
Baseline axial length, mm	0.00 (−0.01 to 0.02)	0.674		
Baseline central corneal thickness, um	0.00 (−0.00 to 0.00)	0.539		
Baseline anterior chamber depth, um	−0.00 (−0.10 to 0.09)	0.942		
Baseline lens thickness, um	−0.02 (−0.11 to 0.06)	0.623		
Baseline average GC-IPL thickness, um	−0.00 (−0.01 to 0.00)	0.303		
Baseline average Choroid Thickness, um	0.00 (0.00 to 0.00)	0.628		
<b>Change of CD within inner ring</b>				
Baseline age, year	0.01 (−0.05 to 0.07)	0.776		
Sex, male	0.62 (−0.43 to 1.68)	0.242		
Baseline BCVA, logMAR	5.85 (−14.2 to 25.9)	0.562		
Baseline IOP, mm Hg	0.01 (−0.18 to 0.20)	0.900		
Baseline axial length, mm	−0.22 (−0.50 to 0.07)	0.131		
Baseline central corneal thickness, um	−0.00 (−0.02 to 0.01)	0.844		
Baseline anterior chamber depth, um	−0.02 (−1.80 to 1.76)	0.983		
Baseline lens thickness, um	0.18 (−1.43 to 1.79)	0.823		
Baseline average GC-IPL thickness, um	0.04 (−0.05 to 0.13)	0.379		
Baseline average choroid thickness, um	0.00 (−0.00 to 0.01)	0.372		
<b>Change of CD within outer ring</b>				
Baseline age, year	0.04 (−0.01 to 0.10)	0.100	0.03 (−0.02 to 0.08)	0.220
Sex, male	−0.41 (−1.29 to 0.48)	0.361		
Baseline BCVA, logMAR	3.74 (−13.0 to 20.5)	0.658		
Baseline IOP, mm Hg	−0.05 (−0.20 to 0.11)	0.548		
Baseline axial length, mm	−0.36 (−0.58 to −0.13)	<b>0.002</b>	−0.33 (−0.56 to −0.11)	<b>0.005</b>
Baseline central corneal thickness, um	0.00 (−0.01 to 0.02)	0.723		
Baseline anterior chamber depth, um	−0.91 (−2.38 to 0.56)	0.220		
Baseline lens thickness, um	0.66 (−0.68 to 2.00)	0.331		
Baseline average GC-IPL thickness, um	0.06 (−0.01 to 0.13)	0.103		
Baseline average choroid thickness, um	0.00 (−0.00 to 0.01)	0.497		

Abbreviations: BCVA, best corrected visual acuity; CD, capillary density; CI, confidence interval; FAZ, foveal avascular zone; GC-IPL, ganglion cell-inner plexiform layer; IOP, intraocular pressure.

Boldface values indicate statistical significance.

\* Multivariate analysis included factors of *P* value ≤ 0.1 in univariate analysis.

† The center sector of the deep capillary plexus was analyzed using the foveal avascular zone area.

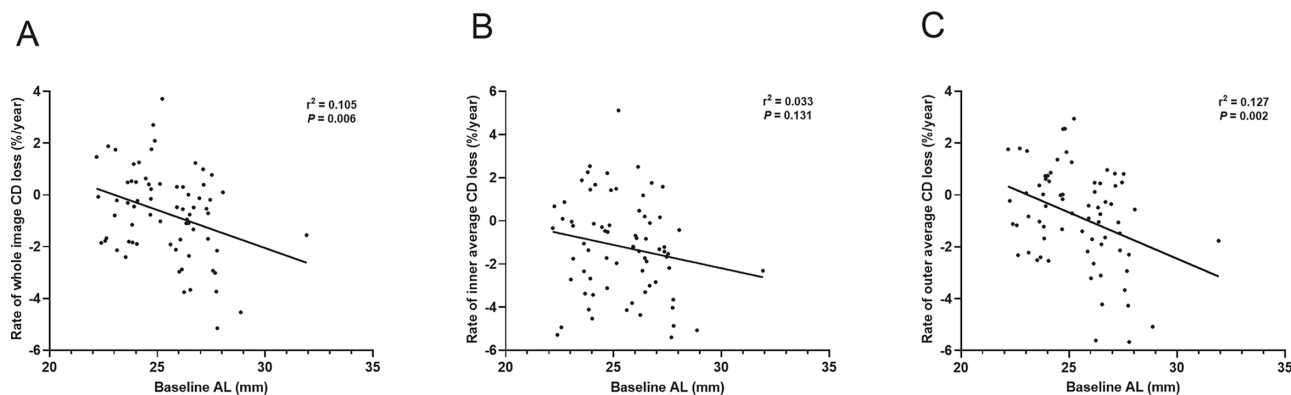
### The Rates of Capillary Density Changes

The rates of macular CD changes in the SCP, DCP, and CC over time are shown in Table 2. Eyes with high myopia showed a significantly faster mean rate of wiCD loss in the DCP (−1.44%/year) than healthy eyes (−0.11%/year, *P* = 0.001). Eyes with high myopia also showed a significantly faster average rate of CD loss in the outer ring than healthy eyes (−1.67%/year vs. −0.14%/year, *P* < 0.001). However, the difference between the average rates of CD loss in the inner ring (−1.58%/year vs. −0.90%/year, *P* = 0.208) and FAZ area change (0.03 mm<sup>2</sup>/year vs. 0.02 mm<sup>2</sup>/year, *P* = 0.903) in the two groups were not statistically significant. In contrast, the

rates of change in the CDs of the SCP and CC (including the whole image, foveal, inner ring, and outer ring regions) were not significantly different between the two groups (all *P* values > 0.05). The maps of the rates of changes in the CD of the DCP in highly myopic and healthy eyes are illustrated in Figure 2.

### Factors Associated With Changes in Capillary Density in the DCP

The relationships between baseline demographic and ocular parameters and the rate of decrease in CD in the DCP are



**FIGURE 3.** Scatterplots illustrating the linear association between baseline AL and rates of change in CD in the DCP in all eyes. A longer AL was negatively correlated with a faster rate of CD loss in the whole image and outer ring.

summarized in Table 3. The univariate analysis showed that baseline AL was significantly associated with both wiCD loss (estimate =  $-0.29$ , 95% confidence interval [CI] =  $-0.50$  to  $-0.09$ ,  $P = 0.006$ ) and outer ring CD loss (estimate =  $-0.36$ , 95% CI =  $-0.58$  to  $-0.13$ ,  $P = 0.002$ ) over time. After adjusting for age in the multivariate analysis, the associations remained significant (estimate =  $-0.27$ , 95% CI =  $-0.48$  to  $-0.06$ ,  $P = 0.012$  and estimate =  $-0.33$ , 95% CI =  $-0.56$  to  $-0.11$ ,  $P = 0.005$ ). No variable was found to correlate with FAZ area change and CD changes in the inner ring (all  $P$  values  $> 0.05$ ). Further quadrant analysis of the DCP showed that baseline AL was significantly associated with decrease in CD in the superior sector of the outer ring ( $P$  values  $< 0.05$  in both univariate and multivariable analyses; Supplementary Table S2). Figure 3 shows the effects of baseline AL on CD decrease in the DCP over time.

## DISCUSSION

In this prospective study, we detected a faster rate of macular CD loss in the DCP of highly myopic eyes than in normal eyes, which was correlated with longer AL at baseline. Moreover, the rate of CD loss in the outer ring of the DCP was associated with baseline AL.

As a risk factor for complications related to high myopia, the relationship between macular microvasculature and high myopia has been assessed in several studies.<sup>10–16</sup> Most of these studies indicated reduction of retinal blood flow in eyes with high myopia compared with non-myopic eyes,<sup>10–14</sup> a finding which is in line with our results. However, to the best of our knowledge, changes in macular microvasculature in eyes with high myopia over time have been investigated in only a study.<sup>28</sup> Shi et al. reported that macular vessel density significantly decreases over time in young patients with myopia.<sup>28</sup> However, they only included superficial slab images in their analysis; the DCP or CC was not included. However, growing evidence indicates that the DCP and CC are more vulnerable to high myopia than the SCP.<sup>11,15,21,29</sup> This may be related to the mechanical stretching caused by excessive axial elongation in highly myopic eyes being more likely to straight and disrupt the vulnerable small-diameter blood vessels in the DCP and CC than the large retinal vessels in the SCP.<sup>15,30–33</sup> Supporting this hypothesis, our results showed that CD loss in the DCP was significantly faster in the high myopia group than in the normal group, whereas the rates of CD loss in the SCP and CC were similar between

the two groups. A possible reason for the similar rates of CD loss in the CC is that the fenestrated capillary network in the CC being more susceptible to age.<sup>34,35</sup>

Emerging evidence demonstrates that longer AL is an important factor associated with decreased retinal density.<sup>12,14,36</sup> Yang et al. reported a significant correlation between the AL and the retinal microvascular network in eyes with high myopia.<sup>12</sup> Cheng et al. observed that decreasing retinal density is correlated with AL elongation.<sup>14</sup> In their myopic macular degeneration study, Zheng et al. also indicated that lower retinal perfusion density is predominantly associated with increasing AL.<sup>36</sup> Similarly, the present study also demonstrated that a faster rate of CD loss in the DCP is significantly associated with longer AL at baseline. Because the DCP contributes to photoreceptor inner segment oxygen requirements (10–15%),<sup>37,38</sup> Therefore, hypoperfusion of the DCP may lead to hypoxia and nutritional deficiency in the photoreceptors and outer retina.<sup>36,38</sup> The loss of oxygen and nutrition would be related to the structural impairment, such as chorioretinal atrophy and choroidal neovascularization. This may help to explain the relationship between longer AL and various pathologic changes in high myopia.

It is noteworthy that the rate of CD reduction in the outer ring, not in the inner ring, was faster in highly myopic eyes than in normal eyes. Similarly, there was only a negative correlation between baseline AL and the rate of CD reduction in the outer ring. One explanation for this finding might be that the absence of large blood vessels and optic nerve fibers in the DCP makes it less resistant to excessive axial elongation of the eyeball.<sup>31,39</sup> The decrease in peripheral retinal vasculature may compensate for the stretching force over the entire retina to preserve the central microcirculation.<sup>40</sup> This conclusion is supported by the findings of previous studies that show that the peripheral retina thickness, rather than the central retina thickness, is significantly lower in highly myopic eyes.<sup>40–42</sup> Further studies are needed to clarify the mechanisms behind these findings.

The major strengths of the present study include its prospective, longitudinal study design, and the comprehensive investigation of the rates of macular CD changes in the inner and outer rings of the SCP, DCP, and CC in eyes with high myopia. The limitations of this study should be noted as well. First, even though the rate of CD decrease was significantly different between the groups, the follow-up duration was relatively short. A study with a longer follow-up duration is ongoing. Second, the lack of eyes with mild or

moderate myopia limited our stratified observation of CD changes in relation to the degree of myopia. Third, only good-quality OCTA images were included in this study. This may have introduced selection bias and affected the generalizability of the results. Fourth, the current study only included adults. It would be interesting to explore if capillary network in children's eyes have similar patterns. Finally, although the latest built in OCTA algorithm (OCTARA) used in our study,<sup>17</sup> it was still difficult to avoid all artifacts completely, such as projection removal artifact.<sup>43</sup> Methods to compensate for the artifacts are still forthcoming.

In conclusion, this study demonstrated that highly myopic eyes show significantly faster reduction in the macular CD in the DCP than normal eyes. The decrease in CD is negatively correlated with the baseline AL, with regional variations. The CD in the outer ring of the DCP, but not in the inner ring, reduces faster when baseline AL is longer. These findings offer new insights into the development of high myopia and support the role of macular CD as a factor in the underlying mechanisms of complications related to high myopia.

### Acknowledgments

The authors thank all research assistants who contributed to the practical organization and execution of this study.

Supported by the High-level Hospital Construction Project, Zhongshan Ophthalmic Center, Sun Yat-sen University (303020104), the National Natural Science Foundation of China (82070955), and the Science and Technology Program of Guangzhou, China.

Disclosure: **F. Lin**, None; **Z. Zhao**, None; **F. Li**, None; **Z. Qiu**, None; **X. Gao**, None; **Y. Song**, None; **P. Wang**, None; **J. Xiong**, None; **W. Cheng**, None; **K. Hu**, None; **M. Chen**, None; **X. Liang**, None; **Y. Yu**, None; **B. Yang**, None; **C. Yang**, None; **F. Wang**, None; **M. Tan**, None; **X. Zhang**, None

### References

- Ohno-Matsui K, Wu PC, Yamashiro K, et al. IMI pathologic myopia. *Invest Ophthalmol Vis Sci*. 2021;62:5.
- Holden BA, Fricke TR, Wilson DA, et al. Global prevalence of myopia and high myopia and temporal trends from 2000 through 2050. *Ophthalmology*. 2016;123:1036–1042.
- Wong TY, Ferreira A, Hughes R, Carter G, Mitchell P. Epidemiology and disease burden of pathologic myopia and myopic choroidal neovascularization: an evidence-based systematic review. *Am J Ophthalmol*. 2014;157:9–25.e12.
- Haarman AEG, Enthoven CA, Tideman JW, et al. The complications of myopia: A review and meta-analysis. *Invest Ophthalmol Vis Sci*. 2020;61:49.
- GBD 2019 Blindness and Vision Impairment Collaborators, Vision Loss Expert Group of the Global Burden of Disease Study. Causes of blindness and vision impairment in 2020 and trends over 30 years, and prevalence of avoidable blindness in relation to VISION 2020: The Right to Sight: An analysis for the Global Burden of Disease Study. *Lancet Glob Health*. 2021;9:e144–e160.
- Ohno-Matsui K. Pathologic myopia. *Asia Pac J Ophthalmol (Phila)*. 2016;5:415–423.
- Ikuno Y. Overview of the complications of high myopia. *Retina*. 2017;37:2347–2351.
- Yokoi T, Ohno-Matsui K. Diagnosis and treatment of myopic maculopathy. *Asia Pac J Ophthalmol (Phila)*. 2018;7:415–421.
- Spaide RF, Fujimoto JG, Waheed NK, Sadda SR, Staurengi G. Optical coherence tomography angiography. *Prog Retin Eye Res*. 2018;64:1–55.
- Sung MS, Lee TH, Heo H, Park SW. Association between optic nerve head deformation and retinal microvasculature in high myopia. *Am J Ophthalmol*. 2018;188:81–90.
- He J, Chen Q, Yin Y, et al. Association between retinal microvasculature and optic disc alterations in high myopia. *Eye (Lond)*. 2019;33:1494–1503.
- Yang Y, Wang J, Jiang H, et al. Retinal microvasculature alteration in high myopia. *Invest Ophthalmol Vis Sci*. 2016;57:6020–6030.
- Li M, Yang Y, Jiang H, et al. Retinal microvascular network and microcirculation assessments in high myopia. *Am J Ophthalmol*. 2017;174:56–67.
- Cheng D, Chen Q, Wu Y, et al. Deep perifoveal vessel density as an indicator of capillary loss in high myopia. *Eye (Lond)*. 2019;33:1961–1968.
- Al-Sheikh M, Phasukkijwatana N, Dolz-Marco R, et al. Quantitative OCT angiography of the retinal microvasculature and the choriocapillaris in myopic eyes. *Invest Ophthalmol Vis Sci*. 2017;58:2063–2069.
- Su L, Ji YS, Tong N, et al. Quantitative assessment of the retinal microvasculature and choriocapillaris in myopic patients using swept-source optical coherence tomography angiography. *Graefes Arch Clin Exp Ophthalmol*. 2020;258:1173–1180.
- Stanga PE, Tsamis E, Papayannis A, et al. Swept-source optical coherence tomography angio (Topcon Corp, Japan): technology review. *Dev Ophthalmol. Dev Ophthalmol. Japan: Topcon Corp*. 2016;56:13–17.
- Ang M, Wong CW, Hoang QV, et al. Imaging in myopia: potential biomarkers, current challenges and future developments. *Br J Ophthalmol*. 2019;103:855–862.
- Ohno-Matsui K, Kawasaki R, Jonas JB, et al. International photographic classification and grading system for myopic maculopathy. *Am J Ophthalmol*. 2015;159:877–883.e877.
- Ohno-Matsui K, Lai TY, Lai CC, Cheung CM. Updates of pathologic myopia. *Prog Retin Eye Res*. 2016;52:156–187.
- Lin F, Li F, Gao K, et al. Longitudinal changes in macular optical coherence tomography angiography metrics in primary open-angle glaucoma with high myopia: A prospective study. *Invest Ophthalmol Vis Sci*. 2021;62:30.
- Tang FY, Ng DS, Lam A, et al. Determinants of quantitative optical coherence tomography angiography metrics in patients with diabetes. *Sci Rep*. 2017;7:2575.
- Spaide RF, Fujimoto JG, Waheed NK. Image artifacts in optical coherence tomography angiography. *Retina*. 2015;35:2163–2180.
- Kamalipour A, Moghimi S, Hou H, et al. OCT angiography artifacts in glaucoma. *Ophthalmology*. 2021;128:1426–1437.
- Llanas S, Linderman RE, Chen FK, Carroll J. Assessing the use of incorrectly scaled optical coherence tomography angiography images in peer-reviewed studies: A systematic review. *JAMA Ophthalmol*. 2020;138:86–94.
- Sampson DM, Gong P, An D, et al. Axial length variation impacts on superficial retinal vessel density and foveal avascular zone area measurements using optical coherence tomography angiography. *Invest Ophthalmol Vis Sci*. 2017;58:3065–3072.
- Hou H, Moghimi S, Proudfoot JA, et al. Ganglion cell complex thickness and macular vessel density loss in primary open-angle glaucoma. *Ophthalmology*. 2020;127:1043–1052.
- Shi Y, Ye L, Chen Q, et al. Macular vessel density changes in young adults with high myopia: A longitudinal study. *Front Med (Lausanne)*. 2021;8:648644.



29. Ye J, Wang M, Shen M, et al. Deep retinal capillary plexus decreasing correlated with the outer retinal layer alteration and visual acuity impairment in pathological myopia. *Invest Ophthalmol Vis Sci.* 2020;61:45.
30. Shimada N, Ohno-Matsui K, Harino S, et al. Reduction of retinal blood flow in high myopia. *Graefes Arch Clin Exp Ophthalmol.* 2004;242:284–288.
31. Yoshikawa Y, Shoji T, Kanno J, et al. Glaucomatous vertical vessel density asymmetry of the temporal raphe detected with optical coherence tomography angiography. *Sci Rep.* 2020;10:6845.
32. Kur J, Newman EA, Chan-Ling T. Cellular and physiological mechanisms underlying blood flow regulation in the retina and choroid in health and disease. *Prog Retin Eye Res.* 2012;31:377–406.
33. Coscas F, Sellam A, Glacet-Bernard A, et al. Normative data for vascular density in superficial and deep capillary plexuses of healthy adults assessed by optical coherence tomography angiography. *Invest Ophthalmol Vis Sci.* 2016;57:Oct211–Oct223.
34. Agrawal R, Ding J, Sen P, et al. Exploring choroidal angioarchitecture in health and disease using choroidal vascularity index. *Prog Retin Eye Res.* 2020;77:100829.
35. Corvi F, Su L, Sadda SR. Evaluation of the inner choroid using OCT angiography. *Eye (Lond).* 2021;35:110–120.
36. Zheng F, Chua J, Ke M, et al. Quantitative OCT angiography of the retinal microvasculature and choriocapillaris in highly myopic eyes with myopic macular degeneration. [published online ahead of print January 4, 2021]. *Br J Ophthalmol*, <https://doi.org/10.1136/bjophthalmol-2020-317632>.
37. Birol G, Wang S, Budzynski E, Wangsa-Wirawan ND, Linsenmeier RA. Oxygen distribution and consumption in the macaque retina. *Am J Physiol Heart Circ Physiol.* 2007;293:H1696–H1704.
38. Scarinci F, Nesper PL, Fawzi AA. Deep retinal capillary nonperfusion is associated with photoreceptor disruption in diabetic macular ischemia. *Am J Ophthalmol.* 2016;168:129–138.
39. Spaide RF. Retinal vascular cystoid macular edema: review and new theory. *Retina.* 2016;36:1823–1842.
40. Lam DS, Leung KS, Mohamed S, et al. Regional variations in the relationship between macular thickness measurements and myopia. *Invest Ophthalmol Vis Sci.* 2007;48:376–382.
41. Lim MC, Hoh ST, Foster PJ, et al. Use of optical coherence tomography to assess variations in macular retinal thickness in myopia. *Invest Ophthalmol Vis Sci.* 2005;46:974–978.
42. Wakitani Y, Sasoh M, Sugimoto M, et al. Macular thickness measurements in healthy subjects with different axial lengths using optical coherence tomography. *Retina.* 2003;23:177–182.
43. Anvari P, Ashrafkhorasani M, Habibi A, Falavarjani KG. Artifacts in optical coherence tomography angiography. *J Ophthalmic Vis Res.* 2021;16:271–286.

## APPENDIX

### **The GSHM study group**

#### *Principal investigators*

Xiulan Zhang, Yizhi Liu, Lin Lv, David Friedman, Jost B. Jonas, and Tin Aung.

#### *Clinical center*

Zhongshan Ophthalmic Center: Yizhi Liu, Xiulan Zhang, Lin Lv, Shida Chen, Wei Wang, Fengbin Lin, Yunhe Song, Fei Li, Kai Gao, Bingqian Liu, Yuhong Liu, and Meiling Chen.

#### *Coordinating center*

Zhongshan Ophthalmic Center: Xiulan Zhang.

#### *Steering Committee*

Neil M. Bressler, Ki Ho Park, Mingguang He, Kyoko Ohno-Matsui, and Robert N. Weinreb.

#### *Data Monitoring Committee*

Ching-yu Cheng, Paul Healey, and Linda M. Zangwill.

#### *Safety Supervision Committee*

Xiang Chen and Guangxian Tang.

#### *Biostatistics and Data Monitoring Center.*

Ling Jin