

UC Davis

Dermatology Online Journal

Title

A case of cutaneous nodules in a sporotrichoid pattern

Permalink

<https://escholarship.org/uc/item/3pq5k7cx>

Journal

Dermatology Online Journal, 25(3)

Authors

Esteves, Mariana
Nogueira, Ana
Azevedo, Filomena

Publication Date

2019

DOI

10.5070/D3253043341

Copyright Information

Copyright 2019 by the author(s). This work is made available under the terms of a Creative Commons Attribution-NonCommercial-NoDerivatives License, available at <https://creativecommons.org/licenses/by-nc-nd/4.0/>

Peer reviewed

A case of cutaneous nodules in a sporotrichoid pattern

Mariana Esteves MD, Ana Nogueira MD, Filomena Azevedo MD

Affiliations: Department of Dermatology and Venereology, Centro Hospitalar Universitário de São João EPE, Porto, Portugal

Corresponding Author: Mariana Esteves MD, Centro Hospitalar Universitário de São João EPE, Porto, Alameda Professor Hernâni Monteiro, 4200-319 Porto, Portugal, Tel: 351-22 551 2100, Email: mariana.cbesteves@gmail.com

Abstract

A sporotrichoid pattern describes a clinical presentation in which inflammatory nodules spread along the path of lymphatic drainage, being reported in association with several infectious, neoplastic, and inflammatory skin conditions. Herein, we report a 65-year-old man presenting with a three-month history of erythematous nodules in a linear distribution along the left hand and forearm. He reported recent rose gardening and regular contact with an aquarium. The diagnosis was made through culture of skin biopsy tissue and isolation of *Mycobacterium marinum*. The patient was treated with a combination of clarithromycin and rifampicin and clinical resolution was evident within two months. We present a patient with a sporotrichoid cutaneous infection by *Mycobacterium marinum*, highlighting that even with the availability of novel microbiological detection techniques, tissue culture remains an essential tool for diagnostic confirmation.

Keywords: sporotrichoid pattern, atypical mycobacteriosis, *Mycobacterium marinum*

Introduction

A sporotrichoid pattern, or nodular lymphangitis, describes a distinctive clinical presentation in which inflammatory nodules spread linearly along the path of lymphatic drainage. It is the classic manifestation of sporotrichosis caused by *Sporothrix schenckii*, but it can also result from cutaneous inoculation with *Mycobacterium*, *Leishmania*, or *Nocardia* species, as well as several other inflammatory and neoplastic conditions [1, 2].

Case Synopsis

A 65-year-old man presented to our department with a three-month history of cutaneous nodules spreading along the lateral aspect of his left hand and forearm. He recalled a rose thorn injury to the left thumb previous to the development of the lesions. He also reported recreational contact with an aquarium that he cleaned regularly. His medical history was only remarkable for arterial hypertension, for which he was taking medication. Before our visit, the patient had already been treated with several courses of antibiotics without improvement and was empirically medicated with itraconazole 200mg/day for the previous two weeks.

Physical examination revealed several erythematous nodules in a linear configuration from the left thumb to the middle third of the forearm (**Figure 1**). Laboratory parameters were within normal limits, except for a slightly increased alanine aminotransferase and alkaline phosphatase. Histopathological analysis of a skin biopsy revealed a dermal infiltrate of lymphocytes and plasma cells surrounding epithelioid granulomas (**Figure 2**) with central necrosis and giant multinucleated cells (**Figure 3**). Periodic acid-Schiff and Ziehl-Neelsen stains were negative. Nevertheless, the histological findings were compatible with a diagnosis of sporotrichosis. The patient continued treatment with itraconazole while waiting for the remaining microbiological test results.

Real-time polymerase chain reaction (PCR) performed on biopsy tissue was negative for all microorganisms tested, including *Sporothrix schenckii* and mycobacterial species. Routine cultures of the

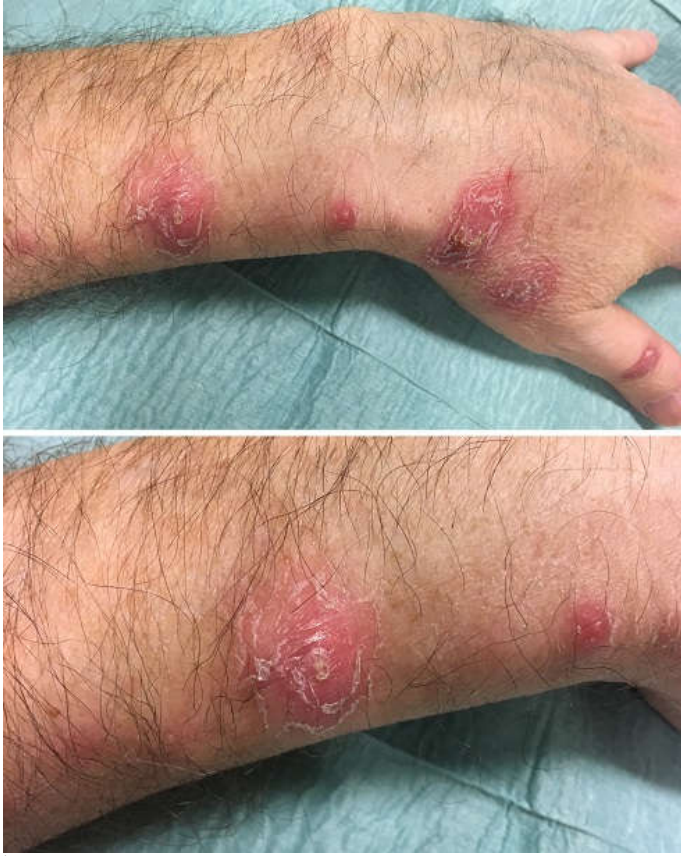

Figure 1. Multiple linear erythematous nodules along the lateral aspect of the left hand and forearm and close-up of one of the lesions.

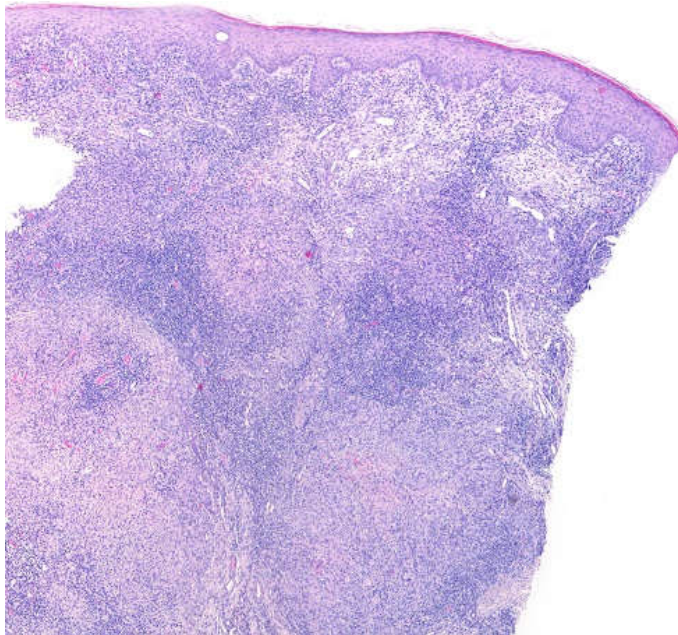


Figure 2. Confluent epithelioid granulomas in the dermis, surrounded by fibrosis and infiltration of lymphocytes and plasma cells (H&E, 40x).

biopsy specimen were negative for both bacterial and fungal infection. However, several weeks later, mycobacterial culture revealed a strain of *Mycobacterium marinum*, thus confirming the diagnosis of this atypical mycobacteriosis.

Antibiotic therapy was initiated with clarithromycin 500mg twice daily, to which rifampicin 600mg/day was added after normalization of hepatic analytical parameters. Complete resolution of the skin lesions was evident after two months of treatment and antibiotics were maintained until completing 6 months of therapy.

Case Discussion

Mycobacterium marinum is a slow-growing nontuberculous mycobacterium with a worldwide distribution in both fresh and salt water. Although being considered an endemic fish pathogen [3, 4], it causes infection in humans owing to contact with contaminated water, followed by bacterial inoculation onto traumatic breaks in the skin [5, 6]. Recently, it is often linked with aquarium maintenance, thus being known as “fish-tank granuloma” [7, 8].

The median incubation time is around three weeks, but it can be as long as 9 months [3, 9]. Owing to an optimal growth at 30-32°C, infection is generally localized to the skin where body temperature is slightly lower. It clinically presents as a solitary papulo-nodule at the inoculation site, commonly the hands and fingers, related to aquatic exposure and trauma [4, 7]. In 20% of patients, proximal extension of the infection through lymphocutaneous spread gives rise to a sporotrichoid pattern. Less frequently, the disease can progress to involve deeper structures, resulting in tenosynovitis, arthritis, or osteomyelitis [8].

Given its indolent nature and atypical clinical manifestations, diagnostic delay is common [6]. Our patient also reported exposure to different sources of infection and possible pathogens, thus increasing the dilemma. The main condition in the differential diagnosis in this case was with sporotrichosis, the

most common cause of nodular lymphangitis. In the appropriate clinical setting, cutaneous nocardiosis or leishmaniasis may need to be considered, as well as other bacterial, fungal, or protozoal infections [1, 2]. In rare cases, inflammatory dermatoses and neoplastic conditions, such as cutaneous lymphoma, squamous cell carcinoma, or keratoacanthoma can also present in a sporotrichoid pattern [2].

Histopathological examination is not particularly helpful in diagnosing this atypical mycobacteriosis [4]. It frequently reveals granulomatous inflammation, but this finding has poor specificity as it can mimic other infectious processes [3, 9]. An acid-fast bacilli stain is positive in a minority of cases [4, 8].

The use of molecular techniques to accelerate bacterial detection has been increasingly reported [9, 10]. However, real-time PCR appears to have low sensitivity in identifying nontuberculous mycobacterium [10, 11], which may relate to specific decontamination methods that reduce mycobacterial viability [11]. This may explain the false-negative result in our case. Therefore, culture of a cutaneous biopsy specimen on Löwenstein-Jensen media remains the gold-standard for laboratory diagnosis, being reported positive in 70 to 80% of cases [4, 7].

There are currently no formal guidelines of treatment for *Mycobacterium marinum* infection. Most commonly used agents include clarithromycin, ethambutol, and rifampicin [3]. Combination therapy is recommended in severe cases, as those with sporotrichoid distribution [4-6]; treatment should be maintained for a minimum of two months after lesions have healed [1, 7]. Adjunctive surgical

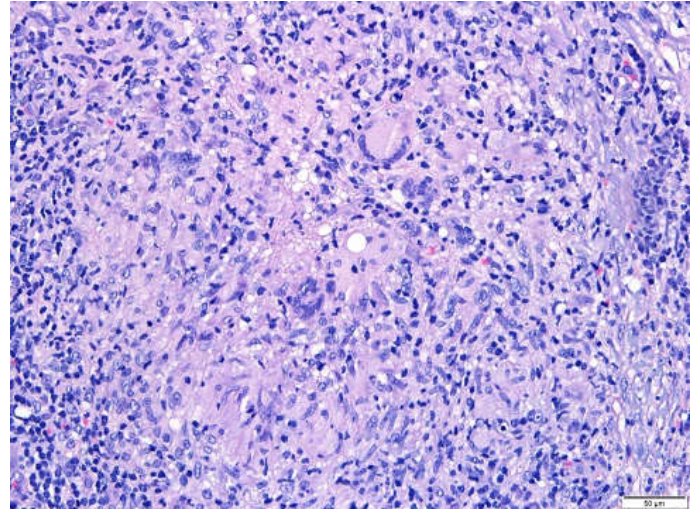


Figure 3. Visualization of giant multinucleated cells at higher magnification (H&E, 100x).

treatment is reserved for cases of deeper infections with subcutaneous involvement [8].

Conclusion

In summary, we present a case of a sporotrichoid cutaneous infection by *Mycobacterium marinum*. A detailed history is essential in order to establish a presumptive diagnosis, but exposure to different sources of infection can sometimes be a confounding factor and an important cause of diagnostic delay. This case also highlights that sophisticated microbiological detection techniques are not entirely infallible and mycobacterial culture still remains essential in many cases.

Potential conflicts of interest

The authors declare no conflicts of interests.

References

- Giordano CN, Kalb RE, Brass C, Lin L, Helm TN. Nodular lymphangitis: Report of a case with presentation of a diagnostic paradigm. *Dermatol Online J.* 2010;16(9):1. [PMID: 20875322].
- Abudu B, Cohen PR. Sporotrichoid Keratoacanthomas: Case Report and Review of Neoplasms Presenting in a Sporotrichoid Pattern. *Cureus.* 2018;10(8):e3196. [PMID: 30402364].
- Johnson MG, Stout JE. Twenty-eight cases of *Mycobacterium marinum* infection: retrospective case series and literature review. *Infection.* 2015;43(6):655-62. [PMID: 25869820].
- Bonamonte D, De Vito D, Vestita M, et al. Aquarium-borne *Mycobacterium marinum* skin infection. Report of 15 cases and review of the literature. *Eur J Dermatol.* 2013;23(4):510-6. [PMID: 24002023].
- Veronese F, Zavattaro E, Farinelli P, Colombo E, Savoia P. An unusual cutaneous infection caused by *Mycobacterium marinum*. *JMM Case Rep.* 2017;4(4):e005088. [PMID: 29026615].
- di Meo N, Stinco G, Trevisini S, et al. Sporotrichoid *Mycobacterium marinum* infection in an elderly woman. *Dermatol Online J.* 2015;21(5):11. [PMID: 26295859].
- Aubry A, Mougari F, Reibel F, Cambau E. *Mycobacterium marinum*. *Microbiol Spectr.* 2017;5(2). [PMID: 28387180].
- Gonzalez-Santiago TM, Drage LA. Nontuberculous Mycobacteria

- Skin and Soft Tissue Infections. *Dermatol Clin*. 2015;33(3):563-77. [PMID: 26143432].
9. Sia TY, Taimur S, Blau DM, et al. Clinical and Pathological Evaluation of *Mycobacterium marinum* Group Skin Infections Associated with Fish Markets in New York City. *Clin Infect Dis*. 2016;62(5):590-5. [PMID: 26673347].
 10. Park JS, Choi JI, Lim JH, et al. The Combination of Real-Time PCR and HPLC for the Identification of Non-Tuberculous Mycobacteria. *Ann Lab Med*. 2013;33(5):349-52. [PMID: 24003425].
 11. Kim JU, Ryu DS, Cha CH, Park SH. Paradigm for diagnosing mycobacterial disease: direct detection and differentiation of *Mycobacterium tuberculosis* complex and non-tuberculous mycobacteria in clinical specimens using multiplex real-time PCR. *J Clin Pathol*. 2018;71(9):774-80. [PMID: 29559518].