

**UCLA**

**UCLA Electronic Theses and Dissertations**

**Title**

Short-term (3-Month) Clinical Outcomes of WaterLase (iPlus) Laser Therapy used as an Adjunct to Non-Surgical Treatment of Chronic Periodontitis: A Randomized, Controlled, Within-Mouth Clinical Study

**Permalink**

<https://escholarship.org/uc/item/3p09h0j1>

**Author**

Raz, Galya

**Publication Date**

2016

Peer reviewed|Thesis/dissertation

UNIVERSITY OF CALIFORNIA

Los Angeles

Short-term (3-Month) Clinical Outcomes of WaterLase (iPlus) Laser Therapy used as an  
Adjunct to Non-Surgical Treatment of Chronic Periodontitis:  
A Randomized, Controlled, Within-Mouth Clinical Study

A thesis submitted in partial satisfaction of the  
requirements for the degree Master of Science in  
Oral Biology

by

Galya Raz

2016



## ABSTRACT OF THE THESIS

Short-term (3-Month) Clinical Outcomes of WaterLase (iPlus) Laser Therapy used as an  
Adjunct to Non-Surgical Treatment of Chronic Periodontitis:  
A Randomized, Controlled, Within-Mouth Clinical Study

by

Galya Raz

Master of Science in Oral Biology

University of California, Los Angeles, 2016

Professor Perry Klokkevold, Chair

Chronic periodontitis is a multifactorial, inflammatory disease that, when left untreated, results in the destruction of tooth-supporting structures including adjacent bone. Laser therapy as an adjunct to non-surgical therapy for treatment of moderate-severe chronic periodontitis has been increasingly advocated yet controversial and experimental evidence has not yet convincingly supported the use of laser treatment. **Objective:** The aim of this randomized, controlled clinical study was to examine the clinical efficacy of laser therapy (Er,Cr:YSGG) as an adjunct to scaling and root planing (SRP) in comparison to conventional non-surgical periodontal therapy alone 3 months after therapy in patients with chronic periodontitis. **Materials & Methods:** Eighteen matched and paired quadrants were evaluated in five patients and randomly treated by SRP

alone (control group) or by SRP + Laser (test group). Clinical measurements (PPD, CAL, REC, BOP, PI) were recorded before treatment at baseline and at 3 months following treatment. Subgingival plaque samples of one patient were taken at baseline and 3 months after treatment and were evaluated for changes using DGGE. **Results:** Non-surgical treatment and subsequent healing and follow-up was uneventful in all cases. Baseline values for PD, REC, CAL, BOP and PI were not significantly different between the test and control groups ( $p < 0.05$ ) and baseline quadrant means for PD, REC and CAL for the test and control treated quadrants presented with similar measures of  $3.7 \pm 1.7$  mm and  $3.6 \pm 1.5$  mm,  $0.3 \pm 0.9$  mm and  $0.3 \pm 0.6$  mm,  $4.1 \pm 2.0$  mm and  $3.8 \pm 1.7$  mm, respectively. Values for PD, REC, CAL, BOP and PI improved significantly 3 months after treatment in both test and control groups. Three month analysis of laser treated quadrants revealed a mean PD reduction of  $0.8 \pm 1.3$  mm, a mean REC increase of  $0.3 \pm 0.7$  mm, and a mean gain in CAL of  $0.5 \pm 1.4$  mm. Evaluation of control quadrants at 3 months revealed a mean PD reduction of  $0.6 \pm 1.1$  mm, a mean REC increase of  $0.2 \pm 0.7$  mm, and a mean gain in CAL of  $0.3 \pm 1.4$  mm. No significant differences were detected between the laser and control treated quadrants. No significant differences in PD, REC, CAL, BOP or PI outcomes could be detected between the test and control groups ( $p < 0.05$ ). Sites where treatment was not indicated (non-qualifying sites) showed statistically significant improvement in PD only. **Conclusions:** Within the limitations of the present study, adjunctive laser therapy (Er,Cr:YSGG, RePaiR protocol) does not show significant advantages to conventional non-surgical therapy alone.

The thesis of Galya Raz is approved.

Renate Lux

Sanjay Mallya

Perry Klokkevold, Committee Chair

University of California, Los Angeles

2016

## TABLE OF CONTENTS

Abstract.....	ii
List of Figures.....	vi
List of Tables.....	vii
Acknowledgements.....	viii
Introduction, Background, and Significance.....	1
Materials and Methods.....	8
Results.....	15
Discussion.....	19
Conclusion and Future Direction.....	25
Figures.....	26
Tables.....	35
Appendix 1.....	40
Appendix 2.....	41
Appendix 3.....	42
References.....	44

## LIST OF FIGURES

Figure 1. Laser Absorption Graph for various lasers used in periodontics [30].....	26
Figure 2a. Clinical case example - REPaIR Protocol.....	27
Figure 2b. Clinical comparison of soft tissue appearance for SRP + Laser treated quadrant at baseline, 1- and 3-months following treatment.....	28
Figure 2c. Clinical comparison of soft tissue appearance for SRP treated quadrant at baseline, 1- and 3-months following treatment.....	29
Figure 2d. Full mouth radiographs corresponding to clinical case in Figures 1a-c.....	30
Figure 3a. DGGE Profile Subject #2, before-treatment (a) 3-months post-treatment (b).....	31
Figure 3b. Close-up of DGGE Profile Subject 2, Sample 6 (Control treated site).....	32
Figure 4. Qualifying Sites, Clinical Parameters, Bar Graphs: Baseline and 3-months following therapy.....	33
Figure 5. Test and control quadrants, Clinical Parameters, Bar Graphs: Baseline and 3-months following therapy.....	34



## LIST OF TABLES.

Table 1. Mean values for clinical parameters of laser treated sites and quadrants.....	35
Table 2. Mean values for clinical parameters of control treated sites and quadrants.....	36
Table 3. Mean values for clinical parameters of non-treated sites.....	37
Table 4. Bleeding on probing and plaque index of laser and control treated quadrants.....	38
Table 5. Distribution of total treated sites and quadrants by patient.....	39

## **ACKNOWLEDGEMENTS**

This project would not have been possible without the help and support of several individuals. Special thanks to my advisor, Dr. Perry Klokkevold, who dedicated substantial time and effort in helping me to develop this project. Great thanks to my committee members, Dr. Renate Lux who supported and guided the microbiological portion of this study, and Dr. Sanjay Mallya who supported and guided the radiological aspects of this study. Without all of their help this project would not have come to fruition. I would also like to thank Dr. Samuel Low and Biolase who helped make this research possible through their generous assistance in obtaining the necessary training and equipment for this project.

## **Introduction, Background and Significance**

Chronic periodontitis is a highly prevalent and often destructive inflammatory disease that results in the destruction of tooth supporting tissues including bone. If left untreated, periodontitis can lead to progressive bone loss causing an increase in tooth mobility and eventual loss of the teeth affected. Periodontitis results from a series of events revolving around bacteria, the host immune inflammatory response and environmental factors [1]. It is frequently initiated by poor oral hygiene and a subsequent alteration in the bacterial population from a primarily gram-positive, aerobic population to a primarily gram-negative, anaerobic one [2]. The progressive destruction of tooth supporting structures is a result of the host's response to the pathogenic bacterial flora and the release of endotoxin leading to the induction of osteoclast-related mediators that target destruction of connective tissue and alveolar bone at sites of disease [3]. While in its early stages periodontal disease remains virtually symptom free, as the disease progresses alterations in the color and texture of gingival tissue become overt and loss of bone is visualized on radiographic examination [4]. Clinically, periodontal disease may be detected through an increase of bleeding on probing (BOP), pocket depth (PD), gingival recession (REC) and in later stages, increased tooth mobility and possibly tooth loss [5].

The treatment of chronic periodontitis involves both professional care and home maintenance. The primary goals of periodontal treatment are to eliminate calcified bacterial deposits as well as disrupt and remove bacterial biofilm while removing the smear layer present on the roots in order to restore the periodontal tissues to health [6].

There are numerous factors that potentially influence the extent of periodontal healing but the ultimate desired outcome is regeneration of the periodontal tissues including bone, periodontal ligament and connective tissue attachment [7].

Following patient education and reinforcement of oral hygiene, the first step in rendering treatment of chronic periodontitis is usually non-surgical therapy in the form of mechanical debridement using ultrasonic instruments and hand scalers, termed scaling and root planing (SRP) [8]. The objectives of treatment are to reduce the bacterial load (biofilm), resolve inflammation and create a clinical environment that is compatible with periodontal health and typically results in improvement of clinical measures with improvements in PD, REC, CAL and BOP [8]. While regeneration of periodontal tissues is possible with conventional scaling and root planing, the primary mode of healing observed in teeth treated with SRP is reduction of the periodontal pocket by formation of a long junctional epithelium, a form of healing that occurs without new cementum nor the insertion of connective tissue fibers to the adjacent diseased root surface [9]. Even so, SRP remains the gold standard in non-surgical treatment of periodontal disease. However, it is not without limitations, which include inadequate access and treatment of anatomically challenging areas such as furcations, grooves and deep pockets [10].

Over the past several years, considerable interest has grown surrounding laser treatment as an adjunctive tool in non-surgical therapy due to its reported ability to perform tissue ablation, provide hemostasis, eliminate bacteria and detoxify root surfaces [11]. Several different lasers have been advocated for adjunctive periodontal

therapy including erbium, chromium-doped: yttrium-scandium-gallium garnet (Er,Cr:YSGG). While this and other lasers including diodes, carbon dioxide (CO<sub>2</sub>), neodymium-doped:yttrium-aluminum-garnet (Nd:YAG), and erbium-doped:yttrium-aluminum-garnet (Er:YAG) have been repeatedly evaluated, lack of homogeneity and clinically relevant results across studies has made it challenging to draw large scale and meaningful recommendations for treatment [11]. Differences between the laser wavelengths and treatment modalities may also complicate the discussion of laser use in adjunctive therapy as a result of their differing effects on tissues being treated. For example the diode, CO<sub>2</sub> and Nd:YAG lasers are associated with increased thermal side effects [11] when used on hard tissues such as root surfaces and bone when compared to erbium lasers [12]. These differences may impact wound healing and clinical outcomes depending on the laser utilized. In other words, each laser comes with its own indications and potential outcomes, therefore conclusions that are relevant to one specific laser may not be applicable to another.

Adjunctive laser therapy is being utilized in three primary ways including: 1) photodynamic therapy, 2) low-level laser therapy (LLLT) and 3) high-level laser therapy. Photodynamic therapy is a technique used to target pathogens with the use of photoactive dyes that become excited to produce singlet oxygen species which are cytotoxic and destructive to bacteria [16]. Low-level laser therapy (LLLT) does not cut or ablate tissue but rather stimulates cells through photo-biomodulation processes [17]. Low-level lasers have been shown to alter intra-cellular photoreceptors such as cytochrome c-oxidase in the respiratory chain and thus alter cellular functions [17].

High-level laser therapy (HLLT) is the most common form of adjunctive therapy utilized with non-surgical periodontal treatment [15]. Effects of high-level lasers include coagulation and ablation of soft tissue and removal of hard tissue and deposits in addition to the reduction of microbial loads which may provide clinical advantages where complete removal of debris and disinfection is not always achieved with conventional mechanical therapy.

In vitro studies evaluating adjunctive laser therapy have shown potential advantages with improved root surface decontamination, reduction in microbiota, reduced inflammatory markers and biomodulation of immune cell activity [11]. However, reports of clinical advantages to adjunctive laser treatment have been limited and many studies have shown limited significant long-term advantages [11] though few studies report clinical findings beyond the short-term healing period. Several studies, systematic reviews and meta-analyses reporting on a variety of adjunctive laser types and therapies compared with mechanical debridement alone have shown limited differences between test and control groups [11, 13, 14]. As recently as 2015, the Journal of the American Dental Association reported that only photodynamic therapy (PDT) using diode lasers as an adjunct to SRP was a favorable use of adjunctive laser therapy though the evidence supporting its use is limited and it should only be used after other alternatives have been considered [13, 14]. For all other modalities of adjunctive laser therapies (LLL and HLLT) including those using diode, Nd:YAG and erbium lasers the authors reported a lack of evidence and a low level of certainty due to limited studies and variability in study design, preventing them from recommending these therapies be

employed. With this in mind, it is important to consider that, due to the variability of study design and limited follow-up, research investigating adjunctive laser therapy is lacking and needs to be further strengthened. Similarly, few studies have evaluated the ability for adjunctive laser therapy to enhance non-surgical regenerative outcomes from baseline.

Several studies have been published investigating the non-surgical effects of Er:YAG, Nd:YAG, diode and CO<sub>2</sub> lasers. While the Er,Cr:YSGG laser is used in dentistry and periodontics, it has not had the same degree of experimental scrutiny and analysis as other common lasers. The Er,Cr:YSGG laser is very similar in design and characteristics to the Er:YAG laser with the Er,Cr:YSGG wavelength being 2,780 nm and the Er:YAG wavelength being 2,940 nm. Both have similar absorption profiles (Figure 1) and show comparable physical and biological alterations in hard and soft tissue, and have clinically commensurate properties [15]. Additionally, both Er:YAG and Er,Cr:YSGG lasers are frequently reported as the safest and most efficient lasers used in dentistry [24]. Due to their high interaction rates with water, both erbium lasers are the most suited for hard-tissue ablation treatments [11, 15, 24]. However, differences between the two lasers are present and include the Er,Cr: YSGG laser being more highly absorbed by hydroxide ions (OH) than by water molecules [24]. Several animal and in vitro studies have suggested that the Er,Cr:YSGG laser may be associated with increased bone regeneration in diseased sites [20, 25]. While several human studies have reported incidences of bone regeneration with radiographic analysis, the standardization of the radiographs in these reports is often questionable and the

number of studies evaluating the effects of Er,Cr:YSGG in humans is limited [25]. A review of the literature also revealed that the advantages of Er,Cr:YSGG lasers have not yet been completely elucidated.

Several adjunctive treatment regimens have been evaluated with a significant amount of heterogeneity present in laser types, use and settings. Few have evaluated the clinical efficacy of a treatment protocol developed for a specific laser, more specifically the Er,Cr:YSGG with a wavelength of 2780 nm (REPaIR, Biolase, Inc. CA), with the intention of providing periodontal regeneration as a long-term clinical outcome. In this study, we will examine whether adjunctive laser therapy of a specific protocol utilizing Er,Cr:YSGG laser provides an advantage to conventional mechanical therapy (SRP) 3-months following non-surgical therapy. Information collected for this study will be applied to subsequent evaluations, with the ultimate goal of identifying whether adjunctive laser therapy provides added benefit in long-term periodontal health with improved regenerative capabilities.



## **Hypothesis**

The use of Er,Cr:YSGG laser therapy as an adjunct to non-surgical scaling and root planing will enhance the short-term (3-month) clinical treatment outcomes for patients with moderate to severe chronic periodontitis.

## **Specific Aims**

The specific aims of this study were to:

1. Evaluate the effect of adjunctive laser (Er,Cr:YSGG) therapy on short-term (3-months) periodontal disease resolution using clinical parameters to assess improvement in periodontal health.
2. Assess the changes in microbiota following SRP with or without adjunctive laser therapy.

## **Materials and Methods**

### *Human Subjects and Privacy*

This study was submitted to and approved by the UCLA Human Research Protection Program (HRPP). IRB# 15-00519.

### *Study Design/Sample*

This study was a single center, prospective randomized, controlled, within mouth study. The study population was derived from patients presenting to the study site with moderate to severe chronic periodontitis affecting at least two quadrants, each with two or more sites probing  $\geq 5$ mm and radiographic evidence of interproximal intrabony defects. The study site for this project was the Postgraduate Periodontics and Implant Surgery Clinic at the UCLA School of Dentistry. All treatments and follow-up evaluations were performed by a single-operator who was a third-year postgraduate periodontal resident (GR).

### Inclusion criteria:

- Age 18 years old or older (male or female)
- Healthy without systemic diseases that may adversely affect healing
- Not pregnant and no current plans to become pregnant
- No periodontal treatment in the previous 12 months
- No systemic antibiotic therapy in the previous 3 months
- At least two quadrants with chronic periodontitis (ideally opposite side same jaw)
- Each quadrant must have two or more sites with probing pocket depths  $\geq 5$ mm
- Presence of interproximal intrabony defect(s)

Exclusion criteria:

- Any systemic disease, medication, or habit known to adversely influence bone metabolism and/or wound healing:
  - Poorly controlled diabetes (HbA1c > 7%)
  - History of bisphosphonate medications
  - History of radiation therapy affecting the proposed treatment site(s)
  - History of immunosuppressive medications (e.g. corticosteroids)
  - History of tobacco use (current or past tobacco use within the past 1 year)
  - Immune compromise caused by disease, treatment or other condition
- Recent history of periodontal surgery (within the previous 2 years)
- Recent history of scaling and root planing (within the previous 1 years)
- Any condition that contraindicates periodontal therapy including surgery

Instrumentation:

The laser to be used in this protocol is the Waterlase iPlus Er,Cr:YSGG laser manufactured by Biolase (Irvine, California, USA). Laser specifications as described by the manufacturer are reported in Appendix 1.

A training session offered by Biolase and The World Congress for Laser Instruction (WCLI) for the use of the Waterlase® iPlus Er,Cr:YSGG laser with the REPaIR protocol was completed by all investigators participating in this study.

A UNC-15 periodontal probe was used in this study to evaluate the clinical parameters. It has markings in 1 mm increments up to 15 mm.

Non-surgical instrumentation included the use of a Symmetry IQ 3000 Piezo Scaler (Hu-Friedy) with fiber optic light and various tips, as well as Universal and Gracey curettes (Hu-Friedy).

Following a thorough review of the patient's health history, clinical and radiographic examination, qualified subjects signed an informed consent to be enrolled in the study. Treatment was randomly assigned to quadrants and implemented according to the following standardized protocol:

1. Participants were provided with oral hygiene aids and received standardized oral hygiene instructions.
2. One week following oral hygiene instruction participants returned for collection of baseline clinical data including:
  - a. Plaque index (%)
  - b. Bleeding on probing (%)
  - c. Probing pocket depth
  - d. Gingival recession
  - e. Clinical attachment levels (calculated)
3. Each qualifying quadrant was randomly assigned to scaling and root planing alone or scaling and root planing with adjunctive laser treatment.

4. At the time of treatment, occlusal contacts were evaluated and appropriate occlusal adjustments made if deemed necessary (i.e. adjustment of occlusal interferences and/or fremitus).
5. Each quadrant was treated, according to assigned group.
6. A plaque sample (biofilm) was collected from selected sites in each qualifying quadrant prior to treatment for microbial analysis. This was repeated at the 3-month re-evaluation appointment.
7. Subjects were instructed to keep a record of the type and amount of analgesics taken and were asked to report on their post-treatment comfort at each follow-up visit (Appendix 2).
8. Subjects were re-examined at 3 months after therapy.
9. Periodontal recall maintenance was provided following the re-examination at the 3-month visit. Oral hygiene instructions were reinforced at each visit.
10. Radiographic imaging (intraoral digital periapical radiograph and cone beam computed tomography scan) were taken of each quadrant/treatment site at baseline (Figure 2d).

Subjects with at least two qualifying quadrants were enrolled in the 3-month re-examination. All qualifying quadrants were randomly assigned to one of the two treatment groups (control or test) and the contralateral quadrant was assigned to the other group. Every subject had at least one quadrant assigned to the control group and one quadrant assigned to the test group and thus served as their own control. Each additional qualifying quadrant in the same individual was assigned to the next treatment

group (i.e. if the second quadrant was assigned to the test group, then the third quadrant was assigned to the control group and the fourth quadrant was assigned to the test group). All treatment was completed with local anesthesia.

Group 1 (control):

- Non-surgical, mechanical scaling and root planing with hand instruments and ultrasonic device (Figure 2c).

Group 2 (test):

- Non-surgical, mechanical scaling and root planing with hand instruments and ultrasonic device including the use of adjunctive WaterLase iPlus (Er,Cr:YSGG) laser therapy according to the following REPaIR protocol. (See Appendix 3, Figure 2a, Figure 2b).

All patients were provided with specific oral hygiene instructions. From day two until day seven, patients were instructed to brush with a manual soft or extra-soft toothbrush and to use interproximal cleaning aids. Patients returned for postoperative evaluation at week 2 and months 1 and 3.

Supportive periodontal therapy (recall maintenance cleanings) was completed following re-examination at 3 months following treatment. Recall maintenance therapy was limited to supragingival scaling and prophylaxis.

### *Data Collection*

Data was collected in a standardized, de-identified fashion and stored in a locked file cabinet at the study site. Data was entered into a password-protected database.

### *Clinical Measurements*

The following clinical measurements were recorded at the initial baseline examination and 3 months after treatment:

- Probing depth (PD) at six sites for each tooth
- Bleeding on probing (BOP) at six sites for each tooth
- Gingival recession at six sites for each tooth
- Clinical attachment level (CAL) at six sites for each tooth (calculated)
- Plaque index % (calculated)
- Bleeding on probing % (calculated)

### *Data Analysis*

Data analyses were conducted using the Prism 7 Software (GraphPad Inc., California, USA). Comparisons of mean PD, REC, CAL, BOP and PI at 6 sites per tooth were made using paired t-tests for within group comparisons and unpaired t-tests between test and control groups. Mean PD, REC, CAL, BOP, PI and standard deviations were calculated for the test and control quadrants and sites for baseline and 3-months following treatment.

Each patient's plaque samples were evaluated using denaturing gradient gel electrophoresis (DGGE) to resolve PCR amplicons derived from the microbial community using universal primer pairs that amplify a specific region of the 16S rRNA encoding gene according to their molecular weight. Following electrophoresis, bands are cloned and sequenced for species identification. Fingerprinting by DGGE provides information about microbial populations and changes can be monitored over time and across treatments (28).



## Results

A total of 5 patients (3 men and 2 women) diagnosed with moderate-to-severe chronic periodontitis in at least two quadrants were included in this study with a total of 18 qualifying quadrants randomized to Group 1 (SRP) and Group 2 (Laser + SRP). The mean age of patients was  $50.2 \pm 10.3$  years. A total of 80 sites were assigned to Group 1 and 90 sites assigned to Group 2 (Table 5). All treatments were well tolerated by the patients and no treatment complications were observed. All patients received 800 mg ibuprofen and 500 mg acetaminophen PO immediately following treatment and all patients denied taking any additional pain medications at home after treatment was rendered. Patient reported outcomes immediately following treatment included sensitivity to hot and cold. At the 3-month examination, all patients denied any persistent thermal sensitivity and reported generalized improvement in chewing comfort and overall satisfaction with their gingival health.

In addition to patient reported outcomes, clinician observations were noted with respect to the laser and its efficacy. The most frequently observed intraoperative finding was the apparent improved ability to remove calculus and degranulate sites treated with the laser. This may be attributed to the Er,Cr:YSGG laser's ability to dehydrate calculus as a result of its interactions (absorption) primarily with water, which may facilitate the separation of calculus from the root surface.

At baseline, similar mean PD, REC and CAL were observed for all test and control quadrants/sites with no significant differences identified between the two groups

( $p < 0.01$ ). Baseline quadrant mean PD, REC and CAL for the test and control treated quadrants were  $3.7 \pm 1.7$  mm and  $3.6 \pm 1.5$  mm,  $0.3 \pm 0.9$  mm and  $0.3 \pm 0.6$  mm,  $4.1 \pm 2.0$  mm and  $3.8 \pm 1.7$  mm, respectively (Tables 1, 2). Baseline qualifying site mean PD, REC and CAL for test and control sites were  $6.2 \pm 1.3$  mm and  $5.8 \pm 1.3$  mm,  $0.5 \pm 1.2$  mm and  $0.3 \pm 0.6$  mm,  $6.5 \pm 2.0$  and  $6.0 \pm 1.7$ , respectively (Tables 1, 2). No statistically significant differences were detected at baseline between Group 1 and Group 2 ( $p < 0.05$ ).

Baseline evaluation of full-mouth series (FMX) and cone beam computed tomography (CBCT) examinations of patients showed all patients having moderate-severe chronic periodontitis affecting at least two quadrants (Figure 2d). All patients presented with at least one vertical defect extending to at least the middle third of the roots of the teeth involved as well as furcation bone loss of at least one molar. Calculus was also noted when visualized during FMX and CBCT analysis. All other structures including bone, soft tissues, airway and paranasal sinuses appeared normal where visualized.

All quadrants and sites (test and control) demonstrated significant reductions in PD, REC, CAL, BOP and PI ( $p < 0.01$ ). Three month analysis of laser treated quadrants revealed a mean PD reduction of  $0.8 \pm 1.3$  mm, a mean REC increase of  $0.3 \pm 0.7$  mm, and a mean gain in CAL of  $0.5 \pm 1.4$  mm. Evaluation of control quadrants at 3 months revealed a mean PD reduction of  $0.6 \pm 1.1$  mm, a mean REC increase of  $0.2 \pm 0.7$  mm,

and a mean gain in CAL of  $0.3 \pm 1.4$  mm. No significant differences were detected between the laser and control treated quadrants ( $p < 0.01$ ).

Further analysis by site was performed and revealed at 3 months following non-surgical therapy that laser treated qualifying sites had a mean PD reduction of  $2.3 \pm 1.5$  mm, a mean REC increase of  $0.6 \pm 0.9$  mm and a mean gain in CAL of  $1.7 \pm 1.8$  mm. The control treated qualifying sites had a mean PD reduction of  $2.1 \pm 1.2$  mm, a mean REC increase of  $0.6 \pm 0.1$  mm and a mean gain in CAL of  $1.5 \pm 1.8$  mm (Tables 1, 2). No significant differences were detected between the outcomes of the laser and control treated sites ( $p < 0.01$ ).

Analysis of non-qualifying (non-treated) sites revealed baseline means of PD, REC and CAL to be  $2.8 \pm 0.6$  mm,  $0.5 \pm 0.9$  mm and  $3.1 \pm 1.0$  mm respectively. At 3-months the mean PD, REC and CAL of non-qualifying sites were observed to be  $2.6 \pm 0.5$  mm,  $0.4 \pm 0.7$  and  $3.2 \pm 1.1$  respectively. Only the change in PD ( $-0.2 \pm 0.5$  mm) was observed to be statistically significant ( $p < 0.01$ ). Data for clinical parameters across quadrants and sites are presented in Tables 1, 2 and 3 and Figures 4 and 5.

Improvements in BOP and PI were observed between baseline and 3 months and were statistically significant within the test and control sites and quadrants ( $p < 0.01$ ). Baseline BOP of control sites was 81.2% and reduced to 21.2% at 3-months. Laser treated sites showed initial BOP of 71.1% at baseline and 20.0% 3-months following treatment. Baseline plaque levels for control sites was found to be 76.2% at baseline

and 13.7% 3-months following treatment. Laser treated sites presented with 82.2% plaque prior to treatment and reduced to 21.1% at the 3-month examination. No significant differences were observed when comparisons were made between test and control treated sites/quadrants ( $p < 0.01$ ) (Table 4).

DGGE analysis of plaque samples from one patient was initially performed and showed apparent changes in all sites from baseline to 3 months. One site that did not yield sufficient DNA for extraction at both baseline and the 3-month re-evaluation. For all other sites sampled, several new bands appeared that were not present at baseline in addition to several bands that disappeared. This shows an apparent change in the bacterial composition following both test and control treatments. However, further analysis is required to identify the bacteria present at baseline and 3 months following treatment and evaluate significance of changes observed especially between test and control-treated quadrants or sites. (Figure 3a-b).

## Discussion

Adjunctive laser treatment to non-surgical periodontal therapy has grown significantly over the past two decades. Several types of lasers and techniques have been investigated. The most common and frequently used lasers in periodontics include diode, CO<sub>2</sub>, Nd:YAG and erbium lasers [15]. All of these lasers have been investigated for use in 1) photodynamic therapy, 2) low-level laser therapy (LLLT) and 3) high-level laser therapy and all three modalities have been shown to have positive impacts on certain aspects of periodontal treatment with in vitro studies but little clinical relevance has been shown in human studies [15].

Photodynamic therapy, like other laser therapies, is a non-specific process and has been shown to be effective in the reduction of bacterial species in vitro [16]. However, a meta-analysis of clinical studies evaluating the use of PDT as an adjunct to SRP revealed that it was not superior to control treatment and therefore, could not be recommended in the clinical management of periodontitis [16]. Similar to our study, adjunctive PDT has shown comparable effects to conventional treatment yet, due to a lack of homogeneity in study design it can be challenging to draw any concrete recommendations for its use. Even so, the present study did show alterations in microbiological outcomes in both test and control sites though further analysis is warranted to be able to compare traditional PDT to HLLT with respect to microbiological outcomes.

Low-level laser therapy (LLLT) does not cut or ablate tissue but rather stimulates cells through photo-biomodulation processes [17]. Low-level lasers function in the milliwatt range with wavelengths usually in the red and near-infrared spectrum and can be used to alter intra-cellular photoreceptors such as cytochrome c-oxidase in the respiratory chain [17]. The absorption of low-level lasers leads to a cascade of events that may have advantageous effects on periodontal healing such as increased cell metabolism and collagen synthesis by fibroblasts as well as increases in leukocyte activity and release of growth factors as observed in vitro [17]. Several clinical studies evaluating low-level laser therapy have shown reduction in periodontal inflammation but, as observed in this present study, no significant differences have been observed in clinical outcomes when compared to conventional SRP [15]. Similar to PDT, recommendations cannot be made as to its use in the clinical management of chronic periodontitis due to lack of sufficient data and heterogeneity in study designs. With this in mind, it is important to note that the present study did potentially provide patients with a concomitant dose of LLLT secondary to the HLLT provided. The true effects of LLLT as a result of HLLT should be further investigated and may warrant a separate study evaluating cellular modulation and activity.

High-level laser therapy (HLLT) can induce various degrees of thermal effects on tissue and is the most common form of adjunctive therapy utilized with non-surgical periodontal treatment [15]. HLLT includes coagulation and ablation of soft tissue and removal of hard tissue and deposits in addition to the reduction of microbial loads. Low level energy penetration is produced simultaneously with HLLT and has the potential to

stimulate tissues and cells without producing irreversible changes potentially enhancing the healing process [15]. The primary effects high-level laser therapies can provide that the previous modalities discussed cannot include removal of bacterial biofilm and deposits as well as decontamination of periodontal pockets and root surfaces in a non-surgical manner as a result of their ablation abilities and consequently their strong bacteriocidal and detoxification effects [15]. These aspects of HLLT may provide clinical advantages in sites where, due to anatomical complexities such as deep periodontal pockets, furcation sites and grooves, complete removal of debris and disinfection is not always achieved with conventional mechanical therapy or the use of alternative forms of laser therapy (PDT and LLLT).

Several studies have suggested an enhanced ability for healing by regeneration of periodontal supporting structures when adjunctive laser therapy is utilized. A handful of animal and human studies involving Nd:YAG [18], diode [19], and erbium [20] lasers have shown potential in the ability for regeneration of periodontal structures with adjunctive laser treatment. However, due to limited sample size and the difficulty in assessing histological aspects of regeneration in humans, there has not been a consensus or recommendation for use of laser therapy specifically for the regeneration of periodontal tissues as adjunctive treatment. Several animal studies have been published discussing the regenerative abilities of Er,Cr:YSGG lasers with respect to bone formation [20, 21]. One small clinical study was published with histological analysis showing potential with Nd:YAG laser treatment for regeneration of periodontally diseased teeth [18] and a small number of studies have reported on erbium lasers

showing some evidence of periodontal regeneration in a small number of cases [22, 23]. While these studies show promise, small sample sizes and limited standardization of clinical and radiographic results limit the ability to expand the findings and make recommendations for adjunctive laser treatment. Moreover, periodontal regeneration has been observed and documented in conventional mechanical non-surgical therapy though results may be limited and defined by the ability for a clinician to access and instrument the affected root surface appropriately [6]. One of the limitations of the current study is the short follow-up period and the lack of measures to assess periodontal regeneration. Even so, future comparison of baseline CBCT scans and subsequent longer term (6 and 12 month) imaging may provide a minimally invasive approach to document periodontal regeneration and has the potential to provide tangible evidence for the regenerative potentials of adjunctive laser therapy.

While there are over 300 studies evaluating adjunctive laser therapy in all modalities, the overarching consensus is that no significant clinical benefits are incurred when lasers are employed with conventional non-surgical therapy [11, 15]. Even though the study reported here presented with a small sample size and limited follow-up after initial therapy these short-term clinical results are consistent with previous studies and similar conclusions can be drawn. Within the limits of this study, significant differences were observed in clinical measures between baseline and 3-months after treatment. However, no significant differences were found between the test and control groups when analysis was performed comparing quadrants and specific qualifying sites.



The microbiological aspect of this study showed an alteration in the bacterial communities following both adjunctive laser and conventional non-surgical therapy. These findings are consistent with findings of previous studies that have shown alterations in the bacterial communities located within periodontal pockets following non-surgical therapy [15]. Previous reports comparing Er:YAG + SRP and SRP alone to have similar changes in bacterial species with a significant increase in cocci and non-motile rods as well as a decrease in the amount of motile rods and spirochetes following treatment [26, 27]. At the 6 and 12 months' examinations, increasing percentages of motile rods and spirochetes and decreasing percentages of cocci and non-motile rods were observed in both groups [26, 27]. Due to the limited analysis of this investigation, no conclusions can be made and further investigation is required to fully appreciate the microbiological alterations that have occurred in both test and control sites.

While this study showed no significant short-term differences between the test and control groups, it is important to note that the Er,Cr:YSGG laser may provide additional long-term benefit and is worthy of further investigation and analysis. In a systematic review by Schwarz and colleagues evaluating 12 publications (11 studies) that used diode, CO<sub>2</sub>, Nd:YAG and Er:YAG lasers, only the Er:YAG laser seemed to possess characteristics most appropriate for non-surgical treatment of chronic periodontitis though the evidence supporting these claims was weak [11]. However, there are limited reports and investigations utilizing the Er,Cr:YSGG laser and even more specifically the REPAIR protocol that was utilized in this study [29]. The limited

information and examination of the Er,Cr:YSGG laser warrants further analysis with respect to the clinical, microbiological and patient reported outcomes of this specific laser.

Considering the challenges observed with conventional non-surgical periodontal therapy, it is not surprising that lasers have been investigated for adjunctive therapy to SRP. However, a large dichotomy is present regarding laser use in periodontics. On one hand, there are studies that claim laser use is associated with better clinical, immunological and microbiological outcomes and that its use is prudent as adjunctive periodontal treatment [12, 15, 18]. Other studies report that no advantage is achieved with laser application in comparison to conventional mechanical debridement [11,13, 14]. While laser use in periodontics remains a largely controversial treatment modality, the Er,Cr:YSGG therapy employed in this study was demonstrated to be as effective as scaling and root planing alone with respect to improvement in inflammation and clinical measures. Within the limitations of this study, additional research is warranted including comprehensive three-dimensional analysis and long-term follow-up to better comprehend the potential of this laser technology.

## **Conclusion and Future Directions**

The focus of this study was to evaluate the clinical application of an Er,Cr:YSGG laser as an adjunct to non-surgical periodontal therapy (SRP) in humans. After clinical evaluation and analysis at 3-months following initial treatment, all qualifying sites showed a reduction in probing depth, a slight increase in recession and a gain in clinical attachment level as well as improvements in bleeding on probing (%) and plaque index. These results are consistent with previous studies evaluating adjunctive laser therapy to non-surgical treatment, more specifically with Er:YAG lasers. However, due to the limited sample size and relatively short timeframe for evaluation in the present study, it is difficult to make conclusions about the use of Er,Cr:YSGG laser in the treatment of chronic periodontitis. Further clinical, radiographic and microbiological evaluations are warranted and will be reported separately as the patients in this study continue to be followed over the entire 12-month clinical trial.

## Figures

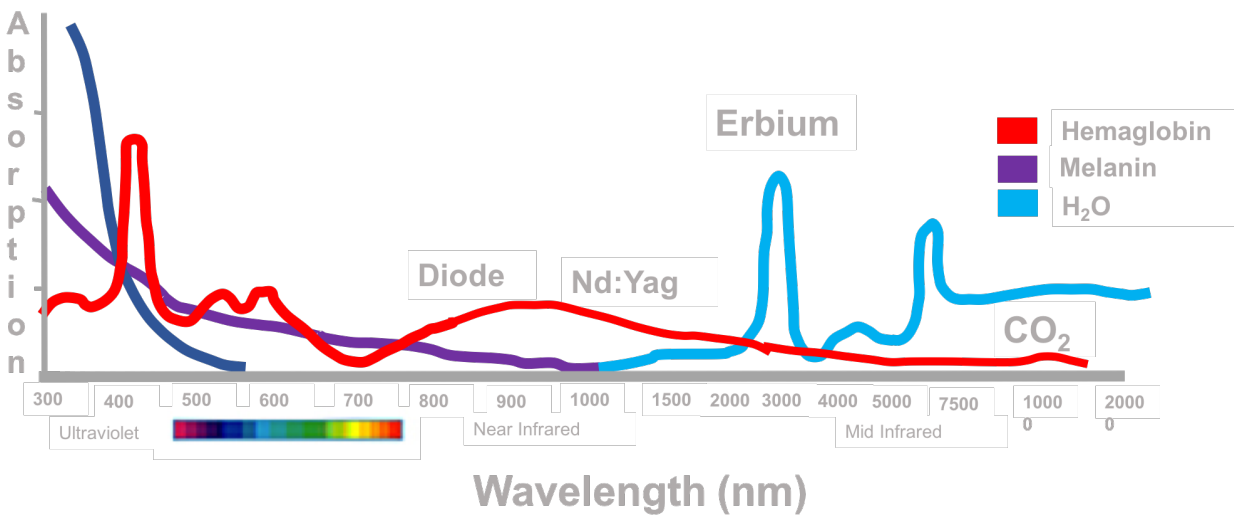


Figure 1. Laser Absorption Graph for various lasers used in periodontics. Adapted from "Lasers in Dentistry: Minimally Invasive Instruments for the Modern Practice" [30]

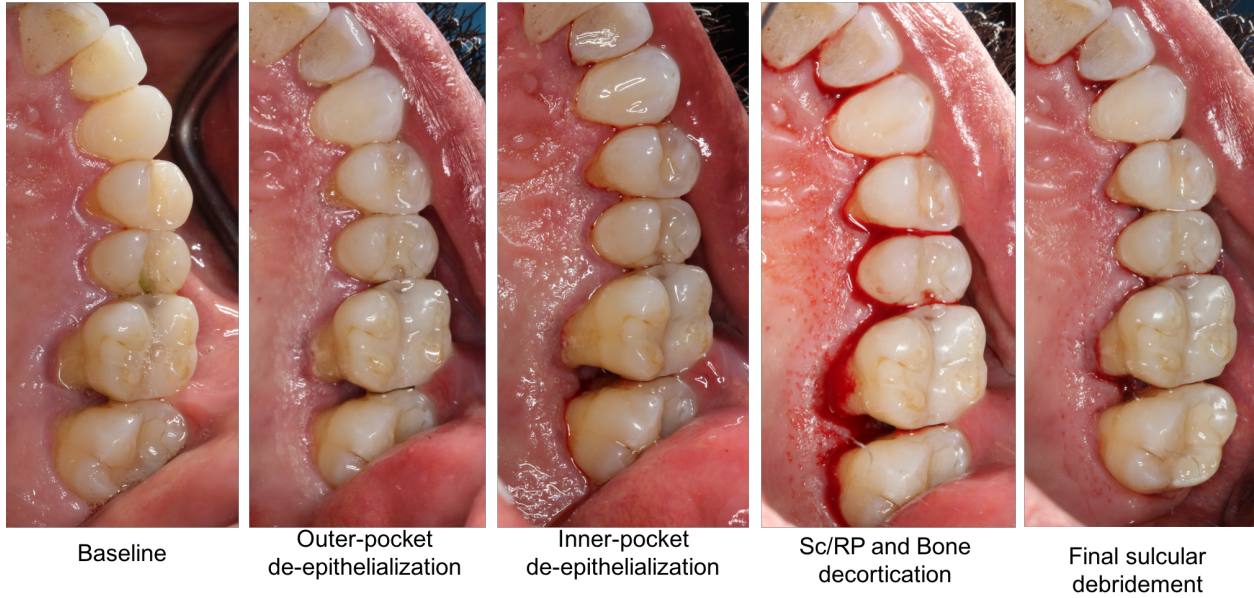
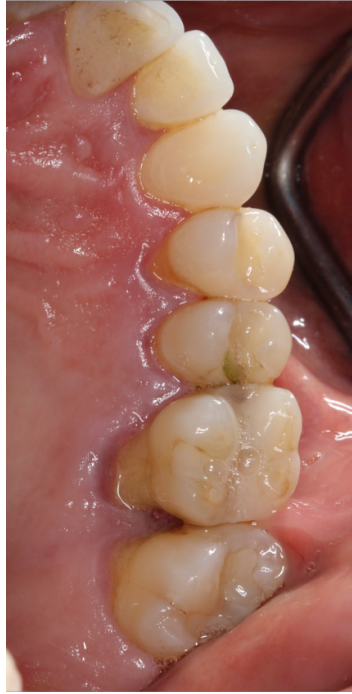
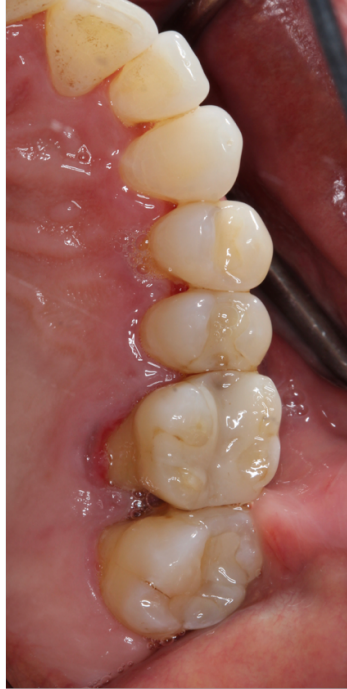
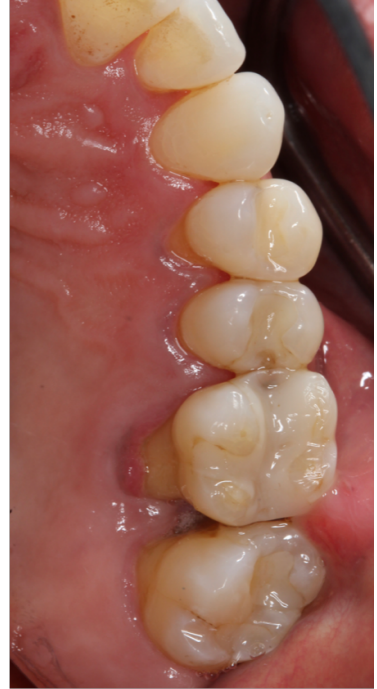Figure 2a. Clinical case presentation of REPAIR Protocol.



**Baseline**

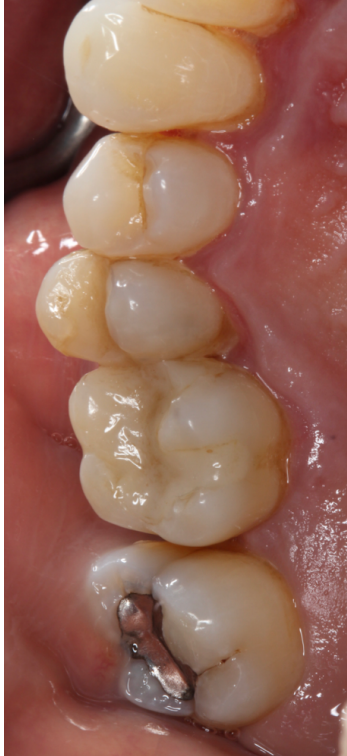

**1 Month Post-Treatment**

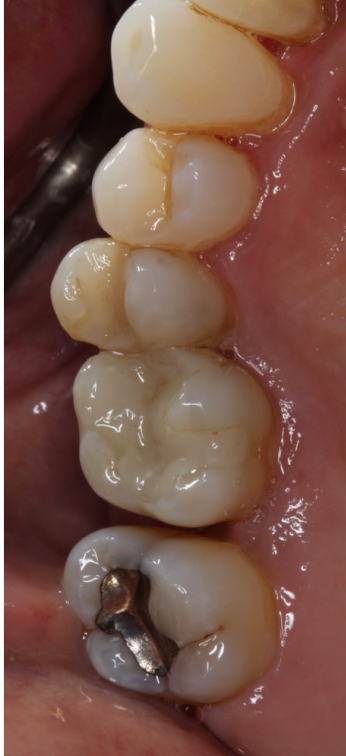

**3 Months Post-Treatment**

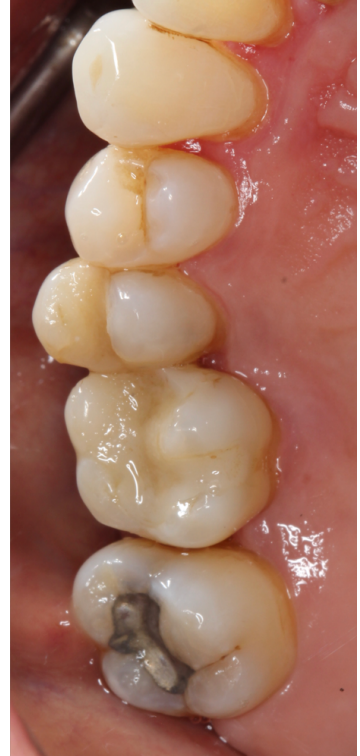Figure 2b. Clinical comparison of soft tissue appearance at baseline, 1- and 3-months following SRP and adjunctive Er,Cr:YSGG laser treatment.



**Baseline**



**1-month Post-  
Treatment**



**3-month Post-  
Treatment**

Figure 2c. Clinical comparison of soft tissue appearance at baseline, 1- and 3-months following SRP.

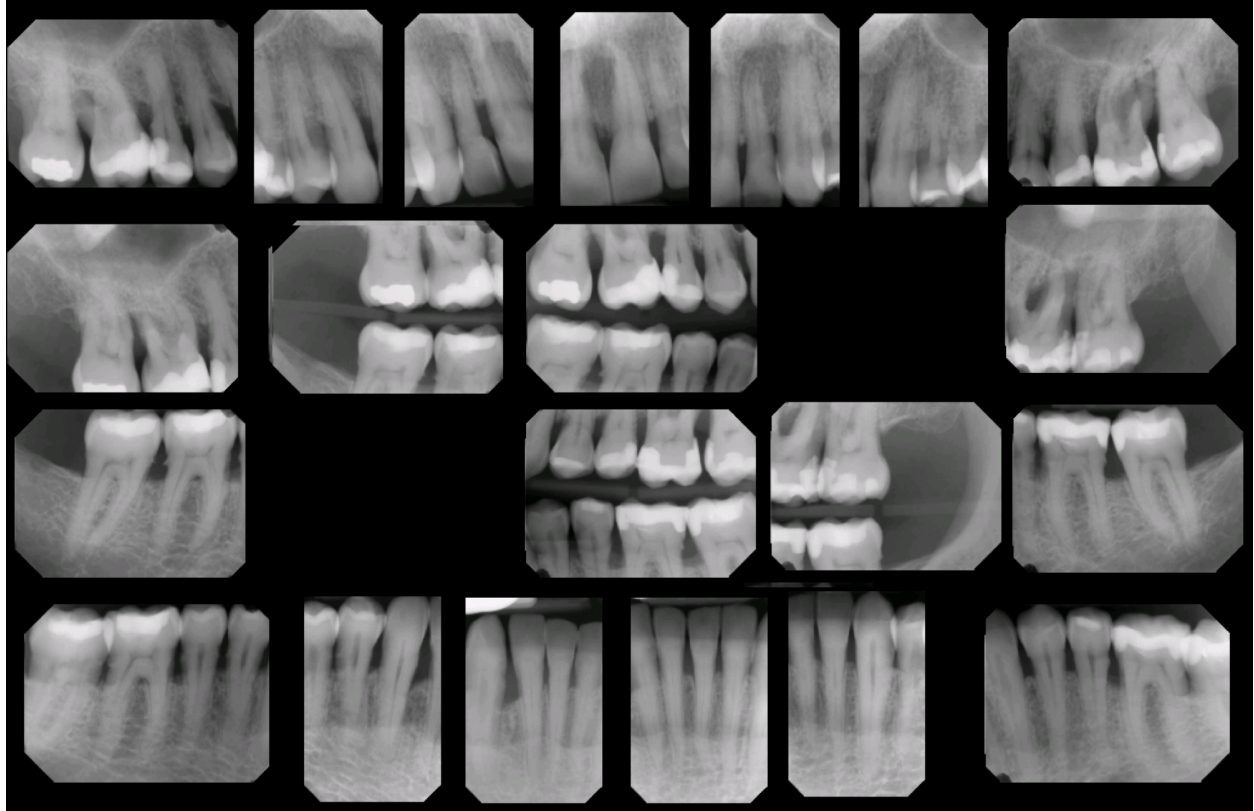


Figure 2d. Full mouth radiographs corresponding to clinical case in Figures 1a-c






Figure 3a. DGGE Profile of Subject #2, before-treatment (a) 3-months post-treatment (b).

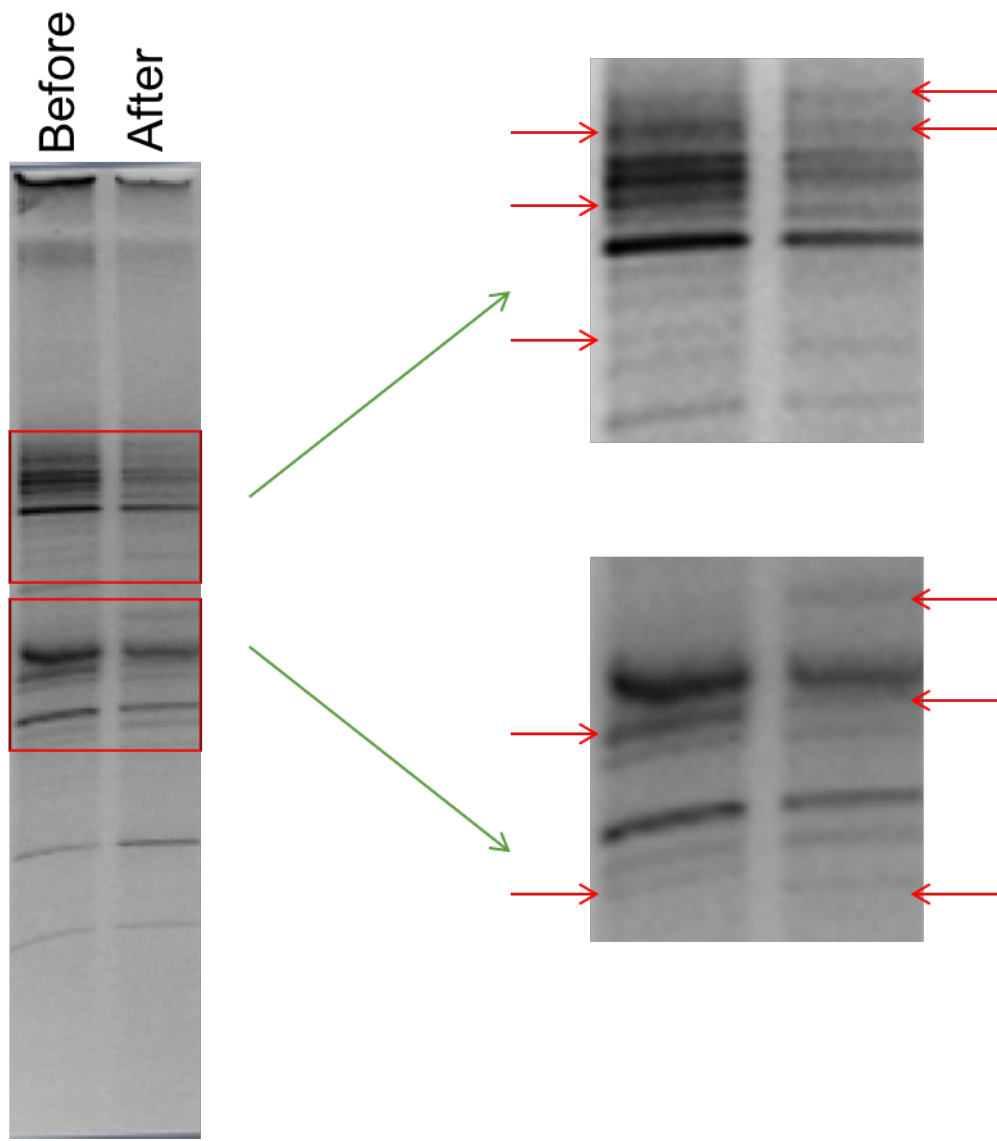


Figure 3b. Close-up of Subject 2, Sample 6 (Control-treated site).

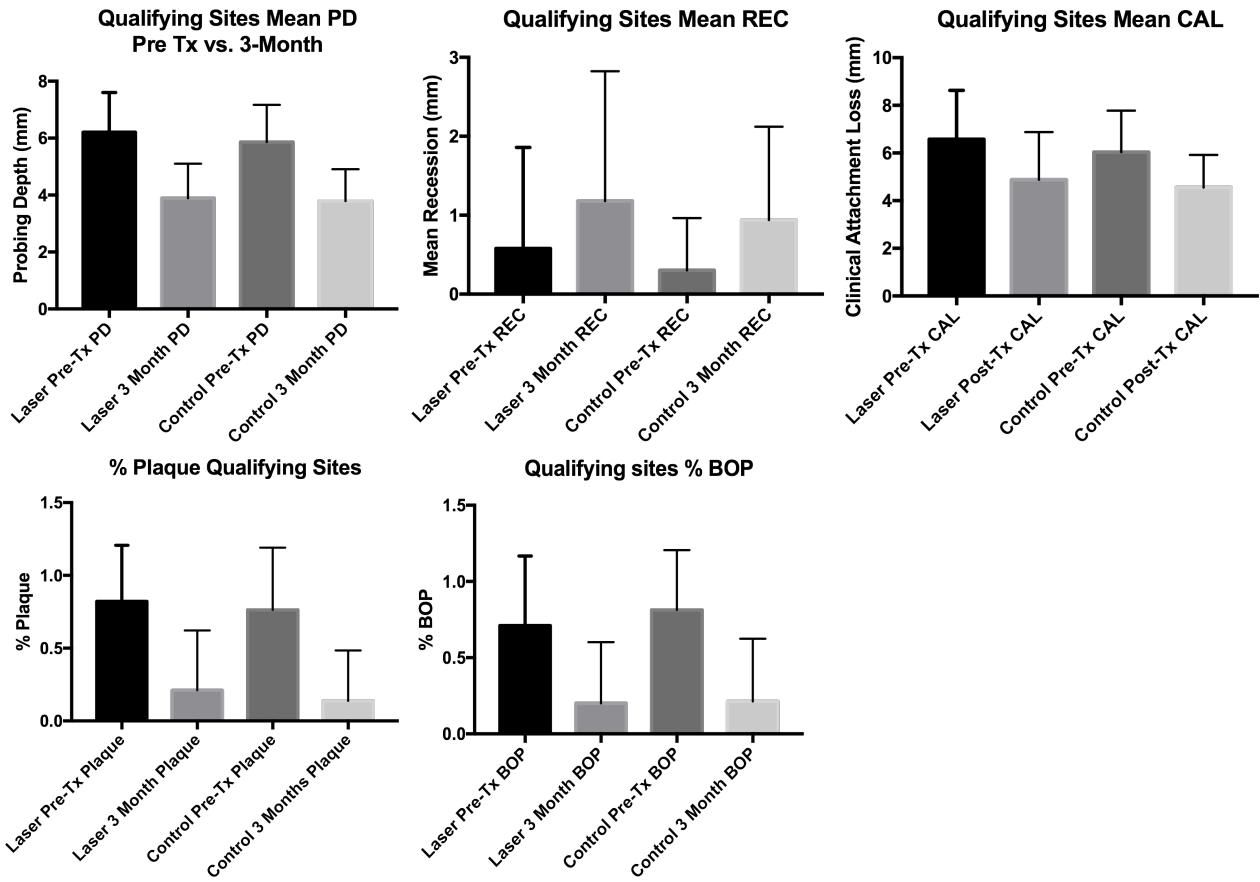


Figure 4. Qualifying Sites, Clinical Parameters, Bar Graphs: Baseline and 3-months following therapy.

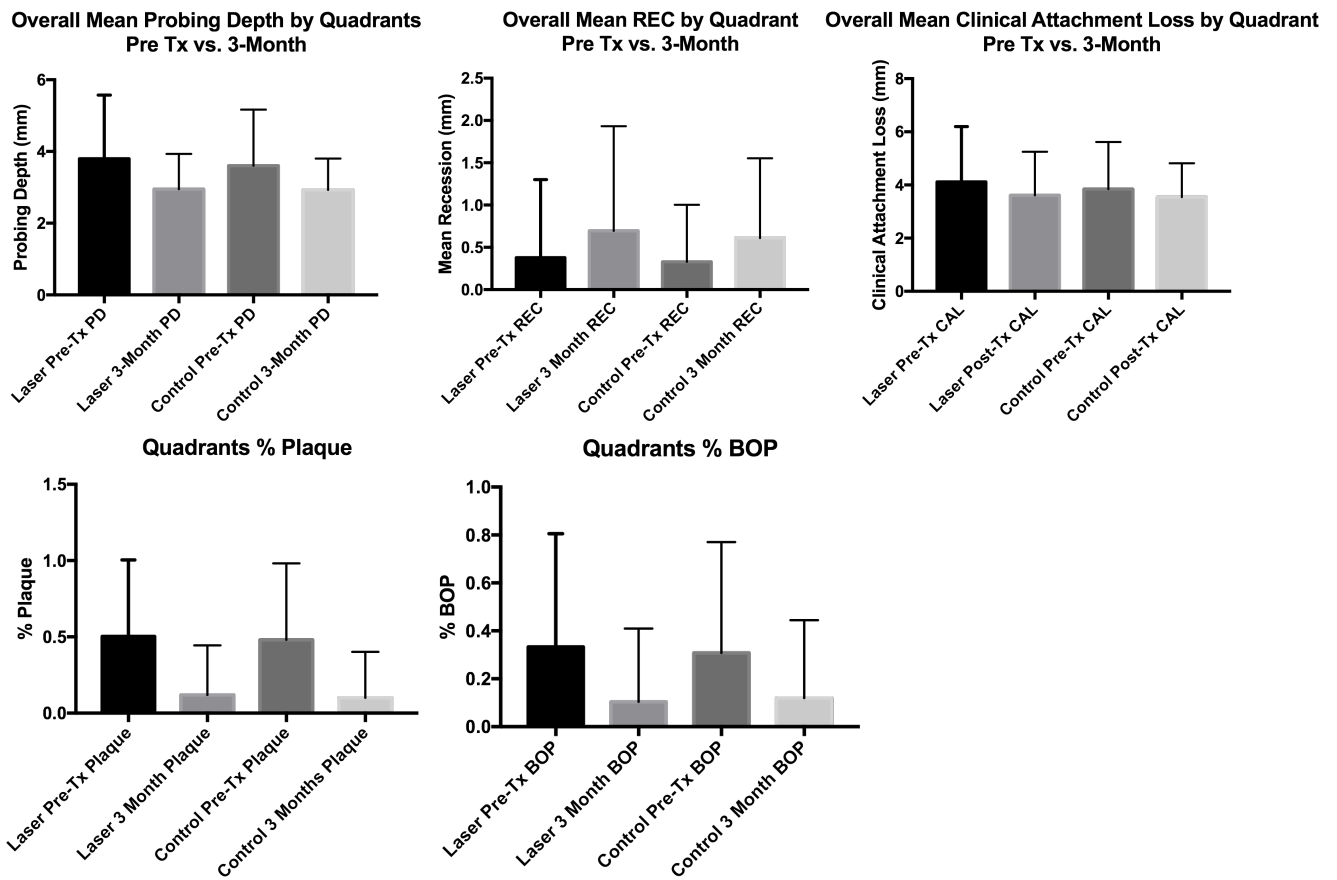


Figure 5. Test and control quadrants, clinical parameters, bar graphs: Baseline and 3-months following therapy.

Tables

<b>Laser + SRP Qualifying sites</b>	<b>Mean PD (mm)</b>	<b>Mean REC (mm)</b>	<b>Mean CAL (mm)</b>
Baseline	6.2 ± 1.3	0.5 ± 1.2	6.5 ± 2.0
3 Months	3.8 ± 1.2	1.1 ± 1.6	4.8 ± 2.0
Difference	-2.3 ± 1.5	0.6 ± 0.9	-1.7 ± 1.8
<b>Laser + SRP Quadrants</b>	<b>Mean PD (mm)</b>	<b>Mean REC (mm)</b>	<b>Mean CAL (mm)</b>
Baseline	3.7 ± 1.7	0.3 ± 0.9	4.1 ± 2.0
3 Months	2.9 ± 0.9	0.7 ± 1.2	3.6 ± 1.6
Difference	-0.8 ± 1.3	0.3 ± 0.7	-0.5 ± 1.4

Table 1. Mean values for clinical parameters of laser treated sites and quadrants.

<b>Control Qualifying sites</b>	<b>Mean PD (mm)</b>	<b>Mean REC (mm)</b>	<b>Mean CAL (mm)</b>
Baseline	5.8 ± 1.3	0.3 ± 0.6	6.0 ± 1.7
3 Months	3.7 ± 1.1	0.9 ± 1.1	4.5 ± 1.3
Difference	-2.1 ± 1.2	0.6 ± 0.1	-1.5 ± 1.8
<b>Control Quadrants</b>	<b>Mean PD (mm)</b>	<b>Mean REC (mm)</b>	<b>Mean CAL (mm)</b>
Baseline	3.6 ± 1.5	0.3 ± 0.6	3.8 ± 1.7
3 Months	2.9 ± 0.8	0.6 ± 0.9	3.5 ± -0.3
Difference	-0.7 ± 1.1	0.2 ± 0.7	-0.3 ± 1.4

Table 2. Mean values for clinical parameters of control treated sites and quadrants.

<b>Non-Treated Sites</b>	<b>Mean PD (mm)</b>	<b>Mean REC (mm)</b>	<b>Mean CAL (mm)</b>
Baseline	2.8 ± 0.6	0.5 ± 0.9	3.1 ± 1.0
3 Months	2.6 ± 0.5	0.4 ± 0.7	3.2 ± 1.1
Difference	-0.2 ± 0.5	-0.1 ± 1.0	0.1 ± 0.9

Table 3. Mean values for clinical parameters of non-treated sites.

<b>Laser + SRP Sites</b>	<b>BOP (%)</b>	<b>PI (%)</b>
Baseline	71.1 ± 45.5	82.2 ± 38.4
3 Months	20.0 ± 40.2	21.1 ± 41.0
Difference	-51.1 ± 54.5	-61.1 ± 49.0
<b>Control Sites</b>	<b>BOP (%)</b>	<b>PI (%)</b>
Baseline	81.2 ± 39.2	76.2 ± 42.8
3 Months	21.2 ± 41.1	13.7 ± 34.6
Difference	-60.0 ± 56.4	-62.5 ± 51.2

Table 4. Bleeding on probing and plaque index of laser and control treated sites.



<b>Subject</b>	<b>Number of Qualifying Quadrants</b>	<b>Number of Qualifying Sites</b>	<b>Number of sites treated w/ Sc/RP alone</b>	<b>Number of sites treated w/ Laser + Sc/RP</b>
1	4	31	15	16
2	2	18	8	10
3	4	35	15	20
4	4	50	26	24
5	4	36	16	20
	<b>18</b>	<b>170</b>	<b>80</b>	<b>90</b>

Table 5: Distribution of total treated sites/quadrants by patient.

## **Appendix 1: Laser Manufacturer Specifications**

Laser Manufacturer Specifications: The laser to be used in this protocol is the Waterlase iPlus Er,Cr:YSGG laser manufactured by Biolase (Irvine, California, USA).

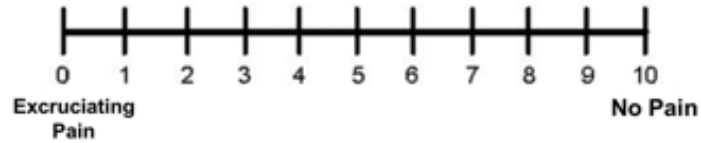
- Model: Waterlase iPlus
- Operating Voltage: 100 VAC  $\pm$  10% / 230VAC  $\pm$  10%
- Frequency: 50 / 60 Hz
- Current Rating: 15.0 A / 8A
- Laser classification: Class 4 (Er,Cr:YSGG), Class 1 (635nm red Aiming Beam)
- Type of laser: Er,Cr:YSGG
- Wavelength: 2780 nm
- Type of operation: Pulse
- Laser energy: 0- -600 mJ
- Aiming Beam: 635nm (red)
- Cooling method: Water cooling (built-in reservoir)
- Outer dimensions (WxDxH): 11" x 19" x 33" (246mm x 585mm x 1057mm)
- Weight: Approx. 75 lb. (34 kg)

## Appendix 2. Patient Satisfaction and Comfort Questionnaire

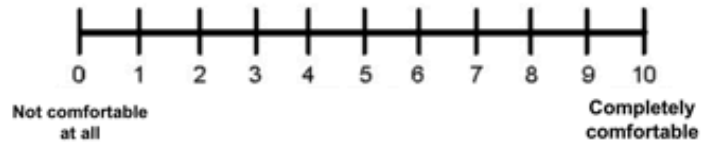
---

### Patient Satisfaction and Comfort Assessment

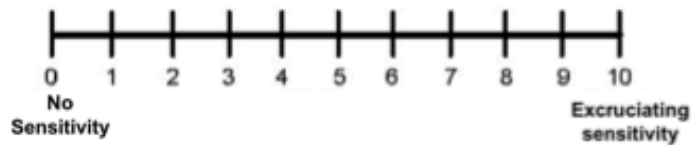
1. How would you rate your pain 3 months after treatment?



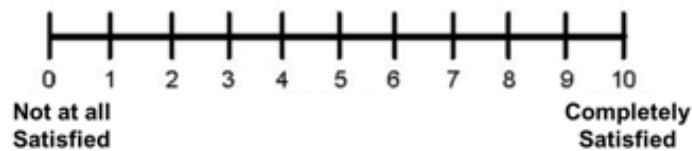
2. How would you rate your chewing comfort 3 months after treatment?



3. How would you rate your dental sensitivity 3 months after treatment?



4. How would you rate your current satisfaction 3 months after treatment?



Comments:

# REPAIR

## REGENERATIVE ER,CR:YSGG PERIODONTITIS REGIMEN

**THE WATERLASE® ER,CR:YSGG PERIO REGIMEN** is the first definitive step-by-step protocol for using an Er,Cr:YSGG laser to assist in the management of early, moderate and severe chronic periodontitis. It consists of three phases: pre-surgical, surgical and post-surgical.

### PHASE I: PRE-SURGICAL PHASE

All patients should have a comprehensive periodontal examination/evaluation including data collection of periodontal charting and radiographs, medical and dental history, and risk assessment.

Phase I treatment is implemented for removal of supra- and subgingival biofilm and calculus through scaling and root planing (S/RP) and the initiation and evaluation of oral hygiene compliance. Occlusal assessment and treatment may be warranted in this phase. Splinting of teeth may be an option.

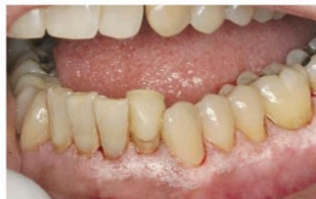### PHASE II: SURGICAL PHASE

Phase II surgical treatment plan is developed based on the re-evaluation of periodontal inflammation and oral hygiene compliance. The surgical plan can be for a single tooth or multiple teeth sites, a quadrant or half-mouth depending on number of indicated sites. If desired, the half-mouth protocol is generally UR/LR followed by at least 2-3 weeks of post-operative management before treating the UL/LL areas.

1

#### OUTER POCKET DE-EPITHELIALIZATION

Outer pocket gingival epithelium is removed from the free gingival margin down to a width at least equal to the pocket depth.



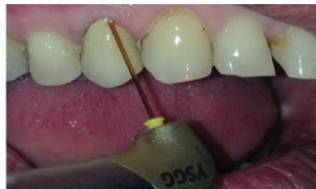
waterlase® iPlus  
Pre-set Settings

Tip: RFTP5  
Power: 1.5W  
Air/Water: 40%/50%  
Pulse rate: 30 Hz  
H mode

2

#### GINGIVECTOMY (AS NEEDED)

A gingivectomy should only be performed if pseudo-pocketing is present. Ensure you do not compromise adequate attached gingivae.



Tip: RFTP5  
Power: 1.5W  
Air/Water: 40%/50%  
Pulse rate: 30 Hz  
H mode

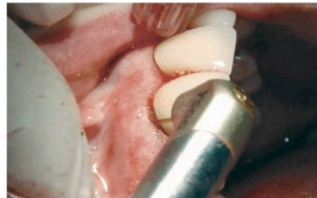
## Appendix 3. Waterlase® iPlus Brochure, Biolase Inc. cont.

### REPAIR WATERLASE® PERIO PROTOCOL CONTINUED

3

#### DE-EPITHELIALIZATION AND RETRACTION

The pocket epithelium should be removed and should be completed apically, down to bone. The gingival margin can be retracted as a mini flap for access.

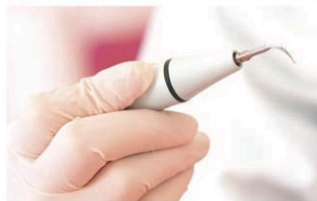

Tip: RFPT5  
Power: 1.5W  
Air/Water: 40%/50%  
Pulse rate: 30 Hz  
H Mode

4

#### SCALING AND ROOT PLANING

Conventional treatment with ultrasonics and hand instruments to remove root surface accretions and/or calculus and to smooth cementum.

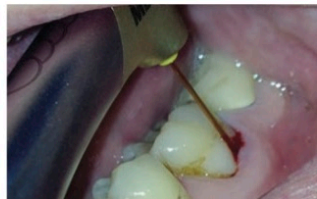


Laser not used

5

#### SULCULAR DEBRIDEMENT / DEGRANULATION

Remove smear layer created by scaling, along with any residual calculus, and prepare the root surface for reattachment. Remove pocket lining and degranulate to expose bone surface.



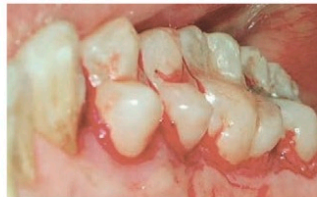Tip: RFPT5  
Power: 1.5W  
Air/Water: 40% / 50%  
Pulse rate: 30 Hz  
H mode

**waterlase® iPlus**  
Increase pulse rate to **75 Hz**  
for faster calculus removal.

6

#### BONE DECORTICATION

Recontour osseous defects. Hold tip parallel to root surface and gently tap all the way down to and into bone, retracting slightly and repeating all the way around tooth. If necessary, change angle of the laser tip and treat into the walls of infrabony defects.

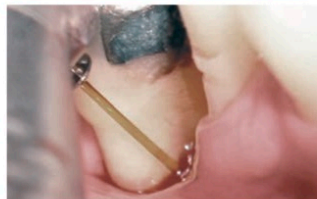


Tip: MZ6  
Power: 2.5W  
Air/Water: 70% / 80%  
Pulse rate: 30 Hz  
H mode

7

#### FINAL SULCULAR DEBRIDEMENT

Remove residual debris and induce blood coagulation.



Tip: RFPT5  
Power: 1.5W  
Air/Water: 10% / 10%  
Pulse rate: 30 Hz  
H mode

8

#### COMPRESS WITH 2X2

Compress surgical site with wet 2x2 for 3-5 minutes.

#### PHASE III: POST-SURGICAL PHASE

- IMMEDIATE POST-OPERATIVE: Brush teeth lightly with soft brush and use mouth rinse to supplement brushing if discomfort exists.
- ONE WEEK AFTER LASER TREATMENT: Gently clean between teeth using an interproximal brush dipped in mouthwash.
- NO PROBING for at least 3 months, at which time a supragingival scaling is completed.

## References

1. Page, R. C., & Kornman, K. S. (1997). The pathogenesis of human periodontitis: an introduction. *Periodontology 2000*, 14(1), 9-11.
2. Socransky, S. S., Haffajee, A. D., Cugini, M. A., Smith, C., & Kent, R. L. (1998). Microbial complexes in subgingival plaque. *Journal of clinical periodontology*, 25(2), 134-144.
3. Hart, T. C., & Kornman, K. S. (1997). Genetic factors in the pathogenesis of periodontitis. *Periodontology 2000*, 14(1), 202-215.
4. Armitage, G. C. (1999). Development of a classification system for periodontal diseases and conditions. *Annals of periodontology*, 4(1), 1-6.
5. Badersten, A., Nilvéus, R., & Egelberg, J. (1990). Scores of plaque, bleeding, suppuration and probing depth to predict probing attachment loss 5 years of observation following nonsurgical periodontal therapy. *Journal of clinical periodontology*, 17(2), 102-107.
6. Heitz-Mayfield, L. J. A., Trombelli, L., Heitz, F., Needleman, I., & Moles, D. (2002). A systematic review of the effect of surgical debridement vs. non-surgical debridement for the treatment of chronic periodontitis. *Journal of clinical periodontology*, 29(s3), 92-102.
7. Garrett, S. (1996). Periodontal regeneration around natural teeth. *Annals of Periodontology*, 1(1), 621-666.
8. Caffesse, R. G., Sweeney, P. L., & Smith, B. A. (1986). Scaling and root planing with and without periodontal flap surgery. *Journal of clinical periodontology*, 13(3), 205-210.

9. Caton, J. G., & Zander, H. A. (1979). The Attachment Between Tooth and Gingival Tissues After Periodic Root Planing and Soft Tissue Curettage\*. *Journal of Periodontology*, 50(9), 462-466.
10. Bower, R. C. (1979). Furcation morphology relative to periodontal treatment: furcation root surface anatomy. *Journal of periodontology*, 50(7), 366-374.
11. Schwarz, F., Aoki, A., Becker, J., & Sculean, A. (2008). Laser application in non-surgical periodontal therapy: a systematic review. *Journal of clinical periodontology*, 35(s8), 29-44.
12. Ishikawa, I., Aoki, A., & Takasaki, A. A. (2004). Potential applications of Erbium: YAG laser in periodontics. *Journal of periodontal research*, 39(4), 275-285.
13. Smiley, C. J., Tracy, S. L., Abt, E., Michalowicz, B. S., John, M. T., Gunsolley, J., ... & Hujoel, P. P. (2015). Evidence-based clinical practice guideline on the nonsurgical treatment of chronic periodontitis by means of scaling and root planing with or without adjuncts. *The Journal of the American Dental Association*, 146(7), 525-535.
14. Smiley, C. J., Tracy, S. L., Abt, E., Michalowicz, B. S., John, M. T., Gunsolley, J., ... & Hujoel, P. P. (2015). Systematic review and meta-analysis on the nonsurgical treatment of chronic periodontitis by means of scaling and root planing with or without adjuncts. *The Journal of the American Dental Association*, 146(7), 508-524.
15. Aoki, A., Mizutani, K., Schwarz, F., Sculean, A., Yukna, R. A., Takasaki, A. A., ... & Koshy, G. (2015). Periodontal and peri-implant wound healing following laser therapy. *Periodontology 2000*, 68(1), 217-269.

16. Azarpazhooh, A., Shah, P. S., Tenenbaum, H. C., & Goldberg, M. B. (2010). The effect of photodynamic therapy for periodontitis: a systematic review and meta-analysis. *Journal of periodontology*, 81(1), 4-14.
17. Qadri, T., Miranda, L., Tuner, J., & Gustafsson, A. (2005). The short-term effects of low-level lasers as adjunct therapy in the treatment of periodontal inflammation. *Journal of clinical periodontology*, 32(7), 714-719.
18. Yukna, R. A., Carr, R. L., & Evans, G. H. (2007). Histologic evaluation of an Nd: YAG laser-assisted new attachment procedure in humans. *The International journal of periodontics & restorative dentistry*, 27(6), 577.
19. Kreisler, M., Meyer, C., Stender, E., Daubländer, M., Willershausen-Zönnchen, B., & d'Hoedt, B. (2001). Effect of diode laser irradiation on the attachment rate of periodontal ligament cells: an in vitro study. *Journal of periodontology*, 72(10), 1312-1317.
20. Mizutani, K., Aoki, A., Takasaki, A. A., Kinoshita, A., Hayashi, C., Oda, S., & Ishikawa, I. (2006). Periodontal tissue healing following flap surgery using an Er: YAG laser in dogs. *Lasers in surgery and medicine*, 38(4), 314-324.
21. Perussi, L. R., Pavone, C., de Oliveira, G. J. P. L., Cerri, P. S., & Marcantonio, R. A. C. (2012). Effects of the Er, Cr: YSGG laser on bone and soft tissue in a rat model. *Lasers in medical science*, 27(1), 95-102.
22. Odor, A. A., Violant, D., Badea, V., & Gutknecht, N. (2016, March). Short-term clinical outcomes of laser supported periodontal treatment concept using Er, Cr: YSGG (2780nm) and diode (940 nm): a pilot study. In *Sixth International*



*Conference on Lasers in Medicine* (pp. 96700G-96700G). International Society for Optics and Photonics.

23. Hakki, S. S., Berk, G., Dundar, N., Saglam, M., & Berk, N. (2010). Effects of root planing procedures with hand instrument or erbium, chromium: yttrium–scandium–gallium–garnet laser irradiation on the root surfaces: a comparative scanning electron microscopy study. *Lasers in medical science*, 25(3), 345-353.
24. Diaci, J., & Gaspirc, B. (2012). Comparison of Er: YAG and Er, Cr: YSGG lasers used in dentistry. *Review. JLAHA*, 1, 1-13.
25. Pavone, C., Perussi, L. R., de Oliveira, G. J. P. L., Scardueli, C. R., Cirelli, J. A., Cerri, P. S., ... & Marcantonio, R. A. C. (2015). Effect of Er, Cr: YSGG laser application in the treatment of experimental periodontitis. *Lasers in medical science*, 30(3), 993-999.
26. Schwarz, F., Sculean, A., Berakdar, M., Georg, T., Reich, E., & Becker, J. (2003). Periodontal treatment with an Er: YAG laser or scaling and root planing. A 2-year follow-up split-mouth study. *Journal of periodontology*, 74(5), 590-596.
27. Schwarz, F., Sculean, A., Berakdar, M., Georg, T., Reich, E., & Becker, J. (2003). Clinical evaluation of an Er: YAG laser combined with scaling and root planing for non-surgical periodontal treatment. *Journal of clinical periodontology*, 30(1), 26-34.
28. Rasiah, I. A., Wong, L., Anderson, S. A., & Sissons, C. H. (2005). Variation in bacterial DGGE patterns from human saliva: over time, between individuals and in corresponding dental plaque microcosms. *Archives of oral biology*, 50(9), 779-787.

29. Dyer, B., & Sung, E. C. (2012). Minimally invasive periodontal treatment using the Er, Cr: YSGG laser. A 2-year retrospective preliminary clinical study. *The open dentistry journal*, 6(1).
30. Pohlhaus, S. R. (2012). Lasers in Dentistry: Minimally Invasive Instruments for the Modern Practice. Retrieved July, 7, 2014.