

# UC Davis

## UC Davis Previously Published Works

### Title

Selective His-bundle pacing in an adult with atrioventricular canal defect via retrograde His localization.

### Permalink

<https://escholarship.org/uc/item/3mx2k9fz>

### Journal

Indian Pacing and Electrophysiology Journal, 21(5)

### ISSN

0972-6292

### Authors

Bury, Anastasia

Cortez, Daniel

### Publication Date

2021

### DOI

10.1016/j.ipej.2021.05.009

### Copyright Information

This work is made available under the terms of a Creative Commons Attribution-NonCommercial-NoDerivatives License, available at

<https://creativecommons.org/licenses/by-nc-nd/4.0/>

Peer reviewed



Contents lists available at ScienceDirect

## Indian Pacing and Electrophysiology Journal

journal homepage: [www.elsevier.com/locate/IPEJ](http://www.elsevier.com/locate/IPEJ)

## Selective His-bundle pacing in an adult with atrioventricular canal defect via retrograde His localization

Anastasia Bury<sup>a</sup>, Daniel Cortez<sup>b, c, \*</sup><sup>a</sup> Central Michigan University College of Medicine, Mount Pleasant, USA<sup>b</sup> University of Minnesota/Masonic Children's Hospital, Minneapolis, USA<sup>c</sup> University of California at Davis, Sacramento, USA

## ARTICLE INFO

## Article history:

Received 15 March 2021

Received in revised form

13 May 2021

Accepted 28 May 2021

Available online 2 June 2021

## Keywords:

Atrioventricular canal defect

3-Dimensional mapping

His-bundle pacing

## A B S T R A C T

Adult congenital heart disease patients may undergo numerous fluoroscopically guided procedures including pacemaker implantation during their lifetime. One alternative to traditional pacemaker setup which may improve long-term pacing outcomes is His bundle pacing. Given the altered His-bundle location, and given increased radiation exposure over a lifetime, we used 3-dimensional mapping to locate the His and to minimize fluoroscopy for placement of a His-bundle pacemaker system in a 31-year old patient with atrioventricular canal defect and complete heart block with 100% RV pacing and epicardial lead fracture.

**Methods:** An Octapolar Livewire catheter (Abbott, Minneapolis, USA) was used for mapping and location of the His bundle from a right femoral venous access on the EnSite Precision system 3-dimensional mapping system (Abbott Medical, Abbott Park, IL). The same map was used to guide 3830 lead placement into the posterior-inferior His-bundle position.

**Results:** Successful placement of a His-bundle pacing system with thresholds of **1Volt@0.4ms** for both the atrial and ventricular leads with selective His-bundle pacing noted. Ten-month follow-up demonstrated His-bundle capture at **0.75V@0.4ms** with stable impedance, sensing and with 100% right ventricular pacing a projected longevity of 12 years total.

**Conclusions:** Successful placement of selective His-bundle pacing can be achieved in an adult patient with atrioventricular canal defect using 3-dimensional mapping.

Copyright © 2021, Indian Heart Rhythm Society. Production and hosting by Elsevier B.V. This is an open access article under the CC BY-NC-ND license (<http://creativecommons.org/licenses/by-nc-nd/4.0/>).

## 1. Introduction

Adult congenital heart disease (CHD) patients are a fast-growing population, reflective of progress in surgical and medical treatments now with nearly 90% of CHD children surviving until adulthood [1]. One notable consequence of this improved mortality rate is secondary long-term complications like heart failure and ventricular desynchrony [2]. In recent years, His bundle pacing has emerged as a highly successful treatment to promote physiologic ventricular activation and an alternative to biventricular pacing to restore ventricular synchrony [3–6]. In order to most effectively apply selective His bundle pacing at low outputs, the placement of leads is a precise and delicate procedure [5]. There are additional challenges associated with lead installation in CHD patients

including lengthier procedure duration related to the many potential anatomic variations of the structurally abnormal heart (2, 8). Advancements in electroanatomic mapping show minimal complications in adult patients and have contributed to enhanced procedural success in part because of greater anatomical mapping detail leading to improved accuracy of lead placement and lowered risk in patients with abnormal intrinsic conduction and complicated congenital cardiac abnormalities among others (8–10). Furthermore, using 3-dimensional mapping during lead implantation reduces intraprocedural fluoroscopy time which may be especially advantageous for CHD patients since over a lifetime, this population is exposed to ionizing radiation during numerous diagnostic and therapeutic procedures.

\* Corresponding author. 5th Floor East Building, 2450 Riverside Minneapolis, MN, 55454, USA.

E-mail address: [dr.danielcortez@gmail.com](mailto:dr.danielcortez@gmail.com) (D. Cortez).

Peer review under responsibility of Indian Heart Rhythm Society.

## 2. Case presentation

A 34-year old female with history of trisomy 21, complete atrioventricular canal defect with history of repair at 5 months of life with perioperative complete heart block and epicardial lead placement  $\times 4$  total and with recent generator placed 5 years prior, who had not been converted to a transvenous system by the preference of her primary cardiologist, presented with ventricular lead fracture at time of left atrioventricular valve repair presentation. Given the numerous epicardial leads placed prior, we assumed this last ventricular lead likely failed due to significant scar burden. Left atrioventricular valve was replaced with a 27mm bioprosthesis valve and temporary pacing wires were placed. Attempts at permanent lead placement were unsuccessful due to high thresholds/lack of capture on the epicardial surface. Thus, she subsequently underwent transvenous device placement.

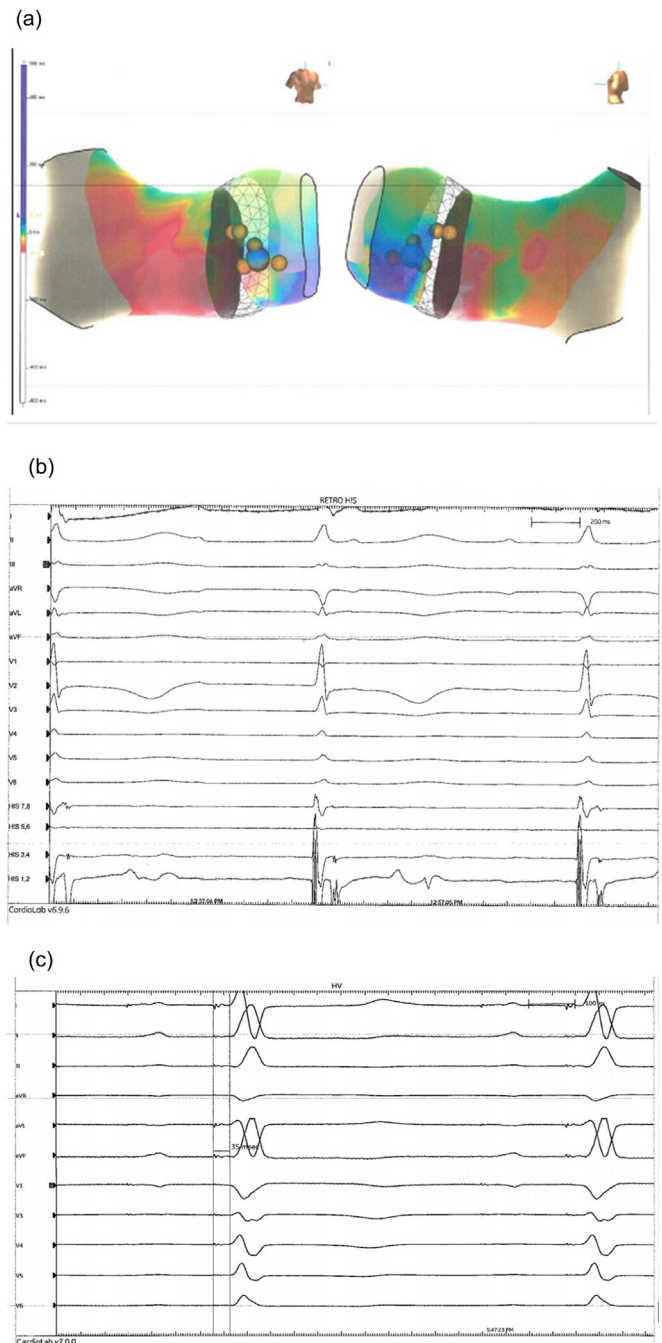
## 3. Procedures

She was brought to the room with airway control and sedation performed by anesthesia including intubation tube placement for airway control. Given need for epicardial device removal and caps to be placed on leads, she was prepped and draped in a standard fashion from neck to umbilicus. Femoral access with a 5-French sheath was obtained and the Octapolar Livewire catheter (Abbott, Minneapolis, USA) was used and mapping of the posterior-inferior retrograde His signal on a site with good pacing capture (2 milliamps), was performed on a 3-dimensional geometry via the Ensite Precision system (Abbott Medical, Abbott Park, USA) during ventricular pacing, given no underlying ventricular rhythm noted (Fig. 1).

A left chest incision was made 1 cm below the clavicle extending 1.5 inches in length and dissection utilizing electrocautery was performed to the level of the sheath covering the pectoralis muscle. At that level, further dissection was performed inferiorly, and a pocket was created of adequate size for the device. At that point axillary venous access was obtained using the Seldinger technique under ultrasound and as needed fluoroscopy guidance, and two 7Fr sheaths were placed. Both sheaths were needed to be left in the vein simultaneously, due to interference otherwise if only a wire were left in place.

Utilizing the 4-French Decapolar Inquiry catheter (Abbott Medical, Abbott Park, USA) through the C315 sheath (Medtronic, Minneapolis, USA), further mapping and location of the His bundle was found from the superior access. At a level where the His signal was identified, the sheath was then left in place just slightly distally to the approximated strongest His signal on the 3-dimensional map. Subsequently, the 69-cm ventricular lead (3830 lead, Medtronic, Minneapolis, USA) was passed through the sheath with unipolar mapping performed to assess location. Fluoroscopy was used to confirm location when we were unsure of the location of the lead or when subsequent deployment was needed. Pacing was performed to make sure his capture was present at outputs of  $10\text{Volts}@0.4\text{ms}$ , at  $5\text{V}@0.4\text{ms}$ , at  $2\text{V}@0.4\text{ms}$  and at  $1\text{V}@0.4\text{ms}$ . At this same location, the 3830 lead was coiled into the His bundle position (Fig. 1 A and B). Subsequently the guiding sheath was slit (with Universal Slitter, Medtronic, Minneapolis) after adequate sensing, pacing and impedance were found. Adequate sensing, pacing threshold and impedance were obtained. The lead was then tied to the pectoralis muscle utilizing 0-Ethibond and the lead tie.

In a similar manner a 59cm 3830 lead was passed through the J-curved Medtronic sheath through the 7-Fr short sheath into the right atrium guiding it toward the septum. An atrial location was chosen where the atrial signal was higher than the ventricular signal with stable threshold. Subsequently the helix was coiled into

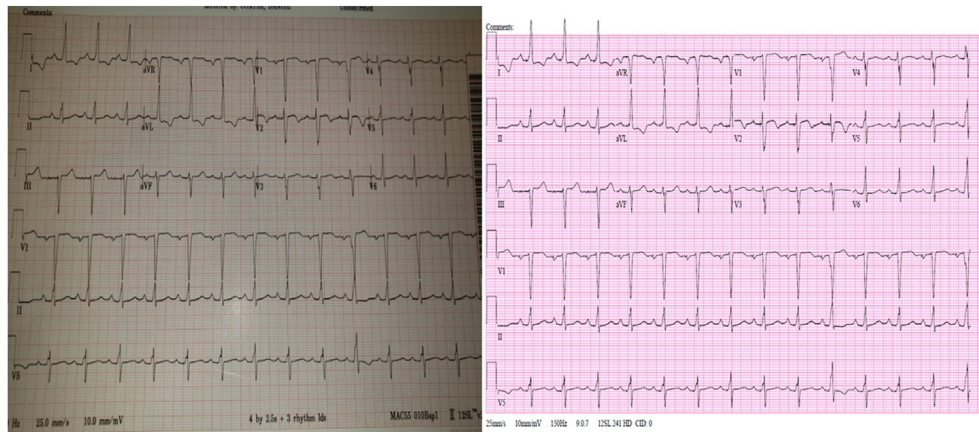


**Fig. 1.** A: 3-dimensional map of earliest ventricular activation and B: retrograde His-bundle noted (arrow) and C: His to ventricular interval with pacing.

the right atrium. Subsequently the guiding sheath was slit (with Universal Slitter) after adequate sensing, pacing and impedance were found. The 3830 lead was used given ease of placement in the atrium.

All leads were sutured to the pectoralis muscle and a Medtronic Azure XT (Minneapolis, USA) dual chamber pacemaker was placed with deep tissue and skin closed with absorbable sutures.

Ventricular capture threshold (His) was  $0.5\text{V}@0.4\text{ms}$ , with impedance of  $589\ \Omega$  and R-wave of 6 mV. The atrial lead had a capture threshold of  $0.5\text{V}@0.4\text{ms}$ , impedance  $551\ \Omega$  and P-wave of 2.5 mV. No complications occurred and the temporary wires and abdominal generator were removed subsequently (with epicardial



**Fig. 2.** Prior to pacemaker (left) and subsequent to pacemaker placement (right) with bipolar pacing.

leads capped). Follow-up at 10-months demonstrated a ventricular threshold of  $0.75V@0.4ms$ , impedance of  $490 \Omega$ , and R-wave of  $5.6 mV$  and normal biventricular function. Fig. 1A–C demonstrates location of lead, retrograde His bundle (arrow) and His-ventricular interval). Fig. 2 demonstrates (left) intrinsic conduction prior to pacemaker placement) and (right) paced morphology.

#### 4. Discussion

We present the feasibility of using 3-dimensional mapping to identify and place a selective His-bundle pacing system in an adult patient with atrioventricular canal defect. Prior reports of His-bundle pacing attempts in patients with anteriorly-displaced His-bundles, in the setting of congenitally-corrected transposition of the great arteries has been demonstrated, but to date this has not been demonstrated in adult patients with posterior-inferior displaced His bundles as in patients with atrioventricular canal defect [7]. Also given the patient's pacemaker dependence, we also used the retrograde His signal (which was posterior-inferior) to identify location for lead placement. The Livewire was used from the femoral venous access, which we use routinely in patients with altered conduction systems given the easier maneuverability from below, and it typically serves well as back-up pacing. The 3-dimensional map we find is helpful for placing multiple possible points to pace from given significant scar burden in patients with ventricular septal defect repairs. It follows then that when available, the option to use 3-dimensional mapping with fluoroscopy confirmation for His bundle and left bundle pacing procedures instead of fluoroscopy only offers notable long-term health advantages for adult CHD patients.

#### 5. Conclusion

This case demonstrates feasibility of His-bundle pacing in patients with atrioventricular canal defects, even if retrograde His bundle is mapped.

#### Acknowledgements

None

#### References

- [1] Nieminen H, Jokinen E, Sairanen H. Late results of pediatric cardiac surgery in Finland: a population-based study with 96% follow-up. *ACC Curr J Rev* 2002;11(1):86–7.
- [2] Diller G, Kempny A, Alonso-Gonzalez R, Swan L, Uebing A, Li W, Babu-Narayan S, Wort S, Dimopoulos K, Gatzoulis M. Survival prospects and circumstances of death in contemporary adult congenital heart disease patients under follow-up at a large tertiary centre. *Circulation* 2015;132(22):2118–25.
- [3] Lyon S, Dandamudi G, Kean A. Permanent his-bundle pacing in pediatrics and congenital heart disease. *J Innov Cardiac Rhythm Manag* 2020;11(2):4005–12.
- [4] Sharma P, Dandamudi G, Naperkowski A, Oren J, Storm R, Ellenbogen K, Vijayaraman P. Permanent His-bundle pacing is feasible, safe, and superior to right ventricular pacing in routine clinical practice. *Heart Rhythm* 2015;12(2):305–12.
- [5] Arnold A, Shun-Shin M, Keene D, Howard J, Sohaib S, Wright I, Cole G, Qureshi N, Lefroy D, Koa-Wing M, Linton N, Lim P, Peters N, Davies D, Muthumala A, Tanner M, Ellenbogen K, Kanagaratnam P, Francis D, Whinnett Z. His resynchronization versus biventricular pacing in patients with heart failure and left bundle branch block. *J Am Coll Cardiol* 2018;72(24):3112–22.
- [6] Sharma P, Huang H, Trohman R, Naperkowski A, Ellenbogen K, Vijayaraman P. Low fluoroscopy permanent his bundle pacing using electroanatomic mapping. *Circulation: Arrhythmia Electrophysiol* 2019;12(2). <https://doi.org/10.1161/circep.118.006967>.
- [7] Moore JP, Gallotti R, Shannon K, Pilcher T, Vinocur J, Cano O, Kean A, Mondesert B, Nurnberg JH, Schall RD, Sharma PS, Nishimura T, Tung R. Permanent conduction system pacing for congenitally corrected transposition of the great arteries. *Heart Rhythm*, 20; [Epub ahead of print].