

UCLA

UCLA Previously Published Works

Title

Point-of-Care Coating of Revision Femoral Stems With Antibiotic-Loaded Calcium Sulfate: Reduction in Infection After 2nd Stage Reimplantation but Not With Aseptic Revisions.

Permalink

<https://escholarship.org/uc/item/3kz63291>

Authors

McPherson, Edward

Crawford, Brooke

Kenny, Steven

et al.

Publication Date

2024-02-01

DOI


10.1016/j.artd.2023.101302

Copyright Information

This work is made available under the terms of a Creative Commons Attribution-NonCommercial-NoDerivatives License, available at

<https://creativecommons.org/licenses/by-nc-nd/4.0/>

Peer reviewed



Original Research

Point-of-Care Coating of Revision Femoral Stems With Antibiotic-Loaded Calcium Sulfate: Reduction in Infection After 2nd Stage Reimplantation but Not With Aseptic Revisions

Edward J. McPherson, MD ^{a,*}, Brooke M. Crawford, MD ^b, Steven G. Kenny, DO MPH ^c,
Matthew V. Dipane, BS ^a, Shahrzad Salarkia, DNP ^a, Alexandra I. Stavarakis, MD ^a,
Madhav Chowdhry, MBBS ^d

^a Department of Orthopedic Surgery, David Geffen School of Medicine at UCLA, Los Angeles, CA, USA

^b Department of Orthopedic Surgery, The University of Miami Miller School of Medicine, Miami, FL, USA

^c Department of Orthopedic Surgery, The Permanente Medical Group, San Rafael, CA, USA

^d Department of Orthopedic Surgery, Jawaharlal Nehru Medical College, AMU, Aligarh, Uttar Pradesh, India

ARTICLE INFO

Article history:

Received 18 January 2023

Received in revised form

24 August 2023

Accepted 4 November 2023

Available online xxx

Keywords:

Revision

Total hip arthroplasty

Calcium sulfate

Point of care

Antibiotic coating

ABSTRACT

Background: Infection rates in revision total hip arthroplasty are lower when antibiotic loaded cemented stems are utilized. Inspired by this technique, a point-of-care coating of antibiotic-loaded calcium sulfate (CaSO₄) was applied to cementless revision stems in aseptic revision and 2nd stage reimplantation total hip arthroplasty.

Methods: One hundred eleven consecutive femoral stems were coated. Just prior to insertion, 10 cc of CaSO₄ was mixed with 1 g vancomycin and 240 mg tobramycin with the paste applied to the stem. The results were compared to a matched cohort (N = 104) performed across the previous 5 years. The surgical methods were comparable, but for the stem coating. The study group was followed for a minimum of 3 years.

Results: In the study cohort of 111 patients, there were 69 aseptic revisions with one periprosthetic joint infection (PJI) (1.4%) and 42 second-stage reimplantations with 2 PJIs (4.8%). In the control cohort of 104 patients, there were 74 aseptic revisions with one PJI (1.4%) and 30 second-stage reimplantations with 7 PJIs (23.3%). There was no significant reduction in PJI rate in the aseptic revision subgroup (1.4% study vs 1.4% control group), $P = 1.000$. Antibiotic stem coating reduced PJI rate in the 2nd stage reimplantation subgroup (23.3% control vs 4.8% study group), $P = .028$. In both groups, there were no cases of aseptic stem loosening.

Conclusions: Point-of-care antibiotic coating of cementless revision femoral stems reduces PJI infection rate in 2nd stage reimplantations only. We theorize that microbes persist in the endosteal cortices after resection and may contribute to infection recurrence.

© 2023 The Authors. Published by Elsevier Inc. on behalf of The American Association of Hip and Knee Surgeons. This is an open access article under the CC BY-NC-ND license (<http://creativecommons.org/licenses/by-nc-nd/4.0/>).

Introduction

The rise in the number of total hip arthroplasty (THA) procedures performed worldwide suggests a concordant rise in associated complications requiring revision surgery [1]. One of the most dreaded complications is periprosthetic joint infection (PJI).

Unfortunately, the incidence of PJI in THA has remained relatively steady in the last 2 decades [2]. Treatment of an established chronic PJI is an aggressive exchange protocol [3]. PJI recurrence after a 2-stage exchange protocol is considered limb-threatening and even life-threatening [4–6]. In fact, PJI after an aseptic revision THA connotes a similar fate. Prevention of PJI in reimplantation/revision of THA is hence emphasized.

Antibiotic-loaded polymethylmethacrylate has been an important method of antibiotic delivery to endosteal bone in revision/reimplantation THA. In registry studies, the survivorship of aseptic revision THA and 2nd stage reimplantation THA for PJI is best when

* Corresponding author. David Geffen School of Medicine at UCLA, Department of Orthopaedic Surgery, 1250 16th Street, Suite 2100, Santa Monica, CA 90404, USA. Tel.: +1 424 259 8598.

E-mail address: edmcpherson@gmail.com

intravenous antibiotics and antibiotic-loaded cement are used concurrently [7]. However, studies have shown that aseptic loosening rates of cemented revision THA are significant in the intermediate term [8–11]. Therefore, in most countries where the financial environment is suitable, cementless implants, which allow for biologic integration, are the preferred choice for aseptic revision and reimplantation THA [12].

The use of cementless femoral stems raises concern for an increased rate of PJI as antibiotic(s) are not applied around the stem. To provide endosteal antibiotic delivery, in this study, a point-of-care antibiotic-loaded coating of pharmaceutical-grade calcium sulfate (CaSO_4) was applied to cementless revision stems in revision/2nd stage reimplantation THA. Our study attempted to answer 2 key questions: 1) Does the coating of cementless revision stems with antibiotic-loaded calcium sulfate (AL- CaSO_4) reduce the occurrence of PJI after aseptic revision THA and 2nd stage reimplantation THA? 2) Does the coating of cementless revision stems with calcium sulfate affect stem fixation?

Material and methods

From December 2010 to December 2015, all cementless femoral stems were coated with pharmaceutical-grade, antibiotic-loaded CaSO_4 (AL- CaSO_4) in patients undergoing a complete (cup and stem) aseptic revision/2nd stage reimplantation of THA. Preoperatively, all patients were graded for PJI risk with host and limb scores [13,14]. A minimum 3-year follow-up was required for inclusion in the study. For comparison, a retrospective cohort from the previous 5 years was established matching the study group in diagnosis, demographics, and PJI host grade. There were no patients excluded from the comparison group. This study received institutional review board approval.

Preoperatively, all patients required a serum erythrocyte sedimentation rate (ESR) and quantitative C-reactive protein (CRP). All hips were preoperatively aspirated by the operating surgeon. All cultures were grown for 14 days on multiple culture mediums [15,16]. To be categorized into the aseptic revision THA subgroup, patients required a normal preoperative ESR and quantitative CRP and negative culture growth on all media. In the patient subgroup treated for PJI, chronic PJI was defined based on the guidelines set by the International Consensus Group on Periprosthetic Joint Infection [17]. In this study, all chronic PJI cases were treated with a 2-stage exchange protocol. The hip was stabilized with a cemented ProstALAC (Prothesis Antibiotic Loaded Acrylic Cement) spacer. Patients were treated with IV antibiotics for 42 days. Serum blood tests and reaspiration were performed 2 weeks after cessation of IV antibiotics. Reimplantation surgery was typically performed at 3

months, when aspiration studies were negative and serum CRP and ESR normalized. For all resection and 2nd stage reimplantation procedures, 6 intraoperative cultures were obtained, which included specimens from mid- and distal diaphysis.

A standard perioperative prophylactic antibiotic regimen was used in all cases for 3 days. This consisted of intravenous vancomycin and cefazolin. In 2-stage reimplantation procedures, intravenous antibiotics were continued until cultures were reviewed at 5 days. In the case of a reimplantation procedure with a previous gram-negative infection, vancomycin was exchanged with the antibiotic selected to treat the infecting organism(s) in the first stage of the procedure.

All surgeries in this study were performed with an extended posterolateral approach by the senior surgeon [18]. For aseptic revisions, perioperative intravenous antibiotics were started 30 minutes prior to incision and continued for 24 hours. For 2nd stage reimplantation procedures, parenteral antibiotics were continued for 5 days. The revision implant system(s) remained consistent throughout the study. On the acetabular side, pelvic/acetabular deficiencies, when large, were reconstructed with a cementless custom multi-flange porous pelvic implant (Zimmer-Biomet, Warsaw) or an off-the-shelf triflange cage (MaxTi, Zimmer-Biomet, Warsaw). The remaining acetabular implants utilized were metal-backed hemisphere cups with porous plasma spray (RB and Dp+5, Zimmer-Biomet, Warsaw). All femoral stems utilized were from the Zimmer-Biomet revision family (Mallory Head Modular Revision or Arcos Modular Revision Stem). Modularity was used to provide maximum implant-bone contact, both proximally and distally. Femoral stems were either fully porous-coated or spline-tapered grit-blasted diaphyseal stems.

The calcium sulfate medium used to coat the femoral stem was Stimulan (Biocomposites, Keele, UK). The antibiotics added were a preset protocol of 1 gram of vancomycin powder and 240 mg of liquid tobramycin (6 cc) mixed into 10 cc of CaSO_4 powder. The antibiotic doses were not altered in patients with chronic kidney disease. The AL- CaSO_4 was mixed, and once it was in an early doughy state (approximately 3 minutes), the stem was coated via finger application to cover the entire stem (Fig. 1a and b). The amount of AL- CaSO_4 required to coat each femoral stem was approximately 5–8 cc, depending on the stem length. Once coated, the stem was immediately inserted before the CaSO_4 set. The top surgical gloves were changed just before coating and insertion of the femoral implant. A multilayered closure was performed using all absorbable sutures. Clinical follow-up of all patients was conducted at 6 weeks, 12 weeks, 6 months, and yearly thereafter.

Statistical analyses were performed using SPSS for Windows (Version 21.0, SPSS Inc., Chicago). Proportions of patients with

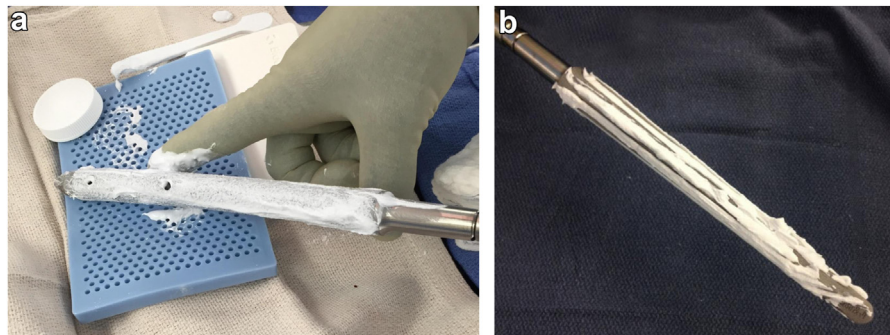


Figure 1. (a, b) Photographs demonstrating point-of-care application of antibiotic-loaded CaSO_4 (ALCS) onto revision femoral stems. The ALCS is applied to the revision stem immediately prior to insertion. The CaSO_4 is spread by finger approximately 3 minutes post-mix to cover the entire modular femoral stem. (a) Application of antibiotic-loaded CaSO_4 onto a fully porous-coated modular femoral stem. Note this stem has holes for distal stem interlocking screws. (b) Application of antibiotic-loaded CaSO_4 onto a grit-blasted spline-tapered modular femoral stem. Once applied, a finger was used to spread the CaSO_4 paste over the entire stem surface.

Table 1
Reasons for aseptic revision THA.

Etiology	Study group	Control group
Implant loosening / mechanical breakage osteolysis	29	36
Malpositioning / prosthetic femoral-acetabular impingement (PFAL)	14	10
Hip instability	5	7
Periprosthetic fracture	9	14
Complex primary (due to fracture or bony deformity)	5	2
Pseudotumor formation / particle wear debris with well-fixed implants	3	0
Protrusion pelvic deformity with or without pelvic discontinuity	4	5

recurrent infection in the study and control groups were compared using Pearson's chi-square test and Fisher's exact test when a group number was less than 5. A *P*-value of less than .05 was considered statistically significant.

Results

The study group of 111 patients consisted of 53 males and 58 females. The mean age was 66.1 years (32–100 years). The mean follow-up was 56.6 months (36–108 months). There were 46 A-hosts, 56 B-hosts, and 9 C-hosts. Sixty-nine patients underwent aseptic revisions. The primary reasons for aseptic revision are listed in Table 1. Forty-two patients underwent a 2nd stage reimplantation procedure for PJI. Ninety-three percent of stems were of spline design, and 7% were porous. There were no aseptically loose femoral stems. We did not experience any cases of acute kidney injury attributable to the use of the AL-CaSO₄ coating.

The overall occurrence of PJI in the study group was 2.7% (3 of 111). In the aseptic revision subgroup, there was 1 infection out of 69 patients (1.4%) that occurred in a C-host. The patient was treated with a resection arthroplasty but suffered a recurrent infection and eventually had a hip disarticulation. In the 2nd stage reimplantation subgroup, there were 2 infections out of 42 patients (4.8%). Both were treated with a repeat 2-stage exchange protocol. The PJIs occurred in 1 A-host and 1 B-host. The organisms grown in the infection failures are listed in Table 2.

The control group of 104 patients consisted of 49 males and 55 females. The mean age was 65.5 years (37–87 years). The mean follow-up was 117.5 months (96–156 months). According to host staging, there were 45 A-hosts, 52 B-hosts, and 7 C-hosts. Seventy-four patients underwent aseptic revisions. Thirty patients

underwent a 2nd stage reimplantation procedure for PJI. Ninety-one percent of stems were of spline design, and 9% were porous. There were no aseptically loose femoral stems.

The overall occurrence of PJI in the control group was 7.7% (8 of 104). In the aseptic revision subgroup, there was 1 infection out of 74 patients (1.4%), which occurred in an A-host. The PJI was treated with a repeat 2-stage exchange protocol. In the 2nd stage reimplantation subgroup, there were 7 infections out of 30 patients (23.3%). All 7 were treated with a repeat 2-stage exchange protocol. The PJIs occurred in 2 A-hosts, 3 B-hosts, and 2 C-hosts. The organisms grown in the infection failures are listed in Table 2.

There was no statistically significant difference in PJI occurrence in the aseptic revision subgroup (1.4% study vs 1.4% control) (*P* = 1.000). In the 2nd stage reimplantation subgroup, there was a significant reduction of PJI occurrence in the study group (4.8% study vs 23.3% control) (*P* = .028).

The mean time for PJI occurrence postprocedure in the study group was 14.7 months (8 to 23). The mean time for PJI occurrence postprocedure in the control group was 9.4 months (3 to 17 months). In the study group, there were 3 reoperations that were not infection-related, while there were 5 reoperations in the control group that were not infection-related. The reasons for reoperation are listed in Table 3.

Finally, the relation of PJI host grade and PJI occurrence was analyzed using a 3-way contingency table. When combining control and study groups together, a worse host grade was significantly associated with PJI occurrence (*P* = .036).

Discussion

This study is the first of its kind to utilize a point-of-care coating of antibiotics on cementless revision femoral stem implants. This method is our strategy of applying an antibiotic coating in the similar "antibiotic delivery zone" as would be seen in an antibiotic-loaded, cemented revision femoral stem. The point-of-care application using AL-CaSO₄ was chosen for several reasons. First, medical-grade CaSO₄ is at present the only US-FDA (United States Food & Drug Administration)-approved product for use in the presence of a bone infection [19]. Secondly, antibiotic loaded CaSO₄ in the form of antibiotic-loaded beads has been utilized for over 2 decades, mainly in PJI treatment, which provides a basis of experience [20]. There are now multiple published antibiotic formulas/combinations [19]. Thirdly, in laboratory studies, AL-CaSO₄ beads do produce significant local antibiotic gradients that extend beyond 10 days [21–26]. Hence, with the application of AL-CaSO₄ to a femoral cementless stem, antibiotic gradients may be adequate to

Table 2
Identified organisms in cases that developed infection.

Study group			Control group		
Case	Organism(s)	Host grade	Case	Organism(s)	Host grade
Case #1 (Aseptic)	Staphylococcus epidermidis, Enterococcus faecium	C	Case #4 (Aseptic)	Methicillin-resistant Staphylococcus aureus (MRSA)	A
Case #2 (2 nd Stage)	Staphylococcus epidermidis	A	Case #5 (2 nd Stage)	MRSA	A
Case #3 (2 nd Stage)	Staphylococcus hominis, Vancomycin Resistant Enterococcus species	B	Case #6 (2 nd Stage)	MRSA, Enterococcus faecalis, Ochrobactrum anthropic	A
			Case #7 (2 nd Stage)	Staphylococcus aureus, Enterococcus faecalis	B
			Case #8 (2 nd Stage)	MRSA, Streptococcus agalactiae, Enterococcus faecium	B
			Case #9 (2 nd Stage)	No bacteria identified	B
			Case #10 (2 nd Stage)	Staphylococcus epidermidis, Klebsiella pneumoniae	C
			Case #11 (2 nd Stage)	MRSA	C

Table 3
Primary reasons for aseptic reoperations.

Failure type	Study group	Control group
Painful hardware (Troch Claw)	1	2
Recurrent dislocation	1	1
Aseptic cup loosening	1	0
Periprosthetic fracture	0	2

affect microbial reserves within bone, if present. Finally, we emphasize the use of a synthetic, pharmaceutical-grade calcium sulfate. Some calcium sulfate products are mined and then refined. Impurities within the mined and refined products are fraught with inconsistencies in setting and local antibiotic delivery [25]. We believe that synthetic products allow for consistent mixing and timing for application to a cementless stem.

Our results showed no difference in PJI occurrence in aseptic revisions with the application of AL-CaSO₄ to a cementless femoral stem. This is encouraging in that, with extensive femoral canal exposure and extended surgical times in revision THA, the microbial contamination risk is higher. The occurrence of infection after an aseptic revision was low—less than 2% in both groups. We believe this is due to our meticulous precautions and asepsis protocols practiced by our center in the operating room. These results suggest that in the aseptic revision population, an adjuvant antibiotic coating of the femoral stem is not necessary. Maintaining good surgical technique, combined with perioperative parenteral antibiotics seems to suffice.

The control cohort had a high relative rate of reinfection compared to the literature (23.3%). Both cohorts had a high proportion of B & C hosts that typically have higher rates of reinfection and amputation [14,27]. Our philosophy was to provide reimplantation to all patients at least once (including C-hosts). Hence, our reduction of infection recurrence in the study group is significant. In fact, the PJI reoccurrence in the 2nd stage reimplantation study group showed similar efficacy to reported 2nd stage reimplantation procedures that employ antibiotic-loaded cemented femoral stems [6,28,29]. We theorize that PJI occurrence was reduced because the applied antibiotic coating affects microbial reserves within the femoral endosteal bone network similar to antibiotic-loaded cement.

It is possible that the application of an antibiotic coating may just delay the reactivation of microbial dormant colonies within the endosteal canalicular network [30–33]. This is supported by the later occurrence of PJI in the study group. However, at our center, we choose a combined antibiotic regimen of vancomycin and tobramycin. This combination may effectively improve eradication of remaining endosteal microbial reserves. This is based on the synergistic effect of vancomycin when combined with an aminoglycoside [34,35]. Much more rigorous studies will be required to validate this contention.

The application of AL-CaSO₄ to cementless femoral revision stems did not adversely affect fixation of these implants. It has been suggested that an applied coating of CaSO₄ may “plug” the porous and grit surfaces, inhibiting bone integration into the stem [36]. Our findings refute this idea, as there were no cases of aseptic stem loosening in our study group. Most cases of subsidence of cementless femoral stems occur during the first year post-operatively [37]. In our study group, with a mean follow-up time of 57 months, there were no cases of aseptic stem loosening of the AL-CaSO₄-coated stems. Finally, the use of 5–8 cc of AL-CaSO₄ applied to a femoral stem was salutary. Kallala et al. demonstrated that this modest volume is unlikely to incur a systemic side effect(s), such as hypercalcemia and/or nephrotoxicity [20].

The strengths of this study are several. First, all procedures were performed by a single surgeon with a consistent practice of difficult revision THA procedures and periprosthetic infections. Surgical bone and soft tissue debridement was consistent and substantial. There was a relatively good match of PJI host grades between the groups, and there were an adequate number of reimplantation cases in each group. There was no change in implant systems, style, or technique. This allowed for a relatively good comparison between the 2 groups.

The criticisms of this study are several. With a single-surgeon study, the number of patients in the study group is small. There is also an issue of wisdom bias. The study group was compared to a matched group 5 years prior. As surgical experience improves over time, it is possible that the surgeon becomes better at debridement of bone and soft tissue, thus improving the success of the study group. Finally, this study was neither randomized nor a multicenter study. A true validation of our study findings would be to apply the stem coating with multiple surgeons employing disparate surgical techniques and implant systems at multiple revision centers.

Conclusions

A point-of-care application of antibiotic-loaded pharmaceutical-grade CaSO₄ was applied to cementless revision femoral stems during aseptic revision THA and 2nd stage reimplantation THA. The AL-CaSO₄ coating of revision femoral stems reduced PJI occurrence in 2nd stage reimplantation procedures only. The calcium sulfate coating did not adversely affect fixation of cementless revision femoral stems. This is a small study group identifying an interesting result that needs to be corroborated with much more rigorous study. A larger, randomized multicenter study will be required to elaborate upon our initial findings.

Conflicts of interest

A. Stavrakis is a paid consultant for Smith & Nephew. E. McPherson is a paid consultant for Zimmer-Biomet, Warsaw, IN, and Austin Medical Ventures Inc.; receives financial support from JBJS-Miller Orthopaedic Review: author & faculty; is an editorial board member of Reconstructive Review; and board member of Joint Implant Surgery Research Foundation. All other authors declare no potential conflicts of interest. For full disclosure statements refer to <https://doi.org/10.1016/j.artd.2023.101302>.

References

- Healy WL, Iorio R, Clair AJ, Pellegrini VD, Della Valle CJ, Berend KR. Complications of total hip arthroplasty: standardized list, definitions, and stratification developed by the hip society. *Clin Orthop Relat Res* 2016;474:357–64. <https://doi.org/10.1007/s11999-016-4804-5>.
- Xu C, Goswami K, Li WT, Tan TL, Yayac M, Wang SH, et al. Is treatment of periprosthetic joint infection improving over time? *J Arthroplasty* 2020;35:1696–16702.e1. <https://doi.org/10.1016/j.arth.2020.01.080>.
- Izakovicova P, Borens O, Trampuz A. Periprosthetic joint infection: current concepts and outlook. *EFORT Open Rev* 2019;4:482–94. <https://doi.org/10.1302/2058-5241.4.180092>.
- Brown TS, Fehring KA, Ollivier M, Mabry TM, Hanssen AD, Abdel MP. Repeat two-stage exchange arthroplasty for prosthetic hip re-infection. *Bone Joint J* 2018;100-B:1157–61. <https://doi.org/10.1302/0301-620X.100B9.BJJ-2018-0470.R1>.
- Khan N, Parmar D, Ibrahim MS, Kayani B, Haddad FS. Outcomes of repeat two-stage exchange hip arthroplasty for prosthetic joint infection. *Bone Joint J* 2019;101-B:110–5. <https://doi.org/10.1302/0301-620X.101B6.BJJ-2018-1556.R1>.
- Kunutsor SK, Whitehouse MR, Blom AW, Beswick AD, Team I. Re-infection outcomes following one- and two-stage surgical revision of infected hip prosthesis: a systematic review and meta-analysis. *PLoS One* 2015;10:e0139166. <https://doi.org/10.1371/journal.pone.0139166>.
- Engesaeter LB, Lie SA, Espehaug B, Furnes O, Vollset SE, Havelin LI. Antibiotic prophylaxis in total hip arthroplasty: effects of antibiotic prophylaxis

- systemically and in bone cement on the revision rate of 22,170 primary hip replacements followed 0–14 years in the norwegian arthroplasty register. *Acta Orthop Scand* 2003;74:644–51. <https://doi.org/10.1080/00016470310018135>.
- [8] Callaghan JJ, Salvati EA, Pellicci PM, Wilson Jr PD, Ranawat CS. Results of revision for mechanical failure after cemented total hip replacement, 1979 to 1982. A two to five-year follow-up. *J Bone Joint Surg Am* 1985;67:1074–85.
- [9] Hunter GA, Welsh RP, Cameron HU, Bailey WH. The results of revision of total hip arthroplasty. *J Bone Joint Surg Br* 1979;61-B:419–21. <https://doi.org/10.1302/0301-620X.61B4.500750>.
- [10] Schmale GA, Lachiewicz PF, Kelley SS. Early failure of revision total hip arthroplasty with cemented precoated femoral components: comparison with uncemented components at 2 to 8 years. *J Arthroplasty* 2000;15:718–29. <https://doi.org/10.1054/arth.2000.6623>.
- [11] Nouri H, Kallel S, Hadj Slimane M, Meherzi MH, Ouertatani M, Karray S. Revision total hip arthroplasty with cemented femoral component. *Eur J Orthop Surg Traumatol* 2008;18:327–32. <https://doi.org/10.1007/s00590-008-0310-0>.
- [12] Chareancholvanich K, Tanchuling A, Seki T, Gustilo RB. Cementless acetabular revision for aseptic failure of cemented hip arthroplasty. *Clin Orthop Relat Res* 1999;140–9. <https://doi.org/10.1097/00003086-199904000-00019>.
- [13] McPherson EJ. Musculoskeletal infection. In: Flynn JM, editor. *American academy of orthopaedic surgeons. OKU 10: orthopaedic knowledge update*. Rosemont, IL: American Academy Of Orthopaedic Surgeons; 2011. p. 239–58.
- [14] McPherson EJ, Woodson C, Holtom P, Roidis N, Shufelt C, Patzakis M. Peri-prosthetic total hip infection: outcomes using a staging system. *Clin Orthop Relat Res* 2002;8–15.
- [15] Schafer P, Fink B, Sandow D, Margull A, Berger I, Frommelt L. Prolonged bacterial culture to identify late periprosthetic joint infection: a promising strategy. *Clin Infect Dis* 2008;47:1403–9. <https://doi.org/10.1086/592973>.
- [16] Williams JL, Norman P, Stockley I. The value of hip aspiration versus tissue biopsy in diagnosing infection before exchange hip arthroplasty surgery. *J Arthroplasty* 2004;19:582–6. <https://doi.org/10.1016/j.arth.2003.11.011>.
- [17] Parvizi J, Gehrke T, Chen AF. Proceedings of the international consensus on periprosthetic joint infection. *Bone Joint J* 2013;95-B:1450–2. <https://doi.org/10.1302/0301-620X.95B11.33135>.
- [18] Hoppenfeld S, deBoer P, Buckley R. *Surgical Exposures in Orthopaedics: The Anatomic Approach*. 5th ed. Philadelphia, PA: Lippincott Williams & Wilkins; 2016.
- [19] McPherson EJ, Dipane MV, Chowdhry M, Wassef AJ. Fabrication of antibiotic-loaded dissolvable calcium sulfate beads: an in vitro mixing lab utilizing various antibiotic mixing formulas. *J Bone Jt Infect* 2021;6:405–12. <https://doi.org/10.5194/jbji-6-405-2021>.
- [20] Kallala R, Harris WE, Ibrahim M, Dipane M, McPherson E. Use of stimulan absorbable calcium sulphate beads in revision lower limb arthroplasty: safety profile and complication rates. *Bone Joint Res* 2018;7:570–9. <https://doi.org/10.1302/2046-3758.710.BJR-2017-0319.R1>.
- [21] Moore K, Os RW, Dusane DH, Brooks JR, Delury C, Aiken SS, et al. Elution kinetics from antibiotic-loaded calcium sulfate beads, antibiotic-loaded polymethacrylate spacers, and a powdered antibiotic bolus for surgical site infections in a novel in vitro draining knee model. *Antibiotics (Basel)* 2021;10:270–82. <https://doi.org/10.3390/antibiotics10030270>.
- [22] Sindeldecker D, Moore K, Li A, Wozniak DJ, Anderson M, Dusane DH, et al. Novel aminoglycoside-Tolerant Phoenix colony variants of *Pseudomonas aeruginosa*. *Antimicrob Agents Chemother* 2020;64:e00623–20. <https://doi.org/10.1128/AAC.00623-20>.
- [23] Sindeldecker D, Stoodley P. The many antibiotic resistance and tolerance strategies of *pseudomonas aeruginosa*. *Biofilm* 2021;3:100056. <https://doi.org/10.1016/j.biofilm.2021.100056>.
- [24] Brooks JR, Dusane DH, Moore K, Gupta T, Delury C, Aiken SS, et al. *Pseudomonas aeruginosa* biofilm killing beyond the spacer by antibiotic-loaded calcium sulfate beads: an in vitro study. *J Bone Jt Infect* 2021;6:119–29. <https://doi.org/10.5194/jbji-6-119-2021>.
- [25] McPherson EJ, Jennings JA, Yunis O, Harris MA, Dipane MV, Curtin NL, et al. Simulated large joint fluid model for evaluating intra-articular antibiotic delivery systems: initial evaluation using antibiotic-loaded calcium sulfate beads. *J Bone Jt Infect* 2022;7:117–25. <https://doi.org/10.5194/jbji-7-117-2022>.
- [26] Wahl P, Guidi M, Benninger E, Ronn K, Gautier E, Buclin T, et al. The levels of vancomycin in the blood and the wound after the local treatment of bone and soft-tissue infection with antibiotic-loaded calcium sulphate as carrier material. *Bone Joint J* 2017;99-B:1537–44. <https://doi.org/10.1302/0301-620X.99B11.BJJ-2016-0298.R3>.
- [27] McPherson EJ, Tontz Jr W, Patzakis M, Woodsome C, Holtom P, Norris L, et al. Outcome of infected total knee utilizing a staging system for prosthetic joint infection. *Am J Orthop (Belle Mead NJ)* 1999;28:161–5.
- [28] Lee YS, Chen AF. Two-stage reimplantation in infected total knee arthroplasty. *Knee Surg Relat Res* 2018;30:107–14. <https://doi.org/10.5792/ksrr.17.095>.
- [29] Corona PS, Vicente M, Carrera L, Rodriguez-Pardo D, Corro S. Current actual success rate of the two-stage exchange arthroplasty strategy in chronic hip and knee periprosthetic joint infection. *Bone Joint J* 2020;102-B:1682–8. <https://doi.org/10.1302/0301-620X.102B12.BJJ-2020-0792.R1>.
- [30] Hamad C, Chowdhry M, Sindeldecker D, Bernthal NM, Stoodley P, McPherson EJ. Adaptive antimicrobial resistance, a description of microbial variants, and their relevance to periprosthetic joint infection. *Bone Joint J* 2022;104-B:575–80. <https://doi.org/10.1302/0301-620X.104B5.BJJ-2021-1759.R1>.
- [31] Zoller SD, Hegde V, Burke ZDC, Park HY, Ishmael CR, Blumstein GW, et al. Evading the host response: staphylococcus “hiding” in cortical bone canalicular system causes increased bacterial burden. *Bone Res* 2020;8:43–53. <https://doi.org/10.1038/s41413-020-00118-w>.
- [32] de Mesy Bentley KL, Trombetta R, Nishitani K, Bello-Irizarry SN, Ninomiya M, Zhang L, et al. Evidence of staphylococcus aureus deformation, proliferation, and migration in canaliculi of live cortical bone in murine models of osteomyelitis. *J Bone Miner Res* 2017;32:985–90. <https://doi.org/10.1002/jbmr.3055>.
- [33] de Mesy Bentley KL, MacDonald A, Schwarz EM, Oh I. Chronic osteomyelitis with staphylococcus aureus deformation in submicron canaliculi of osteocytes: a case Report. *JBJS Case Connect* 2018;8:e8–14. <https://doi.org/10.2106/JBJS.CC.17.00154>.
- [34] Gonzalez Della Valle A, Bostrom M, Brause B, Harney C, Salvati EA. Effective bactericidal activity of tobramycin and vancomycin eluted from acrylic bone cement. *Acta Orthop Scand* 2001;72:237–40. <https://doi.org/10.1080/00016470152846547>.
- [35] Watanakunakorn C, Tison JC. Synergism between vancomycin and gentamicin or tobramycin for methicillin-susceptible and methicillin-resistant staphylococcus aureus strains. *Antimicrob Agents Chemother* 1982;22:903–5. <https://doi.org/10.1128/AAC.22.5.903>.
- [36] Yashavantha Kumar C, Nalini KB, Menon J, Patro DK, Banerji BH. Calcium sulfate as bone graft substitute in the treatment of osseous bone defects, a prospective study. *J Clin Diagn Res* 2013;7:2926–8. <https://doi.org/10.7860/JCDR/2013/6404.3791>.
- [37] Stihsen C, Radl R, Keshmiri A, Rehak P, Windhager R. Subsidence of a cementless femoral component influenced by body weight and body mass index. *Int Orthop* 2012;36:941–7. <https://doi.org/10.1007/s00264-011-1360-1>.