

UC San Diego

UC San Diego Previously Published Works

Title

Osteochondral lesions in Wilsons disease: case report and literature review.

Permalink

<https://escholarship.org/uc/item/3jk283m3>

Authors

Valmadrid, Luke

Lystad, Heather

Smitaman, Edward

et al.

Publication Date

2024

DOI

10.21037/acr-23-217

Copyright Information

This work is made available under the terms of a Creative Commons Attribution-NonCommercial-NoDerivatives License, available at

<https://creativecommons.org/licenses/by-nc-nd/4.0/>

Peer reviewed



Osteochondral lesions in Wilson's disease: case report and literature review

Luke Carmichael Valmadrid^{1^}, Heather Lystad^{1^}, Edward Smitaman^{2^}, Kenneth Vitale^{3^}

¹University of California San Diego School of Medicine, La Jolla, CA, USA; ²Division of Musculoskeletal Imaging, Department of Radiology, University of California San Diego School of Medicine, La Jolla, CA, USA; ³Department of Orthopaedic Surgery, University of California San Diego School of Medicine, La Jolla, CA, USA

Contributions: (I) Conception and design: K Vitale; (II) Administrative support: LC Valmadrid, K Vitale; (III) Provision of study materials or patients: K Vitale; (IV) Collection and assembly of data: LC Valmadrid; (V) Data analysis and interpretation: E Smitaman, K Vitale, LC Valmadrid; (VI) Manuscript writing: All authors; (VII) Final approval of manuscript: All authors.

Correspondence to: Luke Carmichael Valmadrid, MPH. University of California San Diego School of Medicine, 9500 Gilman Dr, La Jolla, CA 92093, USA. Email: lvalmadrid@health.ucsd.edu; Kenneth Vitale, MD, FACSM, FAAPMR. Department of Orthopaedic Surgery, University of California San Diego School of Medicine, 9500 Gilman Dr, La Jolla, CA 92093, USA. Email: kvitale@health.ucsd.edu.

Background: Wilson's disease (WD) is a rare genetic disorder characterized by copper accumulation in the body, leading to a spectrum of health issues, such as liver disease, neurological disturbances, and psychiatric disorders. In recent years, there has been increasing recognition that WD can also result in osteoarticular defects. Research has shed light on the potential of WD to cause these findings, which in some instances, can progress to osteoarthritis and persistent pain. However, the exact pathophysiological process through which WD leads to osteochondral defects remains unclear.

Case Description: We present a case of a 30-year-old male diagnosed with WD exhibiting musculoskeletal symptoms. The patient's medical history revealed chronic intermittent knee pain. Radiographic and magnetic resonance imaging (MRI) studies revealed a substantial osteochondral lesion with high-grade chondral fissuring. This report reviews the proposed pathophysiology of orthopedic pathology in WD, offers an updated literature review, and provides clinical recommendations for management. Treatment options including nonsurgical options and surgery are discussed.

Conclusions: This case underscores the significance of identifying the orthopedic manifestations of WD, even in the absence of classic signs and symptoms. Any WD patient suspected of having osteoarticular defects should be thoroughly evaluated, with a low threshold for initiating imaging studies. Moreover, treatment plans should be tailored to the patient's specific presentation, emphasizing the importance of individualized patient care. This case highlights key findings in WD and provides important insights, particularly on the clinical relevance of osteoarticular defects in WD, the potential application of nonsurgical and surgical treatments, and the importance of individualized patient care in the management of WD.

Keywords: Wilson's disease (WD); osteochondritis dissecans; knee pain; diagnostic imaging; case report

Received: 13 January 2024; Accepted: 21 May 2024; Published online: 05 July 2024.

doi: 10.21037/acr-23-217

View this article at: <https://dx.doi.org/10.21037/acr-23-217>

[^] ORCID: Luke Carmichael Valmadrid, 0000-0003-3069-4114; Heather Lystad, 0009-0002-8502-2235; Edward Smitaman, 0000-0002-7854-7052; Kenneth Vitale, 0000-0001-9633-1928.

Introduction

Background

Wilson's disease (WD) is a monogenic, autosomal recessive disease caused by a mutation in ATP7B, a copper-transporting P-type ATPase. ATP7B plays key roles in the liver in both the delivery of copper to the secretory pathway and the excretion of excess copper in bile (1). As a result of ATP7B mutations, copper eventually accumulates and deposits in various organs, including the liver, brain, kidneys, corneas, and cardiac muscle. Excess intracellular copper leads to increased oxidative stress and ultimately dysfunction of the affected organs (2). In addition to the well-documented hepatic, neurologic, ophthalmic, hematologic, and psychiatric abnormalities associated with WD, patients may also experience a variety of related osteoarticular pathology (3-5). However, musculoskeletal complaints are rarely amongst the presenting symptoms (6) and medical care is often thus focused on hepatic and neurologic manifestations, leading to a relative paucity of literature on the osteoarticular defects of WD (7).

The knees are the most commonly involved joints in WD, with nonspecific arthralgia being a common complaint (5,8). This can cause many of the initial presenting signs of joint damage to be overlooked. Overtime, radiographic

findings emerge, including subchondral sclerosis, chondrocalcinosis, osteochondritis dissecans, subchondral cysts, and osteophytes (9-11). Eventually, joint space narrowing progresses, leading to osteoarthritis and possible need for joint replacement.

Rationale and knowledge gap

Despite the presence of known osteochondral changes associated with WD, the mechanism of such insults has yet to be elucidated (12). Additionally, the nonspecific nature of the symptoms may cause these findings to be overlooked.

Objective

We present a case of a patient with WD who presented with musculoskeletal symptoms and osteoarticular defects on imaging, along with an updated literature review on orthopedic pathology in patients with WD. This case highlights the importance of recognizing the orthopedic manifestations of WD, even in the absence of classic signs and symptoms. We present the following case in accordance with the CARE reporting checklist (available at <https://acr.amegroups.com/article/view/10.21037/acr-23-217/rc>).

Case presentation

A 30-year-old male was referred to our Physical Medicine and Rehabilitation clinic for evaluation of primarily left lateral knee pain for about 2 months.

The patient had a past medical history of WD, thrombocytopenia, cirrhosis, and scoliosis with thoracic facet arthropathy for which spinal fusion was performed three and a half months before the current visit. Notably, the patient also had a prior history of chronic intermittent knee pain first documented in our records during his initial WD visit at 17 years of age. He also had prior osteochondritis dissecans in the right knee status post-surgery three years prior to his current presentation for his left knee. There was no prior trauma or inciting event. There were no mechanical symptoms or instability events. The onset was insidious in nature. The knee pain was located in the lateral left knee, worsened with activity, and improved with rest.

Physical examination of the left knee showed no gross effusion, no gross ligamentous instability, and a range of motion of 0–130 degrees. Palpation elicited lateral joint line tenderness with crepitus and the patient reported pain with McMurray's maneuver.

Highlight box

Key findings

- Patients with Wilson's disease (WD) can present with osteoarticular pathology confirmable with X-ray and magnetic resonance imaging.

What is known and what is new?

- WD is known to be associated with pathological osteochondral changes, but the mechanisms underlying these processes have yet to be clarified and there is a paucity of studies on pathophysiology and treatment.
- This manuscript adds to the literature on WD patients with osteochondral disease, provides an investigation around possible mechanisms for the development of disease, and shares expert recommendations for orthopedic workup in WD patients.

What is the implication, and what should change now?

- Non-specific symptoms and the relative rarity of osteochondral disease in WD patients might lead to delayed diagnosis. This manuscript recommends consensus on orthopedic workup in patients with WD, offering screening, diagnostic, and treatment recommendations from clinical experience.

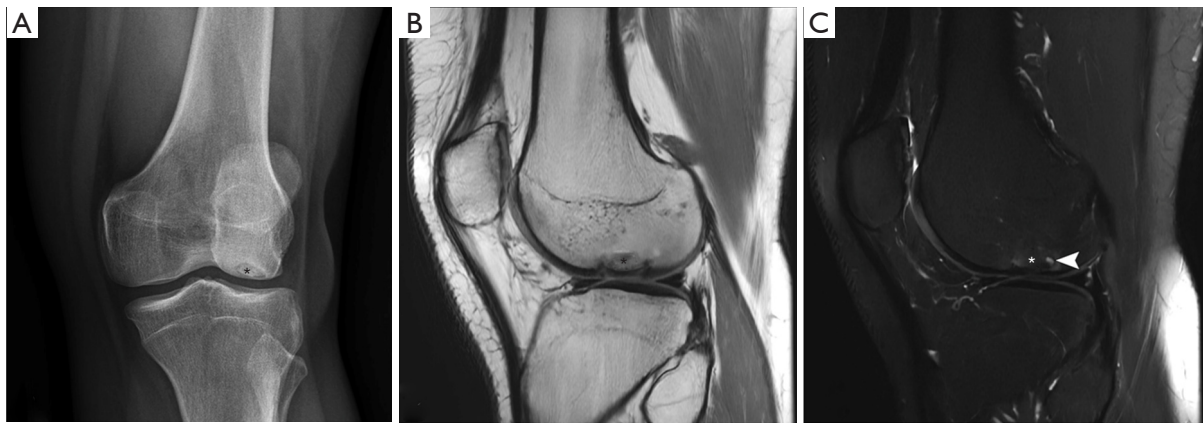


Figure 1 Osteochondral lesion imaging. (A) Frontal radiograph displaying previous osteochondral injury (asterisk) of the lateral femoral condyle. (B) Subsequent sagittal proton density MRI with osteochondral injury (asterisk). (C) T2 fat-suppressed MRI with osteochondral injury (asterisk) and subchondral cystic changes (arrowhead). MRI, magnetic resonance imaging.

Of note, laboratory tests two days before the visit followed the patient's known diagnoses, showing low serum copper (<10 $\mu\text{g/dL}$; normal range, 70–175 $\mu\text{g/dL}$), low ceruloplasmin (3 $\mu\text{g/dL}$; normal range, 18–36 $\mu\text{g/dL}$). Previous labs also showed low serum phosphorous (2.2 mg/dL , normal range, 2.7–4.5 mg/dL) and low 25-OH vitamin D (27 ng/mL ; normal range, 30–100 ng/mL). Blood smear results showed thrombocytopenia ($83 \times 10^3/\mu\text{L}$; normal range, $140 \times 10^3/\mu\text{L}$ – $400 \times 10^3/\mu\text{L}$), mild elevations in both alanine transaminase and aspartate transaminase (ALT/AST), and mild low albumin connected to documented cirrhosis history and splenomegaly.

At this point, the differential diagnosis for lateral knee pain was already narrow due to the patient's prior history of osteochondral disease in the contralateral limb. Aside from osteochondral pathology, lateral meniscal tear, iliotibial band syndrome, discoid lateral meniscus, and hamstring tendinopathy were considered.

Figure 1 shows an osteochondral injury on the lateral femoral condyle of the left knee. The frontal radiograph (Figure 1A) displays a previous osteochondral injury (asterisk) of the lateral femoral condyle, where a depressed ovoid area of subchondral bone is partially outlined by a thin lucency. The subsequent sagittal proton density (Figure 1B) and T2 fat-suppressed (Figure 1C) magnetic resonance imaging (MRI) confirm the osteochondral injury (asterisks) that measures approximately 16 mm \times 12 mm. The injury shows minimal depression of the subchondral bone plate and minimal scattered subchondral cystic changes (arrowhead; Figure 1C), suggesting chronicity with

high-grade chondral fissuring at the margins of this prior likely chronic, osteochondral injury.

Treatment options discussed included physical therapy, activity modification, knee brace, and injections. The patient opted for conservative measures; at follow-up 2 months later, the patient was still experiencing the left lateral knee pain with crepitus. Of note, he also reported continued intermittent and chronic symptoms in the opposite (postsurgical) knee, although compared to the left knee, the right knee symptoms were less bothersome. The left-sided symptoms however had become more pronounced, and the patient wanted to consider surgical options.

He was referred to orthopedic surgery and they discussed the possibility of arthroscopic evaluation with potential debridement and chondroplasty, which would not cure the cartilage injury. However, as the patient seemed to have done well on the contralateral side with a similar surgery, the patient wanted to consider this. The other surgical option was an osteochondral allograft, as other cartilage procedures were not deemed to be effective for him in the context of subchondral involvement. However, after consideration of both surgeries, the patient opted to continue with nonsurgical treatments including physical therapy, and also tried hyaluronic acid injection. He proceeded with and at 5 months' follow-up, he had not opted for surgery.

All procedures performed in this study were in accordance with the ethical standards of the institutional and/or national research committee(s) and with the Helsinki Declaration (as revised in 2013). Written informed consent

was obtained from the patient for publication of this case report and accompanying images. A copy of the written consent is available for review by the editorial office of this journal.

Discussion

Key findings

We have described a patient with WD presenting with knee pain and osteochondral defects confirmed by X-ray and MRI.

Pathogenesis literature review: comparisons with similar research

Both the pathogenesis of copper retention, and the mechanisms underlying osteochondral changes, remain unclear (11), with alterations in calcium and phosphate metabolism as a highly suspected explanation (13). Patients with WD, as in our above case, may develop osteochondral defects due to an underlying disorder of the bone. It should be noted that osteoporosis, bone mineral content, bone mineral density, and hypercalciuria have mixed connections to WD in the literature. Even though osteoporosis bears an association with WD, previous work has suggested that no difference exists in bone mineral content or bone mineral density between children with WD and healthy children (14), but that hypercalciuria, a possible downstream consequence of WD, has been associated with lower bone mineral content and bone mineral density (14). Of note in our case, recent labs showed plasma calcium within normal range, 9.5 mg/dL. No urine labs or recent phosphate measurements were taken.

Another possible mechanism is copper accumulation causing hepatocyte damage resulting in a mild and inadequate, but long-term and sub-clinically poor reabsorption of phosphate; over time, this could hypothetically exacerbate bone weakening in areas of microtrauma through routine “wear and tear” injuries that otherwise would not result in osteochondral defects in those without WD. In our case, the patient does have cirrhosis. This mechanism is not well documented. A previously reported case described a patient with metabolic bone disease resulting from Fanconi’s syndrome attributable to WD, where the patient’s labs revealed normal serum calcium (and 25-OH vitamin D levels), but low serum phosphate (15); these similarities were seen in our case. Hypercalciuria and metabolic bone disease have also been

suggested as vehicles through which renal tubular acidosis presents in patients with WD (15,16). However, the patient in our case did not present with evidence of renal tubular acidosis, the primary upstream cause of metabolic bone disease in patients with WD.

Copper has been found in cartilage biopsies during arthropathy evaluation in patients with WD, which suggested copper deposition in cartilage and synovial biopsies as a potential factor in arthropathy etiology (17). Prior investigation of synovial fluid in 7 WD patients with osteoarticular changes have shown various combinations of microvilli formation, intimal cell hyperplasia, fibrin deposits, and chronic inflammatory cell infiltration; however, this was found in some, but not all patients (12), casting potential doubt on this mechanism as well. Though neither copper deposition nor calcium pyrophosphate crystals were identified on analysis, and despite not demonstrating a relationship between synovial membrane findings and radiologic changes, the authors of this study did not exclude chronic irritation from copper overload as a possible contributory mechanism in osteoarticular changes due to WD (12).

Genetic variation in ATP7B mutations might explain different patterns of osteochondral defects, as several gene mutations have been observed. Molecular genetic analysis has revealed at least 300 distinct mutations of ATP7B gene that consist of 21 exons (18). Furthermore, previous radiographic studies containing sets of siblings with WD have found remarkable osteopathic resemblances inside sibling groups (19,20), and a case study of Japanese patients with WD found that all 13 observed mutations had not been previously detected in European or North American patients (21). Therefore, the variety in gene mutations present in different populations studied above may also account for the variability in clinical presentation and the potential variability in pathogenesis mechanisms due to incomplete penetrance and variable expressivity.

Recommendations for workup

From the literature, any patient with pathological fractures presenting with associated neuropsychiatric or hepatic symptoms, or adolescents with unexplained joint pain, effusion, or radiological features of osteoarthritis in the large joints should be screened for possible WD (7,8). Once a diagnosis has been made, however, there is a lack of consensus on orthopedic workup in WD patients, and it is poorly reported. Due to the discussed difficulties

in predicting which WD patients may manifest with orthopedic pathology based on their lab results, the authors recommend that any WD patient with suspected osteochondral defects, or even nonspecific arthralgias as in our case, be considered for X-ray screening. If evidence of osteochondral pathology is noted on imaging, and/or if the patient presents with mechanical symptoms in the knee such as clicking, catching, locking, or popping symptoms, providers should have a low threshold for ordering advanced imaging with MRI.

In one study showing normal bone mineral density between patients with and without WD, routine bone density testing in adults with WD was not recommended unless patients have other risk factors such as severe neurological involvement, low body mass index (BMI), amenorrhea, and/or liver transplant status (22). However, given the unique constellation of symptoms seen in WD patients, practitioners should maintain a level of suspicion for these problems in patients presenting with chronic musculoskeletal complaints that do not improve with standard treatments.

Recommendations for treatment

Regarding treatment of low bone mineral density in general, a recent systematic review and meta-analysis reported that despite the existence of some high-quality studies, more work is warranted to investigate both preventive measures and treatment of WD-associated osteopenia and osteoporosis (23), which the authors agree with and would also extrapolate for WD-associated osteochondral pathology. Although there are no formal guidelines or recommendations, both prevention and treatment of WD-associated osteochondral disease have been reported. One case report recommends that if WD is suspected as the cause of osteochondral disease, prevention of fractures and morbidities should be prioritized by treating with vitamin D, calcium, and phosphorus supplementation, minimizing copper intake, and by chelation therapy if copper accumulation is a likely mechanism (7). The authors would include the caveat of chelation therapy's potential adverse effects in this case (10), such as wound healing, lupus-like symptom flares, and toxic reactions.

One case report reported on a WD patient with osteoarthritic symptoms that gradually improved (24) and one chart review detailed WD-associated arthralgia resolving, both with chelation therapy (6). However, some research with children suggests that routine WD

treatment might not have significant clinical benefit, nor timely benefit, and emphasizes the necessity of additional therapeutic approaches (13). More serious cases of osteochondritis dissecans have been treated with arthroscopy (11), and one case of a bone cyst involving the entire length of the humerus was treated with surgical management (25), otherwise the literature is sparse on clear surgical indications. Lastly, the development of strategic treatment to address any form of hepatic osteodystrophy, a commonly overlooked metabolic bone disorder in patients with chronic liver disease, often cirrhosis, but also cholangitis and cholestatic disease, which can lead to significant bone loss (26,27), requires a stronger understanding of underlying molecular mechanisms (28). This knowledge is essential for developing targeted treatments that can address the underlying cause of the disorder and improve bone health.

Based on the clinical experience of the authors on this paper, for any patient with a history of WD that presents with arthralgias, we recommend imaging studies early to detect osteochondral lesions before they progress. X-rays are simple and cost-effective, but may miss smaller lesions. Therefore, advanced imaging with MRI (or computed tomography if MRI is not obtainable) is recommended. If available, a magnetic resonance arthrogram can be very useful, as it may better differentiate stable lesions from unstable lesions. If fluid is identified behind an osteochondral fragment, the fragment is typically considered unstable and surgical intervention may be indicated to prevent the fragment from displacing.

Smaller osteochondral lesions can often be managed conservatively with protected weight-bearing, knee braces, physical therapy, and hyaluronic acid injections. Regenerative medicine injections such as platelet-rich plasma (PRP) may be an additional option, but currently has little evidence supporting its use in this context. Importantly, patient education and counseling on osteochondral pathology, with the importance of lifestyle and activity modification, is paramount to prevent enlargement and progression of the osteochondral lesions and associated pathology (fragmentation, bone marrow edema, meniscal pathology). These actions may help avoid the need for surgery. Surgical options are available, but do not guarantee improvement. Arthroscopic debridement, fixation with biocomposite headless screws, and chondroplasty may provide some relief, but they do not cure the cartilage injury. Other surgical options include cartilage restoration procedures, such as Osteochondral Autograft Transfer System (OATS), osteochondral autografts, allografts, and

possibly matrix autologous chondrocyte implantation (MACI). These procedures each have their own risks, may not be effective in all cases, and may fail in the long-term, resulting in progression of arthritis. Early detection of osteochondral lesions is therefore critical to prevent the need for surgery.

Conclusions

The pathogenesis of copper retention and the mechanisms underlying osteochondral changes in WD are not fully understood. Possible mechanisms include osteoporosis or other bone disorders, poor reabsorption of phosphate due to hepatocyte damage, hypercalciuria and metabolic bone disease, copper deposition in cartilage and synovial biopsies, and/or genetic variation in ATP7B mutations. Further workup includes early screening with X-rays and MRI for patients with suspected osteochondral defects or nonspecific arthralgias. Routine bone density evaluation is not recommended in adults with WD unless they have other risk factors. Treatment options are not well-established and may vary depending on the individual patient. While the mechanisms underlying osteopathic lesions in WD remain elusive, this case and review offer further characterization of radiographic and clinical findings for this rare disease complication and provides recommendations on workup and treatment in this patient population.

Acknowledgments

We would like to gratefully acknowledge Mini M. Pathria, MD for her radiological interpretation and reference suggestions for this manuscript.

Funding: None.

Footnote

Reporting Checklist: The authors have completed the CARE reporting checklist. Available at <https://acr.amegroups.com/article/view/10.21037/acr-23-217/rc>

Peer Review File: Available at <https://acr.amegroups.com/article/view/10.21037/acr-23-217/prf>

Conflicts of Interest: All authors have completed the ICMJE uniform disclosure form (available at <https://acr.amegroups.com/article/view/10.21037/acr-23-217/coif>). The authors have no conflicts of interest to declare.

Ethical Statement: The authors are accountable for all aspects of the work in ensuring that questions related to the accuracy or integrity of any part of the work are appropriately investigated and resolved. All procedures performed in this study were in accordance with the ethical standards of the institutional and/or national research committee(s) and with the Helsinki Declaration (as revised in 2013). Written informed consent was obtained from the patient for the publication of this case report and accompanying images. A copy of the written consent is available for review by the editorial office of this journal.

Open Access Statement: This is an Open Access article distributed in accordance with the Creative Commons Attribution-NonCommercial-NoDerivs 4.0 International License (CC BY-NC-ND 4.0), which permits the non-commercial replication and distribution of the article with the strict proviso that no changes or edits are made and the original work is properly cited (including links to both the formal publication through the relevant DOI and the license). See: <https://creativecommons.org/licenses/by-nc-nd/4.0/>.

References

1. Barte MY, Lutsenko S. Hepatic copper-transporting ATPase ATP7B: function and inactivation at the molecular and cellular level. *Biometals* 2007;20:627-37.
2. Wu F, Wang J, Pu C, et al. Wilson's disease: a comprehensive review of the molecular mechanisms. *Int J Mol Sci* 2015;16:6419-31.
3. Bandmann O, Weiss KH, Kaler SG. Wilson's disease and other neurological copper disorders. *Lancet Neurol* 2015;14:103-13.
4. Mindelzun R, Elkin M, Scheinberg IH, et al. Skeletal Changes in Wilson's Disease. *Radiology* 1970;94:127-32.
5. Saito T. Presenting symptoms and natural history of Wilson disease. *Eur J Pediatr* 1987;146:261-5.
6. Yu H, Xie JJ, Chen YC, et al. Clinical features and outcome in patients with osseomuscular type of Wilson's disease. *BMC Neurol* 2017;17:34.
7. Bhatnagar N, Lingaiah P, Lodhi JS, et al. Pathological Fracture of Femoral Neck Leading to a Diagnosis of Wilson's Disease: A Case Report and Review of Literature. *J Bone Metab* 2017;24:135-9.
8. Quemeneur AS, Troceno JM, Ea HK, et al. Musculoskeletal conditions associated with Wilson's disease. *Best Practice & Research Clinical Rheumatology* 2011;25:627-36.

9. Aslan B, Erdoğan H, Yazısız V. The view of joints in the Wilson's disease. *Eur J Rheumatol* 2020;7:205-6.
10. Golding DN, Walshe JM. Arthropathy of Wilson's disease. Study of clinical and radiological features in 32 patients. *Ann Rheum Dis* 1977;36:99-111.
11. Park NH, Kim HS, Yi SY, et al. Multiple osteochondritis dissecans of knee joint in a patient with Wilson disease, focusing on magnetic resonance findings. *Knee Surg Relat Res* 2013;25:225-9.
12. Kaklamanis P, Spengos M. Osteoarticular changes and synovial biopsy findings in Wilson's disease. *Ann Rheum Dis* 1973;32:422-7.
13. Selimoglu MA, Ertekin V, Doneray H, et al. Bone mineral density of children with Wilson disease: efficacy of penicillamine and zinc therapy. *J Clin Gastroenterol* 2008;42:194-8.
14. Cetinkaya A, Ozen H, Yüce A, et al. Bone mineralization in children with Wilson's disease. *Indian J Gastroenterol* 2014;33:427-31.
15. Palkar AV, Shrivastava MS, Padwal NJ, et al. Renal tubular acidosis due to Wilson's disease presenting as metabolic bone disease. *BMJ Case Rep* 2011;2011:bcr0420114121.
16. Subrahmanyam DK, Vadivelan M, Giridharan S, et al. Wilson's disease - A rare cause of renal tubular acidosis with metabolic bone disease. *Indian J Nephrol* 2014;24:171-4.
17. Menerey KA, Eider W, Brewer GJ, et al. The arthropathy of Wilson's disease: clinical and pathologic features. *J Rheumatol* 1988;15:331-7.
18. Di Stefano V, Lionetti E, Rotolo N, et al. Hypercalciuria and nephrocalcinosis as early feature of Wilson disease onset: description of a pediatric case and literature review. *Hepat Mon* 2012;12:e6233.
19. Aksoy M, Camli N, Dincol K, et al. Osseous changes in Wilson's disease. A radiologic study of nine patients. *Radiology* 1972;102:505-9.
20. Aksoy M, Camli N, Dilşen G, et al. Osteoarticular pains and changes in Wilson's disease: a radiological study in fourteen patients in nine Turkish families. *Acta Hepato-gastroenterologica* 1975;22:164-70.
21. Shimizu N, Nakazono H, Takeshita Y, et al. Molecular analysis and diagnosis in Japanese patients with Wilson's disease. *Pediatr Int* 1999;41:409-13.
22. Quemeneur AS, Trocello JM, Ea HK, et al. Bone status and fractures in 85 adults with Wilson's disease. *Osteoporosis International* 2014;25:2573-80.
23. Chenbhanich J, Thongprayoon C, Atsawarungruangkit A, et al. Osteoporosis and bone mineral density in patients with Wilson's disease: a systematic review and meta-analysis. *Osteoporos Int* 2018;29:315-22.
24. Kido J, Matsumoto S, Sugawara K, et al. Wilson disease developing osteoarthritic pain in severe acute liver failure: A case report. *World J Hepatol* 2019;11:607-12.
25. Ji JH, Hwang WH, Lee YS, et al. A rare case of multiple and huge simple bone cysts in Wilson's disease. *J Orthop Surg (Hong Kong)* 2019;27:2309499019843141.
26. Gatta A, Verardo A, Di Pascoli M, et al. Hepatic osteodystrophy. *Clin Cases Miner Bone Metab* 2014;11:185-91.
27. Jadzic J, Djonc D. Bone loss in chronic liver diseases: Could healthy liver be a requirement for good bone health? *World J Gastroenterol* 2023;29:825-33.
28. Ehnert S, Aspera-Werz RH, Ruoff M, et al. Hepatic Osteodystrophy-Molecular Mechanisms Proposed to Favor Its Development. *Int J Mol Sci* 2019;20:2555.

doi: 10.21037/acr-23-217

Cite this article as: Valmadrid LC, Lystad H, Smitaman E, Vitale K. Osteochondral lesions in Wilson's disease: case report and literature review. *AME Case Rep* 2024;8:80.