

UC Davis

Dermatology Online Journal

Title

Cutaneous angiosarcoma of the leg

Permalink

<https://escholarship.org/uc/item/3hq6r0b0>

Journal

Dermatology Online Journal, 25(12)

Authors

Cooper, Hassie
Farsi, Maheera
Dorton, David
et al.

Publication Date

2019

DOI

10.5070/D32512046721

Copyright Information

Copyright 2019 by the author(s). This work is made available under the terms of a Creative Commons Attribution-NonCommercial-NoDerivatives License, available at <https://creativecommons.org/licenses/by-nc-nd/4.0/>

Peer reviewed

Cutaneous angiosarcoma of the leg

Hassie Cooper DO MPH, Maheera Farsi DO, David Dorton DO, Richard Miller DO

Affiliations: Nova Southeastern University College of Osteopathic Medicine/Largo Medical Center Dermatology Residency Program, Largo, Florida, USA

Corresponding Author: Hassie Cooper, DO, 2174 Druid Road, #9107, Clearwater, FL 33764, Tel: 415-652-6484, hassie.cooper@gmail.com

Abstract

Angiosarcomas are malignant neoplasms arising from endothelial cells. Cutaneous angiosarcoma is the most common form, typically occurring in the setting of chronic lymphedema or previous radiation. The head and neck are the most common locations for cutaneous angiosarcoma, with rare occurrence on the trunk and extremities. Herein, we present a case of angiosarcoma on the lower extremity in an elderly man. This 71-year-old man presented with a two-year history of red-yellow discoloration of the left lower leg with subsequent development of black nodules over the past several months prior to presentation. He denied any itching, bleeding, or ulceration. Past medical history included diabetes, hypertension, and non-melanoma skin cancer. Physical examination showed erythematous, violaceous, non-blanchable papules with yellow atrophic regions and overlying black crusted nodules and plaques. Biopsies were taken and the patient was diagnosed with angiosarcoma and referred to a tertiary care center for further evaluation.

Keywords: angiosarcoma, leg, lymphedema, radiation, CD31, CD34, D240

Introduction

Angiosarcomas are malignant neoplasms derived from endothelial cells that historically carry a very poor prognosis [1]. They are rare aggressive tumors, accounting for around 2% of all soft tissue sarcomas. Cutaneous angiosarcomas, the most common type, comprise about 60% of all angiosarcomas [2]. Although the most common form of cutaneous angiosarcoma is the spontaneous/idiopathic form

typically arising in the head and neck [3], angiosarcomas have also been associated with chronic lymphedema, as well as a history of radiation treatment [1, 3]. Herein, we present a patient with cutaneous angiosarcoma arising in the lower extremity of an elderly patient.

Case Synopsis

A 71-year-old man presented with discoloration of his left distal lower extremity for the past two years. He denied any itching, tenderness, or bleeding. His past medical history included diabetes, hypertension, and non-melanoma skin cancer. Medications included aspirin 325mg, atenolol 50mg, glyburide 5mg, hydrochlorothiazide 25mg, ibuprofen 600mg, lovastatin 40mg, nifedipine 30mg, and prazosin 5mg. He denied any allergies. On a previous visit to a dermatology office, he was initially diagnosed with necrobiosis lipoidica. He returned approximately seven months later with an eruption of black nodules within the discoloration that he reported appeared after bumping his shin a few times.

Physical examination revealed erythematous to violaceous, non-blanchable papules and plaques with some yellow, atrophic patches and overlying scattered black, crusted nodules on the left distal lower extremity with mild edematous changes noted in the lower extremities (**Figure 1**). The patient denied any history of prior radiation to the area.

Two 5mm punch biopsies were performed on the left distal and proximal lower leg. The upper dermis showed thin walled vessels with irregularly shaped

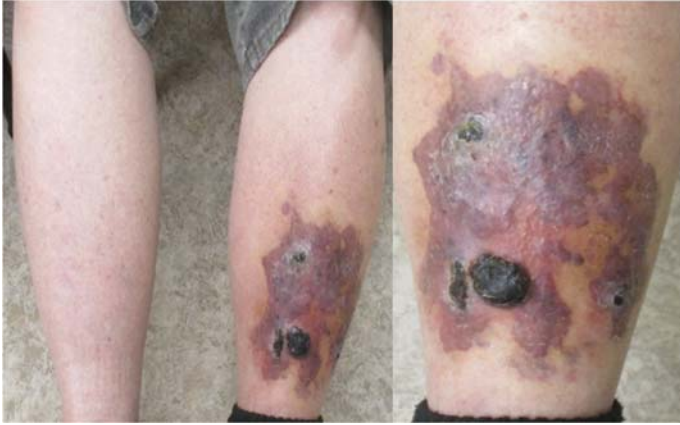

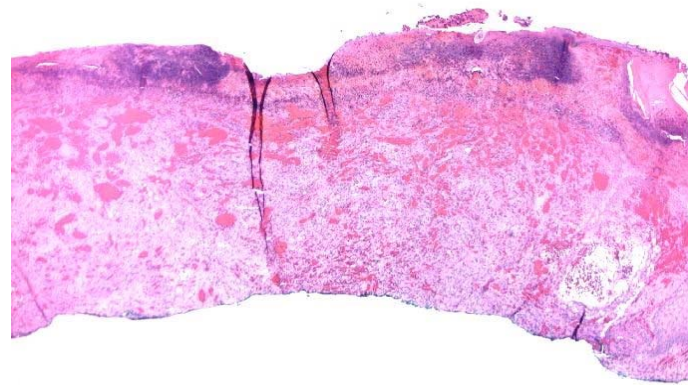
Figure 1. Large violaceous plaques with overlying dark crusted nodules on the left pretibial region.

jagged lumen lined with endothelial cells with protuberant hyperchromatic nuclei and papillations extending into some lumen (**Figure 2**). CD31 (**Figure 3**) and CD34 (**Figure 4**) stains were positive, indicating a vascular origin of the tumor. Staining for HHV8 (**Figure 5**) was negative, effectively excluding Kaposi sarcoma from the differential diagnosis. The initial diagnosis was an atypical vascular proliferation, with a differential diagnosis of diffuse dermal angiomatosis, which would also stain positively for CD31 and CD34 [4]. Further staining revealed D240+, which suggested a partially lymphatic endothelial immunophenotype with a degree of nuclear enlargement and hyperchromasia. These findings, along with the irregular nuclei and jagged vessel lumen described above, were consistent with angiosarcoma.

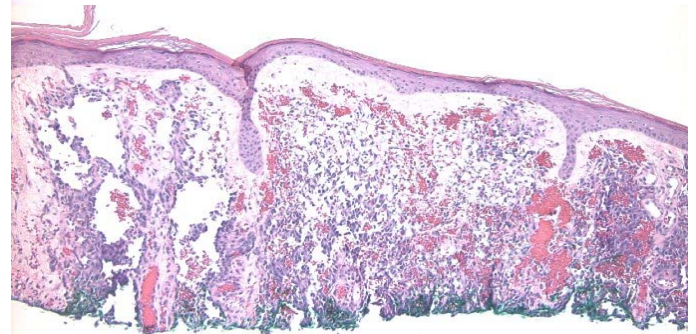
The patient was subsequently referred to a tertiary care center for further evaluation and management. The patient underwent 21×20cm wide local excision of the left leg, which revealed close peripheral margins and involved deep margin. He was subsequently referred for postoperative external beam radiotherapy over a 6-7-week period (6600cGy in 33 fractions). The patient declined radiotherapy treatment at that time and was subsequently lost to follow-up.

Case Discussion

Angiosarcoma is a rare malignant neoplasm of endothelial origin [3]. It is classified into 5 main types:



A



B

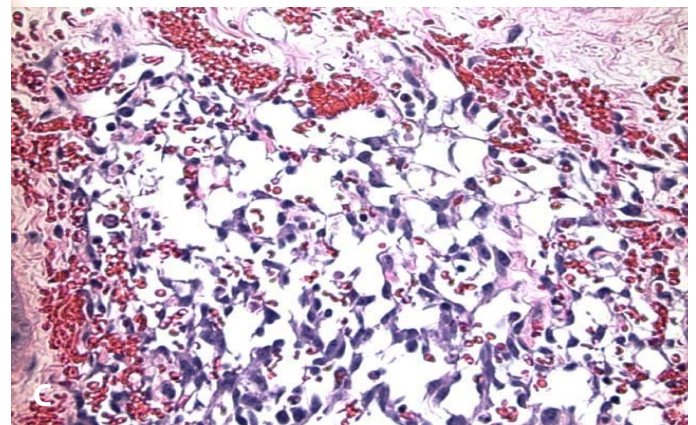


Figure 2. Thin walled vessels in the upper dermis with irregularly shaped jagged lumen. **A)** H&E, 20×, **B)** H&E, 40×. **C)** Endothelial cells with prominent and hyperchromatic nuclei. H&E, 200×.

cutaneous angiosarcoma, soft tissue angiosarcoma, primary-breast angiosarcoma, lymphedema-associated angiosarcoma, and radiation-induced angiosarcoma [1]. Stewart-Treves syndrome describes the most common type of angiosarcoma in the setting of chronic lymphedema, usually appearing on the upper extremity after mastectomy with lymph node dissection [3, 5].

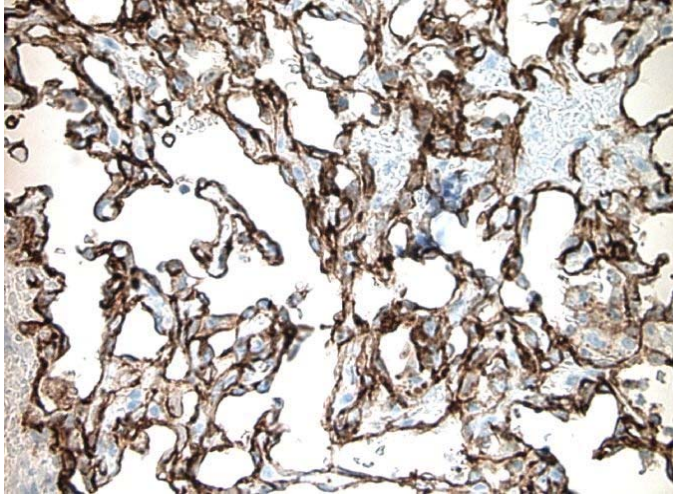


Figure 3. Positive CD31 stain.

Cutaneous angiosarcoma is the most common subtype, comprising about 60% of all angiosarcomas; about 50% appear in the head and neck [2]. Cutaneous angiosarcoma affects men slightly more often than women. Typically, older patients are more commonly diagnosed, with the highest incidence seen in those older than 70 years [3, 6, 7].

Angiosarcoma lesions typically present as a dark patch resembling a bruise. As the tumor progresses, violaceous nodules develop that tend to bleed easily with risk of ulceration. In the setting of lymphedema, indurated plaques or firm nodules appear on underlying non-pitting edema [3]. Differential diagnoses should include other types of vascular tumors, including but not limited to, capillary

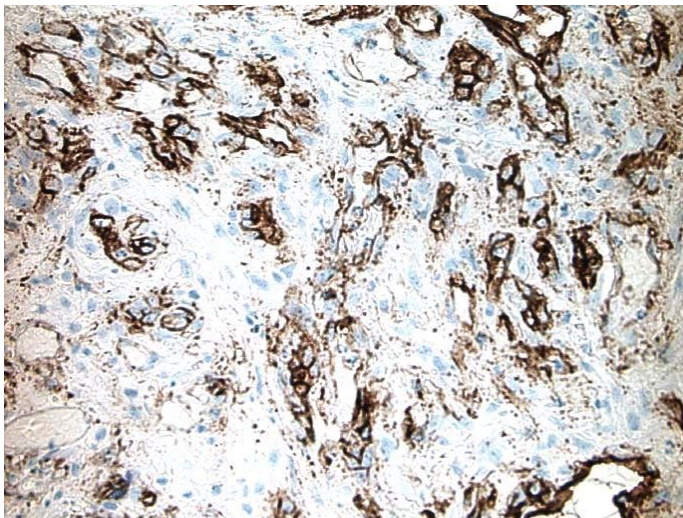


Figure 4. Positive CD34 stain.

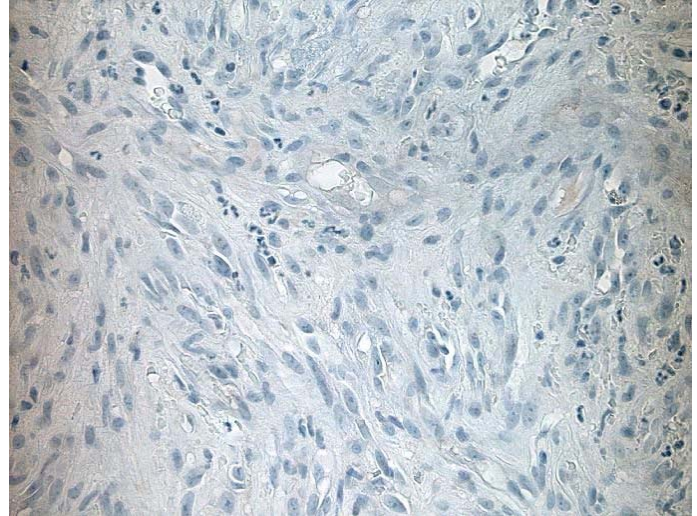


Figure 5. Negative HHV8 stain.

hemangiomas, Kaposi sarcoma, epithelioid hemangioendotheliomas, and hemangiopericytomas [1]. These can be differentiated with appropriate clinical context and history as well as histopathologic evaluation.

On histologic examination, the malignant endothelial cells of angiosarcoma can take on a rounded, polygonal or fusiform shape [1]. In well-differentiated cutaneous angiosarcomas, flattened endothelial cells line vascular channels arranged in an irregular anastomosing pattern creating splits between the collagen bundles [2, 3]. In moderately differentiated angiosarcomas, the vascular channels are more densely packed with multiple layers of endothelial cells that exhibit increased nuclear pleomorphism and formation of intraluminal papillae [2, 3]. Poorly differentiated angiosarcomas are less often cutaneous and will often have similar characteristics to other sarcomas or carcinomas, including endothelial cells with an epithelioid appearance forming sheets and necrotic and hemorrhagic areas [1, 2].

Treatment includes surgical excision with wide margins, chemotherapy, and radiation therapy [3]. Surgical excision is the primary treatment of choice, followed by radiation, as excision with negative margins is difficult to achieve owing to the invasive nature of angiosarcoma in addition to the increased likelihood of recurrence [1]. Chemotherapy is usually the treatment of choice for metastatic angiosarcoma

[1]. Doxorubicin, paclitaxel, and docetaxel have been cited as chemotherapeutic options in previous studies [8].

The prognosis of angiosarcoma is historically quite poor, with a 5-year survival at less than 15% [3]. Other studies found 5-year survival rates slightly higher, at around 20% or 34% [6, 10]. Albores-Saavedra et al. found that cutaneous angiosarcomas of the lower extremities had a 5-year survival of 64% [6]. Morgan et al. found that characteristics associated with the worst outcomes are tumor diameter greater than 5cm, depth of invasion greater than 3mm, positive margins, recurrence, and metastasis [9].

Our case is an unusual presentation of cutaneous angiosarcoma because it occurred on the lower leg. His initial diagnosis of necrobiosis lipoidica based on clinical appearance is somewhat unsurprising given its common appearance on the pretibial surface of the lower extremity (although usually bilaterally), as well as its typical morphology of well-demarcated yellow-brown plaques with violaceous borders and central areas of atrophic change [10]. Deyrup et al. reviewed studies of sporadic cutaneous angiosarcomas and commented that those occurring on the trunk or extremities carry a worse prognosis than those of the head or neck, noting that angiosarcomas of the trunk or extremities displayed

higher risk histologic features associated with worse prognosis [11]. A 2013 case report discussed a patient with a poorly differentiated cutaneous angiosarcoma of the leg with no history of lymphedema or radiotherapy who ultimately received an above the knee amputation and remained free of recurrence or metastasis eleven months after surgery [12]. There are other case reports describing cutaneous angiosarcoma arising in the lower extremity, mainly citing a history of chronic lymphedema in the affected extremity [13, 14].

Conclusion

Angiosarcoma is a rare malignancy and carries a very poor prognosis. It occurs spontaneously or in the setting of chronic lymphedema or previous radiation therapy. Cutaneous angiosarcoma mainly occurs on the face, neck, or scalp and less commonly on the trunk or extremities. Timely recognition of angiosarcoma is important so that the patient can be referred for surgical excision and any necessary adjuvant treatment in order to optimize survival.

Potential conflicts of interest

The authors declare no conflicts of interests.

References

1. Young R, Brown N, Reed M, Hughes D, Woll P. Angiosarcoma. *Lancet Oncol.*: 2010;11: 983-991. [PMID: 20537949].
2. Mendenhall W, Mendenhall C, Werning J, Reith J, Mendenhall N. Cutaneous Angiosarcoma. *Am J Clin Oncol.*: 2006;29: 524-528. [PMID: 17023791].
3. North, P, Kincannon J: Vascular Neoplasms and Neoplastic-like Proliferations. In: *Dermatology*. Bologna J, Jorizzo J, Schaffer J, editors. 2nd ed. Elsevier Limited; 2012, p. 1915-1941.
4. Sriphojanart T, & Vachiramon V. Diffuse Dermal Angiomatosis: A Clue to the Diagnosis of Atherosclerotic Vascular Disease. *Case Rep Dermatol.*: 2015;7(2): 100-106. [PMID: 26120304].
5. Stewart F, Treves N. Lymphangiosarcoma in postmastectomy lymphedema: a report of six cases in elephantiasis chirurgica. *Cancer.*: 1948;1: 64-81. [PMID: 18867440].
6. Albores-Saavedra J, Schwartz A, Henson D, et al. Cutaneous angiosarcoma. Analysis of 434 cases from the Surveillance, Epidemiology, and End Results Program, 1973-2007. *Ann Diagn Pathol.*: 2011;15: 93-97. [PMID: 21190880].
7. Donghi D, Kerl K, Dummer R, Schoenewolf N, Cozzio A. Cutaneous angiosarcoma: own experience over 13 years. Clinical features, disease course and immunohistochemical profile. *J Eur Acad Dermatol Venereol.*: 2010;24: 1230-1234. [PMID: 20236193].
8. Wollina U, Hansel G, Schonlebe J, et al. Cutaneous angiosarcoma is a rare aggressive malignant vascular tumor of the skin. *J Eur Acad Dermatol Venereol.*: 2011;25: 964-968. [PMID: 21108661].
9. Morgan M, Swann M, Somach S, Eng W, Smoller B. Cutaneous angiosarcoma: A case series with prognostic correlation. *J Am Acad Dermatol.*: 2004;50: 867-874. [PMID: 15153886].
10. Sibbald C, Reid S, Alavi A. Necrobiosis Lipoidica. *Dermatol Clin.*: 2015;33(3): 343-360. [PMID: 26143418].
11. Deyrup A, McKenney J, Tighiouart M, Folpe A, Weiss S. Sporadic Cutaneous Angiosarcomas: A Proposal for Risk Stratification Based on 69 Cases. *Am J Surg Pathol.*: 2008;32: 72-77. [PMID: 18162773].
12. Linda D, Harish S, Alowami S, DeNardi F, Deheshi B. Radiology-pathology conference: cutaneous angiosarcoma of the leg. *Clin Imaging.*: 2013;37: 602-607. [PMID: 23601777].
13. Tchernev G, Yungareva I, Mangarov H, et al. Pretibial Located Stewart-Treves Syndrome: Uncommon Presentation in a Bulgarian Patient! *Open Access Maced J Med Sci.*: 2018;6(4): 663-665.

[PMID: 29731936].

14. Harrison W, Chandrasekar C. Stewart-Treves syndrome following idiopathic leg lymphoedema:

15. remember sarcoma. *J Wound Care*: 2015;6 Suppl: S5-7. [PMID: 26075513].