

# **UCLA**

## **Proceedings of UCLA Health**

### **Title**

Brugada Pattern Unmasked by Fever

### **Permalink**

<https://escholarship.org/uc/item/3h57m8m4>

### **Journal**

Proceedings of UCLA Health, 21(1)

### **Authors**

Borenstein, Sivan

Katsman, Alina

### **Publication Date**

2017-08-10

## CLINICAL VIGNETTE

# Brugada Pattern Unmasked by Fever

Sivan Borenstein, B.A., and Alina Katsman, M.D.

### Case

A 29-year-old Asian-American male with past medical history significant only for mitral valve prolapse presents to his primary care physician's office for a 2-day history of fever and dizziness. He was in his usual state of health up until 2 days prior to presentation when he developed rhinorrhea and low back pain. His temperature at home was 103°F. He had poor oral intake and dizziness upon standing. He denies any chest pain, shortness of breath, palpitations, nausea, vomiting, diarrhea, or constipation. His past medical history is significant only for mitral valve prolapse that was diagnosed at age 20 with an echocardiogram. He takes no prescription medications and has no known drug allergies. Family history is negative for sudden cardiac death or early coronary disease. Social history negative for any tobacco, alcohol, or illicit drug use. On physical exam, vitals were: BP 110/66, heart rate 122, Temp 100.2°F, respiratory rate 18, and oxygen saturation 99% on room air. He was in no acute distress. HEENT exam revealed dry mucous membranes. Cardiovascular exam revealed tachycardia but regular rhythm, normal S1 and S2 without any murmurs, rubs, or gallops. Lungs were clear to auscultation bilaterally. Abdomen was soft, non-tender, and non-distended. Extremities did not reveal any edema. Because of the tachycardia, an ECG showed sinus tachycardia with a heart rate of 120 and ST elevation in leads V1-V3 with right bundle branch block (Figure 1). Given concern for myocarditis, patient was transported to the nearest ED for further diagnostic evaluation.

The patient was admitted overnight at a local hospital for workup of his symptoms and ECG findings. Troponins were negative and he was ruled out for acute coronary syndrome. Echocardiogram was normal with an ejection fraction of 65%. The patient was seen by cardiology and determined to have Brugada syndrome. He was treated with intravenous fluid and diagnosed with viral syndrome. He was sent home with close outpatient follow-up.

The patient was seen by his primary care doctor 1 week after discharge. He was feeling better and denied any chest pain, shortness of breath, or dyspnea on exertion. He had recovered from his viral illness. His vitals were all within normal range. A repeat ECG showed normal sinus rhythm, rate 68, normal axis, normal intervals, and a right ventricular conduction delay. He was also seen by an electrophysiologist. Myocardial perfusion study with PET/CT showed no cardiac sarcoidosis, normal cardiac resting perfusion, normal cardiac resting systolic function and no evidence of active extra-cardiac sarcoidosis. Cardiac MRI showed no evidence of

arrhythmogenic right ventricular dysplasia and no abnormal delayed enhancement or scar. His final diagnosis is Type 1 Brugada Pattern. ICD implant was not recommended. Genetic testing was recommended for his family. He was instructed to promptly treat any fever with acetaminophen.

### Discussion

Brugada pattern refers to ECG findings that result from a genetic channelopathy, which may be associated with an increased risk of sudden cardiac death (SCD), though many individuals never manifest cardiac symptoms. The primary ECG pattern in Brugada syndrome is a right bundle branch block and persistent ST segment elevation in otherwise healthy appearing adults.<sup>1,2</sup> Three distinct repolarization patterns are observed, although it is suggested that Type I be used for a Brugada syndrome diagnosis.<sup>3</sup> In general, coved ST-segment elevation is reported to relate to a higher incidence of ventricular tachycardia/ventricular fibrillation and SCD.<sup>1,3</sup>

Estimates of the prevalence of Brugada syndrome vary from 0.01-0.3% of individuals in different populations and is higher among individuals of Asian descent. As the ECG readings of individuals may fluctuate between normal and diagnostic ST-segment patterns, the actual prevalence of Brugada syndrome is unknown. Symptomatic Brugada syndrome can manifest at any age, most commonly between the ages of 30-50 years, with the incidence of SCD occurring at the mean age of 41 +/- 15 years (1,3). Fever is known to unmask a Brugada Type I pattern in otherwise healthy appearing adults.<sup>1,3,4</sup>

Classically, Brugada syndrome has been described as an autosomal dominant disorder, though recently described variable penetrance and expressivity raise the possibility of a more complex polygenic mode of inheritance. In total, 23 genes have been implicated as potential contributors to Brugada syndrome. Despite equal genetic transmission, symptomatic Brugada syndrome is more prevalent and severe in men, who have a 3.4 fold higher risk of VT/VF, potentially related to subtle sex related differences in cardiac electrophysiology and testosterone that promote arrhythmogenesis.

Brugada syndrome is thought to result from a channelopathy in the cardiac cell membrane that results in a pro-arrhythmic outward shift in the balance of transmembrane currents during an early phase in action potential. However, newer research suggests that structural myocardial abnormalities may also play a role on Brugada syndrome.<sup>5</sup> It has therefore been proposed that the Brugada syndrome may be an umbrella diagnosis for

numerous conduction and repolarization abnormalities in which a coved ST elevation represents the final common pathway of both ion channel and structural derangements.<sup>1,2,6</sup>

Patients with Brugada syndrome are typically asymptomatic until they present with arrhythmic syncope or SCD. Fever and vagotonia can unmask Brugada syndrome, usually presenting as a polymorphic ventricular tachycardia and ventricular fibrillation in apparently healthy adults, and is associated with a higher risk of SCD.<sup>1,4,7</sup> Among survivors, syncope from malignant ventricular arrhythmic and spontaneous type-1 ECG are the strongest predictors of future arrhythmias.<sup>1</sup>

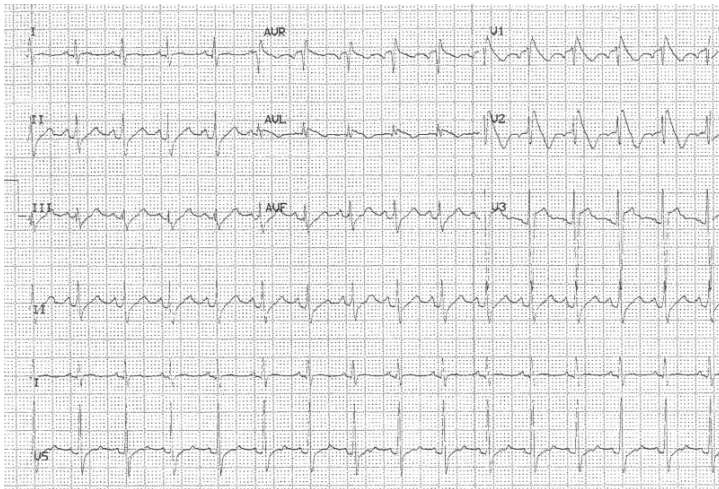
Evaluation of several risk factors in a multifactorial approach have been proposed to improve discrimination of patients at risk of SCD. Currently, the treatment for Brugada syndrome is the implantation of a cardioverter-defibrillator (ICD), especially among young, active patients, and those with a long life expectancy.<sup>1,2</sup> Studies are underway to establish the long-term efficacy and safety of ICDs in Brugada syndrome. The first-line medical therapy among those without and ICD is quinidine.<sup>1,5,8</sup>

### Conclusion

As this case demonstrates, primary care physicians should be aware that Brugada pattern can be unmasked by several conditions, including fever. Our patient underwent testing and treatment with an ICD was not recommended and no further medication was required other than acetaminophen for fever.

### Figures

**Figure 1.** ECG of patient shows a right bundle branch block and ST elevation in the V1-V3 leads.



### REFERENCES

1. **Polovina MM, Vukicevic M, Banko B, Lip GYH, Potpara TS.** Brugada syndrome: A general cardiologist's perspective. *Eur J Intern Med.* 2017 Jun 20. pii:S0953-6205(17)30263-7. doi: 10.1016/j.ejim.2017.06.019. [Epub ahead of print] Review. PubMed PMID: 28645806.
2. **Antzelevitch C, Brugada P, Brugada J, Brugada R.** Brugada syndrome: from cell to bedside. *Curr Probl Cardiol.* 2005 Jan;30(1):9-54. Review. PubMed

PMID:15627121; PubMed Central PMCID: PMC1475801.

3. **Hoogendijk MG, Opthof T, Postema PG, Wilde AA, de Bakker JM, Coronel R.** The Brugada ECG pattern: a marker of channelopathy, structural heart disease, or neither? Toward a unifying mechanism of the Brugada syndrome. *Circ Arrhythm Electrophysiol.* 2010 Jun;3(3):283-90. doi: 10.1161/CIRCEP.110.937029. Review. PubMed PMID: 20551422.
4. **Adler A, Topaz G, Heller K, Zeltser D, Ohayon T, Rozovski U, Halkin A, Rosso R, Ben-Shachar S, Antzelevitch C, Viskin S.** Fever-induced Brugada pattern: how common is it and what does it mean? *Heart Rhythm.* 2013 Sep;10(9):1375-82. doi: 10.1016/j.hrthm.2013.07.030. Epub 2013 Jul 19. PubMed PMID: 23872691; PubMed Central PMCID: PMC3832740.
5. **Probst V, Gourraud JB.** Quinidine in Brugada Syndrome: Still a Long Way to Go.... *Circ Arrhythm Electrophysiol.* 2015 Dec;8(6):1309-10. doi: 10.1161/CIRCEP.115.003576. PubMed PMID: 26671933.
6. **Escárcega RO, Jiménez-Hernández M, Garcia-Carrasco M, Perez-Alva JC, Brugada J.** The Brugada syndrome. *Acta Cardiol.* 2009 Dec;64(6):795-801. Review. PubMed PMID: 20128157.
7. **Brugada R, Campuzano O, Sarquella-Brugada G, Brugada J, Brugada P.** Brugada syndrome. *Methodist Debakey Cardiovasc J.* 2014 Jan-Mar;10(1):25-8. Review. PubMed PMID: 24932359; PubMed Central PMCID: PMC4051330.
8. **Bhar-Amato J, Nunn L, Lambiase P.** A review of the mechanisms of ventricular arrhythmia in brugada syndrome. *Indian Pacing Electrophysiol J.* 2010 Sep 5;10(9):410-25. PubMed PMID: 20930959; PubMed Central PMCID: PMC2933369.

Submitted August 10, 2017