

# UCLA

## UCLA Previously Published Works

### Title

Primary Mpox and Secondary Syphilis in an HIV Patient: A Community Hospital Experience

### Permalink

<https://escholarship.org/uc/item/3qz210vf>

### Authors

Castanares, Geocel-Grace  
D'Assumpcao, Carlos  
Fang, Michelle  
[et al.](#)

### Publication Date

2023

### DOI


10.1177/23247096231165739

### Copyright Information

This work is made available under the terms of a Creative Commons Attribution-NonCommercial License, available at <https://creativecommons.org/licenses/by-nc/4.0/>

Peer reviewed

# Primary Mpox and Secondary Syphilis in an HIV Patient: A Community Hospital Experience

Journal of Investigative Medicine High Impact Case Reports  
Volume 11: 1–6  
© 2023 American Federation for Medical Research  
DOI: 10.1177/23247096231165739  
journals.sagepub.com/home/hic  


Geocel-Grace Castanares, DO<sup>1</sup>, Carlos D'Assumpcao, MD<sup>1</sup> ,  
Michelle Fang, PharmD<sup>1</sup>, Rick McPheeters, DO<sup>1</sup>,  
and Arash Heidari, MD<sup>1</sup> 

## Abstract

Mpox was an emerging outbreak in California in 2022, primarily in major metropolitan areas, as part of the global mpox outbreak declared by World Health Organization in July 2022. Community hospitals outside of major metropolitan areas have seen fewer cases to date, so they may be less equipped to diagnose and treat patients with mpox. They may have limited public health resources commensurate with the area's population density. Mpox may also be superimposed on ongoing local outbreaks of other sexually transmitted infections. We present a case of a person with HIV who contracted mpox and also developed secondary syphilis. Early detection can be beneficial for prompt treatment, decreased burden of disease for the individual, and prevention of further spread of the infection.

## Keywords

mpox, non-variola orthopoxvirus, HIV, syphilis

## Introduction

Mpox virus (formerly monkeypox), a non-variola orthopoxvirus, is the cause of a zoonotic pox disease that is endemic in several Central and West African countries.<sup>1</sup> It was first detected in 1958 in captive monkeys transported to Copenhagen, Denmark, from Africa for research.<sup>2</sup> “Monkeypox” as a name is actually misleading because the largest animal reservoir is small rodents that are hunted for food.<sup>3</sup> It is understood to be spread via direct contact with sores or scabs on infected individuals as well as large respiratory droplets or indirect and direct contact with bodily fluids, including saliva. It is assumed to enter the body through the respiratory tract, broken skin, or mucous membranes.<sup>4</sup>

There are 2 clades, West African and Congo Basin, of which the latter causes more severe illness.<sup>1,5</sup> Sporadic cases and outbreaks in the United States associated with returning travelers<sup>6,7</sup> as well as with the import of small mammals from endemic countries<sup>8</sup> have been reported. In May 2022, several cases of mpox virus West African clade were discovered in the United Kingdom, the United States,<sup>9</sup> and Spain.<sup>10</sup> As part of the United States's response to the emerging outbreak, rapid diagnostic testing with qualitative orthopoxvirus PCR was expanded to commercial labs in July 2022 through the Laboratory Response Network.<sup>11</sup> Since testing expansion, cases in the United States have now been reported in all 50

states, the District of Columbia, and 1 US territory, as well as over 90 other non-endemic countries. These new cases revealed new epidemiological patterns, including high prevalence among gay or bisexual men, or any men or transgender people who have sex with men or transgender people, and their sexual partners<sup>12</sup>; higher rates of sexually transmitted infections,<sup>13</sup> fomite contamination,<sup>14,15</sup> caregiver exposure,<sup>16</sup> health care exposure,<sup>17,19</sup> incarceration,<sup>20</sup> perinatal infection<sup>21</sup>; as well as no known epidemiological risk factors.<sup>22,23</sup> People at risk for severe disease include those with immunocompromising conditions and chronic skin disorders such as eczema. Two cases of mpox-associated encephalomyelitis without underlying immunocompromising conditions have been reported though.<sup>24</sup>

Vaccination is useful for pre-exposure and post-exposure prophylaxis. JYNNEOS is a replication-deficient live

<sup>1</sup>Kern Medical—UCLA, Bakersfield, CA, USA

Received December 16, 2022. Revised February 13, 2023. Accepted March 7, 2023.

## Corresponding Author:

Carlos D'Assumpcao, MD, Department of Medicine, Division of Infectious Diseases, Kern Medical—UCLA, 1700 Mount Vernon Ave, Bakersfield, CA 93306, USA.

Email: carlos.dassumpcao@kernmedical.com



vaccinia virus that is administered subcutaneously. ACAM2000 is a replication-competent live vaccinia-clonal derivative virus vaccine that is administered by skin scarification and is in active use by the military and laboratory personnel for smallpox. These were made available by the US Department of Health and Human Services as part of the National Mpox Vaccine Strategy for the mpox public health emergency 2022.<sup>25</sup> As JYNNEOS administration rate is limited by manufacturing supply, intradermal administration was authorized for emergency use by the US Centers for Disease Control and Prevention (CDC) to increase available supply, as the equivalent volume for 1 subcutaneous vaccine can provide 4 to 5 intradermal doses. Scheduled appointments to ensure utilization of each dose in a vial, generally, 4 to 5 at a time, are recommended to limit waste. Eczema vaccinatum akin to that from smallpox eradication days<sup>26</sup> has not been reported in the current mpox outbreak to date.

Tecovirimat, a novel orally bioavailable antiviral that targets the highly conserved orthopoxvirus VP37 protein to inhibit development and release of mature virions, is US Food and Drug Administration (FDA)-approved for the treatment of smallpox (variola). Tecovirimat has also been made available in the United States for the treatment of mpox through a protocol held by the CDC under the FDA-regulated Expanded Access Investigational New Drug mechanism.<sup>27</sup> Access to tecovirimat is improving nationally through the Strategic National Stockpile via the CDC.

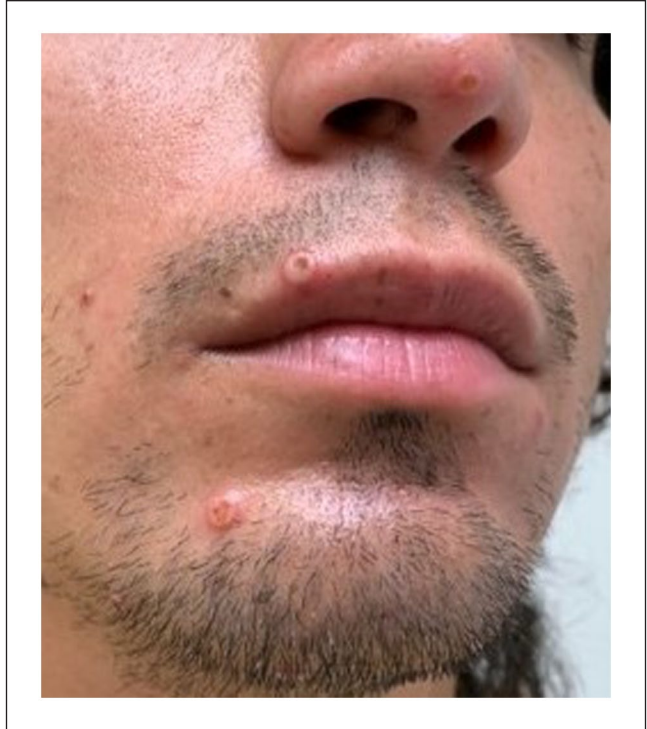Co-infection of mpox, HIV, and syphilis has only been reported 3 times to date.<sup>28-30</sup> Here we report a case of a person with uncomplicated well-controlled HIV who contracted mpox and secondary syphilis. The efforts made in a community hospital setting to diagnose and treat these infections in the setting of a public health emergency are discussed.

## Case Presentation

A 35-year-old man with uncomplicated well-controlled HIV on bicitgravir, emtricitabine, and tenofovir alafenamide presented to the emergency department with multiple facial lesions for 7 days. The first lesion was a small pustular “bump” on his lip. He subsequently developed 4 more lesions on his lips and chin before seeking an evaluation by a physician. Lesions were flesh-colored with a central concavity and small pustular discharge (Image 1). They were non-pruritic and non-tender. Concurrent with the onset of these lesions, he also developed mild right-sided submandibular pain associated with lymphadenopathy.

The patient identifies as bisexual with a history of oral and anal intercourse. The last sexual contact was 2 months prior. He then traveled to Hawaii 3 weeks prior to the index presentation and attended a large public gathering.

Lesions were swabbed for mpox virus using viral culture media and sent to a contracted commercial reference lab for qualitative PCR testing. He returned home to self-isolate. Results were available after 4 days. The reference lab



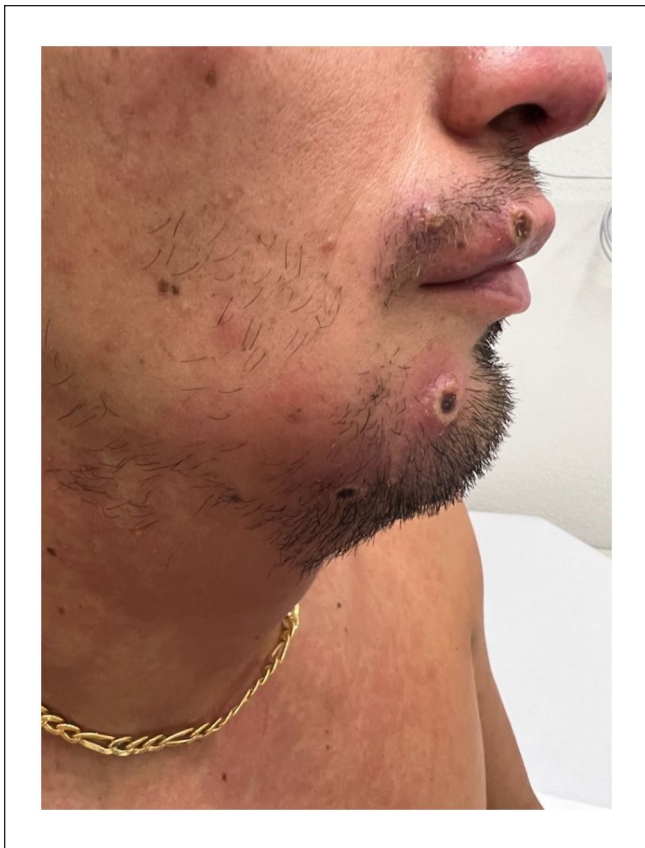**Image 1.** Monkeypox lesions at presentation, 7 days after symptom onset.

notified the local public health department per Laboratory Response Network protocol. Public health officials informed the patient's infectious disease physician who arranged a clinic visit following infection control precautions as recommended by the CDC.

At the clinic visit, his original facial lesions had increased in size and central crusting (Image 2). He had also developed a new diffuse maculopapular rash on the neck, chest, and torso with a herald patch on the right chest (Image 3). Early eczema versus secondary syphilis was the concern at this time. His lymphocyte CD4 count was 588 per cubic millimeter (reference range, 500-1500), and his HIV viral load was undetectable.

After the patient was provided informed consent for use of tecovirimat for treatment of non-variola orthopox virus infection under CDC Expanded Access Investigational New Drug Protocol No. 116039 (IRB No. 6402), he was started on tecovirimat 600 mg twice a day for 14 days. A small supply had already been arranged by the pharmacy department in coordination with the CDC, California Department of Public Health, and Kern County Public Health Department a few weeks in advance for possible local outbreaks.

Co-infection testing eventually revealed reactive syphilis antibody, reactive Fluorescent Treponemal Antibody Absorption test, and reactive Rapid Plasma Reagin test (RPR) with titer 1:1. Through California Reportable Disease Information Exchange, no prior treatment history for syphilis was found. Syphilis was staged as secondary syphilis. He was treated with 2.4 million



**Image 2.** Monkeypox lesions with a maculopapular rash 10 days after symptom onset.

units of benzathine penicillin G intramuscularly once. Urine gonorrhea and chlamydia nucleic acid amplification testing was negative.

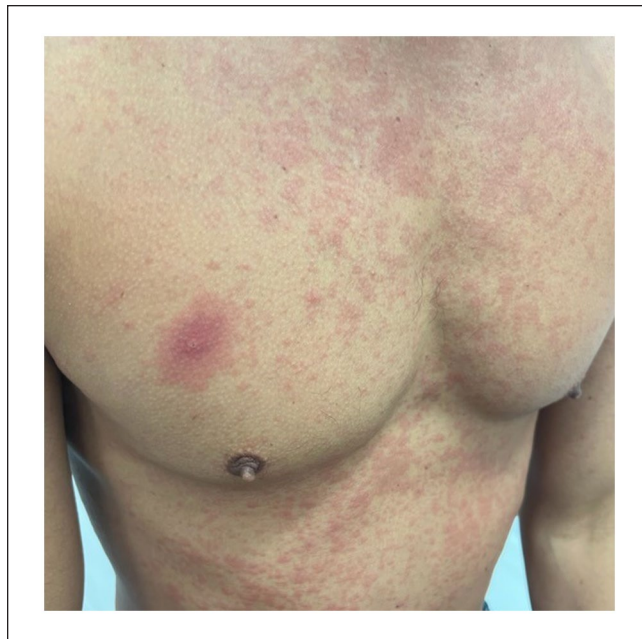At follow-up 1 week (Images 4 and 5) and 3 weeks (Images 6 and 7) after treatment initiation, he showed improvement and subsequent resolution of all symptoms. Isolation was lifted after all lesions had resolved, 4 weeks after symptom onset.

## Discussion

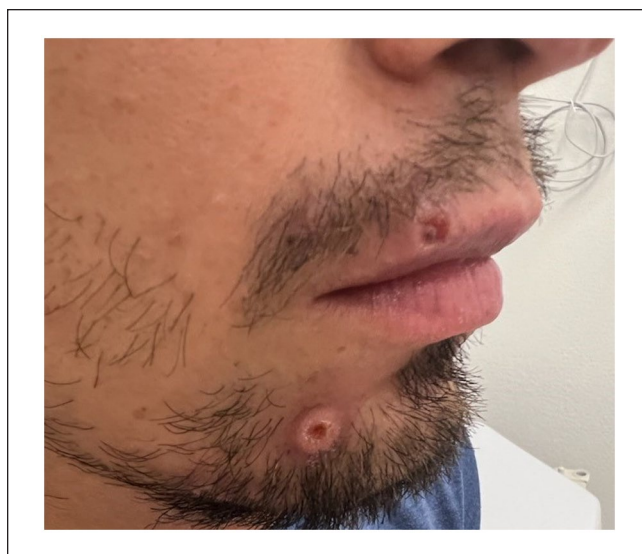This patient represents the first mpox diagnosis at our community institution, months after the mpox public health emergency had been identified at major metropolitan centers. This patient tested the readiness of the preparation plan for mpox at our institution and, in retrospect, offered a critique of the health care system at a local level.

Our patient would have benefited from receiving JYNNEOS as he was at high risk to contract mpox. However, for the months prior to his presentation, the supply of vaccines was still limited in this county and only available at certain public health vaccine clinics by appointment.

Our patient sought medical care for mpox within 1 week of symptom onset at an emergency department. Any earlier entry to care would require improved contact tracing to



**Image 3.** Maculopapular rash with herald patch on right chest.

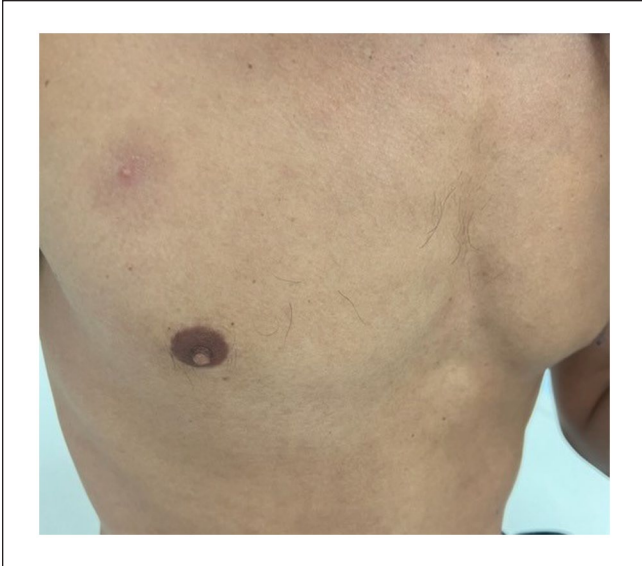

**Image 4.** Monkeypox lesions 17 days after symptom onset, 7 days after treatment initiation.

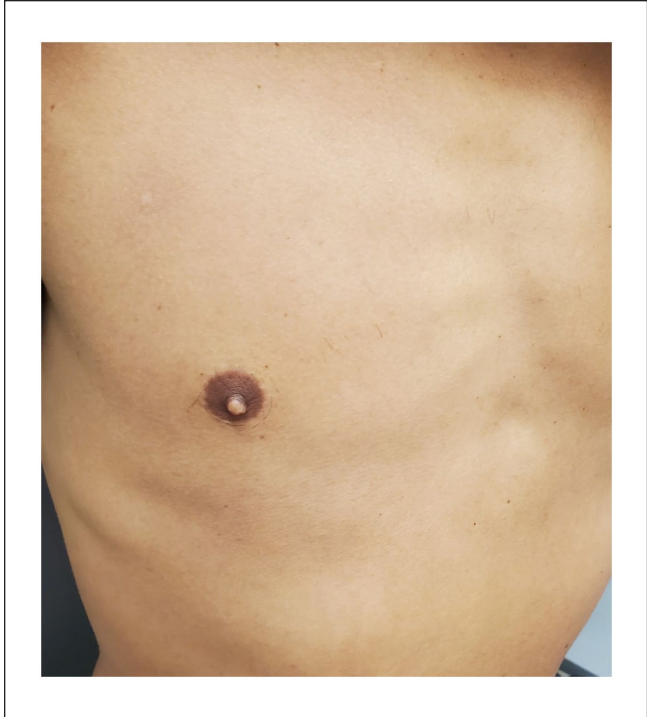
inform exposed contacts and offer post-exposure prophylaxis. He had not been contacted as part of contact tracing efforts. He denied close contact with others since returning from his trip to Hawaii.

The expansion of rapid diagnostic testing to commercial laboratories did help to diagnose him readily. As part of the expansion, testing at many points of initial health care contact, including urgent care clinics, emergency departments, as well as labor and delivery and primary provider offices is now possible. However, a 4-day turnaround for results leaves some room for improvement.

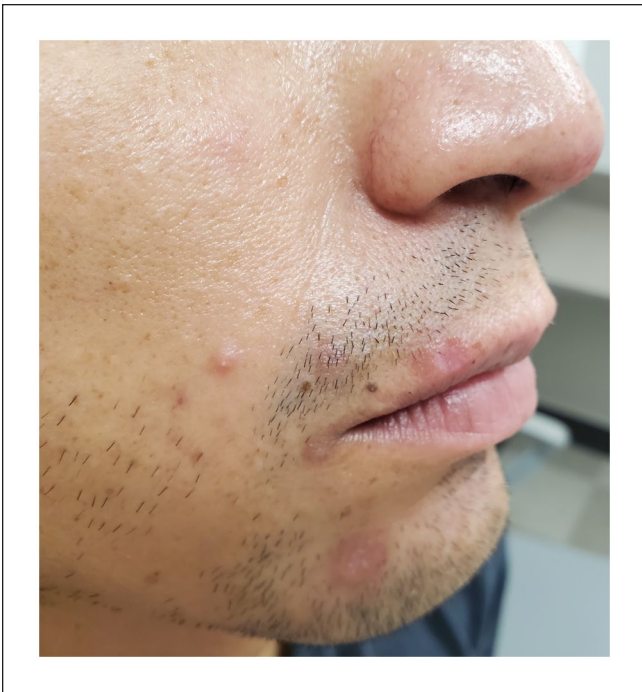



**Image 5.** Seven days after treatment initiation, maculopapular rash has completely resolved, and herald patch on right chest is improving.



**Image 7.** Herald patch is almost completely resolved 3 weeks after penicillin administration.



**Image 6.** Monkeypox lesions 1 week after treatment completion.

A strong clinical pharmacy team secured a supply of tecovirimat through the Strategic National Stockpile before our first patient arrived. This required coordination with the Kern County Public Health Department, the California Department of Public Health, and the CDC. There is a lack of data to date about the effectiveness of tecovirimat in

people with mpox and which patients might benefit the most from tecovirimat. There is also a concern for the development of resistance to tecovirimat from selective pressure with widespread use given its relatively low barrier to resistance. The decision to treat with tecovirimat was based on his HIV status and the onset of a new maculopapular rash that could have been early eczema or secondary syphilis without further testing.

Regular in-person follow-up of patients with mpox is not routine; however, it may yield the most therapeutic benefit given the stigma attached to mpox may lead at-risk individuals to avoid seeking or receiving comprehensive care. Secondary syphilis was eventually diagnosed by physical examination on follow-up. Two additional in-person follow-ups helped alleviate concerns and provide moral support to an otherwise vulnerable patient.

The majority of California's mpox experiences are in major metropolitan centers, such as Los Angeles, San Francisco, and San Diego, where public health resources are concentrated per capita. However, geospatial social determinants of health were found to contribute to health inequities as measured by Healthy Places Index,<sup>31</sup> and greater health inequities were associated with higher rates of sexually transmitted infections such as syphilis.<sup>32</sup> Central Valley of California scored low on the Healthy Places Index, which correlated with greater health inequities and is therefore at risk for more sexually transmitted infections, including syphilis. As such, during this mpox outbreak, co-infection testing

of sexually transmitted infections is important, particularly in areas of greater health inequities.

## Conclusion

Our case shows that patients diagnosed with mpox may need close follow-up to evaluate for new skin lesions and/or sexually transmitted co-infections that may manifest later. Preparation for the care of patients with mpox in a community hospital should follow that at the national level. It starts with the utilization of testing that is widely available now, physician education of signs and symptoms, and a ready supply of appropriate antivirals and personal protective equipment. Further studies need to be performed to validate whether individuals previously diagnosed with sexually transmitted infections such as HIV and syphilis are at higher risk for contracting the mpox virus. Such studies could lead to more effective identification of high-risk patients and more rapid intervention, treatment, and possibly decreased burden of disease.

## Acknowledgments

The authors wish to acknowledge the Kern County Public Health Department for their efforts during the mpox outbreak in Kern County. This case is submitted to American Federation of Medical Research's Western Conference, Carmel, CA, in January 2023.

## Declaration of Conflicting Interests

The author(s) declared no potential conflicts of interest with respect to the research, authorship, and/or publication of this article.

## Funding

The author(s) received no financial support for the research, authorship, and/or publication of this article.



## Ethics Approval

Ethical approval to report this case was obtained from the Kern Medical Institutional Review Board (IRB 22132).

## Informed Consent

Written informed consent was obtained from the patient for their anonymized information and photography to be published in this article.

## ORCID iDs

Carlos D'Assumpcao  <https://orcid.org/0000-0001-9967-9612>  
Arash Heidari  <https://orcid.org/0000-0003-1091-348X>

## References

1. McCollum AM, Damon IK. Human monkeypox. *Clin Infect Dis*. 2013;58(2):260-267.
2. von Magnus P, Anderson EK, Petersen KB, Birch-Andersen A. A pox-like disease in cynomolgus monkeys. *Acta Pathol Microbiol Scand*. 1959;46:156-176.
3. Doty JB, Malekani JM, Kalembo LN, et al. Assessing monkeypox virus prevalence in small mammals at the human-animal interface in the Democratic Republic of the Congo. *Viruses*. 2017;9(10):283.
4. Petersen E, Kantele A, Koopmans M, et al. Human monkeypox. *Infect Dis Clin North Am*. 2019;33(4):1027-1043.
5. Mauldin MR, McCollum AM, Nakazawa YJ, et al. Exportation of monkeypox virus from the African continent. *J Infect Dis*. 2022;225:1367-1376.
6. Rao AK, Schulte J, Chen TH, et al. Monkeypox in a traveler returning from Nigeria: Dallas, Texas, July 2021. *MMWR: Morb Mortal Wkly Rep*. 2022;71(14):509-516.
7. Costello V, Sowash M, Gaur A, et al. Imported monkeypox from international traveler, Maryland, USA, 2021. *Emerg Infect Dis*. 2022;28(5):1002-1005.
8. Reed KD, Melski JW, Graham MB, et al. The detection of monkeypox in humans in the Western Hemisphere. *N Engl J Med*. 2004;350(4):342-350.
9. Minhaj FS, Ogale YP, Whitehill F, et al. Monkeypox outbreak: nine states, May 2022. *MMWR: Morb Mortal Wkly Rep*. 2022;71(23):764-769.
10. Suárez Rodríguez B, Guzmán Herrador BR, Díaz Franco A, et al. Epidemiologic features and control measures during monkeypox outbreak, Spain, June 2022. *Emerg Infect Dis*. 2022;28(9):1847-1851.
11. Aden TA, Blevins P, York SW, et al. Rapid diagnostic testing for response to the monkeypox outbreak: laboratory response network, United States, May 17-June 30, 2022. *MMWR: Morb Mortal Wkly Rep*. 2022;71(28):904-907.
12. Philpott D, Hughes CM, Alroy KA, et al. Epidemiologic and clinical characteristics of monkeypox cases: United States, May 17-July 22, 2022. *MMWR: Morb Mortal Wkly Rep*. 2022;71(32):1018-1022.
13. Curran KG, Eberly K, Russell OO, et al. HIV and sexually transmitted infections among persons with monkeypox: eight U.S. jurisdictions, May 17-July 22, 2022. *MMWR: Morb Mortal Wkly Rep*. 2022;71(36):1141-1147.
14. Pfeiffer JA, Collingwood A, Rider LE, et al. High-contact object and surface contamination in a household of persons with monkeypox virus infection: Utah, June 2022. *MMWR: Morb Mortal Wkly Rep*. 2022;71(34):1092-1094.
15. Morgan CN, Whitehill F, Doty JB, et al. Environmental persistence of monkeypox virus on surfaces in household of person with travel-associated infection, Dallas, Texas, USA, 2021. *Emerg Infect Dis*. 2022;28(10):1982-1989.
16. Saunders KE, Van Horn AN, Medlin HK, et al. Monkeypox in a young infant: Florida, 2022. *MMWR: Morb Mortal Wkly Rep*. 2022;71(38):1220-1221.
17. Marshall KE, Barton M, Nichols J, et al. Health care personnel exposures to subsequently laboratory-confirmed monkeypox patients: Colorado, 2022. *MMWR: Morb Mortal Wkly Rep*. 2022;71(38):1216-1219.
18. Carvalho LB, Casadio LVB, Polly M, et al. Monkeypox virus transmission to healthcare worker through needlestick injury, Brazil. *Emerg Infect Dis*. 2022;28(11):2334-2336.
19. Caldas JP, Valdoleiros SR, Rebelo S, Tavares M. Monkeypox after occupational needlestick injury from pustule. *Emerg Infect Dis*. 2022;28:221374. doi:10.3201/eid2812.221374
20. Hagan LM, Beeson A, Hughes S, et al. Monkeypox case investigation: Cook County Jail, Chicago, Illinois, July-August

2022. *MMWR: Morb Mortal Wkly Rep.* 2022;71(40):1271-1277.
21. Ramnarayan P, Mitting R, Whittaker E, et al. Neonatal monkeypox virus infection. *N Engl J Med.* 2022;387:1618-1620.
  22. Minhaj FS, Petras JK, Brown JA, et al. Orthopoxvirus testing challenges for persons in populations at low risk or without known epidemiologic link to monkeypox: United States, 2022. *MMWR: Morb Mortal Wkly Rep.* 2022;71(36):1155-1158.
  23. Karan A, Styczynski AR, Huang C, et al. Human monkeypox without viral prodrome or sexual exposure, California, USA, 2022. *Emerg Infect Dis.* 2022;28(10):2121-2123.
  24. Pastula DM, Copeland MJ, Hannan MC, et al. Two cases of monkeypox-associated encephalomyelitis: Colorado and the District of Columbia, July-August 2022. *MMWR: Morb Mortal Wkly Rep.* 2022;71(38):1212-1215.
  25. Rao AK, Petersen BW, Whitehill F, et al. Use of JYNNEOS (smallpox and monkeypox vaccine, live, nonreplicating) for preexposure vaccination of persons at risk for occupational exposure to orthopoxviruses: recommendations of the Advisory Committee on Immunization Practices—United States, 2022 [Erratum in: *MMWR: Morb Mortal Wkly Rep.* 2022;71(27):886.]. *MMWR: Morb Mortal Wkly Rep.* 2022;71(22):734-742.
  26. Reed JL, Scott DE, Bray M. Eczema vaccinatum. *Clin Infect Dis.* 2012;54(6):832-840.
  27. O’Laughlin K, Tobolowsky FA, Elmor R, et al. Clinical use of tecovirimat (Tpoxx) for treatment of monkeypox under an investigational new drug protocol: United States, May-August 2022. *MMWR: Morb Mortal Wkly Rep.* 2022;71(37):1190-1195.
  28. Gandrakota N, Lee H, Nwosu O, et al. Monkeypox coinfection with neurosyphilis in a transgender with HIV in Atlanta, USA. *Travel Med Infect Dis.* 2022;50:102454.
  29. Oprea C, Ionuț Popa Ianache I, et al. Monkeypox, severe hepatitis A, and syphilis in an HIV returning traveler from Spain to Romania. *Travel Med Infect Dis.* 2022;50:102455.
  30. Bížová B, Veselý D, Trojáněk M, et al. Coinfection of syphilis and monkeypox in HIV positive man in Prague, Czech Republic. *Travel Med Infect Dis.* 2022;49:102368.
  31. Maizlish N, Delaney T, Dowling H, et al. California healthy places index: frames matter. *Public Health Rep.* 2019;134(4):354-362.
  32. Johnson KA, Snyder RE, Tang EC, et al. Geospatial social determinants of health correlate with disparities in syphilis and congenital syphilis cases in California. *Pathogens.* 2022;11(5):547.