

UCLA

UCLA Previously Published Works

Title

A Novel RPGR Exon ORF15 Mutation in a Family With X-linked Retinitis Pigmentosa and Coats'-like Exudative Vasculopathy

Permalink

<https://escholarship.org/uc/item/3fc5w8zd>

Journal

American Journal of Ophthalmology, 141(1)

ISSN

0002-9394

Authors

Demirci, F Yesim K
Rigatti, Brian W
Mah, Tammy S
[et al.](#)

Publication Date

2006

DOI

10.1016/j.ajo.2005.07.077

Peer reviewed

A Novel *RPGR* Exon ORF15 Mutation in a Family With X-linked Retinitis Pigmentosa and Coats'-like Exudative Vasculopathy

F. Yesim K. Demirci, MD, Brian W. Rigatti, MS, Tammy S. Mah, MS, and Michael B. Gorin, MD, PhD

PURPOSE: To describe the ophthalmic and genetic findings in a family with X-linked retinitis pigmentosa (RP) and Coats'-like exudative vasculopathy.

DESIGN: Observational case series.

METHODS: Family members underwent comprehensive ophthalmologic examination. Leukocyte genomic DNA samples were obtained and screened for *RPGR* (*RP3*) mutations by direct polymerase chain reaction sequencing.

RESULTS: The proband had RP with bilateral Coats'-like vasculopathy and was treated with fluorescein-potentiated argon laser therapy. The findings in two other affected male patients and three obligate carrier female patients were within the clinical spectrum of a typical X-linked-recessive RP. A novel nonsense *RPGR* exon ORF15 mutation (912G>T) was found to segregate with RP in this family.

CONCLUSIONS: This report expands the clinical heterogeneity spectrum caused by *RPGR* mutations and our knowledge concerning the molecular pathologic condition that pertains to Coats'-like RP. Consistent with the literature, Coats' response was not observed in all family members who were affected by RP, which suggests the involvement of other genetic and/or environmental factors. (Am J Ophthalmol 2006;141:208–210. © 2006 by Elsevier Inc. All rights reserved.)

X-LINKED RETINITIS PIGMENTOSA (XLRP) IS A SEVERE form of RP with an early-onset night blindness, progressive visual field constriction, and gradual central vision loss that leads to legal blindness by the third and fourth decades. Mutations in *RPGR* (*RP3*, Xp21.1) are responsible for up to 70% of XLRP¹ and also cause X-linked cone-rod dystrophy (*CORDX1*)² and atrophic macular degeneration.³

Coats' disease is a sporadic form of exudative retinal telangiectasia. It is usually unilateral, affects the young male patients, and manifests in the first decade of life with

intra- and subretinal exudates and dilated tortuous retinal vessels. Retinal telangiectasis that resembles Coats' disease is an uncommon (1.2% to 4.9%) complication of RP and differs from Coats' disease with regard to age (relatively older age), gender (no sex preference), bilateral eye involvement (more often bilateral), progression (more severe prognosis), and retinal location (mainly inferior quadrants and multifocal).⁴ Fifty-five percent of Coats'-like RP cases have been found to be associated with *CRB1* mutations.⁵

The proband was first seen at age 8 years, with a chief complaint of longstanding night blindness and a history of mild amblyopia in the right eye. Family history revealed RP in his brother, two maternal uncles, and one maternal cousin, which is consistent with XL inheritance. He had mild myopia ($-5.25 + 1.75 \times 115$ oculus dexter; $-2.50 + 1.25 \times 160$ oculus sinister), corrected visual acuities of 20/60 oculus dexter and 20/50 oculus sinister, and bilateral markedly constricted confrontation visual fields. Fundus examination revealed markedly attenuated retinal vessels and extensive midperipheral pigment epithelial changes, with rare areas of intraretinal pigment. In the inferior mid-periphery of the left eye, there was a small area of retinovascular leakage with mild exudates and edema. Because this involved an already atrophic area, no treatment was undertaken, and a 6-month follow-up period was recommended. The patient returned 2.5 years later (age, 10.5 years) with markedly decreased vision (oculus dexter: hand motions; oculus sinister: 20/200), bilateral intra- and subretinal exudates, hemorrhage, and macular edema (oculus dexter > oculus sinister). Multiple sessions of modified fluorescein-potentiated argon laser photocoagulation (FPAL)⁶ were applied to vascular leakage areas over a 1-year period. During a 2-year period, the lesions regressed; exudates resolved, and retina reattached (Figures 1 and 2). At his most recent visit (age, 16 years), his vision and retinal status were stable in both eyes.

Clinical findings of other family members (two affected male patients and three obligate carrier female patients) were consistent with typical X-linked-recessive RP with posterior subcapsular cataract complication. The proband was the only family member who had Coats'-like RP. Informed consent was obtained before participation in the study in accordance with a University of Pittsburgh institutional review board-approved protocol. The leukocyte genomic DNA samples were obtained and screened for *RPGR* mutations with direct polymerase chain reaction sequencing of the coding exons and flanking intronic regions. A novel nonsense *RPGR* exon ORF15 mutation (912G>T) was found to segregate with RP in this family (Figure 3).

Our findings provide several new observations for which we could find no reference from a computerized MEDLINE search: (1) association of XLRP with Coats'-like vasculopathy, (2) a novel *RPGR* mutation that confirmed XLRP diagnosis, and (3) use of FPAL as an effective therapy for Coats'-like RP. This report expands the clinical heteroge-

Accepted for publication Jul 29, 2005.

From the Department of Ophthalmology, School of Medicine (F.Y.K.D., B.W.R., T.S.M., M.B.G.), and the Department of Human Genetics, Graduate School of Public Health (F.Y.K.D., M.B.G.), University of Pittsburgh, Pittsburgh, Pennsylvania.

Supported in part by National Institutes of Health grant EY13130; National Institutes of Health core grant EY08098; The Eye & Ear Foundation of Pittsburgh, Pittsburgh, Pennsylvania; and Research to Prevent Blindness, New York, New York.

Inquiries to Michael B. Gorin, MD, PhD, UPMC Eye Center, University of Pittsburgh, 203 Lothrop St, EEINS Building, Room 1025, Pittsburgh, PA 15213; fax: (412) 647-5880; e-mail: gorinmb@upmc.edu

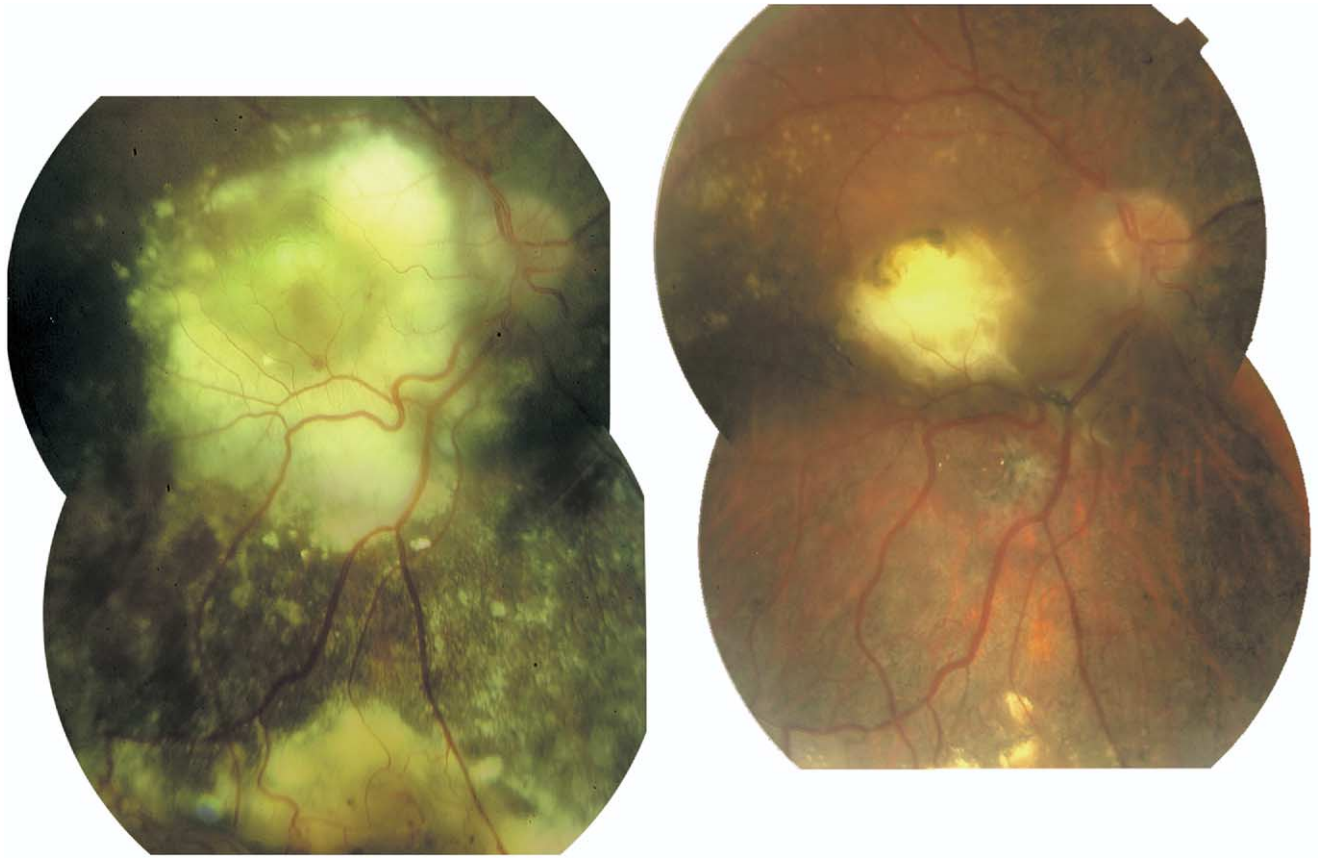


FIGURE 1. The right fundus of the male patient with Coats'-like retinitis pigmentosa at the beginning of (Left Panel) and after (Right Panel) the fluorescein-potentiated argon laser therapy sessions. Note a major focus of retinovascular telangiectasis in the inferior midperiphery with exudates and retinal hemorrhages (Left Panel). A second major area of telangiectasis and leakage, superotemporal to the macula (not shown in this figure), was responsible primarily for the secondary severe macular exudation and edema (Left Panel). After the treatment, the exudates and edema resolved completely, although an atrophic chorioretinal scar in the central macula persisted (Right Panel).

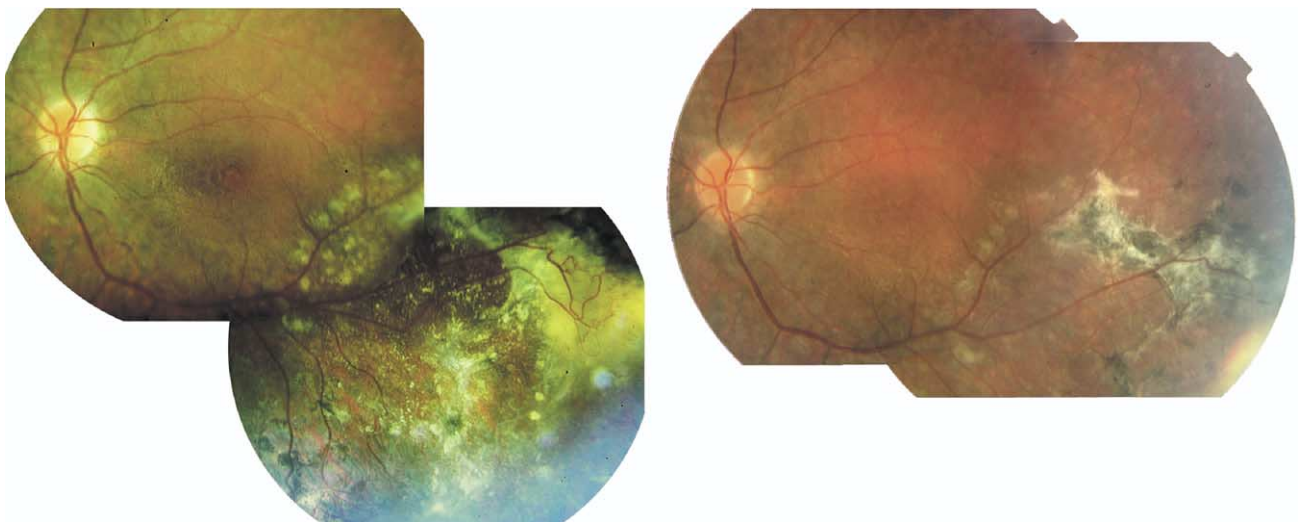


FIGURE 2. The left fundus of the male patient with Coats'-like retinitis pigmentosa at the beginning of (Left Panel) and after (Right Panel) the fluorescein-potentiated argon laser therapy sessions. Note one major focus of retinovascular telangiectasis that is associated with exudates and edema that affect the inferotemporal midperiphery (Left Panel). A complete resolution of exudates and regression of tortuous vessels had been achieved after the treatment (Right Panel). Note the formation of the pigmented subretinal fibrosis and scarring that are temporal to a row of photocoagulation scars. The cystoid macular edema showed partial resolution after the treatment.

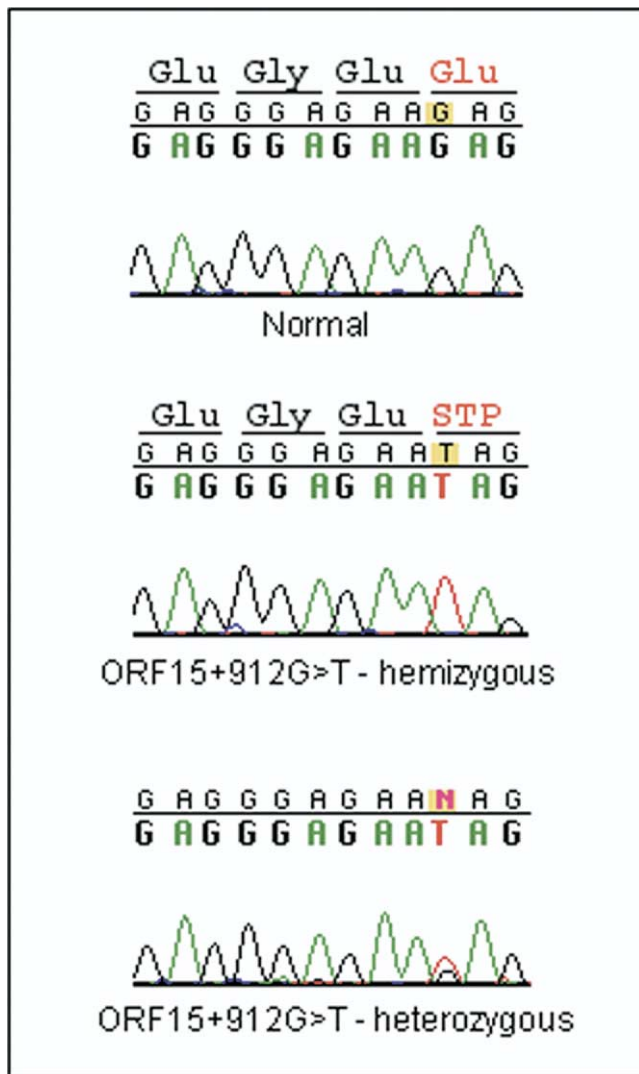


FIGURE 3. *RPGR* exon ORF15 (AF286472) mutation with the predicted alteration in the translation product. Sequence chromatograms show a normal person (Top), the ORF15 + 912G >T mutation in a hemizygous affected male patient (Middle) and in a heterozygous carrier female patient (Bottom). This mutation is predicted to cause a premature stop in the translation that results with a truncated protein that is missing 264 amino acid residues at the carboxyl end.

neity of *RPGR*-associated retinopathies and the genetic heterogeneity of Coats'-like RP.

Consistent with previous reports, Coats' response was not observed in all affected family members, which suggests the involvement of genetic and/or environmental factors that are independent of RP-causing mutation. One study reported the association of germline or somatic Norrie disease gene (*NDP*, Xp11.4) mutations with Coats' disease⁷; however, the *NDP* sequencing did not reveal any germline variants in our family.

Because of their RP-related visual impairment, the patients may not notice the effects of Coats' response at early stages.

It is important to offer periodic retinal examinations to at-risk patients because early recognition and treatment of the problem may lead to a better prognosis. Treatment options include cryotherapy, scleral buckling with subretinal fluid drainage, and traditional photocoagulation. The FPAL appears to be an efficient and the least invasive treatment option for the management of this complication.

REFERENCES

1. Vervoort R, Wright AF. Mutations of *RPGR* in X-linked retinitis pigmentosa (RP3). *Hum Mutat* 2002;19:486–500.
2. Demirci FY, Rigatti BW, Wen G, et al. X-linked cone-rod dystrophy (locus COD1): identification of mutations in *RPGR* exon ORF15. *Am J Hum Genet* 2002;70:1049–1053.
3. Ayyagari R, Demirci FY, Liu J, et al. X-linked recessive atrophic macular degeneration from *RPGR* mutation. *Genomics* 2002;80:166–171.
4. Khan JA, Ide CH, Strickland MP. Coats'-type retinitis pigmentosa. *Surv Ophthalmol* 1988;32:317–332.
5. den Hollander AI, Heckenlively JR, van den Born LI, et al. Leber congenital amaurosis and retinitis pigmentosa with Coats-like exudative vasculopathy are associated with mutations in the crumbs homologue 1 (*CRB1*) gene. *Am J Hum Genet* 2001;69:198–203.
6. Gorin MB. Von Hippel-Lindau disease: clinical considerations and the use of fluorescein-potentiated argon laser therapy for treatment of retinal angiomas. *Semin Ophthalmol* 1992;7:182–191.
7. Black GC, Perveen R, Bonshek R, et al. Coats' disease of the retina (unilateral retinal telangiectasis) caused by somatic mutation in the *NDP* gene: a role for norrin in retinal angiogenesis. *Hum Mol Genet* 1999;8:2031–2035.

Spontaneous Resolution of Macular Microhole

Michael M. Lai, MD, PhD,

Susan B. Bressler, MD, and Julia A. Haller, MD

PURPOSE: To report a case of spontaneous resolution of macular microhole.

DESIGN: Observational case report.

METHODS: Clinical examination and optical coherence tomography (OCT) evaluation of a patient who experienced spontaneous resolution of a macular microhole.

RESULTS: A 62-year-old woman with decreased vision was found to have a full-thickness macular microhole with posterior vitreous detachment and an operculum on fundus biomicroscopy and OCT. Spontaneous resolution of the microhole was documented on clinical examination

Accepted for publication Jul 29, 2005.

From the The Retina Division, Wilmer Ophthalmological Institute, Johns Hopkins University School of Medicine, Baltimore, Maryland.

Inquiries to Julia A. Haller, MD, The Wilmer Ophthalmological Institute, The Johns Hopkins Medical Institutions, 600 North Wolfe St, Baltimore, MD 21287; fax: 410-614-3543; e-mail: jhaller@jhmi.edu.