

UC Irvine

Clinical Practice and Cases in Emergency Medicine

Title

Adrenocortical Carcinoma Discovered with Point-of-care Ultrasound

Permalink

<https://escholarship.org/uc/item/3dp355p2>

Journal

Clinical Practice and Cases in Emergency Medicine, 5(4)

Authors

McIntyre, Mark
Prats, Michael I.

Publication Date

2021

DOI

10.5811/cpcem.2021.5.51875

Supplemental Material

<https://escholarship.org/uc/item/3dp355p2#supplemental>

Copyright Information

Copyright 2021 by the author(s). This work is made available under the terms of a Creative Commons Attribution License, available at <https://creativecommons.org/licenses/by/4.0/>

Peer reviewed

Adrenocortical Carcinoma Discovered with Point-of-care Ultrasound

Mark McIntyre, MD, MBA
Michael I. Prats, MD

Ohio State University College of Medicine, Department of Emergency Medicine,
Columbus, Ohio

Section Editor: Shadi Lahham, MD, MS

Submission history: Submitted January 25, 2021; Revision received May 27, 2021; Accepted May 28, 2021

Electronically published October 5, 2021

Full text available through open access at http://escholarship.org/uc/uciem_cpem

DOI: 10.5811/cpem.2021.5.51875

Case Presentation: A 34-year-old woman presented to the emergency department with bilateral lower extremity edema and shortness of breath. She had been seen by her primary care provider. Lab work and a follow-up with endocrinology had been unrevealing. Using point-of-care ultrasound we identified a cystic mass in the right upper quadrant prompting further imaging.

Discussion: Abdominal and pelvic computed tomography confirmed a mass in the right posterior liver, which was later identified as an adrenocortical carcinoma. Ultrasound is an important diagnostic tool in the setting of lower extremity edema and can be used to assess for heart failure, liver failure, obstructive nephropathy, venous thrombosis, and soft tissue infection. In this case, ultrasound helped expedite the diagnosis and treatment of a rare malignancy. [Clin Pract Cases Emerg Med. 2021;5(4):482–484.]

Keywords: *ultrasound; imaging; malignancy; oncology; adrenocortical carcinoma.*

CASE PRESENTATION

A 34-year-old woman presented to the emergency department (ED) with progressive leg swelling. Thorough laboratory testing as an outpatient and in the ED was unrevealing. To evaluate further the causes of her dyspnea and edema, we performed a point-of-care ultrasound (POCUS) of the heart, lungs, and abdomen. While evaluating for evidence of ascites, a large mass with anechoic center was identified in the right upper quadrant (Video, Images 1 and 2). This prompted computed tomography (CT) of the abdomen and pelvis, which confirmed a 7.9 x 9.1 x 8.7 centimeter mass arising from the right posterior liver, extending into the inferior vena cava with an associated near-occlusive tumor thrombus (Image 3). During admission, a biopsy was performed revealing adrenocortical carcinoma (ACC).

DISCUSSION

Adrenocortical carcinomas can present as either non-secreting or hormone secreting.¹ The diagnostic workup for ACC includes the measurement of steroid hormones produced by tumor, imaging via contrast-enhanced CT or magnetic

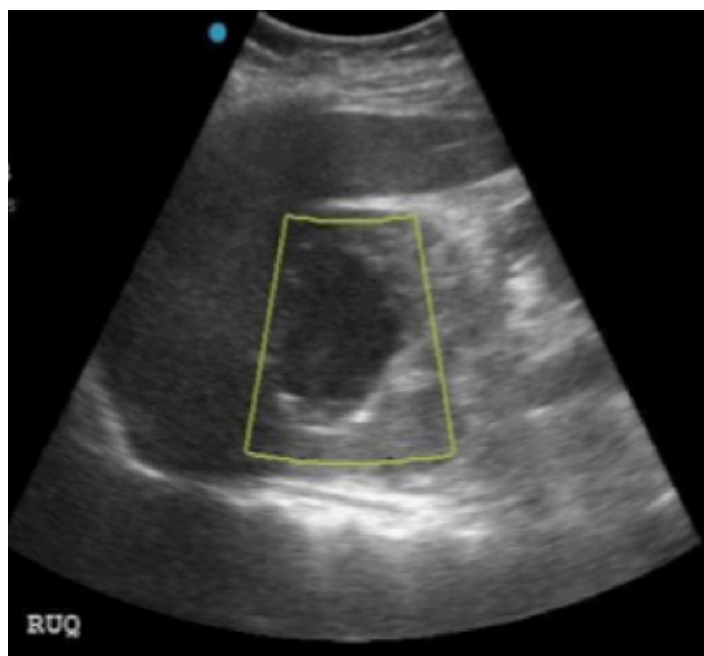

Image 1. Upper quadrant mass seen on emergency physician-performed point-of-care ultrasound. Color Doppler demonstrating no flow (yellow box).

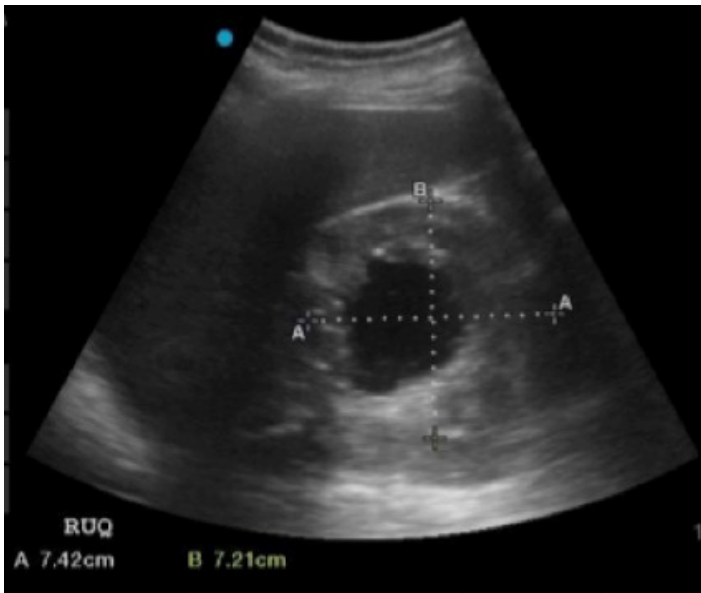


Image 2. Right upper quadrant mass seen on emergency physician-performed point-of-care ultrasound. Measurements showing 7.42 x 7.21 cm in cephalad-caudal and lateral dimensions, respectively.

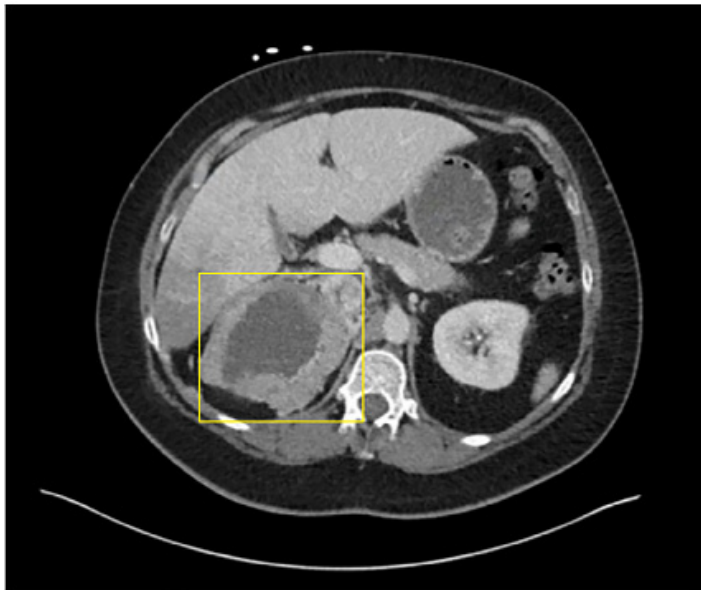

Image 3. Axial computed tomography demonstrating cystic mass in right upper quadrant (yellow box).

resonance, and biopsy if indicated.² An ACC can be quite large, which incurs a higher risk of complications such as vasculature obstruction, related to the size of the malignancy.³ Thus, it is important to identify these tumors expeditiously and begin treatment as soon as possible. The sonographic appearance of ACC is a large, heterogeneous solid or cystic mass positioned adjacent to the kidney.⁴

CPC-EM Capsule

What do we already know about this clinical entity?

Adrenocortical carcinomas present with a variety of symptoms. Typical diagnostic workup includes measuring steroid hormones, computed tomography or magnetic resonance imaging, and biopsy.

What is the major impact of the image(s)?

In these images, the utility of point-of-care ultrasound (POCUS) as a diagnostic tool is demonstrated in the setting of unclear symptom etiology.

How might this improve emergency medicine practice?

Using POCUS can help narrow differential diagnosis, identify symptom etiology, and expedite treatment.

There is a broad differential diagnosis for a patient presenting to the ED with lower extremity edema. Point-of-care ultrasound has proven useful in diagnosing many of these etiologies such as acute heart failure, ascites, obstructive nephropathy, venous thromboembolic disease, and soft tissue infection.⁵ In this case, a systematic POCUS evaluation revealed an unexpected cause for the patient's symptoms, thus expediting her workup and treatment. Multiorgan POCUS is a reasonable early step in the diagnostic management of undifferentiated lower extremity edema. Emergency physicians should be able to recognize concerning sonographic findings and pursue the next steps in diagnostic testing for abdominal neoplasms.

Video. Right upper quadrant mass. Ultrasound transducer held in the posterior axillary line demonstrating a circular mass with an anechoic center (arrow) as the beam fans from anterior to posterior.

The author attests that their institution requires neither Institutional Review Board approval, nor patient consent for publication of this case report. Documentation on file.

Address for Correspondence: Michael I. Prats, MD, Ohio State University Wexner Medical Center, Department of Emergency Department, 757 Prior Hall, 376 W 10th Ave, Columbus, OH 43210. Email: Michael.prats@osumc.edu.

Conflicts of Interest: By the CPC-EM article submission agreement, all authors are required to disclose all affiliations,

funding sources and financial or management relationships that could be perceived as potential sources of bias. The authors disclosed none.

Copyright: © 2021 McIntyre. This is an open access article distributed in accordance with the terms of the Creative Commons Attribution (CC BY 4.0) License. See: <http://creativecommons.org/licenses/by/4.0/>

REFERENCES

1. Libè R, Fratticci A, Bertherat J. Adrenocortical cancer: pathophysiology and clinical management. *Endocr Relat Cancer*. 2007;14(1):13-28.
2. Willatt J and Francis IR. Imaging and management of the incidentally discovered renal mass. *Cancer Imaging*. 2009;9 Spec No A(Special Issue A):S30-S37.
3. Amodru V, Taieb D, Guerin C, et al. Large adrenal incidentalomas require a dedicated diagnostic procedure. *Endocr Pract*. 2019;25(7):669-77.
4. Stapa RZ, Kasperlik-Zaluska AA, Migda B, et al. Echogenicity of benign adrenal focal lesions on imaging with new ultrasound techniques – report with pictorial presentation. *J Ultrason*. 2015;15(63):368-76.
5. ACEP Policy Statement. Ultrasound guidelines: emergency, point-of-care and clinical ultrasound guidelines in medicine. *Ann Emerg Med*. 2017; 69(5):e27-e54.