

UCLA

UCLA Electronic Theses and Dissertations

Title

Estrogen Delivery as a Tool to Enhance Orthodontic Expansion Stability

Permalink

<https://escholarship.org/uc/item/3d02v4gb>

Author

Ohebsion, Tania Serah

Publication Date

2016

Peer reviewed|Thesis/dissertation

UNIVERSITY OF CALIFORNIA

Los Angeles

Estrogen Delivery as a Tool to Enhance
Orthodontic Expansion Stability

A thesis submitted in partial satisfaction
of the requirements for the degree of Master of Science
in Oral Biology

by

Tania Serah Ohebsion

2016

© Copyright by
Tania Serah Ohebsion
2016

ABSTRACT OF THE THESIS

Estrogen Delivery as a Tool to Enhance
Orthodontic Expansion Stability

By

Tania Serah Ohebsion

Master of Science in Oral Biology

University of California, Los Angeles, 2016

Professor Yeumin Hong, Chair

Palatal expansion, frequently utilized for correcting transverse discrepancy, relief of crowding, and prior to bone grafting, is prone to significant relapse. With a need for treatment that improves the success of expansion, we hypothesized that estrogen (E2) will decrease relapse by increasing bone formation following expansion of the suture. Due to its short half-life and potential systemic effects, E2 was combined with nanodiamond (ND) and hydrogel (G). 18 rats underwent 7 days of palatal expansion and were divided into 5 groups (Control, E2, E2/ND, E2/G, E2/ND/G) for palatal injections. After 14 days of retention, expanders were removed for relapse. The addition of ND and G to E2 significantly reduced the relapse ratio and increased bone density. Staining showed greater mineralized area/total area, decreased number of osteoclasts, and increased osteoblasts in sutures in this group. These findings demonstrate local delivery of E2 may improve stability and predictability of palatal expansion.

The Thesis of Tania Serah Ohebsion is approved.

Dean Ho

Reuben Han-Kyu Kim

Yeumin Hong, Committee Chair

University of California, Los Angeles

2016

Table of Contents

Introduction.....	1
Transverse Discrepancy and Palatal Expansion.....	1
Palatal Expansion in Craniofacial Patients.....	4
Previous Studies.....	5
Estrogen.....	6
Nanodiamond and Hydrogel.....	8
Hypothesis and Aims.....	9
Materials and Methods.....	10
Experimental Subjects.....	10
Synthesis of E2/ND.....	10
Synthesis of E2/G.....	11
Synthesis of E2/ND/G.....	12
Expander Design.....	13
Expander Placement.....	13
Injections.....	13
Retention	14
Relapse.....	14
<i>In vivo</i> Micro-CT.....	14
Data Analysis.....	15
Diastema Measurements.....	15
Micro-CT Analysis.....	15
Histological Analysis	16

TRAP staining.....	16
Immunohistochemistry.....	17
Results.....	17
Relapse Ratio.....	17
Micro-CT Analysis	18
Histological Analysis.....	18
Osteoclasts.....	19
Osteoblasts.....	19
Immunohistochemistry.....	20
Discussion.....	20
Conclusion.....	25
Figures.....	27
Works Cited.....	42

INTRODUCTION

Transverse Discrepancy and Palatal Expansion

Palatal expansion is a frequent adjunctive procedure for orthodontic patients when the upper arch is found to be narrower than the lower. While it is typically required for the treatment of a transverse posterior discrepancy, it is also used to relieve minor to moderate crowding in the maxilla, in conjunction with orthopedic facemask treatment of Class III patients, and prior to bone grafting in cleft palate patients.^{1,2,3} In some instances an untreated posterior crossbite results in a functional shift of the mandible that could lead to the development of skeletal asymmetries, changes to the temporomandibular joint, and modifications of soft tissue growth.⁴ Therefore, palatal expansion should be recommended in some instances to avoid alarming long-term consequences to facial skeletal development.

While results of epidemiological studies in different populations are wide-ranging, one study indicates that the incidence of posterior crossbite in the mixed dentition can be as high as 18%.⁵ These findings are attributed to lateral constriction of the maxilla, and this malocclusion typically does not resolve on its own. With age, the midpalatal suture becomes increasingly interdigitated and growth in the transverse dimension of the maxilla is the first to be completed, and a constricted maxillary arch is the aspect of a malocclusion least likely to correct itself.^{6,7} The incidence of maxillary transverse deficiency in the adult population has yet to be determined.⁸

The etiology of transverse discrepancy is multifactorial and can be attributed to both environment and genetics.⁹ In experiments Harvold et al. were able to produce narrow maxillas in rhesus monkeys when transformed from nasal to obligatory oral breathers.¹⁰ Moreover, oral habits, visceral swallowing, and articulation problems were statistically more frequent in the

primary dentition in children presenting with narrow maxillary arches.¹¹ Cozza et al. found that prolonged sucking habits in the mixed dentition of vertical growers increased the prevalence of posterior crossbite by 52% as compared to their control.¹² Hence, transverse discrepancies often develop from environmental factors present in early dentition and transverse correction may be required early in primary or early mixed dentition.

In an autopsy study Melsen was able to categorize the morphological development of the palatal suture into stages.¹³ A very broad and Y shaped suture was present during the infantile period, but once in the juvenile period the suture was more wavy and longer vertically. By the third period, adolescents, the suture was significantly more tortuous and interdigitated. In another autopsy study with specimens ranging from ages 15-35, significant variation was found in the timing of suture ossification.¹⁴ Despite this variation, Bishara recommends that the optimal age for expansion be before 13 to 15 years since in older patients there is a decline in stability and predictability of expansion procedures.⁹

Differing expansion protocols are prescribed depending on the frequency of activation, magnitude of force, duration of treatment, and the patient's age.¹⁵ While during childhood expansion can be accomplished with almost any type of expansion, by early adolescence, substantial force is required to achieve expansion. Rapid maxillary expansion (RPE) increases the transverse dimensions through separation of the maxillary suture and buccal movement of the posterior teeth and alveolar processes.⁵ The relative contribution of the skeletal and dental changes to the total increase in the transverse dimension depends on the patient's maturity.⁵ A recent modification to the RPE design, micro-implant assisted rapid palatal expander (MARPE) utilizes temporary micro-implants in the palate to achieve more skeletal changes. With the

development of MARPE the population in which palatal expansion can be achieved successfully has expanded to include adults and those with fused sutures.¹⁶

The palatal suture consists of mostly collagenous fibrous tissue with osteogenic layers covering the bony surfaces.⁶ In response to forces, the suture widens, the orientation of fiber bundles changes and osteoblasts increase on the bone surfaces indicating bone deposition. Consequently, the gradual deposition of bone in the suture in turn requires a lengthy retention period, since separated maxillary segments relapse toward each other in the time it takes for new bone to fill in.

Bishara recommends leaving in the immobilized expander for a period of 3-6 months for tissue reorganization, followed by placement of a transpalatal holding arch. His findings also propose that the greater the amount of expansion the lengthier the duration of retention.⁹ In a study by Ekstrom et al., much of the mineral content in the suture was obtained rapidly in the first month following expansion but the subsequent mineralization was far more gradual until 3 months time.¹⁷ In experiments using metallic implants Krebs found that a retention period of 3 months with a fixed appliance followed by a removable appliance is suggested and after fixed retention there was a decline in dental arch width that continued for up to 5 years.¹⁸

Hicks established that the amount of relapse varies significantly from 10-23% with fixed retention, to as high as 45% when no retention is used.¹⁹ Another study found that even when palatal expansion is followed by fixed appliances there is significant relapse, with the greatest amount, 37%, in the intercanine width.²⁰ Other long-term follow-up studies have shown that greater than 50% of the achieved expansion was lost within 5 years post-treatment.²¹ Aside from the gradual rate of bone formation, circumaxillary resistance, soft tissue changes, and age have

also been considered to play a role in promoting relapse.²² These findings suggest that the relapse associated with palatal expansion is a substantial problem in clinical orthodontics.

Palatal Expansion in Craniofacial Patients

The effects of relapse are even more significant in the treatment of craniofacial patients such as those with cleft lip and/or palate (CLP), since their treatment often involves already complex, multidisciplinary efforts. The incidence of craniofacial anomalies aside from oral clefts is 1 in 1600 births in the U.S. and may involve jaw deformities such as a narrow palate.²³ Apert, Crouzon and Marfan syndromes are just a few examples of craniofacial syndromes characterized by narrow and arched palates frequently requiring expansion.^{24,25}

With an incidence of 1 in every 700 live births, CLP is one of the most common congenital malformations and is the most frequent craniofacial anomaly.²³ Syndromic clefts have been associated with multiple syndromes such as Pierre-robin, Treacher Collins, and Opitz. CLP patients commonly exhibit maxillary skeletal deficiency comprised of anterior or posterior crossbites or both.²⁶ In a study conducted by Li and Lin on unilateral CLP patients, 65% of patients had bilateral posterior crossbites and the authors attribute this high number to scar tissue constriction, muscle pressure, and trauma from surgical correction of palatal clefts.²⁷

Patients typically require grafting when there is a presence of an oro-nasal fistula or a bony defect in the alveolar process.³ According to Enemark, the optimal treatment sequence involves maxillary expansion in the late mixed dentition—prior to canine eruption—to correct the lateral crossbite and provide greater space for grafting, followed by bone grafting.³ Robertson and Fish reviewed cases of 40 children with expansion and grafting at an early age and found that despite the graft remaining, expansion relapsed and crossbites returned.²⁸ They also concluded that the degree of relapse might be attributed to tension from the soft tissues of the lip

and cheek. In addition, while overexpansion is a possibility to compensate for probable relapse it is not valuable since the goal is to achieve better occlusion.

Nicholson and Plint examined records of cleft palate patients who had undergone maxillary expansion and found that a staggering 80% of the cases had moderate (25-50%) to total (76% or worse) relapse of their initial expansion.²⁹ They showed that even in cases with posterior retention following expansion, only approximately one quarter had acceptable levels of relapse (less than 25%). This indicates that relapse which is already a considerable problem in the general orthodontic population is an even more significant consequence of expansion in CLP patients.

In their study Ramstad and Jendal found that the palatal width reduction was mostly during the first five years following treatment but that the reduction did not even stabilize at their final observation point of 13 years.³⁰ The complications associated with constricting soft tissue scars, aberrant muscular forces, and insufficient palatal bone support, which require expansion in the first place, are what can create an unstable environment prone to relapse.²⁷ Relapse of the palate could potentially lengthen overall treatment time by necessitating repeat expansion and grafting, increase financial demands on families, and invoke emotional distress on patients.

Previous Studies

A number of studies have been conducted in attempts to accelerate bone formation in the palate and prevent the extent of post-expansion relapse. Glycogen synthase kinase-3 β (GSK-3 β) inhibitor was used to stimulate bone formation in the expanding premaxillary suture through β -catenin signaling, but long-term studies are still needed to validate these findings.²² Recombinant human bone morphogenetic protein-2 (rhBMP-2) used to stimulate bone formation in expanded

rat sagittal sutures appears promising but further studies in a palatal expansion model is necessary to confirm.³¹ A recent study using strontium ranelate, a pharmacologic agent for osteoporosis, is limited since the mechanism for induction of bone regeneration is still uncertain to authors.³²

Uysal et al. evaluated the effects of dietary boron on midpalatal suture bone regeneration in rabbits but this study is inadequate since systemic boron administration limits the ability to examine the direct effects of boron on bone regeneration and there are potential adverse systemic effects.³³ Another study that involved oral intake of lithium, an activator of β -catenin signaling, is concerning due to the known systemic effects of lithium.³⁴ Other studies designed to accelerate bone formation following expansion procedures have used Nell-1, thymoquinon, vitamin D, as well as direct electrical currents.^{35,36,37,38}

In a recent study by Iravani a novel expander design was inserted to achieve palatal expansion and bisphosphonate was administered systemically to stimulate bone formation in the suture.³⁹ Relapse was reduced by approximately 50% with bisphosphonate administration compared to control but concerns remain over increase risk of bisphosphonate-related osteonecrosis of the jaw (BRONJ), soft tissue healing, as well as other systemic effects that are yet to be determined. Consequently, there is still a demand for a practical and nontoxic treatment that could stimulate bone formation in the suture and prevent relapse.

Estrogen

Estrogen (E2) is a naturally occurring steroid that plays a critical role in bone homeostasis and it could be utilized to stimulate bone formation in the expanded palatal suture. E2 is the primary female sex hormone that is involved in the development of secondary sexual characteristics, but its effects are seen in many tissues including bone, adipose, brain, skeletal

muscle and the cardiovascular system.⁴⁰ It is involved in regulation of lipoprotein synthesis and insulin responsiveness, as well as maintenance of bone mass in both sexes among its many roles. E2 is clinically important for bone metabolism and the deficiency of which is critical in postmenopausal osteoporosis, a profoundly significant condition particularly for older women.⁴¹

Bone remodeling involves the balance between osteoblastic and osteoclastic activity in the skeleton, and bone homeostasis is disturbed when E2 levels drop.⁴² The actions of E2 are mediated through the estrogen receptor (ER), which is found in two forms: ER α and ER β .^{43,44} Binding of a ligand to the ER triggers conformational changes that result in altered transcriptional activation of E2-regulated genes.⁴⁵ The main mediator of E2's impact on the skeleton is ER α . In its pleiotropic regulation of bone turnover E2 is shown to have effects on osteocytes, osteoblasts, osteoclasts and T cells.⁴² The main function of E2 is to effect bone remodeling via osteocytes, but E2 is also involved in decreasing osteoblast apoptosis. Another role of E2 includes inhibiting bone resorption by direct effects on osteoclasts, but also includes modulating T cell regulation of osteoclasts.

E2's osteoprotective role has been established in a number of notable rodent studies. One study by Nakamura et al. indicates that induction of Fas/FasL by E2 induces osteoclast apoptosis.⁴⁶ Specifically, ER α , the osteoclastic estrogen receptor, mediates bone regulation in female mice, such that ER α ablation in osteoclasts, results in trabecular bone loss in these mice models. In ER α knock-out mice, both cortical and cancellous bone show compromised bone strength.⁴⁷ Another study by Bradford et al. suggests that estrogen is involved in prevention of osteoblast apoptosis by repressing caspase-3 activity in models with G-292 human osteosarcoma cells, a human osteoblast model.⁴⁸

James et al. investigated the effect of E2 and ER on cranial suture biology using mouse suture-derived mesenchymal cells and found that 17 β -estradiol enhanced osteogenic and chondrogenic differentiation in these cells.⁴⁹ Moreover, results were further confirmed *in vivo* when the estrogen antagonist Fulvestant inhibiting calvarial suture fusion. In another study by Bain et al., ovariectomized mice were given 500ug E2, which increased the cancellous bone formation rate by 83% and increased bone formation on the endosteal surface of the diaphysis compared to sham/vehicle mice.⁵⁰

Despite the favorable role of E2 in bone formation, its clinical application is less encouraging due to various limitations including E2's pleiotropic effects and short half-life of approximately 13.5 hours.⁵¹ E2 has various long-term safety issues that have arisen out of treatments designed for the management of osteoporosis.⁵² In fact, the negative side effects associated with the use of E2 are well documented and include invasive breast cancer, coronary heart disease, and stroke.⁵³

Nanodiamonds and Hydrogels

To maximize the efficacy of E2, minimize some of its limitations, ensure that it remains localized, and foster a sustained release, nanodiamond (ND) and hydrogel (G) were considered. NDs are carbon byproducts with many of the desirable properties of large diamonds but packaged in a nanoscale.⁵⁴ They are non-toxic and offer good biocompatibility and chemical stability in solution, qualities that make their clinical application possible and desirable. Additionally, NDs are excellent drug delivery platforms due to their surface characteristics, one of which is their drug retention properties. Importantly, this allows for loading of a variety of therapeutics and the potential for targeted therapy. Moreover, their particles have displayed local and sustained release of therapeutics for up to 1 month. Lam et al. were one of the first to show

this when they adsorbed a chemotherapeutic agent onto ND surfaces.⁵⁵ Results displayed a gradual desorption and sustained release of their cancer cell therapy.

To further guarantee that E2 remains in the desired area for maximum effect, NDs could also be integrated with Gs. Gs are cross-linked arrangements of biocompatible, water-soluble polymers that can be composed of a variety of chemicals that produce unique properties suitable for a vast array of applications.⁵⁶ In a study by Maran et al. that investigated anti-tumor effects in osteosarcoma cells, a G composed of a naturally occurring metabolite of 17 β -estradiol sustained a 21-day release.⁵⁷ G has also been used in the treatment of retinal neurovascular degeneration through sustained release of insulin specifically to the retina, something that is difficult to achieve with conventional methods alone.⁵⁸ When drugs are loaded onto the gel matrix they are released slowly and remain at a high concentration locally. However, one limitation in the use of hydrogels is with hydrophobic drugs, which may be released too rapidly.⁵⁶

In previous experiments using hybrid material consisting of poly (ethylene glycol) diacrylate (PEGDA) hydrogel embedded with ND-drug when compared to gel alone the combination overcame burst-release and showed a stable, slow and controlled administration of therapeutic compounds.⁵⁹ The release profiles for the chemotherapeutic agents used in this study were much more stable compared to samples with the drugs only. Findings of this study indicate the potential use of a ND-G therapy for drug release in the treatment of bone defects.

Hypothesis and Aims

The hypothesis of this study is that E2 will decrease the relapse potential by increasing bone formation following expansion of the midpalatal suture.

Specific Aim 1: To establish a novel platform for sustained, local release of estrogen to be delivered directly to the separated suture.

Specific Aim 2: To analyze the role of the estrogen in preventing relapse of expanded palates through enhanced bone formation in the palatal suture.

The application of these findings will be relevant to the large number of orthodontic patients requiring expansion, including CLP patients.

MATERIALS AND METHODS

Experimental Subjects

Prior to the start of this study, ethical approval was obtained from the animal research ethics committee at UCLA (ARC #2014-014-03A) and all experiments were conducted in accordance with ARC guidelines. A total of 18 female, 6-week old Sprague Dawley rats, each weighing approximately 180 +/- 5 grams, were purchased from Charles River Laboratories, Inc. 6-week old rats were chosen since in a previous experiment by Kanekawa and Shimizu, of the 6, 15, 24, and 52-week rats that underwent palatal expansion, 6 and 15-week rats had increased bone regeneration in the suture.⁶⁰ The rats were divided into the following 5 groups (Figure 1):

- (1) Control group (n=2): single saline injection
- (2) E2 group (n=4): 70ug/kg E2 injection every 2 days
- (3) E2/ND group (n=4): single 500ug/kg E2+ND injection
- (4) E2/G group (n=4): single 500ug/kg E2+G injection
- (5) E2/ND/G group (n=4): single 500ug/kg E2+ND+G injection

Each group was further divided in half into:

- (1) Retention group: sacrificed after 14 days of retention
- (2) Relapse group: sacrificed after an additional 7 days of relapse

Synthesis of E2/ND

ND was purchased from the NanoCarbon Research Institute Co., Ltd (Nagano, Japan). Since ND precipitates in water, it was dissolved in DMF at a ratio of 5:1 (w/v) followed by 40 minutes of sonication and 1 hour of sterilization. Experiments were conducted to determine whether to dissolve E2, a hydrophobic steroid, in EtOH or DMSO, and whether to dry the mixture of E2+ND or not. It was determined that ND dissolved in DMF added to E2 dissolved in 15.6uL of DMSO, vortexed homogenously, freeze-dried overnight –which forces particles to stick together— followed by redispersion in DMSO, offered the best results.

Next, the effect of E2/ND on osteogenic differentiation of mesenchymal stem cells (MSCs) *in vitro* was determined. MSCs were induced to undergo osteogenic differentiation in osteogenic induction media with one of the following: E2 (supplemented every 2 days), E2/N1 (E2 and ND dissolved in EtOH), E2/N2 (E2 and ND dissolved in DMSO), or E2/N3 (E2 and ND conjugated and dissolved in DMSO). Quantification of osteogenic genes was conducted after induction to determine the most favorable gene expression profile (Figure 2). Quantification of RUNX2, master regulator of MSC osteogenic differentiation, at 0, 4, 7 and 10 days demonstrated sustained release of E2. From these *in vitro* experiments, E2/N3 complex (which will be referred to as “E2/ND”) was selected for use in *in vivo* experiments.

That E2/ND sample then underwent thermogravimetric analysis to determine the amount of E2 actually bound to ND (Figure 3). At approximately 234°C, 94% of E2 is bound to ND and at 484°C 68% of it is bound. Initially, 2mg E2 and 5mg ND or a ratio of 0.4 was found. Up to approximately 600°C pure ND is stable. The ratio of masses compared when heated to over 600°C was 26% E2 to 68% ND, or a ratio of 0.38. This resulted in 0.38/0.4, or 95% of E2 bound to ND.

Synthesis of E2/G

While various hydrogels are available, the polymerization technique chosen involves photoinitiation polymerization utilizing chitosan, a naturally occurring biocompatible polysaccharide used in controlled drug delivery.⁶¹ Methacrylated glycol chitosan (MeGC) can be cross-linked using photopolymerization involving free radicals. The initiator riboflavin is selected since there is greater transmission through tissue and therefore greater depth of curing.

Hydrogel was prepared according to methods described by.⁶¹ Briefly, glycol chitosan, glycidyl methacrylate, and RF were purchased from Sigma-Aldrich (St Louis, MO, USA). Glycidyl methacrylate was added to 2% glycol chitosan aqueous solution to produce 1:1 M ratio of glycidyl methacrylate to the amino groups in chitosan. 1 N HCL was used to adjust the pH of the mixture to 9 and then the mixture was allowed to react at room temperature for 48 hours. The reaction media was neutralized and dialyzed against double-distilled H₂O for 8 hours. MeGC was lyophilized for 48 hours and stored in -20°C.

E2+G was prepared by radical polymerization under visible blue curing light. E2 in DMSO was mixed with MeGC in water and riboflavin at a ratio of 100ul of MeGC to 0.5uL riboflavin. To confirm polymerization of E2 embedded MeGC, the mixture was irradiated with visible blue curing light for 40 seconds.

Synthesis of E2/ND/G

To combine the E2+ND with G, E2/ND was mixed homogenously with MeGC in water, and lyophilized overnight (Figure 4). This sample was redispersed in a mixture of water and DMSO with a ratio of 2:8 (v/v), and mixed with riboflavin. After the components were mixed homogenously, they were cured to form E2/ND/G. Finally, the optimal dose ratio of E2, ND, and polymer in combination had to be determined. Since the maximum total injectable volume

in the rat palate must be less than 50uL, it was found that 0.125mg of E2, 0.35mg ND, and 20uL of polymer would be mixed so that the final total volume was less than 50uL.

Preliminary experiments in deceased rats were conducted to determine the feasibility of gel forming beneath palatal tissue following injection and curing of E2/ND/G (Figure 5).

Incisions of palatal tissue revealed that in fact a gel could form successfully.

Expander Design

Expanders were fabricated with 0.014” stainless steel wire bent into a 1.5mm helical spring and 7mm arms that extend to loop around the maxillary incisors (Figure 6a). All expanders were calibrated to 100g of force using a force gauge (Orthopli, Philadelphia, PA) prior to the procedure date. In a previous experiment by Zahrowski and Turley, increased force application resulted in increased osteoprogenitor cells up to 100g of force.⁶² Placement and removal of expanders was practiced on deceased rats provided by UCLA DLAM facilities prior to live rat experiments.

Expander Placement

At T1, animals were anesthetized with 45% isoflurane. Incisors were scrubbed with self-etching primer (TransbondPLus, 3M Unitek, Monrovia, CA) and expanders were fit around and bonded to the maxillary incisors with acrylic resin (Transbond Supreme Low Viscosity Light Cure Adhesive, 3M Unitek, Monrovia, CA) (Figure 6b). Expanders were then left in place for a total of seven days in all animals without reactivation. A soft food diet (DietGel, Clear H2O, Wesbrook, ME) was provided within each rat housing.

Injections

17 β -estradiol was selected from the estrogens since it is the most potent form of E2 and is preferred for evaluating the effects in animal models. The dose of E2 was established based on

previous studies. Samuels et al. found that E2 stimulated cancellous bone formation in a dose-dependent manner over a wide dose range (1-4000ug/kg per day) with significant increases observed at doses of 4ug/kg per day and beyond.⁶³ In another study investigating the role of E2 in regulating bone formation, a dose of 500ug of E2 showed a 5-fold increase in cancellous bone formation compared to a sham/oil delivery.⁵⁰

At T2, which followed seven days of expansion, each rat received its assigned injection using a 29-gauge insulin syringe. A local injection was delivered in the palate in a site midway between the anterior margins of the incisors and anterior palatal foramen according to procedures performed by Sawada et al.⁶⁴ The control group received 50uL of injectable saline. The E2 group received 70ug/kg E2 dissolved in ethanol. The E2/ND group received 500ug/kg E2 with ND. The E2/G group received 500ug/kg E2 with G. The E2/ND/G group received 500ug/kg E2 with ND and G. The E2 only group received an additional 70ug /kg injection every 2 days during the 14 day retention period.

Retention

Immediately following the injections the expanders were changed into retention devices by discontinuing the force application from the helical spring (Figure 6c and 6d). The same acrylic resin was placed on the helix, cured and the retainer was left in for the next 14 days for mechanical retention. At T3, after 14 days of retention, half of the rats from each group were sacrificed

Relapse

After 14 days of retention, expanders were removed in the remaining rats to allow relapse for 7 days. After that relapse period, T4, all remaining rats were euthanized.

In vivo Micro-CT

Live micro-CT (SkyScan 1176, SkyScan N.V., Belgium) was taken for all rats at T1, T2 and T3 to confirm and monitor amount of expansion during the duration of the experiment. Scans were completed at a resolution of 18um, with a 65kV and 380uA X-ray source and 1mm aluminum filter. For induction and during the 11 minutes of scanning rats were anesthetized with 45% isoflurane.

DATA ANALYSIS

Statistical Analysis

The data is expressed as means and the means of each group are compared.

Diastema Measurements

The diastema created between maxillary incisors was measured at four time points using a digital caliper (Figure 7):

T1: Prior to expansion

T2: Post expansion (following 7 days of expansion)

T3: Post retention (following 14 days of retention)

T4: Relapse (following 7 days of relapse)

Relapse ratio was calculated from these measurements using the following equation⁶⁵:

$$\text{Relapse ratio} = (T4-T3)/(T3-T1) \times 100$$

Micro-CT Analysis

Following dissection of samples, the maxillas were fixed with 4% (w/v) paraformaldehyde at 4°C overnight and then washed with 0.1M phosphate-buffered saline. Samples were scanned with micro-CT (SkyScan 1172, SkyScan N.V., Belgium) at a resolution of 18um, with a 70kV and 141uA X-ray source and 0.5mm aluminum filter. 3D image

reconstructions were completed using NRecon software (SkyScan N.V., Belgium), with image correction steps for beam hardening correction, ring artifact correction, and fine-tuning. Images were then viewed and reoriented to align palatal sutures parallel to the transaxial plane with DataViewer software (SkyScan N.V., Belgium).

3D volumetric analysis was completed with CTan software (SkyScan N.V., Belgium) and all analysis were repeated three separate times by a single, trained, operator. Each sample's Region of Interest (ROI) was extended for consistency from the inferior border of the palate to a point 60 slices superiorly, and outlined the palatal suture from the most anterior margin of the maxillary incisors to the posterior margin of the maxillary incisors. Bone mineral density (BMD) as well as bone volume (BV) and tissue volume (TV) were measured to calculate BV/TV of the expanded suture.

Histological Analysis

After Micro-CT, the maxillas were decalcified for 21 days in 14.5% ethylenediaminetetraacetic acid (EDTA 0.1M, pH=7.4) solution that was changed 2 times per week. Samples were washed and then dehydrated in 70% ethanol, after which 3mm tissue blocks were sectioned with cuts made of the suture anterior and posterior to the incisors. Samples were then placed in cassettes and embedded in paraffin by the UCLA Tissue Procurement Core Lab (TPCL). Sectioning was completed along the coronal plane at 10um sections and stained with hematoxylin and eosin (H&E). Photomicrographs were generated using Olympus BX51 microscope at 4x, 10x and 20x magnification (UPLanFL, Olympus) and MicroFire digital microscope camera with Picture Frame software. Mineralized area/ Total area of H&E sections were calculated with Advanced SPOT 4.6 software.

TRAP staining

Tartrate-resistant acid phosphatase (TRAP) staining was completed with TRAP kit (387A Sigma-Aldrich) according to Verron et al.⁶⁶ After sections were de-paraffinized with xylene and ethanol, sections were placed in TRAP stain solution (12.5mg/ml Naphthol AS-BI phosphoric acid + 2.5M acetate buffer + diazotized Fast Garnet GBC solution + deionized water) at 37°C, for 60 minutes in the dark. After rinsing with deionized water and counterstaining in hematoxylin, images were generated using the same microscope at 4x, 10x, and 20x magnification. Staining was assessed three times by a blinded observer and quantified using Advanced SPOT 4.6 software for the number of osteoclasts and number of osteoblasts lining the suture perimeter.

Immunohistochemistry

Immunohistochemistry (IHC) was performed to stain for presence of osteocalcin (OCN) as previously described by Bo et al.⁶⁷ After sections were de-paraffinized with zylene and ethanol, they were incubated with OCN primary antibodies (FL-100, Santa Cruz Biotechnology, INC) at 1:100 dilution and then with biotinylated secondary antibodies (Dako) at 1:200 dilution. After ABC complex incubation (PK-6100, Vectastain Elite ABC Kit, Vector Laboratories Inc) and AEC chromagen development (K346911-2, Dako), positive immunoreactivity was found. Sections were counterstained with hematoxylin and antibody controls were established by incubation with secondary antibody (without primary antibody). Images were generated using the microscope at 4x, 10x, and 20x magnification and osteoblasts were qualitatively assessed.

RESULTS

Relapse Ratio

At T1 all rats had maxillary incisors that were touching such that diastema measurements were 0mm for all. The average diastema measurements following 1 week of retention, at T3,

were 2.8mm with a standard deviation of 0.24mm. The amount of relapse was the least for the E2/ND/G group at a ratio of 7.63%, while for the control group it was significantly higher at 41.85% (Figure 8). The amount of relapse for the other groups were found to be greater than the E2/ND/G group but less than the control and were 20.92% for E2/ND, 20.03% for E2 only, and 16.95% for E2/G group.

Micro-CT Analysis

To determine the effects of E2 on bone formation and bone density in the midpalatal suture following retention and relapse, micro-CT analysis was completed. Figure 9 shows micro-CT images of a suture prior to (T1) and post-expansion (T2), where suture opening can clearly be seen. A representative micro-CT image displaying the ROI before expansion when the suture is not yet opened is seen in Figure 10a. An obvious comparison can be made between bone formation at T3 in control and E2/ND/G group (Figure 10c and 10d). E2/ND/G shows considerably greater bone formation in the suture at T3 compared to control. Bone mineral density (BMD) and BV/TV were greatest for E2/ND/G group compared to control group and all other E2 groups at both T3 and T4 (Figure 11). The differences were greater at T3 suggesting rapid initial bone formation with E2 treatment. Notably, both BMD and BV/TV values were smallest for E2 only group, even compared to control, at both time points.

Histological Analysis

H&E staining was carried out for histological analysis of the midpalatal suture. Figure 12a is a qualitative example of the difference in bone formation between control and E2/ND/G group. H&E staining showed significantly greater areas of rapid bone formation and increased number of osteoblasts in E2/ND/G group compared to control at both T3 and T4. Remodeling sutural bone was more organized and better interdigitated in E2/ND/G group compared to

control group. Analysis was completed through SPOT software used to quantify mineralized area/total area (Figure 12b). H&E sections showed significantly greater mineralized area vs. total area in sutures injected with E2/ND/G compared to all other groups, but especially compared to the control. This indicates greater bone formation in sutures injected with E2/ND/G compared to all other groups. E2/ND group showed the second greatest mineralized area vs. total area at both T3 and T4.

Osteoclasts

TRAP staining was performed to compare the osteoclastic activity among the different groups. Figure 13a is a qualitative depiction of osteoclasts that line the palatal suture and E2/ND/G has fewer numbers of TRAP positive multinucleated osteoclasts present compared to control. E2/ND/G group had appreciably fewer numbers of osteoclasts per bone surface lining the expanded suture than all other groups at T3 and T4 (Figure 13b). In fact as compared to control, there was a 50% decrease in number of osteoclasts in E2/ND/G group at T3 and 63% at T4.

Osteoblasts

TRAP staining was also analyzed for presence of osteoblasts lining the expanded suture. E2/ND/G group had measurably larger number of osteoblasts per bone lining the suture perimeter compared to control, as qualitatively shown in Figure 14a. Quantitative assessment of the number of osteoblasts lining the suture indicate that in E2/ND/G group there were 17% greater number of osteoblasts at T3 and 25% greater number of osteoblasts at T4 compared to control (Figure 14b). Results also indicate that E2/ND group had the greatest number of osteoblast at T3, but are surpassed by E2/ND/G at T4.

Immunohistochemistry

Staining with OCN was performed to examine osteoblast activity in the suture and adjacent bone. A qualitative analysis from Figure 15 indicates slightly greater OCN staining in E2/ND/G compared to control at T3. At T4 there was greater OCN staining for both groups but significantly more is detected in and around the suture in the E2/ND/G group.

DISCUSSION

Given the frequent and significant problem posed by post-expansion relapse, this study was designed to determine whether E2 could decrease relapse following expansion of the midpalatal suture in rats. The aim of this study was to analyze the effect of estrogen on bone formation by examining bone mineralization as well as osteoblast and osteoclast activity in the expanded suture. As part of this study we set out to establish a novel, sustained E2 delivery platform that could remain localized in the palate in an attempt to avoid the pleiotropic effects associated with injection of E2 and to overcome its short half-life.

Rats were monitored closely to check for signs of distress such as lethargy, poor grooming, and excessive weight loss, and weights were taken twice a week for the duration of the study to make sure that expander placement would not interfere with nutritional intake. In addition, soft diet was included in the cage at T1 and T2 so rats were able to consume food despite any discomfort that the expanders may have caused. While all subjects initially lost approximately 4% of their weight, by T2 there was an average increase of 6% of their initial weights and by T3 there was an average weight increase of 24% from T1.

One rat lost its expander immediately, so to maintain consistency of results that expander was not replaced, and that animal served as a sample of an unexpanded suture. One animal was lost for unspecified reasons during *in vivo* micro-CT at T1, and that rat served as a sample for

images of an open suture. Unfortunately, movement from breathing during *in vivo* micro-CT made the use of any expansion measurements generated with this method unreliable. Better procedures to keep head position stable during imaging would be necessary and could benefit future studies by reducing the number of animal subjects necessary.

A previous experiment by James et al. to determine the effect of E2 and ER on mouse sagittal suture found that in *in vitro* experiments the application of 17β -estradiol increased osteogenic differentiation of mesenchymal cells from those sutures.⁴⁹ We therefore sought out to determine what the effects of E2 would be on the expanded palatal suture. To determine the appropriate dose, we turned to a previous study by Bain in which high-dose E2 at 500 μ g stimulated bone formation in a dose-dependent manner.⁵⁰ Therefore, we also chose a high dose of E2 to ensure that an absence of significant effects in the experimental group could not be attributed to a low dose of E2.

The Women's Health Initiative, a program to reduce some of the side effects in postmenopausal women through clinical trials, found that the risks associated with hormone replacement therapy with E2 outweighed the benefits.⁵³ Given the well-publicized risks involved with the systemic administration of E2, we primarily sought out to develop a technique that would maximize the benefits of E2 while minimizing the pleiotropic effects associated with it. Moreover, with a half-life that is little more than half a day, E2 would have to remain localized for a prolonged period to have an effect on bone formation. For that reason, it was imperative that E2 be injected in the palate and remain in the suture for localized, sustained release.

The design of this experiment was meant to be a feasibility study to determine if a sustained, localized E2 delivery system could be created in the first place and what effect if any E2 would have on the sutural bone formation. Due to the small sample size of the study,

establishing statistical significance was not possible for many of the findings. However, this study is valuable in showing important trends with the application of E2. The first success of this study is the development of a nanodiamond-embedded hydrogel for sustained E2 release. The development of E2/ND/G involved many confirmatory steps prior to proceeding with the experiment. Gene expression profile of Runx2 in induced MSCs showed that E2+ND conjugated and dissolved in DMSO displayed sustained release of E2 over the course of 10 days. Thermogravimetric analysis confirmed successful assembly of E2/ND, which had 95% binding to each other. Moreover, actual gel formation was confirmed by injecting it into the palate of a dead animal, curing it, and then making an incision for visual confirmation.

The proposed mechanism of action of E2/ND/G begins with hydrogels forming a network, or matrix, that keeps drugs sequestered. As previously described by Man et al., a G embedded with ND-drug avoided burst release, a complication when G is used alone that can result in build up of unmetabolized therapeutics and eventual toxicity.⁵⁹ Since G becomes swollen in watery environments, drugs inside it are released from the matrix through both diffusion and swelling.⁶⁸ It is hypothesized that E2/ND is gradually released from G matrix and then E2 is steadily and continuously released from ND, similar to experiments with amoxicillin and ND.⁶⁹ E2 enters cells and interacts with ER and subsequently enters the nucleus to regulate gene transcription and the resulting protein expression.⁴⁵

The different analysis showed that when E2/ND/G was used it had superior results to E2/ND and E2/G. Utilizing E2/ND/G showed clear advantages over control as well as all other E2 samples for reduction in relapse ratio of the suture. The average relapse ratio for E2/ND/G group was an 80% reduction as compared to control group. Our control relapse rate of 41.85% is supported by Hicks' findings that relapse varies from 10-23% with fixed retention, to up to 45%

when no retention is used.¹⁹ It is possible that the amount of relapse we obtained would have been slightly reduced if a longer retention period were utilized. This 80% reduction in relapse ratio of E2/ND/G compared to control was greater than what Iravani's study found, which was only a 50% decrease when bisphosphonate was used as compared to control.³⁹

E2/ND/G group also increased BMD and BV/TV in the suture relative to all other groups. While BMD increases were only marginally greater than what was achieved by the control, this is in line with clinical findings. In fact, previous studies on E2 therapy in postmenopausal women found that there was 5% increase in BMD when E2 was given through hormonal therapy over a 3 year period, which was significantly more than the approximately 2% reduction of BMD in control patients.⁷⁰ In addition, histological analysis demonstrated greater mineralized area vs. total area, reduction in osteoclasts and increase in osteoblasts in the E2/ND/G group. Therefore, there were clear advantages to combining both ND and G with E2 compared to E2/ND and E2/G alone.

Since bone remodeling is a continuous balance between bone destruction by osteoclasts and new bone formation by osteoblasts, it is important to evaluate the effect of E2 on both osteoclasts and osteoblasts. At T3 the E2/ND group had greatest numbers of osteoblasts per suture perimeter but at T4, E2/ND/G surpassed that significantly. This finding supports our claim that the addition of G to E2/ND promotes the sustained osteoinductive effects of E2 for a longer duration of time than with E2/ND alone. Our findings also indicate that E2/ND/G had a greater relative effect on reduction of the number of osteoclasts than on increase in number of osteoblasts. Validation of our findings arises from studies on postmenopausal osteoporosis. Postmenopausal women frequently experience osteoporosis induced by E2 insufficiency, and that bone loss stems from enhanced bone resorption.⁷¹ Subsequently, when E2 is administered to

osteoporotic patients, its mechanism is to reduce resorption through osteoclast death.⁴⁶ E2's role on osteoclasts is also confirmed by Nakamura et al. who found that E2 regulates the lifespan of mature osteoclasts. They propose that when ER α is activated by E2, it shortens the lifespan of osteoclasts by activating apoptosis through Fas/FasL.

One interesting finding that should be discussed was that the E2 only group had reduced BMD And BV/TV compared to all other groups including the control. Moreover, this group showed reduced number of osteoblasts and increased number of osteoclasts at T3 compared to all other groups, despite that number of osteoclasts reducing significantly at T4. One reason to explain this is the presence of ethanol at 30% concentration, in the E2 mixture to aid in dissolving of E2 powder. In fact, ethanol has been shown to increase bone resorption through osteoclast activity, and decrease osteoblast differentiation.⁷² Therefore, it is likely that ethanol suspension used for E2 had an inhibitory effect on bone formation and negated any of the positive effects to be had by the E2 alone.

Based on the results of this preliminary study and given an alpha of 0.05 and a power level of 0.8, the sample size for a follow-up study was determined to be 6 rats per group. This follow-up study has already been completed, the results of which are currently being analyzed. 42 rats were divided into only three groups this time. Control, E2 only, and E2/ND/G were chosen since trends indicated that the E2/ND/G group consistently showed the greatest difference from the control group. Another change that was implemented in this follow-up study to ensure more controlled results is that saline control now has a small amount of ethanol in it to correspond to the amount of ethanol in the E2 group. In addition, the amount of ethanol in the E2 group has been reduced significantly to avoid any risk of bone defects developing from the caustic effect of ethanol. Another modification that should have been addressed is to create ND

only and G only controls groups to eliminate any potential osteoinductive effects posed by these two components.

Our study is innovative in that it is the first to combine E2 with both ND and G for greater efficacy of treatment. Future applications for this local and sustained delivery of E2 are numerous. Most directly, the findings of this study may be utilized to improve the predictability of expansion, a development that is useful for orthodontic patients with transverse discrepancies, but is particularly beneficial to CLP patients where stability is even more of a problem. The long-term goal of this study is to further develop this therapeutic model as an anabolic agent for regenerating craniofacial defects and possibly bone defects in general. After obtaining the results of this study, a patent application (Case #2016-173) has been filed with UCLA Office of Intellectual Property for nanodiamond-embedded hydrogels for sustained hormone release to enhance bone defect repair.

CONCLUSION

- A sustained, local release of E2 was successfully developed using nanodiamonds and hydrogel.
- This was the first study to examine the effects of E2 on the midpalatal suture of rats.
- All E2 groups reduced the relapse ratio following expansion and retention of the midpalatal suture of rats compared to control.
- Micro-CT analysis indicated greater BMD and BV/TV in sutures injected with E2/ND/G compared to control.
- Greater mineralized area vs. total area was found in H&E stains of sutures injected with all E2 groups, but particularly E2/ND/G.

- E2/ND/G group had an increase in number of osteoblasts as well as a significant reduction in number of osteoclasts compared to control.
- E2/ND/G had the greatest overall effect on stimulation of bone formation in the suture.
- The findings of this study may be utilized to reduce relapse and/or the retention period following palatal expansion, especially in CLP patients.
- Future applications of local and sustained delivery of E2 are immeasurable.

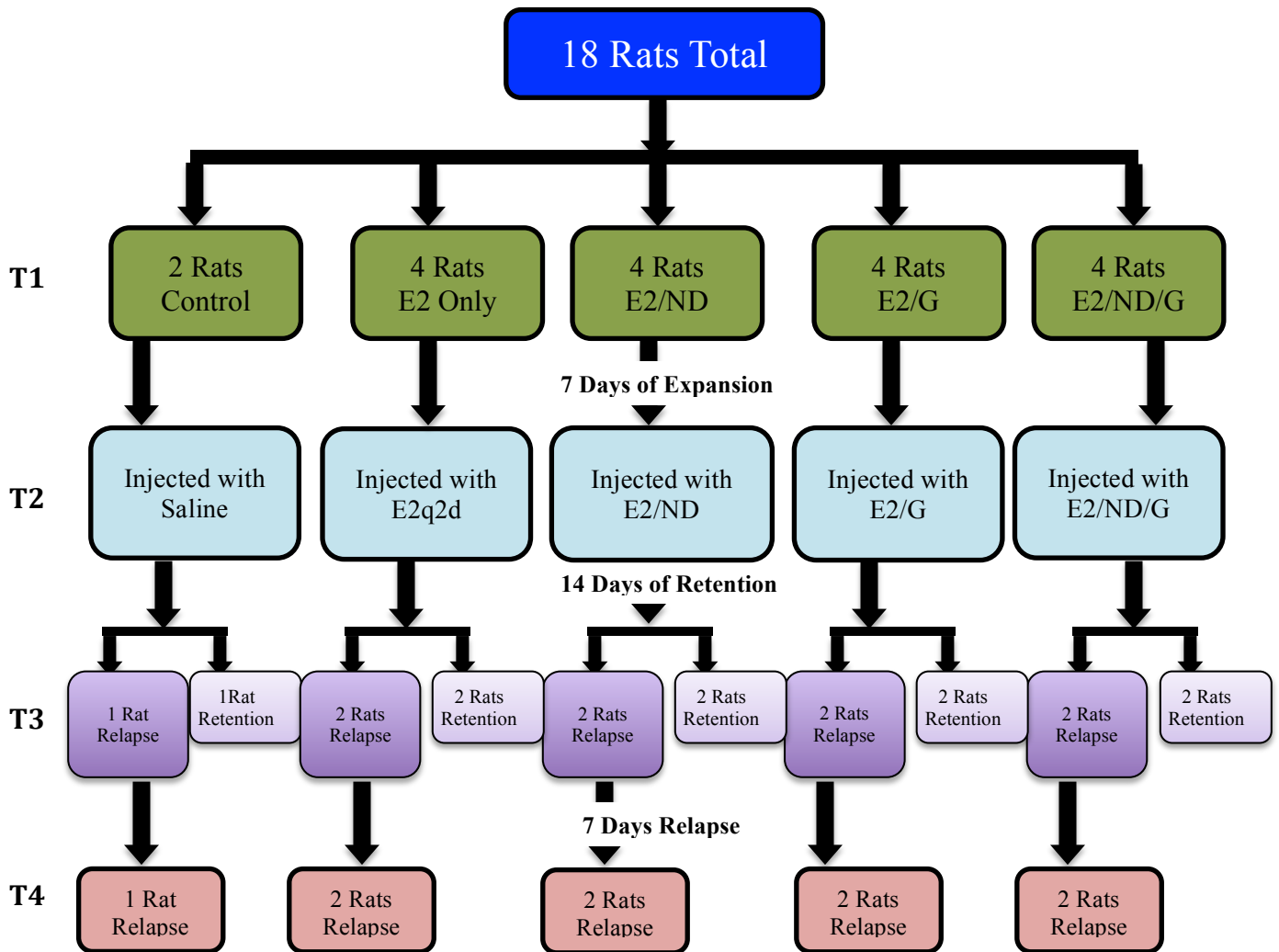


Figure 1. Experimental Timeline

A total of 18 Sprague Dawley rats underwent 7 days of palatal expansion and were then divided into five groups: Control, E2, E2/ND, E2/G, E2/ND/G. 500ug/kg of E2 was used in E2/ND, E2/G, E2/ND/G, and for E2 group 70ug/kg was injected q2d. After retaining the expansion for 14 days, expanders were removed and rats were allowed to relapse for 7 days.

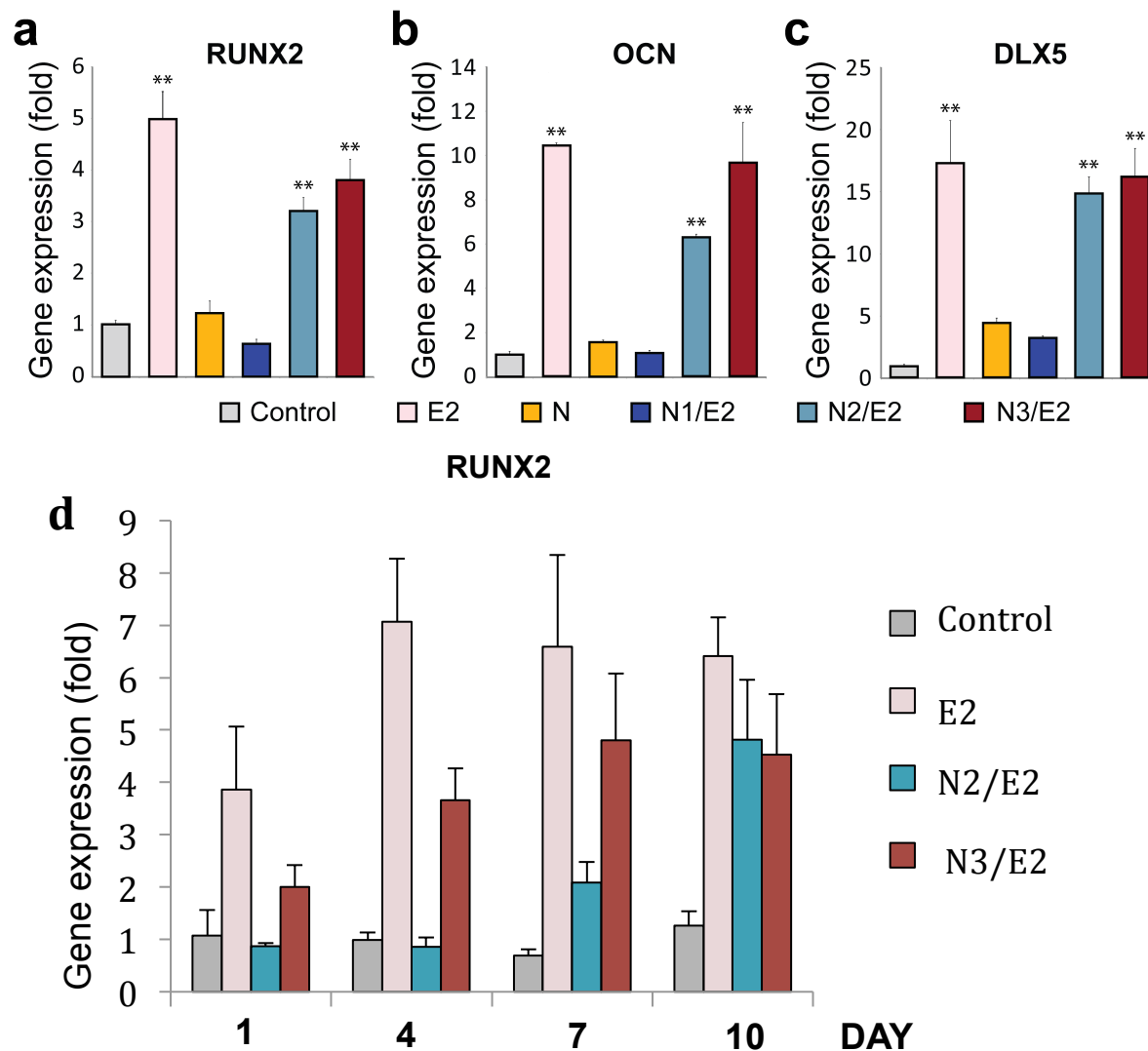


Figure 2. Osteogenic Differentiation of MSCs *in vitro*

MSCs were induced to undergo osteogenic differentiation in induction media with E2 and E2/N1 (E2 and ND dissolved in EtOH), E2/N2 (E2 and ND dissolved in DMSO), and E2/N3 (E2 and ND conjugated and dissolved in DMSO). (a-c) Quantification of osteogenic genes after 3 days of induction. (d) Quantification of RUNX2, master regulator of MSC osteogenic differentiation at 0, 4, 7 days demonstrating sustained release of E2.

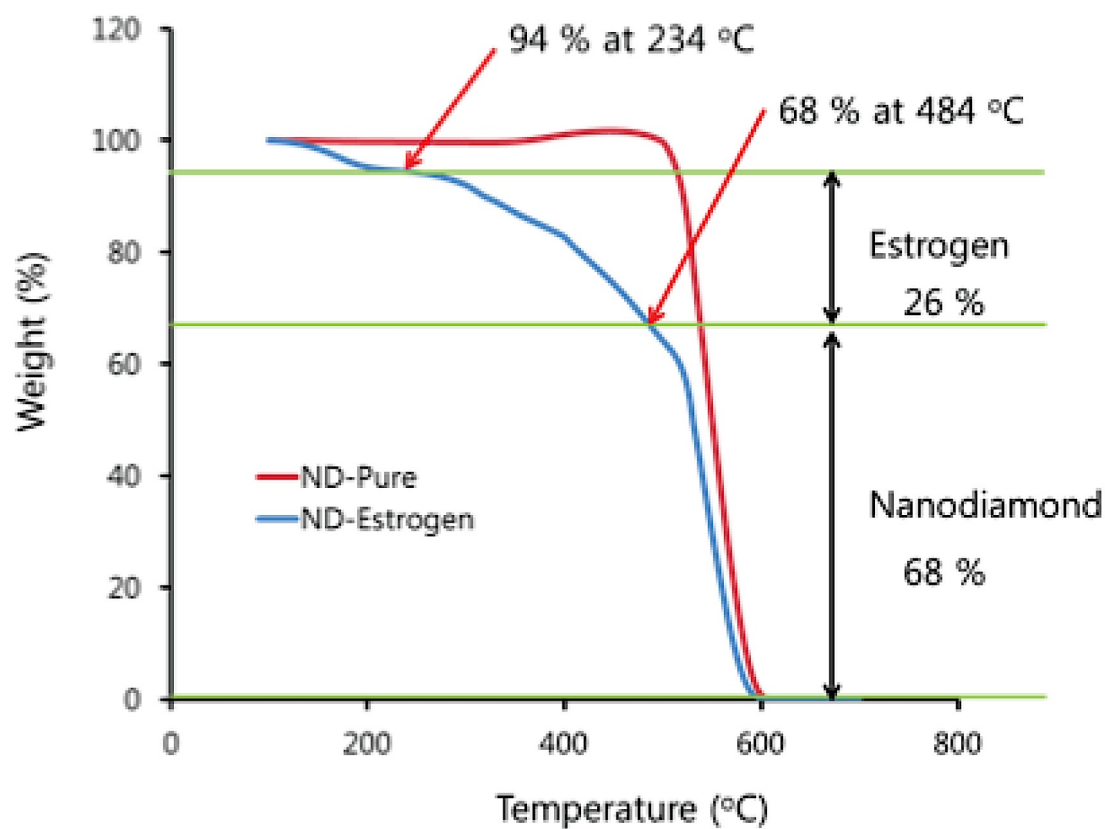


Figure 3. Thermogravimetric Analysis

Thermogravimetric analysis completed to determine the amount of E2 bound to ND revealed that 95% of E2 was bound to ND initially.

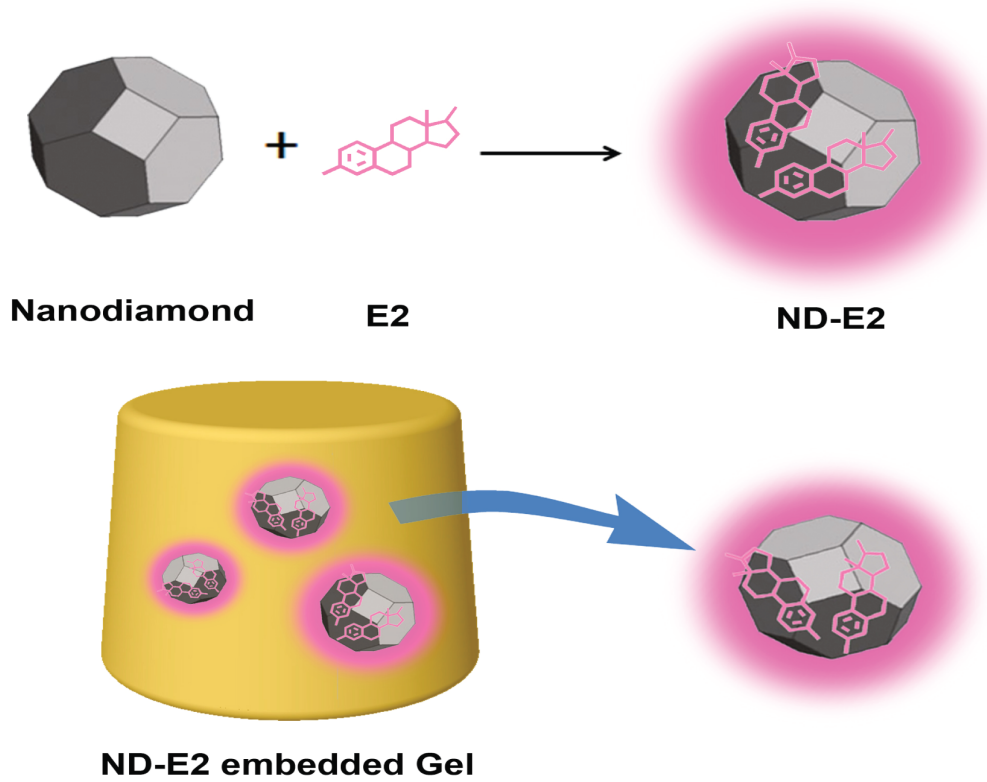


Figure 4. Diagram of E2/ND/G formation

ND is loaded with E2 and then the complex is embedded within gel for sustained release of E2.

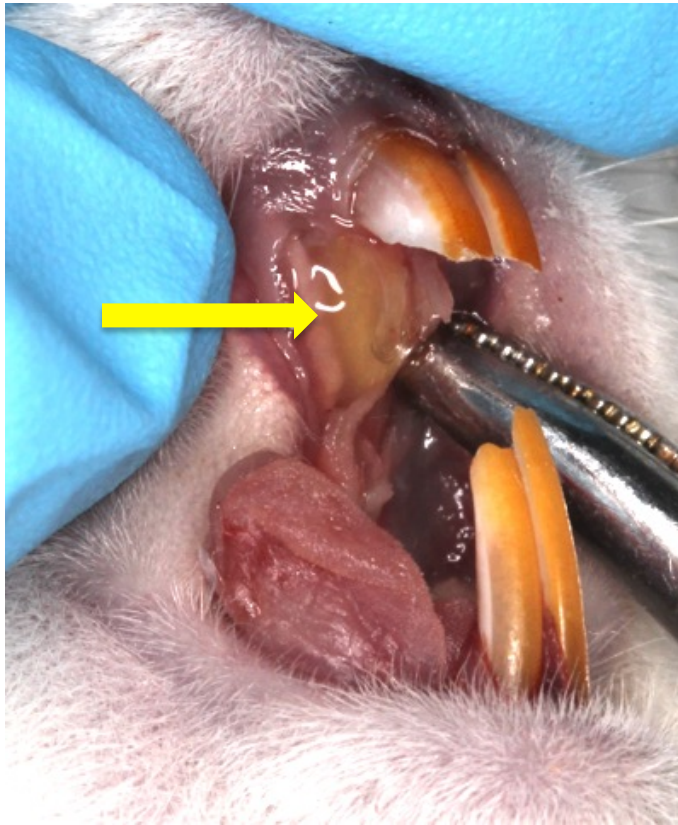


Figure 5. Gel Formation

Palatal incision was made to reveal successful gelation following curing through the palate.

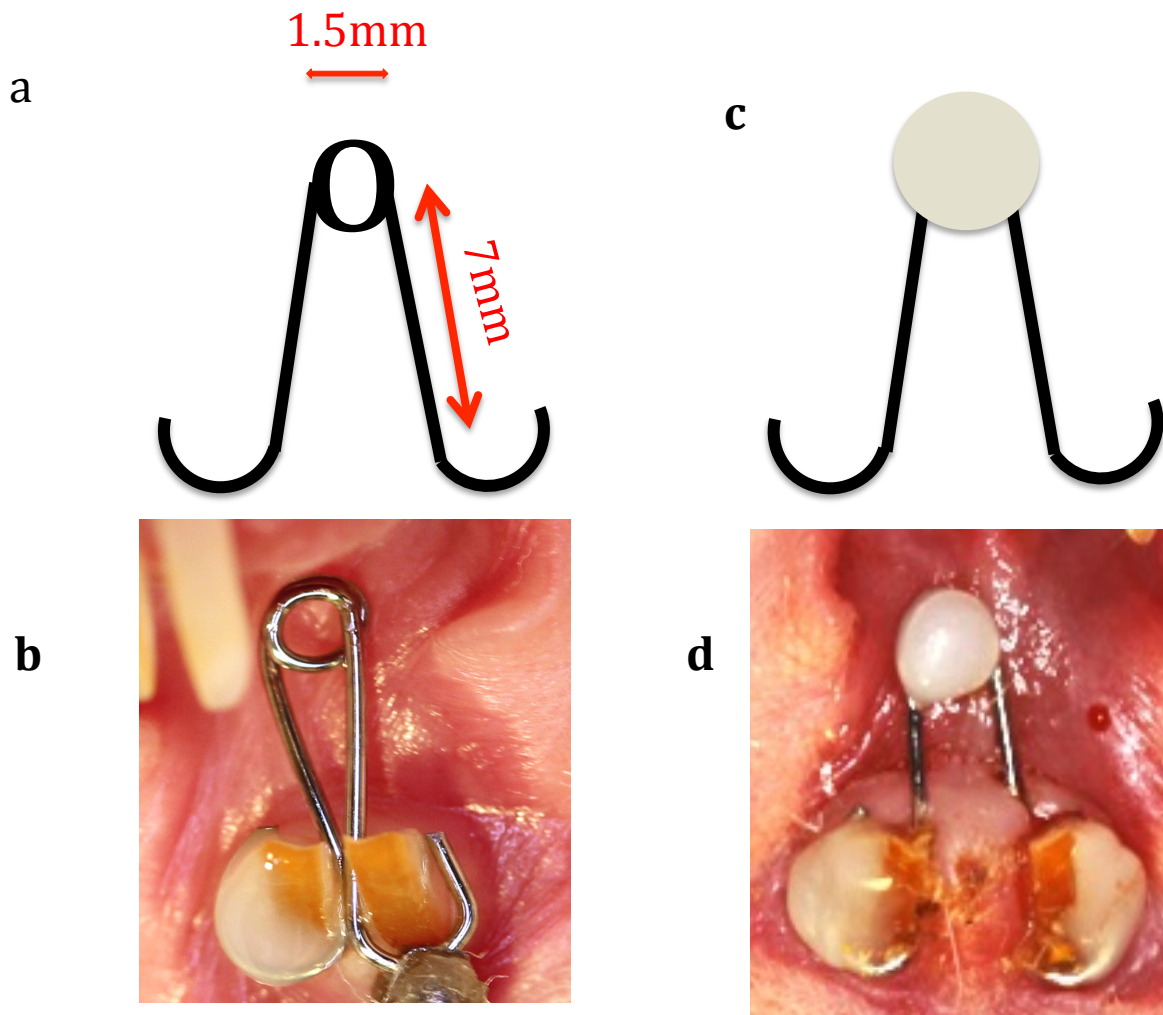


Figure 6. Palatal Expander and Retainer Design .

(a) Palatal expander dimensions (1.5mm helix and 7mm arms) and (b) palatal expander placed intraorally with acrylic resin. (c) Retainer after force from helix is arrested and (d) converted retainer intraorally.

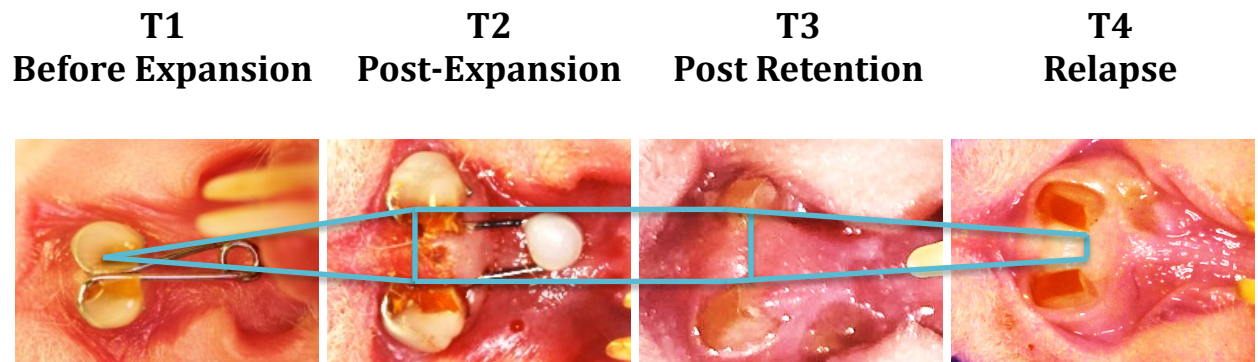


Figure 7. Palatal Expansion and Relapse.

A digital caliper was used to measure diastemas at the gingival level at 4 timepoints.

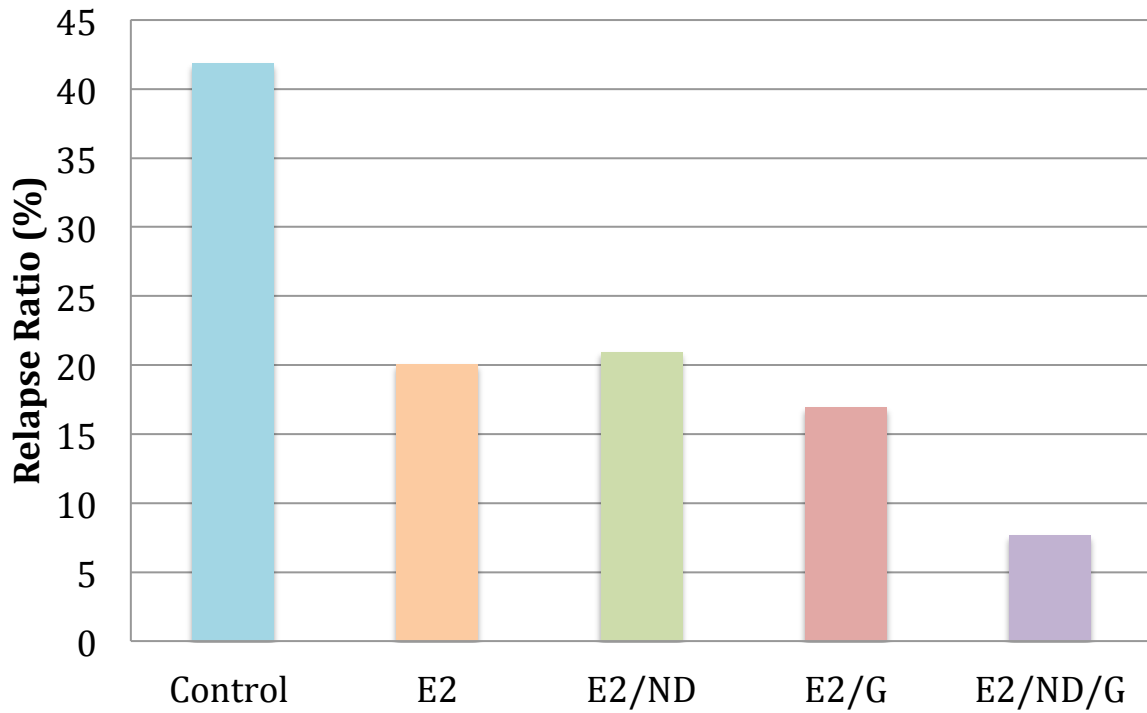


Figure 8. Relapse Ratio

Calculations of relapse ratio showing that addition of G and ND to E2 significantly reduced relapse ratio by 5.5 fold compared to control.

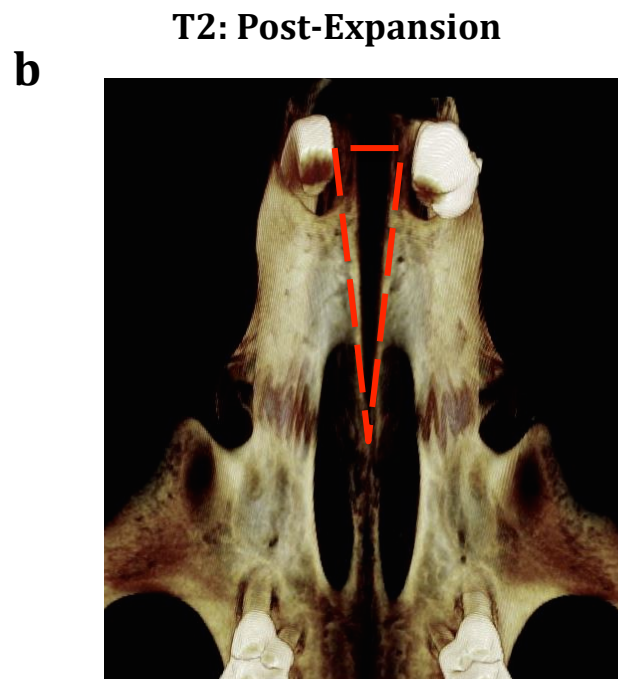
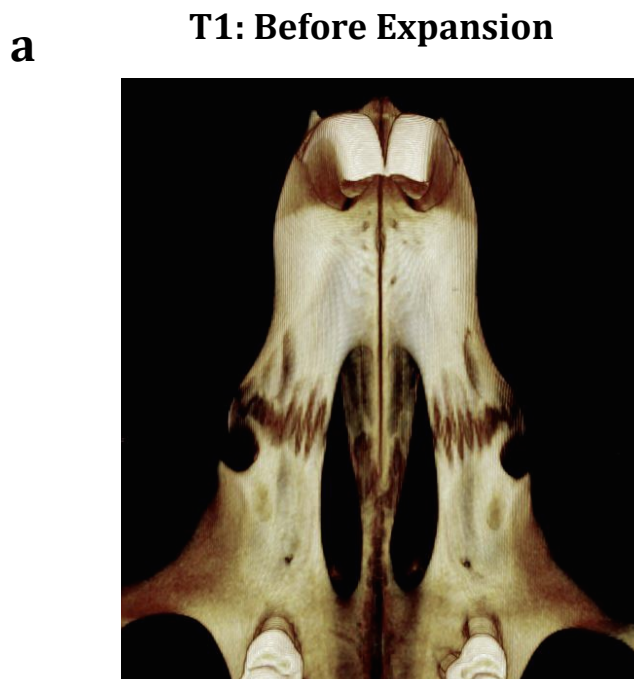


Figure 9. Micro-CT Image of Suture.

(a) Rat maxilla prior to expansion at T1. (b) Maxilla following 1 week of expansion, T2, establishing opening of suture.

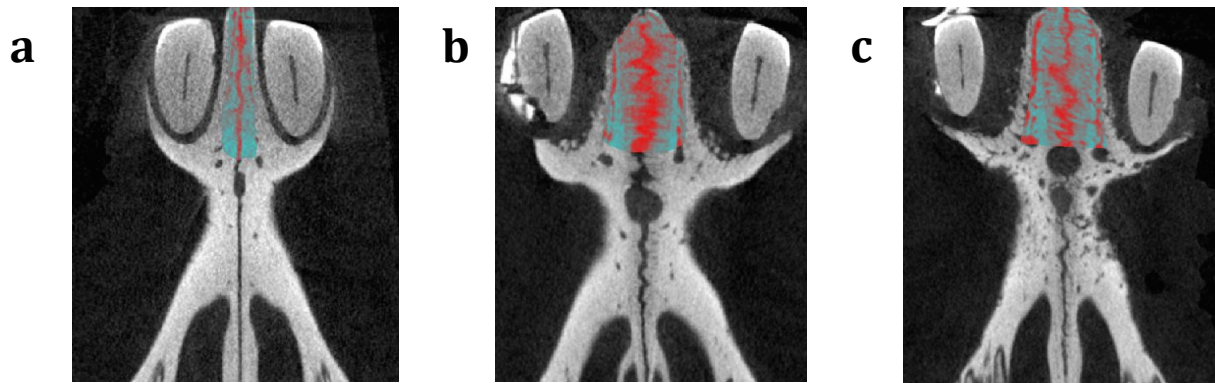


Figure 10. Micro-CT Images of Palatal Expansion.

(a) Before expansion. (b) Post-retention of control group. (c) Post-retention of E2/ND/G group.

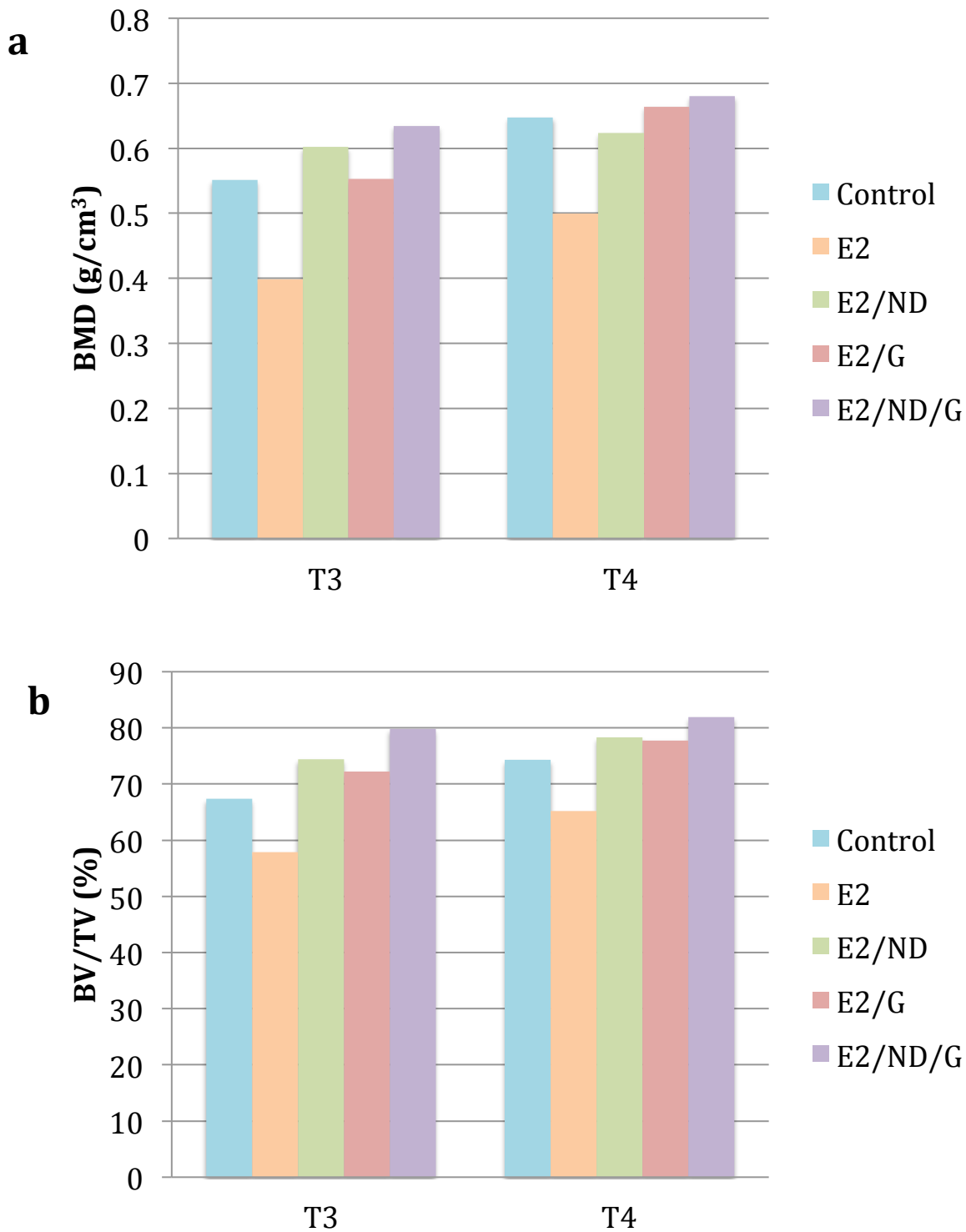


Figure 11. Micro-CT Analysis of Bone Formation.

(a) Bone mineral density (BMD) and (b) Bone volume to Tissue volume (BV/TV) was increased for E2/ND/G group compared to all other groups at both T3 and T4.

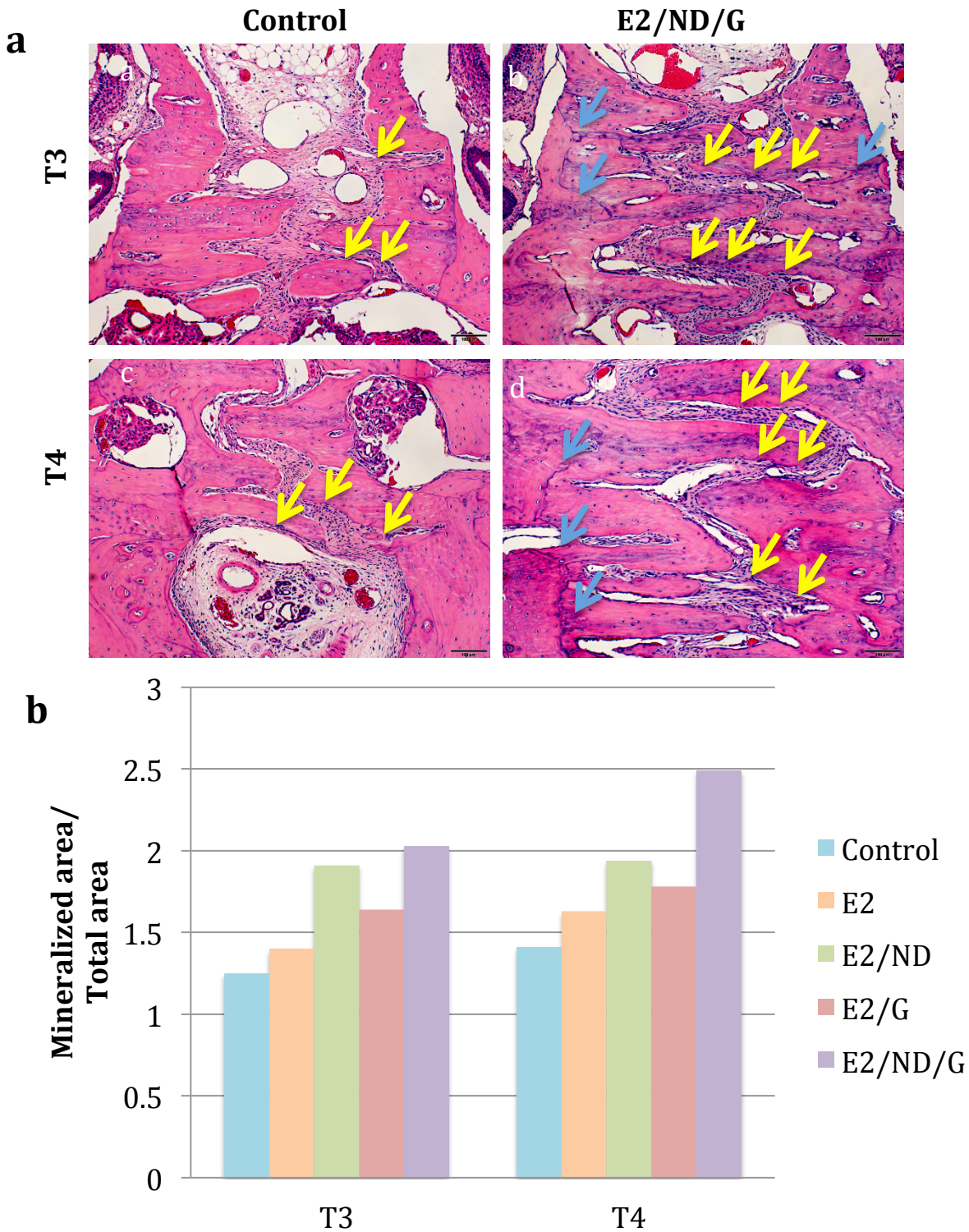


Figure 12. H&E Staining of Palatal Suture

(a) H&E staining of sutures at 10x magnification showing greater areas of rapid bone formation (blue arrows) and osteoblasts (yellow arrows) in E2/ND/G group compared to control. (b) Mineralized area/total area on H&E calculated from SPOT 4.6 software increased in E2/ND/G group.

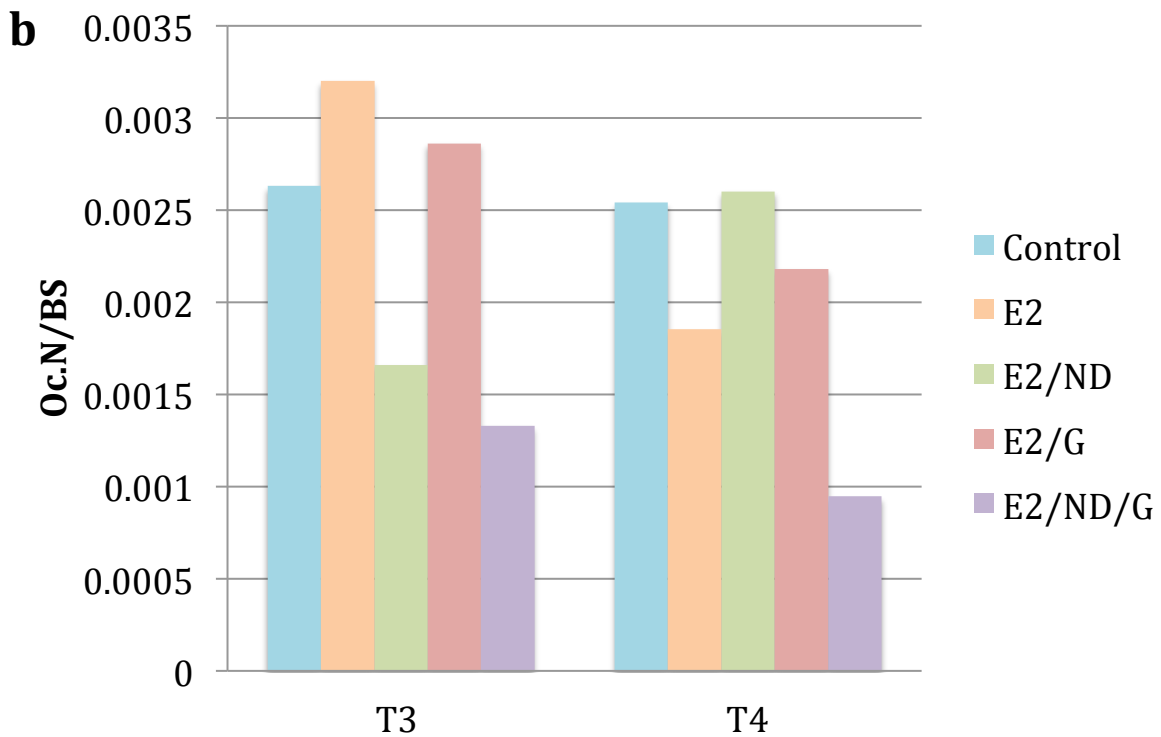
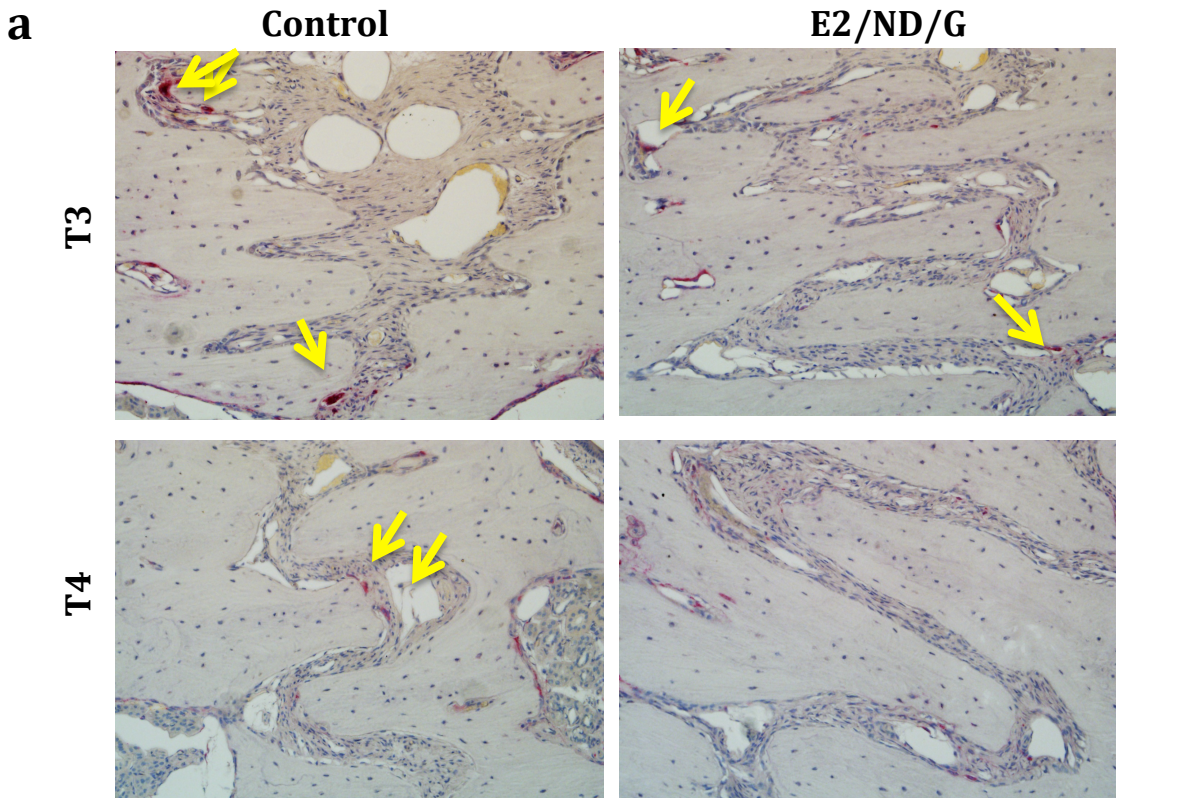


Figure 13. TRAP Staining and Osteoclasts in Palatal Suture

(a) Representative TRAP staining at 20x magnification showing reduced number of osteoclasts (yellow arrows) in E2/ND/G group compared to control. (b) Quantification of number of osteoclasts per bone perimeter shows reduced number of osteoclasts in E2/ND/G compared to all other groups.

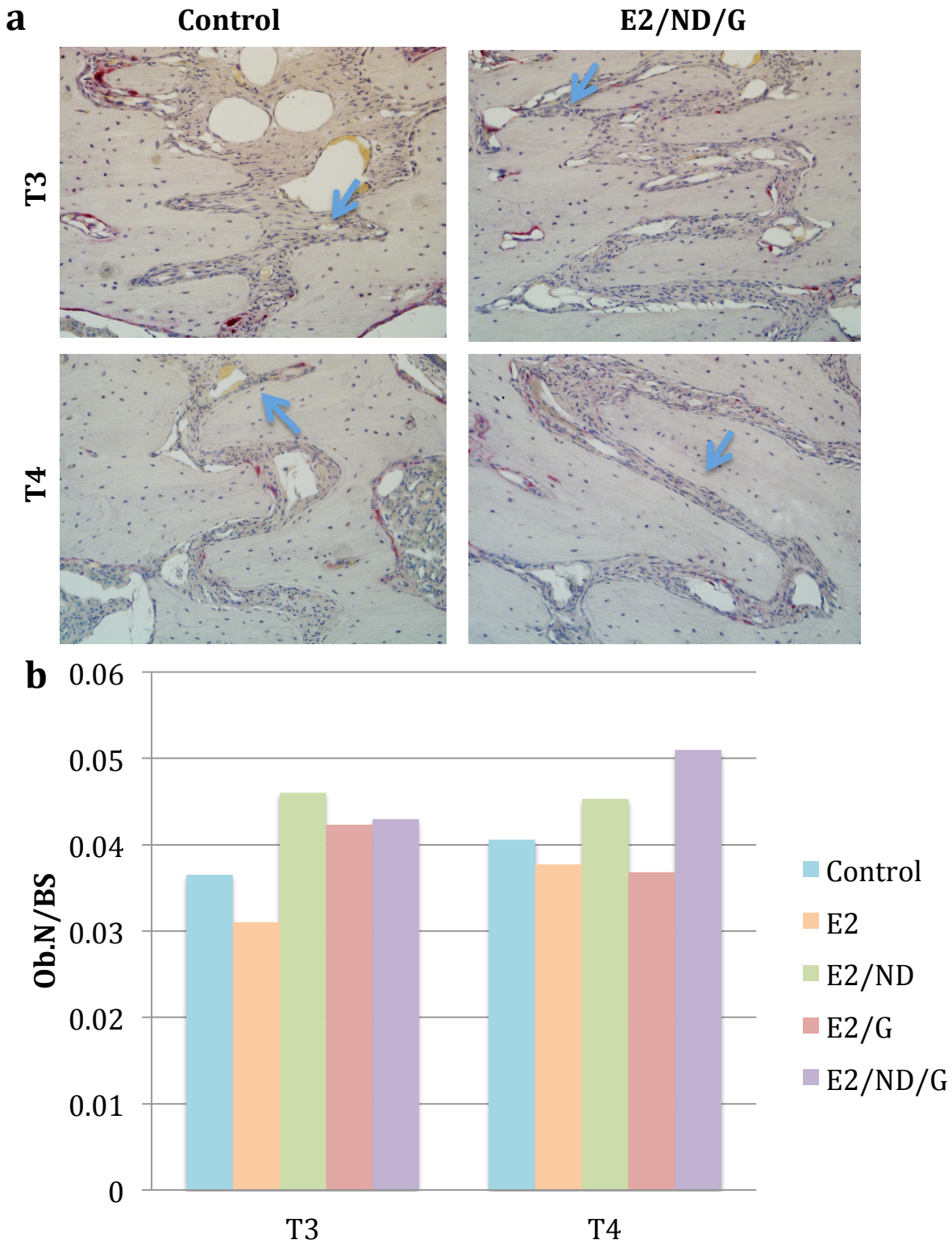


Figure 14. TRAP Staining and Osteoblasts in Palatal Suture

(a) Representative TRAP staining at 20x magnification showing increased number of osteoblasts (blue arrows) in E2/ND/G group compared to control. (b) Quantification of number of osteoblasts per bone perimeter shows increased number of osteoblasts in E2/ND/G compared to control.

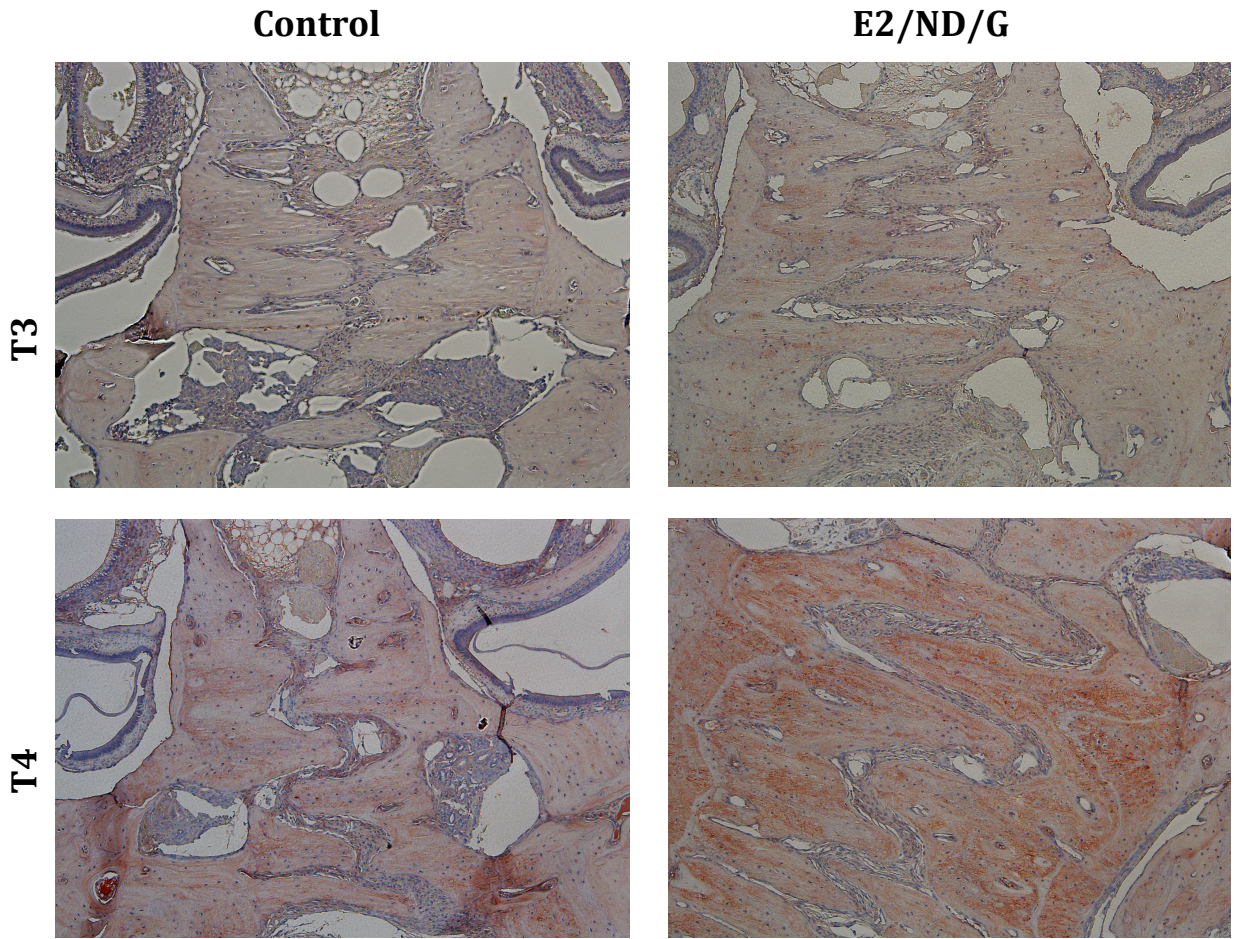


Figure 15. Immunohistochemistry Staining of the Palatal
Representative OCN staining at 10x magnification showing increased OCN staining (brown) at T4 in both groups, but particularly E2/ND/G group.

Works Cited

- ¹ McNamara JA Jr, Baccetti T, Franchi L, Herberger Ta. Rapid maxillary expansion followed by fixed appliances: a long-term evaluation of changes in arch dimensions. *Angle Orthod.* 2003; 73(4): 344-53.
- ² Turley PK. Managing the developing Class III malocclusion with palatal expansion and facemask therapy. *Am J Orthod Dentofacial Orthop.* 2002;122(4):349-52.
- ³ Enemark H, Krant-Simonsen E, Schramm JE. Secondary bonegrafting in unilateral cleft lip palate patients: indications and treatment procedure. *Int J Oral Surg.* 1985; 14(1): 2-10.
- ⁴ Binder RE. Correction of posterior crossbites: diagnosis and treatment. *Pediatric Dentistry.* 2004; 26(3): 266-72.
- ⁵ Da Silva Filho OG, Boas MC, Capelozza Filho L. Rapid maxillary expansion in the primary and mixed dentitions: a cephalometric evaluation. *Am J Orthod Dentofacial Orthop.* 1991; 100(2): 171-179.
- ⁶ Graber L, Vanarsdall R, Vig K. *Orthodontics, current principles and techniques, 5th Edition.* 2011; 813.
- ⁷ Proffit WR, Fields HW. *Contemporary Orthodontics, 5th edition.* St. Louis: Elsevier, 2013.
- ⁸ Suri L, Taneja P. Surgically assisted rapid palatal expansion: A literature review. *Am J Orthod Dentofacial Orthop.* 2008;133:290-302.
- ⁹ Bishara SE, Staley RN. Maxillary expansion: clinical implications. *Am J Orthod Dentofacial Orthop.* 1987; 91(1): 3-14.
- ¹⁰ Harvold EP, Chierici G, VArgervik K. Experiments on the development of dental malocclusions. *Am J Orthod.* 1972; 61(1) 38-44.
- ¹¹ Seemann j, Kundt G, Stahl de Castrillon F. Relationship between occlusal findings and orofacial myofunctional status in primary and mixed dentition: part I: interrelation between space conditions and orofacial dysfunctions. *J Orofac Orthop.* 2011; 72(1): 21-32 .
- ¹² Cozza P, Baccetti T, Franchi L, Mucedero M, Polimeni A. Transverse features of subjects with sucking habits and facial hyperdivergency in the mixed dentition. *Am J Orthod Dentofacial Orthop.* 2007; 132(2): 226-9.
- ¹³ Melsen B. Palatal growth studied on human autopsy material. A histological microradiographic study. *Am J Orthod.* 1975; 68(1):42-54.
- ¹⁴ Persson M, Thilander B. Palatal suture closure in man from 15 to 35 years of age. *Am J Orthod.* 1977; 72(1):45-52.
- ¹⁵ Sandikccioglu M, Hazar S. Skeletal and dental changes after maxillary expansion in the mixed dentition. *Am J Orthod and Dentofacial Orthop.* 1997; 111(3): 321-327.
- ¹⁶ MacGinnis M, Chu H, Youssef G, Wu KW, Machado AW, Moon W. The effects of micro-implant assisted rapid palatal expansion (MARPE) on the nasomaxillary complex—a finite element method (FEM) analysis. *Progress in Orthodontics.* 2014;15(1):52. doi:10.1186/s40510-014-0052-y.
- ¹⁷ Ekstrom C, Henrikson CO, Jensen R. Mineralization in the midpalatal suture after orthodontic expansion. *Am J Orthod.* 1977; 71(4):449-55.
- ¹⁸ Krebs A. Mid-palatal suture expansion studied by the implant method over a seven-year period. *Trans Eur Orthod Soc.* 1964:131-142.

-
- ¹⁹ Hicks EP. Slow maxillary expansion. A clinical study of the skeletal versus dental response to low-magnitude force. *Am J Orthod.* 1978;73(2):121-41.
- ²⁰ Gurel HG, Memili B, Erkan M, Sukurica Y. Long-term effects of rapid maxillary expansion followed by fixed appliances. *Angle Orthod.* 2010; 80(1): 5-9.
- ²¹ Moussa R, O'Reilly MT, Close JM. Long-term stability of rapid palatal expander treatment and edgewise mechanotherapy. *AM J Orthod Dentofac Orthop.* 1995;108:478-88.
- ²² Jiang Y, Liu HX, Guo JJ, Tang GH, Xian YF. Stimulation of bone formation in the expanding premaxillary suture with a GSK-3 β inhibitor. *Oral Dis.* 2013;19(1):73-9.
- ²³ *Report of a WHO Registry Meeting on Craniofacial Anomalies.* Rep. Geneva: World Health Organization, 2003. Print.
- ²⁴ Utreja A, Evans CA. Marfan Syndrome – An orthodontic Perspective. *Angle Orthod.* 2009;79(2): 394-400.
- ²⁵ Stavropoulos D, Tarnow P, Mohlin B, Kahnberg KE, Hagberg C. Comparing pateitns with Apert and Crouzon syndromes—clinical features and cranio-maxillofacial surgical reconstruction. *Swed Dent J.* 2012;36(1):25-34.
- ²⁶ Tindlund RS. Skeletal response to maxillary protraction in patients with cleft lip and palate before age 10 years. *Cleft Palate Craniofac J.* 1994;31(4):295-308.
- ²⁷ Li W, Lin J. Dental Arch Width Stability after quadhelix and edgewise treatment in complete unilateral cleft lip and palate. *Angle Orthod.* 2007;77(6): 1067-1072.
- ²⁸ Robertson NR, Fish J. Some observations on rapid expansion followed by bone grafting in cleft lip and palate. *Cleft Palate J.* 1972; 9:236-45.
- ²⁹ Nicholson PT, Plint DA. A long-term study of rapid maxillary expansion and bone grafting in cleft lip and palate patients. *Europ J of Orthod.* 1989;11:186-192
- ³⁰ Ramsatd T, Jendal T. A long-term study of tranverse stability of maxillary teeth in patients with unilateral complete cleft lip and palate. *J Oral Rehabil.* 1997;24(9):658-65.
- ³¹ Lai RF, Zhou Zy, Chen T. Accelerating bone generation and bone mineralization in the interparietal sutures of rats using rhBMP-2/ACS composite after rapid expansion. *Exp Anim.* 2013;62(3):189-96.
- ³² Zhao S, Wang X, Li N, Chen Y, Su Y, Zhang J. Effects of strontium renelate on bone formation in the mid-palatal suture after rapid maxillary expansion. *Drug Des Devel Ther.* 2015;9:2725-34.
- ³³ Uysal T, Ustdal A, Sonmez MF, Ozturk F. Stimulation of bone formation by dietary boron in an orthopedically expanded suture in rabbits. *Angle Orthod.* 2009;79(5):984-90.
- ³⁴ Tang GH, Xu J, Chen RJ, Qian YF, Shen G. Lithium delivery enhances bone growth during midpalatal expansion. *J Dent Res.* 2011;90(3):336-40.
- ³⁵ Cowan CM, Cheng S, Ting K, Soo C, Walder B, Wu B, Kuroda S, Zhang X. Nell-1 induced bone formation within the distracted intermaxillary suture. *Bone.* 2006;38(1):48-58.
- ³⁶ Kara MI, Erciyas K, Altan AB, Ozkut M, Ay S, Inan s. Thymoquinone accelerates new bone formation in the rapid maxillary expansion procedure. *Arch Oral Biol.* 2012;57(4):357-63.
- ³⁷ Uysal T, Amasyali M, Enhos S, Sonmez MF, Sagdic D. Effect of ED-71, a new active vitamin D analog, on bone formation in an orthopedically expanded suture in Rats. A histomorphometric study. *Eur J Dent.* 2009;3(3):165-72.

-
- ³⁸ Uysal T, Amasyali M, Olmez H, Karslioglu Y, Gunhan O. Stimulation of bone formation by direct electrical current in an orthopedically expanded suture in the rat. *Korean J Orthod.* 2010;40(2):106-114.
- ³⁹ Iravani G. Effects of bisphosphonate administration in bone formation and retention/relapse upon mid-palatal suture expansion [dissertation]. Los Angeles, CA: Univeristy of California, Los Angeles; 2014.
- ⁴⁰ Wend K, Wend P, Krum SA. Tissue-specific effects of loss of estrogen during menopause and aging. *Front Endocrinol.* 2012;3:19
- ⁴¹ Albright, F, Bloomberg, E, Smith, PH. Postmenopausal osteoporosis. *Trans. Assoc. Am. Physicians.* 1940;55:298-305.
- ⁴² Khosla S, Oursler MJ, Monroe DG. Estrogen and the skeleton. *Trends Endocrinol Metab.* 2012;11:576-81.
- ⁴³ Katzenellenbogens BS. Estrogen receptors: bioactivities and interactions with cell signaling pathways. *Biol Reprod.* 1996;54:287-293.
- ⁴⁴ Kuiper GG, Carlsson B, Grandien K, Enmark E, Haggblad J, Nilsson S et al. Comparison of the ligand binding specificity and transcript tissue distribution of estrogen receptor alpha and beta. *Endocrinology.* 1997;138:863-870.
- ⁴⁵ Nilsson S, Mäkelä S, Treuter E, Tujague M, Thomsen J, Andersson G, Enmark E, Pettersson K, Warner W, Gustafsson JA. Mechanism of estrogen action. *Physiological Reviews.* January 2001;81: 1535-1565.
- ⁴⁶ Nakamura T, Imai Y, Matsumoto T, Sato S, Takeuchi K, Igarashi K, Harada Y, Azuma Y, Krust A, Yamamoto Y, Nishina H, Takeda S, Takayanagi H, Metzger D, Kanno J, Takaoka K, Martin TJ, Chambon P, Kato S. Estrogen prevents bone loss via estrogen receptor alpha and induction of Fas ligand in osteoclasts. *Cell.* 2007; 130(5):811–823.
- ⁴⁷ Melville KM, Kelly NH, Khan SA, Schimenti JC, Ross FP, Main RP, van der Meulen MC. Female mice lacking estrogen receptor-alpha in osteoblasts have compromised bone mass and strength. *J Bone Miner Res.* 2013; [epub ahead of print].
- ⁴⁸ Bradford PG, Gerace KV, Roland RL, Chrzan BG. Estrogen regulation of apoptosis in osteoblasts. *Physiol Behav.* 2010;99(2):181-185.
- ⁴⁹ James AW, Theologis AA, Brusmann SA, Xu Y, Carre AL, Leucht P, Hamilton K, Korach KS, Longaker MT. Estrogen/estrogen receptor alpha signaling in mouse posterofrontal cranial suture fusion. *Plos One.* 2009;4(9):e7120.
- ⁵⁰ Bain SD, Bailey MC, Celino DL, Lantry MM, Edwards MW. High-dose estrogen inhibits bone resorption and stimulates bone formation in the ovariectomized mouse. *J Bone Miner Res.* 1993;8(4):435-52.
- ⁵¹ O'Connell MB. Pharmacokinetic and pharmacologic variation between different estrogen products. *The J of clin Pharmac.* 2013; 35(9). 18S-24S.
- ⁵² Khajuria DK, Razdan R, Mahapatra DR. Drugs for the management of osteoporosis: a review. *Rev Bras Reumatol.* 2011;51(4):365-82.
- ⁵³ Writing Group for the Women's Health Initiative Investigators. Risks and benefits of estrogen plus progestin in healthy postmenopausal women: principal results from the Women's Health Initiative randomized controlled trial. *JAMA.* 2002;288:32-333.
- ⁵⁴ Mochalin V, Shenderova O, Ho D, Gogotsi Y. The properties and applications of nanodiamonds. *Nature Nanotechnology.* 2012;7: 11–23.

-
- ⁵⁵ Lam, R. *et al.* Nanodiamond-embedded microfilm devices for localized chemotherapeutic elution. *ACS Nano*. 2008;**2**: 2095–2102
- ⁵⁶ Hoare TR, Kohane DS. Hydrogels in drug delivery: progress and challenges. *Polymer*. 2008;**49**(8):1993-2007.
- ⁵⁷ Maran A, Dadsetan M, Buenz CM, Shogren KL, Lu L, Yaszemski MJ. Hydrogel-PLGA delivery system prolongs 2-methoxyestradiol-mediated anti-tumor effects in osteosarcoma cells. *J Biomed Mater Res A*. 2013; **101**(9): 2491-9.
- ⁵⁸ Misra GP, Singh RS, Aleman TS, Jacobson SG, Gardner TW, Lowe TL. Subconjunctivally implanted hydrogels with degradable and thermoresponsive properties for sustained release of insulin to the retina. *Biomaterials*. 2009;**30**(33):6541-7.
- ⁵⁹ Man, H. B., Lam, R., Chen, M., Osawa, E. and Ho, D Nanodiamond-therapeutic complexes embedded within poly(ethylene glycol) diacrylate hydrogels mediating sequential drug elution. *Phys. Status Solidi A*. 2012; **209**: 1811–1818.
- ⁶⁰ Kanekawa M, Simizu N. Age-related changes on bone regeneration in midpalatal suture during maxillary expansion in the rat. *Am J Orthod Dentofacial Orthop*. 1998; **114**: 646-53.
- ⁶¹ Hu J, Hou Y, Park H, Choi B, Hou S, Chung A, Lee M. Visible light crosslinkable chitosan hydrogels for tissue engineering. *Acta Biomater*. 2012 May;**8**(5):1730-8.
- ⁶² Zahrowski J, Turley PK. Force magnitude effects upon osteoprogenitor cells during premaxillary expansion in rats. *Angle Orthod*. 1992; **62**(3): 197-202.
- ⁶³ Samuels A, Perry MJ, Goodship AE, Fraser WD, Tobias TH. Is high-dose estrogen-induced osteogenesis in the mouse mediated by an estrogen receptor? *Bone*. 2000; **27**(1): 41-46
- ⁶⁴ Sawada M, Simizu N. Stimulation of bone formation in the expanding mid-palatal suture by transforming growth factor-B1 in the rat. *European J of Orthod*. 1996;**18**:169-179.
- ⁶⁵ Ozturk F, Babacan H, Inan S, Gumus C. Effects of bisphosphonates on sutural bone formation and relapse: A histologic and immunohistochemical study. *Am J Orthod Dentofacial Orthop* 2011;**140**(1):e31-41.
- ⁶⁶ Verron E, Masson M, Khoshniat S, Duplomb L, Wittrant Y, Baud'huin M, Badran Z, Bujoli B, Janvier P, Scimeca JC, Bouler JM, Guicheux J. Gallium modulates osteoclastic bone resorption *in vitro* without affecting osteoblasts. *British J of Pharmacology*. 2010; **159**: 1681-1692.
- ⁶⁷ Bo Y, Chang J, Liu Y, Li J, Kevork K, Al-Hazimi K, Graves DT, Park NH, Wang CY. Wnt4 signaling prevents skeletal aging and inflammation by inhibiting nuclear factor-kB. *Nature Medicine*. 2014; **20**: 1009-1017.
- ⁶⁸ Bhattarai N, Gunn J, Zhang M. chitosan-based hydrogels for onctrolled, localized drug delivery. *Adv. Drug Delivery Rev*. 2010; **62**: 83-99.
- ⁶⁹ Lee DK, Kim SV, Limansubroto AN, Yen A, Soundia A, Wang CY, Shi W, Hong C, Tetradis S, Kim Y, Park NH, Kang MH, Ho D. Nanodiamond-gutta percha composite biomaterials for root canal therapy. *ACS Nano*. 2015; **9**(11): 11490-11501.
- ⁷⁰ The Writing Group for the PEPI. Effects of hormone therapy on bone mineral density: results from the postmenopausal estrogen/progestin interventions (PEPI) trial. *Jama*. 1996;**276**: 1389-96.
- ⁷¹ Delmas PD. Treatment of postmenopausal osteoporosis. *Lancet*. 2002; **359**: 2018-26.
- ⁷² Turner RT. Skeletal response to alcohol. *Alcohol Clin Exp Res*. 2000; **24**(11): 1693-1701.