

# UC San Diego

## UC San Diego Previously Published Works

### Title

Cytomegalovirus Retinitis in an Eye with Unilateral Retinoblastoma: A Case Report.

### Permalink

<https://escholarship.org/uc/item/3cm2x1pd>

### Journal

Case Reports in Ophthalmology, 15(1)

### ISSN

1663-2699

### Authors

Meller, Leo

Jagadeesh, Vasan

Oca, Michael

et al.

### Publication Date

2024

### DOI

10.1159/000538738

### Copyright Information

This work is made available under the terms of a Creative Commons Attribution-NonCommercial License, available at <https://creativecommons.org/licenses/by-nc/4.0/>

Peer reviewed

Case Report

# Cytomegalovirus Retinitis in an Eye with Unilateral Retinoblastoma: A Case Report

Leo Meller<sup>a,b</sup> Vasan Jagadeesh<sup>a</sup> Michael Oca<sup>a</sup> Katherine Wilson<sup>a</sup>  
Connor Zuraski<sup>c</sup> Zachary A. Koretz<sup>b</sup> Patricia Chevez-Barrios<sup>d</sup>  
Catherine Liu<sup>b</sup> Jesse L. Berry<sup>e</sup> Nathan L. Scott<sup>b</sup>

<sup>a</sup>School of Medicine, University of California, San Diego, CA, USA; <sup>b</sup>Viterbi Family Department of Ophthalmology and Shiley Eye Institute, University of California San Diego, San Diego, CA, USA; <sup>c</sup>Department of Pathology, School of Medicine, University of California, San Diego, CA, USA; <sup>d</sup>Department of Pathology and Genomic Medicine, Houston Methodist Hospital, Houston, TX, USA; <sup>e</sup>Ocular Oncology and Retinoblastoma Program, Children's Hospital Los Angeles, Los Angeles, CA, USA

## Keywords

Retinoblastoma · Cytomegalovirus · Retinitis · Pediatric · Case report

## Abstract

**Introduction:** Cytomegalovirus (CMV) retinitis in the setting of pediatric retinoblastoma is exceedingly unusual. Here, we present the first reported case of CMV retinitis in an enucleated eye with retinoblastoma after chemotherapy in the western hemisphere. **Case Presentation:** A 2-year-old Hispanic male without a family history of retinoblastoma presented with a 3-month history of right eye exotropia and squinting. Clinical examination revealed dense white vitreous opacities in the right eye. Ocular oncology evaluation unveiled an exudative retinal detachment with vitreous seeds, subretinal seeding, and a tumor emanating from the retina in the superonasal quadrant of the right eye. The patient was diagnosed with unilateral Group D retinoblastoma, and RB1 sequencing revealed a pathogenic variant with mosaicism. Treatment involved systemic chemotherapy, intravitreal chemotherapy, and cryotherapy. However, the patient developed a rhegmatogenous retinal detachment with diffuse vitreous hemorrhage and ultimately underwent right eye enucleation. Interestingly, histopathological analysis of the enucleated eye revealed concomitant CMV retinitis alongside retinoblastoma. After consultation with infectious disease, antiviral treatment was not initiated as the patient remained asymptomatic and maintained a recovered immune system. Repeat CMV PCR confirmed viral clearance. The patient received a prosthetic eye and continues to be monitored for retinoblastoma recurrence. **Conclusion:** Clinicians should be aware of the

potential for CMV retinitis to develop in retinoblastoma patients receiving chemotherapy, which may complicate clinical decision-making and management. Timely identification of CMV retinitis in this setting may improve patient ocular outcomes and overall prognosis.

© 2024 The Author(s).  
Published by S. Karger AG, Basel

## Introduction

Cytomegalovirus (CMV) is the primary cause of congenital viral infections, with an incidence ranging from 0.5% to 2% of all live births [1]. While approximately 90% of infected children appear healthy at birth, symptoms may manifest later in life [1]. CMV retinitis is a relatively uncommon but clinically significant ocular manifestation that typically occurs in individuals who may be immunocompromised [2]. CMV retinitis causes necrosis of the outer retinal cells, appearing as numerous white dots with a granular appearance and varying levels of intraretinal bleeding [3]. As the necrosis worsens, the underlying retinal pigment epithelium atrophies, revealing choroidal vasculature with serious adverse effects on the visual system, including blurry vision, floaters, and loss of peripheral vision [3, 4]. Retinal necrosis, hemorrhage, and vasculitis caused by CMV retinitis can further contribute to blindness and even death if the infection remains untreated [5].

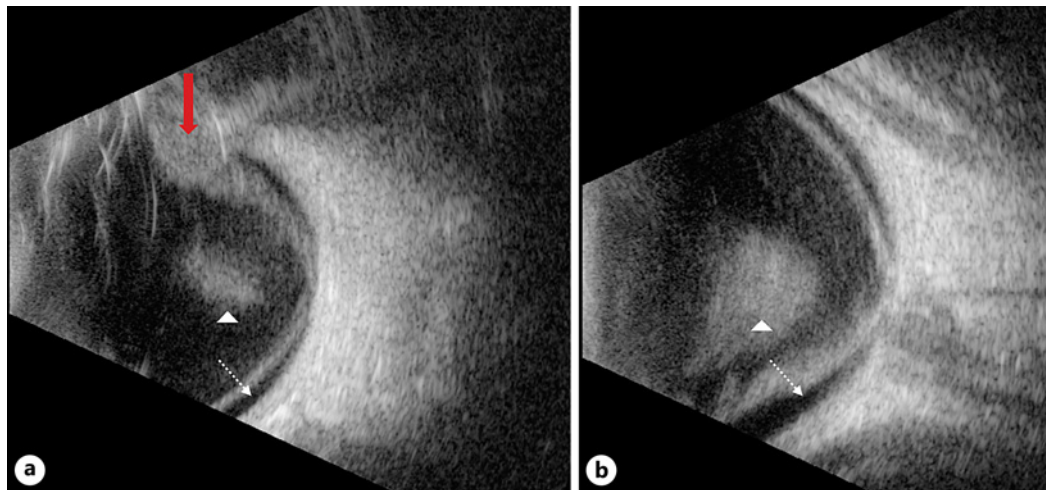
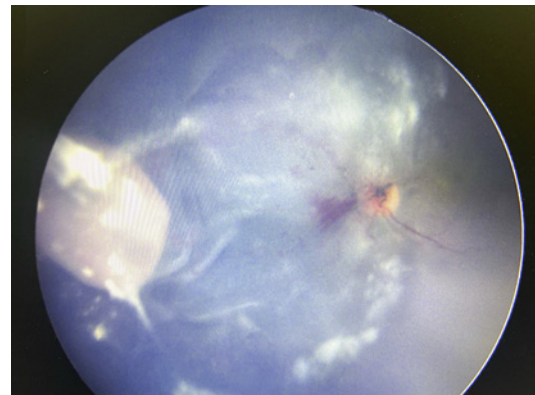
Retinoblastoma, on the other hand, is the most common primary intraocular malignancy, primarily occurring in early childhood [6]. It arises from a genetic mutation of the RB1 gene, leading to the uncontrolled proliferation of immature retinal cells [7]. Retinoblastoma typically presents with various clinical manifestations, such as leukocoria, strabismus, or reduced visual acuity, and is generally unilateral or bilateral [6].

The concomitant presence of CMV retinitis and retinoblastoma in the same pediatric patient represents an exceedingly rare clinical scenario. This case report highlights a co-occurrence of CMV retinitis and retinoblastoma in a pediatric patient without congenital CMV infection or a family history of retinoblastoma. To the best of our knowledge, this is the first reported case of CMV retinitis in an enucleated eye with retinoblastoma within the western hemisphere, following one report in Korea [8]. The CARE Checklist has been completed by the authors for this case report and is attached as online supplementary material (for all online suppl. material, see <https://doi.org/10.1159/000538738>).

## Case Presentation

A 2-year old Hispanic male with no family history of retinoblastoma presented to a pediatric ophthalmology clinic in August 2022 with 3 months of exotropia and squinting in the right eye. On examination, his pupils were equal, round, and reactive to light. His intraocular pressures were within normal limits (8 and 11 mm Hg in the right and left eye, respectively), and his anterior segment exam was unremarkable in each eye. On fundusoscopic examination of the right eye, dense white vitreous opacities and hemorrhage at the nasal aspect of the disc were noted. Examination of the left eye was unremarkable. The patient was then referred to the ocular oncology service for evaluation for retinoblastoma. An examination under anesthesia was performed and corroborated the documented exam findings. It also revealed an exudative retinal detachment with subretinal seeding inferiorly, as well as a 6-mm × 6-mm tumor in the superonasal quadrant of the right eye (Fig. 1). B-scan ultrasound of the right eye confirmed dense vitreous seeding, a hyperechogenic mass in the superonasal

**Fig. 1.** RetCam fundus photography of the right eye. There are scattered dense white vitreous opacities throughout the vitreous cavity. The retina is detached with prominent corrugations and maintains a dusky appearance. There is a prominent juxta-papillary retinal hemorrhage abutting the nasal aspect of the optic disc. A white exophytic retinal tumor emanates from the superior nasal quadrant. Findings are consistent with retinoblastoma with concomitant CMV retinitis.

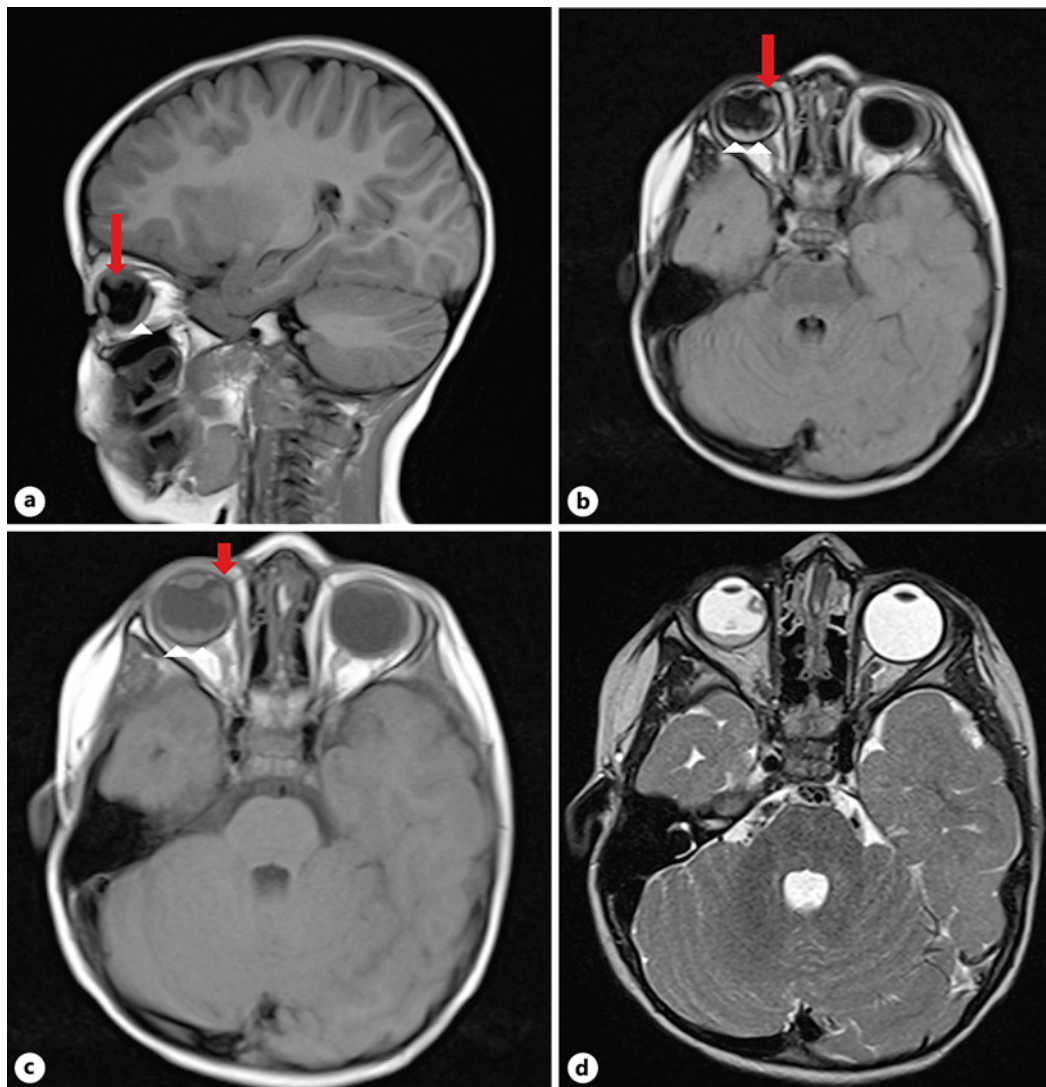


**Fig. 2.** B-Scan of the right eye. **a, b** B-scan ultrasound of the right eye confirmed dense vitreous seeds along with a retinal mass emanating from the superonasal quadrant. There was no evidence of extrascleral extension. A low-lying exudative retinal detachment is also noted. There is no evidence of optic nerve compromise. Red arrow: retinoblastoma; white arrowhead: dense vitreous seeds; white dashed arrow: retinal detachment.

quadrant, and a low-lying exudative retinal detachment (Fig. 2). A clinical diagnosis of unilateral right-sided group D retinoblastoma was made, and an MRI of the brain and orbit with and without contrast (Fig. 3) was consistent with the diagnosis and without evidence of trilateral disease. RB1 sequencing revealed mosaicism for a pathogenic variant: c.1597G>T (p.Glu533\*).

Treatment was initiated with systemic chemotherapy (cisplatin, vincristine, cyclophosphamide) in September 2022 and intravitreal chemotherapy (topotecan 30 µg in November 2022 and later melphalan 20 µg in December 2022), and cryotherapy was applied to active areas of the nasal tumor until end of December 2022. Unfortunately, the patient developed a rhegmatogenous retinal detachment with diffuse vitreous hemorrhage. As this limited the ability to monitor tumor response, the patient ultimately underwent enucleation in January 2023.

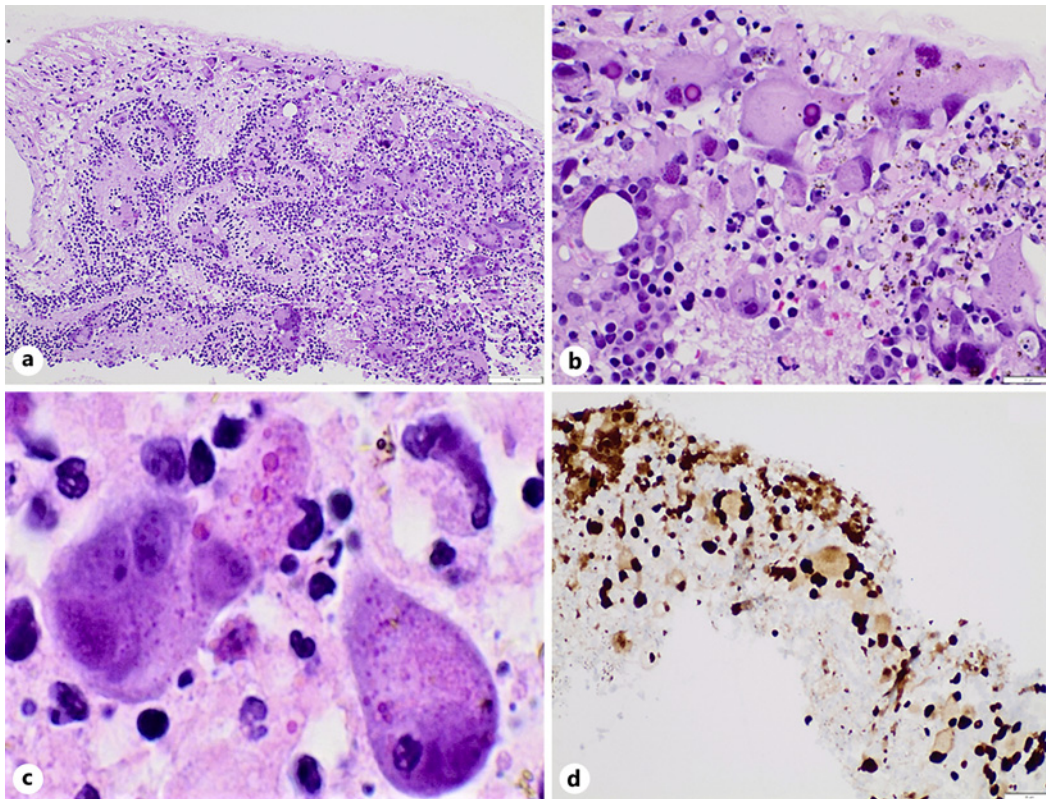
Interestingly, histopathology from the enucleated eye was positive for CMV retinitis in addition to retinoblastoma (Fig. 4). The patient had no known sick contacts, maternal prenatal labs were negative for HIV, Hepatitis B, and syphilis, there was no evidence of



**Fig. 3.** MRI of the orbit with and without contrast. **a** Sagittal T1-weighted. **b** Axial contrast enhanced T1-weighted. **c** Axial non-contrast T1-weighted. **d** Axial T2 without manipulation. Demonstration of a retinal detachment along with a nodular 3 mm enhancing focus along the nasal aspect of the globe in the right eye. It emanates from the expected position of the ora serrata and appears consistent with retinoblastoma. Red arrow: retinoblastoma; white arrowhead: exudative retinal detachment.

infection during pregnancy, and the patient had a normal hearing screening at birth. The patient was evaluated by the pediatric infectious disease service who determined that congenital CMV infection was unlikely given the lack of any stigmata of congenital infections and that most likely this represented an infection acquired while the patient was immunosuppressed during the 3-month period of chemotherapy (September–December 2022). Plasma CMV PCR was positive for CMV with a viral load of 918 IU/mL. Since the right eye had been enucleated and the patient was asymptomatic, no antiviral treatment was prescribed. Repeat CMV PCR the following month was negative, confirming clearance of the CMV infection. There was no indication for further CMV testing or antiviral treatment. The patient was fitted with a prosthesis for the right eye and continues to be monitored for recurrence of retinoblastoma.





**Fig. 4.** Histopathologic findings of cytomegalovirus retinitis. Magnocellular, pleomorphic cells with granular, eosinophilic cytoplasmic inclusions and smudgy, intensely basophilic nuclear inclusions in a turbulent background of karyorrhexis and neutrophils were observed (**a**,  $\times 100$ ; **b**,  $\times 400$ ; **c**,  $\times 600$ ). Immunohistochemistry for cytomegalovirus shows intense positivity (**d**).

## Discussion

Herein, we present a rare case of CMV retinitis occurring in a 2-year-old Hispanic male in the setting of unilateral retinoblastoma. CMV is a primary cause of mortality among patients receiving hematopoietic stem cell transplantation (HSCT) [9], but less common in children receiving cancer treatment without HSCT. In our case, subsequent evaluation by the pediatric infectious disease service determined that the CMV infection was unlikely to be congenital due to the lack of other signs that typically accompany congenital CMV infections, such as petechiae, jaundice, and microcephaly. Instead, the present CMV infection likely occurred during immunosuppression due to chemotherapy. Importantly, children undergoing immunosuppressive therapies such as chemotherapy for retinoblastoma are at elevated risk for decreased vision, irreversible blindness, and even morbidity and mortality from CMV infection [8]. This case thus adds to the growing literature on CMV in pediatric retinoblastoma patients without HSCT by describing the potential occurrence of CMV retinitis and further demonstrates the need for heightened vigilance and monitoring of CMV in children undergoing immunosuppressive treatment for retinoblastoma.

Although CMV infection is known to be lethal in patients undergoing treatment for cancer, there are no standardized guidelines for prophylaxis and screening [10]. For pediatric retinoblastoma patients, little is known about the risk factors for developing CMV during their treatment. A recent cohort study conducted in Korea by Han et al. [11] found that certain factors, such as diagnosis with retinoblastoma or neuroblastoma and younger age of diagnosis, have been considered to place patients at a higher risk of developing CMV during

chemotherapy treatment. However, the association between younger age and CMV infection was attributed to the unique seroepidemiology of CMV in Korea; children had higher baseline CMV seropositivity (81.7%), indicating that CMV DNAemia and subsequent reactivation were more likely in children compared to adults. Thus, more data are needed to better stratify pediatric patients based on their risks of developing infection during immunosuppressants in other countries. In our case, antiviral therapy did not appear to be indicated as the patient's viral load was low, the right eye had been enucleated, and the patient was asymptomatic.

The management of retinoblastoma can be notably complex due to its potential to masquerade as other ocular diseases. Common conditions that may occur concurrently or may be mistaken for include vitreous hemorrhage, persistent fetal vasculature, Coat's disease, and ocular toxocariasis [12, 13]. Retinoblastoma symptoms may also distract from CMV symptoms, as both can present with fatigue and lymphadenopathy. In addition to presenting with similar systemic symptoms, the ocular symptoms which manifest from both pathologies are also similar. For instance, retinoblastoma and CMV patients commonly present with vision loss. Vision loss due to retinoblastoma can be due to retinal detachment, tumor growth, or optic nerve invasion, while CMV retinitis vision loss can stem from hemorrhage, edema, or detachment [14]. Both of which can result in acute or gradual loss of vision depending on the extent of the malignancy or infection. Another common symptom is leukocoria or white pupillary reflex. In cases of retinoblastoma, this results from light reflection off of the tumor, while in CMV, this sign occurs due to the inflamed retina and/or vitreous [15]. In light of these similarities, clinicians should keep both conditions in mind when considering clinical management. Differentiation can be made through ophthalmic exams and imaging. Moreover, a dilated eye exam, urine, and blood tests can detect signs of CMV retinitis. Retinoblastoma, while signs may also be evident during a dilated eye exam, is confirmed through other imaging studies including ultrasound and MRI. In terms of management, in the setting of co-commitment CMV retinitis and retinoblastoma, if the retinoblastoma in the infected eye does not warrant enucleation, the CMV retinitis should be managed with intravenous ganciclovir, foscarnet, or oral valganciclovir regardless of the CMV etiology [16].

In conclusion, the presence of CMV retinitis in this case of unilateral retinoblastoma demonstrates the importance to remain aware of such occurrences, especially in immunocompromised patients at risk for infection and vision loss. We further underscore the importance of recognizing and managing concurrent pathologies in retinoblastoma patients to improve patient vision outcomes and overall prognosis.

### Statement of Ethics

Ethical approval is not required for this study in accordance with local or national guidelines. Written informed consent was obtained from the legal guardian for publication of this case report and any accompanying images.

### Conflict of Interest Statement

The authors have no conflicts of interest to declare.

### Funding Sources

This study was not supported by any sponsor or funder.

### Author Contributions

L.M., V.J., M.O., K.W., C.Z., Z.A.K., J.L.B., and N.L.S.: substantial contributions to the conception or design of the work, drafting the work or reviewing it critically for important intellectual content, final approval of the version to be published, and agreement to be accountable for all aspects of the work in ensuring that questions related to the accuracy or integrity of any part of the work are appropriately investigated and resolved. P.C.-B. and C.L.: drafting the work or reviewing it critically for important intellectual content, final approval of the version to be published, and agreement to be accountable for all aspects of the work in ensuring that questions related to the accuracy or integrity of any part of the work are appropriately investigated and resolved.

### Data Availability Statement

All data generated or analyzed during this study are included in this article and its online supplementary material files. Further inquiries can be directed to the corresponding author.

### References

- 1 Coats DK, Demmler GJ, Paysse EA, Du LT, Libby C. Ophthalmologic findings in children with congenital cytomegalovirus infection. *J AAPOS*. 2000;4(2):110–6. <https://doi.org/10.1067/mpa.2000.103870>
- 2 Boeckh M. Complications, diagnosis, management, and prevention of CMV infections: current and future. *Hematol Am Soc Hematol Educ Program*. 2011;2011:305–9. <https://doi.org/10.1182/asheducation-2011.1.305>
- 3 Au Eong KG, Beatty S, Charles SJ. Cytomegalovirus retinitis in patients with acquired immune deficiency syndrome. *Postgrad Med J*. 1999;75(888):585–90. <https://doi.org/10.1136/pgmj.75.888.585>
- 4 Port AD, Orlin A, Kiss S, Patel S, D'Amico DJ, Gupta MP. Cytomegalovirus retinitis: a review. *J Ocul Pharmacol Ther*. 2017;33(4):224–34. <https://doi.org/10.1089/jop.2016.0140>
- 5 de la Torre JC, Martínez-Salas E, Diez J, Villaverde A, Gebauer F, Rocha E, et al. Coevolution of cells and viruses in a persistent infection of foot-and-mouth disease virus in cell culture. *J Virol*. 1988;62(6):2050–8. <https://doi.org/10.1128/JVI.62.6.2050-2058.1988>
- 6 Abramson DH, Frank CM, Susman M, Whalen MP, Dunkel IJ, Boyd NW. Presenting signs of retinoblastoma. *J Pediatr*. 1998;132(3 Pt 1):505–8. [https://doi.org/10.1016/s0022-3476\(98\)70028-9](https://doi.org/10.1016/s0022-3476(98)70028-9)
- 7 Mallipatna A, Marino M, Singh AD. Genetics of retinoblastoma. *Asia Pac J Ophthalmol*. 2016;5(4):260–4. <https://doi.org/10.1097/APO.0000000000000219>
- 8 Han MS, Choi EH, Lee HJ, Yun KW, Kang HJ, Hong KT, et al. Cytomegalovirus disease in a retinoblastoma cohort: the role of preemptive screening. *Pediatr Blood Cancer*. 2020;67(3):e28101. <https://doi.org/10.1002/pbc.28101>
- 9 Yoon HS, Lee JH, Choi ES, Seo JJ, Moon HN, Kim MN, et al. Cytomegalovirus infection in children who underwent hematopoietic stem cell transplantation at a single center: a retrospective study of the risk factors. *Pediatr Transplant*. 2009;13(7):898–905. <https://doi.org/10.1111/j.1399-3046.2008.01084.x>
- 10 García-Bustos V, Salavert M, Blanes R, Cabañero D, Blanes M. Current management of CMV infection in cancer patients (solid tumors). *Epidemiology and therapeutic strategies*. *Rev Esp Quimioter*. 2022;35(Suppl 3):74–9. <https://doi.org/10.37201/req/s03.16.2022>
- 11 Han SH, Yoo SG, Do Han K, La Y, Kwon DE, Lee KH. The incidence and effect of cytomegalovirus disease on mortality in transplant recipients and general population: real-world nationwide Cohort data. *Int J Med Sci*. 2021;18(14):3333–41. <https://doi.org/10.7150/ijms.62621>
- 12 Ghassemi F, Ghadimi H, Amoli FA, Esfahani MR, Tavakoli V, Fariba G. Diffuse infiltrating retinoblastoma coexisting with ocular toxoplasmosis. *Int Ophthalmol*. 2014;34(1):137–40. <https://doi.org/10.1007/s10792-013-9753-3>
- 13 Jansen RW, de Bloeme CM, Brisse HJ, Galluzzi P, Cardoen L, Göricke S, et al. MR imaging features to differentiate retinoblastoma from Coats' disease and persistent fetal vasculature. *Cancers*. 2020;12(12):3592. <https://doi.org/10.3390/cancers12123592>
- 14 Bigagli E, Agostiniani S, Pugi A, Rombi B, Tornaboni EE, Censullo ML, et al. Unforeseen cytomegalovirus retinopathy following high dose thiotepa and proton irradiation in a pediatric patient with high-risk medulloblastoma: a case report. *Front Pediatr*. 2023;11:1145941. <https://doi.org/10.3389/fped.2023.1145941>
- 15 Zhao Q, Li NN, Chen YX, Zhao XY. Clinical features of cytomegalovirus retinitis in patients with acquired immunodeficiency syndrome and efficacy of the current therapy. *Front Cell Infect Microbiol*. 2023;13:1107237. <https://doi.org/10.3389/fcimb.2023.1107237>
- 16 Tan BH. Cytomegalovirus treatment. *Curr Treat Options Infect Dis*. 2014;6(3):256–70. <https://doi.org/10.1007/s40506-014-0021-5>