

UCLA

UCLA Previously Published Works

Title

Angioid streaks associated with abetalipoproteinemia

Permalink

<https://escholarship.org/uc/item/3c60352q>

Journal

Ophthalmic Genetics, 15(3-4)

ISSN

1381-6810

Authors

Gorin, Michael B

Paul, T Otis

Rader, Daniel J


Publication Date

1994

DOI

10.3109/13816819409057843

Peer reviewed



Angioid streaks associated with abetalipoproteinemia

Michael B. Gorin, T. Otis Paul & Daniel J. Rader

To cite this article: Michael B. Gorin, T. Otis Paul & Daniel J. Rader (1994) Angioid streaks associated with abetalipoproteinemia, *Ophthalmic Genetics*, 15:3-4, 151-159, DOI: [10.3109/13816819409057843](https://doi.org/10.3109/13816819409057843)

To link to this article: <http://dx.doi.org/10.3109/13816819409057843>



Published online: 08 Jul 2009.



Submit your article to this journal [↗](#)



Article views: 7



View related articles [↗](#)

© Ophthalmic Genetics 0167-6784/94/
US\$ 3.50

Ophthalmic Genetics – 1994, Vol. 15,
No. 3/4 pp. 151-159
© *Aeolus Press*
Buren (The Netherlands) 1994

Accepted 10 September 1994

Angioid streaks associated with abetalipoproteinemia

Michael B. Gorin¹
T. Otis Paul²
Daniel J. Rader^{3*}

¹ Departments of Ophthalmology and Human Genetics, University of Pittsburgh School of Medicine and Graduate School of Public Health, Pittsburgh, PA 15213

² Smith-Kettlewell Eye Research Institute, San Francisco, CA 94115

³ Molecular Disease Branch; National Heart, Lung, and Blood Institute; National Institutes of Health, Bethesda, MD 20892
USA

Abstract Angioid streaks were observed in two patients with abetalipoproteinemia. The progression of the angioid streaks was minimal over the years that these patients received vitamin A and E supplementation, though in one patient the development of subretinal neovascular membranes within the angioid streaks was the cause of rapid central visual loss. The simultaneous appearance of two rare entities in unrelated individuals strengthens the relationship between these two disorders that has been suggested by previous case studies. The authors propose a common metabolic pathway involving trace element deficiencies that may account for this relationship as well as the association of angioid streaks with other rare disorders such as Paget's disease, hypoparathyroidism, lead poisoning, hyperphosphatemia, and a number of hemoglobinopathies. Their study of these two patients underscores the need for further investigations as to the role of copper, zinc and omega-3 fatty acids in the pathogenesis of retinopathy in abetalipoproteinemia.

Key words Abetalipoproteinemia; lipid malabsorption syndromes; angioid streaks; trace elements; essential fatty acid deficiency; zinc; copper; metabolic retinopathy

Introduction It has long been recognized that abetalipoproteinemia (Bassen Kornzweig disease) results in a progressive retinopathy affecting both rod and cone function.¹⁻³ Though vitamins A and E are the mainstay therapy for this disease of lipid transport, the degenerative process can be progressive despite supplementation.³⁻⁷ Lipid malabsorption, one feature of abetalipoproteinemia, is associated with a number of deficiencies in addition to the fat-soluble vitamins, including essential fatty acids and minerals that are known to play a role in the maintenance of the retina and pigment epithe-

Acknowledgements: The authors wish to thank Dr. R. E. Anderson for performing serum lipid analyses of these patients and for his helpful discussion and comments.

* *Current address:* Department of Medicine, University of Pennsylvania, Philadelphia, PA 19104, USA

lium.⁸ Though the metabolic disturbances and retinal abnormalities reported for individuals who are homozygous for abetalipoproteinemia or hypobetalipoproteinemia are very similar, family studies have established genetic heterogeneity for these two disorders.⁹ Mutations in apolipoprotein B have been identified in a number of patients with hypobetalipoproteinemia¹⁰ while the primary genetic defect for abetalipoproteinemia involves a microsomal triglyceride transfer protein.¹¹⁻¹³

There are three other reports^{7,14,15} of abetalipoproteinemia associated with angioid streaks. One of these reports appears to include one of the patients in this report.¹⁴ The case reported by Runge *et al.* as having angioid streaks probably had hypobetalipoproteinemia rather than classical abetalipoproteinemia. Previously no mechanism for the association of these two disorders has been proposed.

While at least 50% of patients with angioid streaks have evidence of pseudo-xanthoma elasticum, the remaining cases have been correlated with a variety of systemic conditions. Ehlers-Danlos and Marfan's syndrome, like pseudo-xanthoma elasticum, are associated with genetic abnormalities of connective tissue. A much larger and more diverse group of conditions are associated with angioid streaks and yet their role in the pathogenesis of these lesions remains unknown. Angioid streaks have been seen in patients with Paget's disease, hyperparathyroidism, lead poisoning, hyperphosphatemia, and hemoglobinopathies such as hereditary spherocytosis, beta thalassemia, alpha thalassemia, and sickle cell disease.^{14,16-18}

We observed angioid streaks associated with abetalipoproteinemia in two unrelated individuals. These cases reinforce the association of these extremely rare disorders that has been previously reported. Based upon photographic comparisons, these angioid streaks have remained stable in these individuals during a five- and ten-year-period of vitamin A and E supplementation therapy. In light of our findings in these patients, we have reexamined the hypotheses regarding the etiology of angioid streaks and propose a unifying, testable hypothesis to account for the association of these lesions with a wide range of systemic diseases.

Case reports **CASE I** A 32-year-old Jewish male, with a history of abetalipoproteinemia and pigmentary retinopathy was referred to the National Institute of Health for evaluation and treatment. The patient had childhood growth retardation and the diagnosis of abetalipoproteinemia was made at age five. He was intermittently treated with vitamin E since the age of seven, with periods of noncompliance for as long as one year. He enlisted in the Air Force at age 19 with a visual acuity of 20/20 bilaterally. Angioid streaks were first noted when the patient was 22 years old and visual acuities were 20/20 at that time. He had decreased dark adaptation which reportedly normalized after vitamin A therapy. Vision continued to deteriorate over the next several years and vitamin therapy compliance was poor. A skin biopsy was negative for pseudoxanthoma elasticum. At age 26, he experienced a subretinal neovascularization of the macula of the right eye that reduced his visual acuity to 20/400. Visual acuity in the left eye remained 20/20. Night blindness became much more severe during the next five years. His medications were vitamin A—50,000 units daily, vitamin K—10 mg daily, and vitamin E—9,600 I.U. daily. He was noted to have mild cerebellar signs, intermittent steatorrhea, absent vibratory sense, and decreased deep tendon reflexes on general

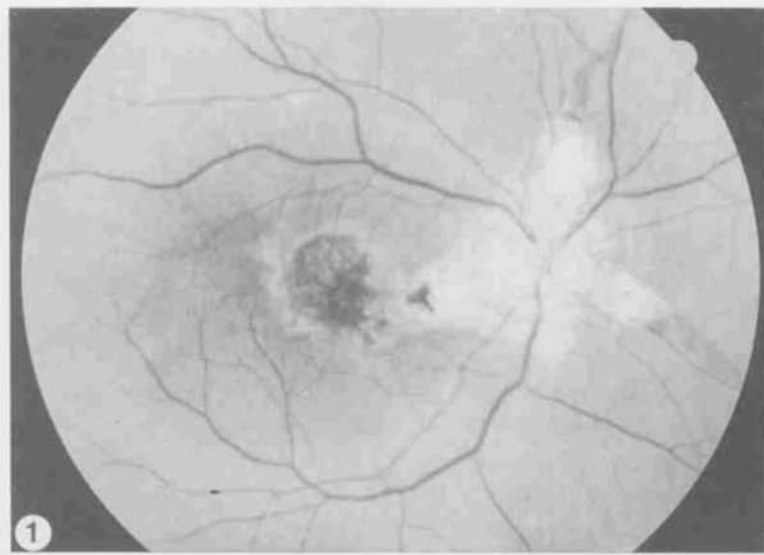


Fig. 1. (Case 1). Fundus photograph of the right eye demonstrating peripapillary atrophy and angioid streaks emanating from the optic nerve. The hyperpigmented lesion in the center of the macula is the result of a subretinal neovascular membrane with persistent subretinal fluid. Note the mild attenuation of the retinal arterioles consistent with the relative preservation of peripheral retinal function.

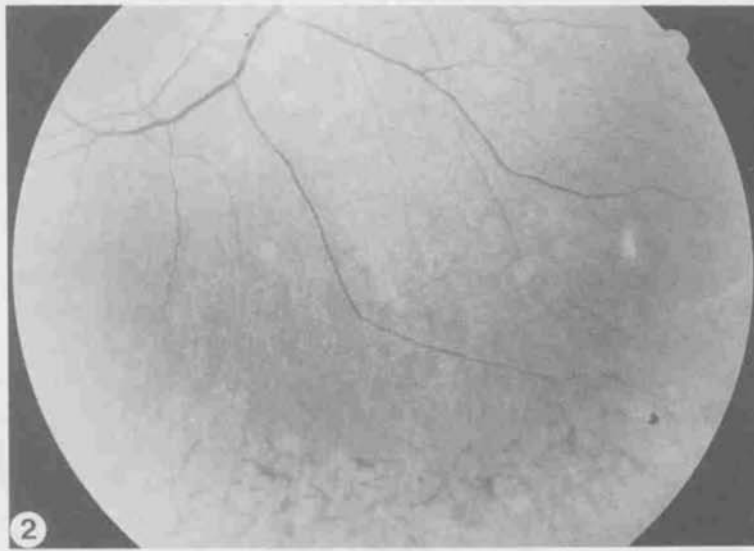


Fig. 2. (Case 1). Fundus photograph of the right eye inferior to the optic disc demonstrating the granular pigmentary changes and the presence of intraretinal pigment spicules in the midperipheral retina.

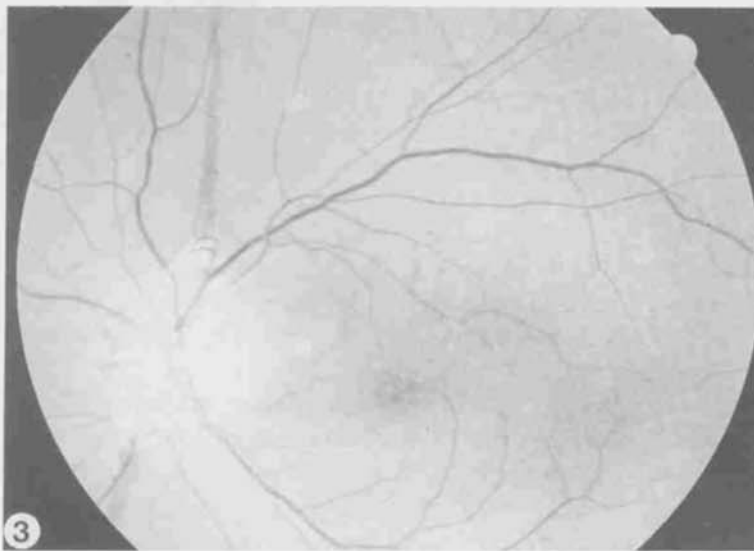


Fig. 3. (Case 1). Fundus photograph of the left eye demonstrating angioid streaks, peripapillary atrophy, a granular pigmentary retinopathy and fine, drusen-like deposits in the parafoveal area at the level of the pigment epithelium.

Laboratory data		Value	Normal range	Laboratory data		Value	Normal range
Serum Zn	N	77	(60-130) $\mu\text{g}/\text{dl}$	Vitamin E serum	L	2	(5-20) $\mu\text{g}/\text{ml}$
Serum Cu	N	89	(70-150) $\mu\text{g}/\text{dl}$	Cholesterol	L	41	(148-239) mg/dl
Urinary Zn	N	780	(150-1250) $\mu\text{g}/24\text{hr}$	Triglycerides	L	< 4	(58-213) mg/dl
Urinary Cu	L	10	(15-50) $\mu\text{g}/24\text{hr}$	Plasma free			
Vitamin A serum	L	< 10	(30-95) $\mu\text{g}/\text{ml}$	fatty acids	L	12	(22-67) $\mu\text{g}/\text{ml}$
Carotene	N	19	(5-20) $\mu\text{g}/\text{ml}$				

TABLE I.

physical examination. There was no other history of abetalipoproteinemia in the family. His sister was examined (TOP) and found to be completely normal, including visual fields and dark adaptation.

His chief complaint was vision loss of his right eye and moderate nyctalopia. The best-corrected visual acuity in the right eye was 20/60 with $-4.75 + 1.00 \times 072$. There was a subretinal neovascular membrane arising from an angioid streak involving the fovea (Fig. 1). Examination of that eye demonstrated a diffuse pigmentary retinopathy with intraretinal pigment ('bone spicules') in the periphery and pigment clumping in the macula (Fig. 2). The best-corrected visual acuity of the left eye was 20/15 with $-4.25 + 1.25 \times 125$. The fundus was affected in a symmetric fashion with respect to the right eye except that the angioid streaks did not involve the fovea and there was no evidence of a subretinal neovascular membrane (Fig. 3).

Visual function tests Goldmann-Weekers dark adaptometry was 1.5 log units elevated over normal mean for the right eye and 1.3 units for the left eye. Electro-oculography demonstrated the absence of a normal light rise (1.09). Goldmann visual fields demonstrated mild peripheral depression with a central scotoma of the right eye. The electroretinogram demonstrated a reduction in amplitude and increase in implicit time of all wave forms. Rod mediated responses were more reduced than cone responses.

CASE 2 The patient presented as a 36-year-old Japanese female who, as an infant, had steatorrhea, growth retardation, and ataxia. Diagnosis of abetalipoproteinemia was first made at age 28. Previously, she was thought to have celiac disease, later pseudo-obstructive bowel disease. Her medical history included progressive ataxia, peripheral neuropathy, and hypothyroidism. Despite treatment with oral vitamins A, E, and K, she experienced progression of her visual symptoms. Intramuscular vitamin E administration was poorly tolerated. Angioid streaks were first observed at age 28. She has taken vitamin A (15,000 I.U. per day) and vitamin E (400 I.U. per day) periodically since age 28. The family history was notable for three sisters who were also affected with abetalipoproteinemia. None of the sisters had angioid streaks, though one person had bilateral, spoke-like peripapillary atrophy of the pigment epithelium.

A skin biopsy was negative for pseudoxanthoma elasticum. Her neurologic examination demonstrated peripheral neuropathy with decreased vibratory and position sense, and ataxia.

Current ocular complaints were reduced peripheral visual fields, night blindness, and progressive inability to see colors—particularly red. The best-

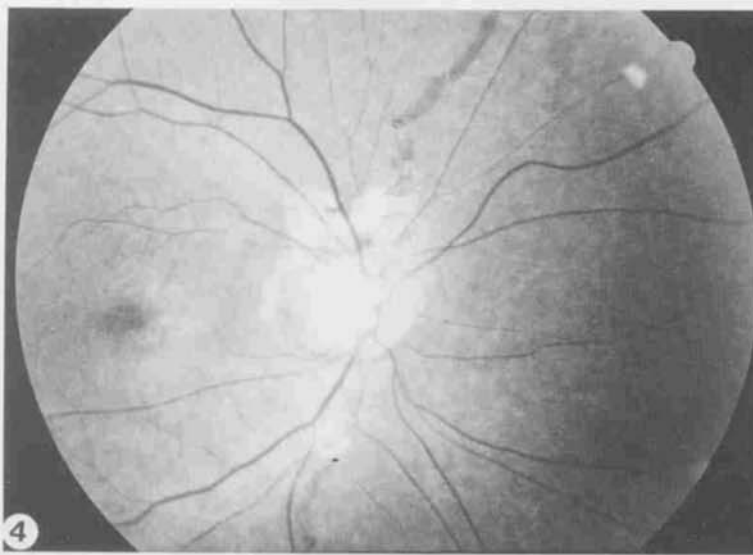


Fig. 4. (Case 2). Fundus photograph of the right eye demonstrating peripapillary atrophy and angioid streaks emanating from the optic nerve. The retinal arterioles and veins are markedly attenuated as compared to those of Case 1. The severity of the vascular attenuation is consistent with the extensive loss of peripheral retinal function as observed with Goldmann perimetry.

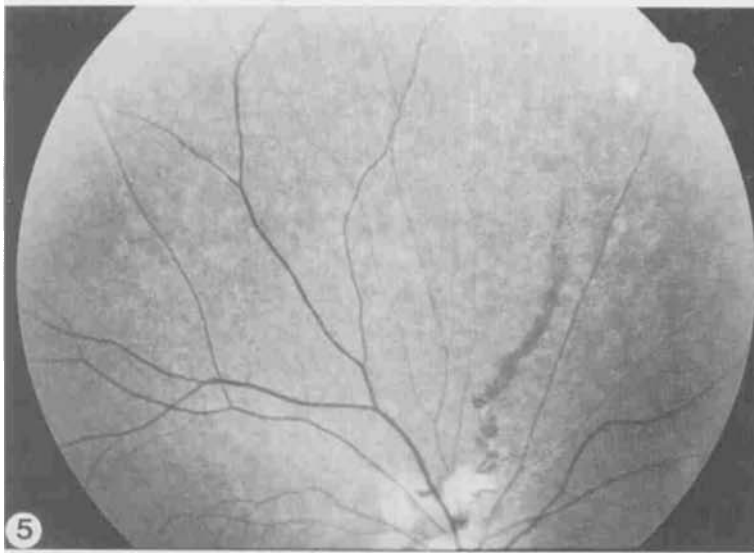


Fig. 5. (Case 2). Fundus photograph of the right eye superior to the optic disc demonstrating the granular pigmentary changes and the presence of fine, drusen-like deposits at the level of the pigment epithelium throughout the posterior pole.

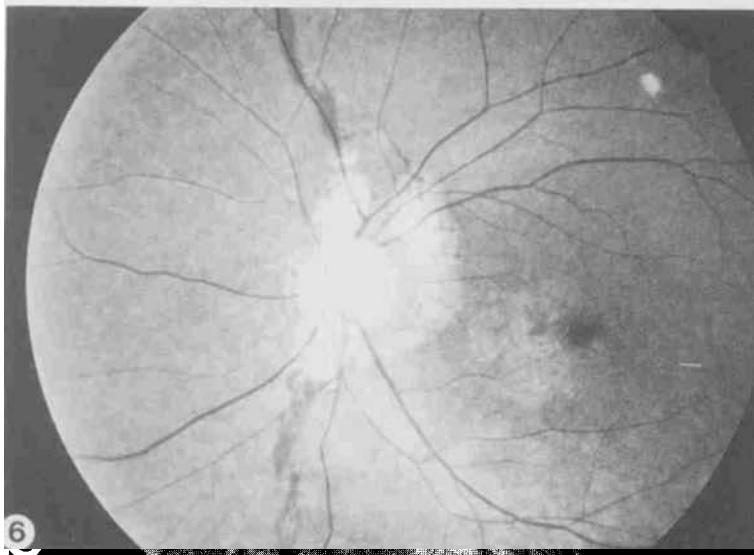


Fig. 6. (Case 2). Fundus photograph of the left eye demonstrating angioid streaks, peripapillary atrophy, and the granular pigmentary retinopathy affecting the macula and peripheral retina. The retinal vasculature is attenuated to the same extent as observed in the right eye.

Laboratory data		Value	Normal range	Laboratory data		Value	Normal range
Serum Zn	N	76	(60-130) $\mu\text{g}/\text{dl}$	Vitamin E serum	L	19	(5-20) $\mu\text{g}/\text{ml}$
Serum Cu	N	142	(70-150) $\mu\text{g}/\text{dl}$	Cholesterol	L	33	(148-239) mg/dl
Urinary Zn	N	757	(150-1250) $\mu\text{g}/24\text{hr}$	Triglycerides	L	4	(58-213) mg/dl
Urinary Cu	L	11	(15-50) $\mu\text{g}/24\text{hr}$	Plasma free			
Vitamin A serum	L	50	(30-95) $\mu\text{g}/\text{ml}$	fatty acids	L	8	(22-67) $\mu\text{g}/\text{ml}$
Carotene	N	10	(5-20) $\mu\text{g}/\text{ml}$				

TABLE 2.

corrected visual acuities were 20/100 for the right eye with $-3.75 + 0.50 \times 005$, and 20/80 in the left eye with -3.50 sphere. Fundus examination showed bilateral pigmentary retinopathy and angioid streaks (Figs. 4, 5, and 6).

Visual function tests Goldmann-Weekers dark adaptometry was elevated 2.5 log units over normal mean. Goldmann visual fields demonstrated marked constriction bilaterally to the five-degree isopter. Electroretinography demonstrated reduction in amplitude and increase in implicit times observed in all wave forms. Rod mediated responses were more abnormal than cone responses. Serial electroretinograms over a six-year period demonstrated progressive deterioration of both amplitudes and implicit times despite therapy.

Discussion These cases expand the association of abetalipoproteinemia and angioid streaks and provide a rare opportunity to reexamine the metabolic derangements caused by abetalipoproteinemia and the potential factors that contribute to the retinopathy, angioid streaks, and vision loss. The youngest prior case of abetalipoproteinemia and angioid streaks was reported by Muller and Lloyd in a 23.5-year-old female.¹⁹ Based upon our records, angioid streaks were present in our patients no later than age 22 (Case 1) and age 29 (Case 2). Ducker and Dieckert^{14,15} noted the potential for vision loss secondary to angioid streaks in the macula in these patients. This was the case for one of our patients, Case 1, whose vision loss was due to a subretinal neovascular membrane arising from an angioid streak. In Case 2, the primary threat to vision was the widespread retinal degeneration which caused a marked depression of peripheral vision and nightblindness.

The genetic abnormalities in some of the disorders associated with angioid streaks such as Ehler-Danlos and pseudo-xanthoma elasticum (PXE) act in a fashion to alter the constituents of the basement membrane, particularly those of the elastic layers.²⁰ Calcium deposition is almost universally found in skin biopsies of patients with PXE and has been identified in Bruch's membrane from several patients. Paton²¹ postulated that calcium deposition secondary to Paget's disease, hypercalcemia, and hyperphosphatemia are responsible for the angioid streaks in these patients, rather than a structural defect in the basement membrane. The association of angioid streaks with retinal and optic disc drusen has reinforced the notion of calcium deposition playing a major role in the pathogenesis of these lesions.¹⁶ It has been hypothesized that the hemoglobinopathies cause iron deposition that leads to fragility in the basement membrane.^{14,16,21} Iron deposition has been reported in two instances of angioid streaks, but other studies have not con-

firmed these observations.¹⁸ In sickle cell disease, breaks in Bruch's membrane have also been attributed to choroidal stasis and ischemia (see^{16,18}).

In abetalipoproteinemia and hypobetalipoproteinemia, there is no evidence that calcium or iron metabolism is significantly altered. Skin biopsies of the two individuals were negative for PXE and calcium deposition. The first patient had a history of mild anemia but was not on supplemental iron. Our second patient had a history of chronic hemolytic anemia and was on supplemental oral iron. The lack of association of angioid streaks with other disorders causing iron overload also argues that iron deposition is unlikely to be causal in the development of these lesions. The association of angioid streaks in abeta/hypobetalipoproteinemia patients may reflect an alternative mechanism that does not require the deposition of calcium or iron into the basement membrane as a primary event.

Cellular pathways responsible for basement membrane turnover and modeling are likely to act in the pathogenesis of angioid streaks. The role of the trace elements, zinc and copper, for the maintenance of the basement membrane has been emphasized in the pathogenesis of age-related maculopathy (ARM).^{22,23} Though ARM is distinct from angioid streaks, these disorders share progressive degenerative changes in Bruch's membrane with the deposition of calcium and other materials at Bruch's membrane.¹⁶ Zinc is an essential cofactor for carbonic anhydrase in the pigment epithelium, carboxypeptidase, and cytosolic superoxide dismutase. Copper is a cofactor for lysyl oxidase, an enzyme critical for elastin and collagen crosslinking, tyrosinase (essential for melanin production), as well as cytosolic superoxide dismutase and cytochrome oxidase.²⁴ Zinc deficiency has been reported in sickle cell anemia, alcoholism, chronic renal failure, and thrombocytopenia. Elevation in phosphate excretions can also lead to zinc depletion, and deficiencies are well described in Paget's disease, hyperparathyroidism and hypercalcemia.²⁵ Zinc and copper absorption are interrelated²⁶ and hypocupremia has been induced by zinc supplementation.²⁷

To our knowledge, trace metal levels and their metabolism have been overlooked in patients with abetalipoproteinemia. In other diseases that cause lipid and vitamin A malabsorption, such as alcoholic cirrhosis and biliary cholestasis, deficiencies in zinc have been well described.^{28,29} Peroxisomal abnormalities were found in a hepatic biopsy of an abetalipoproteinemia patient^{30,31} and such changes could be consistent with the impairment of superoxide dismutase, which resides in the peroxisome.

The retinopathy of abetalipoproteinemia is a secondary effect of systemic metabolic derangements caused by an inability to absorb essential fatty acids and fat-soluble vitamins. The vulnerabilities of the pigment epithelium and retina are largely due to their requirements for vitamins A and E, as evidenced by the partial reversal and stabilization of retinal dysfunction by therapy.³¹⁻³³ However, there is evidence that a selective vitamin E deficiency, while causing serious neurologic dysfunction, does not necessarily cause retinal dysfunction or degeneration.³⁴ Though improvement of visual function has been established by supplemental vitamin A and E, reversal of the retinopathy is incomplete. Our own patients who have been on long-term supplemental vitamin therapy continue to demonstrate a gradual decline in retinal function. It is probable that additional deficiencies and/or metabolic disturbances may play a role in the retinopathy of abetalipoproteinemia. Though we have discussed the role of zinc as a possible contributor to angioid

streaks, zinc deficiency is also associated with abnormal dark adaptation and retinopathy, independently of vitamin A levels.^{29,35} Animal studies have shown that deficiencies of omega-3 fatty acids can independently cause retinal dysfunction.³⁶ The levels of these essential fatty acids in ocular tissues have not been examined in this group of patients. We found that the plasma free fatty acids were extremely low in both of our patients. It may be advisable to include supplementation of these essential unsaturated fatty acids in the treatment of abetalipoproteinemia and hypobetalipoproteinemia.

We undertook to examine zinc and copper levels in our patients, at a time in which there appeared to be no active progression of the angioid streaks and the retinopathy was relatively stable. Both serum zinc and copper levels and urinary zinc levels were normal in both individuals though the urinary excretion of copper was markedly low. The low urinary excretion of copper in the presence of normal serum levels is suggestive of a reduced flux of copper that may contribute to selective abnormalities of copper utilization and/or represent a compensatory increased absorption of zinc at the expense of copper absorption. A major drawback to our analysis is that chronic element deficiencies can be overlooked by a spot analysis, and serum and urine levels of an element may not reflect its bioavailability to target tissues and enzymes. Ultimately it will be necessary to carry out elemental analysis of tissues and assay the enzymatic activities of key enzymes that rely on these elements as cofactors. We believe that these studies would be of benefit not only for the patients with abetalipoproteinemia but also for those patients who develop angioid streaks in association with other systemic disorders. This will help to establish the role of copper and zinc in the etiology of Bruch's membrane degeneration and to assess the potential for therapeutic intervention. The evaluation of functional zinc and copper levels in patients who are developing angioid streaks from different etiologies will be necessary to test this hypothesis.

Note added in proof: The recent discovery that Sorsby's fundus dystrophy is the result of mutations in the tissue inhibitor of metalloproteinase-3³⁷ reinforces our suggestion that the metabolism of Bruch's membrane may be highly dependent on basement membrane-specific enzymes, including the metalloproteinases, that are likely to be sensitive to copper and zinc bioavailability.

References

- 1 Cogan D, Rodrigues M, Chu R, Schaefer E. Ocular abnormalities in abetalipoproteinemia: A clinicopathologic correlation. *Ophthalmology* 1984; 91 (8): 991-998.
- 2 Berson E. Electroretinographic findings in retinitis pigmentosa. *Jpn J Ophthalmol* 1987; 31 (3): 327-348.
- 3 Brin M, Pedley T, Lovelace R, Emerson R, Gouras P, MacKay C et al. Electrophysiologic features of abetalipoproteinemia. *Neurology* 1986; 36: 669-673.
- 4 Bieri J, Hogg J, Schaefer E, Zech L, Brewer HJ. Vitamin A and vitamin E replacement in abetalipoproteinemia. *Ann Intern Med* 1984; 100 (2): 238-239.
- 5 Bishara S, Merin S, Cooper M, Azizi E et al. Combined vitamin A and E therapy prevents retinal electrophysiological deterioration in abetalipoproteinemia. *Br J Ophthalmol* 1982; 66 (12): 767-770.
- 6 MacGilchrist A, Mills P, Noble M, Foulds W et al. Abetalipoproteinemia in adults: role of vitamin therapy. *J Inherited Metab Dis* 1988; 11 (2): 184-190.
- 7 Runge P, Muller D, McAllister J, Calver D et al. Oral vitamin E supplements can prevent the retinopathy of abetalipoproteinemia. *Br J Ophthalmol* 1986; 70 (3): 166-173.
- 8 Rader D, Brewer H. Abetalipoproteinemia: New insights into lipoprotein assembly and vitamin E metabolism from a rare genetic disease. *JAMA* 1993; 270: 865-869.

- 9 Huang LS, Janne PA, de Graaf J, Cooper M, Deckelbaum RJ, Kayden H et al. Exclusion of linkage between the human apolipoprotein B gene and abetalipoproteinemia. *Am J Hum Genet* 1990; 46 (6): 1141-1148. [published erratum appears in *Am J Hum Genet* 1990 Jul; 47 (1): 172]
- 10 Young S, Linton M. Genetic abnormalities in apolipoprotein B. *Trends Cardiovasc Med* 1991; 1: 59-65.
- 11 Wetterau J, Aggerbeck L, Bouma M-E, Eisenberg C, Munck A, Hermier M et al. Absence of microsomal triglyceride transfer protein in individuals with abetalipoproteinemia. *Science* 1992; 258: 999-1001.
- 12 Sharp D, Blinderman L, Combs KA, Kienzle B, Ricci B, Wager SK et al. Cloning and gene defects in microsomal triglyceride transfer protein associated with abetalipoproteinemia. *Nature* 1993; 365 (6441): 65-69.
- 13 Shoulders C, Brett D, Bayliss J, Narcisi T, Jarmuz A, Grantham T et al. Abetalipoproteinemia is caused by defects of the gene encoding the 97 kDa subunit of a microsomal triglyceride transfer protein. *Hum Molec Genet* 1993; 2: 2109-2116.
- 14 Dieckert J, White M, Christmann L, Lambert H. Angioid streaks associated with abetalipoproteinemia. *Ann Ophthalmol* 1989; 21 (5): 172-175, 179.
- 15 Duker J, Belmont J, Bosley T. Angioid streaks associated with abetalipoproteinemia. *Arch Ophthalmol* 1987; 105 (9): 1173-1174.
- 16 Archer D, Logan W. Angioid Streaks. In: Krill A, editor. *Krill's Hereditary Retinal and Choroidal Diseases*, vol 2. Hagerstown, MD: Harper & Row Publ, 1977: 851-909.
- 17 Aessopos A, Stametelos G, Savvides P, Kavouklis E, Gabriel L, Rombos L et al. Angioid streaks in homozygous beta thalassemia. *Am J Ophthalmol* 1989; 108: 356-359.
- 18 Geeraets W, Guerry D. Angioid streaks and sickle cell disease. *Am J Ophthalmol* 1960; 49: 450-470.
- 19 Muller D, Lloyd J. Effect of large oral doses of vitamin E on the neurological sequelae of patients with abetalipoproteinemia. *Ann NY Acad Sci* 1982; 393: 133-144.
- 20 Klien B. Angioid streaks. A clinical and histopathologic study. *Am J Ophthalmol* 1947; 30: 955-968.
- 21 Paton D. *The Relation of Angioid Streaks to Systemic Disease*. Springfield, IL: Charles C Thomas, 1972.
- 22 Newsome D, Rothman R. Zinc uptake in vitro by human retinal pigment epithelium. *Invest Ophthalmol Vis Sci* 1987; 23: 1795.
- 23 Newsome D, Swartz M, Leone C, Elston C, Miller E. Oral zinc in macular degeneration. *Arch Ophthalmol* 1988; 106: 192.
- 24 Prohaska J. Biochemical functions of copper in animals. In: Prasad A, editor. *Essential and Toxic Trace Elements in Human Health and Disease*. New York: Alan R Liss, 1986: 105-124. (Albanese A, Kritchevsky D, editors. *Current Topics in Nutrition and Disease*; vol 18).
- 25 Prasad A. Clinical spectrum and diagnostic aspects of human zinc deficiency. In: Prasad A, editor. *Essential and Toxic Trace Elements in Human Health and Disease*. New York: Alan R Liss, 1986: 3-53. (Albanese A, Kritchevsky D, editors. *Current Topics in Nutrition and Disease*; vol 18).
- 26 Hoadley J, Cousins R. Regulatory mechanisms for intestinal transport of zinc and copper. In: Prasad A, editor. *Essential and Toxic Trace Elements in Human Health and Disease*. New York: Alan R Liss, 1986: 141-155. (Albanese A, Kritchevsky D, editors. *Current Topics in Nutrition and Disease*; vol 18).
- 27 Prasad A, Brewer G, Schoemaker E, Rabbani P. Hypocupremia induced by zinc therapy in adults. *JAMA* 1978; 240: 2166-2168.
- 28 Halsted J, Hackley A, Rudzki C, Smith Jr. J. Plasma zinc in liver disease. Comparison with normal controls and certain other chronic diseases. *Gastroenterology* 1968; 54: 1098.
- 29 McClain C, Van Thiel D, Parker S, Badzin L, Gilbert H. Alteration in zinc, vitamin A, retinol-binding protein in chronic alcoholics: A possible mechanism for night blindness and hypogonadism. *Alcoholism* 1979; 3: 135.
- 30 Avigan M, Ishak K, Gregg R, Hoofnagle J. Morphologic features of the liver in abetalipoproteinemia. *Hepatology* 1984; 4 (6): 1223-1226.
- 31 Collins J, Scheinberg I, Giblin D, Sternlieb I. Hepatic peroxisomal abnormalities in abetalipoproteinemia. *Gastroenterology* 1989; 97 (3): 766-770.
- 32 Illingworth D, Connor W, Miller R. Abetalipoproteinemia. Report of two cases and review of therapy. *Arch Neurol* 1980; 37 (10): 659-662.
- 33 Judisch G, Rhead W, Miller D. Abetalipoproteinemia. Report of an unusual patient. *Ophthalmologica* 1984; 1-2: 73-79.
- 34 Harding A, Matthews S, Jones S, Ellis C, Booth I, Muller D. Spinocerebellar degeneration associated with a selective defect of vitamin E absorption. *N Engl J Med* 1985; 313 (1): 32-35.
- 35 Russell R, Morrison S, Smith F, Oaks E, Carney E. Vitamin A reversal of abnormal dark adaptation in cirrhosis. Study of effects on retinal transport system. *Ann Int Med* 1968; 88: 622.
- 36 Neuringer M, Conner W, Van Petten C, Barstad L. Dietary omega-3 fatty acid deficiency and visual loss in infant Rhesus monkeys. *J Clin Invest* 1984; 73: 272-276.
- 37 Weber BHF, Vogt G, Pruett RC, Stohr H, Felbor U. Mutations in the tissue inhibitor of metalloproteinases-3 (TIMP3) in patients with Sorsby's fundus dystrophy. *Nature Genetics* 1994; 8 (4): 352-356.