

UC San Diego

UC San Diego Previously Published Works

Title

Bilateral Retinal Detachments in a Healthy 22-year-old Woman After Moderna SARS-COV-2 Vaccination

Permalink

<https://escholarship.org/uc/item/3bf598sr>

Journal

Journal of Emergency Medicine, 61(6)

ISSN

0736-4679

Authors

Subramony, Rachna
Lin, Lucia Christiana
Knight, Darren K
[et al.](#)

Publication Date

2021-12-01

DOI

10.1016/j.jemermed.2021.07.034

Peer reviewed



Since January 2020 Elsevier has created a COVID-19 resource centre with free information in English and Mandarin on the novel coronavirus COVID-19. The COVID-19 resource centre is hosted on Elsevier Connect, the company's public news and information website.

Elsevier hereby grants permission to make all its COVID-19-related research that is available on the COVID-19 resource centre - including this research content - immediately available in PubMed Central and other publicly funded repositories, such as the WHO COVID database with rights for unrestricted research re-use and analyses in any form or by any means with acknowledgement of the original source. These permissions are granted for free by Elsevier for as long as the COVID-19 resource centre remains active.

Clinical Communications: Adult

Bilateral Retinal Detachments in a Healthy 22-year-old Woman After Moderna SARS-COV-2 Vaccination

Rachna Subramony, MD,* Lucia Christiana Lin, BS,† Darren K. Knight, MD,‡ Amir Aminlari, MD,* and Ioan Belovarski, MD, MPH*

*Department of Emergency Medicine, University of California San Diego, San Diego, California, †University of California San Diego School of Medicine, San Diego, California, and ‡The Viterbi Family Department of Ophthalmology, Shiley Eye Institute, University of California San Diego, San Diego, California

Reprint Address: Rachna Subramony, MD, Department of Emergency Medicine, University of California San Diego, 200 W. Arbor Drive, Mail Code 8676, San Diego, CA 92103.

Abstract—Background: Although uncommon, retinal detachments are medically urgent and can result in permanent vision loss if untreated. Bilateral retinal detachments in healthy individuals are even more rare. In addition, there are no cases to date of retinal detachment associated with either coronavirus disease 2019 (COVID-19) or after receiving the Moderna (mRNA-1273) severe acute respiratory syndrome coronavirus-2 (SARS-CoV-2) vaccine. **Case Report:** A 22-year-old woman with myopia but no ocular trauma or other major medical history presented to the emergency department with 5 days of progressive, painless vision loss in her right eye. On examination, her visual acuity with corrective lenses was 20/70 in the right eye, 20/20 in the left eye, and 20/25 with both eyes open. Point-of-care ultrasound of the eye showed a retinal detachment in the right eye. She was subsequently seen by ophthalmology and diagnosed with bilateral retinal detachments (macula off in the right, macula on in the left), despite being asymptomatic in her left eye. She underwent bilateral vitrectomies for simultaneous rhegmatogenous retinal detachments. Although the patient denied any preceding trauma, she did note having received her second dose of the COVID-19 vaccine 10 days before the onset of symptoms.

Why Should an Emergency Physician Be Aware of This? We present a rare and unusual case of simultaneous bilateral retinal detachments in a healthy, young woman with no major medical history or medications. She received the COVID-19 vaccine a few days prior. Our case outlines a

possible association with the vaccine and emphasizes the importance of ultrasonography in diagnosing time-sensitive medical conditions. © 2021 Elsevier Inc. All rights reserved.

Keywords—bilateral retinal detachment; Moderna vaccine; COVID-19 vaccine; ultrasound; POCUS

Introduction

Retinal detachment occurs when the neurosensory retina separates from the underlying retinal pigment epithelium. It is an urgent medical condition that can cause permanent vision loss or blindness if not identified and corrected rapidly (1). Presentation typically includes sudden, painless loss or blurring of vision in the affected eye. Some patients report partial loss of their visual fields, which may be described as a veil or shadow cast in one area, while others report seeing flashes or floaters (2). The annual incidence is about 1 in 10,000 or about 1 in 300 over a lifetime (3). Those at risk include individuals with personal or family history of retinal detachment, traumatic eye injury, prior eye surgery, diabetic retinopathy, posterior vitreous detachment, degenerative myopia, and certain genetic disorders, such as Marfan's or Stickler's syndrome. Certain eye diseases also predispose individuals to retinal detachment, including retinoschisis or lattice degeneration, in

which the retina separates into two layers or thins out, respectively (2).

The most common form of retinal detachment is rhegmatogenous retinal detachment (RRD), in which a retinal tear enables the influx of fluid from the vitreous cavity into the subretinal space, thus resulting in retinal separation (1). These tears have various etiologies, including chronic degenerative processes as well as acute traumas. Comparatively, non-RRD is when there are no retinal tears. This group can be divided into tractional, in which diabetic retinopathy allows scarred blood vessels to pull the retina off the eye, or exudative, in which traumatic or inflammatory processes allow subretinal fluids to form, pushing the retina off the eye. One study showed the incidence of bilaterality in patients with retinal detachments to be approximately 10%, with only 18% of those cases presenting simultaneously (4). Simultaneous bilateral RRD, more specifically, has an annual incidence of 0.35 patients per 100,000 individuals, and is more likely to occur in young, highly myopic, male patients with multiple round atrophic retinal holes (4,5).

Retinal detachment can be further divided by whether the macula remains attached (macula on) or not (macula off). Patients with macula-on RRD typically have good initial visual acuity and a better prognosis with successful surgery than macula-off RRD (1). As such, macula-on RRD is a medically urgent condition, given the risk of rapid progression, and patients should have surgery as soon as possible to prevent macular detachment and possibly permanent loss of vision. If the macula is already detached, nonemergent surgery is recommended within 1 to 2 weeks, as some visual function may still be salvaged (2,6). Point-of-care ultrasound (POCUS) has been shown to be a useful tool in expediting the diagnosis and management of retinal detachments, which can improve patient outcomes (7).

The unique feature in our case is that our patient presented to the emergency department (ED) with simultaneous bilateral RRD, despite no preceding ocular trauma or major risk factors aside from myopia. She denied prior infection with severe acute respiratory syndrome coronavirus-2 (SARS-CoV-2), but did report that she received the Moderna (mRNA-1273) SARS-CoV-2 vaccine a few days prior to the onset of her symptoms. To our knowledge, there have been no previously reported cases of retinal detachment associated with either SARS-CoV-2 or the coronavirus disease 2019 (COVID-19) vaccine.

Case Report

Our patient was a 22-year-old woman with myopia (approximately 20/300 in either eye uncorrected) requiring corrective lens use who initially presented to a commu-

nity ED with 5 days of progressive, painless vision loss of her right eye. She endorsed a decrease of the visual field, alacrimation, and darkened vision in the affected eye with occasional flashes. She denied any other major medical history, use of contact lenses, or changes in her left eye vision. She also denied trauma, headache, chest pain, dyspnea, or other somatic pain. Of note, the patient recently received her second dose of the COVID-19 vaccine 15 days prior to her ED visit (10 days before the onset symptoms), and her first dose 44 days prior.

On examination, patient appeared well with normal vitals signs. Her pupils were equal, round, and reactive to light, with intact extraocular movements. No conjunctival changes were appreciated. Visual acuity while using her corrective lenses was 20/70 in the right eye, 20/20 in the left eye, and 20/25 with both eyes open. Remainder of her examination was unremarkable.

A limited POCUS of the eye was performed using the high-frequency linear probe to obtain sagittal and transverse views of the bilateral eyes. The posterior segment showed a single echogenic line attaching to the optic nerve, which was consistent with retinal detachment of the right eye. The community ED did not have an ophthalmologist on call, so the patient was discharged with a referral to follow-up in ophthalmology clinic in the morning.

The next morning, the community ophthalmologist evaluated the patient and diagnosed her with macula-off inferotemporal retinal detachment on the right as well as a smaller macula-on temporal retinal detachment on the left. She was sent the same day to a hospital with an on-call retinal specialist and was re-evaluated by the corresponding ED for admission. During that visit, another POCUS of the eye was performed (Figures 1 and 2), which confirmed bilateral temporal retinal detachments.

After a negative COVID-19 test, the patient was admitted, within 24 h she underwent bilateral vitrectomies with a transconjunctival pars plana approach for repairs of RRDs associated with numerous retinal tears bilaterally (Figures 3 and 4). She had follow-up visits with ophthalmology on postoperative days 1, 6, and 13, with reportedly improved field of vision and acuity in the right eye.

Discussion

In our case, the patient presented to the ED with painless vision loss in her right eye. Despite an absence of symptoms in her left eye, she was diagnosed with bilateral atraumatic RRDs (macula off in the right eye and macula on in the left), and she was referred directly for ophthalmologic evaluation. Given the time-sensitive nature of her condition, she underwent appropriate urgent surgery with improvement in her symptoms.

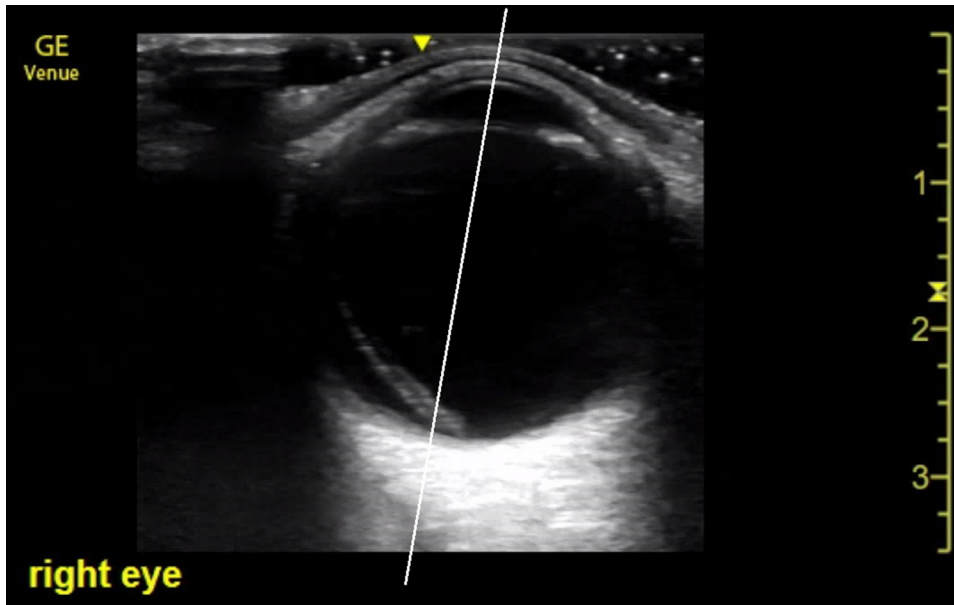


Figure 1. Ultrasound of right eye temporal retinal detachment crossing through pupillary midline (white line), detaching macula.

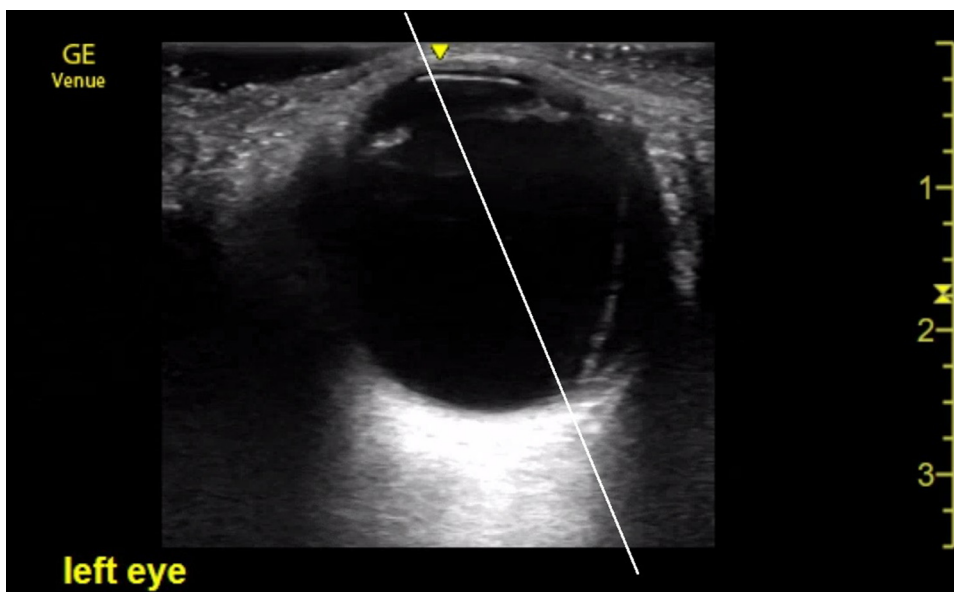


Figure 2. Ultrasound of left eye temporal retinal detachment sparing the pupillary midline (white line), with macula intact.

Aside from a myopia requiring corrective lenses, the patient had no known risk factors for retinal detachment upon presentation, including no preceding trauma, family history of retinal detachments, or other ocular conditions. The only notable event mentioned by the patient was that she had received her SARS-CoV-2 vaccine 10 days prior to the onset of her symptoms. This raised the possibility of an association between either COVID-19 or the SARS-CoV-2 vaccine and risk for ocular disease.

The Moderna (mRNA-1273) SARS-CoV-2 vaccine is formulated in lipid particles to enable the delivery of

nucleoside-modified mRNA into host cells, which subsequently express the SARS-CoV-2 *S*-antigen. Administration of the vaccine elicits an immune response to the *S*-antigen in the host, who then develops antibodies to protect against future infection by COVID-19. Known adverse effects of the COVID-19 vaccine include pain, swelling, and redness at the site of vaccine administration lasting up to an average of 2.6 and 3.2 days after first and second vaccine doses, respectively, as well as fever, fatigue, headache, chills, vomiting, arthralgias, myalgias, and urticaria, which can last on average up to 2.6 to 3.1

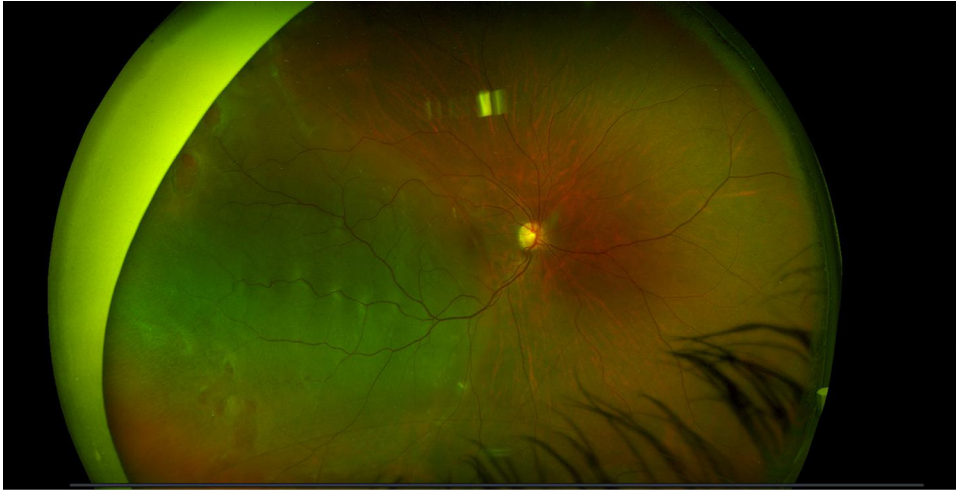

Figure 3. Funduscopy of right eye temporal retinal detachment with multiple retinal holes and detached macula.

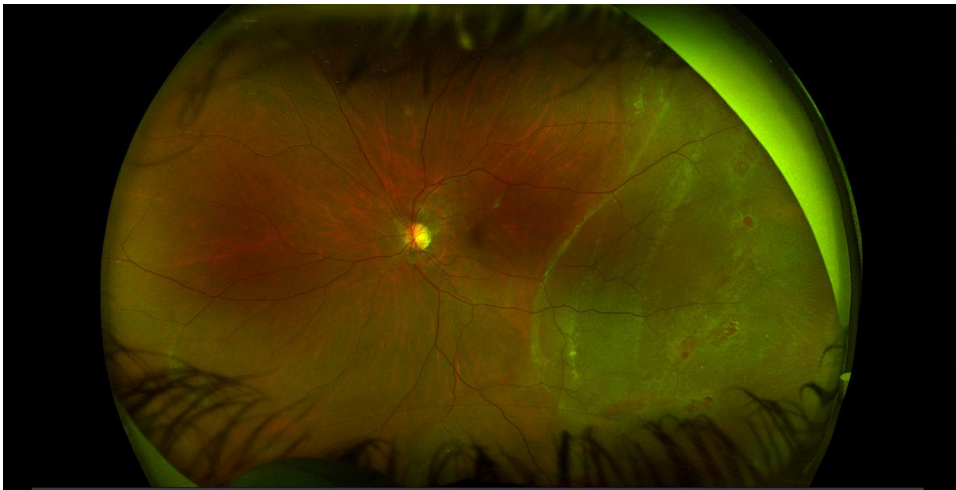

Figure 4. Funduscopy of left eye temporal retinal detachment with multiple retinal holes but intact macula.

days, respectively. Cases of facial swelling and Bell's palsy have also been reported, occurring within 28 days of vaccination (8,9). Individuals with hyaluronic acid dermal fillers have also had more pronounced delayed inflammatory responses, occurring approximately 36 h to eight days after vaccine administration (10).

However, ocular involvement or manifestations of either COVID-19 or the SARS-CoV-2 vaccine are rare in the published literature. There are known reports of transmission through the eyes and the development of follicular conjunctivitis due to infection (11). A study from Brazil also suggested that patients with severe COVID-19 may develop acute vascular lesions of the inner retina, including flame-shaped hemorrhages and cotton wool spots (12). However, neither finding was noted in our patient. Although the COVID-19 vaccines have not been associated with visual pathologies to date, all previous vaccines

have been reported to have occasional ocular manifestations, typically uveitis (13). Viral infections, such as human herpesviruses, measles, rubella, and arboviruses, are common causes of posterior uveitis specifically, which is an inflammation of the posterior uveal tract that consists of the retina and choroid. Although some viral illnesses are self-limiting, others remain latent in their hosts with the risk of reactivation. Active viral infection of the eye can progress to acute retinal necrosis, and ultimately, retinal detachment. Retinal detachment is an especially common complication among patients with uveitis (14).

Rhegmatogenous detachments, in particular, are often related to abnormally strong vitreous adhesions causing mechanical separation during posterior vitreous detachment (PVD), a process associated with aging (15). Vitreous liquefaction and PVD increase with higher grades of myopia (16). The other group of rhegmatogenous breaks

are primarily round holes associated with areas of local retinal atrophy or thinning, including lattice degeneration, as was seen with our patient. These round holes infrequently (only 1.5% of cases) develop persistent traction and lead to retinal detachments as liquified vitreous enters the subretinal space (17). Our patient's presentation with a non-PVD rhegmatogenous detachment was notable given her young age, bilateral detachments, and round hole lattice degeneration. Although data are lacking regarding the overall incidence of bilateral RRD by age group, a prospective analysis of the incidence of RRD in Scotland demonstrated non-PVD round hole detachments in only 4.9% of RRD cases over a 2-year period, with < 19% of those affected eyes having specifically lattice degeneration (18).

Why Should an Emergency Physician Be Aware of This?

Our unique case presents a possible association between the SARS-CoV-2 vaccine and the risk for retinal detachment. As more individuals are vaccinated in an effort to curb the COVID-19 pandemic, other cases may present within urgent cares and emergency departments. As case reports can only suggest an association, and not establish causality, despite our experience with this case, we agree with the Centers for Disease Control and Prevention (CDC) recommendation that the benefits outweigh the risks of vaccination and should continue to be offered to everyone who is eligible. In addition, this case emphasizes the importance of POCUS in the ED, particularly in diagnosing time-sensitive medical conditions. The timely use of ultrasound in the ED was crucial in rapidly diagnosing and expediting the treatment of our patient's disease process, and likely prevented her permanent vision loss. It is recommended that emergency physicians be well-equipped and adequately trained in ultrasonography in order to best serve the general population.

References

1. Steel D. Retinal detachment. *BMJ Clin Evid* 2014;2014:0710.

2. Jalali S. Retinal detachment. *Community Eye Health* 2003;16(46):25–6.
3. Haimann MH, Burton TC, Brown CK. Epidemiology of retinal detachment. *Arch Ophthalmol* 1982;100:289–92.
4. Krohn J, Seland JH. Simultaneous, bilateral rhegmatogenous retinal detachment. *Acta Ophthalmol Scand* 2000;78:354–8.
5. Bodanowitz S, Hesse L, Kroll P. Gleichzeitige bilaterale rhegmatogene Netzhautablösung [Simultaneous bilateral rhegmatogenous retinal detachment]. *Klin Monbl Augenheilkd* 1995;206:148–51 [in German].
6. Ross WH. Visual recovery after macula-off retinal detachment. *Eye (Lond)* 2002;16:440–6.
7. Jacobsen B, Lahham S, Lahham S, Patel A, Spann S, Fox JC. Retrospective review of ocular point-of-care ultrasound for detection of retinal detachment. *West J Emerg Med* 2016;17:196–200.
8. Meo SA, Bukhari IA, Akram J, Meo AS, Klonoff DC. COVID-19 vaccines: comparison of biological, pharmacological characteristics and adverse effects of Pfizer/BioNTech and Moderna Vaccines. *Eur Rev Med Pharmacol Sci* 2021;25:1663–9.
9. Moderna COVID-19 Vaccine. Facts sheets. COVID-19 Real Time Learning Network. Infectious Diseases Society of America. Accessed 10 March 2021. Available at: <https://www.idsociety.org/covid-19-real-time-learning-network/vaccines/moderna-covid-19-vaccine/>
10. Munavalli GG, Guthridge R, Knutsen-Larson S, Brodsky A, Matthew E, Landau M. COVID-19/SARS-CoV-2 virus spike protein-related delayed inflammatory reaction to hyaluronic acid dermal fillers: a challenging clinical conundrum in diagnosis and treatment. *Arch Dermatol Res* 2021 Feb 9:1–15.
11. Dockery DM, Rowe SG, Murphy MA, Krzystolik MG. The ocular manifestations and transmission of COVID-19: recommendations for prevention. *J Emerg Med* 2020;59:137–40.
12. Pereira LA, Soares LCM, Nascimento PA, et al. Retinal findings in hospitalised patients with severe COVID-19 [published online ahead of print October 16, 2020]. *Br J Ophthalmol* doi:10.1136/bjophthalmol-2020-317576
13. Benage M, Fraunfelder FW. Vaccine-associated uveitis. *Mo Med* 2016;113:48–52.
14. De Hoog J, Ten Berge JC, Groen F, Rothova A. Rhegmatogenous retinal detachment in uveitis. *J Ophthalmic Inflamm Infect* 2017;7:22.
15. Sebag J. Ageing of the vitreous. *Eye (Lond)* 1987;1(Pt 2):254–62.
16. Sebag J, Balazs EA. Human vitreous fibres and vitreoretinal disease. *Trans Ophthalmol Soc UK* 1985;104(Pt 2):123–8.
17. Davis MD. Natural history of asymptomatic retinal breaks. *Ophthalmology* 1982;89:1033–9.
18. Mistry D, Singh J, Yorston D, et al. The predisposing pathology and clinical characteristics in the Scottish retinal detachment study. *Ophthalmology* 2011;118:1429–34.