

UCLA

UCLA Previously Published Works

Title

Percutaneous snare retrieval of a partially embedded wallstent

Permalink

<https://escholarship.org/uc/item/39x408md>

Journal

Catheterization and Cardiovascular Interventions, 61(3)

ISSN

1522-1946

Authors

Curran, Peter J
Currier, Jesse
Tobis, Jonathan

Publication Date

2004-03-01

DOI

10.1002/ccd.10792

Copyright Information

This work is made available under the terms of a Creative Commons Attribution License, available at <https://creativecommons.org/licenses/by/4.0/>

Peer reviewed

Percutaneous Snare Retrieval of a Partially Embedded Wallstent

Peter J. Curran, MD, Jesse Currier, MD, and Jonathan Tobis,*MD

Although removal of a stent is a well described method for treating an acutely dislodged or embolized device, removal of a previously deployed stent is unusual. We describe a case where a partially dislodged wallstent in a saphenous vein graft was removed using a snare to permit deployment of a balloon mounted stent across a proximal vein graft stenosis.

Key words: snare; dislodged stent; saphenous vein graft

INTRODUCTION

Retrieval of dislodged or embolized coronary stents is a rare occurrence in interventional cardiology [1,2]. Successful methods of managing this complication include the use of snares, baskets, a second wire, and a distally placed angioplasty balloon. A distal embolization protection device has also been used for the retrieval of a dislodged stent in a saphenous vein graft [3]. All of these cases occurred after acute loss of the stent. The following unique case describes the retrieval by snare of a partially embedded but dislodged self-expanding Wallstent from a saphenous vein graft.

CASE REPORT

The patient is a 68-year-old male with aortic stenosis and coronary artery disease resulting in aortic valve replacement and coronary bypass surgery in 1987 that included a saphenous vein graft to the posterior descending artery (PDA) and sequential vein graft to the diagonal branch and left anterior descending artery (LAD). Four months prior to admission, he presented with dyspnea and pulmonary congestion. The patient underwent repeat aortic valve replacement with a 23mm Carpentier-Edwards (Edwards Lifesciences) bovine pericardium valve and also had a radial artery graft placed to the distal LAD and a new saphenous vein graft to the PDA. Two months later, he presented to a local hospital with an acute coronary syndrome. Coronary angiography showed a new 80% proximal stenosis of the vein graft to the LAD. A 4.5 mm self-expanding Magic Short Wallstent (Boston Scientific) was positioned across the stenosis. No post dilatation was performed. Two weeks later, the patient presented to this hospital with recurrent chest pain and elevated troponin of 13.6 ng/ml. Angiography revealed that the Wallstent was protruding 10 mm into the aorta and the distal end no longer covered the stenosis (Fig. 1A). The patient was considered high risk to undergo repeat bypass surgery due to two previous operations and severely decreased ejection fraction of 23%. The partially dis-lodged stent was positioned such that deployment of a new stent

coaxially, or along side of it into the graft, would be difficult. Thus, it was decided to remove the Wallstent with a snare.

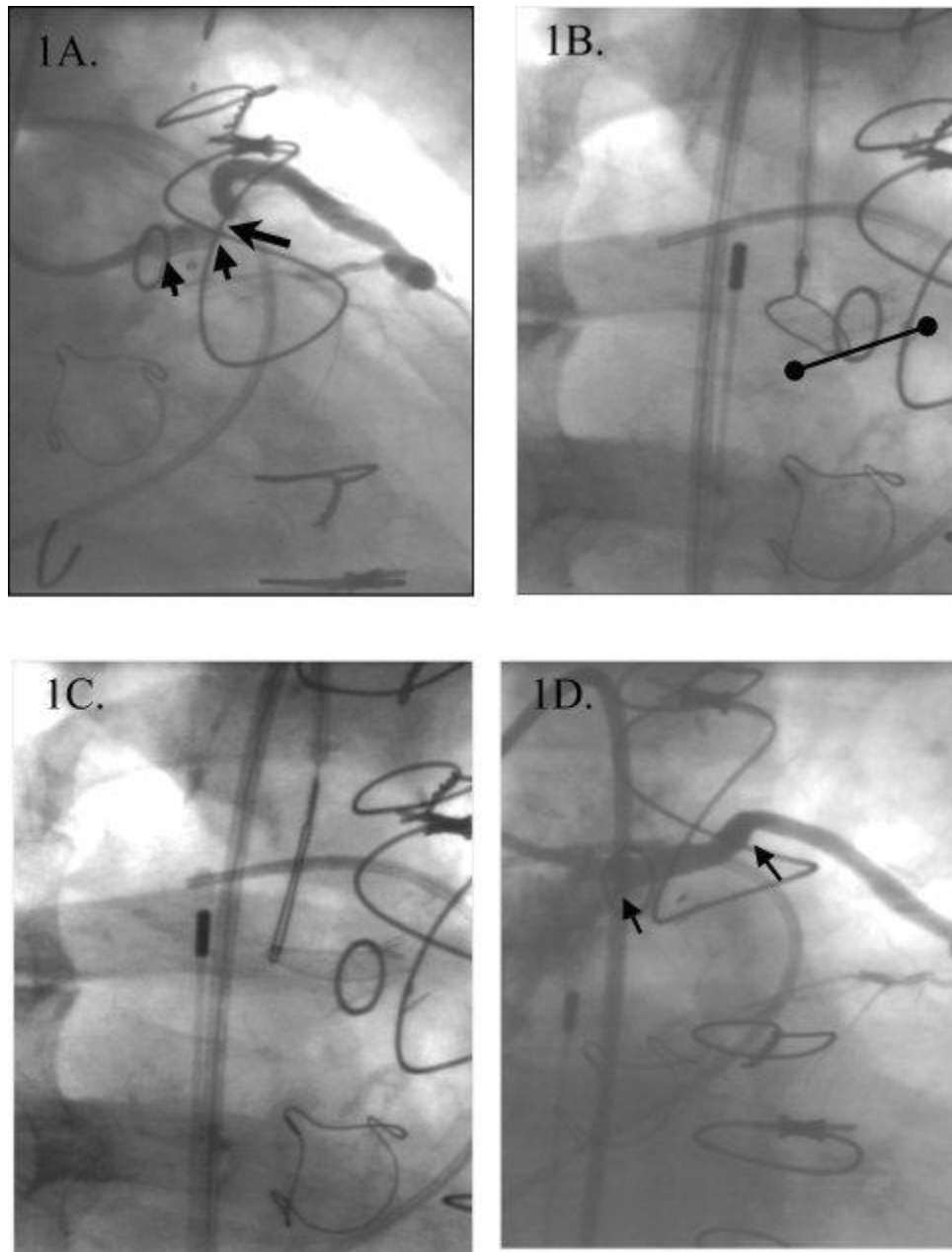


Figure 1.

A: Saphenous vein graft (SVG) to left anterior descending artery showing Wallstent (small arrows) proximal to stenosis (large arrow). Note the tapered appearance of the self-expanding stent. B: 15 mm snare encircling partially dislodged Wallstent (4.5 mm x 18 mm) protruding from proximal saphenous vein graft into aorta (black line). The circle marker on the aorta indicates the level of SVG ostium. Also visualized are the intra-aortic balloon pump catheter tip, pulmonary artery catheter, and aortic valve prosthesis. C: Wallstent snared and partially retracted into the aorta. D: Angiogram following placement of an Ultra (5.0 x 18 mm) balloon-expandable stent (arrows).

An 8 Fr multipurpose guiding catheter with a 15 mm diameter snare was positioned near the proximal end of the Wallstent protruding into the aorta from the saphenous vein graft (Fig. 1B). The flexible self-expanding stent was successfully snared and removed via the 8 Fr femoral introducing sheath without difficulty (Fig. 1C). Subsequently, a successful angioplasty was performed with deployment of an Ultra (Guidant) 5.0 X 18 mm balloon-expandable stent inflated to 16 atm and postexpanded to 20 atm (Figs. 1D and 2).




Figure 2. Wallstent attached to snare and 8 Fr multipurpose catheter.

DISCUSSION

When retrieval of a partially deployed or embolized stent is not technically feasible due to the location of the stent in the coronary or peripheral circulation, a common technique is to compress the stent against the arterial lumen with a dilation balloon or second stent [4 – 6]. In this reported case, this strategy would not be practical due to the location of the partially deployed Wallstent from the proximal anastomosis of the saphenous vein graft into the aorta. This case is also unusual in that the Wallstent had migrated from its original position. A possible explanation for this is that the self-expanding stent had not been postdilated. Additionally, during our predilation, the stenosis was noted to be rigid and consistent with fibrotic tissue, which may explain the tapering of the distal aspect of the stent and the proximal migration of the Wallstent. This proximal migration of the stent, and short time since insertion, may have contributed to the ease of removal.

REFERENCES

1. Cantor W, Lazzam C, Cohen E, et al. Failed coronary stent deployment. *Am Heart J* 1998;136:1088–1095.
2. Colombo A, Tobis JM. Retrieval techniques for lost coronary artery stents: techniques in coronary artery stenting. London: Martin Dunitz. 2000. p 278–281.
3. Webb JG, Solankhi N, Carere RG. Facilitation of stent retention and retrieval with an emboli containment device. *Catheter Cardio-vasc Interv* 2000;50:215–217.
4. Cishek MB, Laslett L, Gershony G. Balloon catheter retrieval of dislodged coronary artery stents: a novel technique. *Cathet Cardiovasc Diagn* 1995;34:350–352.
5. Rozenman Y, Burstein M, Hasin Y, Gotsman M. Retrieval of occluding unexpanded Palmaz-Schatz stent from a saphenous aorto-coronary vein graft. *Cathet Cardiovasc Diagn* 1995;34:159–161.
6. Meisel SR, DiLeo J, Rajakaruna M, Pace B, Frankel R, Shani J. A technique to retrieve stents dislodged in the coronary artery followed by fixation in the iliac artery by means of balloon angioplasty and peripheral stent deployment. *Catheter Cardiovasc Interv* 2000;49:77–81.

Division of Cardiology, University of California at Los Angeles, Los Angeles, California

*Correspondence to: Dr. Jonathan Tobis, Division of Cardiology, University of California at Los Angeles, 47-123 Center for Health Sciences, 10883 Le Conte Avenue, Los Angeles, CA 90095. E-mail: jtobis@mednet.ucla.edu

Received 6 August 2003; Revision accepted 25 October 2003

DOI 10.1002/ccd.10792

Published online in Wiley InterScience (www.interscience.wiley.com).