

# UC Irvine

## UC Irvine Previously Published Works

### Title

Facet Joints of the Spine: Structure-Function Relationships, Problems and Treatments, and the Potential for Regeneration

### Permalink

<https://escholarship.org/uc/item/39r740g7>

### Journal

Annual Review of Biomedical Engineering, 20(1)

### ISSN

1523-9829

### Authors

O'Leary, Siobhan A  
Paschos, Nikolaos K  
Link, Jarrett M  
[et al.](#)

### Publication Date

2018-06-04

### DOI

10.1146/annurev-bioeng-062117-120924

Peer reviewed



*Annual Review of Biomedical Engineering*  
Facet Joints of the Spine:  
Structure–Function  
Relationships, Problems and  
Treatments, and the Potential  
for Regeneration

Siobhan A. O’Leary,<sup>1</sup> Nikolaos K. Paschos,<sup>2</sup>  
Jarrett M. Link,<sup>3</sup> Eric O. Klineberg,<sup>4</sup> Jerry C. Hu,<sup>3</sup>  
and Kyriacos A. Athanasiou<sup>3</sup>

<sup>1</sup>Department of Biomedical Engineering, University of California, Davis, California 95616, USA

<sup>2</sup>Department of Orthopedic Surgery, Division of Sports Medicine, Boston Children’s Hospital, Harvard Medical School, Massachusetts 02115, USA

<sup>3</sup>Department of Biomedical Engineering, University of California, Irvine, California 92617, USA; email: athens@uci.edu

<sup>4</sup>Department of Orthopaedic Surgery, University of California, Davis, Sacramento, California 95816, USA

Annu. Rev. Biomed. Eng. 2018. 20:145–70

The *Annual Review of Biomedical Engineering* is online at [bioeng.annualreviews.org](http://bioeng.annualreviews.org)

<https://doi.org/10.1146/annurev-bioeng-062117-120924>

Copyright © 2018 by Annual Reviews.  
All rights reserved

### Keywords

facet joint, zygapophyseal joint, osteoarthritis, tissue engineering, spinal stenosis, biomechanics

### Abstract

The zygapophyseal joint, a diarthrodial joint commonly referred to as the facet joint, plays a pivotal role in back pain, a condition that has been a leading cause of global disability since 1990. Along with the intervertebral disc, the facet joint supports spinal motion and aids in spinal stability. Highly susceptible to early development of osteoarthritis, the facet is responsible for a significant amount of pain in the low-back, mid-back, and neck regions. Current noninvasive treatments cannot offer long-term pain relief, while invasive treatments can relieve pain but fail to preserve joint functionality. This review presents an overview of the facet in terms of its anatomy, functional properties, problems, and current management strategies. Furthermore, this review introduces the potential for regeneration of the facet and particular engineering strategies that could be employed as a long-term treatment.



## Contents

1. INTRODUCTION .....	146
2. FACET JOINT ANATOMY AND BIOMECHANICS .....	147
2.1. Articular Processes .....	148
2.2. Articular Cartilage .....	149
2.3. Synovium, Synovial Fold, and Fibrous Capsule .....	149
2.4. Nerve Endings .....	150
2.5. Role of the Facet Joint in Spine Biomechanics .....	150
2.6. Biomechanical Alterations Postdegeneration and Surgical Intervention .....	150
3. PAIN AND PATHOLOGY ASSOCIATED WITH THE FACET JOINT .....	151
3.1. Facet Joint Injury .....	151
3.2. Facet Joint Pain .....	151
3.3. Facet Joint Degeneration .....	153
3.4. The Relationship Between the Facet Joint and Intervertebral Disc Degeneration .....	153
3.5. Comorbidities .....	154
4. MANAGEMENT OF BACK PAIN RELATED TO FACET JOINT PATHOLOGY .....	154
4.1. Conservative Management .....	154
4.2. Operative Management .....	156
5. FUTURE DIRECTIONS: COULD TISSUE ENGINEERING PROVIDE A NEW TREATMENT STRATEGY FOR FACET-RELATED MORBIDITY? ..	158
5.1. Key Criteria to Engineer Facet Cartilage .....	159
5.2. Potential Strategies to Engineer Facet Cartilage .....	160
5.3. Key Criteria for an Engineered Total Facet Joint .....	162
5.4. Envisioning an Engineered Total Facet Joint .....	162
6. CONCLUSION .....	163

## 1. INTRODUCTION

The highly innervated, diarthrodial zygapophysial joint, or the facet joint, is located at either side of the posterior vertebral body. The facet joint's opposing bony surfaces are covered by a layer of hyaline articular cartilage, and the joint is encapsulated by the synovium and fibrous capsule. This joint can have meniscus-like structures that improve joint congruency. Facet joints work in pairs, along with the intervertebral disc (IVD), to constrain the motion of the vertebrae while aiding in the transmission of spinal loads (1).

The facet joint is frequently dislocated or fractured due to motor vehicle- or sports-related trauma (2–4). These events impair normal spine function, cause pain, and can potentially lead to varying degrees of degeneration within the facet joint. Whether induced by trauma or age-related changes, facet joint degeneration, which has been implicated as a possible cause of pain, is prevalent. Facet degeneration may develop in patients as young as 15 years old (5); almost two-thirds of people are affected to some degree by the time they reach the age of 30 years (6). Severe and potentially symptomatic lumbar osteoarthritis (OA) usually affects the elderly population (7). Not all cases of facet degeneration result in patient pain; however, advanced OA, concomitant hypertrophy of the facet, and IVD degeneration all contribute to spinal canal nerve impingement



in symptomatic spinal stenosis (8), the most common reason for lumbar surgery in the United States (9). These pathological conditions also play a role in other back-related morbidities such as spondylolisthesis (10) and scoliosis (11).

The facet joint is severely understudied. Consequently, the mechanism of facet joint pain and its relationship to degeneration are not fully understood and often debated; however, the facet joint is increasingly being recognized as a source of back pain. Low-back pain is common, affecting ~59.1 million people in the United States (12). In 2011, 28.9% of all US adults experienced low-back pain, and 15.5% suffered from neck pain (13). Back pain burdens both the nation's health and health care system at a total cost of \$100–200 billion per year, rivaling heart disease, diabetes, and cancer as the nation's top health concerns (14, 15). The developing recognition of the facet joint's contribution to back pain is reflected in the dramatic increase of facet joint interventions in recent years (e.g., during 2000–2011, there was an increase of 308% per 100,000 Medicare beneficiaries) (16). Although diagnosing facet joint pain is difficult, it is estimated to be responsible for 16–40% (17–23), 34–48% (20–22), and 39–67% (21, 22, 24) of pain felt in the low-back, mid-back, and neck regions, respectively. Thus, the facet joint is the locus of highly significant pathology.

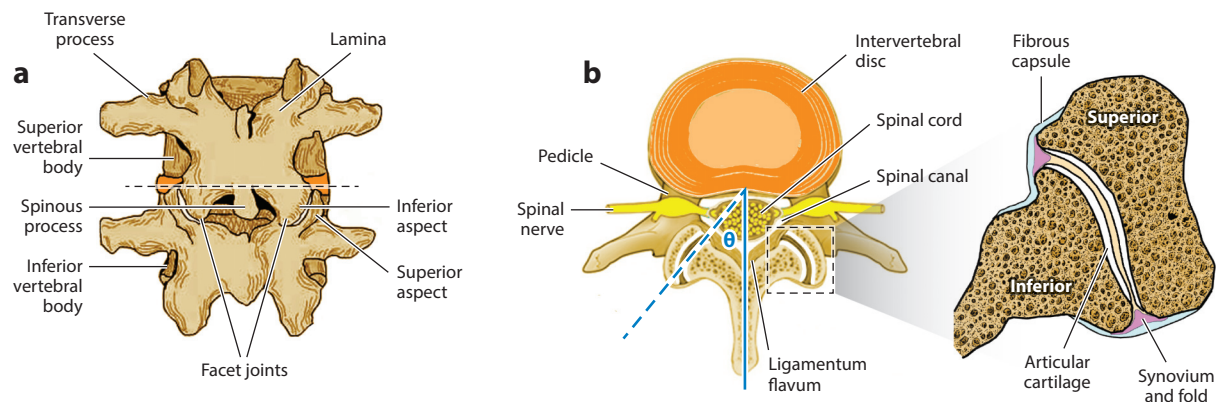
Conservative pain-relieving facet joint treatments such as intraarticular injections, medial branch blocks, and radio-frequency denervation offer only short-term pain relief and aim to relieve symptoms rather than to treat underlying mechanisms or damaged tissues (25). Invasive surgical options for stenosis, spondylolisthesis, and scoliosis often require removal of the facet joints to reduce pain. However, such procedures are commonly accompanied by spinal fusion, known to induce adjacent segment disease (26, 27), as well as complete immobilization of the fused spinal segments. Thus, there is a need to develop a surgical option for pain management that does not compromise the function of the treated facet or the integrity of adjacent facets. To that end, researchers and clinicians alike are seeking new treatment modalities for this troubled joint. For instance, metallic prostheses are currently in clinical trials (28). However, due to their inability to recapitulate healthy spine biomechanics and kinematics, prostheses and other therapies in the clinic often fall short of providing a durable, motion-preserving solution. In light of these shortcomings, tissue engineering of a biomimetic facet joint may serve as an attractive solution for motion preservation and long-term pain management since it would recreate the characteristics of a healthy spine.

This article presents an overview of the facet joint in terms of its anatomy, functional properties, problems, and current treatment and management strategies. Discussion of the diagnosis of facet joint pain, a controversial issue, can be found elsewhere (29, 30). To provide context to a more extensively characterized joint, this review compares the facet joint with the knee. This review aims to discuss, for the first time, how tissue engineering may be a viable option for treating the facet joint.

## 2. FACET JOINT ANATOMY AND BIOMECHANICS

Together, the IVD and the facet joints, known as the three-joint complex, connect adjacent vertebrae, stabilize the spine, and facilitate articulation (31). Primary constituents of the facet joint include the subchondral bone, articular cartilage, synovium, and fibrous capsule. These joints are densely innervated, actively supporting motor function and transmission of pain. Because the spine's biomechanics are regionally dependent, the facet orientation relative to the sagittal and transverse planes and shape of the articulating surface vary, both among and within the cervical, thoracic, and lumbar spinal regions (32–34). Furthermore, variation in facet joint structure and number can be observed across species (35). Altogether, these anatomical components form a joint that bears nontrivial loads when the spine experiences compression, flexion, extension, and/or torsion.





**Figure 1**

Facet joint anatomy. (a) Posterior view of the motion segment. (b) Axial view of the motion segment and a closer look (right) at the facet joint and its individual components. Sagittal orientation angle ( $\theta$ ) refers to the facet joint’s orientation with reference to the sagittal plane.

### 2.1. Articular Processes

The inferior aspect of the facet joint extends from the lamina of the superior vertebral body and meets the superior aspect of the facet joint extending from the inferior vertebral body (Figure 1a). Relative to the sagittal plane, the orientation of the articular surfaces (angle  $\theta$ ), for which these protrusions provide support, changes from one spinal level to the next (Figure 1b) (Table 1). The largely sagittal orientation of the lumbar facet joint, in combination with the high degree of mutual convexity and concavity of the opposing joint surfaces in this region, enables a greater range of motion in terms of flexion, as well as higher resistance to axial rotation (36). Furthermore, the smaller inclination angle (see Table 1 for definition and data) of the lumbar facets provides increased protection against forward displacement of the spinal segment. In the cervical and

**Table 1** Structural and functional properties of the human facet joint

	Cervical	Thoracic	Lumbar	References
Surface area	0.80–1.07 cm <sup>2</sup>	0.69–1.15 cm <sup>2</sup>	0.97–2.12 cm <sup>2</sup>	161
Sagittal orientation angle <sup>a</sup>	70–96°	93–110°	27–46°	32, 33
Inclination angle <sup>b</sup>	31–59°	62–78°	71–86°	161
Range of motion per motion segment	Flexion/extension: 8–17° Lateral bending: 4–11° Axial rotation: 8–12°	Flexion/extension <sup>c</sup> : ~1–4° Lateral bending <sup>d</sup> : 6–9° Axial rotation <sup>d</sup> : 2–9°	Flexion/extension <sup>c</sup> : 12–20° Lateral bending: 3–8° Axial rotation: 2–5°	162, 163
Contact forces on facet surfaces	Flexion/extension: 17–27 N Lateral bending: 17–40 N Axial rotation: 26–30 N	No data	Flexion/extension: 46–109 N Lateral bending: 10–75 N Axial rotation: 56–120 N	164–167

<sup>a</sup>The sagittal orientation angle is depicted in Figure 1.

<sup>b</sup>The inclination angle is defined as the angle between the transverse plane and the best-fit plane between the articulating surfaces of the facet.

<sup>c</sup>The range presented here is a sum of the degree of flexion and extension.

<sup>d</sup>Rib cages were removed from thoracic spines before range-of-motion testing.



thoracic regions, a less sagittal orientation of the joint, a greater inclination angle, and roughly planar articular surfaces facilitate a greater range of both axial rotation and lateral bending in comparison to the lumbar region, especially at C5 and C6 (32). In general, the shape and orientation of the articular processes of the facet joint at each spinal level serve to modulate range of motion and effectively bear loads to maintain spinal function.

Given that researchers often use large-animal models for facet joint research, it is important to note that differences exist in facet joint structure and biomechanics between humans and other species. All commonly used large-animal models are quadrupedal, leading to marked differences in facet joint size and shape (37). Additionally, the number of facet joints changes from species to species because the sum of functional spinal units varies from species to species. These differences yield loading patterns different from those in bipedal humans, which may limit the applicability of quadrupedal animal models.

## 2.2. Articular Cartilage

Articular cartilage, covering the surfaces of the inferior and superior subchondral bone protrusions, enables low-friction movement and experiences tensile, compressive, and shear loads (38). Unlike cartilages of other joints, the cartilage of human facet joints is not well characterized. The histological, mechanical, and biochemical characteristics of lumbar facet joint cartilage of the minipig, monkey, and rabbit have recently been reported (37). Like articular cartilage found elsewhere, facet joint cartilage is organized into superficial, middle, and deep zones. In the superficial zone, collagen fibers are oriented tangential to the joint surface, and chondrocytes appear flattened; in the middle (or transitional) zone, collagen fibers are arranged in a more isotropic fashion, and chondrocytes increase in number and roundness; in the deep zone, both the collagen and chondrocytes are oriented perpendicular to the joint surface. Facet joint cartilage's aggregate modulus is similar across species, between opposing surfaces of the joint (i.e., inferior and superior), and across lumbar spinal levels. The average values for the aggregate modulus range from 0.159 to 0.174 MPa, and the thickness ranges from 290 to 370  $\mu\text{m}$ . Similarly, the glycosaminoglycan (GAG), collagen, and DNA contents of the minipig and rabbit cartilage are comparable between joint surfaces and spinal levels ranging from 2.4% to 4.2%, from 15.77% to 16.62%, and from 0.029% to 0.034% per wet weight, respectively. A separate study reported that in canine L3–L4 and L4–L5 superior facet joint cartilage, the tensile modulus and aggregate modulus are  $10.08 \pm 8.07$  MPa and  $0.55 \pm 0.13$  MPa, respectively (38). Additionally, the compressive Young's modulus of ovine cervical facet joint cartilage was found to be  $0.76 \pm 0.35$  MPa (39), and the compressive stiffness of equine cervical facet joint cartilage was found to be  $\sim 0.118$  MPa (S.A. O'Leary, J.L. White, J.C. Hu & K.A. Athansiou, unpublished data). Aside from animal data, a comprehensive description of normal human facet joint cartilage of the lumbar, thoracic, or cervical region has yet to be reported. Performing these characterizations in humans will aid in the selection of an appropriate animal model for facet joint research.

## 2.3. Synovium, Synovial Fold, and Fibrous Capsule

The synovium, synovial folds, and fibrous capsule enclose the facet joint space and play a biomechanical role. The synovium directly surrounds the facet joint, while the synovial fold—sometimes termed a meniscoid—folds into the area between the inferior and superior facet (40). Cervical synovial folds comprise fibrous, adipose, or fibroadipose tissue. The synovium prevents synovial fluid from escaping; the synovial fold increases surface contact area, improving joint congruence. Within the cervical spine, posterior synovial folds protrude into the joint space by a median of



2.81 mm, whereas anterior synovial folds extend by a median of 3.52 mm (40). Superposed to the synovium, the fibrous capsule is composed of ligamentous tissue and completely surrounds the joint (41). It regulates the internal environment of the facet in terms of nutrients and immune cells. Furthermore, in conjunction with the ligamentum flavum (ligaments that connect to the lamina of adjacent vertebrae), the fibrous capsule provides mechanical stability to ensure that opposing facet surfaces remain close to one another (**Figure 1b**). In the lumbar spine, the fibrous capsule tensile strength parallel and perpendicular to the axis of collagen fiber orientation is 1.90 MPa and 0.95 MPa, respectively (41). The complex modulus of elasticity parallel to collagen fiber orientation is 1.63 MPa; perpendicular to collagen fiber orientation, the viscous and elastic secant moduli are 1.81 and 1.00 MPa, respectively (41). Altogether, the synovium, synovial fold, and fibrous capsule preserve and augment the mechanical function of the underlying articular cartilage, and thus must be considered when addressing any aspect of the facet joint for the purposes of basic research or therapy development.

#### 2.4. Nerve Endings

Whereas the articular cartilage of the facet joint is aneural, the subchondral bone, synovium, synovial folds, and joint capsule are innervated extensively (42). These nerve endings, which form part of the medial branch emanating from the dorsal ramus, are involved in pain sensation and proprioception (43). The medial branch is particularly important because it is responsible for sensory input from the midline of the spine to the facet joint line (43). As such, many facet joint diagnostics and interventions rely on mitigating pain by blocking medial branch nervous signals (discussed in Section 4.1.1).

#### 2.5. Role of the Facet Joint in Spine Biomechanics

Biomechanically, the facet joint, together with the IVD and spinal ligaments, bears some of the compressive load in the spine and inhibits excessive flexion, translation, and torsion that could lead to pathological conditions. In the lumbar spine, *in vitro* studies have shown that the facet articular surface alone bears 6–30% of axial compressive loads, depending on the mode of spinal motion (44). The cervical and upper thoracic facet joints transmit 23% of axial compressive loads (45). Note that loads in the cervical spine are smaller than those in the lumbar spine (**Table 1**) (44, 45). The loading profile changes from level to level according to the curvature of the spine and the geometry of the individual facet joints, making generalizations about the biomechanics of the facet joint difficult (31). As shown by measurements of the effects of facetectomy, the facet joint ensures that the spinal column resists joint distraction, shear forces, and lateral or anteroposterior translation and imparts sufficient torsional stiffness (31). For example, joint distraction increased under the same tensile load following facetectomy (46). When combined with other loading types, such as flexion, the risk of joint distraction and subsequent trauma can increase further (46). Thus, biomechanically competent facet joints preserve normal spinal motion and mitigate potential trauma or degeneration.

#### 2.6. Biomechanical Alterations Postdegeneration and Surgical Intervention

Facet joint biomechanics change significantly because of tissue degeneration and spinal surgical intervention. For example, degeneration of the IVD, as part of the three-joint complex, is expected to affect the facet. Similarly, degeneration of the facet joint can lead to a compromised IVD (6). Disc degeneration has been associated with an increased range of motion in the lumbar





facet joints, which could lead to increased compressive stress and promote cartilage degeneration (47). Disc narrowing also increases axial compressive loads in the lumbar facet surface by 70%, far exceeding normal load-bearing capacity (48). Disc replacement has been employed to treat disc degeneration; however, this procedure may also result in kinematic and biomechanical changes that could have adverse effects on the facet. The effects of a disc implant at the L5–S1 spine segment were assessed in a finite-element model of the lumbar spine. Depending on the anteroposterior location of the implant, the sum of flexion and extension range of motion can vary from 11.5° to 15°, demonstrating that the range of motion depends on where the surgeon places the implant (49). Furthermore, under lateral bending on the ipsilateral side, lumbar facet joint forces as a function of cranial/caudal implant location can range from 70 to 115 N, possibly leading to disruption of articular cartilage homeostasis (49). Another study concluded that, after cervical disc replacement, the range of motion in the associated facet joints increased from  $9.6^\circ \pm 5.1^\circ$  to  $16.2^\circ \pm 3.6^\circ$  postimplantation (50). Interestingly, in the same study, facet contact pressures in extension or flexion did not change significantly (50). Despite conflicting results based on experimental methods, patient population, or intervention type, degeneration and surgical intervention often lead to deviations from the biomechanics observed in a healthy, intact facet joint. Generally, in cases of advanced, extensive degeneration, all affected tissues—for instance, both the IVD and the facet joint—must be treated to restore the joint to a healthy state.

### 3. PAIN AND PATHOLOGY ASSOCIATED WITH THE FACET JOINT

#### 3.1. Facet Joint Injury

The facet joint is a common site of traumatic injury. It is estimated to sustain damage in 70% of all subaxial cervical spine injuries (**Figure 2d**) (51). Damage to the cervical spine usually occurs because of single or combined abnormal movements (i.e., flexion, extension, rotation, lateral bending, and compression) primarily due to motor (52) or sports-related accidents (52, 53). Trauma to the cervical spine encompasses a wide spectrum of injuries, ranging from displaced and nondisplaced fractures to subluxed, perched, locked, or dislocated facets, and can be unilateral or bilateral in nature (4, 54). The facet capsule, ligamentum flavum, and disc are the most frequently cited areas of soft tissue disruption by these injuries (55–57). Cervical injuries most frequently occur at levels C5–C6 and C6–C7 (2) and are more common among males (52, 58), people 15–45 years old, and people older than 65 (52, 58). Although the cervical levels are particularly vulnerable, the facet joint is also involved in 22.5% of all of injuries related to the thoracic and lumbar levels (59).

#### 3.2. Facet Joint Pain

Aside from facet-related trauma, where imaging is primarily used as the diagnostic tool, the diagnosis of facetogenic pain is difficult and remains a significant source of controversy within the field (29, 30). Currently, the use of repeated nerve blocks as a diagnostic tool is the most validated approach (60). Use of this tool reveals that the incidence rate of facet pain in people without evidence of disc herniation, radiculitis, or sacroiliac joint arthritis is 16–40% (17, 19–23, 61), 39–67% (20–22), and 34–48% (21, 22, 24) in cases of chronic low-back pain, cervical pain, and thoracic pain, respectively. In these cases, repeated nerve blocks elicited pain relief response of at least 80%. The prevalence of lumbar facet joint pain also increases with age (62). The facet is considered a source of back and neck pain inasmuch as pain can be removed by treating the facet joint alone.

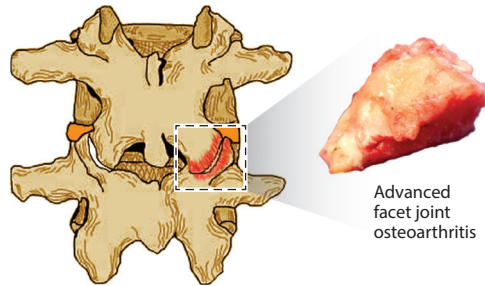




**Figure 2**

Common facet-related problems, including (a) osteoarthritis, (b) spinal stenosis, (c) degenerative spondylolisthesis, and (d) trauma, as well as the associated causes, risk factors, and potential outcome.

**a Osteoarthritis**



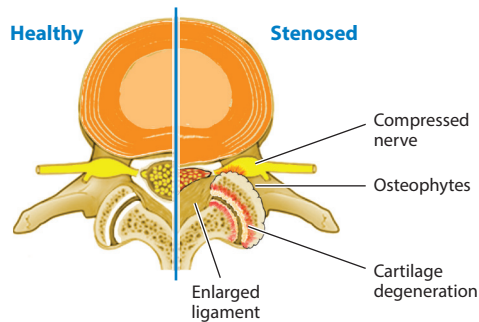
**Main causes/risk factors**

- Biomechanical loading
- Increase in severity with age
- Disc degeneration
- Genetics

**Outcome**

- Cartilage lesions and thinning
- Subchondral bone sclerosis
- Synovial and subchondral bone cysts
- Osteophytes and hypertrophy
- Back pain

**b Spinal stenosis**



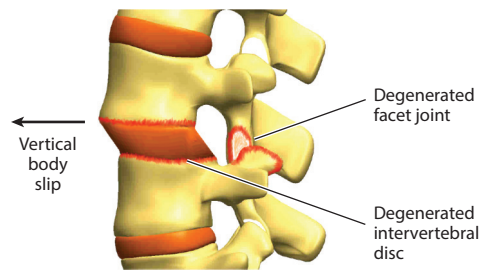
**Main causes/risk factors**

- Hypertrophic spinal elements
- Advanced facet hypertrophy
- Development of facet osteophytes
- Facet joint inflammation

**Outcome**

- Reduced spinal canal dimensions
- Compressed neural elements
- Neurogenic claudication
- Leg pain

**c Degenerative spondylolisthesis**



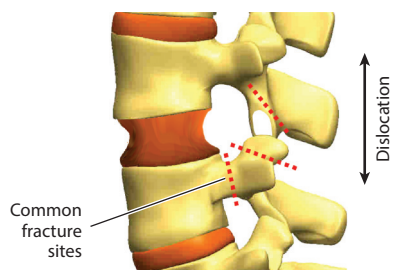
**Main causes/risk factors**

- Degeneration of facet joints/disc
- Facet orientation/tropism

**Outcome**

- Translation of one vertebra in relation to another
- Vertebral body spur formation
- Sclerosis of cartilaginous end plate
- Hypertrophy and ossification of ligaments
- Further degeneration of the facet joint
- Back and neurologic pain

**d Trauma**



**Main cause/risk factor**

- Abnormal motion of spine due to trauma

**Outcome**

- Subluxation
- Dislocation
- Fracture
- Damaged facet capsule/disc/ligaments/cartilage
- Spinal instability
- Neurologic injury
- Back and/or neck pain

### 3.3. Facet Joint Degeneration

OA of the facet joint is a progressive degenerative disease (**Figure 2a**). The development of OA usually begins with changes in articular cartilage and spreads to the synovium, capsule, subchondral bone, ligaments, and musculature, leading to failure of the entire joint (63, 64). In advanced stages, degeneration is usually not limited to specific sites and tends to affect the entire cartilage surface (37). There is no consensus on whether the inferior or superior surface is more disease prone. Typical radiographic features of OA include joint space narrowing from cartilage thinning, osteophytes, subchondral cysts, articular process hypertrophy, and subchondral bone sclerosis (65).

Facet OA occurs frequently. According to a cadaveric study based on the presence of osteophytes in the lumbar facets, OA (ranging from mild to severe) is a universal finding in adults older than 60 years, and severity increases with age (6). A computed tomography (CT)-based study of people with a mean age of 67 years found severe lumbar facet OA in 54% of patients (7). Prevalence may vary by ethnicity; a recent CT-based study of the lumbar spine of Korean patients reported a prevalence as low as ~18% (66). Lumbar facet degeneration is most commonly found at L4–L5 and L5–S1; however, all lumbar levels are considered susceptible (6, 66–69). OA's prevalence is strongly associated with increasing age, bone mass index (70, 71), and a more sagittal orientation of the joint (72–74); whether the last of these is a result or cause of degeneration is unknown. Regarding the cervical facet joint, the severity of degeneration increases with age (75, 76), is slightly more common in men (75, 76), and typically manifests at C2–C3, C3–C4, and C4–C5 (75, 77, 78). Population-based assessments of the prevalence of OA in the thoracic spine appear to be lacking.

Despite the reported prevalence of facet degeneration, the relationship between facet degeneration and back pain is unclear. It is often assumed that facet degeneration is the source of back pain; however, there is little evidence to support such a general claim. For example, in two CT-based studies performed by the same authors, facet degeneration was reported to be between 60% and 70%, but an association between degeneration and low back pain could not be established (65, 79). By contrast, more recent CT-based studies have concluded that severe degeneration is associated with back pain in older adults and that degeneration at spinal levels L4–L5 and L5–S1 correlates with back pain among women (80, 81). Establishing a distinct relationship between joint degeneration and pain has always been challenging, and similar inconsistencies can be found within the context of other osteoarthritic joints within the body, for example, the knee. Possible reasons for this have been attributed mainly to the lack of specificity of degeneration on current imaging techniques and the use of unreliable and underdeveloped grading scales. Although the specificity of diagnostic tools can be improved when detecting facet degeneration, it is important to note that facet degeneration should not be considered synonymous with back pain.

### 3.4. The Relationship Between the Facet Joint and Intervertebral Disc Degeneration

OA of the facet joint is strongly associated with degeneration of the IVD due to their intrinsically linked biomechanics. This relationship was originally described as a cascade of degenerative events initiated either by the facet joints or by the disc (82). It is believed that facet degeneration usually follows disc degeneration, with facet overloading resulting from disc incompetence (67, 69). However, this sequence has been challenged by studies that have found facet joint OA in the absence of disc degeneration (70, 83). For example, one magnetic resonance imaging (MRI)-based study reported that 22% of individuals, recruited as part of the Framingham Heart Study, had facet joint OA without disc degeneration, occurring most frequently at levels L4–L5 and L5–S1 (70). Although this study did not find an association between age and facet joint OA in the absence



of disc degeneration, an earlier, cadaveric study found facet OA without disc degeneration to be common among individuals younger than 30 years (83).

Methods used in studies that examine associations between IVD degeneration and facet OA have been subject to criticism. It has been suggested that studies reporting facet joint OA only in the company of disc degeneration may contain population bias because all study participants had low-back pain and, thus, were not representative of the general population (70). The ability of current imaging techniques to detect early OA changes in the facet joint has been questioned; such changes may be underreported (84). A cadaveric study of facet joint OA in association with disc degeneration noted that mild OA occurred in subjects as young as 15 years old (85), suggesting higher prevalence in adults if modalities other than current imaging techniques are employed. To date, all studies assessing the relationship between disc degeneration and facet joint OA are cross-sectional in design; therefore, an assessment of a causal relationship between them is difficult despite the observation of a strong relation between the two.

Ironically, surgical treatments of degenerated discs can encourage facet OA progression. Despite the popularity of spinal fusion for treating a plethora of pathologies, this technique can induce adjacent segment disease (ASD). ASD describes degeneration of motion segments adjacent to the treated level, including the development of facet OA (27, 86). The reported annual incidence of symptomatic ASD in the cervical and lumbar spine is 2.9% (87) and 2.5% (26), respectively, and it has a 10-year prevalence rate of 22.2% and 19.2%. Disc arthroplasty was introduced to preserve motion and to prevent ASD. However, disc prosthesis surgery accelerates the rate of facet OA at the index level (88), and the incidence of ASD has not changed substantially (88, 89). In this respect, there is insufficient evidence to support disc arthroplasty as being superior to fusion. Despite surgical advancements, current treatments may continue to adversely affect the facet.

### 3.5. Comorbidities

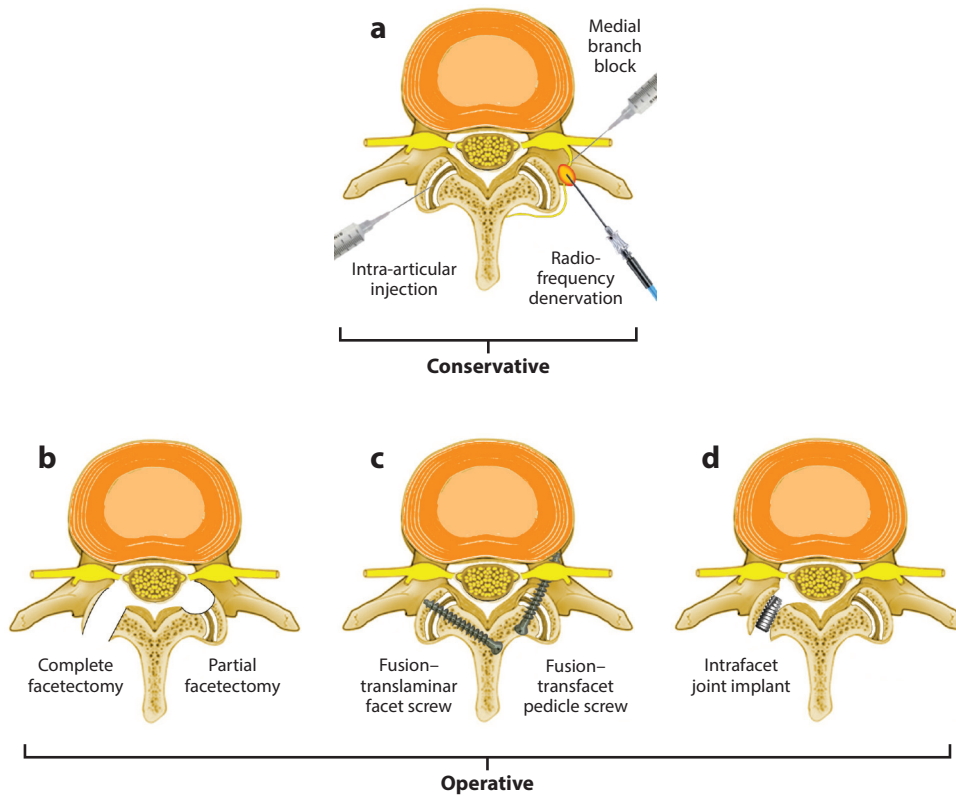
Degeneration of the facet joint plays a significant role in other back-related morbidities, such as degenerative spinal stenosis, spondylolisthesis, and scoliosis. Spinal stenosis usually develops later in life and is the most frequently cited reason for lumbar spine surgery in the United States and some European countries (**Figure 2b**) (9, 90–92). Advancement of degenerative spinal stenosis and progression of facet joint hypertrophy with subsequent development of osteophytes can compress the spinal neural elements, leading to neurogenic intermittent claudication (8, 93, 94). Degenerative spondylolisthesis (**Figure 2c**) occurs in ~14% of adults (95), whereas scoliosis affects 2–32% of adults (96, 97) and 60% of the elderly population (11). Although the involvement of facet pathology in degenerative spondylolisthesis and scoliosis is not fully understood, facet degeneration and its contribution to spinal instability are thought to be associated with these conditions (96, 98–101). Additional studies to understand facet joint structure–function relationships may further elucidate our understanding of the facet’s role in these conditions.

## 4. MANAGEMENT OF BACK PAIN RELATED TO FACET JOINT PATHOLOGY

### 4.1. Conservative Management

When physical therapy or analgesics fail to resolve facet-related pain, additional conservative interventions are considered. Such interventions include medial branch blocks, intra-articular injections, and radio-frequency denervation.





**Figure 3**

Conservative and operative management strategies for facet joint pathologies, including (a) injections, (b) facetectomies, (c) fusion systems, and (d) implants.

**4.1.1. Medial branch blocks.** Medial branch block injections, also known as nerve blocks, are typically used to diagnose facetogenic pain (Figure 3a). Their usefulness in the treatment of facet-related pain has also been investigated, although their effectiveness in providing pain relief is a topic of debate (29). Injections targeting the medial branch nerve interrupt pain signal transmission. Some studies report greater than 50% pain relief in ~85% of patients after lumbar facet joint nerve blocks (102, 103), whereas other studies report 50% pain relief after a single or double nerve block in 40–58% of patients (104, 105). The duration of these interventions is temporary, as they remain effective in fewer than 10% of patients after 1 year (106). Medial branch blocks are typically indicated only for diagnostic purposes; additional data would be useful to evaluate their therapeutic effectiveness.

**4.1.2. Intra-articular injections (or facet block injections).** Intra-articular facet injections (Figure 3a), typically consisting of anesthetics and corticosteroids (107), have been evaluated for their potential effectiveness in mitigating facetogenic pain. The effectiveness of these injections has become a subject of controversy. Most systematic reviews and high-level randomized control trials conclude that there is no benefit in pain and functional status from intra-articular injection compared with placebo (108–111). The use of ultrasonography to accurately guide injections has recently become more popular than fluoroscopy, as ultrasonography appears to be more effective

(112). However, any potential positive effect of these injections is considered temporary and requires multiple subsequent injections to maintain relief. Thus, currently there is not enough evidence to recommend their use for the treatment of facetogenic pain.

**4.1.3. Radio-frequency denervation of the facet joint.** Radio-frequency denervation is considered the most successful treatment approach for chronic facetogenic pain (**Figure 3a**) (107). Briefly, this technique uses radio-frequency energy, delivered percutaneously, to heat and temporarily damage medial branch fibers, preventing the transmission of pain signals originating from the facet (113). When compared with placebo, radio-frequency denervation provided improved back motion, pain relief, and functional outcomes over a 1- to 6-month period (114–116). However, several studies found no difference in pain relief between this technique and a sham treatment. Reasons cited for studies that do not find a significant association between pain relief and radio-frequency often include the use of inconsistent criteria for patient selection as well as differences in the positioning of the electrodes (117, 118). These results imply that the efficacy of radio-frequency denervation may be adversely affected by patient- and technique-specific factors (29). In general, radio-frequency denervation is widely accepted as the most effective intervention for facetogenic pain; however, most reports emphasize that pain relief from this technique is temporary (29, 116, 119).

## 4.2. Operative Management

If conservative management fails, operative management can be considered, including facet joint excision as well as fusion and replacement systems. An increasing number of newly introduced facet interventions exist, indicating a growing appreciation for the contribution of the facet joints in back pain. Considering that many of these interventions have not been fully developed, clinical evidence is often lacking; thus, assessment of their potential benefits has to rely on biomechanical studies. However, despite the importance of biomechanical studies in research and development of new interventions, they provide a limited indication of the expected clinical performance; therefore, results should be interpreted with caution.

**4.2.1. Facet joint excision (facetectomy).** Facet joint excision, including both partial and complete facetectomy, is usually performed when neurological symptoms are present. Nerve root impingement due to stenosis is common (**Figure 3b**), but, can also occur due to trauma. Facetectomy is rarely performed for degenerative facet joints alone and is considered an important adjunct to operative management (29).

Partial facetectomy involves the excision of the medial facet portion with the lateral attachments of the ligamentum flavum. The total removal of the joint, as well as the ligamentum flavum, is considered a complete facetectomy. The main indication for this technique is persistent degenerative spine disease, associated with advanced facet joint hypertrophy and osteophytes, that does not respond to conservative treatments (108, 120). Because facetectomy is typically combined with other techniques, it is challenging to evaluate its efficacy. One clinical study reported that following a partial facetectomy alone, at least 70% of patients no longer had pain radiating to the lower limbs (121).

The main concern with either partial or complete facetectomy is resulting spinal instability. Using a finite-element model, a comparison between partial and complete facetectomy showed that spinal instability was associated with the extent of resection (122). In addition, a biomechanical study found that with substantial facet resection, the main concern is resulting iatrogenic spinal





instability, which can reduce failure strength by up to 50% (123). Therefore, facetectomy is frequently accompanied by fusion techniques that restore spinal stability.

**4.2.2. Facet joint fusion systems.** Facet joint fusion is considered advantageous because it can theoretically ensure spinal stability postfacetectomy (124). Furthermore, it is a relatively straightforward technique with a minimal risk of complications (125). Several facet joint fusion systems are used clinically, yet the published research detailing patient outcomes for these systems is limited. Spinal instability is the primary indication for fusion, which can be caused by facet trauma, as well as following decompression surgeries in cases of symptomatic spinal stenosis, spondylolisthesis, and so forth.

Translaminar facet screws (TLFSs), placed into the facet joints via the lamina (**Figure 3c**), are considered important elements to enhance fusion (126). A cohort study of 120 patients that used the Core Outcome Measure Index (ratings of leg and back pain intensity, function, symptom-specific well-being, general quality of life, and social and work disability) to assess outcomes of TLFS fixation versus transforaminal lumbar interbody fusion found that both procedures had similar scores (3.6 versus 4.0), and 78% of patients in both groups reported a good global outcome (the operation helped or helped a lot). However, ~18% of the patients who underwent TLFS fixation required additional surgery, mainly due to pseudoarthrosis or ASD, in a mean period of 3.4 years (127).

Transfacet pedicle screws (TFPSs), placed through the facet joint extending into the pedicle, provide another alternative to the traditional pedicle screw fixation technique (**Figure 3c**) (128). According to biomechanical studies, both techniques are reported to have comparable strength in both thoracic and lumbar spine fixation (128, 129). The minimally invasive nature of this technique is promising, but additional long-term data are necessary to evaluate its safety and ability to achieve solid fusion (130, 131).

Intra-facet joint implants (wedge body/spacers) inserted into the facet joint space to engage the opposing joint surfaces can provide necessary distraction for stabilization (**Figure 3d**) (132). The implants could also improve rotational stability (133). A clinical study reported an excellent outcome for 25 out of 36 patients (134).

**4.2.3. Facet replacement systems.** In the last decade, the increasing need for more effective management of facetogenic pain and thorough decompression without fusion-associated morbidity has led to the development of techniques akin to total knee or hip arthroplasty. Similar to the operative management techniques mentioned above, limited data have been published; thus, conclusions about the efficacy of these systems are largely based on biomechanical studies and may be premature.

The anatomic facet replacement system (AFRS) is composed of two separate implants that are fixated with pedicle screws to the vertebra and with a cross-linking component to one another. As shown with a finite-element model, the implant demonstrated kinematics similar to those of the intact facet joint (135). No clinical studies have been reported so far (135).

Biomechanical test results indicate the total facet arthroplasty system (TFAS) also has potential to restore facet joint motion and provide stabilization (136–138). Fixed to the vertebral body with pegs, this device incorporates a sphere sliding along a curved plate to preserve joint movement and articulation (136). The TFAS allows for more motion in all directions compared with a rigid fixation system (136). Despite these promising preliminary studies, no clinical data have been reported yet.

The total posterior arthroplasty prosthesis, commonly referred to as TOPS, is a posterior dynamic fixation device that involves removal of all of the posterior elements of the spine, including

the affected facet joints and spinous process. A biomechanical evaluation of the device found that it can restore lateral bending and axial rotation kinematics of the intact spine (139). In a preliminary clinical report, TOPS was associated with a decrease in pain of 76% after 1 year (140). Outcomes were maintained at 7-years follow-up, as indicated by the Oswestry Disability Index of 7.8 at 7 years versus 49.1 preoperatively. However, 1 out of 10 patients experienced a device-related failure 3 months after surgery (141). Further research is necessary to evaluate the exact role and applicability of this system in facet joint degeneration.

In addition to the larger arthroplasty systems described above, a facet joint resurfacing system has also been proposed as a solution to facet joint degeneration. Limited preliminary data report improved pain and functionality at 24 months after surgery (142). One out of eight patients (12.5%) suffered an implant dislocation that required reoperation with posterior lumbar interbody fusion, indicating that additional studies are needed to evaluate safety.

### 5. FUTURE DIRECTIONS: COULD TISSUE ENGINEERING PROVIDE A NEW TREATMENT STRATEGY FOR FACET-RELATED MORBIDITY?

Despite the facet's contribution to the economic and social burdens of back pain, no treatment can provide an effective, long-term, restorative solution for this joint. Tissue engineering, however, offers promise for treating maladies in numerous tissues. Specifically, engineering articular cartilage has long been a priority, considering its susceptibility to pathology, its innate inability to regenerate, and the failure of current treatments to produce robust neotissue (143). Within the last two decades, investigations of various cell sources, biomaterials, and stimuli have brought the field closer to functional biologic replacements of both cartilage and underlying bone (144). Yet, despite similar joint pathology, facet tissue engineering remains almost completely unexplored (Table 2) (145). Thus, the application of tissue-engineering principles to the facet may provide a much-needed, long-term, motion-preserving solution.

As discussed above, the facet joint is part of a highly complex system that includes an IVD, ligaments, musculature, and so forth, all of which are susceptible to both degenerative changes and trauma. Therefore, the proposal to tissue-engineer a replacement for this joint cannot currently be considered an all-encompassing solution for all facet-related issues. Instead, to begin with, one can consider facet joint trauma and spinal afflictions such as spondylolisthesis as targets for tissue engineering, as these indications would benefit from the development of a biological replacement. As described above, in these cases, facet trauma or facet degeneration and concomitant hypertrophy are key contributors to nerve impingement, necessitating the complete or partial removal of facets and/or laminae. The development of a tissue-engineered replacement can be considered for regaining spinal stability without the need for fusion. This would preserve the function of the joint as well as protect the integrity of the adjacent facets. As mentioned above, these indications are already the target of at least four facet arthroplasty systems that are currently in clinical trials. Thus, a biological replacement for the facet would provide a novel solution to an already well-recognized and significant problem.

Such a replacement may also offer a long-term solution for facet-mediated pain in the absence or presence of disc pain. Although it is difficult to isolate the facet joint as the sole source of axial pain, use of the best diagnostic tools available has revealed that its prevalence is significant. In these cases, replacement of the facet with a biological solution may provide a longer-term treatment strategy compared with currently available treatments. In addition, considering that facet OA is currently a contraindication to disc replacement, the development of a biological facet replacement may become an adjunct to biological disc replacement. Finally, as the technology matures, a tissue-engineered solution may serve to target the facet in a broader context and may





**Table 2** A comparison between the facet joint and the knee

	Knee	Facet joint	Reference(s)
Surface area	Femur: $29.5 \pm 2.5 \text{ cm}^2$ Tibial plateau: $22.5 \pm 2.4 \text{ cm}^2$	Inferior: $0.69\text{--}1.97 \text{ cm}^2$ Superior: $0.74\text{--}2.12 \text{ cm}^2$	161, 168
Articular cartilage properties	Thickness: 2–3 mm GAG/WW: 5–10% Collagen/WW: 15–20% Aggregate modulus: 80–2,000 kPa Young's modulus: 5–25 MPa Tensile strength <sup>b</sup> : 3–11 MPa	Thickness <sup>a</sup> : $\sim 0.5 \text{ mm}$ GAG/WW <sup>a</sup> : $\sim 4\%$ Collagen/WW <sup>a</sup> : $\sim 17\%$ Aggregate modulus <sup>a</sup> : $\sim 550 \text{ kPa}$ Young's modulus <sup>a</sup> : $\sim 10 \text{ MPa}$ Tensile strength <sup>a</sup> : $\sim 4 \text{ MPa}$	38, 169–171
Contact forces	Medial condyle: $\sim 1,750 \text{ N}$ Lateral condyle: $\sim 500 \text{ N}$ Patellofemoral: $\sim 925 \text{ N}$	Cervical <sup>c</sup> : $\sim 17\text{--}40 \text{ N}$ Thoracic: no data Lumbar <sup>d</sup> : $\sim 10\text{--}120 \text{ N}$	164 165–167, 172
Reasons for hospital visits	Degenerative changes and traumatic events due to, for example, focal lesions, osteochondritis dissecans, OA, meniscus tears, ligament tears (1.8% of hospital visits due to knee symptoms)	Degenerative changes and traumatic events due to, for example, spinal stenosis, spondylolisthesis, traumatic injury, whiplash (1.3% of hospital visits due to back symptoms)	173
Example treatments	NSAIDs, intra-articular injections, microfracture, ACI, MACI, meniscectomy, and total knee arthroplasty	NSAIDs, intra-articular injections, medial branch blocks, partial facetectomy, spine fusion, and arthroplasty systems	31, 144
PubMed searches <sup>e</sup>	799 results for “knee, tissue engineering” 3,815 results for “knee, properties” 521 results for “knee, characterization”	6 results for “facet joint, tissue engineering” 39 results for “facet joint, properties” 13 results for “facet joint, characterization”	Not applicable

<sup>a</sup>These facet joint cartilage properties are from canine tissue.

<sup>b</sup>The knee cartilage tensile strength is from equine tissue.

<sup>c</sup>Forces were measured with strain gauges and neural network models at C5–C6 in human cadaveric spines (C3–T1).

<sup>d</sup>Forces were measured with pressure sensors at L5–S1 in human cadaveric spines.

<sup>e</sup>PubMed searches did not include Medical Subject Headings terms.

Abbreviations: ACI, autologous chondrocyte implantation; GAG, glycosaminoglycan; MACI, matrix-assisted autologous chondrocyte implantation; NSAID, nonsteroidal anti-inflammatory drug; OA, osteoarthritis; WW, wet weight.

extend to the treatment of other facet-related issues. The following section discusses the criteria, strategies, and challenges associated with tissue engineering of a facet cartilage replacement, as well as a total joint replacement.

### 5.1. Key Criteria to Engineer Facet Cartilage

Creating a facet cartilage replacement through tissue engineering can restore joint function and treat pathology of the joint. It is increasingly recognized that developing a biomimetic replacement is integral to achieving functionality (144). On the basis of what is known about facet cartilage, it may possess properties more amenable to functional tissue engineering than other synovial joints (e.g., the knee). Facet cartilage is thinner and has a much smaller surface (**Table 2**), so it requires less neotissue volume, potentially negating nutrient diffusion issues associated with engineering

thicker cartilage (146). Furthermore, it may be possible to engineer an entire synovial joint surface, not merely cartilage constructs for focal defects, which would avoid well-known integration issues between native and engineered cartilage (147). Also, the facet experiences lower compressive loads than the knee (**Table 2**). In fact, the range of compressive stiffness values in engineered cartilage already approaches those observed in native facet cartilage of several animal models (37, 148). In addition, a recent report demonstrates that the mechanical, biochemical, and histological properties of various animal models do not significantly differ between the opposing facet joint surfaces and the spinal levels in which they are located (37). Such uniformity in properties avoids the need to tissue-engineer site-specific replacements and reduces the complexity of the task. Although these design aspects bode well for potentially engineering a facet cartilage replacement, further design criteria must first be established.

Although data describing the human facet's anatomical and geometric characteristics exist (**Table 1**), the properties of human facet articular cartilage have not been reported. The ubiquitous nature of facet joint degeneration has rendered the acquisition of healthy human spines a challenge. As such, an appropriate large-animal model for the facet has yet to arise. Not only are these properties necessary for the design of a functional facet replacement, they would also contribute to our understanding of the facet's structure–function relationships and pathophysiology. The articular cartilage of canine, porcine, leporine, primate (37), and equine models has been extensively characterized (S.A. O'Leary, J.L. White, J.C. Hu & K.A. Athansiou, unpublished data); thus, significant progress has been made in this area. However, deeper analysis of facet tissues in humans will be paramount for establishing design criteria toward engineering functional tissue replacements.

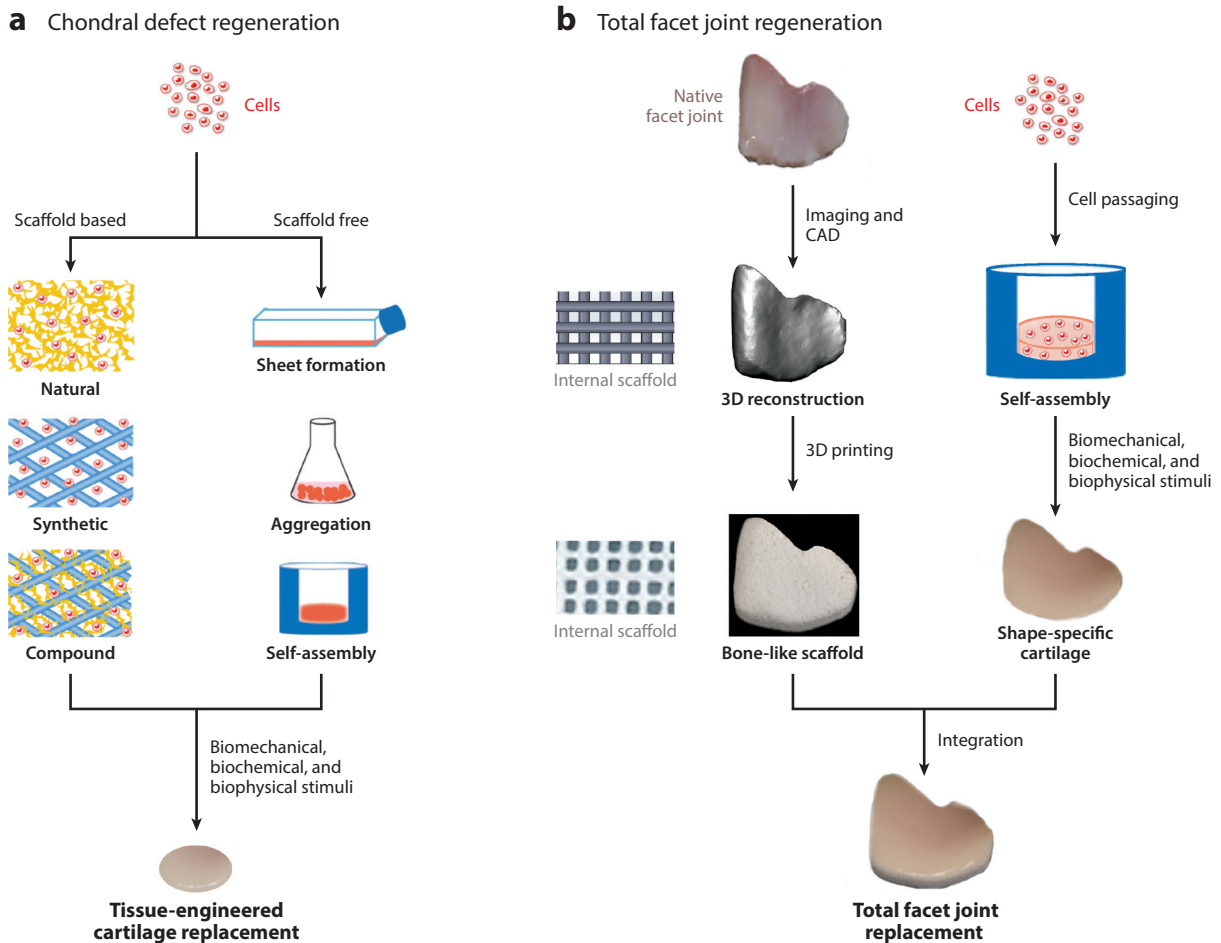
Cell sources for tissue-engineered facet neocartilage also need to be explored. As mentioned above, the volume of required engineered tissue is small; thus, the necessary number of initial cells may be lower. However, using an autologous source of chondrocytes from healthy facet cartilage, a strategy commonly used in the knee, may not be an option. Several confounding factors, such as small surface area and facet cartilage degeneration, limit the applicability of this strategy. Therefore, alternative cell sources that are currently being researched for replacements of other joint cartilage—including autologous chondrocytes harvested from other sites in the body, allogeneic chondrocytes, or mesenchymal stem cells (MSCs) (e.g., marrow-, synovial membrane-, or adipose-derived)—may be viable for tissue-engineering a facet cartilage replacement.

## 5.2. Potential Strategies to Engineer Facet Cartilage

There are numerous important considerations in engineering a biological replacement for the entire facet joint. To achieve a positive clinical outcome, tissue-engineered facet cartilage must allow for replication of tissue function as well as maintenance of long-term stability after implantation. The following is a discussion of the key aspects that should be considered when developing a strategy to tissue-engineer the facet joint.

**5.2.1. Scaffold based.** Traditional tissue-engineering approaches often use biodegradable, polymeric scaffolds to mimic the three-dimensional (3D) structure of native cartilage (**Figure 4a**). Scaffolds provide temporary mechanical support and biological cues for embedded cells to maintain phenotype and promote growth of neocartilage. Many scaffold-based approaches are currently being investigated, some of which are available clinically for treatment of the knee and other joints. For example, MSCs harvested from the iliac crest and embedded in collagen or hyaluronic acid matrices are beneficial for treatment of talus osteochondral defects (149). Also, autologous matrix-induced chondrogenesis is considered a promising one-step cartilage repair technique that





**Figure 4**

Tissue-engineering the facet joint. Potential strategies toward regeneration of (a) facet cartilage to treat chondral defects and (b) the joint to treat total joint afflictions. Strategies to tissue-engineer a cartilage replacement can be scaffold based, requiring the use of a natural, synthetic, or compound scaffold, or can be scaffold free, using cell sheet and aggregate engineering techniques or the self-assembly process. Many of these strategies may also have the potential to engineer the entire facet joint surface. One such strategy, the self-assembly process, generates neotissue without a scaffold and without external energy input, thus mimicking developmental events. Shape specificity is also achievable using this method. Shape-specific self-assembled cartilage integrated with 3D-printed bone could represent the first biologic total joint replacement, which would be an important step in advancing the field of tissue engineering. Abbreviation: CAD, computer-aided design.

combines microfracture with the implantation of an acellular biomaterial (150). In addition to these, scaffolds made of polylactides and/or polyglycolides result in tissue with similar histomorphology to native cartilage (151, 152). While these scaffold-based methods appear promising, their durability warrants further investigation to assess long-term success.

**5.2.2. Scaffold free.** A promising, emerging paradigm that may potentially be applied to facet cartilage is scaffold-free tissue engineering (Figure 4a). Scaffold-free strategies aim to produce tissues by mimicking developmental processes while also reducing the risk of scaffold degradation

toxicity, stress shielding, and cell-signaling hindrance. RevaFlex, which consists of an expanded sheet of juvenile allogeneic chondrocytes, is in clinical trials for use in cartilage repair in the knee, and preliminary results have been positive (153). Similarly, Chondrosphere, a product that is also targeted for the knee, uses only autologous cell aggregates and is also in clinical trials. At a 1-year follow up, all assessment scores were significantly increased (154). An approach known as the self-assembling process yields neocartilage that, when treated with biochemical and biomechanical stimuli, has compressive and tensile properties approaching those of native knee cartilage (148, 155). Given that functional properties of self-assembled cartilage are similar to those of animal facet cartilage (148, 155, 156), this method may have the capacity to regenerate human facet cartilage. Furthermore, self-assembly allows for control over tissue shape, potentially leading to replication of the complex curvature of the facet's articular surface (157). Although these scaffold-free strategies are promising, long-term clinical trials need to be performed to assess their efficacy.

### 5.3. Key Criteria for an Engineered Total Facet Joint

A challenge for tissue-engineered facet cartilage may involve difficulty accessing the joint. Due to the facet's anatomical positioning, small size, and high congruence, distracting and/or disarticulating the joint using current surgical equipment is challenging. This problem is exacerbated by the facet's tendency toward hypertrophy, often resulting in excessive bony overgrowth. Therefore, surgical instruments and techniques need to be developed in parallel to match the needs of this treatment strategy. Encouragingly, total facet joint arthroplasty systems and associated surgical techniques have already been developed and are currently in clinical trials. Therefore, these techniques could be adopted and refined to implant a biological facet replacement. Interestingly, a replacement of the entire facet (opposing articular surfaces and underlying bone) may obviate the issues associated with accessing the articular surface while addressing the overarching problem of joint degeneration. Of course, the degree to which the facet is degenerated and the quality of the remaining bone for the purposes of attachment would have to be assessed on a patient-specific basis. Indeed, due to the facet's favorable design (discussed above), it could be a suitable candidate for the first total biologic joint replacement.

To successfully engineer a total facet replacement, the implant must fully function upon implantation, conform to the facet shape, and be fixed securely. Current chondral and osteochondral engineering strategies rely on the surrounding native tissue for structural support, fixation, cells, and bioactive factors. Therefore, a design for a readily implantable total biologic joint necessitates engineering and maturation of both cartilage and bone layers within a single integrated structure *in vitro*. Like cartilage regeneration strategies, both layers need to mimic properties of their respective native structures. Furthermore, implant fabrication processes need to be capable of replicating facet geometry, which is known to be level and patient specific (158). Other considerations, such as implant fixation and development of appropriate surgical techniques, would need to be addressed. However, current osteochondral engineering strategies developed primarily for repairing focal defects in the knee, in particular those involving 3D printing, may hold translational potential for entire facet joint regeneration.

### 5.4. Envisioning an Engineered Total Facet Joint

A potential approach to engineering a total biologic joint prosthesis may involve an *in vitro*, self-assembled, shape-specific cartilage construct integrated with a 3D-printed shape-specific, underlying bone-like substrate (**Figure 4b**). As discussed above, native cartilage properties have been achieved *in vitro* via self-assembly in concert with various stimuli; thus, the self-assembling



process can be considered a promising option for the creation of a biomimetic cartilage replacement (148, 155). Typically, engineering bony tissue requires the use of a scaffold. Unlike conventional scaffold fabrication methods, 3D printing can precisely control external geometry as well as internal pore size, porosity, and spatial distribution to meet design needs (159). Ceramics, known for their excellent bioactivity, osteoconductivity, and compositional similarity to bone, have successfully been 3D printed and shown to support bone formation (160). Thus, integration of self-assembled cartilage with 3D-printed ceramic scaffolds may be an attractive design for a total biologic joint prosthesis. Furthermore, precise control of both the internal bone architecture and the external implant shape may enhance integration between cartilage and bone, as well as enable the design of a fixation method. Although many current tissue-engineering strategies would need refinement to account for facet-specific design criteria and tissues such as the fibrous capsule, tissue engineering may provide a durable, motion-preserving treatment modality for this troubled joint.

## 6. CONCLUSION

In a healthy state, facet joints facilitate and guide spinal motion, ensuring proper kinematics at each level. However, since facets are the locus of highly significant pathology, pain, and disability, new management strategies continue to be explored. Unfortunately, a durable, motion-preserving solution still has not been identified. While continued characterization of facet structure–function relationships and refinement of tissue-engineering techniques are necessary, a biologic facet joint replacement may one day emerge as an all-inclusive treatment for local facetogenic trauma and degeneration and may help solve more pervasive issues within the spine.

## DISCLOSURE STATEMENT

E.O. K. has been a consultant for DePuy Synthes, Stryker, Springer, and Trevena, Inc. and has received honoraria from K2M and AOSpine. The other authors are not aware of any affiliations, memberships, funding, or financial holdings that might be perceived as affecting the objectivity of this review.

## LITERATURE CITED

1. Pal GP, Routal RV. 1987. Transmission of weight through the lower thoracic and lumbar regions of the vertebral column in man. *J. Anat.* 152:93–105
2. Aarabi B, Walters BC, Dhall SS, Gelb DE, Hurlbert RJ, et al. 2013. Subaxial cervical spine injury classification systems. *Neurosurgery* 72:170–86
3. Crawford NR, Duggal N, Chamberlain RH, Park SC, Sonntag VK, Dickman CA. 2002. Unilateral cervical facet dislocation: injury mechanism and biomechanical consequences. *Spine* 27:1858–64
4. Dvorak MF, Fisher CG, Aarabi B, Harris MB, Hurlbert RJ, et al. 2007. Clinical outcomes of 90 isolated unilateral facet fractures, subluxations, and dislocations treated surgically and nonoperatively. *Spine* 32:3007–13
5. Li J, Muehleman C, Abe Y, Masuda K. 2011. Prevalence of facet joint degeneration in association with intervertebral joint degeneration in a sample of organ donors. *J. Orthop. Res.* 29:1267–74
6. Eubanks JD, Lee MJ, Cassinelli E, Ahn NU. 2007. Prevalence of lumbar facet arthrosis and its relationship to age, sex, and race: an anatomic study of cadaveric specimens. *Spine* 32:2058–62
7. Suri P, Hunter DJ, Rainville J, Guermazi A, Katz JN. 2013. Presence and extent of severe facet joint osteoarthritis are associated with back pain in older adults. *Osteoarthr. Cartil.* 21:1199–206
8. Genevay S, Atlas SJ. 2010. Lumbar spinal stenosis. *Best Pract. Res. Clin. Rheumatol.* 24:253–65
9. Weinstein JN, Lurie JD, Olson P, Bronner KK, Fisher ES, Morgan MTS. 2006. United States trends and regional variations in lumbar spine surgery: 1992–2003. *Spine* 31:2707–12



10. Newman P, Stone K. 1963. The etiology of spondylolisthesis. *J. Bone Joint Surg. Br.* 45:39–59
11. Vanderpool DW, James JI, Wynne-Davies R. 1969. Scoliosis in the elderly. *J. Bone Joint Surg. Am.* 51:446–55
12. Lawrence RC, Felson DT, Helmick CG, Arnold LM, Choi H, et al. 2008. Estimates of the prevalence of arthritis and other rheumatic conditions in the United States. Part II. *Arthritis Rheum.* 58:26–35
13. Natl. Cent. Health Stat. 2012. *Health, United States, 2011: With Special Feature on Socioeconomic Status and Health.* Hyattsville, MD: Natl. Cent. Health Stat.
14. Katz JN. 2006. Lumbar disc disorders and low-back pain: socioeconomic factors and consequences. *J. Bone Joint Surg. Am.* 88(Suppl. 2):21–24
15. Gaskin DJ, Richard P. 2012. The economic costs of pain in the United States. *J. Pain* 13:715–24
16. Manchikanti L, Pampati V, Singh V, Falco FJ. 2013. Assessment of the escalating growth of facet joint interventions in the Medicare population in the United States from 2000 to 2011. *Pain Phys.* 16:E365–78
17. Manchikanti L, Pampati S, Cash KA. 2010. Making sense of the accuracy of diagnostic lumbar facet joint nerve blocks: an assessment of the implications of 50% relief, 80% relief, single block, or controlled diagnostic blocks. *Pain Phys.* 13:133–43
18. Manchikanti L, Pampati V, Singh V, Beyer C, Damron K, Fellows B. 2001. Evaluation of the role of facet joints in persistent low back pain in obesity: a controlled, prospective, comparative evaluation. *Pain Phys.* 4:266–72
19. Manchikanti L, Hirsch JA, Pampati V. 2003. Chronic low back pain of facet (zygapophysial) joint origin: Is there a difference based on involvement of single or multiple spinal regions? *Pain Phys.* 6:399–405
20. Manchikanti L, Singh V, Pampati V, Damron KS, Beyer CD, Barnhill RC. 2002. Is there correlation of facet joint pain in lumbar and cervical spine? An evaluation of prevalence in combined chronic low back and neck pain. *Pain Phys.* 5:365–71
21. Manchikanti L, Boswell MV, Singh V, Pampati V, Damron KS, Beyer CD. 2004. Prevalence of facet joint pain in chronic spinal pain of cervical, thoracic, and lumbar regions. *BMC Musculoskelet. Disord.* 5:15
22. Manchukonda R, Manchikanti KN, Cash KA, Pampati V, Manchikanti L. 2007. Facet joint pain in chronic spinal pain: an evaluation of prevalence and false-positive rate of diagnostic blocks. *J. Spinal Disord. Tech.* 20:539–45
23. Manchikanti L, Manchukonda R, Pampati V, Damron KS, McManus CD. 2007. Prevalence of facet joint pain in chronic low back pain in postsurgical patients by controlled comparative local anesthetic blocks. *Arch. Phys. Med. Rehabil.* 88:449–55
24. Manchikanti L, Singh V, Pampati V, Beyer CD, Damron KS. 2002. Evaluation of the prevalence of facet joint pain in chronic thoracic pain. *Pain Phys.* 5:354–59
25. Boswell MV, Colson JD, Sehgal N, Dunbar EE, Epter R. 2007. A systematic review of therapeutic facet joint interventions in chronic spinal pain. *Pain Phys.* 10:229–53
26. Sears WR, Sergides IG, Kazemi N, Smith M, White GJ, Osburg B. 2011. Incidence and prevalence of surgery at segments adjacent to a previous posterior lumbar arthrodesis. *Spine J.* 11:11–20
27. Park P, Garton HJ, Gala VC, Hoff JT, McGillicuddy JE. 2004. Adjacent segment disease after lumbar or lumbosacral fusion: review of the literature. *Spine* 29:1938–44
28. Serhan H, Mhatre D, Defossez H, Bono CM. 2011. Motion-preserving technologies for degenerative lumbar spine: the past, present, and future horizons. *SAS J.* 5:75–89
29. Cohen SP, Huang JH, Brummett C. 2013. Facet joint pain—advances in patient selection and treatment. *Nat. Rev. Rheumatol.* 9:101–16
30. Boswell MV, Manchikanti L, Kaye AD, Bakshi S, Gharibo CG, et al. 2015. A best-evidence systematic appraisal of the diagnostic accuracy and utility of facet (zygapophysial) joint injections in chronic spinal pain. *Pain Phys.* 18:E497–533
31. Jaumard NV, Welch WC, Winkelstein BA. 2011. Spinal facet joint biomechanics and mechanotransduction in normal, injury and degenerative conditions. *J. Biomech. Eng.* 133:071010
32. Pal GP, Routal RV, Saggi SK. 2001. The orientation of the articular facets of the zygapophysial joints at the cervical and upper thoracic region. *J. Anat.* 198:431–41
33. Masharawi Y, Rothschild B, Dar G, Peleg S, Robinson D, et al. 2004. Facet orientation in the thoracolumbar spine: three-dimensional anatomic and biomechanical analysis. *Spine* 29:1755–63





34. Tulsi RS, Hermanis GM. 1993. A study of the angle of inclination and facet curvature of superior lumbar zygapophyseal facets. *Spine* 18:1311–17
35. McLain RF, Yerby SA, Moseley TA. 2002. Comparative morphometry of L4 vertebrae: comparison of large animal models for the human lumbar spine. *Spine* 27:E200–6
36. Pal GP, Routal RV. 1999. Mechanism of change in the orientation of the articular process of the zygapophyseal joint at the thoracolumbar junction. *J. Anat.* 195:199–209
37. O'Leary SA, Link JM, Klineberg EO, Hu JC, Athansiou KA. 2017. Characterization of facet joint cartilage properties in the human and interspecies comparisons. *Acta Biomater.* 54:367–76
38. Elder BD, Vigneswaran K, Athansiou KA, Kim DH. 2009. Biomechanical, biochemical, and histological characterization of canine lumbar facet joint cartilage. *J. Neurosurg. Spine* 10:623–28
39. Abd Latif MJ, Jin Z, Wilcox RK. 2012. Biomechanical characterisation of ovine spinal facet joint cartilage. *J. Biomech.* 45:1346–52
40. Farrell SF, Osmotherly PG, Cornwall J, Rivett DA. 2015. The anatomy and morphometry of cervical zygapophyseal joint meniscoids. *Surg. Radiol. Anat.* 37:799–807
41. Little JS, Khalsa PS. 2005. Material properties of the human lumbar facet joint capsule. *J. Biomech. Eng.* 127:15–24
42. Kallakuri S, Li Y, Chen C, Cavanaugh JM. 2012. Innervation of cervical ventral facet joint capsule: histological evidence. *World J. Orthop.* 3:10–14
43. Zhou L, Schneck CD, Shao Z. 2012. The anatomy of dorsal ramus nerves and its implications in lower back pain. *Neurosci. Med.* 3:192–201
44. Takigawa T, Espinoza Orias AA, An HS, Gohgi S, Udayakumar RK, et al. 2010. Spinal kinematics and facet load transmission after total disc replacement. *Spine* 35:E1160–66
45. Pal GP, Routal RV. 1986. A study of weight transmission through the cervical and upper thoracic regions of the vertebral column in man. *J. Anat.* 148:245–61
46. Raynor RB, Moskovich R, Zidel P, Pugh J. 1987. Alterations in primary and coupled neck motions after facetectomy. *Neurosurgery* 21:681–87
47. Li W, Wang S, Xia Q, Passias P, Kozanek M, et al. 2011. Lumbar facet joint motion in patients with degenerative disc disease at affected and adjacent levels: an in vivo biomechanical study. *Spine* 36:E629–37
48. Adams MA, Hutton WC. 1983. The mechanical function of the lumbar apophyseal joints. *Spine* 8:327–30
49. Dreischarf M, Schmidt H, Putzier M, Zander T. 2015. Biomechanics of the L5-S1 motion segment after total disc replacement—influence of iatrogenic distraction, implant positioning and preoperative disc height on the range of motion and loading of facet joints. *J. Biomech.* 48:3283–91
50. Bauman JA, Jaumard NV, Guarino BB, Weisshaar CL, Lipschutz DE, et al. 2012. Facet joint contact pressure is not significantly affected by ProDisc cervical disc arthroplasty in sagittal bending: a single-level cadaveric study. *Spine J.* 12:949–59
51. Vaccaro A, Koerner J, Radcliff K, Oner FC, Reinhold M, et al. 2015. AOSpine subaxial cervical spine injury classification system. *Eur. Spine J.* 25:2173–84
52. Hasler RM, Exadaktylos AK, Bouamra O, Benneker LM, Clancy M, et al. 2012. Epidemiology and predictors of cervical spine injury in adult major trauma patients: a multicenter cohort study. *J. Trauma Acute Care Surg.* 72:975–81
53. Kuster D, Gibson A, Abboud R, Drew T. 2012. Mechanisms of cervical spine injury in rugby union: a systematic review of the literature. *Br. J. Sports Med.* 46:550–54
54. Beyer CA, Cabanela ME. 1992. Unilateral facet dislocations and fracture-dislocations of the cervical spine: a review. *Orthopedics* 15:311–15
55. Nadeau M, McLachlin SD, Bailey SI, Gurr KR, Dunning CE, Bailey CS. 2012. A biomechanical assessment of soft-tissue damage in the cervical spine following a unilateral facet injury. *J. Bone Joint Surg.* 94:e156
56. Sim E, Vaccaro AR, Berzlanovich A, Schwarz N, Sim B. 2001. In vitro genesis of subaxial cervical unilateral facet dislocations through sequential soft tissue ablation. *Spine* 26:1317–23
57. Vaccaro AR, Madigan L, Schweitzer ME, Flanders AE, Hilibrand AS, Albert TJ. 2001. Magnetic resonance imaging analysis of soft tissue disruption after flexion-distraction injuries of the subaxial cervical spine. *Spine* 26:1866–72





58. Lowery DW, Wald MM, Browne BJ, Tigges S, Hoffman JR, Mower WR. 2001. Epidemiology of cervical spine injury victims. *Ann. Emerg. Med.* 38:12–16
59. Reinhold M, Audige L, Schnake KJ, Bellabarba C, Dai LY, Oner FC. 2013. AOSpine injury classification system: a revision proposal for the thoracic and lumbar spine. *Eur. Spine J.* 22:2184–201
60. Bogduk N. 2008. Evidence-informed management of chronic low back pain with facet injections and radiofrequency neurotomy. *Spine J.* 8:56–64
61. Manchikanti L, Singh V, Pampati V, Damron KS, Barnhill RC, et al. 2001. Evaluation of the relative contributions of various structures in chronic low back pain. *Pain Phys.* 4:308–16
62. Manchikanti L, Pampati V, Rivera J, Fellows B, Beyer C, Damron K. 2001. Role of facet joints in chronic low back pain in the elderly: a controlled comparative prevalence study. *Pain Pract.* 1:332–37
63. Gellhorn AC, Katz JN, Suri P. 2013. Osteoarthritis of the spine: the facet joints. *Nat. Rev. Rheumatol.* 9:216–24
64. Kim JS, Ali MH, Wydra F, Li X, Hamilton JL, et al. 2015. Characterization of degenerative human facet joints and facet joint capsular tissues. *Osteoarthr. Cartil.* 23:2242–51
65. Kalichman L, Kim DH, Li L, Guermazi A, Hunter DJ. 2010. Computed tomography–evaluated features of spinal degeneration: prevalence, intercorrelation, and association with self-reported low back pain. *Spine J.* 10:200–8
66. Ko S, Vaccaro AR, Lee S, Lee J, Chang H. 2014. The prevalence of lumbar spine facet joint osteoarthritis and its association with low back pain in selected Korean populations. *Clin. Orthop. Surg.* 6:385–91
67. Fujiwara A, Tamai K, Yamato M, An HS, Yoshida H, et al. 1999. The relationship between facet joint osteoarthritis and disc degeneration of the lumbar spine: an MRI study. *Eur. Spine J.* 8:396–401
68. Maataoui A, Vogl TJ, Middendorp M, Kafchitsas K, Khan MF. 2014. Association between facet joint osteoarthritis and the Oswestry Disability Index. *World J. Radiol.* 6:881–85
69. Butler D, Trafimow JH, Andersson GB, McNeill TW, Huckman MS. 1990. Discs degenerate before facets. *Spine* 15:111–13
70. Suri P, Miyakoshi A, Hunter DJ, Jarvik JG, Rainville J, et al. 2011. Does lumbar spinal degeneration begin with the anterior structures? A study of the observed epidemiology in a community-based population. *BMC Musculoskelet. Disord.* 12:202
71. Goode AP, Marshall SW, Renner JB, Carey TS, Kraus VB, et al. 2012. Lumbar spine radiographic features and demographic, clinical, and radiographic knee, hip, and hand osteoarthritis. *Arthritis Care Res.* 64:1536–44
72. Kalichman L, Suri P, Guermazi A, Li L, Hunter DJ. 2009. Facet orientation and tropism: associations with facet joint osteoarthritis and degeneratives. *Spine* 34:E579–85
73. Linov L, Klindukhov A, Li L, Kalichman L. 2013. Lumbar facet joint orientation and osteoarthritis: a cross-sectional study. *J. Back Musculoskelet. Rehabil.* 26:421–26
74. Fujiwara A, Tamai K, An HS, Lim TH, Yoshida H, et al. 2001. Orientation and osteoarthritis of the lumbar facet joint. *Clin. Orthop. Relat. Res.* 2001:88–94
75. Park MS, Lee YB, Moon S-H, Lee H-M, Kim T-H, et al. 2014. Facet joint degeneration of the cervical spine: a computed tomographic analysis of 320 patients. *Spine* 39:E713–18
76. Uhrenholt L, Hauge E, Charles AV, Gregersen M. 2008. Degenerative and traumatic changes in the lower cervical spine facet joints. *Scand. J. Rheumatol.* 37:375–84
77. Park MS, Moon SH, Kim TH, Lee SY, Jo YG, Riew KD. 2015. Relationship between modic changes and facet joint degeneration in the cervical spine. *Eur. Spine J.* 24:2999–3004
78. Lee MJ, Riew KD. 2009. The prevalence cervical facet arthrosis: an osseous study in a cadveric population. *Spine J.* 9:711–14
79. Kalichman L, Li L, Kim DH, Guermazi A, Berkin V, et al. 2008. Facet joint osteoarthritis and low back pain in the community-based population. *Spine* 33:2560–65
80. Suri P, Hunter DJ, Rainville J, Guermazi A, Katz JN. 2013. Presence and extent of severe facet joint osteoarthritis are associated with back pain in older adults. *Osteoarthr. Cartil.* 21:1199–206
81. Ko S, Vaccaro AR, Lee S, Lee J, Chang H. 2014. The prevalence of lumbar spine facet joint osteoarthritis and its association with low back pain in selected Korean populations. *Clin. Orthop. Surg.* 6:385–91
82. Kirkaldy-Willis W, Farfan H. 1982. Instability of the lumbar spine. *Clin. Orthop. Relat. Res.* 165:110–23



83. Eubanks JD, Lee MJ, Cassinelli E, Ahn NU. 2007. Does lumbar facet arthrosis precede disc degeneration? A postmortem study. *Clin. Orthop. Relat. Res.* 464:184–89
84. Bough B, Thakore J, Davies M, Dowling F. 1990. Degeneration of the lumbar facet joints. Arthrography and pathology. *J. Bone Joint Surg. Br.* 72:275–76
85. Li J, Muehleman C, Abe Y, Masuda K. 2011. Prevalence of facet joint degeneration in association with intervertebral joint degeneration in a sample of organ donors. *J. Orthop. Res.* 29:1267–74
86. Virk SS, Niedermeier S, Yu E, Khan SN. 2014. Adjacent segment disease. *Orthopedics* 37:547–55
87. Hilibrand AS, Carlson GD, Palumbo MA, Jones PK, Bohlman HH. 1999. Radiculopathy and myelopathy at segments adjacent to the site of a previous anterior cervical arthrodesis. *J. Bone Joint Surg.* 81:519–28
88. Hellum C, Berg L, Gjertsen O, Johnsen LG, Neckelmann G, et al. 2012. Adjacent level degeneration and facet arthropathy after disc prosthesis surgery or rehabilitation in patients with chronic low back pain and degenerative disc: second report of a randomized study. *Spine* 37:2063–73
89. Nunley PD, Jawahar A, Kerr EJ 3rd, Gordon CJ, Cavanaugh DA, et al. 2012. Factors affecting the incidence of symptomatic adjacent-level disease in cervical spine after total disc arthroplasty: 2- to 4-year follow-up of 3 prospective randomized trials. *Spine* 37:445–51
90. Ciol MA, Deyo RA, Howell E, Kreif S. 1996. An assessment of surgery for spinal stenosis: time trends, geographic variations, complications, and reoperations. *J. Am. Geriatr. Soc.* 44:285–90
91. Jansson KA, Blomqvist P, Granath F, Nemeth G. 2003. Spinal stenosis surgery in Sweden 1987–1999. *Eur. Spine J.* 12:535–41
92. Du Bois M, Szpalski M, Donceel P. 2012. A decade's experience in lumbar spine surgery in Belgium: sickness fund beneficiaries, 2000–2009. *Eur. Spine J.* 21:2693–703
93. Lee CK, Rauschnig W, Glenn W. 1988. Lateral lumbar spinal canal stenosis: classification, pathologic anatomy and surgical decompression. *Spine* 13:313–20
94. Lee SY, Kim T-H, Oh JK, Lee SJ, Park MS. 2015. Lumbar stenosis: a recent update by review of literature. *Asian Spine J.* 9:818–28
95. Kalichman L, Kim DH, Li L, Guermazi A, Berkin V, Hunter DJ. 2009. Spondylolysis and spondylolisthesis: prevalence and association with low back pain in the adult community-based population. *Spine* 34:199–205
96. Aebi M. 2005. The adult scoliosis. *Eur. Spine J.* 14:925–48
97. van Dam BE. 1988. Nonoperative treatment of adult scoliosis. *Orthop. Clin. N. Am.* 19:347–51
98. Pichaisak W, Chotiarnwong C, Chotiarnwong P. 2015. Facet joint orientation and tropism in lumbar degenerative disc disease and spondylolisthesis. *J. Med. Assoc. Thai.* 98:373–79
99. Xu C, Lin B, Ding Z, Xu Y. 2015. Cervical degenerative spondylolisthesis: analysis of facet orientation and the severity of cervical spondylolisthesis. *Spine J.* 16:10–15
100. Nakayama T, Ehara S. 2015. Spondylolytic spondylolisthesis: various imaging features and natural courses. *Jpn. J. Radiol.* 33:3–12
101. Bao H, Zhu F, Liu Z, Bentley M, Mao S, et al. 2014. Vertebral rotatory subluxation in degenerative scoliosis: facet joint tropism is related. *Spine* 39:B45–51
102. Manchikanti L, Singh V, Falco FJ, Cash KA, Pampati V. 2010. Evaluation of lumbar facet joint nerve blocks in managing chronic low back pain: a randomized, double-blind, controlled trial with a 2-year follow-up. *Int. J. Med. Sci.* 7:124–35
103. Fotiadou A, Wojcik A, Shaju A. 2012. Management of low back pain with facet joint injections and nerve root blocks under computed tomography guidance. A prospective study. *Skelet. Radiol.* 41:1081–85
104. Cohen SP, Williams KA, Kurihara C, Nguyen C, Shields C, et al. 2010. Multicenter, randomized, comparative cost-effectiveness study comparing 0, 1, and 2 diagnostic medial branch (facet joint nerve) block treatment paradigms before lumbar facet radiofrequency denervation. *Anesthesiology* 113:395–405
105. Schwarzer AC, Aprill CN, Derby R, Fortin J, Kine G, Bogduk N. 1994. The false-positive rate of uncontrolled diagnostic blocks of the lumbar zygapophysial joints. *Pain* 58:195–200
106. Manchikanti L, Pampati V, Bakhit CE, Rivera JJ, Beyer CD, et al. 2001. Effectiveness of lumbar facet joint nerve blocks in chronic low back pain: a randomized clinical trial. *Pain Phys.* 4:101–17
107. Staal JB, de Bie RA, de Vet HC, Hildebrandt J, Nelemans P. 2009. Injection therapy for subacute and chronic low back pain: an updated Cochrane review. *Spine* 34:49–59



108. Carette S, Marcoux S, Truchon R, Grondin C, Gagnon J, et al. 1991. A controlled trial of corticosteroid injections into facet joints for chronic low back pain. *N. Engl. J. Med.* 325:1002–7
109. Chou R, Loeser JD, Owens DK, Rosenquist RW, Atlas SJ, et al. 2009. Interventional therapies, surgery, and interdisciplinary rehabilitation for low back pain: an evidence-based clinical practice guideline from the American Pain Society. *Spine* 34:1066–77
110. Dagenais S, Yelland MJ, Del Mar C, Schoene ML. 2007. Prolotherapy injections for chronic low-back pain. *Cochrane Database Syst. Rev.* 18:CD004059
111. Vekaria R, Bhatt R, Ellard DR, Henschke N, Underwood M, Sandhu H. 2016. Intra-articular facet joint injections for low back pain: a systematic review. *Eur. Spine J.* 25:1266–81
112. Wu T, Zhao WH, Dong Y, Song HX, Li JH. 2016. Effectiveness of ultrasound-guided versus fluoroscopy or computed tomography scanning guidance in lumbar facet joint injections in adults with facet joint syndrome: a meta-analysis of controlled trials. *Arch. Phys. Med. Rehabil.* 97:1558–63
113. Maas ET, Ostelo RW, Niemisto L, Jousimaa J, Hurri H, et al. 2015. Radiofrequency denervation for chronic low back pain. *Cochrane Database Syst. Rev.* 10:CD008572
114. Nath S, Nath CA, Pettersson K. 2008. Percutaneous lumbar zygapophysial (facet) joint neurotomy using radiofrequency current, in the management of chronic low back pain: a randomized double-blind trial. *Spine* 33:1291–97
115. Tekin I, Mirzai H, Ok G, Erbuyun K, Vatanserver D. 2007. A comparison of conventional and pulsed radiofrequency denervation in the treatment of chronic facet joint pain. *Clin. J. Pain* 23:524–29
116. Stovner LJ, Kolstad F, Helde G. 2004. Radiofrequency denervation of facet joints C2–C6 in cervicogenic headache: a randomized, double-blind, sham-controlled study. *Cephalalgia* 24:821–30
117. Leclaire R, Fortin L, Lambert R, Bergeron YM, Rossignol M. 2001. Radiofrequency facet joint denervation in the treatment of low back pain: a placebo-controlled clinical trial to assess efficacy. *Spine* 26:1411–16
118. van Wijk RM, Geurts JW, Wynne HJ, Hammink E, Buskens E, et al. 2005. Radiofrequency denervation of lumbar facet joints in the treatment of chronic low back pain: a randomized, double-blind, sham lesion-controlled trial. *Clin. J. Pain* 21:335–44
119. Poetscher AW, Gentil AF, Lenza M, Ferretti M. 2014. Radiofrequency denervation for facet joint low back pain: a systematic review. *Spine* 39:E842–49
120. Garrido E, Connaughton PN. 1991. Unilateral facetectomy approach for lateral lumbar disc herniation. *J. Neurosurg.* 74:754–56
121. Sanderson PL, Getty CJ. 1996. Long-term results of partial undercutting facetectomy for lumbar lateral recess stenosis. *Spine* 21:1352–56
122. Zander T, Rohlmann A, Klöckner C, Bergmann G. 2003. Influence of graded facetectomy and laminectomy on spinal biomechanics. *Eur. Spine J.* 12:427–34
123. Cusick JF, Yoganandan N, Pintar F, Myklebust J, Hussain H. 1988. Biomechanics of cervical spine facetectomy and fixation techniques. *Spine* 13:808–12
124. Jacobs RR, Montesano PX, Jackson RP. 1989. Enhancement of lumbar spine fusion by use of translaminar facet joint screws. *Spine* 14:12–15
125. Park YK, Chung HS. 1999. Instrumented facet fusion for the degenerative lumbar disorders. *Acta Neurochir.* 141:915–20
126. Heggeness MH, Esses SI. 1991. Translaminar facet joint screw fixation for lumbar and lumbosacral fusion. A clinical and biomechanical study. *Spine* 16:S266–69
127. Grob D, Bartanusz V, Jeszenszky D, Kleinstück FS, Lattig F, et al. 2009. A prospective, cohort study comparing translaminar screw fixation with transforaminal lumbar interbody fusion and pedicle screw fixation for fusion of the degenerative lumbar spine. *J. Bone Joint Surg. Br.* 91:1347–53
128. Akbay A, Inceoğlu S, Milks R, Schlenk R, Palaoglu S, Benzel EC. 2005. Thoracic transfacet pedicle screw fixation: a new instrumentation technique. *J. Neurosurg. Spine* 3:224–29
129. Chin KR, Reis MT, Reyes PM, Newcomb AG, Neagoe A, et al. 2015. Stability of transforaminal lumbar interbody fusion in the setting of retained facets and posterior fixation using transfacet or standard pedicle screws. *Spine J.* 15:1077–82



130. Luo P, Chen YH, Wu YS, Dou HC, Chi YL, Lin Y. 2015. Comparison of transforaminal lumbar interbody fusion performed with unilateral pedicle screw fixation or unilateral pedicle screw—contralateral percutaneous transfacet screw fixation. *Br. J. Neurosurg.* 30:86–90
131. Chin KR, Seale J, Cumming V. 2015. Mini-open or percutaneous bilateral lumbar transfacet pedicle screw fixation: a technical note. *J. Spinal Disord. Tech.* 28:61–65
132. Fisher MA, O’Neil MJ, Serhan HA. 2008. *Intra-facet fixation device and method of use.* US Patent 8133261
133. Hartensuer R, Riesenbeck O, Schulze M, Gehweiler D, Raschke MJ, et al. 2014. Biomechanical evaluation of the Facet Wedge: a refined technique for facet fixation. *Eur. Spine J.* 23:2321–29
134. Goel A, Shah A. 2011. Facetal distraction as treatment for single- and multilevel cervical spondylotic radiculopathy and myelopathy: a preliminary report. *J. Neurosurg. Spine* 14:689–96
135. Goel VK, Mehta A, Jangra J, Faizan A, Kiapour A, et al. 2007. Anatomic Facet Replacement System (AFRS) restoration of lumbar segment mechanics to intact: a finite element study and in vitro cadaver investigation. *SAS J.* 1:46–54
136. Sjøvold SG, Zhu Q, Bowden A, Larson CR, de Bakker PM, et al. 2012. Biomechanical evaluation of the Total Facet Arthroplasty System<sup>®</sup> (TFAS<sup>®</sup>): loading as compared to a rigid posterior instrumentation system. *Eur. Spine J.* 21:1660–73
137. Zhu Q, Larson CR, Sjøvold SG, Rosler DM, Keynan O, et al. 2007. Biomechanical evaluation of the Total Facet Arthroplasty System: 3-dimensional kinematics. *Spine* 32:55–62
138. Phillips FM, Tzermiadianos MN, Voronov LI, Havey RM, Carandang G, et al. 2009. Effect of the Total Facet Arthroplasty System after complete laminectomy—facetectomy on the biomechanics of implanted and adjacent segments. *Spine J.* 9:96–102
139. Wilke HJ, Schmidt H, Werner K, Schmolz W, Drumm J. 2006. Biomechanical evaluation of a new total posterior-element replacement system. *Spine* 31:2790–96
140. McAfee P, Khoo LT, Pimenta L, Capuccino A, Sengoz A, et al. 2007. Treatment of lumbar spinal stenosis with a total posterior arthroplasty prosthesis: implant description, surgical technique, and a prospective report on 29 patients. *Neurosurg. Focus* 22:E13
141. Anekstein Y, Floman Y, Smorgick Y, Rand N, Millgram M, Mirovsky Y. 2015. Seven years follow-up for total lumbar facet joint replacement (TOPS) in the management of lumbar spinal stenosis and degenerative spondylolisthesis. *Eur. Spine J.* 24:2306–14
142. de Kelft EV. 2016. Lumbar facet resurfacing: first experience with the FENIX implant. *Clin. Spine Surg.* 29:E475–81
143. Makris EA, Gomoll AH, Malizos KN, Hu JC, Athanasiou KA. 2015. Repair and tissue engineering techniques for articular cartilage. *Nat. Rev. Rheumatol.* 11:21–34
144. Huey DJ, Hu JC, Athanasiou KA. 2012. Unlike bone, cartilage regeneration remains elusive. *Science* 338:917–21
145. Elder BD, Kim DH, Athanasiou KA. 2010. Developing an articular cartilage decellularization process toward facet joint cartilage replacement. *Neurosurgery* 66:722–27
146. Kelly TA, Ng KW, Wang CC, Ateshian GA, Hung CT. 2006. Spatial and temporal development of chondrocyte-seeded agarose constructs in free-swelling and dynamically loaded cultures. *J. Biomech.* 39:1489–97
147. Makris EA, MacBarb RF, Paschos NK, Hu JC, Athanasiou KA. 2014. Combined use of chondroitinase-ABC, TGF- $\beta$ 1, and collagen crosslinking agent lysyl oxidase to engineer functional neotissues for fibrocartilage repair. *Biomaterials* 35:6787–96
148. Natoli RM, Skaalure S, Bijlani S, Chen KX, Hu J, Athanasiou KA. 2010. Intracellular Na<sup>+</sup> and Ca<sup>2+</sup> modulation increases the tensile properties of developing engineered articular cartilage. *Arthritis Rheum.* 62:1097–107
149. Giannini S, Buda R, Vannini F, Cavallo M, Grigolo B. 2009. One-step bone marrow-derived cell transplantation in talar osteochondral lesions. *Clin. Orthop. Relat. Res.* 467:3307–20
150. Kon E, Filardo G, Roffi A, Andriolo L, Marcacci M. 2012. New trends for knee cartilage regeneration: from cell-free scaffolds to mesenchymal stem cells. *Curr. Rev. Musculoskelet. Med.* 5:236–43
151. Athanasiou K, Korvick D, Schenck R Jr. 1997. Biodegradable implants for the treatment of osteochondral defects in a goat model. *Tissue Eng.* 3:363–73



152. Chu CR, Douchis JS, Yoshioka M, Sah RL, Coutts RD, Amiel D. 1997. Osteochondral repair using perichondrial cells. A 1-year study in rabbits. *Clin. Orthop. Relat. Res.* 1997:220–29
153. McCormick F, Cole BJ, Nwachukwu B, Harris JD, Adkisson Iv HD, Farr J. 2013. Treatment of focal cartilage defects with a juvenile allogeneic 3-dimensional articular cartilage graft. *Oper. Tech. Sports Med.* 21:95–99
154. Fickert S, Gerwien P, Helmert B, Schattenberg T, Weckbach S, et al. 2012. One-year clinical and radiological results of a prospective, investigator-initiated trial examining a novel, purely autologous 3-dimensional autologous chondrocyte transplantation product in the knee. *Cartilage* 3:27–42
155. Makris EA, Responde DJ, Paschos NK, Hu JC, Athanasiou KA. 2014. Developing functional musculoskeletal tissues through hypoxia and lysyl oxidase–induced collagen cross-linking. *PNAS* 111:E4832–41
156. Elder B. 2009. Biomechanical, biochemical, and histological characterization of canine lumbar facet joint cartilage. *J. Neurosurg. Spine* 10:623–28
157. Gunja NJ, Huey DJ, James RA, Athanasiou KA. 2009. Effects of agarose mould compliance and surface roughness on self-assembled meniscus-shaped constructs. *J. Tissue Eng. Regen. Med.* 3:521–30
158. Pal GP, Routal RV. 2001. The orientation of the articular facets of the zygapophyseal joints at the cervical and upper thoracic region. *J. Anat.* 198:431–41
159. Butscher A, Bohner M, Hofmann S, Gauckler L, Müller R. 2011. Structural and material approaches to bone tissue engineering in powder-based three-dimensional printing. *Acta Biomater.* 7:907–20
160. Bose S, Vahabzadeh S, Bandyopadhyay A. 2013. Bone tissue engineering using 3D printing. *Mater. Today* 16:496–504
161. Panjabi MM, Oxland T, Takata K, Goel V, Duranceau J, Krag M. 1993. Articular facets of the human spine quantitative three-dimensional anatomy. *Spine* 18:1298–310
162. White AA 3rd. 1969. Analysis of the mechanics of the thoracic spine in man. An experimental study of autopsy specimens. *Acta Orthop. Scand. Suppl.* 127:1–105
163. White AA 3rd, Panjabi MM. 1978. The basic kinematics of the human spine. A review of past and current knowledge. *Spine* 3:12–20
164. Ivicsics MF, Bishop NE, Püschel K, Morlock MM, Huber G. 2014. Increase in facet joint loading after nucleotomy in the human lumbar spine. *J. Biomech.* 47:1712–17
165. Collie KO, Butler JB, Reyes PM, Newcomb AGUS, Theodore N, Crawford NR. 2013. Biomechanical evaluation of a metal-on-metal cervical intervertebral disc prosthesis. *Spine J.* 13:1640–49
166. Rohlmann A, Zander T, Schmidt H, Wilke H-J, Bergmann G. 2006. Analysis of the influence of disc degeneration on the mechanical behaviour of a lumbar motion segment using the finite element method. *J. Biomech.* 39:2484–90
167. Rousseau M-A, Bradford DS, Bertagnoli R, Hu SS, Lotz JC. 2006. Disc arthroplasty design influences intervertebral kinematics and facet forces. *Spine J.* 6:258–66
168. Ateshian GA, Soslowsky LJ, Mow VC. 1991. Quantitation of articular surface topography and cartilage thickness in knee joints using stereophotogrammetry. *J. Biomech.* 24:761–76
169. Shepherd DET, Seedhom BB. 1999. Thickness of human articular cartilage in joints of the lower limb. *Ann. Rheum. Dis.* 58:27–34
170. Athanasiou KA, Darling EM, DuRaine GD, Hu JC, Reddi AH. 2013. *Articular Cartilage*. Boca Raton, FL: CRC
171. Gratz KR, Wong VW, Chen AC, Fortier LA, Nixon AJ, Sah RL. 2006. Biomechanical assessment of tissue retrieved after in vivo cartilage defect repair: tensile modulus of repair tissue and integration with host cartilage. *J. Biomech.* 39:138–46
172. Shelburne KB, Torry MR, Pandy MG. 2005. Muscle, ligament, and joint-contact forces at the knee during walking. *Med. Sci. Sports Exerc.* 37:1948–56
173. Natl. Cent. Health Stat. 2010. *National Ambulatory Medical Care Survey: 2010 Summary Tables*. Washington, DC: Natl. Cent. Health Stat. [http://www.cdc.gov/nchs/ahcd/web\\_tables.htm](http://www.cdc.gov/nchs/ahcd/web_tables.htm)

