

UC Irvine

UC Irvine Previously Published Works

Title

Phase IIA trial testing erlotinib as an intervention against intraductal pancreatic mucinous neoplasms.

Permalink

<https://escholarship.org/uc/item/3934z1d4>

Journal

Cancer prevention research (Philadelphia, Pa.), 4(4)

ISSN

1940-6215

Authors

Lipkin, Steven
Lee, John
Imagawa, David
[et al.](#)

Publication Date

2011-04-01

Supplemental Material

<https://escholarship.org/uc/item/3934z1d4#supplemental>

Peer reviewed

Phase IIA Trial Testing Erlotinib as an Intervention against Intraductal Pancreatic Mucinous Neoplasms

Steven Lipkin¹, John Lee¹, David Imagawa¹, Stephen M. Hewitt², Chris Tucker³, Jason A. Zell¹, Vanessa Wong¹, Angela Garcia¹, Rachel Gonzalez¹, Gary Della Zanna⁴, Ellen Richmond⁴, L.M. Rodriguez⁴, M. Bigg⁵, F. Schnoll-Sussmans⁵, and Frank Meyskens¹

Intraductal papillary mucinous neoplasms (IPMN) are a distinct type of precursor lesions that cause about 5% of pancreatic adenocarcinoma (1, 2). Four-year survival rates of 40% to 75% are reported (3–7). There is currently no chemotherapy specifically approved for treating IPMNs. The number of IPMN cases has significantly increased over the last decade (8).

Erlotinib (Tarceva) is an orally active epidermal growth factor receptor (EGFR) inhibitor. Combined erlotinib/gemcitabine therapy improves overall survival and progression-free survival versus gemcitabine alone in pancreatic adenocarcinoma patients (9). However, whether erlotinib and its active metabolite achieve therapeutic levels in pancreatic tissue has never been evaluated. Preclinical work shows that EGFR is important in IPMN tumorigenesis (10, 11). To test whether EGFR inhibition is efficacious in the treatment of IPMNs, we performed a phase IIA observational single-arm study of 100 mg/d of erlotinib in patients with IPMNs (ClinicalTrials.gov identifier: NCT00482625). The primary hypothesis was that erlotinib decreases tumor protein levels of MUC5AC, a biomarker of activated EGFR, which is highly expressed in IPMNs (12, 13; Supplementary Fig. S1). Secondary outcomes included safety in IPMN patients and pharmacokinetics in pancreatic tissue. The latter would be consistent with the proposed mechanism of action that erlotinib acts intrinsically on the IPMN cells, rather than through an indirect mechanism such as activation of immune surveillance. Inclusion/exclusion criteria for patient selection are in Supplementary Table S1. Participants were required to have pretreatment IPMN endoscopic ultrasound-fine needle aspiration (EUS-FNA) core biopsy tissue for comparison with posttreatment tissue. All patients underwent EUS using a GF-UC160P curvilinear array echoendoscope with Prosound Alpha 10 ultrasound processor. FNA of solid lesions used a 22-g EchoTip needle and 10 mL of negative suction. IPMN cell

blocks were fixed, embedded in paraffin, and processed in the same manner as postsurgical specimens. Participants received 100 mg erlotinib for 21 to 42 days before their scheduled surgical IPMN resection. After partial pancreas resection, pre- and posttreatment IPMN MUC5AC protein levels were compared. Resected pancreatic tissue was also used to quantify pharmacokinetics of erlotinib and OSI-420, its major active metabolite, which had not previously been performed. Six participants were enrolled, 5 were treated with erlotinib 100 mg for 21 to 42 days, and 4 completed the trial and had pre and posttreatment tissue for analysis. One participant, a 54-year-old Caucasian man, who presented with abdominal pain and had an IPMN of 3-cm low-density mass in head of pancreas (Supplementary Fig. S2) had a complete clinical response, as assessed by pretreatment CT (computed tomography) scan and postresection pathologic analysis of the resected pancreas. No mass lesion consistent with residual IPMN was present at resection; however, residual carcinoma in situ was identified in the resected specimen. As a result, there was insufficient posttreatment tissue for evaluation of posttreatment MUC5AC protein levels. Importantly, the patient remains in complete remission 2.5 years after erlotinib neoadjuvant therapy and surgery. Three patients had usable tissue samples for pre- and post-erlotinib treatment analysis of MUC5AC. Immunohistochemistry for MUC5AC showed a reduced number of positive IPMN cells and staining intensity in 2 of 3 patient-matched tissue comparisons (Fig. 1). For the third patient, pretreatment biopsy tissue was insufficient for analysis and not scored.

Pharmacokinetics of pancreatic erlotinib were performed in 4 participants (Supplementary Table S2). Concentrations were determined in matched plasma and pancreatic tissue by HPLC-MS/MS (high-performance liquid chromatography-mass spectrometry) as previously described (14). Erlotinib (OSI-774) and its major active metabolite (OSI-420) were detected in preoperative plasma and postresection pancreas. These data are consistent with a direct mechanism EGFR inhibition by erlotinib in pancreatic adenocarcinoma and IPMN, rather than indirect mechanisms. The highest plasma and pancreatic tissue concentrations (plasma 754 ng/dL and pancreatic tissue 360 ng/mL) were in the participant with the complete clinical response. The concentration of erlotinib in pancreatic tissue was more than 4 times versus the lowest concentration. The concentration of major active metabolite OSI-420 almost double that of the lowest concentration sample.

No patient terminated the trial early and no unanticipated grade 3 and 4 adverse events were reported. In

Authors' Affiliations: ¹Department of Medicine and Chao Family NCI Designated Comprehensive Cancer Center, University of California Irvine, Irvine, California; ²Laboratory of Pathology, National Cancer Institute, Bethesda, Maryland; ³OSI Pharmaceuticals, Boulder, Colorado; ⁴Division of Cancer Prevention, National Cancer Institute, Rockville, Maryland; and ⁵Division of Gastroenterology/Hepatology, Department of Medicine, Weill Cornell Medical College, New York

Note: Supplementary data for this article are available at Cancer Prevention Research Online (<http://cancerprevres.aacrjournals.org/>).

Corresponding Author: Steven Lipkin, Weill Cornell Medical College, 718 Caspary, 541 East 71st Street, New York, NY 10021. Phone: 212-774-7160; Fax: 212-774-7167; E-mail: stl2012@med.cornell.edu

doi: 10.1158/1940-6207.CAPR-10-0373

©2011 American Association for Cancer Research.

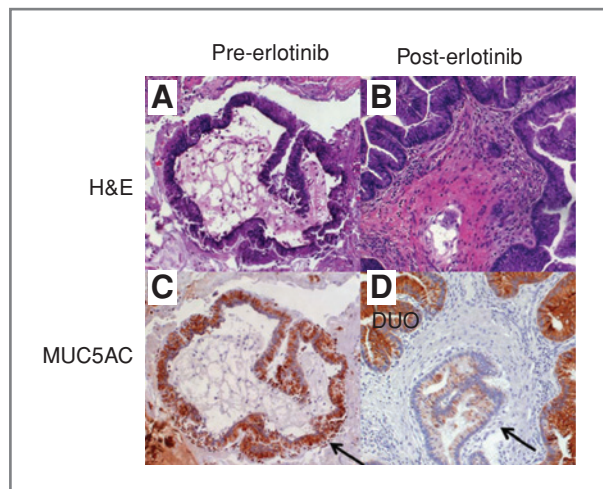


Figure 1. Hematoxylin and eosin (H&E) and MUC5AC immunohistochemistry on (A and C) pre- and (B and D) post-erlotinib pancreatic specimens. IPMN tissue is indicated by the arrow. DUO, normal duodenal epithelium.

particular, no significant issues with grade 3 and 4 rash were noted. One patient had a grade 1 acneiform rash. Two patients had grade 1 dry skin, 2 had grade 1 decreased appetite, 1 had grade 1 headache, one had grade 2 diarrhea, and 1 had grade 1 insomnia. Overall, 100 mg erlotinib was well tolerated by patients and no unanticipated drug-related adverse events were seen. The one participant with grade 2 rash also had the highest pancreatic tissue erlotinib and OSI-420 levels and the complete clinical response.

This study was limited by the number of evaluable trial participants and does not allow definitive conclu-

sions as to the primary hypothesis that 100 mg erlotinib reduces IPMN MUC5AC protein levels. Our results show that of 4 participants who completed the protocol, 3 had evaluable tissue. Of these 3 participants with evaluable tissue, 2 had reduced MUC5AC levels, consistent with a reduction of activated EGFR in IPMN and 1 had a complete clinical response with only microscopic disease detectable after erlotinib. This participant also developed grade 2 rash and had the highest serum and pancreatic concentrations of erlotinib and its active metabolite OSI-420.

There is currently no approved medical therapy to treat IPMN. Because of this, there is great variance in the standard of care for IPMNs. Some U.S. centers approach any pancreatic mass (including adenocarcinomas, IPMNs, neuroendocrine tumors, mucinous cystic neoplasms and other tumor types) as potentially harboring malignancy and resect the entire pancreas without pre-diagnostic biopsy. At the other end, on the basis of the same literature, other centers perform watchful waiting only. Overall, our data are consistent with potential efficacy of erlotinib in the treatment of IPMNs and revealed no unforeseen safety issues in IPMN patients. These data support further investigation of erlotinib and other EGFR inhibitors for the treatment of IPMNs in larger, multicenter trials.

Disclosure of Potential Conflicts of Interest

Chris Tucker is an employee of Astellas Pharmaceuticals.

Received December 11, 2010; revised February 9, 2011; accepted February 23, 2011; published online April 4, 2011.

References

- Hruban RH, Takaori K, Klimstra DS, Adsay NV, Albores-Saavedra J, Biankin AV, et al. An illustrated consensus on the classification of pancreatic intraepithelial neoplasia and intraductal papillary mucinous neoplasms. *Am J Surg Pathol* 2004;28:977-87.
- Takaori K, Hruban RH, Maitra A, Tanigawa N. Pancreatic intraepithelial neoplasia. *Pancreas* 2004;28:257-62.
- Sohn TA, Yeo CJ, Cameron JL, Hruban RH, Fukushima N, Campbell KA, et al. Intraductal papillary mucinous neoplasms of the pancreas: an updated experience. *Ann Surg* 2004;239:788-97; discussion 797-9.
- Sohn TA, Yeo CJ, Cameron JL, Iacobuzio-Donahue CA, Hruban RH, Lillmoie KD. Intraductal papillary mucinous neoplasms of the pancreas: an increasingly recognized clinicopathologic entity. *Ann Surg* 2001;234:313-21; discussion 321-2.
- Chari ST, Yadav D, Smyrk TC, DiMagno EP, Miller LJ, Raimondo M, et al. Study of recurrence after surgical resection of intraductal papillary mucinous neoplasm of the pancreas. *Gastroenterology* 2002;123:1500-7.
- Zell JA, Rhee JM, Ziogas A, Lipkin SM, Anton-Culver H. Race, socioeconomic status, treatment, and survival time among pancreatic cancer cases in California. *Cancer Epidemiol Biomarkers Prev* 2007;16:546-52.
- Le H, Ziogas A, Rhee JM, Lee JG, Lipkin SM, Zell JA. A population-based, descriptive analysis of malignant intraductal papillary mucinous neoplasms of the pancreas. *Cancer Epidemiol Biomarkers Prev* 2008;17:2737-41.
- Adsay NV. The "new kid on the block": intraductal papillary mucinous neoplasms of the pancreas: current concepts and controversies. *Surgery* 2003;133:459-63.
- Herbst RS, Prager D, Hermann R, Fehrenbacher L, Johnson BE, Sandler A, et al. TRIBUTE: a phase III trial of erlotinib hydrochloride (OSI-774) combined with carboplatin and paclitaxel chemotherapy in advanced non-small-cell lung cancer. *J Clin Oncol* 2005;23:5892-9.
- Siveke JT, Einwächter H, Sipos B, Lubeseder-Martellato C, Klöppel G, Schmid RM. Concomitant pancreatic activation of Kras(G12D) and Tgfa results in cystic papillary neoplasms reminiscent of human IPMN. *Cancer Cell* 2007;12:266-79.
- Chadwick B, Willmore-Payne C, Tripp S, Layfield LJ, Hirschowitz S, Holden J. Histologic, immunohistochemical, and molecular classification of 52 IPMNs of the pancreas. *Appl Immunohistochem Mol Morphol* 2009;17:31-9.
- Perrais M, Pigny P, Copin MC, Aubert JP, Van Seuning I. Induction of MUC2 and MUC5AC mucins by factors of the epidermal growth factor (EGF) family is mediated by EGF receptor/Ras/Raf/extracellular signal-regulated kinase cascade and Sp1. *J Biol Chem* 2002;277:32258-67.
- Guzman K, Randell SH, Nettesheim P. Epidermal growth factor regulates expression of the mucous phenotype of rat tracheal epithelial cells. *Biochem Biophys Res Commun* 1995;217:412-8.
- Hamilton M, Wolf JL, Rusk J, Beard SE, Clark GM, Witt K, et al. Effects of smoking on the pharmacokinetics of erlotinib. *Clin Cancer Res* 2006;12:2166-71.

Cancer Prevention Research



Phase IIA Trial Testing Erlotinib as an Intervention against Intraductal Pancreatic Mucinous Neoplasms

Steven Lipkin, John Lee, David Imagawa, et al.

Cancer Prev Res 2011;4:512-513.

Updated version Access the most recent version of this article at:
<http://cancerpreventionresearch.aacrjournals.org/content/4/4/512>

Supplementary Material Access the most recent supplemental material at:
<http://cancerpreventionresearch.aacrjournals.org/content/suppl/2011/04/04/4.4.512.DC1.html>

Cited Articles This article cites by 14 articles, 5 of which you can access for free at:
<http://cancerpreventionresearch.aacrjournals.org/content/4/4/512.full.html#ref-list-1>

Citing articles This article has been cited by 2 HighWire-hosted articles. Access the articles at:
<http://cancerpreventionresearch.aacrjournals.org/content/4/4/512.full.html#related-urls>

E-mail alerts [Sign up to receive free email-alerts](#) related to this article or journal.

Reprints and Subscriptions To order reprints of this article or to subscribe to the journal, contact the AACR Publications Department at pubs@aacr.org.

Permissions To request permission to re-use all or part of this article, contact the AACR Publications Department at permissions@aacr.org.