

# UCSF

## UC San Francisco Previously Published Works

### Title

Complement Factor I Gene Variant as a Treatable Cause of Recurrent Aseptic Neutrophilic Meningitis: A Case Report.

### Permalink

<https://escholarship.org/uc/item/38b7q46r>

### Journal

Neurology(R) neuroimmunology & neuroinflammation, 10(5)

### ISSN

2332-7812

### Authors

Rolfes, Mary

Harroud, Adil

Zorn, Kelsey C

et al.

### Publication Date

2023-09-01

### DOI

10.1212/nxi.0000000000200121

### Copyright Information

This work is made available under the terms of a Creative Commons Attribution-NonCommercial-NoDerivatives License, available at

<https://creativecommons.org/licenses/by-nc-nd/4.0/>

Peer reviewed

# Complement Factor I Gene Variant as a Treatable Cause of Recurrent Aseptic Neutrophilic Meningitis

## A Case Report

Mary Rolfes, MD, Adil Harroud, MD, Kelsey C. Zorn, BA, MHS, Asritha Tubati, BS, Charles Omura, BS, MS, Kenneth Kurtz, MD, Mehrdad Matloubian, MD, Amy Berger, MD, Charles Y. Chiu, MD, Michael R. Wilson, MD,\* and Prashanth S. Ramachandran, MBBS\*

### Correspondence

Dr. Ramachandran  
pramachandra@unimelb.edu.au

*Neurol Neuroimmunol Neuroinflamm* 2023;10:e200121. doi:10.1212/NXI.0000000000200121

## Abstract

Mutations in the complement factor I (*CFI*) gene have previously been identified as causes of recurrent CNS inflammation. We present a case of a 26-year-old man with 18 episodes of recurrent meningitis, who had a variant in *CFI*(c.859G>A,p.Gly287Arg) not previously associated with neurologic manifestations. He achieved remission with canakinumab, a human monoclonal antibody targeted at interleukin-1 beta.

---

\*These authors contributed equally to this work as senior authors.

From the Weill Institute for Neurosciences (M.R., M.R.W.), Department of Neurology, University of California, San Francisco; Montreal Neurological Institute and Hospital (A.H.), Department of Neurology and Neurosurgery, McGill University, Montréal, QC, Canada; Department of Biochemistry and Biophysics (K.C.Z., A.T.); Department of Laboratory Medicine (C.O., C.Y.C.); Kaiser Permanente Santa Rosa Medical Center (K.K.) Department of Medicine (M.M.), Division of Rheumatology; Department of Medicine (A.B.), Molecular Medicine Consult Service; Department of Medicine (C.Y.C.), Division of Infectious Diseases, University of California, San Francisco; The Peter Doherty Institute for Infection and Immunity (P.S.R.); Department of Neurology (P.S.R.), Royal Melbourne Hospital; and Department of Neurology (P.S.R.), St. Vincent's Hospital, University of Melbourne, Australia.

Go to [Neurology.org/NN](https://Neurology.org/NN) for full disclosures. Funding information is provided at the end of the article.

The Article Processing Charge was funded by the authors.

This is an open access article distributed under the terms of the Creative Commons Attribution-NonCommercial-NoDerivatives License 4.0 (CC BY-NC-ND), which permits downloading and sharing the work provided it is properly cited. The work cannot be changed in any way or used commercially without permission from the journal.

## Glossary

**aHUS** = atypical hemolytic-uremic syndrome; **AMD** = age-related macular degeneration; **ED** = emergency department; **HSV-1** = herpes simplex virus type 1; **HSV-2** = herpes simplex virus type 2; **LDLRA** = low-density lipoprotein receptor type A; **LP** = lumbar puncture; **MAC** = membrane attack complex; **mNGS** = metagenomic next-generation sequencing; **PMNs** = polymorphonuclear leukocytes; **RBC** = red blood cell; **WBC** = white blood cell.

## Case

An 18-year-old man presented to the emergency department (ED) with 4 days of rigors, sweats, and new-onset headaches associated with photophobia and nausea.<sup>1-4</sup> His medical history included recurrent painful gum and hard palate ulcers as early as 10 years of age, allergic rhinitis, and asthma. He denied substance use, animal exposures, and recent travel. His monozygotic twin brother had been recently diagnosed with ulcerative colitis and had a history of oral ulcers and 1 episode of presumed aseptic meningitis, though never confirmed by CSF analyses.

Vitals were notable for a temperature of 38.4°C. The remainder of his general and neurologic examinations was normal except for neck stiffness, prompting a lumbar puncture (LP). CSF analyses demonstrated cloudy colorless fluid, a total white blood cell (WBC) count of 2,201/μL (reference range 0–5/μL) with a differential of 68% polymorphonuclear leukocytes (PMNs) and 31% lymphocytes, a red blood cell (RBC) count of 14/μL (reference range 0–5/μL), glucose of 44 mg/dL (reference range 40–70 mg/dL), and protein of 142 mg/dL (reference range 15–45 mg/dL). Gram stain, bacterial and fungal cultures, cryptococcal antigen, and herpes simplex virus type 1 (HSV-1) and HSV type 2 (HSV-2), and enterovirus PCR showed negative results. Basic laboratory values were normal. He was treated empirically with IV methylprednisolone, vancomycin, and meropenem for presumed bacterial meningitis. Blood cultures showed negative results, and antibiotics were discontinued. Repeat LP 3 days later demonstrated WBC of 877/μL with a differential of 94% lymphocytes, RBC of 47/μL, glucose of 48 mg/dL, and protein of 42 mg/dL. He represented to the ED 3 months later with headaches and a temperature of 38°C, but an LP was not performed, and he was discharged with supportive care.

The patient remained healthy until 2 years later when he presented to the ED with similar symptoms, which responded well to prednisone. Over the subsequent 2 years, he continued to have attacks of headaches and low-grade fevers with repeat LPs demonstrating aseptic neutrophilic meningitis (Figure 1). Additional infectious testing including CSF metagenomic next-generation sequencing (mNGS), rheumatologic testing, and autoimmune testing including autoimmune encephalopathy panel and aquaporin-4 antibodies was unrevealing. A full body PET scan evaluating for malignancy was normal.

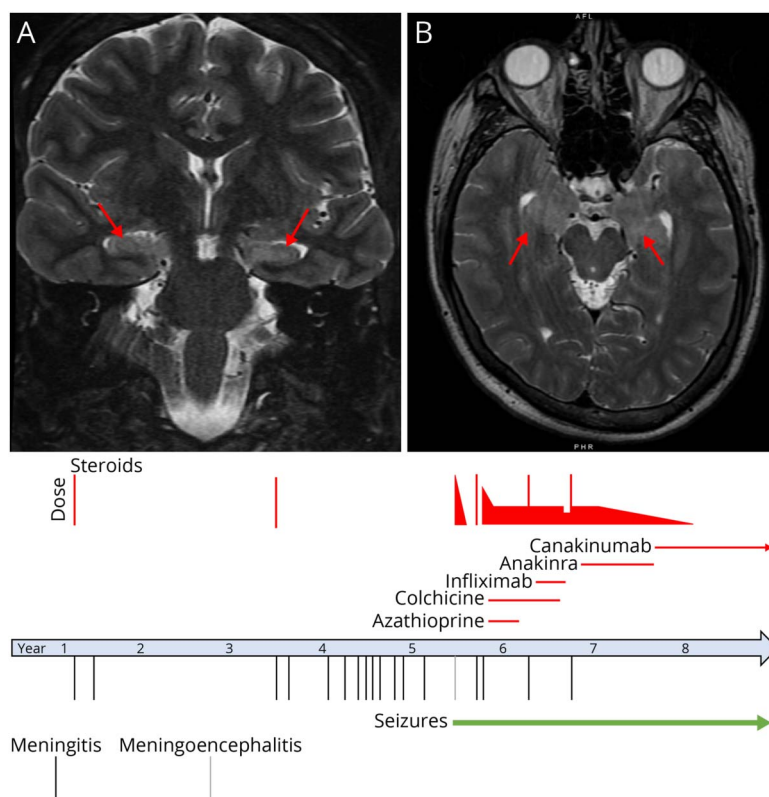
Four years after his initial presentation, the patient presented with a first-time generalized tonic-clonic seizure. He was febrile,

somnolent, and disoriented immediately postseizure. While several prior brain MRIs were normal, a repeat brain MRI during this admission showed symmetric T2 signal abnormalities in the hippocampi (Figure 1). His mental status improved in the acute period, but he continued to have cognitive deficits with neuropsychological testing demonstrating new deficits in verbal discrimination, attention, and working memory. He had ongoing temporal lobe seizures that decreased in frequency with the initiation of valproic acid and lamotrigine. A follow-up brain MRI 1 month later was normal.

During and independent of attacks, the patient also developed painful ulcers on the base of the mouth and inner lips. During 1 attack, he developed a painful scrotal ulcer. HSV-1 and HSV-2 swabs showed negative results, and biopsies were benign. He also had a painful erythematous lesion that would wax and wane on his right lateral leg. Given concern for neuro-Behçet disease, treatment with colchicine and azathioprine was initiated, which improved the ulcers but did not prevent the meningitis flares. During flares, the patient was treated with 80 mg of oral pulse prednisone for 5 days with rapid symptom resolution, followed by a taper. However, he became steroid dependent with disease flares when weaned under 20 mg of prednisone daily. Due to ongoing attacks, he was transitioned from azathioprine to infliximab for 5 months without improvement (Figure 1).

His family history and phenotype marked by recurrent ulcers and aseptic meningitis, along with extensive negative infectious, rheumatologic, and malignancy workup, raised concern for a monogenic autoinflammatory condition. Whole-exome sequencing revealed a nonsynonymous variant in *CFI* (c.859G>A, p.Gly287Arg). Subsequent genetic testing in his brother confirmed the presence of the same variant. The variant is rare (allele frequency  $8.5 \times 10^{-5}$  in Genomic Aggregation Database non-Finnish Europeans)<sup>5</sup> and consistently predicted in silico to be deleterious (Sorting Intolerant from Tolerant score 0, range 0–1 with <0.05 considered deleterious; PolyPhen score 1.0, range 0.0–1.0 with >0.908 considered probably damaging; and Combined Annotation-Dependent Depletion PHRED score 23.2, indicating top 1% of most deleterious variants).<sup>6</sup> It is located on the calcium-binding low-density lipoprotein receptor type A (LDLRA) domain, which likely plays a role in the protein's structure.<sup>7</sup> Notably, several reports describe alternative mutations in *CFI* with phenotypes of recurrent aseptic meningitis and encephalitis and other systemic

**Figure 1** Brain MRI and Timeline of Meningitis Attacks and Treatment



Coronal T2-weighted (A) and axial T2-weighted (B) images demonstrating symmetric T2 signal hyperintensities in the hippocampi (red arrows) which were nonenhancing.

complications responsive to IL-1 blockade.<sup>1,8</sup> Based on his mutation, functional complement studies were performed, including total classical complement pathway activity (CH50), alternative complement pathway activity (AH50), C3, C4, C3c, and C1q component concentrations, and Factor levels I, B, and H, all of which were normal.

In this context, anakinra, a recombinant IL-1 receptor antagonist, was initiated with a slow prednisone wean. Given the injection site pain and rash, the patient was subsequently transitioned to canakinumab and successfully weaned off prednisone. He remains on 150 mg of canakinumab monthly and at the last follow-up had no recurrence of ulcers or meningitis in more than 20 months (Figure 1).

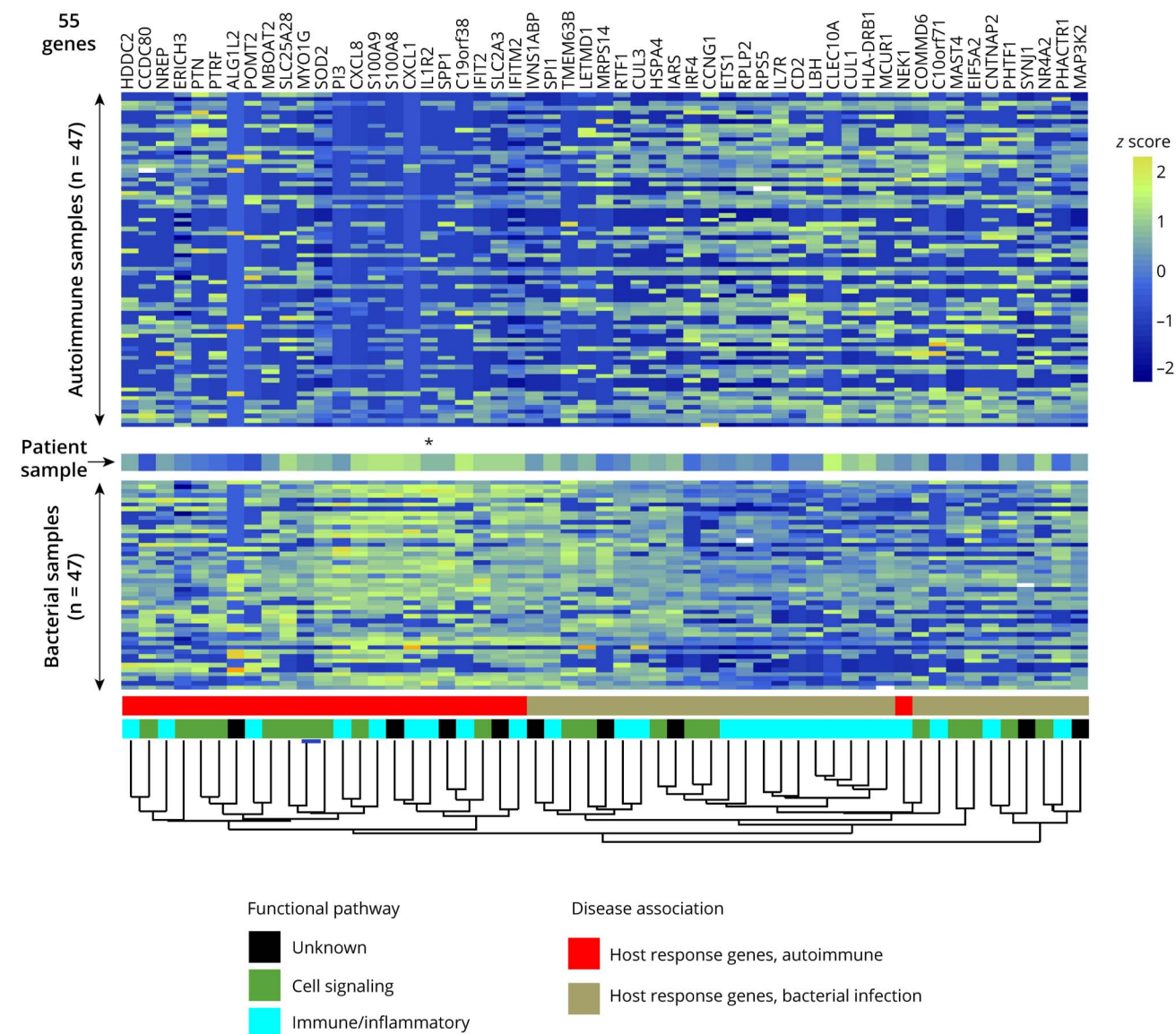
To further assess the immune response of our patient, we analyzed the host gene expression data generated by the clinical mNGS assay from whole CSF collected during an acute meningitis episode and compared it with that obtained from a cohort of 47 patients with autoimmune encephalitis and 47 patients with bacterial meningitis. Unsupervised hierarchical clustering demonstrated our patient's gene expression pattern aligned more closely with that of the bacterial meningitis cohort (Figure 2). Notably, our patient also showed an elevated expression of IL-1 receptor 2 (IL-1R2), a

protein that inhibits the effects of IL-1 and which may have been upregulated in the context of increased inflammation,<sup>9</sup> thus potentially explaining the successful treatment with IL-1 blockade (Figure 2, asterisk).

## Discussion

We describe a patient with more than 15 episodes of aseptic neutrophilic meningitis with concurrent mouth and genital ulcers and subsequent meningoencephalitis, seizures, and persistent cognitive deficits who was found to have a non-synonymous heterozygous mutation in *CFI* p.Gly287Arg. CFI is a critical inhibitor of the classical and alternative complement pathways by cleaving C3a and C3b.<sup>7</sup> Perturbations lead to uncontrolled activation of the complement system and subsequent increased formation of the membrane attack complex (MAC).<sup>10</sup> Complete *CFI* deficiency, a recessive disorder, is exceedingly rare and classically presents with severe bacterial infections, including CNS infections with encapsulated organisms.<sup>11</sup> Emerging evidence suggests inappropriate activation of the complement cascade secondary to mutations in *CFI* may play a role in systemic autoinflammatory diseases such as atypical hemolytic-uremic syndrome (aHUS),<sup>10,12-14</sup> age-related macular degeneration (AMD),<sup>15,16</sup> and leukocytoclastic vasculitis.<sup>17</sup>

**Figure 2** Heat Map Showing the CSF Host Transcriptional Profile of the Patient Compared With Profiles From Patients With Autoimmune Encephalitis or Bacterial Meningitis



Normalized RNA expression levels, as arranged by unsupervised hierarchical clustering reflect gene overexpression (light green) and underexpression (dark blue). The asterisk denotes the column corresponding to the IL1R2 gene, which is overexpressed in the patient and bacterial meningitis samples relative to the autoimmune samples.

Inflammatory neurologic disorders including recurrent aseptic meningitis,<sup>2</sup> meningoencephalitis,<sup>3</sup> and acute hemorrhagic<sup>8</sup> and nonhemorrhagic leukoencephalitis<sup>4</sup> have also been associated with mutations in the *CFI* gene. To date, there are more than 100 different pathologic *CFI* mutations with single heterozygous variants most frequently reported in cases of autoimmunity.<sup>18</sup>

The heterozygous mutation in this patient was classified as a variant of unknown significance in accordance with ACMG guidelines, but computational and functional evidence with multiple in silico models predict that it is likely pathogenic.<sup>5,6</sup> Furthermore, the same variant was previously associated with

multiple cases of aHUS<sup>13,14</sup> and AMD where radial immunodiffusion documented low *CFI* serum levels in 3 heterozygous variant carriers.<sup>15,16</sup> Notably, a recent study reported that epithelial cells transfected with mutant (p.Gly287Arg) *CFI* plasmids expressed lower levels of recombinant *CFI* compared with those transfected with wild type in supernatants (49%) and lysates (26%) by ELISA and confirmed on Western blot.<sup>19</sup> Another study found evidence of excessive activation in complement alternative pathway functional assays in a patient with aHUS and p.Gly287Arg.<sup>13</sup> *CFI* is also characterized by intolerance to functional genetic variation, as indicated by a depletion of loss-of-function mutations (LoFtool score 0.157, range 0–1 with most haplo insufficient genes between 0 and 0.2),<sup>20</sup> suggesting



that haploinsufficiency is the underlying mechanism in heterozygous patients such as ours. In short, the variant identified in our patient is rare, predicted to be deleterious, reported in related conditions, and is associated with lower *CFI* levels and possibly complement pathway disinhibition.

Our patient's functional complement testing, component concentrations, and factor levels were normal, with the important caveat that these were only completed while he was on immunosuppressive therapy, which may have affected the results. The patient's brother had normal functional complement testing, though testing was also performed while he was on immunosuppressive therapy (vedolizumab) for his ulcerative colitis. Furthermore, normal circulating complement levels have been shown in other cases of both complete and partial *CFI* deficiencies.<sup>3,4,19,21</sup> Therefore, normal complement testing, especially outside the acute episodes, should not rule out a diagnosis of *CFI*-related disease.

Using RNA-seq data generated from the clinical mNGS assay, CSF gene expression resembled that of the bacterial meningitis cohort, suggesting similar inflammatory mechanisms including complement activation, which is known to occur in bacterial meningitis.<sup>22</sup> Of importance, IL-1 receptor 2 (*IL1R2*) expression was upregulated, potentially as a negative feedback loop in response to IL-1 production.<sup>23</sup> IL-1 upregulation is a key feature of autoinflammatory syndromes, playing a role in the cytokine response responsible for recurrent episodes of inflammation.<sup>1,24,25</sup> While the underlying link between the complement system and IL-1 $\beta$  remains unclear, it is plausible that dysregulation of the complement system and increase in the MAC may trigger the subsequent inflammatory response leading to upregulation of IL-1 $\beta$  through complex interactions with NF- $\kappa$ B signaling and the inflammasome.<sup>26,27</sup>

Our patient experienced recurrent attacks when steroids were weaned, which is consistent with those observed in other reports.<sup>8</sup> Others have tried IV immunoglobulins,<sup>8</sup> plasma exchange,<sup>3,4</sup> cyclophosphamide,<sup>3</sup> rituximab,<sup>4</sup> and anakinra<sup>8</sup> with variable success. Our patient finally achieved an extended and ongoing disease remission with IL-1 $\beta$  blockade, supporting the underlying role of IL-1 activation in disease pathogenesis and further supporting the conclusion that the mutation in the *CFI* gene was causative. In this case, canakinumab was successfully used to treat CNS inflammation secondary to a *CFI* mutation.

Before the genetic diagnosis was made, we considered whether the patient had a rare phenotype of neuro-Behçet disease characterized by recurrent ulcers, meningitis, and CSF with a neutrophilic pleocytosis.<sup>27</sup> However, aseptic meningitis is rarely the sole manifestation of neuro-Behçet disease, and our patient lacked other characteristic features: neuroimaging did not show mesodiencephalic, cerebellar, or basal ganglia lesions or vasculitis, he had no evidence of peripheral nervous system involvement, his CSF pleocytosis was much higher than is typical, and he did not have the HLA-B51 genotype.<sup>28</sup> Similarly, neuro-

Sweet disease is known to cause recurrent neutrophilic meningitis and skin changes, but our patient's skin biopsies did not show the characteristic neutrophilic infiltration. Full body PET/CT and HLA testing were also not supportive.<sup>29</sup> Neurosarcoidosis was considered, but overall believed to be less likely, given the recurrent discrete bouts of neutrophilic meningitis without nodular leptomeningeal abnormalities. It is important to note that neutrophilic-predominant CSF is uncommon in noninfectious conditions, and therefore, a neutrophilic CSF in the absence of an infectious etiology should prompt clinicians to consider an autoinflammatory condition.

In summary, we present a case of a patient with a heterozygous nonsynonymous mutation in the *CFI* gene not previously associated with neurologic manifestations who presented with more than 15 episodes of aseptic neutrophilic meningitis and later meningoencephalitis who ultimately achieved an extended and ongoing clinical remission with canakinumab. Our patient's phenotype concerning for an autoinflammatory condition that was responsive to steroids and IL-1 $\beta$  inhibition and his extensive negative infectious, rheumatologic, and malignant evaluations lead us to believe the *CFI* mutation was causative. Diagnosis of adult-onset autoinflammatory conditions remains challenging, given the underrecognition of the CNS complications of monogenic autoinflammatory conditions and their variable clinical phenotypes. Our case adds to the emerging literature supporting the role of *CFI* mutations in fulminant neuroinflammation that can mimic bacterial and other causes of infectious meningitis and highlights the importance of genetic testing in patients with uncertain diagnoses because it may identify treatable conditions. Additional research is needed to further investigate the underlying mechanisms by which *CFI* gene dysfunction can lead to CNS inflammation.

## Study Funding

The authors report no targeted funding.

## Disclosure

The authors report no relevant disclosures. Go to Neurology.org/NN for full disclosures.

## Publication History

Received by *Neurology: Neuroimmunology & Neuroinflammation* December 22, 2022. Accepted in final form March 10, 2023. Submitted and externally peer reviewed. The handling editor was Editor Josep O. Dalmau, MD, PhD, FAAN.

## Appendix Authors

Name	Location	Contribution
Mary Rolfes, MD	Weill Institute for Neurosciences, Department of Neurology, University of California, San Francisco	Drafting/revision of the article for content, including medical writing for content; major role in the acquisition of data; study concept or design; and analysis or interpretation of data

Continued

## Appendix (continued)

Name	Location	Contribution
<b>Adil Harroud, MD</b>	Montreal Neurological Institute and Hospital, Department of Neurology and Neurosurgery, McGill University, Montréal, QC, Canada	Drafting/revision of the article for content, including medical writing for content; analysis or interpretation of data
<b>Kelsey C. Zorn, BA, MHS</b>	Department of Biochemistry and Biophysics, University of California, San Francisco	Drafting/revision of the article for content, including medical writing for content; major role in the acquisition of data
<b>Asritha Tubati, BS</b>	Department of Biochemistry and Biophysics, University of California, San Francisco	Major role in the acquisition of data
<b>Charles Omura, BS, MS</b>	Department of Biochemistry and Biophysics, University of California, San Francisco	Drafting/revision of the article for content, including medical writing for content; analysis or interpretation of data
<b>Kenneth Kurtz, MD</b>	Department of Laboratory Medicine, University of California, San Francisco	Drafting/revision of the article for content, including medical writing for content
<b>Mehrdad Matloubian, MD</b>	Kaiser Permanente Santa Rosa Medical Center	Drafting/revision of the article for content, including medical writing for content; analysis or interpretation of data
<b>Amy Berger, MD</b>	Department of Medicine, Division of Rheumatology, University of California, San Francisco	Drafting/revision of the article for content, including medical writing for content; analysis or interpretation of data
<b>Charles Y. Chiu, MD</b>	Department of Laboratory Medicine; Department of Medicine, Division of Infectious Diseases, University of California, San Francisco	Drafting/revision of the article for content, including medical writing for content; analysis or interpretation of data
<b>Michael R. Wilson, MD</b>	Weill Institute for Neurosciences, Department of Neurology, University of California, San Francisco	Drafting/revision of the article for content, including medical writing for content; major role in the acquisition of data; study concept or design; and analysis or interpretation of data; additional contributions: cosenior author
<b>Prashanth S. Ramachandran, MBBS</b>	The Peter Doherty Institute for Infection and Immunity; Department of Neurology, Royal Melbourne Hospital; Department of Neurology, St. Vincent's Hospital, University of Melbourne, Australia	Drafting/revision of the article for content, including medical writing for content; major role in the acquisition of data; study concept or design; and analysis or interpretation of data

## References

- Diprose W, Jordan A, Anderson NE. Autoinflammatory syndromes in neurology: when our first line of defence misbehaves. *Prac Neurol*. 2022;22:145-153.
- Bonnin AJ, Zeitz HJ, Gewurz A. Complement factor I deficiency with recurrent aseptic meningitis. *Arch Intern Med*. 1993;153(11):1380-1383.
- Haerynck F, Stordeer P, Vandewalle J, et al. Complete factor I deficiency due to dysfunctional factor I with recurrent aseptic meningo-encephalitis. *J Clin Immunol*. 2013;33(8):1293-1301.
- Altmann T, Torvell M, Owens S, et al. Complement factor I deficiency: a potentially treatable cause of fulminant cerebral inflammation. *Neuro Neuroimmunol Neuro-inflamm*. 2020;7(3):e689.
- Karczewski KJ, Francioli LC, Tiao G, et al. The mutational constraint spectrum quantified from variation in 141,456 humans. *Nature*. 2020;581:434-443.
- Cunningham F, Allen JE, Allen J, et al. Ensembl 2022. *Nucleic Acids Res*. 2022;50(D1):D988-D995.
- Roversi P, Johnson S, Caesar J, et al. Structural basis for complement factor I control and its disease-associated sequence polymorphisms. *Proc Natl Acad Sci USA*. 2011;108(31):12839-12844.
- Broderick L, Gandhi C, Mueller J, et al. Mutations in complement factor I and potential mechanisms of neuroinflammation in acute hemorrhagic leukoencephalitis. *J Clin Immunol*. 2013;33(1):162-171.
- Peters VA, Joesting JJ, Freund GG. IL-1 receptor (IL-1R2) and its role in immune regulation. *Brain Behav Immun*. 2013;32:1-8.
- Nilsson SC, Sim RB, Lea SM, Fremeaux-Bacchi V, Blom AM. Complement factor I in health and disease. *Mol Immunol*. 2011;48(14):1611-1620.
- Shields AM, Pagnamenta AT, Pollard AJ, et al. Classical and non-classical presentations of complement factor I deficiency: two contrasting cases diagnosed via genetic and genomic methods. *Front Immunol*. 2019;10:1150.
- Sheerin NS, Kavanagh D, Goodship TJ, Johnson S. A national specialized service for England for atypical haemolytic uraemic syndrome—the first year's experience. *QJM*. 2016;109(1):27-33.
- Maga TK, Nishimura CJ, Waver AE, et al. Mutations in alternative pathway complement proteins in American patients with atypical uremic syndrome. *Hum Mutat*. 2010;31(6):E1445-E1460.
- Feng S, Eyler SJ, Zhang Y, et al. Partial ADAMTS13 deficiency in atypical hemolytic uremic syndrome. *Blood*. 2013;122(8):1487-1493.
- Tan PL, Garrett ME, Willer JR, et al. Systematic functional testing of rare variants: contributions of CFI to age-related macular degeneration. *Invest Ophthalmol Vis Sci*. 2017;58(3):1570-1576.
- Kavanagh D, Yu T, Shramm EC, et al. Rare genetic variants in the CFI gene are associated with advanced age-related macular degeneration and commonly result in reduced serum factor I levels. *Hum Mol Genet*. 2015;24(13):3861-3870.
- Bay JT, Katzenstein TL, Kofoed K, et al. Novel CFI mutation in a patient with leukocytoclastic vasculitis may redefine the clinical spectrum of complement factor I deficiency. *Clin Immunol*. 2015;160(2):315-318.
- Osborne AJ, Breno M, Borsa, et al. Structural validation of rare complement variants provides insights into the molecular basis of atypical hemolytic uremic syndrome and C3 glomerulonephritis. *J Immunol*. 2018;200(7):2464-2478.
- de Jong S, Volokhina EB, de Breuk A, et al. Effect of rare coding variants in the CFI gene on Factor I expression levels. *Hum Mol Genet*. 2020;29(14):2313-2324.
- Fadista J, Oskolkov N, Hansson O, et al. LoFtool: a gene intolerance score based on loss-of-function variants in 60706 individuals. *Bioinformatics*. 2017;33(4):471-474.
- Alba-Dominguez M, Lopez-Lera A, Garrido S, et al. Complement factor I deficiency: a not so rare immune defect. Characterizations of new mutations and the first large gene deletion. *Orphanet J Rare Dis*. 2012;7:42.
- Koelman DL, Brouwer MC, van de Beek D. Targeting the complement system in bacterial meningitis. *Blood*. 2019;142(11):3325-3337.
- Ahmad S, Singh P, Sharma A, et al. Transcriptome meta-analysis deciphers in immune response-associated gene signatures during sepsis. *Genes*. 2019;10(12):1005.
- Jesus AA, Goldback-Mansky R. IL-1 Blockade in autoinflammatory syndromes. *Annu Rev Med*. 2014;65:223-244.
- Federici S, Martini A, Gattorno M. The central role of anti-IL-1 blockade in the treatment of monogenic and multi-factorial autoinflammatory diseases. *Front Immunol*. 2013;4(351):1-12.
- Xie C, Jane-Wit D, Pober JS, et al. Complement membrane attack complex: new roles, mechanisms of action, and therapeutic targets. *Am J Pathol*. 2020;190(6):1138-1150.
- Diaz-del-Olmo I, Worboys J, Martin-Sanchez F, et al. Internalization of the membrane attack complex triggers NLRP3 inflammasome activation and IL-1 $\beta$  secretion in human macrophages. *Front Immunol*. 2021;12:1-14.
- Borhani-Haghghi A, Kardeh B, Banerjee S, et al. Neuro-Behçet's disease: an update on diagnosis, differential diagnosis, and treatment. *Mult Scler Relat Disor*. 2020;30:101906.
- Bucelli RC, Schaffer A, Musiek A, Yuan K. Neuro-sweet disease: a case of recurrent encephalitis and febrile neutrophilic dermatosis. *Neuro Clin Pract*. 2016;6(3):e20-e23.