

# UC Davis

## Dermatology Online Journal

### Title

Early onset drug-induced hypersensitivity syndrome with lymphopenia, hepatitis, and normal eosinophils induced by BRAF/MEK inhibitor after immune checkpoint inhibitor therapy

### Permalink

<https://escholarship.org/uc/item/37f1t16d>

### Journal

Dermatology Online Journal, 28(1)

### Authors

Buhle, Anna  
Johnson, Nathan  
Grider, Douglas  
[et al.](#)

### Publication Date

2022

### DOI

10.5070/D328157062

### Copyright Information

Copyright 2022 by the author(s). This work is made available under the terms of a Creative Commons Attribution-NonCommercial-NoDerivatives License, available at <https://creativecommons.org/licenses/by-nc-nd/4.0/>

Peer reviewed

# Early onset drug-induced hypersensitivity syndrome with lymphopenia, hepatitis, and normal eosinophils induced by BRAF/MEK inhibitor after immune checkpoint inhibitor therapy

Anna Buhle<sup>1</sup> BS, Nathan Johnson<sup>2</sup> MD, Douglas Grider<sup>3,4</sup> MD, Mariana Phillips<sup>3</sup> MD

Affiliations: <sup>1</sup>Virginia Tech Carilion School of Medicine, Roanoke, Virginia, USA, <sup>2</sup>Section of Dermatology, Department of Internal Medicine, Virginia Tech Carilion School of Medicine, Roanoke, Virginia, USA, <sup>3</sup>Section of Dermatology, Department of Internal Medicine, Virginia Tech Carilion School of Medicine, Roanoke, Virginia, USA, <sup>4</sup>Department of Basic Science Education, Virginia Tech Carilion School of Medicine, Roanoke, Virginia, USA

Corresponding Author: Mariana Phillips MD, 1 Riverside Circle, Suite 300, Roanoke, VA 24016, Tel: 540-581-0171, Email: [maphillips@carilionclinic.org](mailto:maphillips@carilionclinic.org)

## Abstract

Targeted therapy (BRAF/MEK inhibitors) is frequently employed in the treatment of metastatic melanoma following immune checkpoint inhibitor therapy inefficacy or intolerance. Although BRAF inhibitors are commonly associated with cutaneous eruptions, they rarely cause severe cutaneous adverse drug reactions such as drug-induced hypersensitivity syndrome (DIHS). Drug-induced hypersensitivity syndrome is a severe drug reaction characterized by extensive eruption often seen in conjunction with fever, facial edema, lymphadenopathy, eosinophilia, atypical lymphocytosis, and variable visceral organ injury characteristically beginning 2-8 weeks after initiating the causative drug. We report a case of atypical DIHS with reduced latency, mucosal involvement, lymphopenia, normal eosinophils, and no lymphadenopathy that occurred secondary to vemurafenib and cobimetinib therapy following melanoma progression while on pembrolizumab. Previous immune checkpoint inhibitor therapy has been associated with atypical DIHS in patients on BRAF/MEK inhibitors. Early recognition of the atypical clinical features of this hypersensitivity reaction is important so that drug discontinuation and corticosteroids can be initiated early.

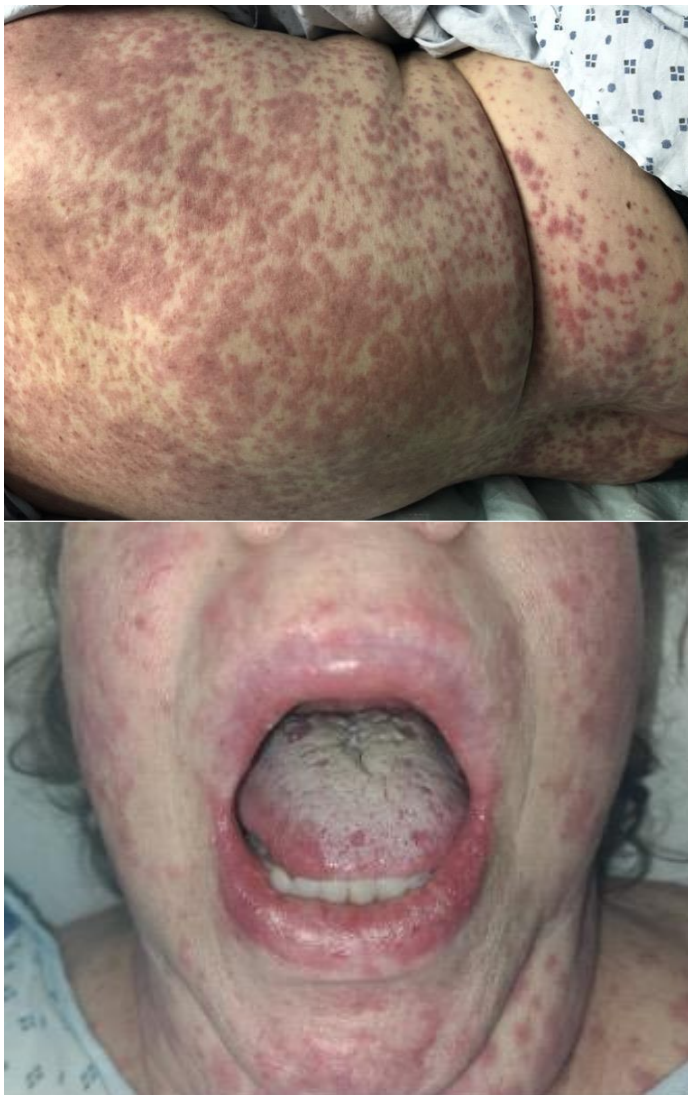
**Keywords:** DIHS, DRESS, drug, eosinophilia, hypersensitivity, immune, PD1, pembrolizumab, rash, vemurafenib

## Introduction

Vemurafenib is a targeted therapy used to treat metastatic melanoma with *BRAF* V600 driver mutations. BRAF inhibitors, such as vemurafenib, are usually used in combination with MEK inhibitors as this has been shown to improve clinical outcomes [1,2]. BRAF inhibitors are commonly associated with cutaneous eruptions. However, they only rarely cause severe cutaneous adverse reactions (SCARs) such as drug-induced hypersensitivity syndrome (DIHS). Drug-induced hypersensitivity syndrome, formerly known as drug reaction with eosinophilia and systemic symptoms (DRESS), is a drug reaction characterized by extensive cutaneous eruption often seen in conjunction with fever, facial edema, lymphadenopathy, eosinophilia, atypical lymphocytosis, and variable visceral organ injury characteristically beginning 2-8 weeks after initiating the causative drug. As their use in the treatment of metastatic melanoma has increased, several studies have documented an atypical DIHS presentation caused by BRAF/MEK inhibitors in the setting of previous immune checkpoint inhibitor therapy [2-7]. Presented is a patient with DIHS with reduced latency, mucosal involvement, lymphopenia, normal eosinophils, and absent lymphadenopathy secondary to vemurafenib and cobimetinib following a failure of pembrolizumab for the treatment of metastatic melanoma.

## Case Synopsis

A 67-year-old woman presented to the emergency department with a 2-day history of an extensive and progressive rash, high fevers, and elevated liver enzymes. The patient appeared ill but was not lethargic. Striking facial edema and erythema was noted. The eruption consisted of blanchable, slightly dusky and purpuric macules and papules involving the head, neck, trunk, groin, and extremities. Affected areas on her arms and back demonstrated a pseudotargetoid appearance (**Figure 1**). The eruption was not pruritic, painful, or tender to palpation. There were crusted erosions and ulcerations of the lips, gingiva, tongue, and oropharynx; she reported difficulty with swallowing

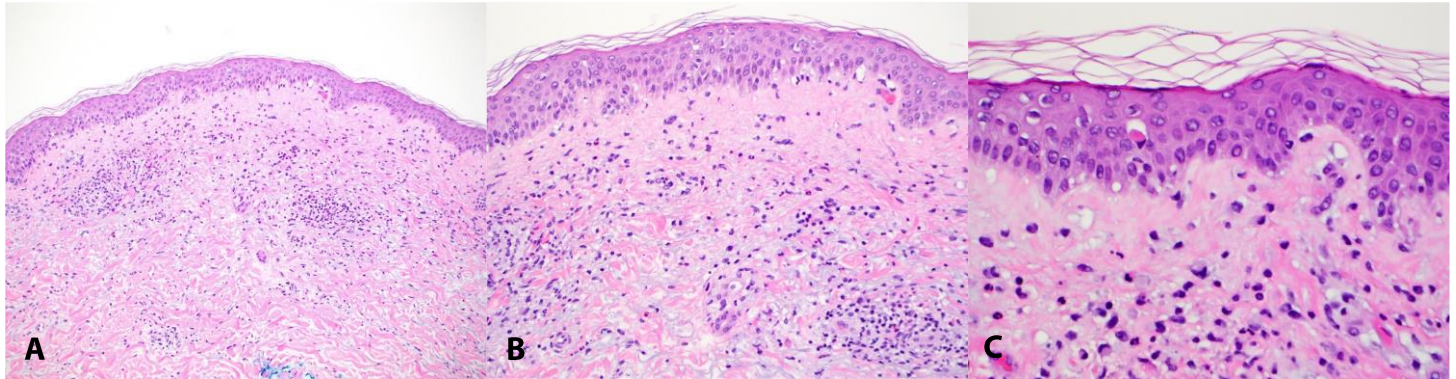


**Figure 1.** Patient with extensive morbilliform rash with facial involvement and ulceration of the oral mucosa.

due to pain (**Figure 1**). The conjunctiva and vaginal mucosa were unaffected. There was no cervical, axillary, or inguinal lymphadenopathy. Laboratory analysis showed elevated liver enzymes (AST 277IU/L; ALT 152IU/L), hyponatremia, severe lymphopenia (0.2K/ $\mu$ L), and normal eosinophils. Her RegiSCAR score was 3 (possible DRESS syndrome), [8]. The patient's past medical history was notable for metastatic melanoma for which she was initially treated with radiation followed by pembrolizumab. She had been treated with pembrolizumab for six months before transitioning to targeted therapy due to disease progression. Therapy with vemurafenib and cobimetinib commenced ten days before her rash onset. The patient's high fevers, severe morbilliform rash, mucositis, lymphopenia, and elevated liver enzymes were highly suggestive of a severe drug reaction and the initial differential diagnosis included toxic epidermal necrolysis (TEN) owing to the extensive oral mucosal involvement and dusky nature of the cutaneous eruption. Skin biopsy was performed and showed mild vacuolar alteration at the dermoepidermal junction with an underlying dermal lymphohistiocytic infiltrate and a few scattered neutrophils and eosinophils (**Figure 2**). A few apoptotic epidermal keratinocytes were seen but no epidermal necrosis noted, helping to exclude TEN (**Figure 2**). Both neutrophils and eosinophils were present in the deep dermal inflammatory infiltrate favoring the diagnosis of DIHS over erythema multiforme. The biopsy findings in this case are well within those previously reported for DIHS [9,10]. The patient was discontinued on vemurafenib/cobimetinib and started on high dose methylprednisone with subsequent rapid improvement in her liver enzyme elevations and lymphopenia. Her eruption and mucositis were markedly improved, but still present, at one-week follow-up. For further treatment of her melanoma, alternative BRAF inhibitors were not attempted and the patient was started on ipilimumab.

## Case Discussion

This report documents a patient who presented with DIHS following vemurafenib/cobimetinib therapy, highlighting the atypical presentation and reduced



**Figure 2.** Hematoxylin and eosin pathology, **A)** from the patient's abdomen with a basket-weave cornified layer, vacuolar alteration at the dermal-epidermal junction, and a dermal inflammatory infiltrate to the mid-dermis composed of a predominantly lympho-histiocytic infiltrate with a few eosinophils and neutrophils, 10 $\times$ . **B)** Higher power view from the patient's abdomen highlighting lymphocytes, histiocytes, neutrophils, and eosinophils infiltrating to the mid-dermis, 20 $\times$ . **C)** Biopsy from the patient's left arm highlighting an apoptotic epidermal keratinocyte in addition to the vacuolar alteration at the dermal-epidermal junction and the dermal inflammatory infiltrate, 40 $\times$ .

latency (10 days) from drug initiation to onset of DIHS. The lymphopenia, absent lymphadenopathy, and absent eosinophilia seen in this patient are strikingly similar to DIHS in other patients treated with immune checkpoint inhibitors followed by BRAF inhibitors [4,11]. In one meta-analysis comparing DIHS in patients taking BRAF inhibitors with and without prior immune checkpoint inhibition, patients with prior immune checkpoint inhibitor therapy were less likely to have lymphadenopathy (8.7% versus 43%), peripheral eosinophilia (26% versus 71%), and atypical lymphocytes (8.7% versus 50%). However, they found that the likelihood of lymphopenia was similar in the two groups (8.7% versus 14%), [11]. These findings suggest "immune priming" by an immune checkpoint inhibitor can increase the risk of an atypical DIHS presentation in patients undergoing BRAF/MEK inhibitor therapy [4]. Although the exact mechanism of this reaction is not known, it is believed that immune checkpoint inhibition predisposes to a stronger T cell-mediated drug reaction by blocking the negative regulation of T cells [5,12]. Among BRAF/MEK inhibitors, SCARs are most associated with vemurafenib, suggesting that vemurafenib is likely the cause of this patient's DIHS [3].

Among SCARs, DIHS classically occurs later than most, usually with onset 2-8 weeks following drug exposure. However, DIHS in patients treated with

BRAF inhibitors tends to occur earlier than DIHS caused by other drugs (less than two weeks). Furthermore, this relationship occurs at similar rates in patients with and without prior immune checkpoint inhibitor therapy [2,3,11]. Although it was previously speculated that prior immune checkpoint inhibitor therapy predisposed to DIHS with decrease latency, these results suggest that BRAF inhibitors specifically seem to cause the early onset DIHS seen in this patient population.

With limited alternative treatment options metastatic melanoma, rechallenge with alternative BRAF/MEK inhibitors or desensitization to the offending agent has sometimes been attempted following SCAR. In fact, there are several case studies demonstrating successful desensitization to vemurafenib or successful switch to an alternative BRAF inhibitor such as dabrafenib [2-4,13-16]. However, these challenges often require systemic corticosteroids and need to be done in a controlled environment as rebound symptoms have been shown to occur [3,4,11]. Although rechallenge and desensitization were not attempted with this patient, it may be an important therapeutic option in patients who are using BRAF/MEK inhibitors to treat metastatic melanoma and experience SCARs. Further research is still needed to evaluate the risks and benefits of attempting rechallenge/desensitization versus alternative therapies in the treatment of this disease.

As immune checkpoint inhibitors and targeted therapies become increasingly utilized in the treatment of metastatic melanoma, findings such as those seen in this patient make it increasingly important for clinicians to recognize the atypical DIHS. Distinguishing TEN and maculopapular eruptions from DIHS is important in patients treated with vemurafenib and other BRAF inhibitors. Although maculopapular rashes are very common in the setting of vemurafenib therapy—occurring in up to 59% of patients—DIHS is far less common. However, it carries a much more serious prognosis and requires prompt drug discontinuation, initiation of systemic corticosteroids, and inpatient as well as outpatient monitoring for weeks after rash onset. This case presented a diagnostic challenge in that elevated liver enzymes, lack of eosinophilia, severe oral mucosal involvement, and reduced latency were initially suggestive of TEN. Recognizing the atypical presentation of DIHS that occurs following

checkpoint inhibition led to prompt diagnosis and corticosteroid initiation on the night of admission.

## Conclusion

This report adds to the body of evidence prompting clinicians to consider atypical DIHS in patients who develop cutaneous eruptions soon after beginning BRAF/MEK inhibitor therapy. Unfortunately, many patients taking BRAF/MEK-inhibitor therapy are at the end of their therapeutic ladder for advanced melanoma. Therefore, further investigation should focus on determining if other agents within the same class of medications are safe to trial in patients who develop DIHS to a single BRAF inhibitor.

## Potential conflicts of interest

The authors declare no conflicts of interest.

## References

1. Long GV, Hauschild A, Santinami M, et al. Adjuvant Dabrafenib plus Trametinib in Stage III BRAF-Mutated Melanoma. *N Engl J Med*. 2017;377:1813-1823. [PMID: 28891408].
2. Brégeon B, Bernier C, Josselin N, et al. Drug reaction with eosinophilia and systemic symptoms syndrome induced by combination of vemurafenib and cobimetinib in melanoma: A series of 11 cases. *J Am Acad Dermatol*. 2019;80:558-562. [PMID: 30081108].
3. Torres-Navarro I, de Unamuno-Bustos B, Botella-Estrada R. Systematic review of BRAF/MEK inhibitors-induced Severe Cutaneous Adverse Reactions (SCARs). *J Eur Acad Dermatol Venereol*. 2021;35:607-614. [PMID: 32846030].
4. Rana J, Maloney N, Rieger K, et al. Drug-Induced Hypersensitivity Syndrome like Reaction with Angioedema and Hypotension Associated with BRAF Inhibitor Use and Antecedent Immune Checkpoint Therapy. *JAAD Case Reports*. 2021;13:147-151. [PMID: 34195327].
5. Lamiaux M, Scalbert C, Lepesant P, et al. Severe skin toxicity with organ damage under the combination of targeted therapy following immunotherapy in metastatic melanoma. *Melanoma Res*. 2018;28:451-457. [PMID: 29985833].
6. Imafuku K, Yoshino K, Ymaguchi K, et al. Nivolumab therapy before vemurafenib administration induces a severe skin rash. *J Eur Acad Dermatol Venereol*. 2017;31:e169-e171. [PMID: 27546003].
7. Naqash AR, File DM, Ziemer CM, et al. Cutaneous adverse reactions in B-RAF positive metastatic melanoma following sequential treatment with B-RAF/MEK inhibitors and immune checkpoint blockade or vice versa. A single-institutional case-series. *J Immunother Cancer*. 2019;7:4. [PMID: 30621779].
8. Kardaun SH, Mockenhaupt M, Roujeau JC. Comments on: DRESS syndrome. *J Am Acad Dermatol*. 2014;71:1000-1000.e2. [PMID: 25437959].
9. Orime M. Immunohistopathological Findings of Severe Cutaneous Adverse Drug Reactions. *J Immunol Res*. 2017;2017:6928363. [PMID: 29226159].
10. Ortonne N, Valeyrie-Allanore L, Bastuji-Garin S, et al. Histopathology of drug rash with eosinophilia and systemic symptoms syndrome: a morphological and phenotypical study. *Br J Dermatol*. 2015;173:50-58. [PMID: 25630796].
11. Maloney NJ, Rana J, Yang JJ, Zaba LC, Kwong BY. Clinical features of drug-induced hypersensitivity syndrome to BRAF inhibitors with and without previous immune checkpoint inhibition: a review. *Support Care Cancer*. 2022;30:2839-2851. [PMID: 34546454].
12. Arenbergerova M, Mrazova I, Horazdovsky J, et al. Toxic epidermal necrolysis induced by vemurafenib after nivolumab failure. *J Eur Acad Dermatol Venereol*. 2017;31:e253-e254. [PMID: 27739125].
13. Tahseen AI, Patel NB. Successful dabrafenib transition after vemurafenib-induced toxic epidermal necrolysis in a patient with metastatic melanoma. *JAAD Case Rep*. 2018;4:930-933. [PMID: 30320198].
14. Jeudy G, Dalac-Rat S, Bonniaud B, et al. Successful switch to dabrafenib after vemurafenib-induced toxic epidermal necrolysis. *Br J Dermatol*. 2015;172:1454-1455. [PMID: 25384395].
15. Pinard C, Mignard C, Samain A, Duval-Modeste AB, Joly P. Successful use of dabrafenib after the occurrence of drug rash with eosinophilia and systemic symptoms (DRESS) induced by vemurafenib. *JAAD Case Rep*. 2017;3:532-533. [PMID: 29296640].
16. Minor DR, Rodvien R, Kashani-Sabet M. Successful desensitization in a case of Stevens-Johnson syndrome due to vemurafenib. *Melanoma Res*. 2012;22:410-411. [PMID: 22828249].
17. Ros J, Muñoz-Couselo E. DRESS syndrome due to vemurafenib treatment: switching BRAF inhibitor to solve a big problem. *BMJ Case Rep*. 2018;2018:bcr2018224379. [PMID: 30275021].