

UCSF

UC San Francisco Previously Published Works

Title

Experimental Schistosoma haematobium pulmonary hypertension.

Permalink

<https://escholarship.org/uc/item/36t48542>

Journal

Pulmonary Circulation, 14(1)

ISSN

2045-8932

Authors

Kassa, Biruk

Fonseca-Balladares, Dara

Kumar, Rahul

et al.

Publication Date



2024

DOI

10.1002/pul2.12336

Peer reviewed

Experimental *Schistosoma haematobium* pulmonary hypertension

Biruk Kassa^{1,2} | Dara C. Fonseca-Balladares^{1,2} | Rahul Kumar^{1,2} |
Michael H. Lee^{1,2}  | Claudia Mickael³ | Linda Sanders³ | Kevin Nolan^{1,2} |
Brian B. Graham^{1,2} 

¹Department of Medicine, Lung Biology Center, Zuckerberg San Francisco General Hospital, San Francisco, California, USA

²Department of Medicine, University of California San Francisco, San Francisco, California, USA

³Department of Medicine, University of Colorado Anschutz Medical Campus, Aurora, Colorado, USA

Correspondence

Brian B. Graham, University of California San Francisco, 1001 Potrero Ave, Bldg 5, Room 5J1, San Francisco, CA 94127, USA.
Email: brian.graham@ucsf.edu

Funding information

American Heart Association; Congressionally Directed Medical Research Programs, Grant/Award Number: W81XWH2210457; American Thoracic Society; Cardiovascular Medical Research and Education Fund; National Heart, Lung, and Blood Institute, Grant/Award Numbers: K08HL168310, K01HL161024, P01HL152961, R01HL135872; United Therapeutics Corporation; Jenesis Innovative Research Award

Abstract

Whether all *Schistosoma* species cause pulmonary hypertension (PH) is unclear. Experimentally exposing mice to *Schistosoma haematobium* eggs caused PH, which was less severe than that induced by *S. mansoni* exposure. These findings align with the relatively uncommon reports of pulmonary arterial hypertension associated with *S. haematobium*.

KEYWORDS

parasitic infections, pulmonary hypertension, pulmonary hypertension experimental

INTRODUCTION

Schistosomiasis is a major cause of pulmonary arterial hypertension (PAH) worldwide.^{1,2} *Schistosoma mansoni* is the most prevalent species worldwide and causes intestinal schistosomiasis, whereas *Schistosoma haematobium* is the second most common and causes urinary schistosomiasis. Most schistosomiasis-PAH clinical reports involve *S. mansoni*, with limited information on PAH due to other species. One example is a 1990 report of a 21-year-old woman from Senegal presenting with dyspnea, *S. haematobium* eggs in the urine, and a mean

pulmonary artery pressure of 62 mmHg on right heart catheterization.³ Another is a 1964 report of two cases in Iraq, 25- and 40-year-old women, both presenting with dyspnea and edema, *S. haematobium* eggs in the urine or sputum, and right heart enlargement on chest X-ray and electrocardiography.⁴

Mice exposed to *S. mansoni* can model pulmonary hypertension (PH), with the severity correlating to the number of intrapulmonary eggs, the degree of lung inflammation, and proximity between vessels and regions of inflammation.⁵⁻⁷ Mice exposed to *Schistosoma japonicum*, endemic in Asia and the third most common

Biruk Kassa, Dara C. Fonseca-Balladares, and Rahul Kumar contributed equally to this study.

This is an open access article under the terms of the [Creative Commons Attribution-NonCommercial](https://creativecommons.org/licenses/by-nc/4.0/) License, which permits use, distribution and reproduction in any medium, provided the original work is properly cited and is not used for commercial purposes.

© 2024 The Authors. *Pulmonary Circulation* published by John Wiley & Sons Ltd on behalf of Pulmonary Vascular Research Institute.

species, also develop PH, albeit more mild than that induced by *S. mansoni*.⁸ Here, we tested if *S. haematobium* exposed mice can manifest PH, and evaluated the severity relative to other *Schistosoma* species.

METHODS

Animal models

All studies were approved by the UCSF IACUC, Protocol #AN181431. *S. haematobium* eggs were harvested from *S. haematobium* infected hamsters, whereas *S. mansoni* eggs were harvested from *S. mansoni* infected mice, provided by the Biomedical Research Institute, using standard techniques.⁹ Experimental mice were C57Bl6/J from Jackson, 6 to 8 weeks old, and female. Mice were intraperitoneally sensitized with 240 *Schistosoma* eggs per gram body weight, followed 14 days later by intravenous challenge with 175 *Schistosoma* eggs per gram body weight.

Experimental endpoints

Right heart catheterization was conducted to measure right ventricle systolic pressure (RVSP) and right ventricle (RV) hypertrophy using a standard open-chest technique with a pressure-volume catheter (Millar).^{10,11} The left lung was formalin-fixed and paraffin-embedded (FFPE) and the right lung was frozen. FFPE tissue was stained for α -smooth muscle actin by published protocol.⁸ Images were captured, the vascular media identified, the average outer and internal medial layer radii quantified, and the fractional medial thickness calculated as the radii difference divided by the external radius. We used the optical rotator¹² to estimate peri-egg granuloma volumes from hematoxylin and eosin-stained slides. Whole-lung lysates were prepared from frozen tissue macerated and sonicated in radioimmunoprecipitation assay buffer containing anti-proteases, and total protein content (Bradford assay) and interleukin (IL)-4 and IL-13 concentrations assessed by enzyme-linked immunosorbent assay (ELISA) (M4000B and M1300CB; R&D Systems).

Statistics

Prism (v9.5, GraphPad) was used. Normality was determined using Shapiro–Wilk testing, pairwise comparisons using unpaired *t* test or Mann–Whitney *U* test, and multiple comparisons using analysis of

variance (ANOVA) or ANOVA on ranks, with post-hoc testing. Details are in the text and figure legend. $p < 0.05$ was considered statistically significant. The data are available from the authors upon reasonable request.

RESULTS

We adapted our PH mouse model^{8,10,11} to use *S. haematobium* eggs. Mice were intraperitoneally sensitized with eggs, and 2 weeks later intravenously challenged with eggs by tail vein injection. Female mice were used, as *Schistosoma*-PAH occurs more commonly in females,¹ and we have not previously found differences between males and females. One week later, right heart catheterization and tissue collection was performed (Figure 1a). This approach models egg embolization to the lungs as occurs in chronic disease. We found that *S. haematobium*-exposed mice exhibited PH as compared to unexposed mice, evidenced by mean RVSP elevation from 24.3 to 26.9 mmHg (unpaired *t* test $p = 0.0113$; Figure 1b). There was no change in RV hypertrophy (Figure 1c), which is generally mild in this model, presumably related to the relatively short time course. An increase in medial thickness was observed when quantitatively analyzing the pulmonary vasculature (Figure 1d).

We previously found *S. japonicum* causes milder PH than *S. mansoni*.⁸ Now comparing *S. haematobium*-exposed mice, we observed a milder PH phenotype compared to *S. mansoni*, and similar to that previously observed with *S. japonicum*⁸: within the three groups, one-way ANOVA $p = 0.0003$, and post-hoc testing corrected for multiple comparisons was $p = 0.005$ between *S. mansoni* and *haematobium*; $p = 0.0029$ between *S. mansoni* and *japonicum*; and $p = 0.99$ between *S. haematobium* and *japonicum* (Figure 1b).

We quantified inflammation in whole lung lysates by ELISA for the Type 2 cytokines IL-4 and IL-13. *S. haematobium*-exposed mice showed a notable increase in both IL-4 and IL-13 compared to controls (Figure 1e,f). Compared to *S. mansoni*, IL-4 and IL-13 concentrations were both lower. Analyzing peri-egg granuloma volumes revealed that *S. haematobium*-exposed mice had smaller granulomas than *S. mansoni*-exposed mice, and comparable to *S. japonicum*-exposed mice⁸ (Figure 1g).

As dual exposure to *S. haematobium* and *mansoni* occurs,¹³ we explored the potential for cross sensitization. Mice sensitized to *S. mansoni* and then challenged with *S. haematobium* displayed a PH severity comparable

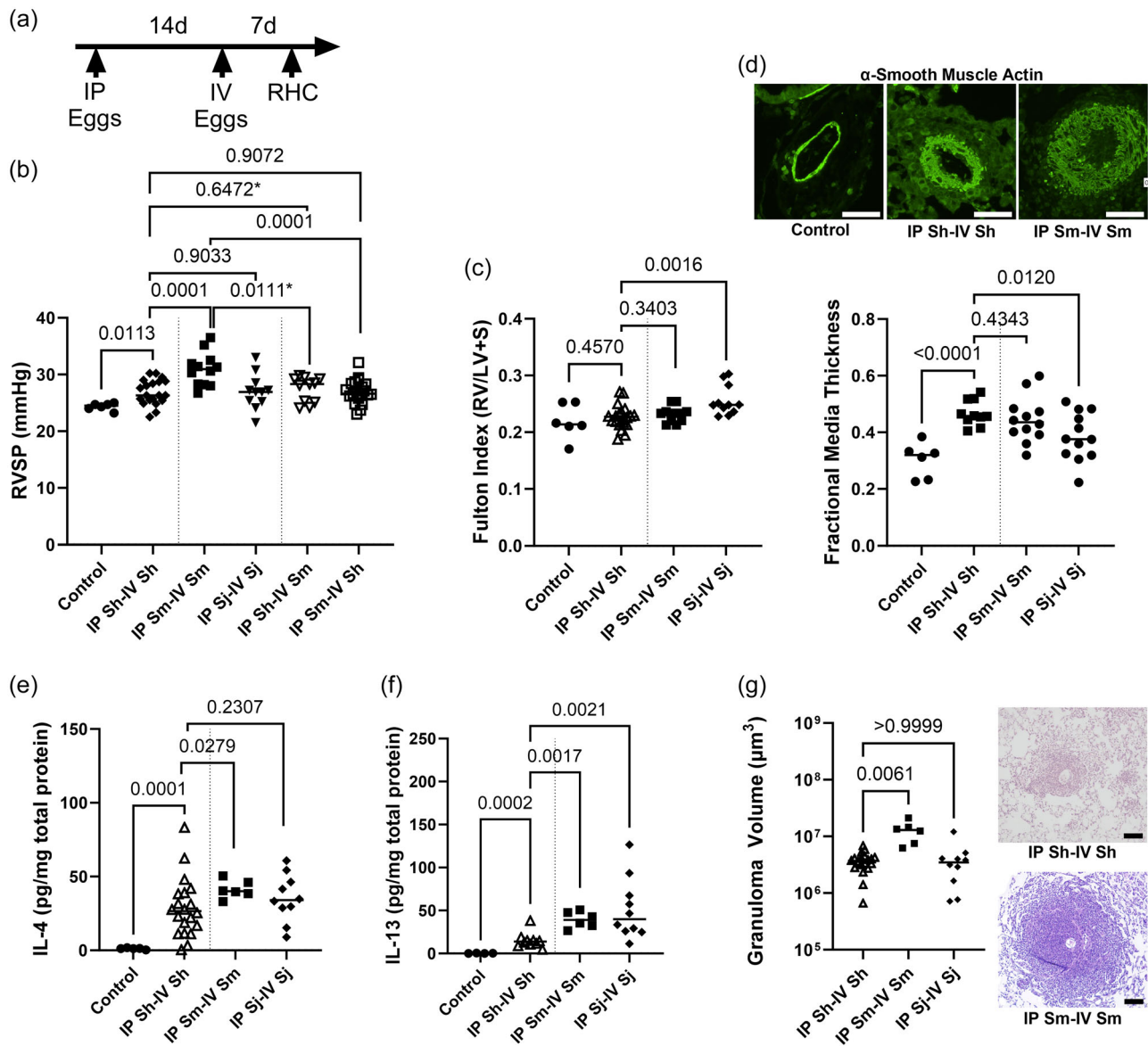


FIGURE 1 Pulmonary hypertension and the immune phenotype of *Schistosoma haematobium*-exposed mice. (a) Summary of model. (b) Right ventricle systolic pressure (RVSP; unpaired *t* test *p* values shown, except for those marked by * which are Mann-Whitney *U* test *p* values; *N* = 6–20/group). (c) Fulton index, a measure of right ventricle hypertrophy (Mann-Whitney *U* test *p* values shown; *N* = 6–20/group). (d) Fractional media thickness of the pulmonary vasculature (unpaired *t* test *p* values shown; *N* = 6–12/group), with representative images (scale bars = 50 μ m). Concentration of (e) interleukin (IL)-4 (Mann-Whitney *U* test *p* values shown; *N* = 6–20/group) and (f) IL-13 (Mann-Whitney *U* test *p* values shown; *N* = 6–10/group) in whole lung lysates assessed by enzyme-linked immunosorbent assay. (g) Estimated peri-egg granuloma volume (analysis of variance on ranks $p < 0.0001$; post-hoc Dunn's tests with *p* values shown; *N* = 6–20/group), with representative images (scale bars = 100 μ m). Note all the intraperitoneal Sj-IV Sj data shown here for comparison are from Kassa et al.⁸ IV, intravenous; RHC, right heart catheterization; Sh, *S. haematobium*; Sj, *Schistosoma japonicum*; Sm, *Schistosoma mansoni*.

to mice sensitized and challenged solely with *S. haematobium*, indicating *S. mansoni*'s ability to substitute for *S. haematobium* for sensitization (Figure 1b). However, mice sensitized to *S. haematobium* and challenged with *S. mansoni* had PH comparable to the *S. haematobium*-only group, and milder than *S. mansoni*-only, indicating that *S. haematobium* cannot effectively replace *S. mansoni* during sensitization.

DISCUSSION

In our study, mice experimentally exposed to *S. haematobium* developed PH, with a phenotype milder than that induced by *S. mansoni* and comparable to that induced by *S. japonicum*. The severity of *Schistosoma*-PH correlated with the degree of inflammation, as has been observed in other contexts.^{6–8,10} A prior mouse study also

reported *S. haematobium* causes smaller granulomas than *S. mansoni*.¹⁴ An unexpected observation was *S. haematobium* is less effective than *S. mansoni* at sensitizing before challenge with *S. mansoni*, whereas *S. haematobium* and *S. mansoni* were equally effective at sensitizing for *S. haematobium* challenge.

The three predominant *Schistosoma* species globally are *S. mansoni*, *haematobium*, and *japonicum*. There are other less common species restricted to specific locales, or that infect animals. Only *S. haematobium* causes urinary disease, as it homes to the bladder venous plexus where it lays its eggs. The other *Schistosoma* species home to the portal venous system. Despite differing clinical manifestations, *S. mansoni* and *haematobium* share 89% genetic similarity (synteny),¹⁵ and trace to a common ancestor 1 million years ago.¹⁶ In contrast, *S. japonicum*'s shared ancestry with *S. mansoni* dates back 3.8 million years, with a genetic similarity of only 67% and 52% to *S. mansoni* and *haematobium*, respectively.^{15,16} Differences in egg antigenicity likely modulates inflammation, and thus PH; this includes antigen ability to bind host immune receptors, and antigen quantity released by the egg.

We previously observed that *S. mansoni* and *japonicum* effectively cross-sensitize for each other.⁸ The observed relative inability of *S. haematobium* to cross-sensitize for *S. mansoni* is paradoxical given these two species have a closer genetic relationship than *S. japonicum*. Investigating this incongruence further, possibly through in vitro systems, might shed light on mechanisms by which the immune system responds to *Schistosoma* and drives PAH.

The absence of well-documented schistosomiasis-PAH reports from regions of the world where only *S. haematobium* is endemic suggests that this species might less frequently lead to PAH than *S. mansoni*. Alternatively, there could be limited testing or reporting in these regions. Publication of more reports or systematic screening would be helpful to determine disease prevalence, including distinguishing specific species and evaluating for dual infection where appropriate. For example, Farrag et al.¹⁷ screened 370 individuals in the Nile River delta, where both species are endemic, finding 8.6% of seropositive individuals had an estimated RVSP > 40 mmHg by echocardiography. The serologic test they used detects antibodies against both *S. haematobium* and *mansoni*, and clinical characteristics of the cohort included both hematuria (as from *S. haematobium*) and hepatomegaly (as from *S. mansoni*).

It is likely that chronic infection with any *Schistosoma* species can result in organ fibrosis and egg embolization through shunts to systemic veins and the

lungs. In chronic *S. haematobium* infection, the bladder is fibrosed; with intestinal *Schistosoma* species, preportal fibrosis develops. Differences in fibrosis and vascular networks between the liver and bladder could result in different egg burdens in the lungs, and thus disease prevalence.

A limitation of the *Schistosoma* mouse model is the number of eggs administered by body weight is much greater than that present in humans. In mice, PH severity correlates with egg burden.^{5,6} The higher dose facilitates studying experimental PH in a feasible duration of weeks, rather than the years it takes infected humans to develop PAH. Another limitation is we administered the same number of eggs for all *Schistosoma* species, whereas fecundity varies, with *S. japonicum* particularly laying more eggs per worm pair.¹⁸

In summary, our findings identify that mice exposed to *S. haematobium* can develop PH, albeit milder than *S. mansoni*-induced PH. This aligns with the sparse clinical documentation of PAH cases associated with *S. haematobium*.

AUTHOR CONTRIBUTIONS

Brian B. Graham conceived the study. Biruk Kassa, Rahul Kumar, and Brian B. Graham designed the study. Biruk Kassa, Dara C. Fonseca-Balladares, Rahul Kumar, Michael H. Lee, Claudia Mickael, Linda Sanders, and Kevin Nolan performed experiments. All authors interpreted the data. Brian B. Graham wrote the manuscript. All authors reviewed and approved the manuscript.

ACKNOWLEDGMENTS

The reagent was provided by the Schistosomiasis Resource Center of the Biomedical Research Institute (Rockville, MD) through NIH-NIAID Contract HHSN 272201700014I. This work was supported by grant funding provided by R01HL135872 and P01HL152961 to B. B. G.; W81XWH2210457 from the US Department of Defense, Fulbright Scholarship (12398-BR), and K08HL 168310 to M. H. L.; American Heart Association Grant 19CDA34730030, ATS Foundation/Pulmonary Hypertension Association Research Fellowship, the Cardiovascular Medical Research Fund and United Therapeutics Genesis Innovative Research Award to R. K.; R01HL135872-06S1 to D. F. B.; and 1K01HL161024-01 to C. M.

CONFLICT OF INTEREST STATEMENT

The authors declare no conflict of interest.

DATA AVAILABILITY STATEMENT

The data are available from the authors upon reasonable request.

ETHICS STATEMENT

All studies were approved by the UCSF IACUC, Protocol #AN181431.

ORCID

Michael H. Lee  <http://orcid.org/0000-0002-5739-8369>

Brian B. Graham  <http://orcid.org/0000-0001-7541-2585>

REFERENCES

- Sibomana JP, Campeche A, Carvalho-Filho RJ, Correa RA, Duani H, Pacheco Guimaraes V, Hilton JF, Kassa B, Kumar R, Lee MH, Loureiro CMC, Mazimba S, Mickael C, Oliveira RKF, Ota-Arakaki JS, Rezende CF, Silva LCS, Sinkala E, Ahmed HY, Graham BB. Schistosomiasis pulmonary arterial hypertension. *Front Immunol*. 2020;11:608883.
- Knafel D, Gerges C, King CH, Humbert M, Bustinduy AL. Schistosomiasis-associated pulmonary arterial hypertension: a systematic review. *Eur Respir Rev*. 2020;29(155):190089.
- Bourée P, Piveteau J, Gerbal JL, Halpen G. [Pulmonary arterial hypertension due to bilharziasis. Apropos of a case due to *Schistosoma haematobium* having been cured by praziquantel]. *Bull Soc Pathol Exot*. 1990;83(1):66–71.
- Damulji SF, Al-Khoury M, Johnstone RM. Cor pulmonale due to chronic infestation with *Schistosoma haematobium*. *J Trop Med Hyg*. 1964;67:220–3.
- Crosby A, Soon E, Jones FM, Southwood MR, Haghight L, Toshner MR, Raine T, Horan I, Yang P, Moore S, Ferrer E, Wright P, Ormiston ML, White RJ, Haight DA, Dunne DW, Morrell NW. Hepatic shunting of eggs and pulmonary vascular remodeling in *Bmpr2*^{+/-} mice with schistosomiasis. *Am J Respir Crit Care Med*. 2015;192(11):1355–65.
- Graham BB, Mentink-Kane MM, El-Haddad H, Purnell S, Zhang L, Zaiman A, Redente EF, Riches DWH, Hassoun PM, Bandeira A, Champion HC, Butrous G, Wynn TA, Tuder RM. Schistosomiasis-induced experimental pulmonary hypertension. *Am J Pathol*. 2010;177(3):1549–61.
- Kolosionek E, King J, Rollinson D, Schermuly RT, Grimminger F, Graham BB, Morrell N, Butrous G. Schistosomiasis causes remodeling of pulmonary vessels in the lung in a heterogeneous localized manner: detailed study. *Pulm Circ*. 2013;3(2):356–62.
- Kassa B, Lee MH, Kumar R, Mickael C, Sanders L, Tuder RM, Mentink-Kane M, Graham BB. Experimental schistosoma japonicum-induced pulmonary hypertension. *PLoS Negl Trop Dis*. 2022;16(4):e0010343.
- Tucker MS, Karunaratne LB, Lewis FA, Freitas TC, Liang YS. Schistosomiasis. *Curr Protoc Immunol*. 2013;103:19.
- Kumar R, Mickael C, Kassa B, Sanders L, Koyanagi D, Hernandez-Saavedra D, Freeman S, Morales-Cano D, Cogolludo A, McKee AS, Fontenot AP, Butrous G, Tuder RM, Graham BB. Th2 CD4+ T cells are necessary and sufficient for Schistosoma—pulmonary hypertension. *J Am Heart Assoc*. 2019;8(15):e013111.
- Kumar R, Mickael C, Kassa B, Gebreab L, Robinson JC, Koyanagi DE, Sanders L, Barthel L, Meadows C, Fox D, Irwin D, Li M, McKeon BA, Riddle S, Dale Brown R, Morgan LE, Evans CM, Hernandez-Saavedra D, Bandeira A, Maloney JP, Bull TM, Janssen WJ, Stenmark KR, Tuder RM, Graham BB. TGF- β activation by bone marrow-derived thrombospondin-1 causes Schistosoma- and hypoxia-induced pulmonary hypertension. *Nat Commun*. 2017;8:15494.
- Tandrup T, Gundersen HJG, Vedel Jensen EB. The optical rotator. *J Microsc*. 1997;186(Pt 2):108–20.
- WeerakoonGobert KGAD, Gobert GN, Cai P, McManus DP. Advances in the diagnosis of human schistosomiasis. *Clin Microbiol Rev*. 2015;28(4):939–67.
- Domingo EO, Warren KS. Granuloma formation around *Schistosoma mansoni*, *S. haematobium*, and *S. japonicum* eggs. Size and rate of development, cellular composition, cross-sensitivity, and rate of egg destruction. *Am J Trop Med Hyg*. 1970;19(2):292–304.
- Young ND, Jex AR, Li B, Liu S, Yang L, Xiong Z, Li Y, Cantacessi C, Hall RS, Xu X, Chen F, Wu X, Zerlotini A, Oliveira G, Hofmann A, Zhang G, Fang X, Kang Y, Campbell BE, Loukas A, Ranganathan S, Rollinson D, Rinaldi G, Brindley PJ, Yang H, Wang J, Wang J, Gasser RB. Whole-genome sequence of *Schistosoma haematobium*. *Nat Genet*. 2012;44(2):221–5.
- Claire J, Andrew S, Dobson P, Russell Stothard J. Out of animals and back again: Schistosomiasis as a Zoonosis in Africa. In: Rokni MB, editor. *Schistosomiasis*. Rijeka: IntechOpen; 2012, Ch. 11. <https://doi.org/10.5772/25567>
- Farrag A, El-Aroussy W, Zaghoul S, El-Guindy M, Yacoub M. Prevalence and severity of pulmonary hypertension in asymptomatic rural residents with schistosomal infection in the Nile Delta. *Trop Med Int Health*. 2012;17(1):112–8.
- Cheever AW. Comparison of pathologic changes in mammalian hosts infected with *Schistosoma mansoni*, *S. japonicum* and *S. haematobium*. *Mem Inst Oswaldo Cruz*. 1987;82:39–45.

How to cite this article: Kassa B, Fonseca-Balladares DC, Kumar R, Lee MH, Mickael C, Sanders L, Nolan K, Graham BB. Experimental *Schistosoma haematobium* pulmonary hypertension. *Pulm Circ*. 2024;14:e12336. <https://doi.org/10.1002/pul2.12336>